

Seyed Behrooz Mostofi



# Rapid Orthopedic Diagnosis

 Springer

# Rapid Orthopedic Diagnosis



# Rapid Orthopedic Diagnosis

Seyed Behrooz Mostofi

With 267 Figures



Springer

Seyed Behrooz Mostofi, FRCS (TR&Orth)  
Senior Registrar in Orthopaedics  
University of London  
UK

ISBN 978-1-84800-208-1 e-ISBN 978-1-84800-209-8  
DOI 10.1007/978-1-84800-209-8

British Library Cataloguing in Publication Data  
A catalogue record for this book is available from the British Library

Library of Congress Control Number: 2008925046

© Springer-Verlag London Limited 2009

Apart from any fair dealing for the purposes of research or private study, or criticism or review, as permitted under the Copyright, Designs and Patents Act 1988, this publication may only be reproduced, stored or transmitted, in any form or by any means, with the prior permission in writing of the publishers, or in the case of reprographic reproduction in accordance with the terms of licences issued by the Copyright Licensing Agency. Enquiries concerning reproduction outside those terms should be sent to the publishers.

The use of registered names, trademarks, etc. in this publication does not imply, even in the absence of a specific statement, that such names are exempt from the relevant laws and regulations and therefore free for general use.

Product liability: The publisher can give no guarantee for information about drug dosage and application thereof contained in this book. In every individual case the respective user must check its accuracy by consulting other pharmaceutical literature.

Printed on acid-free paper

9 8 7 6 5 4 3 2 1

springer.com

*To Kian and Tania Mostofi*

# Foreword

---

It is indeed a pleasure to write the foreword to this useful book which describes the most commonly used orthopedic clinical diagnostic tests to assist a wide audience within the medical world.

The organization of this book is easy to follow and logical. Each chapter begins with the patient's initial presentation, which is followed by an outline of the need to take account of specific variables in arriving at a differential diagnosis. The author underlines the importance of using the patient's own account as a valuable tool in reaching a diagnosis. Essential anatomy is included throughout the book. For ease of reference, all the chapters are similarly structured. Its style is simple and uncluttered, offering a step-by-step approach and avoiding overlong explanations.

All in all, this book fulfills the criteria of a reference book, a practical guide, and a succinct aide memoire for those preparing for exams. It is truly a text for everyone who must conduct orthopedic examinations, including medical students, general practitioners, and orthopedic residents. It is an outstanding contribution to the orthopedic literature.

Francis J. Hornicek, MD, PhD  
Chief, Orthopaedic Oncology Service  
Co-director, Center for Sarcoma and  
Connective Tissue Oncology  
Massachusetts General Hospital  
Harvard Medical School  
Boston, MA, USA

# Foreword

---

Judgment – the ability to make the correct decision for the individual patient is the hallmark of the good clinician. For the surgeon, this is “the knowing what to do” and when to do it or equally important “the knowing what not to do.” For the general practitioner, it is the art of distinguishing the ill from the worried well and knowing which patient needs specialist advice.

Good judgment derives from the ability to synthesize clinical experience, basic knowledge, and clinical diagnosis (i.e. the history and signs) with the interpretation of investigations to reach the best treatment option. This basic process of how to practice medicine dates back to the ancient Egyptians, probably to the era of the Pyramids. If you have never read the case histories from Mr. Edwin Smith Papyrus, your medical education is incomplete! The Egyptians only had history and signs plus clinical experience by which to reach a conclusion. Today, we have the power of modern science and a vast array of treatments. However while the advances in results are remarkable, errors remain.

All too often, failure is the result of history and signs, the areas in which the ancient Egyptians excelled. Only rarely is error due to the lack of high-powered knowledge. If you do not believe me, read the annual report of any medical defence society. Doctors who take a proper history, know how to examine, and keep good records do not often feature in these publications. If by mischance they are sued, they have a good defence, for it is clear they have provided conscientious care.

This book aims to remind, refresh, and improve the essential basic skills of history taking and clinical signs. With practice, they can indeed be “rapid.” Without these, “judgment” will be prone to error. I am reminded of a story about the late Professor Kessel of the Royal National Orthopaedic Hospital, who in being asked by his trainee “sir what shall I do with this x-ray?” replied “file it my boy, file it!” Imaging, however clever, does not tell you whether the pathology is relevant or, if relevant, how much it hurts. The knowledge and skills so clearly summarized and displayed in this book remains essential to good practice.

Frederick W. Heatley  
Emeritus Professor of Orthopaedics  
King's College  
London

# Preface

---

The first decade of the twenty-first century has witnessed the continuation of an explosion in our knowledge and understanding of all aspects of disease. Accompanying this has been the increasing reliance of clinicians on more and more complex imaging modalities and laboratory tests. It is the assertion of this author; however, that the fundamental skills of history taking and clinical examination remain the most important tools in reaching diagnosis.

This book aims to nurture these age-old skills of listening, observation, and examination by demonstrating their invaluable application in modern medical practice. In writing this book, I have drawn on not only my own experience, but on a wealth of advice from both those I have taught and those who have taught me. The omission of an exhaustive inventory of differential diagnoses for every clinical finding has been an intentional one; I strictly adhere to listing the most common conditions that a clinician will encounter to maintain practical value and clarity. For the same reason, I have also endeavored to describe the most useful and frequently performed clinical tests only, rather than the multitude of possible tests that exist for all conditions.

It is my hope that the resulting book will be useful for all those involved in the care of orthopaedic patients; for medical students in emphasising the most salient features of common presentations, for general practitioners in providing clear and concise information on which to base daily practice and for residents as a ready reference for day-to-day use and also for professional examinations.

Seyed Behrooz Mostofi  
London  
January 2008

# Acknowledgments

---

I acknowledge the help and advice I received from the following surgeons who have helped me enormously with constructive criticism and helpful suggestions:

**Richard J. de Asla M.D.**

Co-director, Foot and Ankle Service, Department of Orthopaedic Surgery, Massachusetts General Hospital *and* Instructor of Orthopaedics, Harvard Medical School, Boston, MA, USA

**S. Ali Mostoufi MD, FAAPMR, FAAPM**

Assistant Professor of Physical Medicine and Rehabilitation, Tufts University School of Medicine *and* Medical Director, Boston Spine Center, Boston, MA, USA

**Roderick G Wetherell MD FRCS**

Consultant Hand & Orthopaedic Surgeon, East Kent Hospitals NHS Trust. UK

**Philip L. Housden FRCS (Orth)**

Consultant Orthopaedic Surgeon, William Harvey Hospital, Ashford, Kent, UK

**Adrian J Carlos MBChB, MRCS, MSc**

Specialist Registrar in Orthopaedics, South East Thames, London Deanery, UK

**Barry Hinxes FRCS**

Consultant Orthopaedic Surgeon, Conquest Hospital, St. Leonards-On-Sea, East Sussex, UK

**Francis Lam FRCS (Tr & Orth)**

Consultant Orthopaedic Surgeon, Hillingdon Hospital, UK

**Benedict A Rogers MA, MSc, MRCP, MRCS**

Specialist Registrar in Orthopaedics, South West Thames, London Deanery, UK

**Seyed Behzad Mostofi DDS, MDS, FRACDS**

Consultant Oral & Maxillofacial Surgeon, Toronto, Canada

In addition:

I am grateful to Dr. Andrée Bates, whose unfailing support is a source of inspiration.

I am appreciative of the assistance from Dr. Joanna Maggs, who has critically read many versions of this manuscript.

I would like to express my appreciation to the many patients who agreed to have their photographs appear in this book.

I am grateful to Mrs. Emma Singh for being affable and extremely tolerant while modeling, and to Mr. Ravi Singh, consultant orthopaedic surgeon, for his photography skills.

I thank Mr. James Farley for his time and cooperation while modeling for some of the photographs.

I recognize the efforts of Mr. Abbas Rashid for his help in the preparation of the elbow chapter.

I offer special thanks for the help, support, and encouragement which I received from Mr. Grant Weston at Springer, who made the production of this book possible.

Seyed Behrooz Mostofi



# Contents

---

Foreword by <i>Francis J. Hornicek</i> .....	vii
Foreword by <i>Frederick W. Heatley</i> .....	ix
Preface .....	xi
Acknowledgments .....	xiii
1 Shoulder.....	1
2 Elbow .....	39
3 Wrist and Hand .....	61
4 Spine .....	133
5 Hip.....	189
6 Knee .....	217
7 Foot and Ankle.....	259
Index .....	313

# Chapter 1

## Shoulder

---

### **LISTEN**

#### **Mechanism of Injury (If Applicable)**

Certain mechanisms of injury result in characteristic patterns of structural damage.

#### **Common Examples**

Fall on outstretched hand → anterior dislocation of shoulder  
→ fracture of proximal humerus

Electrocution, seizures → posterior dislocation of shoulder

Holding on to an object while falling from a height (severe traction to the arm) → brachial plexus injury

Fall on to the elbow/blow to the tip of the shoulder → acromioclavicular joint (ACJ) dislocation/subluxation

#### **Age**

Young → instability  
→ ACJ dislocation

Middle age → calcifying tendonitis  
→ rotator cuff tear  
→ adhesive capsulitis  
→ ACJ arthritis

Old → rotator cuff tear  
→ glenohumeral joint arthritis  
→ cuff arthropathy (combination of cuff tear and arthritis)

**Pain**

**Site of Pain**

Localized pain (to which the patient can point with a finger (Figure 1.1)→ACJ pathology

Generalized pain (especially over deltoid) (Figure 1.2)→rotator cuff lesion  
→subacromial pathology

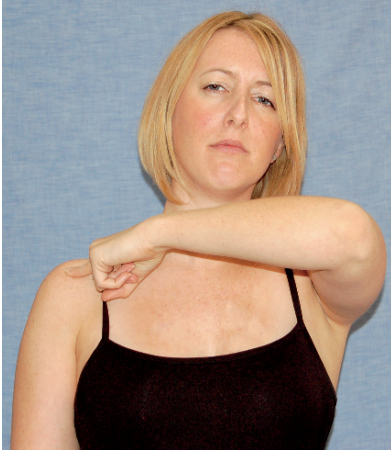

FIGURE 1.1.



FIGURE 1.2.

**What Activity Brings on the Pain?**

Pain during midrange of arm elevation → subacromial impingement  
→ rotator cuff lesion

Pain during terminal degrees of arm elevation → ACJ pathology

Pain during throwing → SLAP (Superior Labrum Anterior to Posterior) lesion

**Type of Pain**

Aching pain → degenerative changes

Sharp pain/catching pain → ACJ pathology  
→ subacromial impingement

Pain after activity → inflammatory arthropathy  
→ tendinosis

Night pain → rotator cuff lesion  
→ glenohumeral arthritis  
→ adhesive capsulitis  
→ infection  
→ tumor

**Stiffness**

Rest stiffness/ early morning stiffness → rheumatoid arthritis  
→ inflammatory arthropathy  
→ osteoarthritis

**LOOK****From the Front****Alignment:**

Ask the patient to stand facing you. In this position the patient should be able to keep both arms by the side.

Arm held in internal rotation → posterior dislocation of shoulder

Arm held in internal rotation with flexion of the wrist → Erb's palsy

Arm held in abduction → inferior dislocation of shoulder (luxatio erecta)

### **Shoulder Height**

Normally shoulders should be at the same level.

If one shoulder is higher than the other → painful shoulder  
→ Sprengel's deformity

If one shoulder is lower than the other (drooping shoulder)  
→ trapezius paralysis

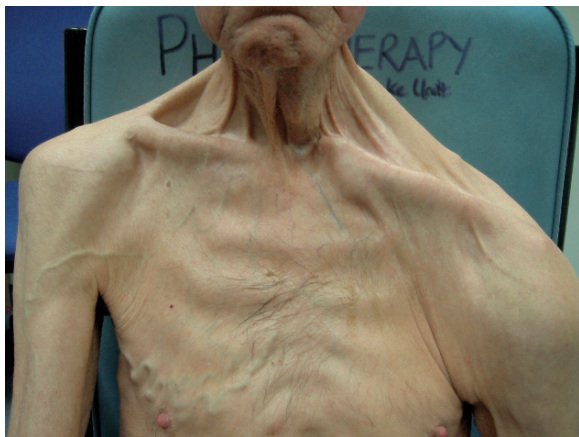### **Scars**

Comment on:

Position: posterior triangle incision may have caused spinal accessory nerve palsy  
Surgical or traumatic  
Healed with primary or secondary intention

### **Deformity and muscle wasting**

1. Trapezius muscles: These should be symmetrical. Wasting can be easily identified (Figure 1.3). Injury to spinal accessory nerve which supplies the muscle can occur in:
  - Dissection of the neck
  - Lymph node biopsy
  - Brachial plexus injuries



**FIGURE 1.3.** Injury to the spinal accessory nerve following a lymph node biopsy. Note drooping shoulder and wasting of trapezius. Prominent left SCJ is due to osteoarthritis.

2. Deltoid: Makes the contour of the shoulder. Anterior and middle fibers are best visualized from the front.
  - Flattening of the shoulder → anterior dislocation of the shoulder (causes prominent lateral edge of the acromion)
  - Swelling of deltoid → fractured neck of humerus
  - Atrophy of deltoid → axillary nerve injury
3. Acromioclavicular joint: Prominence of the ACJ is usually easy to spot (Figure 1.4). It varies between individuals and may be normal. Pathological causes of prominent ACJ:
  - Subluxation/dislocation
  - Degenerative arthritis
  - Chronic/acute inflammation
4. Clavicle: A subcutaneous bone, but may be difficult to see its length in obese individuals.
  - Asymmetry of clavicle → fracture/non-union

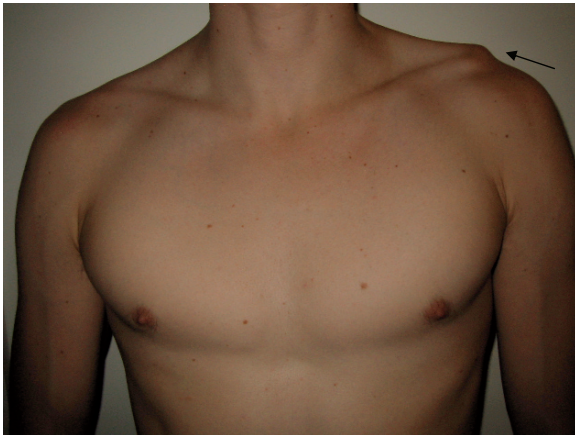


FIGURE 1.4. Subluxation of left ACJ (*black arrow*).

5. Sternoclavicular joint: this is easily seen in most patients though more difficult in the obese.

If SCJ is more prominent →

Anterior dislocation/subluxation of SCJ as a result of trauma or subsequent to incorrect internal fixation of the clavicle (Figures 1.5)

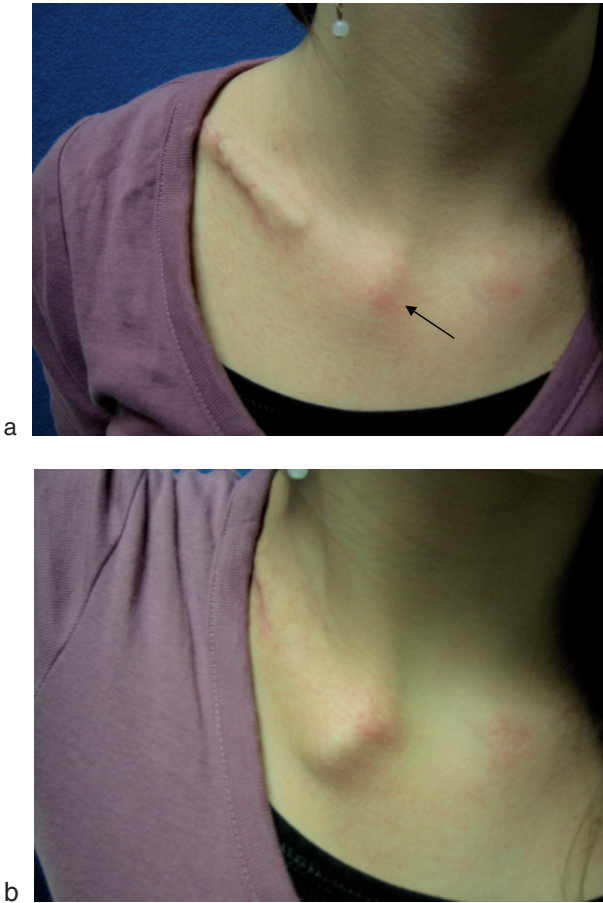

FIGURE 1.5. Subluxation of right SCJ. (a) Note the surgical scar, subcutaneous plate and prominence of SCJ. (b) On shoulder abduction, the subluxation is more visible.

- Infection
- Arthritis and osteophyte formation
- Tumors
- If SCJ less prominent → posterior dislocation of SCJ

### **From the Side**

If ACJ prominent → dislocation/subluxation

Deltoid: Makes the contour of the shoulder. Middle fibers are best visible from the side.

If acromion prominent

- Anterior dislocation of the shoulder
- Atrophy of deltoid

### **From Behind**

1. Trapezius muscles: These should be symmetrical. Wasting can be easily identified.
  - Injury to spinal accessory nerve which supplies the muscle can occur in:
    - Dissection of the neck
    - Lymph node biopsy
    - Brachial plexus injuries
2. Deltoid: Makes the contour of the shoulder. Middle and posterior fibers are best visualized from behind.
  - Flattening (squaring off) of the shoulder → anterior dislocation of the shoulder (causes prominent lateral edge of the acromion)
  - Swelling of deltoid → fracture neck of humerus
  - Atrophy of deltoid → axillary nerve injury
3. Scapula: This is the key structure while inspecting the shoulder joint from behind.
  - Size and position:
    - Prominent, small and high scapula → Sprengel's deformity (congenital elevation of the scapula)



**Borders of scapula:**

The scapula has three borders: superior, medial and lateral (Figure 1.6a). All are well covered by various muscles in normal individuals. Prominent borders means there is an atrophy of the muscles and this gives the vital clue to the possible diagnosis, especially in longstanding cases.

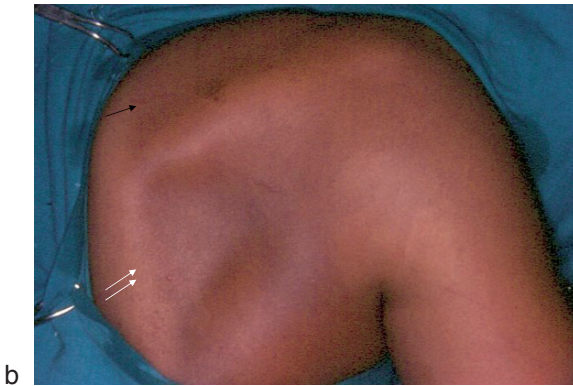

FIGURE 1.6. (a) Borders of scapula. (b) Sever atrophy of supraspinatus (*black arrow*) and infraspinatus (*white arrows*) of the right shoulder. Spine of scapula is easily visible.

**Superior border:** This is further divided by the spine of the scapula. The supraspinatus muscle lies in the superior fossa. The infraspinatus and teres minor muscles fill the infraspinatus fossa. Atrophy of these muscles make the spine of the scapula more prominent (Figure 1.6b), despite the fact that the trapezius covers the supraspinatus completely.

**Prominent spine of scapula:**

Atrophy of supraspinatus/trapezius (above the spine of the scapula) → rotator cuff tear

→ suprascapular nerve palsy (entrapment at the suprascapular notch)

Infraspinatus and teres minor muscles (below the spine of the scapula) → rotator cuff tear

→ suprascapular nerve palsy (entrapment at the spinoglenoid notch)

**Medial border:** This is covered by the serratus anterior, trapezius and rhomboid muscles. The serratus anterior is the main muscle which stabilizes the scapula against the chest wall.

**Prominent medial border:**

Internal rotation of the arm (normal)

Tight posterior and/or inferior capsule of the shoulder joint

Atrophy of serratus anterior/ trapezius/ rhomboid muscle

**Lateral border:** This is covered by the latissimus dorsi.

**Prominence of lateral border of scapula:**

Atrophy of latissimus dorsi → brachial plexus injury  
(Thoracodorsal nerve C6, 7, 8 nerve roots)

## FEEL

Patient in sitting position in front of a mirror, with examiner standing behind the patient looking at his face in the mirror.

## Sternoclavicular Joint

Start your palpation in the middle of the clavicle and move medially toward the joint. The SCJ is 1.5cm to 2cm lateral to the middle of the sternal notch. Tenderness may be present due to:

Injury

Infection

Tumor

**Clavicle**

Run your fingers along the clavicle. Tenderness or swelling may be due to:

- Fracture
- Non-union

**ACJ**

Follow the clavicle laterally to its end. Usually one can feel the articulation between the acromion and the clavicle. If you are not sure, grasp the patient's elbow with one hand and push ever so gently upward while your index finger is placed over the acromion and clavicle to detect the subtle movement in the joint.

**Coracoid**

This can be felt 2 cm inferior to the junction between the middle and lateral thirds of the clavicle. Its tenderness may signify adhesive capsulitis due to involvement of the coracohumeral ligament or pectoralis minor enthesopathy.

**Coracoclavicular Ligament**

As the name suggests, it runs between the coracoid and the lateral end of the clavicle. It is important to check it for tenderness once you have palpated the acromion. It is helpful to distinguish between types I and II of ACJ injuries if tenderness is present (type II) (Figure 1.7).

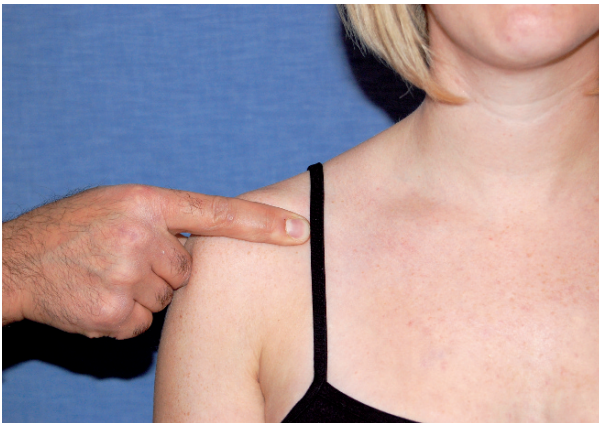

FIGURE 1.7. Coracoclavicular ligament.

## Acromion

The anterior edge of the acromion is lateral to the ACJ. The posterolateral edge is easily felt if you run your thumb backward as you follow the curve of the deltoid muscle. Hold the acromion between your index finger and thumb. It is much larger than you may have thought.

If painful:

Fracture

Os acromiale

### Os acromiale

An ossification center that fails to unite to the acromion.

Eliciting the tenderness over the anterior and lateral to the acromion is more useful. To facilitate the palpation, passively extend the arm.

If painful:

Subacromial bursitis

Rotator cuff tear (variable)

## Biceps Tendon

Hold the arm in 10° of internal rotation and run your thumb just distal to the anterior edge of the acromion. It is often very difficult to palpate the biceps tendon as it lies deep to the deltoid muscle. Tenderness in the area 1–4 cm distal to the anterior edge of the acromion is considered as biceps tendinitis.

## Trapezius

Tenderness and trigger points may be elicited, which are usually associated with cervical spine pathology.

## Range of Movement

Active movements are inspected first from the front and then from behind for scapulothoracic and scapulohumeral rhythm. If you observe a difference in the range of movement between the two shoulders, assist the patient and passively take the arm through the remaining range of movement. This is a passive range of movement.

**Forward Flexion**

This occurs in the sagittal plane. Whilst the patient is sitting or standing, ask him to lift the arm as far as possible (Figure 1.8).

Normal range: 160–180°

If limited → arthritis

→ adhesive capsulitis

→ rotator cuff tear

*Note: Shoulder surgeons use the term forward elevation. This movement is forward flexion performed in the most comfortable plane for the patient; usually about 30° from the sagittal plane.*



FIGURE 1.8. Forward flexion.



FIGURE 1.9. Abduction.

### Abduction

This occurs in the coronal plane. While the patient is sitting or standing, ask him to lift the arm sideways as far as he can (Figure 1.9). Observe the rhythm and overall movement. The glenohumeral movements account for 0–90° of abduction. The initial abduction occurs entirely at the glenohumeral joint and then the scapula starts to rotate as the arm is abducted further.

The ratio of glenohumeral to scapulothoracic movements is usually 2:1 between 30–90° of abduction. The last 60° of abduction occurs entirely at the scapulothoracic joint.

Pressing firmly on the glenohumeral joint eliminates scapulothoracic movement, while making it possible to assess the passive range of movements.

Normal range of movement: 160–180°

Decreased in:

Arthritis of the glenohumeral joint

Adhesive capsulitis

If abduction is painful, note the degree of abduction when the pain is elicited.

Pain only between 60–120° (Painful arc) → impingement  
→ rotator cuff tear

Pain in terminal degrees of abduction → ACJ pathology

If the patient cannot initiate abduction → weakness of deltoid  
→ massive rotator cuff tear

*Note: If the patient cannot abduct the arm, he will try to do so by shrugging the shoulder, thus substituting / supplementing the glenohumeral movement with scapulothoracic abduction.*

### **Adduction**

Ask the patient to put the hand over the opposite shoulder. Pain in this movement is usually due to ACJ pathology (Figure 1.10). The patient is unable to adduct the arm in anterior dislocation of the shoulder. Passive adduction is an important clinical test to determine if the humeral head is located immediately after reduction of the shoulder joint.

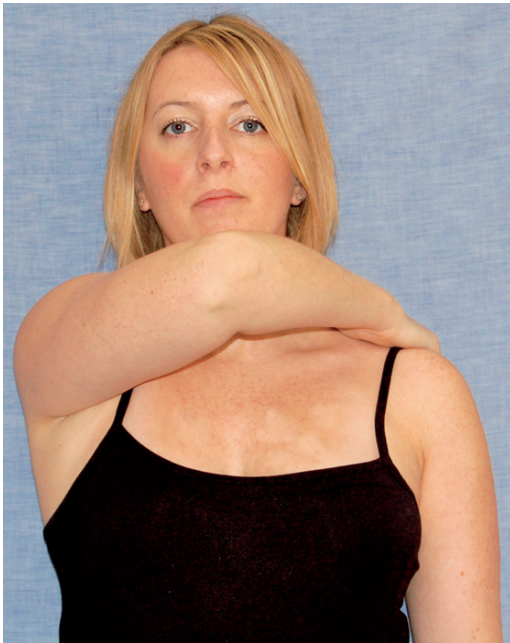

FIGURE 1.10. Adduction.

### **External Rotation**

Ask the patient (sitting or standing) to bend the elbow to 90° of flexion, while keeping it by the side and externally rotating the forearm (Figure 1.11). It is often necessary to maintain the position



of the patient's arm by gently putting your hand on the lateral aspect of the elbow to prevent abduction. External rotation can also be measured with the shoulder abducted to  $90^\circ$  (Figure 1.12).



FIGURE 1.11. External rotation.

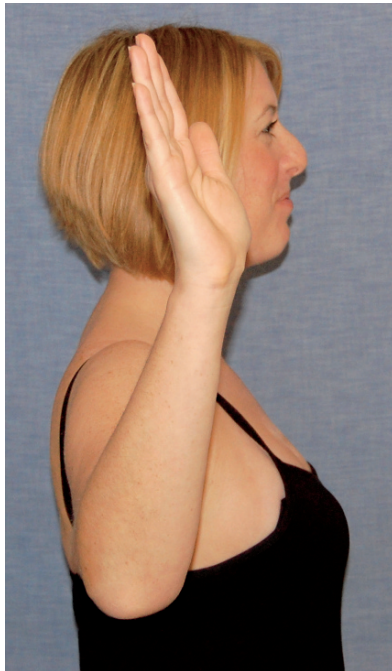

FIGURE 1.12. External rotation in abduction.



Normal range of movement: 45–90°

Increased passive external rotation → Massive rotator cuff tear  
involving subscapularis

Decreased external rotation → Adhesive capsulitis  
→ Glenohumeral arthritis  
→ Posterior dislocation of the shoulder (Rowe's sign)

### **Internal Rotation**

The patient is asked to reach up his back with the back of his hand. The vertebral level reached is noted and compared with the other side. This is a complex movement of internal rotation and extension of the shoulder (Figure 1.13).

### **Spinous Process Levels**

Spine of scapula: T3

Inferior angle of scapula: T7

Iliac crest: L4–5

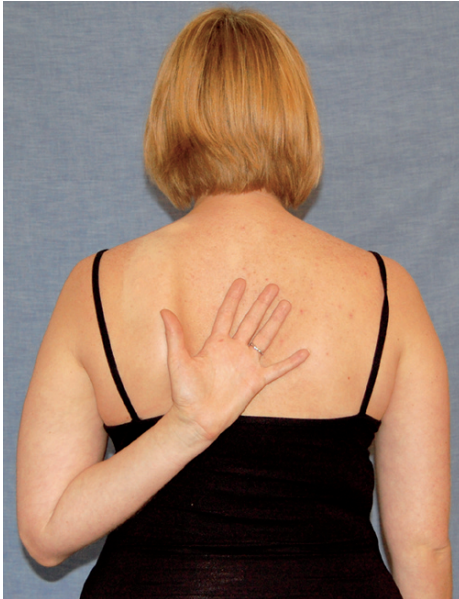

FIGURE 1.13. Internal rotation.

Normal level: T7–T9

Internal rotation can also be measured with the shoulder abducted to 90° (Figure 1.14).

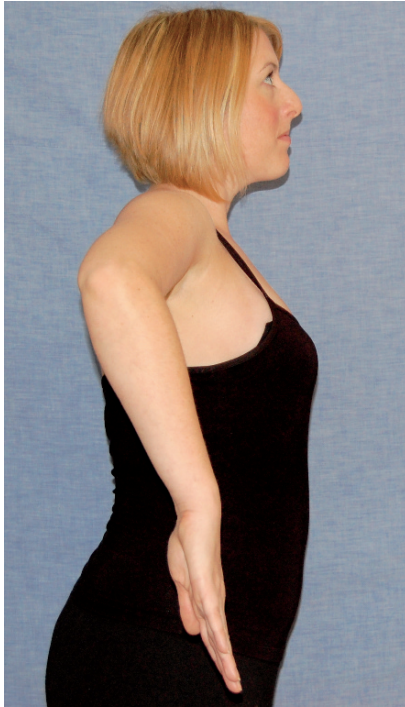

FIGURE 1.14. Internal rotation in abduction.

## Muscle Testing

### Trapezius (Spinal Accessory Nerve C3,4)

Stand behind the patient and ask him to shrug his shoulders. Contraction of the trapezius is seen and compared with the opposite side. (Figure 1.15)

Muscle power is tested throughout this book according to the MRC grading scale.

### Medical Research Council Scale

Grade	Description
-------	-------------

0	no contraction
1	flicker or trace of contraction
2	active movement with gravity eliminated
3	active movement against gravity
4	active movement against gravity and resistance
5	normal power

The inferior fibers are assessed by asking the patient to push against the wall. If weak or paralyzed, *rotary* winging of the scapula is observed, in which the inferior angle of the scapula moves laterally and away from the midline.

Cause of weakness:

Injury during dissection of the neck /lymph node biopsy

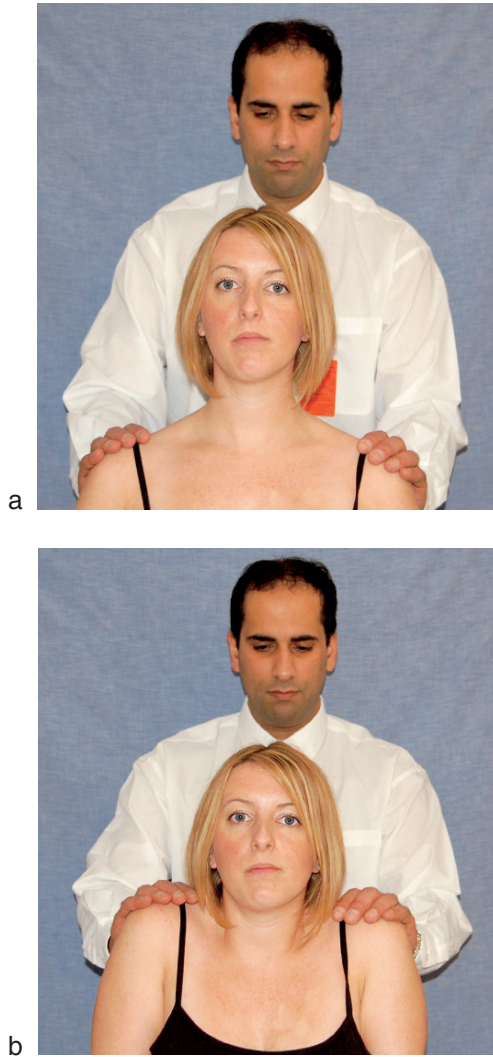


FIGURE 1.15. (a) Assessing the trapezius muscle. Ask the patient to “shrug the shoulders.” (b) The power can be assessed by applying resistant.

**Serratus Anterior (Long Thoracic Nerve C5,6,7)**

Stand behind the patient and ask him to push against the wall with arms at the level of the shoulder. If weak or paralyzed, the medial border of the scapula moves away from the chest wall (scapular winging) (Figure 1.16).

If the patient is unable to lift the arm to push the wall due to weakness of other muscles, the examiner passively lifts the arm and holds it in the desired position and then asks the patient to push against the wall.

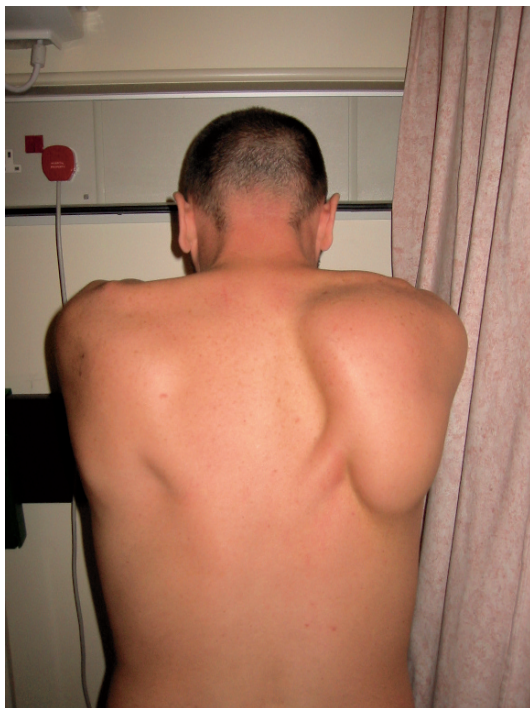

FIGURE 1.16. Winging of right scapula due to wasting of serratus anterior. This fireman sustained a traction injury to right arm while falling from a height.

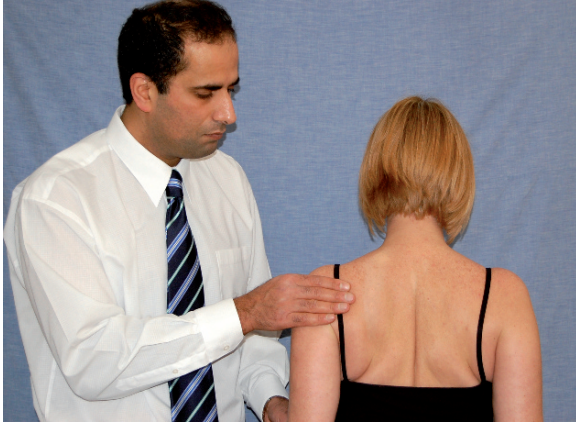

FIGURE 1.17. Assessing the rhomboid.

**Rhomboid (Dorsal Scapular Nerve C5)**

The patient is asked to pull the shoulders back, while the examiner applies resistance to the spine of the scapula (Figure 1.17).

**Latissimus Dorsi (Thoracodorsal Nerve C6,7,8)**

Ask the patient to abduct the arm to 90°. The examiner applies resistance to the point of the elbow and asks the patient to pull the elbow down to the side. The other hand feels for the contract-muscle (Figure 1.18).

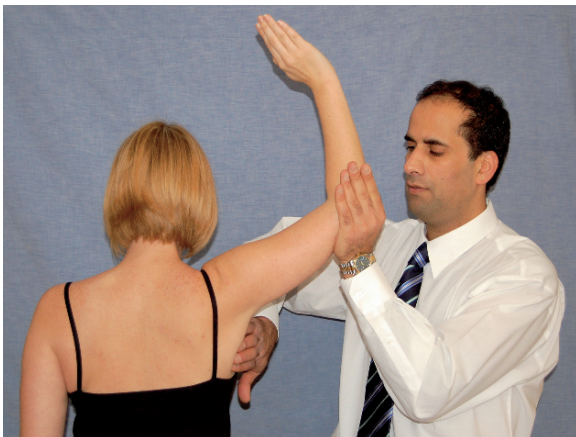

FIGURE 1.18. Assessing the Latissimus dorsi.

**Deltoid (Axillary Nerve C5, 6)**

Ask the patient to abduct the shoulder to 90° and hold the position. The anterior, middle, and posterior fibers are now palpable.

If the patient is unable to abduct the shoulder, either due to pain (after dislocation of the shoulder or surgery) or injury to the axillary nerve, the following method is very useful.

The anterior fibers of the deltoid assist flexion. To assess the anterior fibers, stand facing the patient. Put the arm in slight flexion and ask the patient to try to flex it further while you apply resistance just above the elbow. Your other hand is placed over the deltoid to palpate the contracture of the muscle (Figure 1.19a).

The middle fibers of the deltoid are pure abductors. To assess the middle fibers, stand facing the patient. Put the arm in slight abduction and ask the patient to try to abduct it further while you apply resistance just above the elbow. Your other hand is placed over the deltoid to palpate the contracture of the muscle (Figure 1.19b).

Likewise, to assess the posterior fibers which assist extension, stand facing the patient. Put the arm in slight extension and ask the patient to try to extend it further while you apply resistance just above the elbow. Your other hand is placed over the deltoid to palpate the contracture of the muscle (Figure 1.19c).

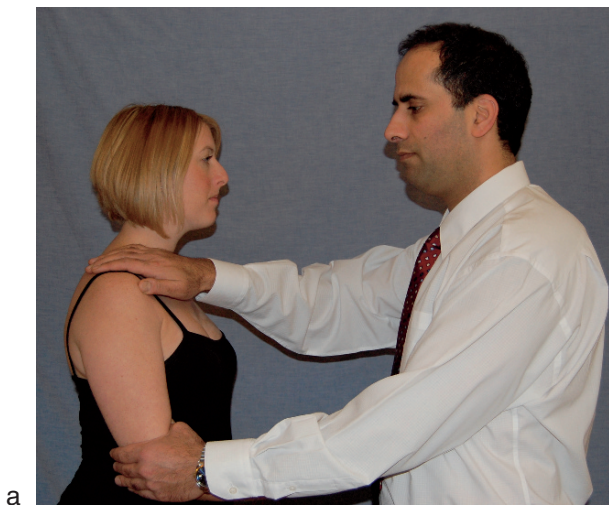

FIGURE 1.19. (a) Assessing the anterior fibers of deltoid. (b) Assessing the middle fibers of deltoid. (c) Assessing the posterior fibers of deltoid.



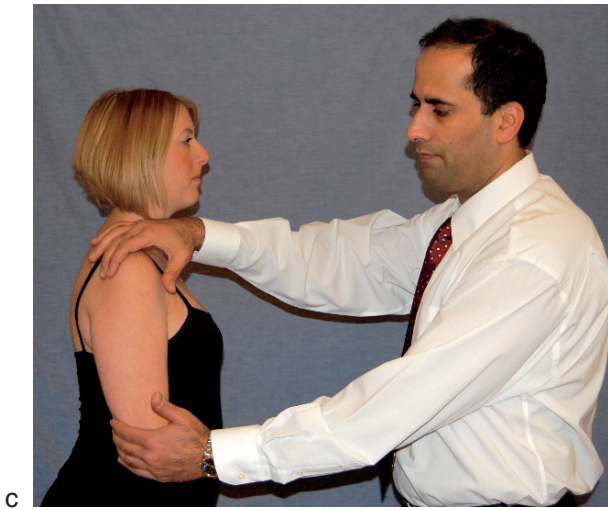
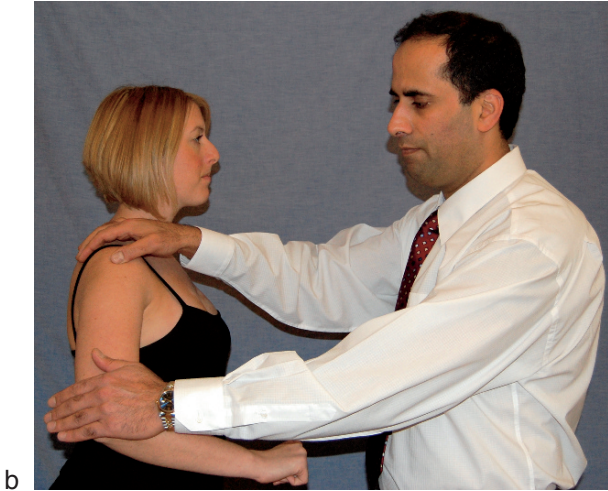
FIGURE 1.19. Cont'd.



**Pectoralis major (Lateral Pectoral Nerve C5, 6)**

Stand facing the patient, who is instructed to place the hands on the hips and press firmly. The tendon is often visible or can be palpated in the anterior axillary fold (Figure 1.20).

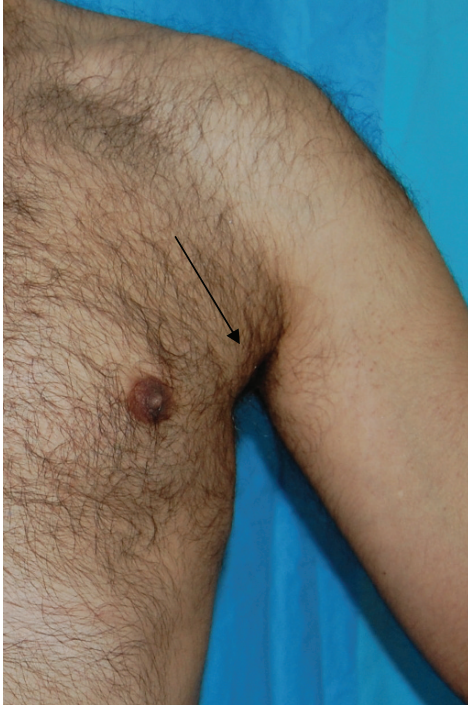

FIGURE 1.20. Pectoralis major tendon.

**Rotator Cuff**

The rotator cuff, consists of the tendons of four muscles: subscapularis, supraspinatus, infraspinatus and teres minor.

**Subscapularis (Suprascapular Nerve C5, 6)**

Stand behind the patient. The patient is asked to place the back of his hand into the small of the back (to eliminate the action of pectoralis major). Then the patient is asked to hold the hand away from the back (Figure 1.21). If he is able to do so, it means the subscapularis is functioning (negative lag test). The examiner then pushes against the patient's distal forearm toward the spine to assess the power. This is called Gerber's lift off test.

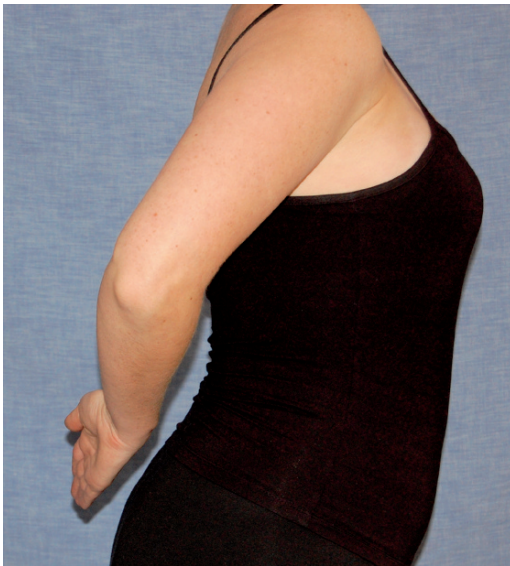


FIGURE 1.21. Assessing the subscapularis.

In patients who cannot internally rotate due, for example, to osteoarthritis, ask the patient to push his hands on the abdomen firmly and bring the elbows forward. In weakness of the subscapularis (positive test), the patient is unable to bring the elbows forward and the arm falls posterior to the coronal plane of the body. To assess the power, the examiner applies resistance to the elbow anteriorly. This is the Napoleon belly press test (Figure 1.22).

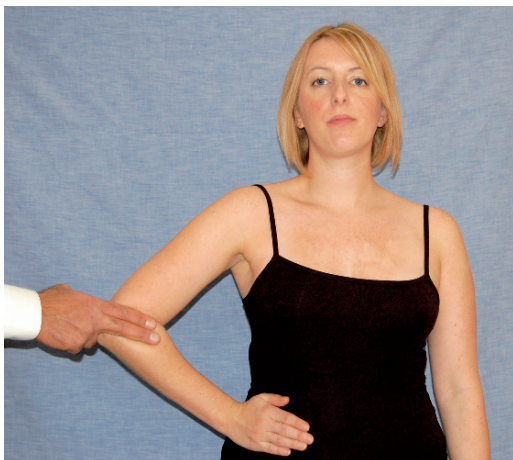

FIGURE 1.22. Napoleon belly press test.

**Supraspinatus (Suprascapular Nerve C5, 6)**

Stand facing the patient. Place the patient's arm in 30° of abduction and 30° of forward elevation (in the plane of the scapula) with thumb facing down (position of emptying a can). The examiner then applies resistance, while asking the patient to maintain the position. The examiner can feel the muscle contraction with the other hand (Figure 1.23). This is Jobe's or the empty can test.

For the lag test (Drop arm sign), the shoulder is forward elevated to 90° in the scapular plane and the patient is asked to hold the arm in that position. In the presence of weakness or a tear, the patient is unable to do so and the arm drops down with minimal control.

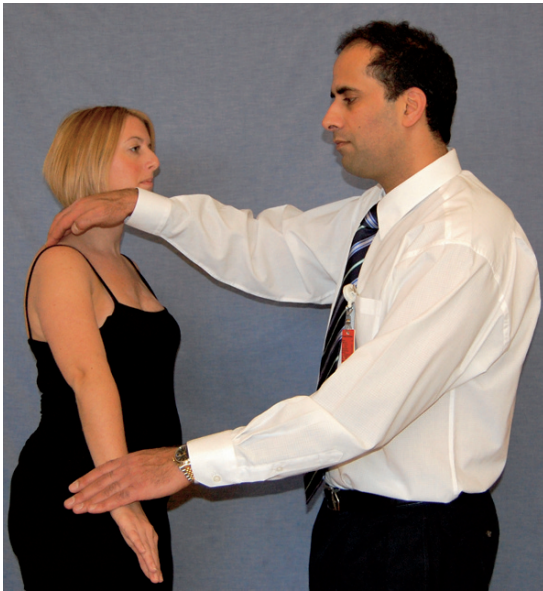

FIGURE 1.23. Jobe's test.

**Infraspinatus (Suprascapular Nerve C5, 6) and Teres Minor (Axillary Nerve C5, 6)**

These two muscles are tested together.

Ask the patient (sitting or standing) to bend the elbow to 90° of flexion and keep it by his side. It is often necessary to maintain the position of the patient's arm by gently putting your hand on the lateral aspect of the elbow. Then ask the patient to externally rotate the forearm while you apply resistance to the distal forearm (Figure 1.24). The examiner can feel the muscle contraction with the other hand.

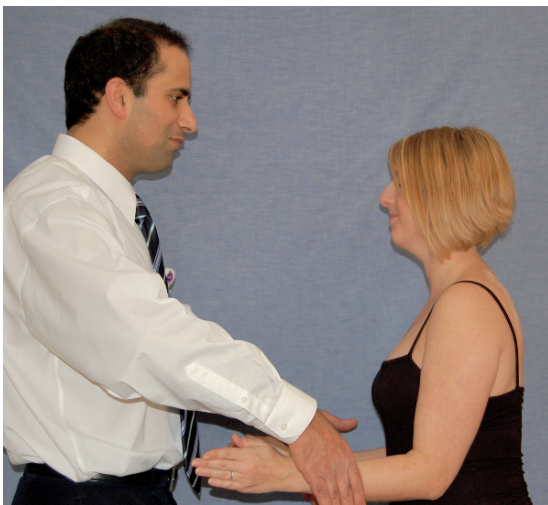

FIGURE 1.24. Assessing the infraspinatus and teres minor.

The external rotation lag test is carried out by holding the arm passively in maximum external rotation and then releasing it. If the arm falls into internal rotation, there is severe weakness of the external rotators, which is seen in massive rotator cuff tears.

## Special Tests

### Subacromial Impingement Tests

1. Neer's sign: While the patient is sitting or standing, the examiner passively elevates the patient's internally rotated arm in the plane of the scapula (about  $30^\circ$  from the coronal plane), thereby bringing the supraspinatus to a level where it impinges against the coracoacromial ligament and the anteroinferior aspect of the acromion (Figure 1.25). A painful arc of movement between  $70^\circ$  and  $120^\circ$  is taken as a positive sign for impingement.

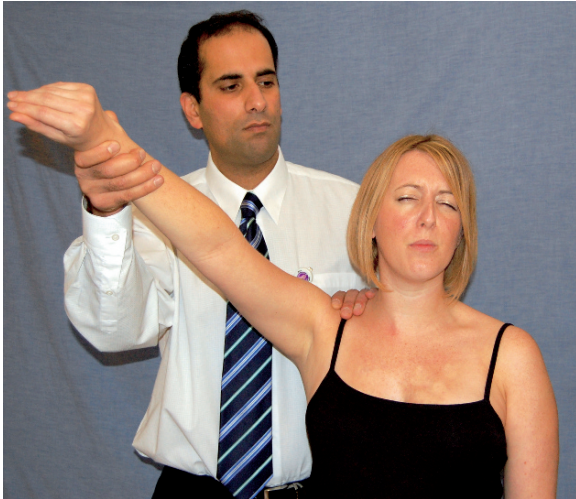

FIGURE 1.25. Neer's sign.

2. Neer's test: If the Neer's impingement sign is positive, inject local anesthetic into the subacromial space and repeat the test. If the pain is eliminated by the injection (positive Neer's test) a rotator cuff impingement or tear is suspected.
3. Hawkins' test: Ask the patient, sitting or standing, to forward flex the shoulder to  $90^\circ$  and keep the forearm parallel to the floor. The examiner holds the patient's arm and internally rotates it further (Figure 1.26).

If this produces pain, it suggests pathology of the rotator cuff or subacromial bursitis.

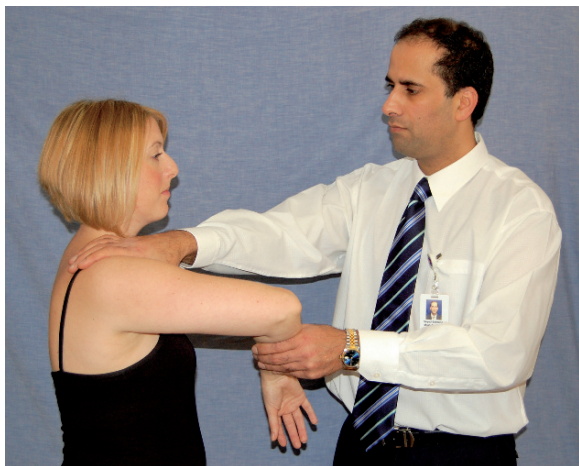

FIGURE 1.26. Hawkins' test.

### Instability Tests

Before testing, ask the patient if the shoulder feels unstable and in which direction. Voluntary dislocators can dislocate and relocate their shoulders with ease. Assess for evidence of generalized ligamentous laxity according to Beighton's score (out of 9).

#### Beighton's Score for Assessing Hypermobility

1. Hyperextension of the little finger beyond  $90^\circ$
  2. Passive apposition of the thumb to the flexor aspect of the forearm.
  3. Hyperextension of the elbow beyond  $10^\circ$
  4. Hyperextension of the knee beyond  $10^\circ$
  5. Forward flexion of the trunk so that the palms of the hands rest easily upon the floor.
- 
1. Drawer tests: These are performed to quantify the amount of anterior and posterior laxity.  
 While standing behind the patient, use one hand to stabilize the shoulder girdle by holding on to the scapula with your thumb and coracoid with your index finger and, with the other hand, hold on to the humeral head.  
 For the anterior drawer test, apply an anterior translational force (Figure 1.27a) and for the posterior drawer test apply a posterior translational force (Figure 1.27b). Quantify the amount of translation in relation to the diameter of the humeral head:  
 Hawkins grading of anterior draw
 

0	<25%
1	25–50%
2	50–100%
3	Dislocatable
- Note: The amount of posterior laxity is greater than the anterior in most normal individuals.*



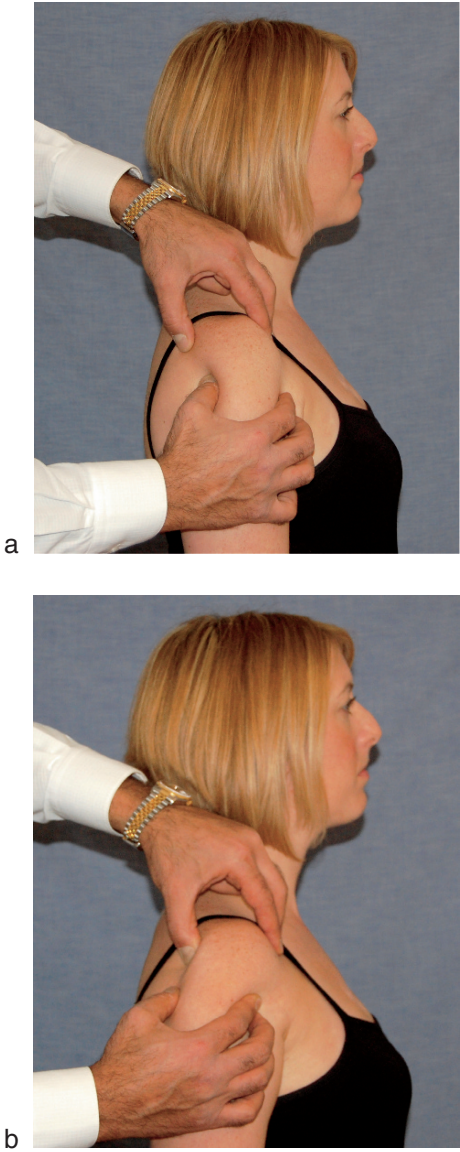


FIGURE 1.27. (a) Anterior drawer test. (b) Posterior drawer test.

2. The sulcus sign: Inferior laxity is demonstrated by the sulcus sign. With a relaxed patient standing or sitting, apply inferior traction to the arm by holding just above the elbow and look for a sulcus between the lateral edge of the acromion and the head of the humerus (Figure 1.28). The patient may show signs of apprehension during the test. In an individual with hypermobile joints, the sulcus sign may be positive bilaterally. In these situations, usually the size of the sulcus is larger in the symptomatic side.

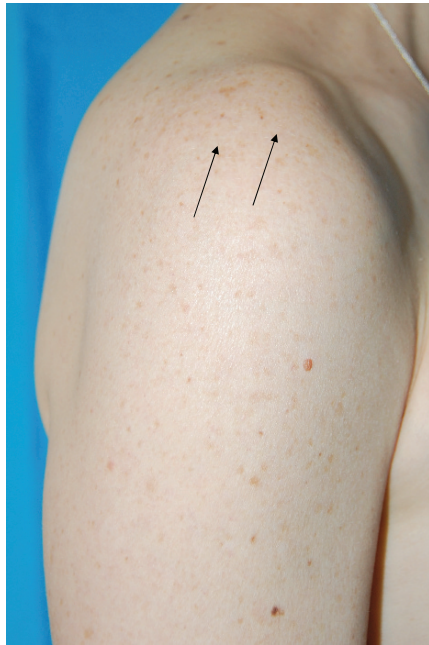


FIGURE 1.28. Sulcus sign.

3. Anterior apprehension test: With the patient sitting, standing or preferably in the supine position, the examiner abducts the arm to  $90^\circ$  and slowly externally rotates it. A positive test is indicated by an apprehensive look on the patient's face or an uncomfortable feeling of instability (Figure 1.29). Sometimes the pectoralis major can be seen to contract. If there is evidence of anterior instability, proceed to the Jobe's relocation test, with the patient in the supine position.

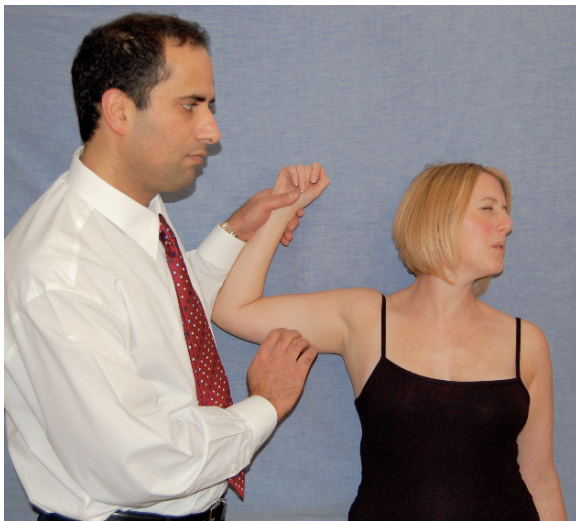

FIGURE 1.29. Anterior apprehension test.

4. Jobe's relocation test: The shoulder is again abducted and externally rotated to the maximum. When the point of apprehension has been reached, apply a posteriorly directed force to the front of the humerus using the palm of your hand. A positive test is indicated by a decrease in pain or apprehension (Figure 1.30). On releasing the pressure, the pain and apprehension returns. If the relocation test produces increased pain, consider other causes, such as posterior instability or impingement.
5. Posterior apprehension test: The arm is forward flexed to 90° and internally rotated to the maximum. Whilst applying a posteriorly directed force along the humeral shaft, adduct the arm across the body. A positive test is indicated by pain or apprehension.

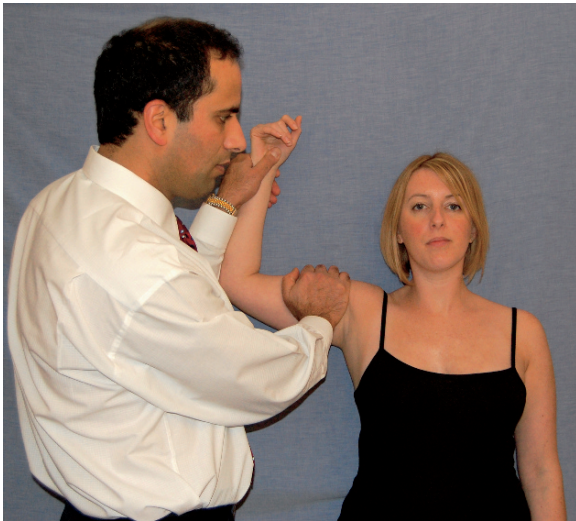

FIGURE 1.30. Jobe's relocation test.



a

FIGURE 1.31. O'Brien's test. (a) Thumb down position. (b) Palm up position.

### Labral Tests

There are numerous tests described for diagnosing a tear of the glenoid labrum or SLAP (Superior Labrum Anterior to Posterior) lesions. Unfortunately none of them is specific. However, for completeness, we are mentioning a few tests commonly performed.

1. O'Brien's test: Patient is standing or sitting and facing the examiner. The arm is forward flexed to  $90^\circ$  and adducted  $10^\circ$  medial to the sagittal plane of the body. With the arm in internal rotation so that the thumb is facing downward, apply downward force and ask the patient to resist. Repeat the test with the palm facing upward (Figure 1.31).

Pain produced deep in the shoulder joint with palm up → Labral tear

Pain produced on top of the shoulder with thumb down → ACJ pathology.



**b**

FIGURE 1.31. Cont'd.

**ACJ Pathology**

**Scarf Test:** The examiner stands facing the patient. Ask the patient to put the hand over the opposite shoulder while holding the elbow at the level of the shoulder. Then the examiner applies force to the patient's elbow, moving it into further cross chest adduction (Figure 1.32). Reproduction of pain over the ACJ indicates a positive test.

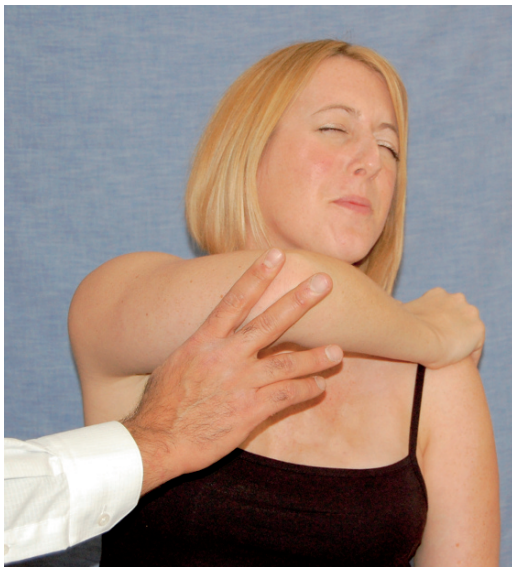

FIGURE 1.32. Scarf test.

# Chapter 2

## Elbow

---

### **LISTEN**

#### **Mechanism of Injury (If Applicable)**

Patient usually remembers their position at the time of injury  
Certain mechanisms of injury result in characteristic patterns

Fall on outstretched hand → supracondylar fracture  
→ posterior dislocation  
→ radial head fracture

Direct blow to elbow → olecranon fracture

Fall on to flexed elbow → supracondylar fracture  
→ anterior dislocation  
→ capitellar fracture

A child being lifted by arms → subluxation of radial head

#### **Pain**

##### **Site of Pain**

Localized pain (to which the patient can point with a finger)

Medial epicondyle → medial epicondylitis (golfer's elbow)  
→ cubital tunnel syndrome  
→ ulnar collateral ligament injuries

Lateral epicondyle → lateral epicondylitis (tennis elbow)  
→ radial tunnel syndrome  
→ osteochondritis of capitellum

Generalized pain → osteoarthritis and other inflammatory arthropathy  
→ gout  
→ infection  
→ tumors



### **Type of Pain**

Aching pain → degenerative changes

Sharp pain/ catching pain → loose body

Pain after activity → inflammatory arthropathy  
→ tendinosis

### **Radiation of Pain**

Conditions involving the lateral compartment (radiocapitellar joint) provoke pain that extends over the lateral aspect of the elbow, with radiation proximally to the midhumerus and distally over the forearm.

### **Stiffness**

Rest stiffness/early morning stiffness → rheumatoid arthritis  
→ inflammatory arthropathy  
→ osteoarthritis

### **Swelling**

Spontaneous → rheumatoid arthritis  
→ bursitis  
→ septic arthritis

Localized posterior → rheumatoid nodules  
→ olecranon bursa  
→ gouty tophi

### **Neurological Symptoms**

Altered sensation  
Weakness/Atrophy

**LOOK****With the Arms by the Side (Elbow in Extension)**

Scars, skin grafts, sinuses, erythema

Carrying angle: Normal valgus angulation of the elbow. Ask the patient to stand with the arms by their side with the elbows extended and forearms supinated. The angle formed between the longitudinal axis of the arm and the forearm is the carrying angle. (Figure 2.1)

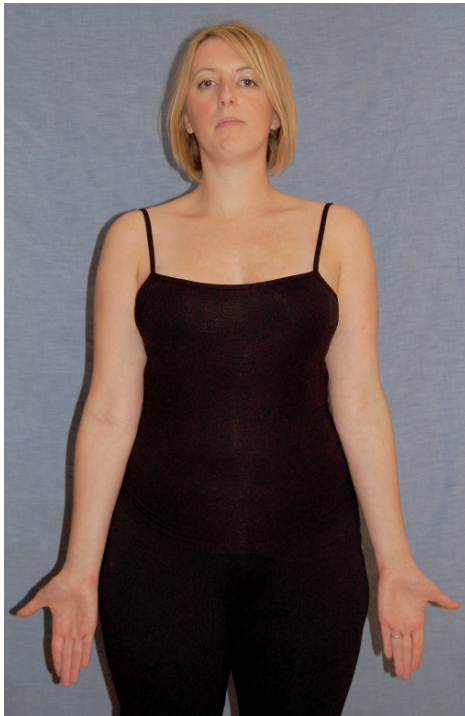

FIGURE 2.1. Carrying angle.

Normal average:

Men  $\rightarrow 10^\circ$

Women  $\rightarrow 13^\circ$

Increased carrying angle (cubitus valgus)  $\rightarrow$  nonunion lateral condyle fracture  
 $\rightarrow$  premature closure of lateral epiphysis

Decreased carrying angle (cubitus varus)  $\rightarrow$  malunited supracondylar fractures  
 $\rightarrow$  premature closure of medial epiphysis

### **With the Elbow in Flexion**

Scars, sinuses, erythema

Swellings in the posterior aspect of the elbow are easily seen.

Causes  $\rightarrow$  effusions

$\rightarrow$  rheumatoid nodules

$\rightarrow$  olecranon bursa

### **FEEL**

Increased skin temperature  $\rightarrow$  septic arthritis

$\rightarrow$  bursitis

$\rightarrow$  acute attack of gout

### **Lateral Side**

#### **Lateral Epicondyle**

Visible landmark in most patients.

Flexion of the elbow to  $90^\circ$  helps identification in obese patients.

**Radial head:**

With the patient's elbow flexed to 90°, the examiner first palpates the lateral epicondyle with his thumb. The radial head is 2 cm distal to the lateral epicondyle. Pronation and supination of the patient's forearm facilitate the palpation of the radial head (Figure 2.2).

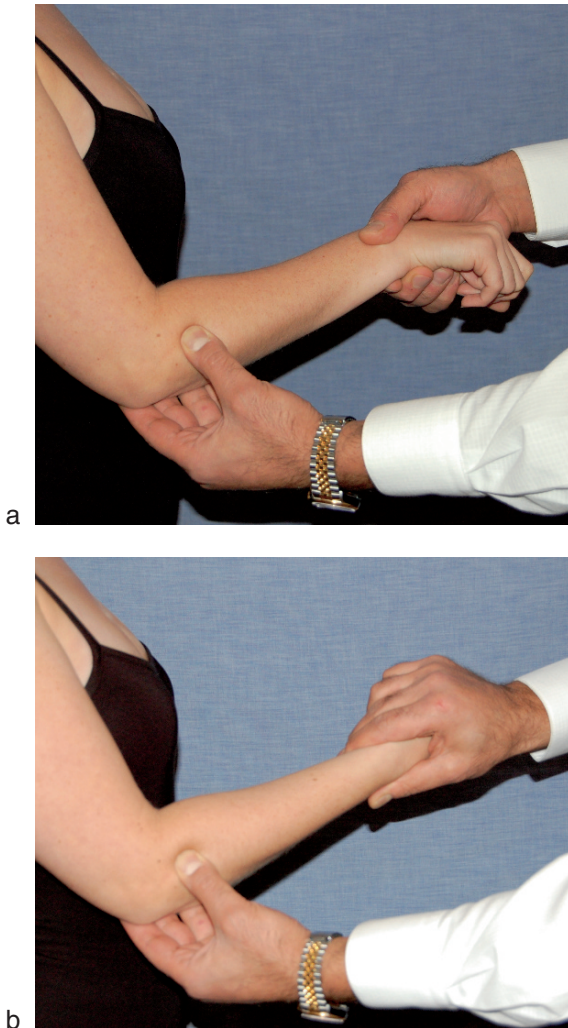


FIGURE 2.2. (a) Palpation of the radial head. Forearm pronated. (b) Palpation of the radial head. Forearm supinated.

If painful → Radial head fracture  
 → Radiohumeral arthritis

### Posterior Interosseous Nerve

Four finger breadths distal to lateral epicondyle (Figure 2.3), the posterior interosseous nerve passes between two heads of supinator under a thick ligament called *arcade of Frohse*. Entrapment of the nerve at this site is known as radial tunnel syndrome.

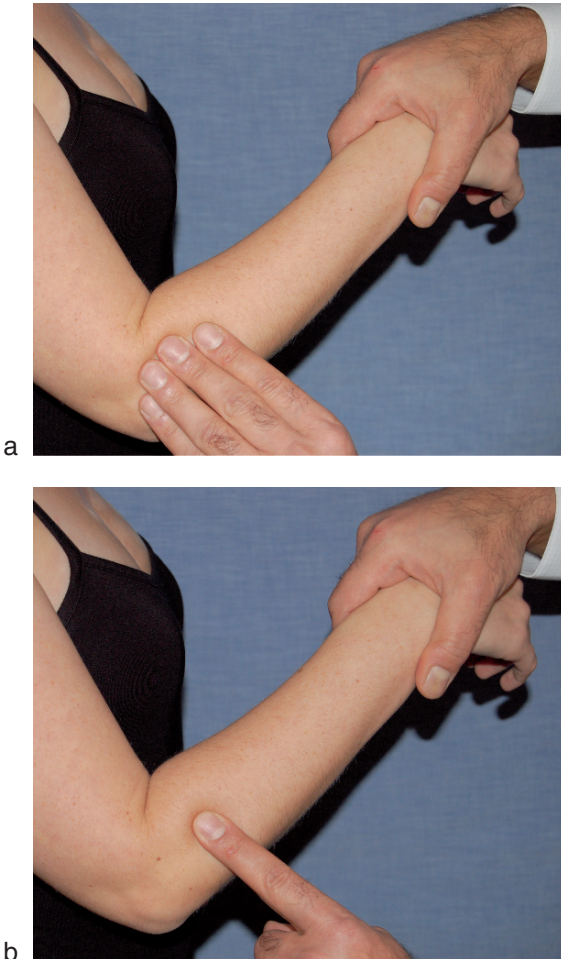


FIGURE 2.3. (a) Posterior interosseous nerve. (b) The index finger is over the *arcade of Frohse*.

### From Behind

#### Tip of the Olecranon

The tip of the olecranon and the olecranon fossa are palpated for tenderness.

The bony prominences of the lateral epicondyle, the radial head and the olecranon form a triangle (Figure 2.4). The center of this triangle is the radiohumeral joint capsule. Careful palpation may reveal minor effusions or low grade synovitis.

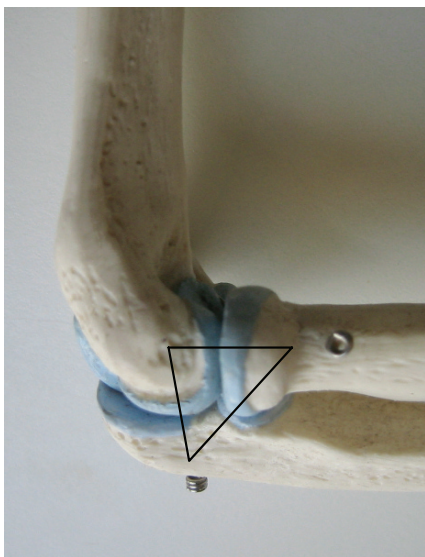


FIGURE 2.4. Relationship of the three bony points.

## Medial Side

### Medial Epicondyle

The most prominent structure of the medial side of the elbow is the medial epicondyle. The ulnar nerve can be felt behind the medial epicondyle (Figure 2.5). To facilitate palpation, the patient's arm should be in slight abduction, external rotation, and the elbow flexed between 20 and 70°.

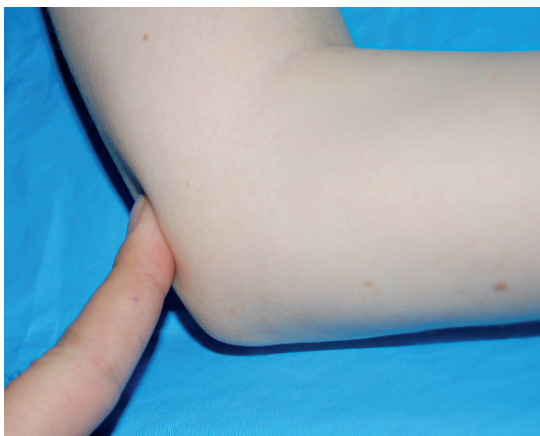

FIGURE 2.5. Palpation of ulnar nerve behind medial epicondyle.

### Bony Prominences of the Epicondyles and the Apex of the Olecranon

The examiner puts his thumb on the lateral epicondyle, the index finger on the olecranon and the middle finger on the medial epicondyle and feels for the relationship of these bony prominences. They form a triangle when the elbow is flexed to 90° and a straight line when the elbow is in extension (Figures 2.6 and 2.7).

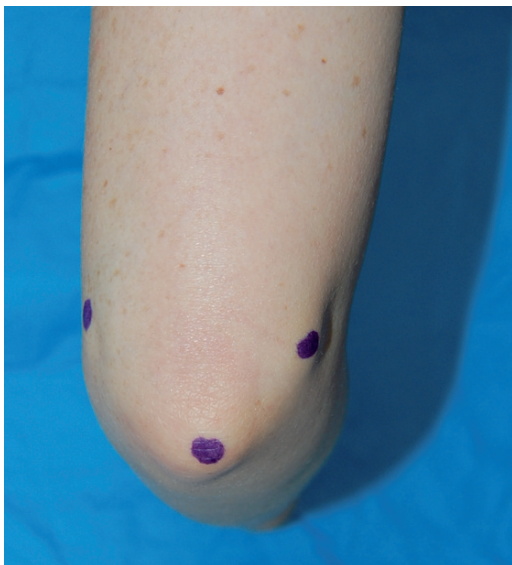

FIGURE 2.6. Three bony points.

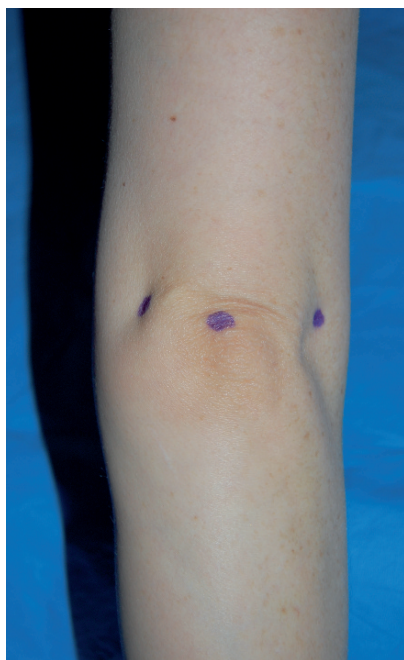


FIGURE 2.7. Three bony points in full extension.



**From the Front**

Lacertus fibrosus is the most prominent band anteriorly when the patient is made to flex the forearm against resistance (Figure 2.8)

The biceps tendon is lateral to lacertus fibrosus

The brachial artery is felt medial to the biceps tendon

The median nerve is medial to the brachial artery.

The musculocutaneous nerve is lateral to the biceps tendon.

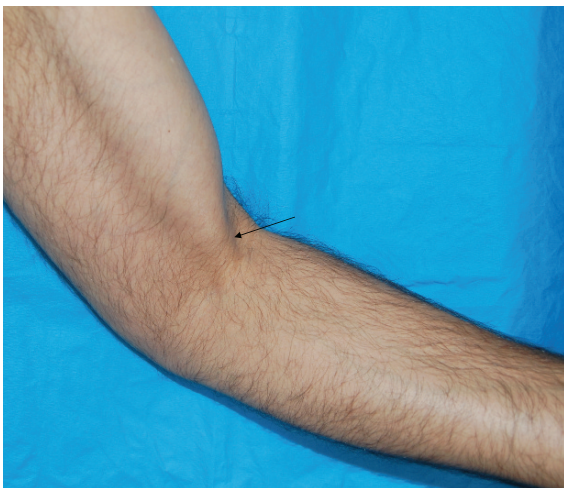

FIGURE 2.8. Lacertus fibrosus.

## Range of Movement

### Flexion – Extension

The patient is asked to abduct the shoulder to  $90^\circ$ , and then bend the elbow as far as possible. The degree of flexion and extension is measured (Figures 2.9 and 2.10).

Normal Flexion  $\rightarrow 0$  to  $140^\circ$

Hyperextension  $\rightarrow 0$  to  $-10^\circ$

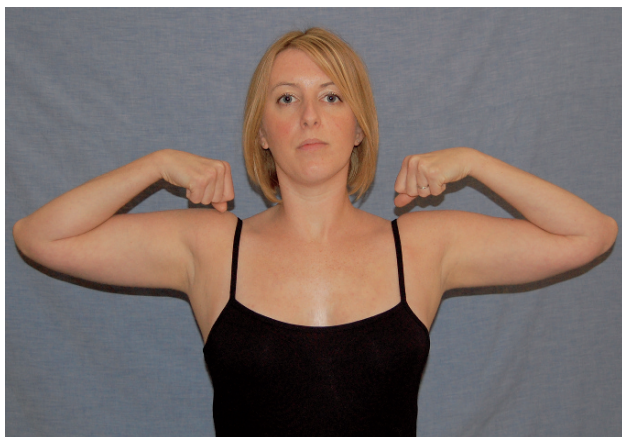

FIGURE 2.9. Flexion.

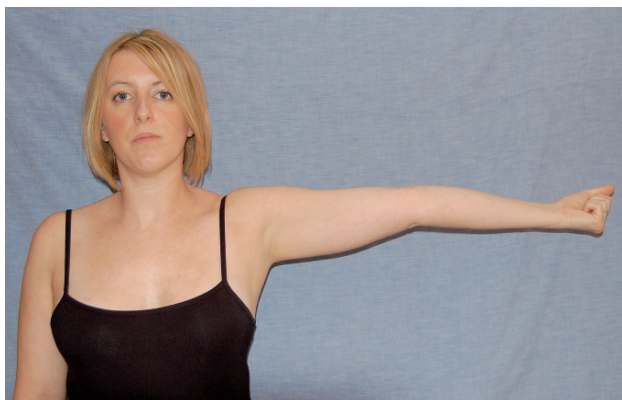

FIGURE 2.10. Extension.

**Pronation – Supination**

The patient is instructed to show the palm and back of the hands while he flexes the elbows to 90° and keeps the arms by his side (Figures 2.11 to 2.14).

Normal Range:

Pronation → 0 to 70°

Supination → 0 to 85°

The passive range of movement is evaluated after the active range is measured by the examiner.

Passive movements should be pain-free.

If pain elicited

with hyperextension → posterior impingement

with hyperflexion → anterior impingement (between corono-  
id tip and fossa)

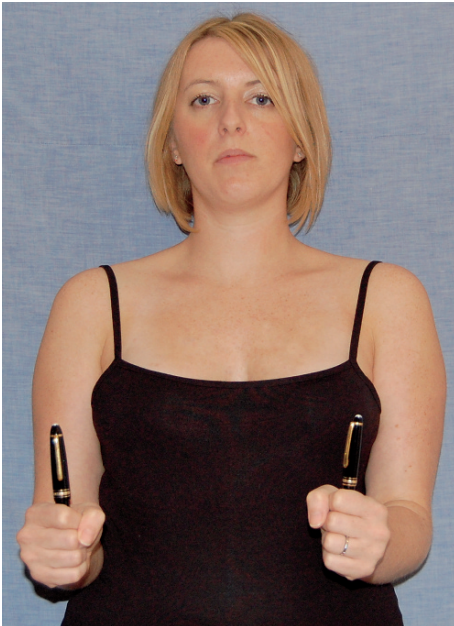

FIGURE 2.11. Neutral rotation.

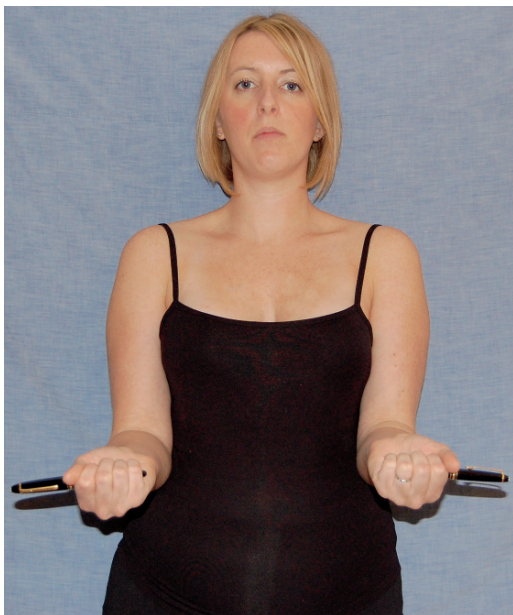

FIGURE 2.12. Supination.

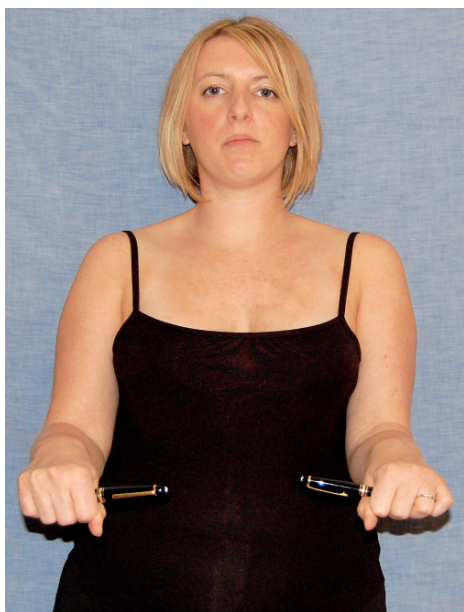

FIGURE 2.13. Pronation.

During examination for the passive range, the examiner feels for the end point of each movement. The common end points are:

**Bony**→Two hard surfaces meeting, bone to bone (e.g., elbow extension as the olecranon locks into the olecranon fossa).

**Capsular**→Leathery feel, further motion available (e.g. forearm pronation and supination).

**Soft tissue approximation**→Soft tissue contact (e.g., elbow flexion as the movement is blocked by the bulk of the arm and forearm muscles).

**Spasm**→Muscle contraction limits motion

**Springy block**→Intra-articular block; rebound is felt

**Empty**→Movement causes pain, pain limits movement



FIGURE 2.14. Incorrect method of recording pronation. The elbows must be kept by the sides.

## Muscle Testing

### **Biceps (Musculocutaneous nerve)**

To assess the biceps, the patient is asked to flex the elbow to 90° and maintain the position. The examiner supports the elbow with one hand, holds the wrist with the other hand and attempts to extend the elbow (Figure 2.15).

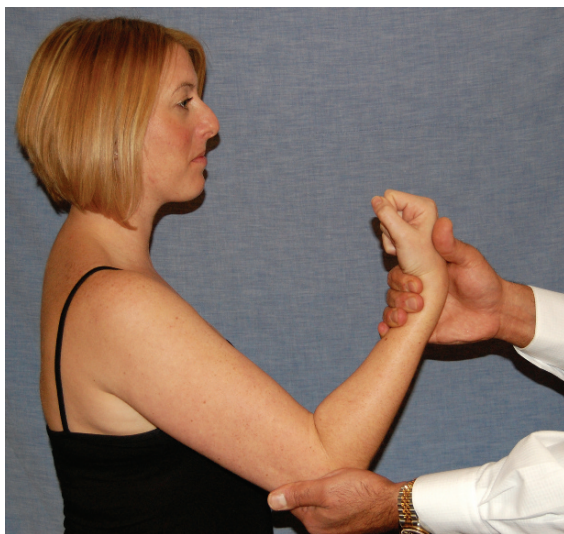

FIGURE 2.15. Assessing the biceps.



**Triceps (Radial Nerve)**

To assess the triceps, the patient is asked to flex the elbow to 90° and maintain the position. The examiner supports the elbow with one hand and holds the wrist with the other hand and attempts to flex the elbow (Figure 2.16).

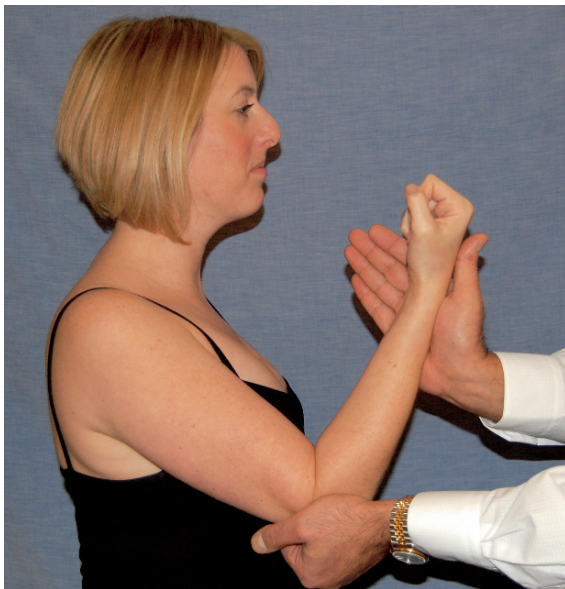

FIGURE 2.16. Assessing the triceps.

**Brachioradialis (Radial Nerve)**

The patient is asked to flex the elbow to 90° with the wrist in neutral and to maintain that position. The examiner holds the elbow with one hand and exerts downward pressure to the radial border of the distal forearm with the other hand. The brachioradialis muscle stands out in the proximal forearm (Figure 2.17).

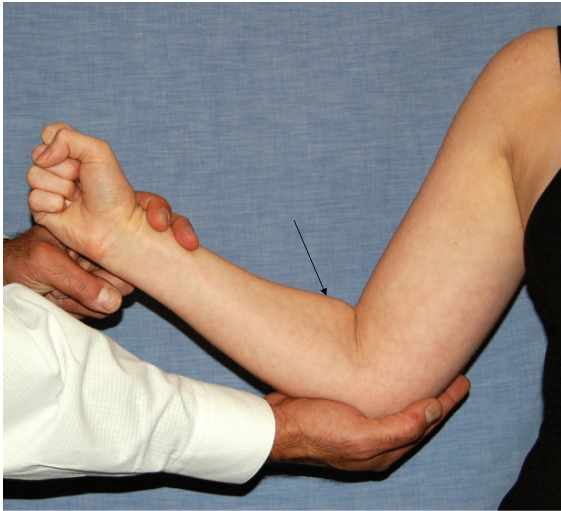


FIGURE 2.17. Assessing the brachioradialis. The black arrow points toward the muscle.

**Pronator teres and Pronator quadratus (Median nerve)**

(Tested together)

The patient is asked to flex the elbow to 90° with the forearm fully pronated and maintain the position. The examiner stabilizes the elbow with one hand and with the other hand holds the wrist and attempts to supinate the forearm (Figure 2.18).





FIGURE 2.18. Assessing the pronators.

Supination of the elbow joint is provided by the supinator (radial nerve) and the biceps muscle (musculocutaneous nerve). The power of the supinator muscle cannot be elicited in isolation. To assess the overall supination power of the forearm, the patient is asked to flex the elbow to  $90^\circ$  with the forearm fully supinated and maintain the position. The examiner stabilizes the elbow with one hand and with the other hand holds the wrist and attempts to pronate the forearm (Figure 2.19).

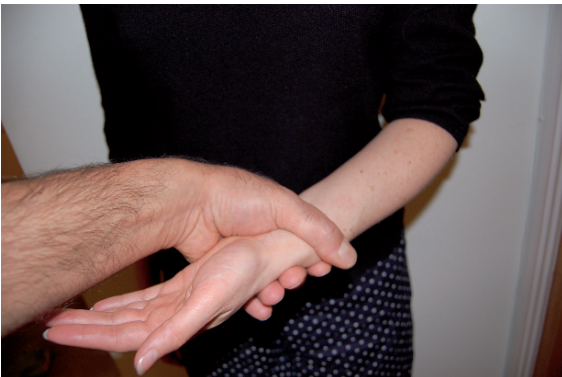

FIGURE 2.19. Assessing the supinators.

Complete neurological examination is mandatory and this is covered in the Hand and Wrist chapter.

### Special Tests

#### Varus Stress Test

The examiner puts one hand above and one hand below the elbow. With the forearm in full supination and the elbow in extension, the examiner exerts varus force (Figure 2.20).

Opening of the lateral compartment → lateral ligament laxity

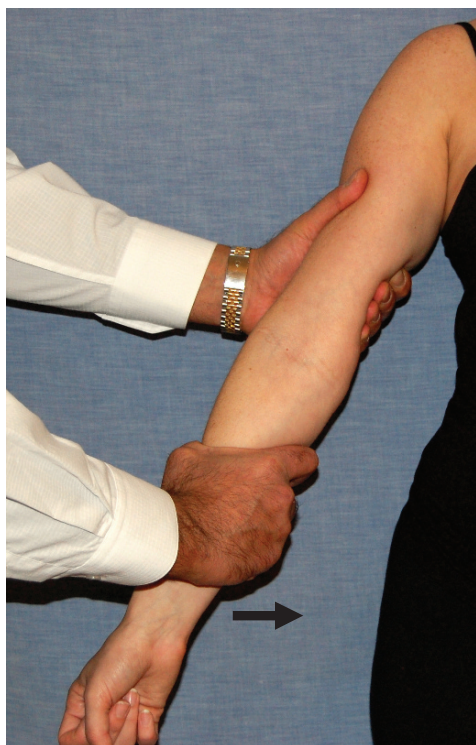

FIGURE 2.20. Varus stress test. Note the direction of force.

**Valgus Stress Test**

The examiner puts one hand above and one hand below the elbow. With the forearm in full supination and the elbow in slight flexion, the examiner exerts valgus force (Figure 2.21).

Opening of medial compartment → medial ligament laxity

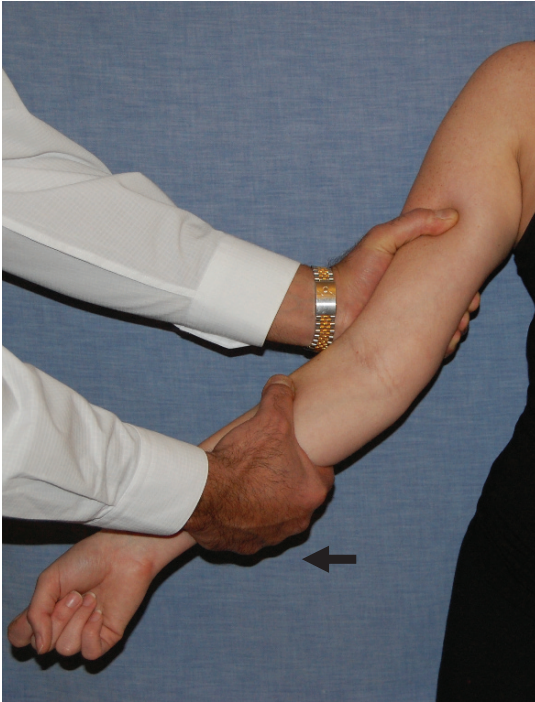

FIGURE 2.21. Valgus stress test. Note the direction of force.

**Lateral Pivot Shift Test**

This is a test for posterolateral rotatory instability of the elbow: Ask the patient to place the arm over his head. The examiner then holds the patient's wrist and the elbow. The forearm is fully supinated, and valgus stress is applied as the elbow is moved from the fully extended position to a flexed position. This reproduces posterolateral rotatory instability, which manifests as pain and apprehension in the patient.

**Tinel's Test**

For ulnar nerve neuropathy.

With the elbow flexed to 20°, the examiner taps gently over the ulnar groove between the olecranon and the medial epicondyle. In a positive test, there is a tingling sensation down the forearm to the ulnar distribution in the hand.

**Provocative Test for Lateral Epicondylitis**

The patient is instructed to extend the wrist and fingers and maintain the position. The examiner applies downward force to the middle finger (ECRB inserts into the base of the third metacarpal) while the elbow is in full extension. In a positive test, it produces pain at the lateral epicondyle.

# Chapter 3

## Wrist and Hand

---

### LISTEN

#### Mechanism of Injury (If Applicable)

Certain mechanisms of injury result in characteristic patterns of structural damage.

##### Common Examples

Punching a hard object → Fracture head/neck of little finger metacarpal

Being hit by a ball over the finger/sudden flexion while making bed → Mallet finger

“Catching” the thumb by snowboarder/skier<sup>1</sup> → ulnar collateral injury

Using the hand like a hammer → fracture/nonunion of hook of hamate<sup>2</sup>

Fall on to extended wrist → Colles’ fracture

Fall on to flexed wrist → Smith’s fracture

Cut on flexor aspect of finger → Tendon and/or nerve injury

---

<sup>1</sup>Traditionally it is called gamekeeper’s thumb and it was one of the occupational injuries. It is however more often seen in winter sport enthusiasts.

<sup>2</sup>Cobblers’s fracture.

### **Account of Symptoms**

Waking up at night with hand pain, pins and needles → carpal tunnel syndrome

Pain and pins and needles in hand after trauma or using a crutch → ulnar tunnel syndrome

Pain and stiffness in finger on waking → flexor tenovaginitis

### **Location of Pain**

#### **Radial Side of the Wrist**

de Quervain's disease

Radiocarpal osteoarthritis

Scaphoid nonunion

Scaphotrapeziotrapezoid (STT) osteoarthritis

#### **Ulnar Side of the Wrist**

Ulnar styloid fracture

Injuries to triangular fibrocartilage complex (TFCC)

Ulnar abutment

Caput ulnae (rheumatoid patients)

Radiolunar osteoarthritis

Pisotriquetral osteoarthritis

#### **In the Center of the Wrist**

Avascular necrosis (AVN) of lunate

Scapholunate dissociation

Midcarpal osteoarthritis

## LOOK

The patient is facing the examiner with hands over a pillow or on the table. The examiner begins by asking the patient to keep their hands relaxed.

### The Palm

1. In a relaxed position the arcade of flexion of fingers should be observed. With the wrist in the neutral position, each finger is slightly more flexed than its radial neighbor (Figure 3.1).

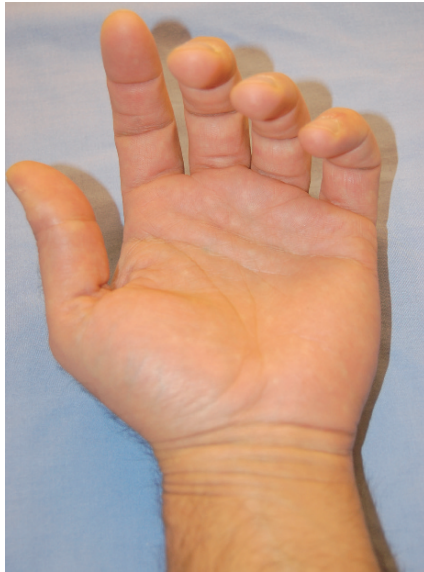

FIGURE 3.1. Normal arcade of flexion.

**Abnormal Arc**

One or more fingers remain in the fully extended position (Pointing finger sign) → flexor digitorum profundus (FDP) tendon avulsion or laceration (Figure 3.2).

Limited flexion in a finger → flexor digitorum superficialis tendon laceration  
→ stiff finger

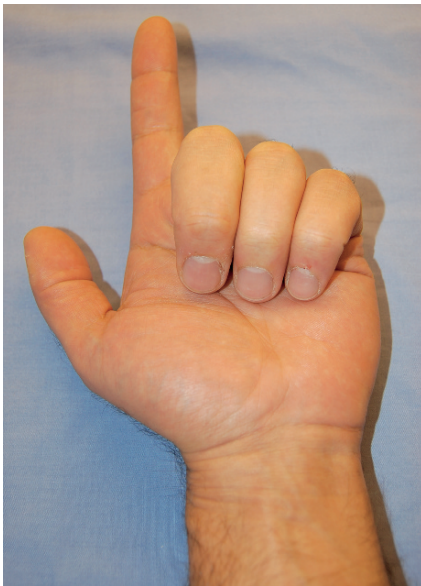


FIGURE 3.2. Pointing finger sign.



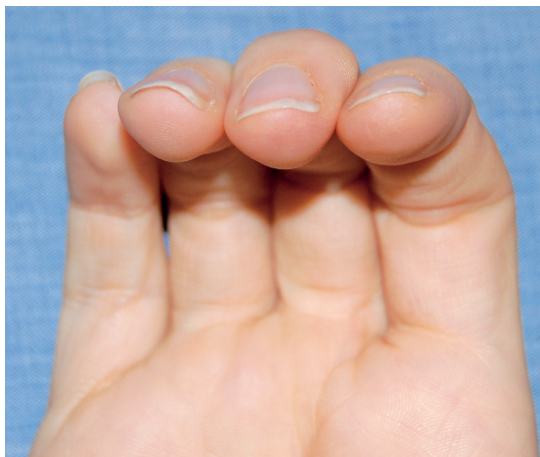

FIGURE 3.3. Normal rotational alignment of the fingers.

At the same time one must look for the rotational alignment of the finger by observing the fingernails. Usually fingernails are parallel with each other. Abnormal rotation due to fractures or malunion can be observed in this way (Figure 3.3).

Then ask the patient to fully extend all the fingers.

#### 2. Swelling of the finger/s

Fusiform swelling → rheumatoid arthritis (synovitis)

→ fracture and ligamentous injuries

→ flexor tendon sheath infection

### **Pyogenic Flexor Tenosynovitis**

Kanavel's classical signs

1. Tenderness over flexor tendon
2. Fusiform swelling of the finger
3. Finger held in slightly flexed position
4. Increased pain on passive extension

### **Common Hand Swellings**

Ganglion

Mucous cyst

Giant cell tumour of tendon sheath

Villonodular synovitis

Bone tumour (Enchondroma)

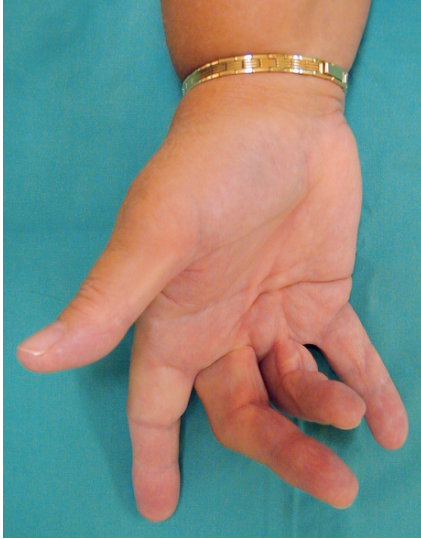

FIGURE 3.4. Dupuytren's contracture. (Courtesy of Mr. Wetherell)

3. Nodular thickening of palm, especially ring and little finger → Dupuytren's contracture (Figure 3.4).

**Compare the Thenar Eminences**

Atrophy of thenar muscles → median nerve pathology  
→ osteoarthritis base of thumb

**Compare the Hypothenar Eminences**

Atrophy of hypothenar muscles → ulnar nerve pathology

4. Swelling Around the Wrist

**Radial Side**

Ask the patient to bring the palms close together (Figure 3.5)

- i. Compare the thenar muscles. Subtle differences can be observed easily.
- ii. Alignment of the thumb and its deformity can be observed (look at the deformity section later in this chapter).

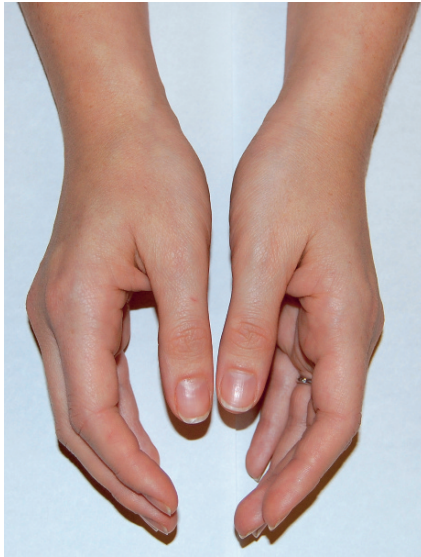


FIGURE 3.5. Compare the thenar eminences.



FIGURE 3.6. Compare the hypothenar eminences.

While palms are together, ask the patient to flex the elbows and observe the ulnar border of the hands (Figure 3.6).

**Ulnar Side**

- i. Compare the hypothenar muscles. Subtle differences can be observed easily.
- ii. Flexion deformity of the little finger metacarpal, if present, can be seen.
- iii. Look at the elbow joint. Any scars which may be associated with ulnar nerve pathology or other abnormalities can be seen.

**Dorsum of the Hands****Nails**

Pitting of the nails → psoritic arthropathy (Figure 3.7)

Swelling around the nail bed → paronychia

Thickening and distortion → fungal infection

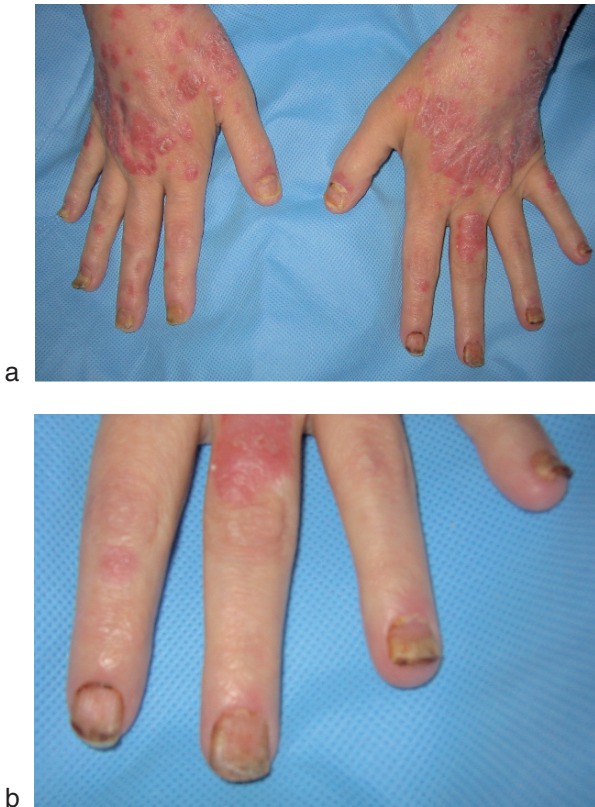


FIGURE 3.7. (a) Psoriasis lesion on the hand. (b) Nail changes in psoriasis.

## Swelling of Fingers and Hand

### Abbreviations

DIPJ: Distal interphalangeal joint  
PIPJ: Proximal interphalangeal joint  
MCPJ: Metacarpophalangeal joint  
CMCJ: Carpometacarpal joint  
IPJ: Interphalangeal joint

Around the base of the nail → mucous cyst  
→ giant cell tumour

DIPJ level (Heberden's nodes) → osteoarthritis (Figure 3.8)

PIPJ level (Bouchard's nodes) → rheumatoid arthritis  
→ Gouty tophus

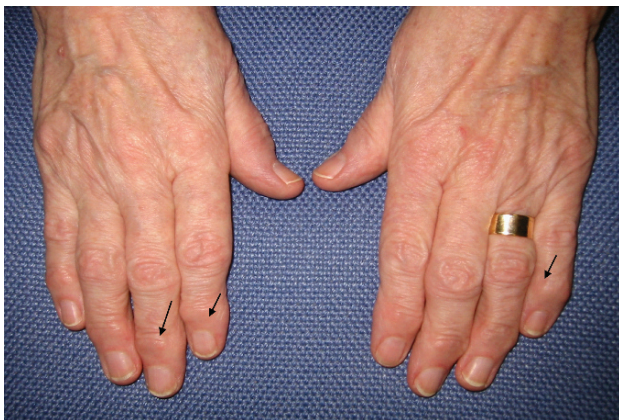


FIGURE 3.8. Heberden nodes.

MCPJ level → rheumatoid arthritis (synovitis) (Fig 3.9)

CMCJ of the thumb → osteoarthritis (Figure 3.10)

Thickening of the dorsal skin over PIP joints (Garrod's pad)  
→ Dupuytren's disease

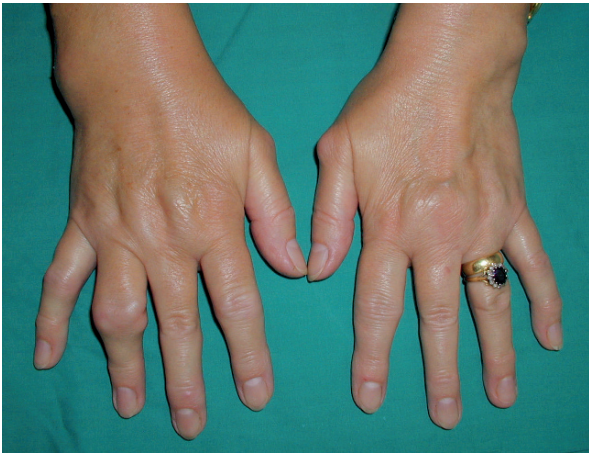

FIGURE 3.9. Synovitis MCPJs level and PIPs especially right ring finger. (Courtesy of Mr. Wetherell)

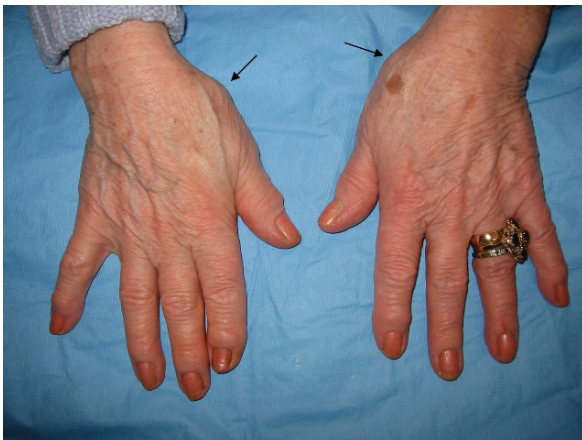

FIGURE 3.10. Arthritis at base of the thumbs.



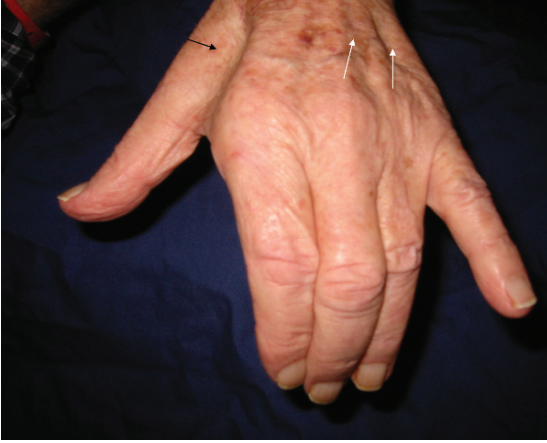

FIGURE 3.11. Atrophy of first dorsal interosseous (*black arrow*), guttering of the dorsum of the hand (*white arrows*) and abduction of the little finger.

Atrophy of first dorsal interosseous → ulnar nerve pathology. Intrinsic wasting of other fingers follows later which causes guttering of the dorsum of the hand (Figure 3.11).

### Swellings of the Wrist

#### Radial side

Fracture of radius

Synovitis (Dumbbell shape swelling, either side of extensor retinaculum in rheumatoid arthritis)

Ganglion

de Quervain's (nodular swelling proximal to radial styloid)

#### Ulnar side

Rheumatoid arthritis

Synovitis

Caput ulnae



## Deformities

### Mallet Finger

Flexed DIPJ that is unable to actively extend

Due to extensor tendon rupture / avulsion fracture (Figure 3.12)

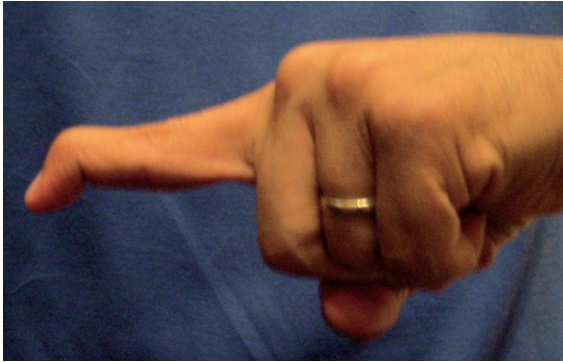

FIGURE 3.12. Mallet finger deformity.

### Mallet Thumb

Flexed IPJ that is unable to actively extend

### Swan Neck Deformity

DIPJ flexed, PIPJ hyperextended (Figure 3.13)

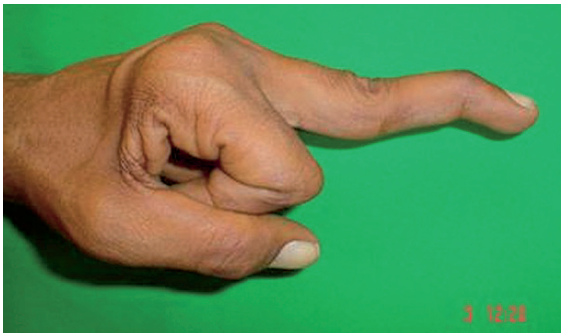


FIGURE 3.13. Swan neck deformity. (Courtesy of Dr. Anil K. Bhat<sup>3</sup>)

<sup>3</sup>Dr. Anil K. Bhat, Associate Professor, Hand and Microvascular Surgery, Department of Orthopaedics, Kasturba Medical College, Manipal, India.

Due to:

imbalance of forces at the PIPJ and lax volar plate, seen in  
rheumatoid arthritis

Mallet finger (secondary to retraction of extensor mechanism)

Laceration /transfer of FDS

Intrinsic contracture

**Boutonniere Deformity**

PIPJ flexed, DIPJ extended (Figure 3.14)

Due to rupture or attenuation central slip of extensor tendon.

Seen in:

Laceration

Traumatic rupture

Rheumatoid arthritis (attenuation secondary to capsular  
distension)

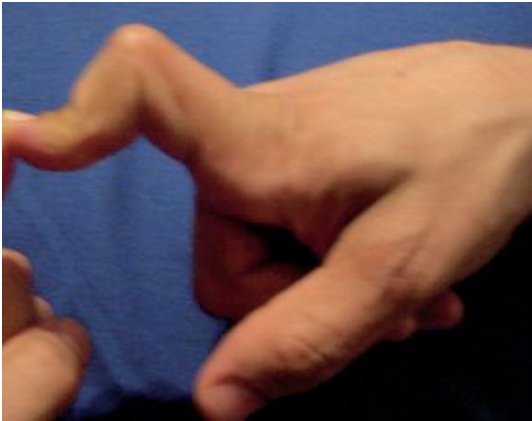

FIGURE 3.14. Boutonniere deformity.

**Z Thumb**

MCPJ flexed, IPJ hyperextended (Figure 3.15).  
Due to imbalance of forces at the MCP and IPJ.  
Seen in

Rheumatoid arthritis → EPB rupture  
→ FPL rupture

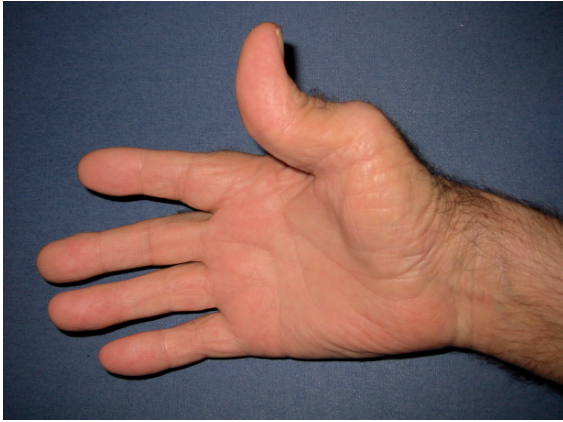


FIGURE 3.15. Z thumb deformity.

**Vaughn-Jackson Syndrome**

Inability to extend the little, ring, and middle finger (Figure 3.16) due to rupture (often sequential) of extensor tendons in rheumatoid arthritis.

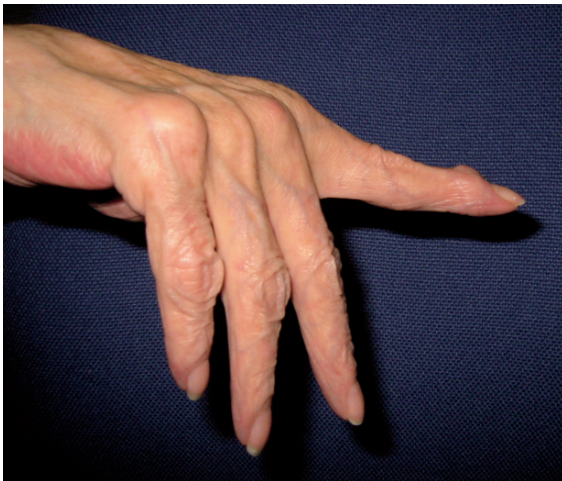

FIGURE 3.16. Vaughn-Jackson syndrome.

**Ulnar Drift**

Ulnar deviation of the fingers at MCPJ (Figure 3.17). At the late stage, the MCPJ may sublux or dislocate. Seen in rheumatoid arthritis.

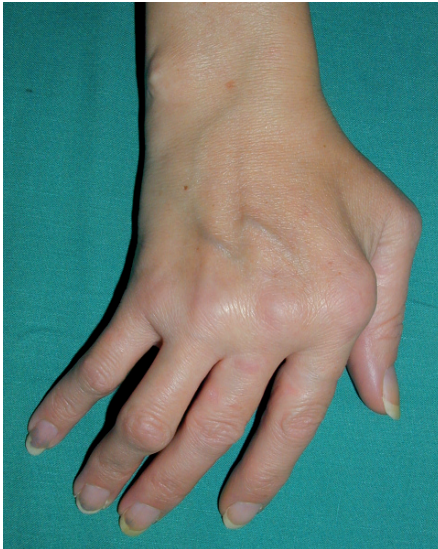

FIGURE 3.17. Ulnar drift. (Courtesy of Mr. Wetherell)

**Claw Hand (Intrinsic Minus)**

Hyperextension of MCPJ, flexion of PIPJ and DIPJ of all fingers  
Loss of intrinsic muscles and over activity of long extensors  
(Figure 3.18).

Seen in:

- Combined median and ulnar nerve palsy
- Volkmann's ischemic contracture
- Lower lesions of brachial plexus (Klumpke palsy)

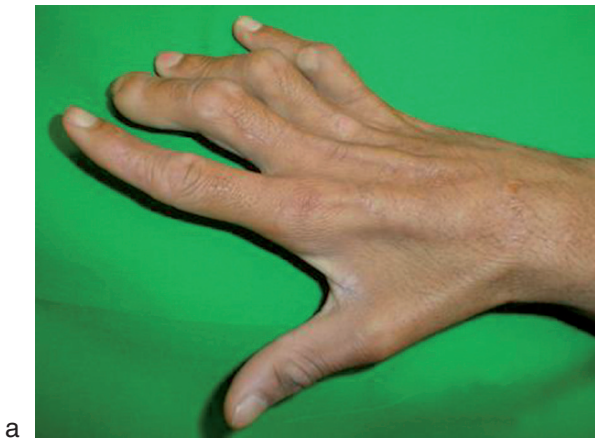


FIGURE 3.18. (a) Claw hand with interosseous muscle atrophy. (b) Flattening of distal metacarpal arch in claw hand. (c) Joint contracture in claw hand with resorption of distal phalanges in leprosy. (Courtesy of Dr. Anil K. Bhat)

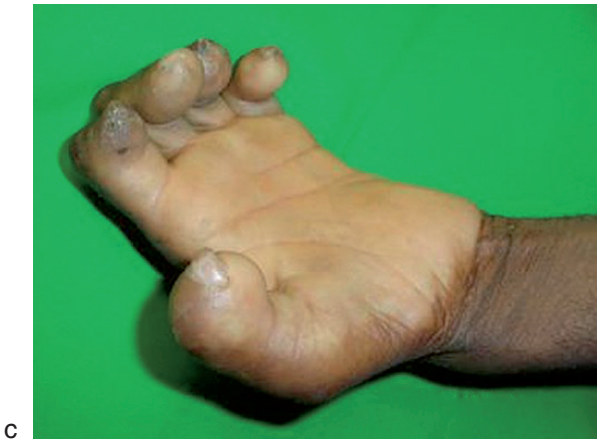
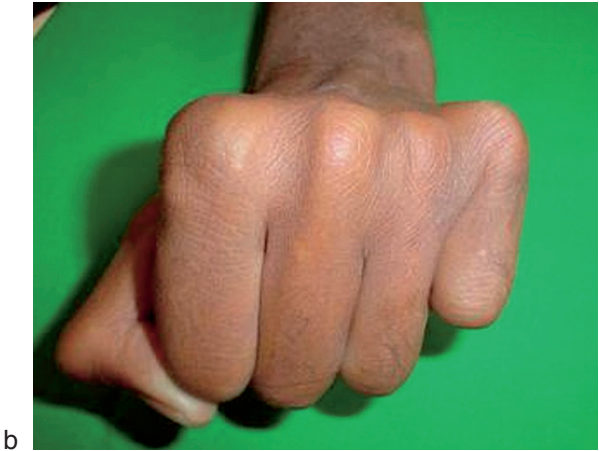
FIGURE 3.18. Cont'd.

**Intrinsic Plus Hand**

Flexion of MCPJs and extension of PIPs and DIPs (Figure 3.19)

Seen in:

Subluxation/dislocation of distal joints

Intrinsic tightness in rheumatoid arthritis

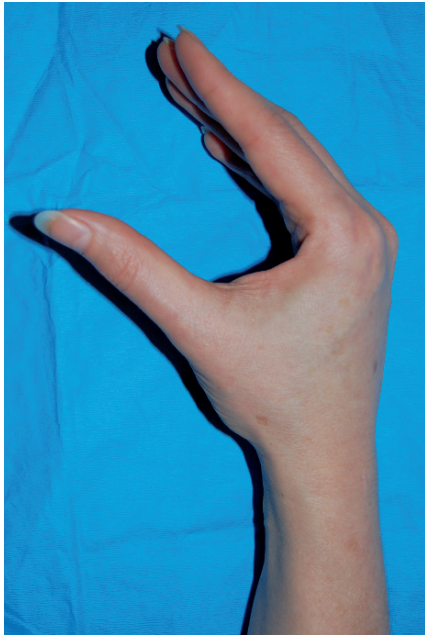

FIGURE 3.19. Simulation of intrinsic plus hand.

### **Ulnar Clawing**

Hyperextension of MCPJ, flexion of PIPJ and DIPJ of ring and little finger (Figure 3.20).

Seen in:

Low ulnar nerve palsy

*Note: In high ulnar nerve palsy the action of the FDP is lost; hence the DIPs are not flexed. This results in a lesser deformity in the hand called*

### **Ulnar Paradox**

The higher the lesion, the lesser the deformity

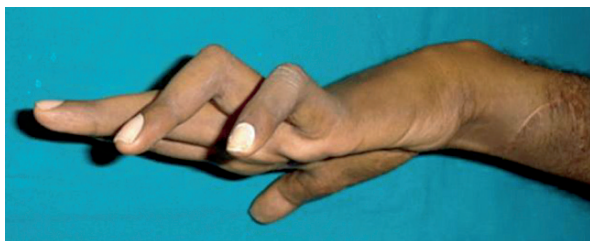


FIGURE 3.20. Ulnar claw hand. Note the laceration of distal forearm, hyperextension of MCPJ, and flexion of PIPJ. (Courtesy of Dr. Anil K. Bhat)



**Benediction Hand Deformity (Bishop's Hand)**

Hyperextension of MCPJs of index to little finger

Flexion of PIPJ and DIPJ; this manifests as slight flexion only in index and middle fingers and severe flexion in ring and little fingers (Figure 3.21).

Wasting of hypothenar, interosseous, and two medial lumbrical muscles.

Seen in: Longstanding ulnar nerve palsy




FIGURE 3.21. Simulation of Benediction hand deformity.

**Ape Hand Deformity**

The thumb rotates toward the other fingers due to pull of extensors as a result of wasting of thenar muscles. Seen in: Longstanding median nerve palsy.

**Wrist Drop**

Inability to extend the wrist, thumb and fingers (Figure 3.22)

Seen in: High radial nerve palsy.

*Note: Patients with low radial nerve palsy have at least one radial wrist extensor intact.*

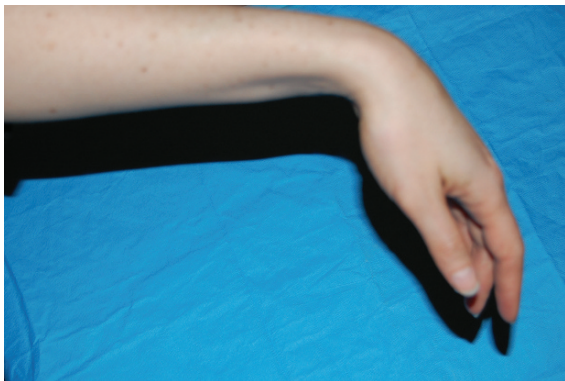


FIGURE 3.22. Wrist drop.

**Mannerfelt-Norman Syndrome**

Attritional rupture of FPL over osteophytes in carpal tunnel;  
Commonly seen in rheumatoid arthritis.

**Common Congenital Deformities**

Syndactyly: Webbed or conjoined fingers (Figure 3.23).

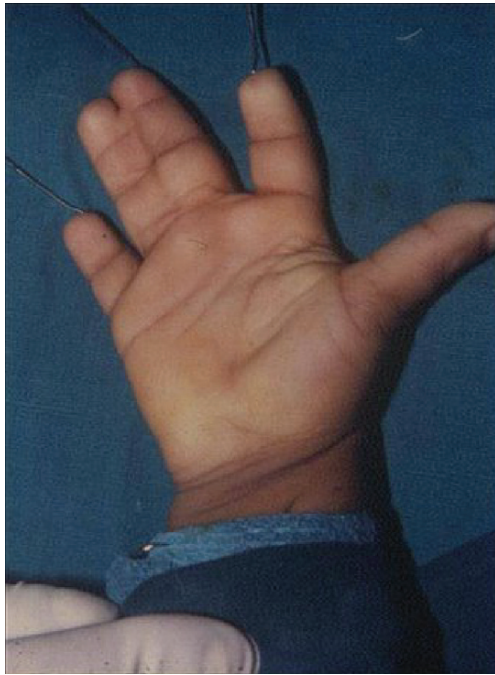

FIGURE 3.23. Syndactyly. (Courtesy of Dr. Bhaskaranand Kumar<sup>4</sup>)

---

<sup>4</sup>Dr. Bhaskaranand Kumar, Professor and Unit Chief, Hand and Microvascular Surgery, Department of Orthopaedics, Kasturba Medical College, Manipal, India.

Polydactyly: Extra digit (Figure 3.24 and 3.25).

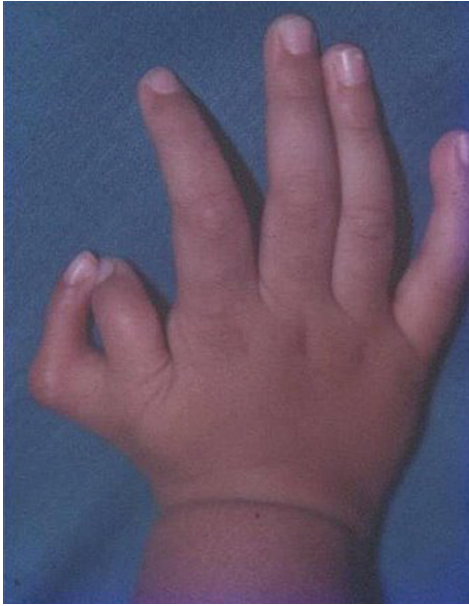

FIGURE 3.24. Polydactyly. (Courtesy of Dr. Bhaskaranand Kumar)

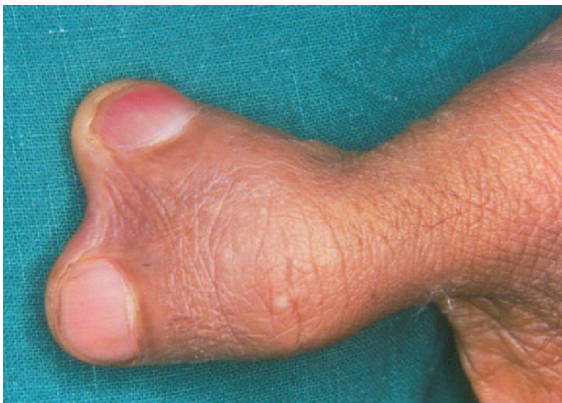

FIGURE 3.25. Polydactyly. (Courtesy of Dr. Bhaskaranand Kumar)

Macroductyly: Overgrowth of one or more digits (Figure 3.26).

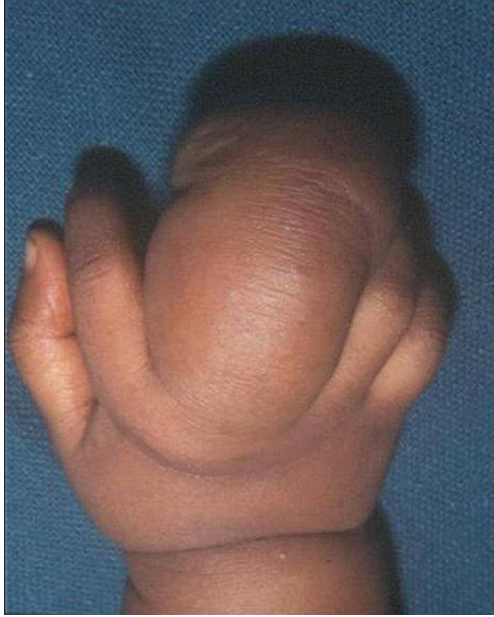

FIGURE 3.26. Macroductyly of middle finger. (Courtesy of Dr. Bhaskaranand Kumar)

Camptodactyly: Fixed flexion deformity of PIPJ (usually the little finger) (Figure 3.27).



FIGURE 3.27. Bilateral Camptodactyly. (Courtesy of Dr. Bhaskaranand Kumar)

Clinodactyly: Radial deviation of the little finger (Figure 3.28).

Radial club hand: Marked radial deviation of the wrist (Figure 3.29).

Partial or complete absence of the radius and thumb.

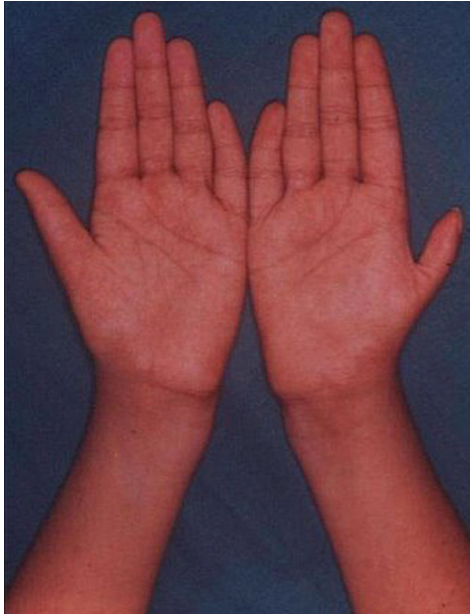


FIGURE 3.28. Bilateral clinodactyly. Note the hypoplastic right thumb. (Courtesy of Dr. Bhaskaranand Kumar)

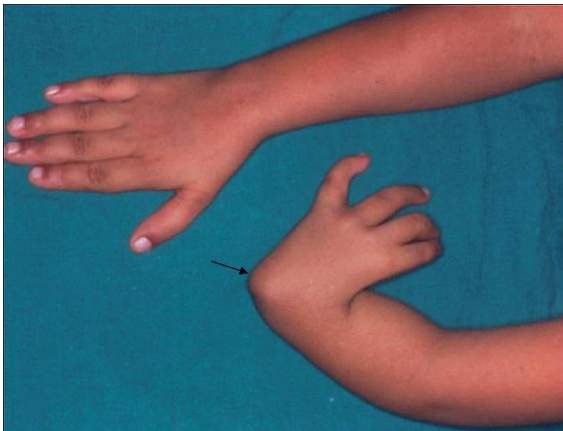


FIGURE 3.29. Radial club hand. Note the prominent head of the ulna (arrow) and absent thumb. (Courtesy of Dr. Bhaskaranand Kumar)



## FEEL

## Wrist

**Radial Styloid Process**

The distal-most projection from the lateral side of the radius is the radial styloid process. Its level compares with the ulnar styloid. Usually the radial styloid is more distal than that of the ulna in a pronated forearm. Shortening of the radial styloid (compared to the other side) may be due to:

- radial fracture
- radiocarpal arthritis
- Kienböck's disease (advanced stage)

Tenderness at the radial styloid → fracture  
 → radioscaphoid arthritis

Tenderness just proximal to the radial styloid → de Quervain's disease

Tenderness distal to the radial styloid → nonunion of scaphoid  
 → trapeziometacarpal osteoarthritis  
 → STT osteoarthritis

**Anatomical Snuffbox** (Figure 3.30)

The waist of scaphoid can be felt distal to the radial styloid process.  
 Tenderness → fracture or nonunion

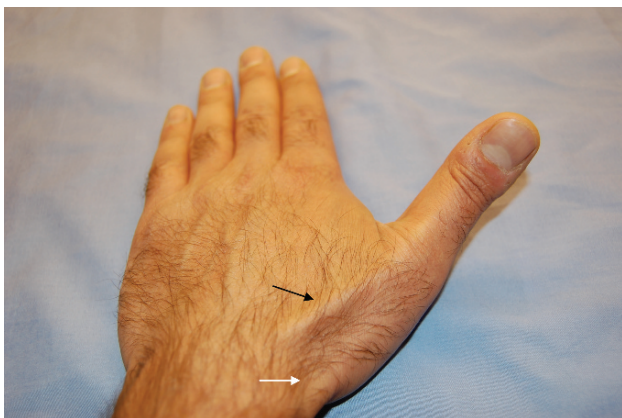


FIGURE 3.30. Anatomical snuffbox. Note the EPL tendon (*black arrow*) and APL, EPB tendons (*white arrow*).



**Anatomical Snuff Box**

Dorsal border: EPL

Volar border: APL, EPB

Floor: waist of scaphoid

Content: Radial artery

**Trapezium**

Just distal to the waist of scaphoid, pulsation of the dorsal branch of the radial artery is felt with gentle palpation. The artery pulsates over the trapezium, which can be felt with firm palpation. The bony ridge immediately distal to this is the trapeziometacarpal joint.

Tenderness → trapeziometacarpal joint arthritis

**Lister's Tubercle**

About 2 cm ulnar to the radial styloid, a ridge can be felt on the dorsum of the radius. The tendon of the EPL sharply turns from the ulnar to the radial side of the tubercle to its insertion at the distal phalanx of the thumb.

Just distal to Lister's tubercle, with the wrist in slight flexion, the examiner's finger falls over the edge of the radius into a small depression, which is the scapholunate joint. With deeper palpation the proximal pole of the scaphoid can be felt.

**Scaphoid**

Keep your thumb over the proximal pole of the scaphoid (as described above). With your index finger, feel the radial pulse and follow the artery toward the wrist. Just distal to the wrist crease and about one finger-breadth toward the midline, a firm bony point is felt. This is the distal pole of the scaphoid. Put your index finger on it. With passive radial and ulnar deviation of the wrist, one can easily feel the movement of the scaphoid. Pressure over the poles of the scaphoid can confirm the fracture or nonunion.

**Ulnar Head**

This is a round structure on the ulnar side and it is visible in most individuals.

Tenderness → fracture/nonunion  
→ dorsal subluxation  
→ active synovitis (rheumatoid arthritis)  
→ caput ulnae

Prominent → rheumatoid arthritis  
→ malunited radial fractures  
→ synovitis

Absent → previous surgical resection (Darrach's procedure)

**Distal Radioulnar Joint**

Feel the ulnar head. On palpation on the radial side of the ulnar head, the examiner can feel a depression, which is the distal radioulnar joint. Alternate pronation and supination to neutral, helps the examiner to locate the joint.

Tenderness → Fractures involving the joint  
→ Instability  
→ Active synovitis (rheumatoid arthritis)  
→ Osteoarthritis

**Ulnar Styloid Process**

Palpate the ulnar head on the ulnar border. Slightly distal to it a small protuberance of ulna can be felt, which is the ulnar styloid process.

Tenderness → fracture  
→ nonunion

**TFCC**

Feel the ulnar head dorsally. In the depression just distal to this is the TFCC. Sometimes slight flexion of the wrist helps to find the spot.

Tenderness → TFCC lesions

*Note: Rotation of the hand on fixed forearm with wrist ulnar-deviated (Grind test) increases the TFCC symptoms.*

**Pisiform**

This can be felt at the base of the hypothenar muscle and provides attachment for the flexor carpi ulnaris (FCU). The ulnar artery can be felt radial to the FCU tendon.

Tenderness → pisotriquetral osteoarthritis

### **Hamate**

This is radial and distal to the pisiform in line with the ring finger. To locate it, the examiner puts the interphalangeal crease of his thumb on the pisiform of in direction of the base of the patient's index finger. The tip of the examiner's thumb should feel a firm bony point, which is the hook of hamate.

Tenderness → fracture, nonunion

The pisiform and hamate are connected by the pisohamate ligament which makes the roof of the ulnar tunnel (Guyon's canal).

### **Guyon's Canal**

Floor: flexor retinaculum

Roof: pisohamate ligament

Ulnar border: pisiform

Radial border: hamate

The ulnar nerve has two sensory branches above the wrist which supply the dorsal and palmar aspects of the hand. Hence, if compression of the ulnar nerve occurs above the Guyon's canal, the patient will have altered sensation of the hand in addition to the fingers. The motor loss for a lesion above or in the canal is the same. In the other words, motor loss with preserved sensation in the little finger means lesion of the nerve beyond the bifurcation at the level of hook of hamate.

### **Trigger Finger**

The examiner palpates the A1 pulley, which is at the level of the transverse flexor crease of the palm or proximal flexor crease of the thumb, by putting his index finger and his thumb in position

(Figure 3.31a) and asking the patient to gently flex and extend the finger (Figure 3.31b). As the finger extends, the examiner may feel a sudden jerky movement or a nodule on the tendon.

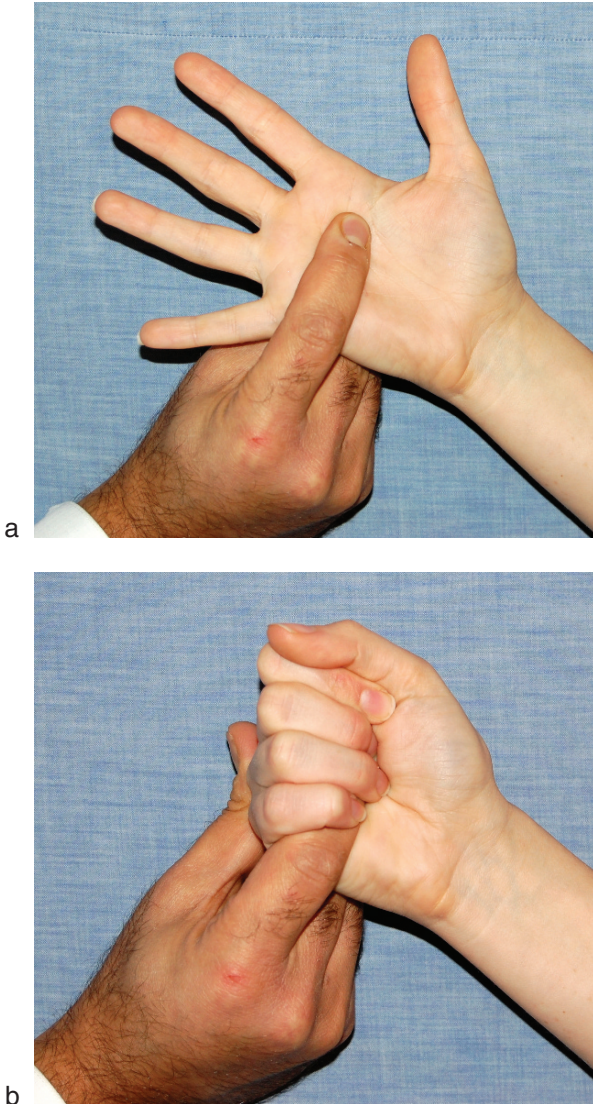


FIGURE 3.31. (a) Palpating the A1 pulley. (b) Active flexion and extension of hand by the patient.

### **Extensor Tendons**

If subluxation or dislocation of the MCPJs has occurred, the examiner must ascertain whether a tendon rupture is present or not. To do this, the examiner tries to bring the finger in question into extension and then asks the patient to maintain that position.

If the patient can maintain the finger in extension the extensor tendon is intact.

### **Range of movement**

#### **Supination /Pronation**

The patient is instructed to keep his elbows by his side and asked to show the palms of the hands and then the back of the hands. At times it is necessary for the examiner to keep a hand at the patient's elbow to ensure that movement of the shoulder does not compensate for deficient forearm rotation.

Normal range:

supination: 0–90°

pronation: 0–80°

#### **Wrist**

To assess dorsiflexion, ask the patient to put the palms of the hands together and bring the elbows up (prayer position) (Figure 3.32).



FIGURE 3.32. Dorsiflexion.

To assess palmar flexion, ask the patient to put the backs of the hands together ('reverse' prayer position) (Figure 3.33).

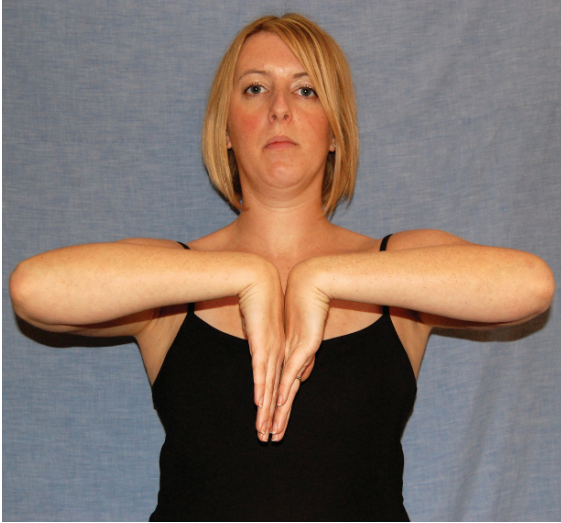

FIGURE 3.33. Palmar flexion.

To assess radial and ulnar deviation, ask the patient to keep the elbow by the side, pronate the forearm and then bend the wrist toward the radius (Figure 3.34) and ulna (Figure 3.35) respectively. It is sometimes easier to do the movements yourself and ask the patients to copy. Always do both sides simultaneously to compare.

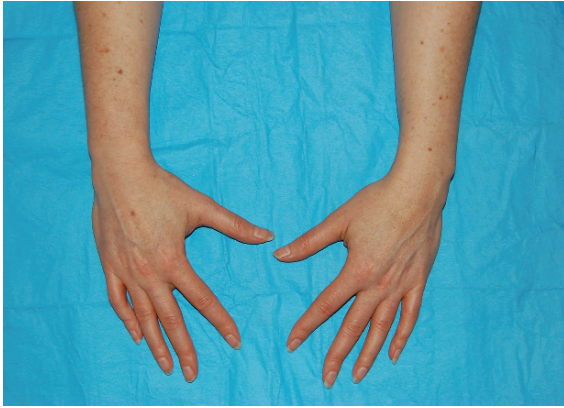

FIGURE 3.34. Radial deviation.

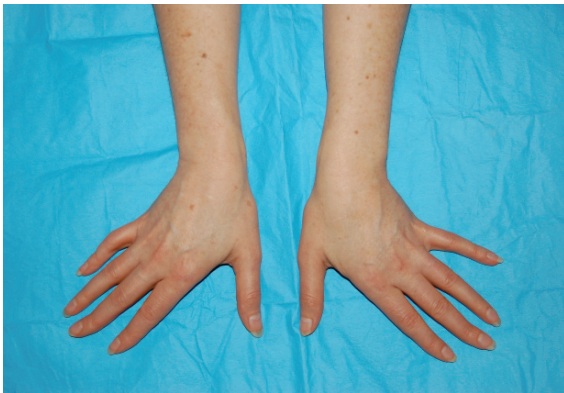

FIGURE 3.35. Ulnar deviation.

Normal range:

Dorsiflexion: 0–90°

Palmar flexion: 0–80°

Radial deviation: 0–20°

Ulnar deviation: 0–40°

### **Hand**

Ask the patient to make a fist and assess the gross finger movements. Individual joints can be measured if abnormality is detected.

Normal Flexion of Finger

MCPJ            0–90°

PIPJ            0–100°

DIPJ            0–80°

Passive movements of the finger should be performed with the MCPJ in hyperextension and repeated with the MCPJ in flexion. This differentiates intrinsic from extrinsic tightness and is known as the Bunnell test. In the presence of intrinsic tightness, the amount of flexion of the IPJs is less when the MCPJs are hyperextended.

Normal Flexion of Thumb

MCPJ            –5° (hyperextension) to 55°

IPJ              –20° (hyperextension) to 80°

### **Nerve and Muscle Examination**

The causes of neurological disorders vary widely.

The differential points of some of the neurological disorders are mentioned with each condition:

Lacerations → complete / incomplete loss of nerve function

Poliomyelitis → motor weakness only, no sensory loss

Leprosy → sensory changes first then motor weakness

Charcot-Marie-Tooth disease → extensive motor weakness, later dissociated sensory loss



### Common Neurological Conditions in Orthopedic Patients (in the developed world)

Individual nerve lesion:

1. Laceration
2. Compression neuropathy
3. Mononeuritis (diabetes mellitus)

Neurological disorders

1. MS, demyelination
2. Diabetic peripheral neuropathy
3. Polio (Rare)

#### Radial Nerve

The radial nerve is divided into the posterior interosseous nerve and a sensory branch at the level of the lateral epicondyle.

The following muscles are innervated by the radial nerve above the elbow joint:

1. Brachioradialis
2. Extensor carpi radialis longus (ECRL)

Injury to the nerve above the elbow joint results in high radial nerve palsy.

#### Posterior Interosseous Nerve

This is predominately a motor nerve and carries sensory fibres only from the dorsal wrist capsule. The following muscles are innervated by the posterior interosseous nerve:

1. Supinator (*Cannot be tested clinically*).<sup>5</sup>
2. Extensor carpi radialis brevis (ECRB): Variable
3. Extensor digitorum communis (EDC)
4. Extensor carpi ulnaris (ECU)
5. Extensor digiti minimi (EDM)
6. Abductor pollicis longus (APL)
7. Extensor pollicis longus (EPL)
8. Extensor pollicis brevis (EPB)
9. Extensor indicis proprius (EIP)

Injury to the nerve below the elbow joint results in low radial nerve palsy.

---

<sup>5</sup>Extension of the elbow limits action of the biceps and may reveal weakness in supinator.

**Brachioradialis**

The patient is asked to flex the elbow to 90° with the wrist in neutral and maintain the position. The examiner holds the elbow with one hand and exerts downward pressure to the radial border of the distal forearm with the other hand. The brachioradialis muscle stands out in the proximal forearm (Figure 3.36).

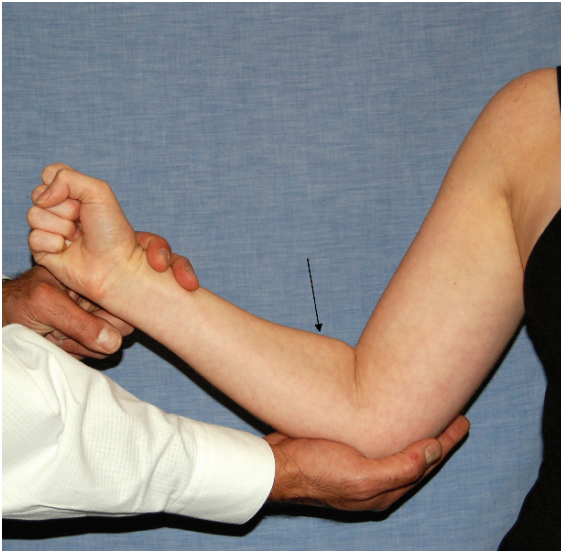

FIGURE 3.36. Assessing the Brachioradialis. The *black arrow* points toward the muscle.

**Extensor Carpi Radialis Longus and Brevis (ECRL and ECRB)**

The patient is asked to extend the wrist with radial deviation and flex the elbow to 90° while the arm is held tightly at the side. The examiner stabilizes the forearm with one hand and with the other hand exerts downward pressure on the radial side of the dorsum of the patient's hand (Figure 3.37). The tendons of the ECRL & ECRB can be felt about 1 cm ulnar to the radial styloid process.

*Note: It is extremely difficult to ascertain the integrity of the ECRB in the presence of an intact ECRL. The presence of an intact ECRB is variable in posterior interosseous nerve palsy. A patient with posterior interosseous nerve palsy will have at least one radial wrist extensor intact thus wrist extension is present but deviates to radial side.*

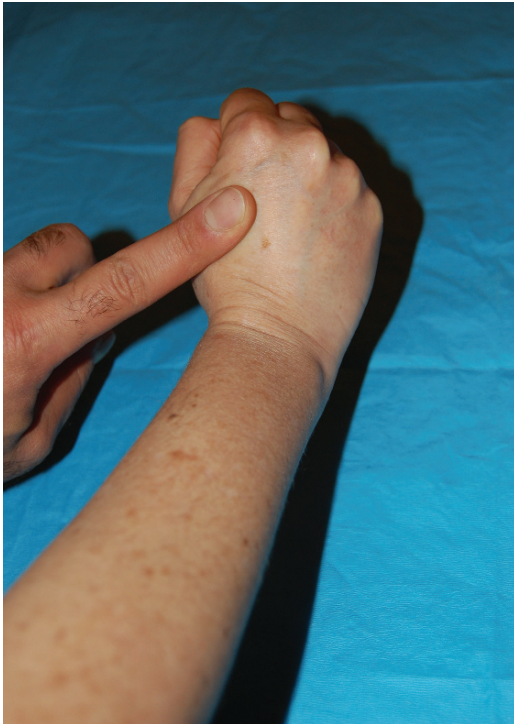

FIGURE 3.37. Extensor carpi radialis longus and brevis.

**Extensor Carpi Ulnaris (ECU)**

The patient is asked to extend the wrist with ulnar deviation and flex the elbow to 90° while the arm is held tightly at the side. The examiner stabilizes the forearm with one hand and with the other hand exerts downward pressure on the ulnar side of the dorsum of the patient's hand (Figure 3.38). The tendon of ECU can be felt just distal to the head of the ulna.

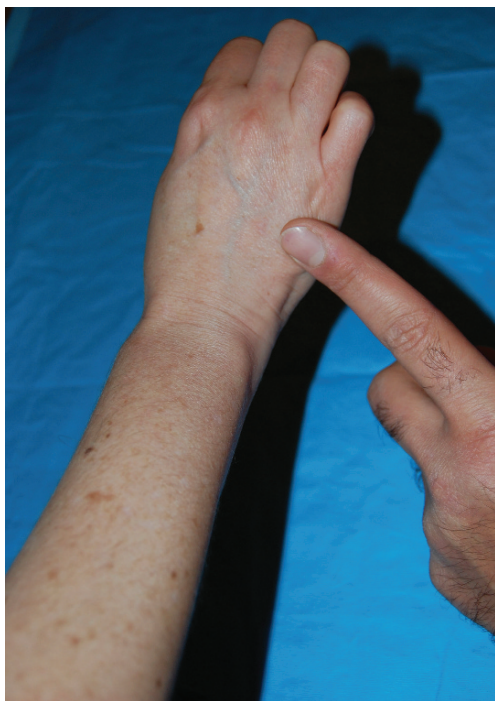

FIGURE 3.38. Extensor carpi ulnaris.

**Extensor Digitorum Communis (EDC)**

To test the EDC, the patient is asked to extend the fingers at the MCPJs and flex the PIPJs and IPJs (claw like position) and maintain the position, with the wrist in neutral and the forearm pronated. The examiner stabilizes the forearm with one hand and exerts pressure just distal to the MCPJs to flex the fingers (Figure 3.39).



FIGURE 3.39. Extensor digitorum communis.

**Extensor Digiti Minimi (EDM) and Extensor Indicis Proprius (EIP)**

These two muscles can be tested together. Ask the patient to make a fist and then extend the index and little fingers. The examiner stabilizes the forearm with one hand and exerts pressure just distal to the MCPJs to flex the fingers (Figure 3.40). The tendons of EIP and EDM are *ulnar* to the EDC in the index and little fingers.

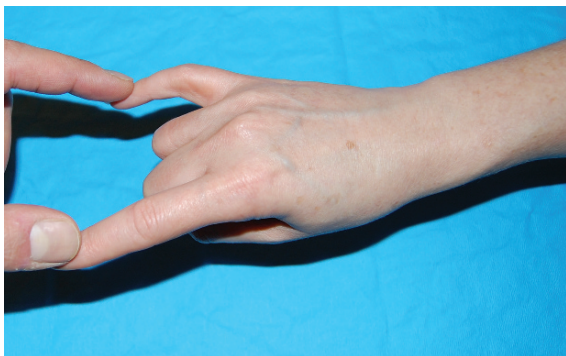


FIGURE 3.40. Extensor digiti minimi (EDM) and extensor indicis proprius (EIP).

**Abductor Pollicis Longus (APL)**

The examiner asks the patient to put his hand on the table and abduct the thumb against resistance. The APL tendon is visible just distal to the tip of the radial styloid process. (Figure 3.41).

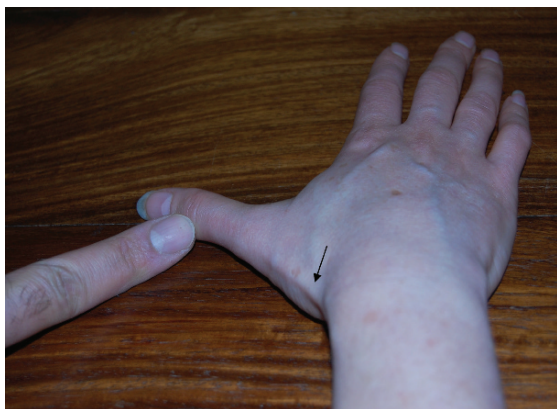

FIGURE 3.41. Abductor pollicis longus tendon (*black arrow*).

**Extensor Pollicis Longus (EPL)**

The patient keeps the hand flat on the table, and lifts the thumb off the table while keeping the palm in contact (table top test). The examiner may exert pressure to the tip of the thumb. The tendon of EPL is easily seen. This can be considered as an autonomous test for the radial nerve (Figure 3.42).

**EPL Tendon Rupture**

Seen in:

Rheumatoid arthritis

Complication of Colles' fracture

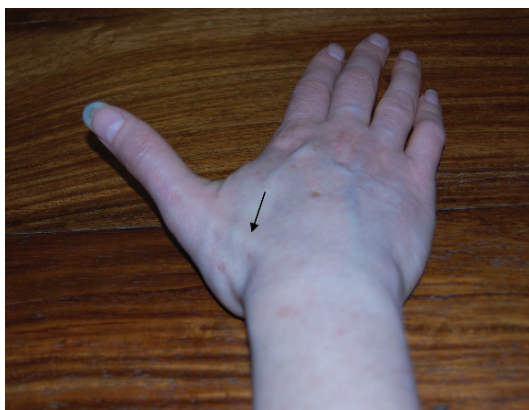

FIGURE 3.42. Extensor pollicis longus.

**Extensor Pollicis Brevis (EPB)**

The patient is asked to do a thumbs up sign and maintain the position. Then the examiner exerts pressure to the dorsum of the proximal phalanx to flex the MCPJ (Figure 3.43).

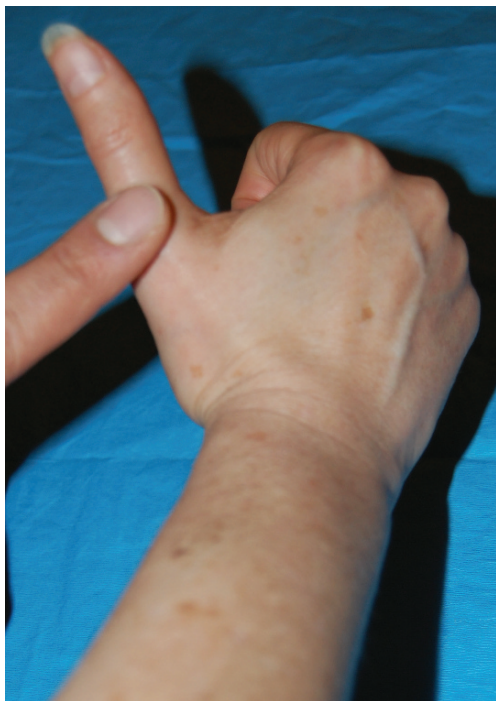

FIGURE 3.43. Extensor pollicis brevis.



### Muscle Insertion

Brachioradialis	Radial styloid
ECRL	Base of 2nd metacarpal
Supinator	Neck and shaft of radius
ECRB	Base of 3rd metacarpal
EDC	Middle and distal phalanx
ECU	Base of 5th metacarpal
EDM	Extensor expansion little finger
APL	Base of first metacarpal
EPL	Base of distal phalanx of thumb
EPB	Base of proximal phalanx of thumb
EIP	Extensor expansion index finger

### Median Nerve

The median nerve gives off a muscular branch and an anterior interosseous branch in the proximal forearm. It supplies the following muscles:

1. Pronator teres (PT)
2. Flexor carpi radialis (FCR)
3. Palmaris longus (PL)
4. Flexor digitorum superficialis (FDS)
5. Flexor digitorum profundus (FDP) middle finger
6. Anterior interosseous nerve:
  - a. Flexor digitorum profundus (FDP) index finger
  - b. Flexor pollicis longus (FPL)
  - c. Pronator quadratus (PQ)

Injuries to the nerve *proximal to the origin of the anterior interosseous nerve* result in high median nerve palsy.

The median nerve supplies the following muscles after crossing the wrist joint:

1. Abductor pollicis brevis (APB)
2. Opponens pollicis
3. Flexor pollicis brevis (FPB)
4. Two radial lumbricals

*Note: Thumb abduction and opposition are frequently retained in low median nerve palsy due to variability of thenar muscle innervations.*

**Pronator Teres (PT) and Pronator Quadratus (PQ)**

These two muscles are tested together. The patient is asked to keep the elbow flexed to 90° and keep the forearm in full supination. The examiner holds the distal forearm and asks the patient to turn the hand over (Figure 3.44).

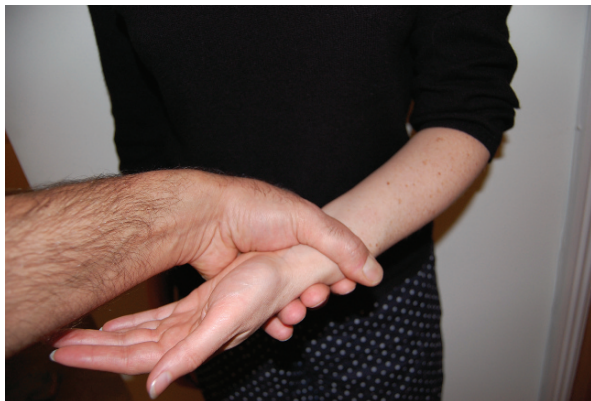

FIGURE 3.44. Assessing pronator teres and pronator quadratus.

**Flexor Carpi Radialis (FCR)**

The patient is asked to supinate the forearm, flex and radially deviate the wrist and flex the elbow to 90° while the arm is held tightly at the side. The examiner stabilizes the forearm with one hand and exerts downward pressure to the radial side with the other hand (Figure 3.45).

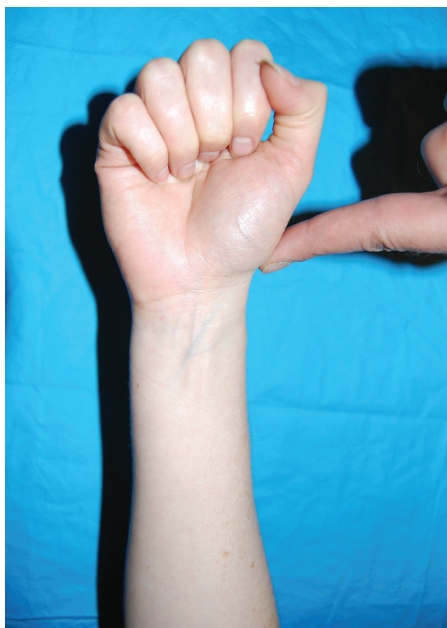

FIGURE 3.45. Flexor carpi radialis.

**Palmaris Longus (PL)**

The patient is asked to bring the pulps of the thumb and little finger together, with the wrist in slight flexion (Figure 3.46). Occasionally exerting resistance to the wrist helps the tendon to become more prominent. The presence of this muscle is important, especially when planning tendon transfer.

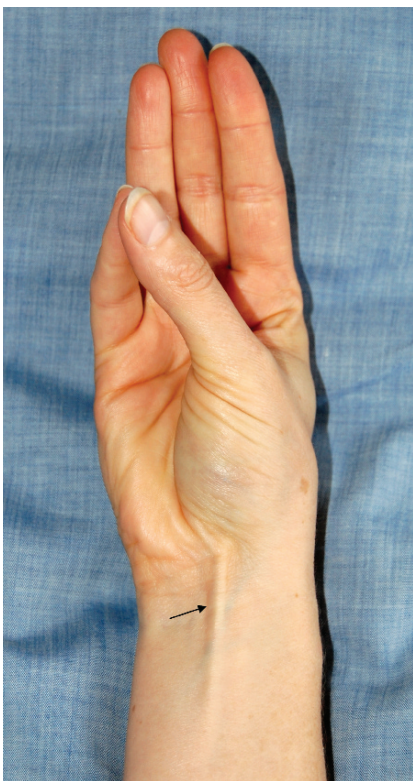

FIGURE 3.46. Palmaris longus tendon (*black arrow*).

**Flexor Digitorum Superficialis (FDS)**

The patient's hand is palm up on the table. The patient is then instructed to flex one finger while the examiner holds the other three fingers in full extension (Figure 3.47). To ensure the FDP is not acting, the examiner moves the DIPJ passively. It should be flail.

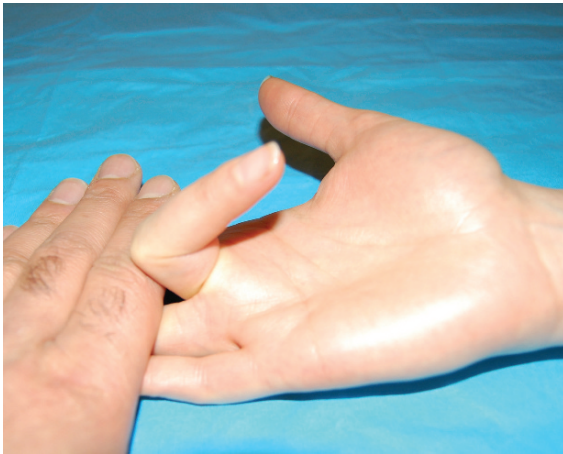

FIGURE 3.47. Assessing the flexor digitorum superficialis.

**Flexor Digitorum Profundus (FDP) Middle Finger**

The examiner stabilizes the PIPJ of the finger in extension and then asks the patient to bend the tips of the finger (Figure 3.48).

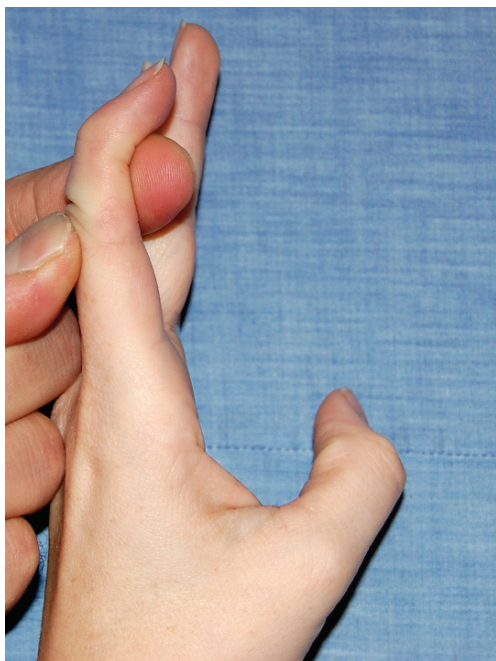

FIGURE 3.48. Assessing the flexor digitorum profundus.

**Abductor Pollicis Brevis (APB)**

The patient is asked to put the hand on the table with the palm facing up, then bring the thumb toward the ceiling and maintain the position (Figure 3.49). The examiner exerts pressure on the radial side of the thumb (Figure 3.50) and feels for contracture of the muscle at the thenar eminence. This is the autonomous motor test for the median nerve.

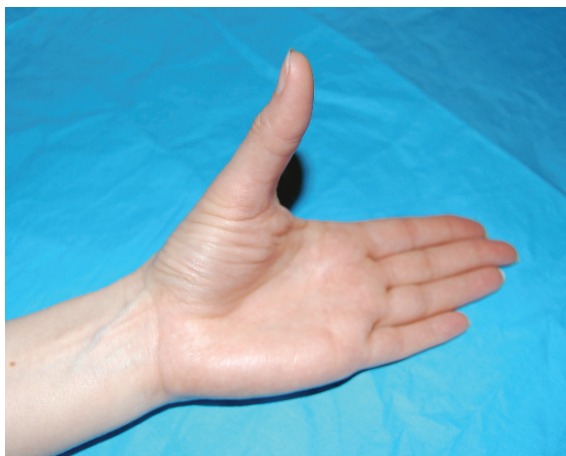

FIGURE 3.49. Thumb toward the ceiling to assess abductor pollicis brevis.

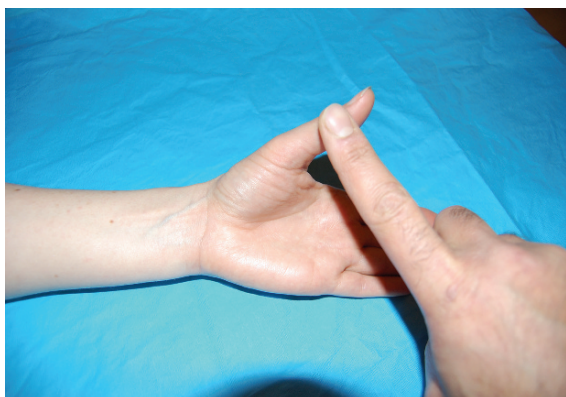

FIGURE 3.50. Assessing abductor pollicis brevis.

**Opponens Pollicis**

The patient is asked to bring the tips of the thumb and little finger together and maintain the position. The examiner then exerts pressure to the little finger and the thumb to pull them apart (Figure 3.51).

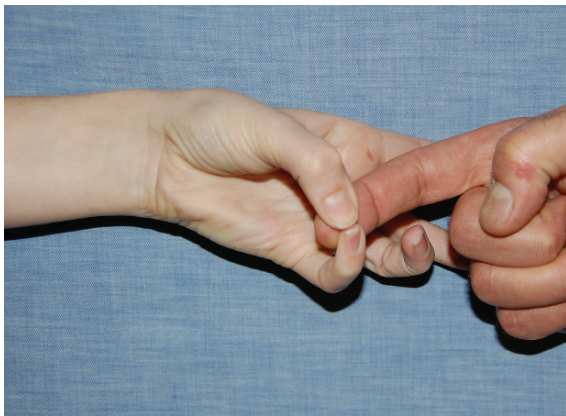


FIGURE 3.51. Assessing the opponens pollicis.



**Flexor Pollicis Brevis (FPB)**

The patient is asked to flex the thumb in the palm and maintain the position. The examiner then exerts pressure to the proximal phalanx, trying to bring it into extension (Figure 3.52).

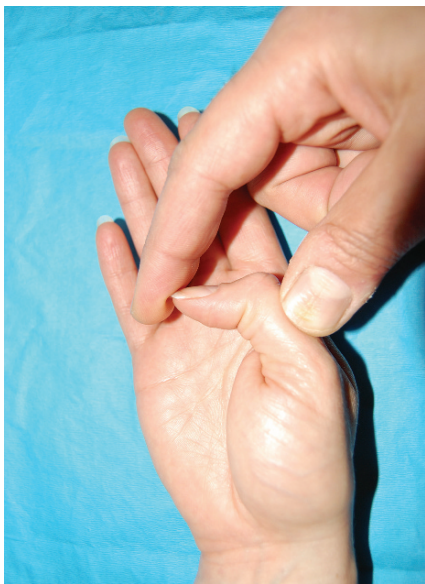

FIGURE 3.52. Assessing the flexor pollicis brevis.

### Two Radial Lumbricals

All the lumbricals are tested together. The patient is asked to flex the MCPJs to 90° with the fingers straight. The examiner then exerts pressure to the DIPJs, trying to flex the fingers (Figure 3.53).

#### Muscle Insertion

PT	Lateral shaft of radius
FCR	Base of 2nd and 3rd metacarpals
PL	Flexor retinaculum and palmar aponeurosis
FDS	Middle phalanx
FDP	Distal phalanx
FPL	Distal phalanx of thumb
PQ	Anterior shaft of radius
APB	Base of proximal phalanx of thumb
Opponens pollicis	Shaft of metacarpal of thumb
FPB	Base of proximal phalanx of thumb
Lumbricals	Extensor expansion

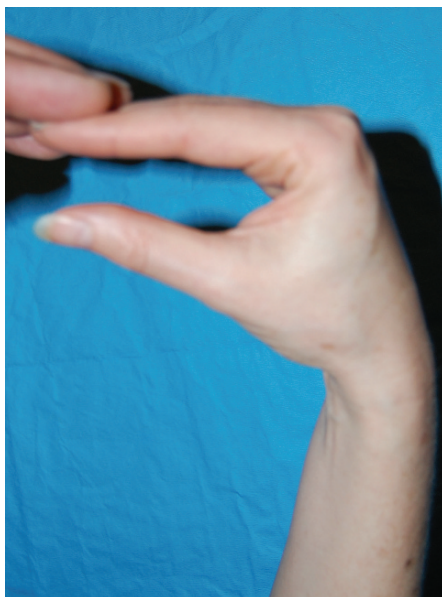


FIGURE 3.53. Assessing the lumbricals.

**Ulnar Nerve**

The ulnar nerve gives off two muscle branches in the proximal forearm:

1. Flexor carpi ulnaris (FCU)
2. Flexor digitorum profundus (FDP) ring and little finger

Injury to the nerve proximal to the elbow joint results in high ulnar nerve palsy.

The ulnar nerve innervates the following muscles after crossing the wrist joint:

1. Opponens digiti minimi
2. Abductor digiti minimi
3. Flexor digiti minimi brevis
4. Adductor pollicis
5. Two ulnar lumbricals
6. Dorsal Interossei
7. Palmar Interossei
8. Flexor pollicis brevis (deep head) - variable

**Flexor Carpi Ulnaris (FCU)**

The patient is asked to supinate the forearm, flex and ulnar-deviate the wrist and flex the elbow to 90°, while the arm is held tightly at the side. The examiner stabilizes the forearm with one hand and exerts downward pressure to the ulnar side with the other hand (Figure 3.54).

**Flexor Digitorum Profundus (FDP) Ring and Little Finger**

The examiner stabilizes the PIPJ of the fingers in extension and then asks the patient to bend the tips of the fingers.

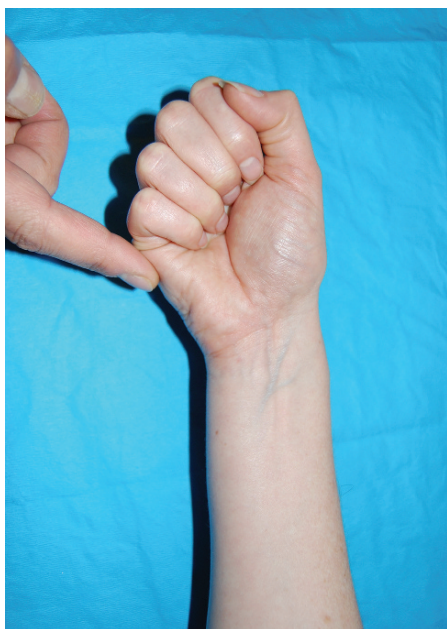

FIGURE 3.54. Assessing the Flexor carpi ulnaris.

**Opponens Digiti Minimi**

The patient is asked to bring the tips of the thumb and little finger together and maintain the position. The examiner then exerts pressure to the little finger and the thumb to pull them apart (Figure 3.51).

**Abductor Digiti Minimi**

The patient is asked to abduct the little the finger and maintain the position while the forearm is pronated and the elbow flexed to 90°. The examiner then presses his index finger against the ulnar border of the patient's little finger, while with the other hand feeling for the muscle contracture in the hypothenar eminence (Figure 3.55). This can be considered an autonomous motor test for the ulnar nerve.

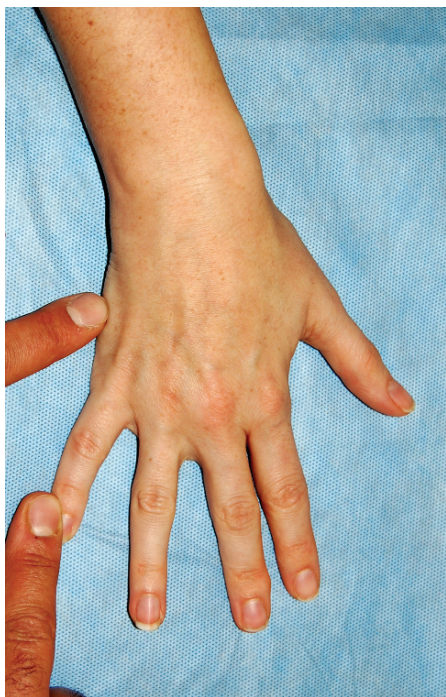

FIGURE 3.55. Assessing the abductor digiti minimi.

**Adductor Pollicis**

The examiner places one finger between the thumb and the index finger metacarpal and asks the patient to adduct the thumb against the examiner's finger (Figure 3.56).

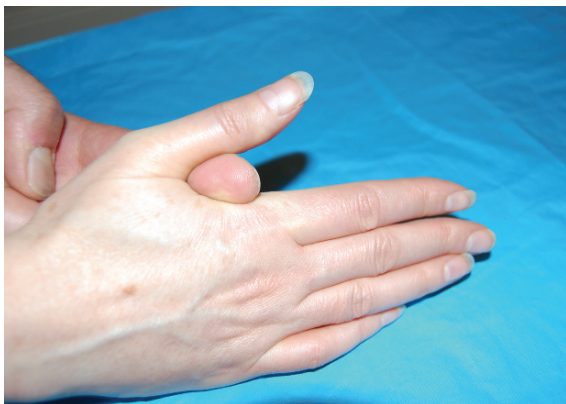

FIGURE 3.56. Assessing the adductor pollicis.

### Two Ulnar Lumbricals

All the lumbricals are tested together. The patient is asked to flex the MCPJs to 90° with the fingers straight. The examiner then exerts pressure to the DIPJs, trying to flex the fingers (Figure 3.53).

### Dorsal Interossei

Dorsal interossei are finger abductors. The patient is asked to spread the fingers as far apart as possible and maintain the position, while the forearm is pronated and the elbow flexed to 90°. The examiner then exerts pressure to the index and little finger to push them back together (Figure 3.57).

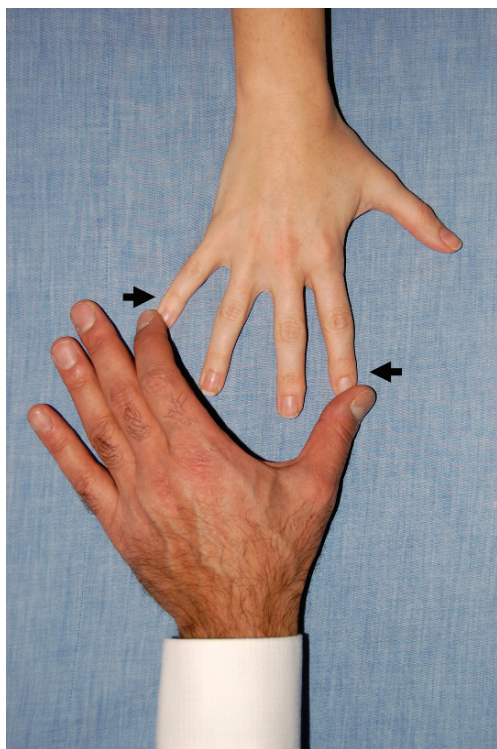


FIGURE 3.57. Note the direction of the force.



Alternatively, to test the first dorsal interosseous, the patient is asked to put the hand on the table palm down and abduct the index finger and maintain the position. The examiner then presses his index finger against the radial border of the patient's index while with the other hand feeling for the muscle contraction (Figure 3.58).

**The action of different sets of lumbricals can be remembered as:**

**Dorsal** → **AB**duct

**Palmar** → **AD**duct

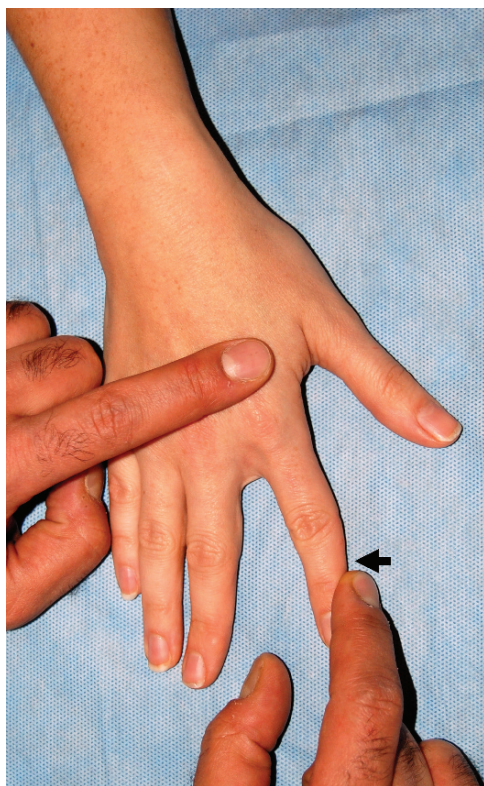


FIGURE 3.58. Note the direction of the force.



### Palmar Interossei

Palmar interossei are finger adductors. The examiner places a piece of paper between the patient's index and middle fingers and asks him/her to squeeze the fingers together and hold the paper. The examiner then withdraws the paper and resistance is noted (Figure 3.59). The test is repeated for the other fingers.

**If the patient can do a thumbs up sign, all the three nerves above the elbow joint are intact.<sup>6</sup>**

Radial nerve → EPL

Median nerve → FDP index and middle finger

Ulnar nerve → FDP ring and little finger

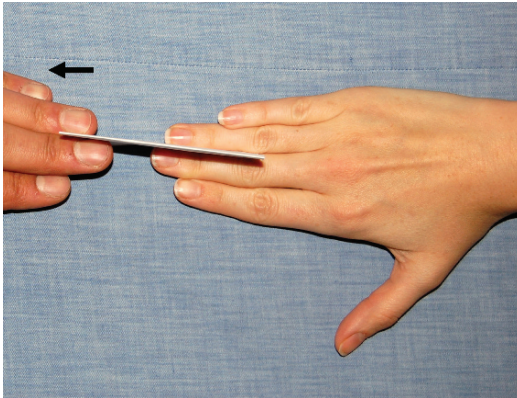


FIGURE 3.59. Assessing the palmar Interossei.

<sup>6</sup>I learned this from one of my great teachers, Dr. Sharath Kumar Rao (Professor and Unit chief, Department of Orthopaedics, Kasturba Medical College, Manipal, India), a gifted surgeon and a superb clinician. To my knowledge, it has not been reported in the literature.

### **Muscle Insertion**

FCU	Pisiform, base of 5th metacarpal
FDP	Distal phalanx
Opponens digiti minimi	Medial border 5th metacarpal
Abductor digiti minimi	Base of proximal phalanx
Flexor digiti minimi brevis	Base of proximal phalanx
Adductor pollicis	Base of proximal phalanx
Lumbricals	Extensor expansion
Dorsal Interossei	Proximal phalanges, dorsal expansion
Palmar Interossei	Proximal phalanges, dorsal expansion

### **Sensory Branches**

All three nerves supply sensory branches to the hand.

Radial nerve: lateral side of dorsum of the hand and the lateral 3½ fingers

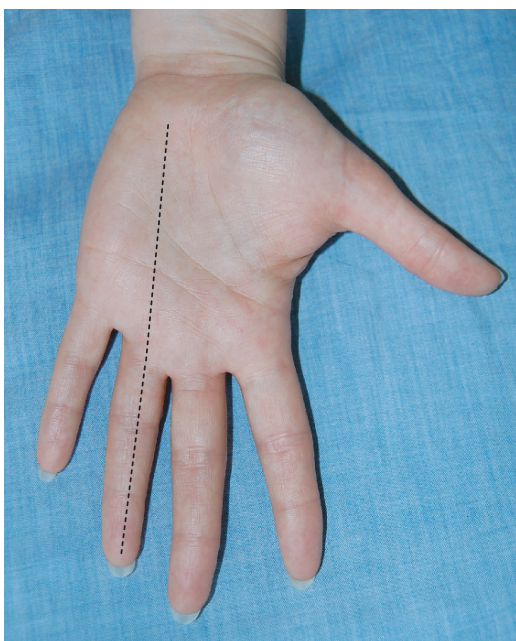
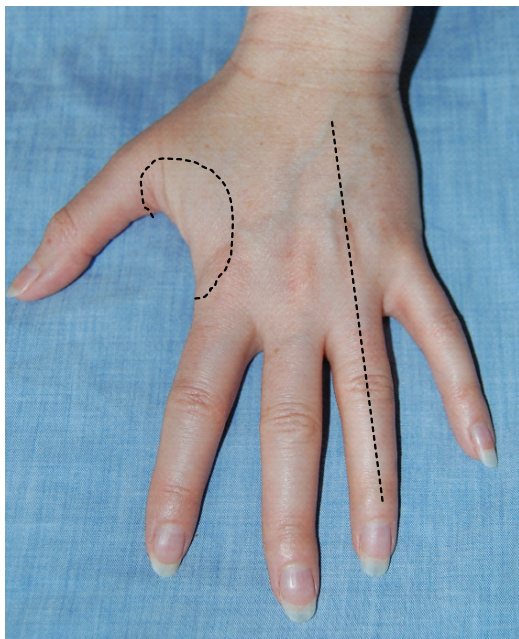
Autonomous zone: dorsal 1st web space

Median nerve: palmar and dorsal lateral 3½ fingers, thenar eminence

Autonomous zone: tip of the index finger

Ulnar nerve: palmar and dorsal medial 1½ fingers, hypothenar eminence medial side of dorsum of the hand

Autonomous zone: tip of the little finger



## Special Tests

### Modified Durkan's Test

This is a test for diagnosis of carpal tunnel syndrome. The examiner exerts direct compression over the median nerve between the tendons of PL and FCR at the wrist joint with his index finger for a minute (Figure 3.60). If compression of the median nerve produces numbness or tingling of the fingers, then irritation of the nerve is suspected. The time for development of symptoms and severity of the compression of the median nerve are in direct proportion.

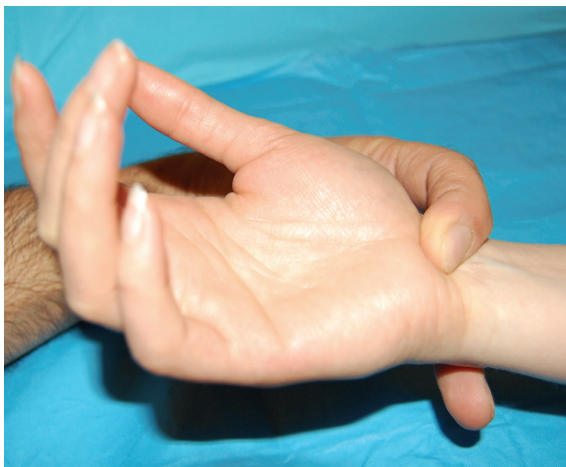


FIGURE 3.60. Modified Durkan's test.

**Tinel's Sign**

This is another test for diagnosis of carpal tunnel syndrome. The patient's wrist is supported on the table. With the tip of the middle finger, the examiner taps the median nerve between the tendons of PL and FCR. The test is considered positive if the patient complains of pain or a shooting electric current sensation down the hand (Figure 3.61). *Advancing* Tinel's sign is the most important clinical test in eliciting regeneration of a peripheral nerve after injury at any site.

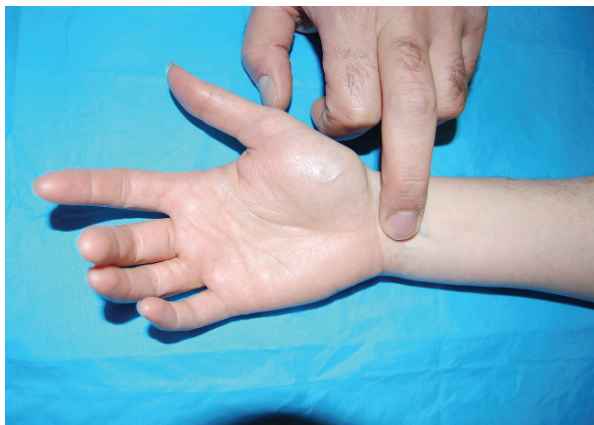

FIGURE 3.61. Tinel's sign.

**Finklestein's Test**

This is a test for stenosing tenovaginitis (de Quervain's disease) of the EPB and APL tendons. The patient is instructed to flex the thumb in the palm. The examiner then either passively deviates the wrist toward the ulna or asks the patient to do it actively (Figures 3.62 and 3.63). If painful, the diagnosis is confirmed.

*Note: This test can be uncomfortable; hence it is important to do it last in the sequence of the examination.*

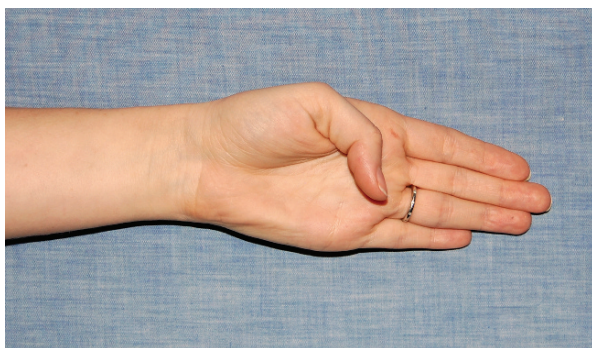


FIGURE 3.62. Finklestein's test.

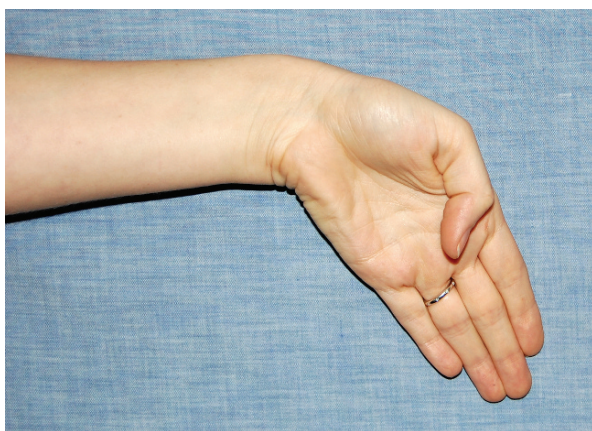


FIGURE 3.63. Finklestein's test. Active ulnar deviation.



**Froment's Test**

This is another method to test adductor pollicis and is often used to demonstrate ulnar nerve pathology. The patient is asked to hold a piece of paper between the thumb and index finger while the examiner applies gentle traction to withdraw the paper (Figure 3.64). If the adductor pollicis is normal the patient's




FIGURE 3.64a. Froment's test




FIGURE 3.64b. Froment's test, side view.

thumb should remain flat. In weakness of the adductor pollicis, the patient recruits the FPL to hold on to the paper. This causes flexion of the IPJ (Figure 3.65).




FIGURE 3.65. Positive Froment's test.



**Kiloh-Nevin (The “O”) Sign**

This is a test for the anterior interosseous nerve. The patient is asked to make a nail to nail pinch and maintain the position (Figure 3.66). The examiner then assesses the strength of FPL and FDP by hooking his index finger inside the “O” and trying to pull them apart.

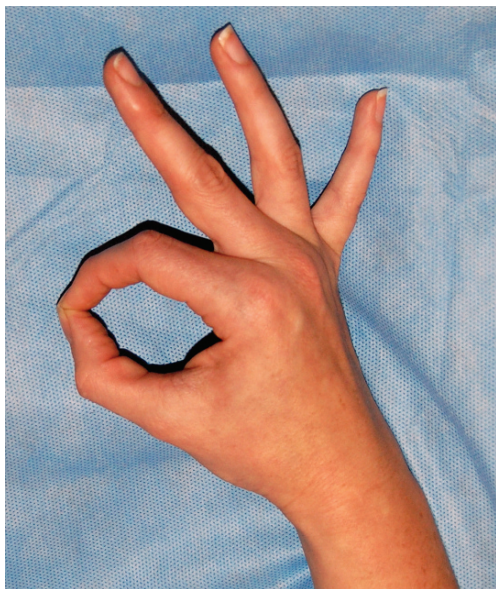


FIGURE 3.66. Kiloh-Nevin (“O”) sign. Note the flexion of IPJ of thumb and DIPJ of index finger.

**Kirk Watson Test**

This is a test for scapholunate instability. The patient's forearm is pronated, with the wrist in ulnar deviation. The examiner presses the thumb over the distal pole of the patient's scaphoid and the fingers of the same hand over the distal radius, providing counter pressure. The examiner then brings the wrist to radial deviation (Figure 3.67). In scapholunate instability, the proximal pole of the scaphoid subluxes over the dorsum of the radius, which may be associated with a clunk. By releasing the pressure from the thumb, the scaphoid can pop back into the joint. It can be very painful.

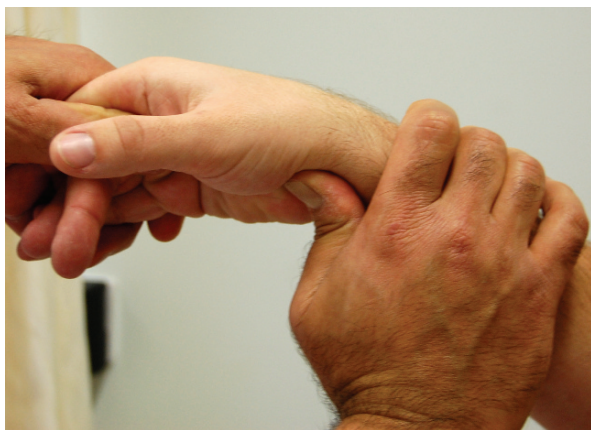

FIGURE 3.67. Kirk Watson Test.

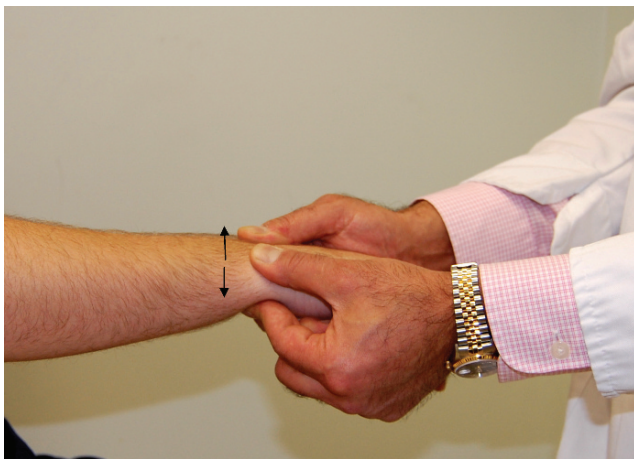

FIGURE 3.68. Piano key test.

### **Piano Key Test**

This is the test to elicit subluxation or arthritis of the radioulnar joint. The patient is asked to flex the elbow and pronate the forearm. To test the right side, the examiner holds the distal radius with his right thumb and index finger and moves the head of the ulna up and down (Figure 3.68). If the amount of translation is more than on the other side, instability is suspected. Pain or clicking during this maneuver is suggestive of arthritis of the radioulnar joint. It is typically associated with rheumatoid arthritis and caput ulnae.

### **Grind Test**

This is the test to elicit arthritis in the CMCJ of the thumb. The examiner holds the metacarpal with his thumb and index finger and presses down to reduce the joint, then loads it axially and moves it in a circular movement. A diagnosis of arthritis is suspected if the manoeuvre reproduces the patient's pain.

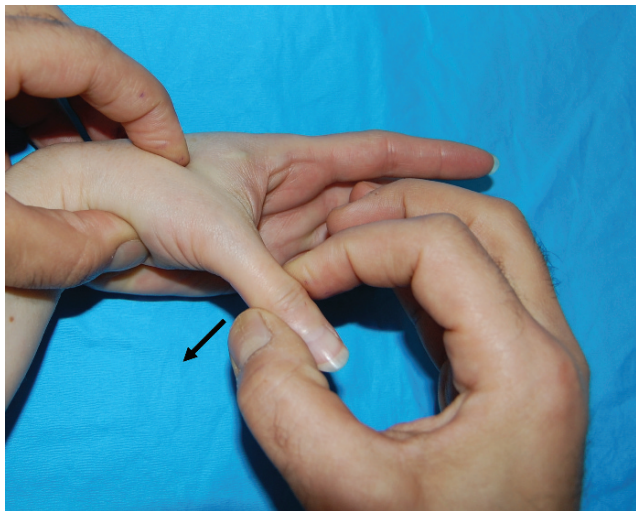


FIGURE 3.69. Assessment of ulnar collateral ligament stability. Note the direction of the force.

### **Ulnar Collateral Ligament (UCL) Stability**

Stability of the ulnar collateral ligament of the thumb is vital for grip. The examiner holds the metacarpal of the thumb just below the joint. The phalanx should be flexed to relax the capsule. Then gentle abduction force is applied to the MCPJ (Figure 3.69). If the amount of abduction is significantly more than the normal side with no firm end point, rupture of the ulnar collateral ligament is suspected. Alternatively the patient can attempt to abduct the thumb with his index finger. The amount of laxity is compared with the opposite side.

### **Bunnell Test**

This differentiates intrinsic from extrinsic tightness. The examiner hyperextends the MCPJ and measures the PIP flexion. The test is repeated with MCPJ flexed. In the presence of intrinsic tightness, the amount of flexion of PIP joints is less when MCPJs are hyperextended.

# Chapter 4

## Spine

---

### THE CERVICAL/THORACIC SPINE

#### LISTEN

Patients with spinal problems usually complain of back/neck pain and/or limb pain with a resultant loss of function.

#### Mechanism of Injury (If Applicable)

Fall from height/road traffic accident → fractures/ligamentous injury

Twisting or lifting injury/fall from low height → cervical strain  
→ herniated disc  
→ fracture in osteoporotic patient

#### Age

##### Children

- Congenital /developmental disorders
- Infection
- Primary tumor
- Trauma

##### Adults

- Herniated disc
- Spondylolisthesis
- Acute fractures

##### Older adults

- Spondylosis
- Stenosis
- Osteoporotic fractures
- Metastatic disease

**Pain****Site of pain**

Neck/thoracic spine pain → degenerative disc disease  
→ facet joint pathology  
→ herniated disc  
→ spinal deformity  
→ infection  
→ tumor

**Pain Pattern in Facet Joint Pathology**

C1-2 articulation → Suboccipital pain  
C2-3 facet → Upper neck pain radiate to head  
C3-4-5 facet → Mid neck pain  
C6-7-T1 facets → Lower neck pain radiate to scapula

Neck and arm pain → herniated disc  
→ spinal stenosis  
→ infection  
→ tumor

Unilateral → herniated disc

Bilateral → metabolic/systemic disease  
→ central disc prolapse

**Type of pain**

Aching pain → degenerative changes  
→ stenosis  
→ myofascial

Sharp radiating pain → herniated disc

Night/ Rest pain → usually not mechanical in origin. In patients with no history of trauma, other causes, such as primary or metastatic bone tumor, should be ruled out.

**Onset of Pain**

Sudden onset → herniated disc  
→ infection  
→ tumor

Gradual onset → stenosis  
→ spondylosis  
→ rheumatoid arthritis  
→ inflammatory arthropathy

**Relieving Factor**

Pain relieved by activity → ankylosing spondylitis

**Stiffness**

Stiffness is common and nonspecific in many pathological conditions. However *prolonged* morning stiffness is seen in:

Rheumatoid arthritis

Ankylosing spondylitis

Other inflammatory arthropathies

**Numbness or Paresthesia**

May be associated with radiculopathy. Usually patient's complaint of numbness/paresthesia points to the dermatomal level of lesion

Neck → C3

Shoulder tip → C4

Deltoid and lateral elbow → C5

Thumb → C6

Middle finger → C7

Little finger → C8

Medial elbow → T1

Medial arm → T2

Axilla → T3

Nipple → T4

Chest wall → T5-8

Abdominal wall → T9-12 (umbilicus is T10)

**Weakness of the Arms/Hands**

Herniated disc

Cervical spondylosis/stenosis

Cervical stenosis produces *lower motor neurone* finding at the level of the lesion and *upper motor neurone* deficit below the lesion.

**Deformity**

Ankylosing spondylitis  
Scheuermann's disease  
Kyphosis  
Scoliosis

**Myelopathy**

A myelopathy is a neurological disorder involving spinal cord or brain resulting in the upper motor neuron lesion. It affects both upper and lower limb.

Signs & Symptoms:

- unsteady gait
- limb weakness (upper>lower limb)
- sensory changes
- spasticity
- urinary dysfunction

Bowel or Bladder dysfunction → myelopathy

Difficulty with walking/balance → myelopathy due to cervical or thoracic spondylosis

*Note: If myelopathy suspected, do not forget to look at the hands for Wartenberg's sign. Little finger spontaneously abducts due to weakness of intrinsic.*

**LOOK****Scars**

Comments on

Location

Surgical or traumatic

Healed with primary or secondary intention

**Skin Abnormalities**

Dimple, or hair, tuft → spina bifida

Abnormal pigmentation → neurofibromatosis (up to 4 café-au-lait spots is normal)



**Alignment**

Stiff neck → patient keeps the neck in one position (often due to muscle spasm)

**Causes**

Disc lesions (tilt toward the lesion)

Inflammatory process

Cervical injury

Acute cervical strain

Torticollis → the chin is tilted upward and toward one side.

**Causes of Torticollis**

1. Infantile
2. Secondary due to
  - skin scarring and burns
  - herniated disc
  - infections including tuberculosis
  - ankylosing spondylitis

From behind

Level of the shoulders

Scapula for winging

From side

Lordosis of cervical spine, kyphosis of thoracic spine and lordosis of lumbar spine. Base of occiput rests directly above the sacrum.

Chest Wall Asymmetry (Pectus Excavatum, Pectus Carinatum)

**Pectus Excavatum (funnel chest):** the sternum is depressed giving a concave shape to chest.

**Pectus Carinatum (pigeon chest):** the sternum is protruded giving a convex shape to chest.

**Kyphotic Curve**

Differentiate between simple kyphosis, gibbus, and Dowager's hump. A curve at the C7/T1 junction is typical of ankylosing spondylitis, whereas if in the thoracic spine, it may indicate previous Scheuermann's disease or osteoporotic wedge fractures.

**Kyphosis:** normal and abnormal dorsal curvature of spine.

**Gibbus:** sharp posterior angulations due to collapse or wedging of one or more vertebrae.

**Dowager's hump:** abnormal dorsal curvature of the upper thoracic/cervical spine due to osteoporotic collapse commonly found in elderly women. "Dowager" means widow of British peer.

## **Abnormal Gaits**

### **Shuffling Gait**

The patient is unaware of position of swinging foot in the space and hence unable to determine the moment of heel strike.

Cause: Posterior cord syndrome (loss of proprioception below the lesion)

### **Foot Drop or Slap Foot Gait**

The foot is either dragged on the ground during swing phase or it hit the ground on each step.

Causes:

Posterior cord syndrome

L4 nerve root compression

### **Ataxic Gait**

Broad based and unsteady

Causes

Alcohol abuse

Myelopathy subsequent to significant cervical/central thoracic stenosis

## FEEL

### Spinous Process

- Palpate the tip of spinous processes along the length of the cervical and thoracic spine. Feel for any tenderness or abnormal step deformity (spondylolisthesis). Start at the top. The first you will feel is C2. The most prominent is C7 and can be distinguished from T1 as it glides on neck extension. C3 is at the level of hyoid and C4 is at the level of thyroid cartilage (Adam's apple).
- Localize the position of tender points to bony structure and surrounding muscles.
- Any shift in alignment may indicate facet dislocation or fracture.
- Are there any changes in temperature in the skin and feel for consistency of any lumps (bony, muscle spasm).
- Trachea, thyroid and esophagus should be palpated. Look for lymphadenopathy in patients with history of cancer.

### Facet Joint

Ask the patient to relax the neck muscles. With posterolateral approach you could palpate the cervical facet joints about 2.5 cm from midline. Count from C7 up, to identify the painful facet joint(s). They are about a finger breadth apart from each other and arranged symmetrically. Often one or more is painful and reproduces patient's pattern of pain.

**MOVE****Cervical Spine**

Best assessed by actively instructing the patient on the movement required.

Deficits in flexion/extension/lateral bend and rotation need to be noted. Most of the conditions result in a global reduction of neck movements.

**Flexion**

“Chin to chest”(Figure 4.1): Observe the patient for any pain during flexion. Midrange pain is due to instability. Normal: 75°

Flexion is limited and/or painful in:

- Spondylosis (Osteoarthritis)

- Herniated disc

- Rheumatoid arthritis

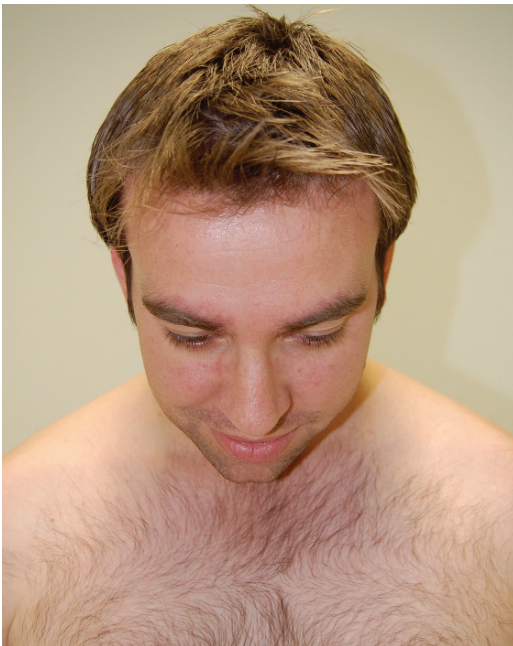

FIGURE 4.1. Flexion of cervical spine.

**Extension**

“Look up at the ceiling” (Figure 4.2). Normal: 60°

Extension is limited and/or painful in:

Facet joint degeneration

Herniated disc

Rheumatoid arthritis

Fixed scoliosis/kyphosis

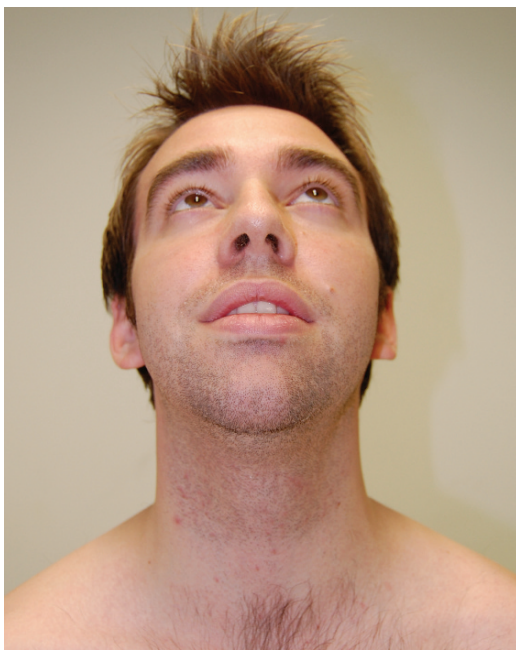

FIGURE 4.2. Extension of cervical spine.

### **Lateral Flexion**

“Put your ear on shoulder”(Figure 4.3): Patient with limited movements, may bring the shoulder to ear! Normal: 20°–45°

Lateral flexion is limited and/or painful in:

Cervical radiculopathy with lateral flexion to the contralateral side.

Lymphadenopathy

Torticollis



FIGURE 4.3. Lateral flexion of cervical spine.

**Lateral Rotation**

“Put your chin on your shoulder” (Figure 4.4). Normal :70°–90°  
Limited rotation and /or painful in:

Rheumatoid arthritis

Spondylosis

Cervical sprain

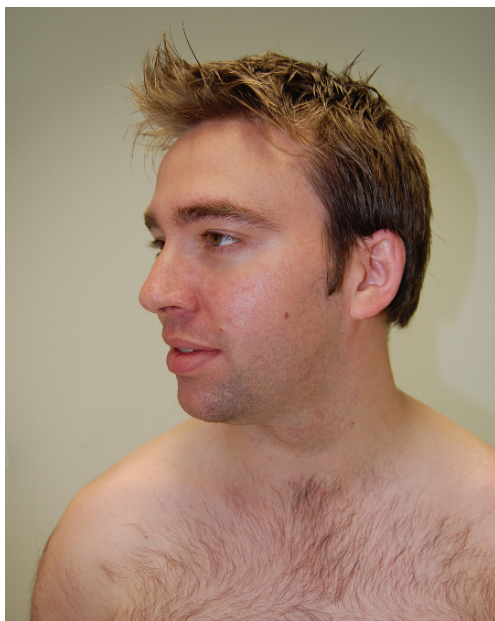

FIGURE 4.4. Lateral rotation of cervical spine.

## Thoracic Spine

### Flexion and Extension

Flexion and extension in the thoracic spine is limited. The patient is asked to sit on a straight-backed chair (to reduce the lumbopelvic movement) and then instructed to bend forward and then backward.

Normal flexion:  $20^{\circ}$ – $45^{\circ}$

Normal extension:  $25^{\circ}$ – $45^{\circ}$

### Rotation

With the patient in a sitting position, ask him to cross the arms or place the hands on opposite shoulders and then rotate to right and left (Figure 4.5).

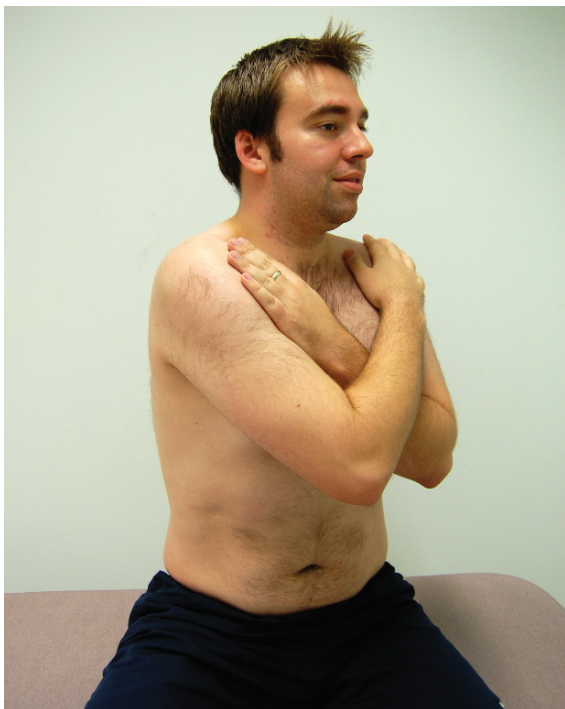

FIGURE 4.5. Assessing the rotation of the thoracic spine.



### Chest Expansion

With the patient in a standing position, a tape measure is placed at the level of the nipples (4th intercostal space). Take the measurement at maximum exhalation (Figure 4.6). Then the patient is asked to inhale as much as possible and hold the breath while a second measurement is taken. Usually the difference between the two readings should be above 5 cm. Chest expansion is said to be decreased if it is less than 2.5 cm, which may be a sign of ankylosing spondylitis.

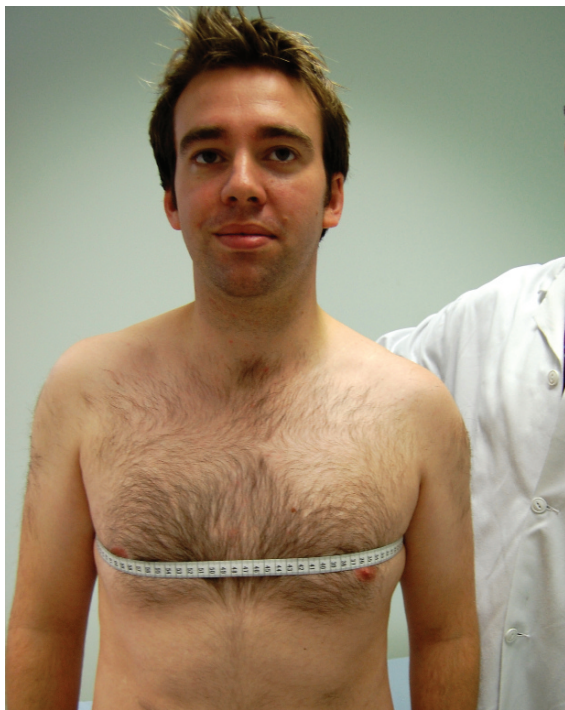

FIGURE 4.6. Measurement of chest expansion.

## Muscle Testing

Examination of the muscles is done to determine the involved nerve root level.

### C5 Nerve Root

Exits between C4-5 vertebrae.

Deltoid muscle is tested.

The patient is asked to abduct the arm to 60–90° and maintain this position while the examiner exerts downward pressure on the elbow (Figure 4.7)

### C5 Nerve Root Compression

C4-5 disc herniation or other pathology

Sensory deficit

Upper lateral arm and elbow

Muscle weakness

Deltoid

Biceps (variable)

Reflex changes

Biceps

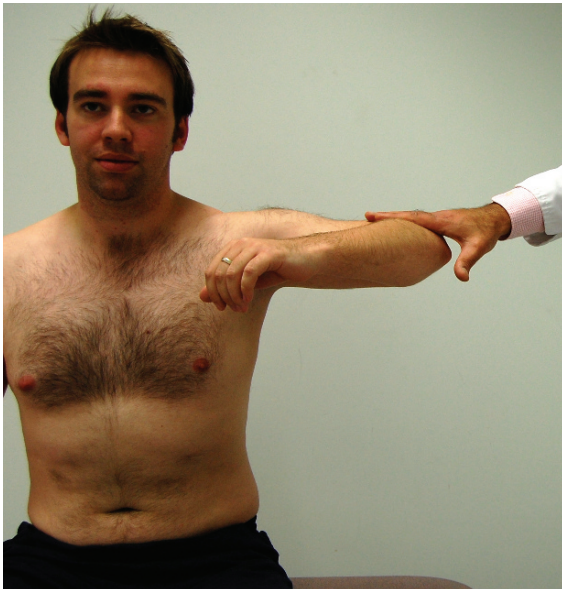

FIGURE 4.7. Assessing the deltoid.

### C6 Nerve Root

Exits between C5-6 vertebrae.

Biceps and wrists extensors are tested.

To test the biceps, patient is asked to flex the elbow to 90° and maintain the position. The examiner supports the elbow with one hand and holds the wrist with the other hand and attempts to extend the elbow (Figure 4.8).

To test the wrist extensors, the patient is asked to extend the wrist and flex the elbow to 90° while the arm is held tightly at the side. The examiner stabilizes the forearm with one hand and exerts downward pressure with the other hand (Figure 4.9).

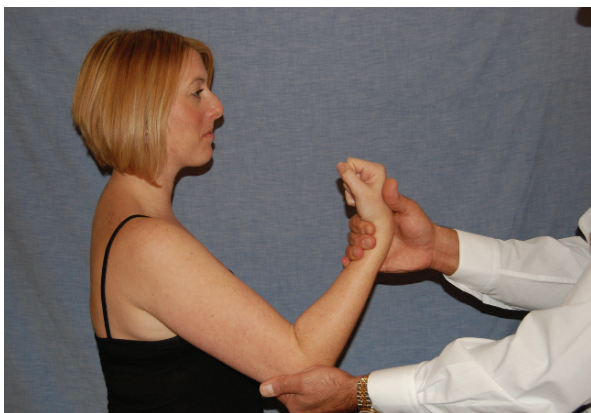

FIGURE 4.8. Assessing the power of biceps.

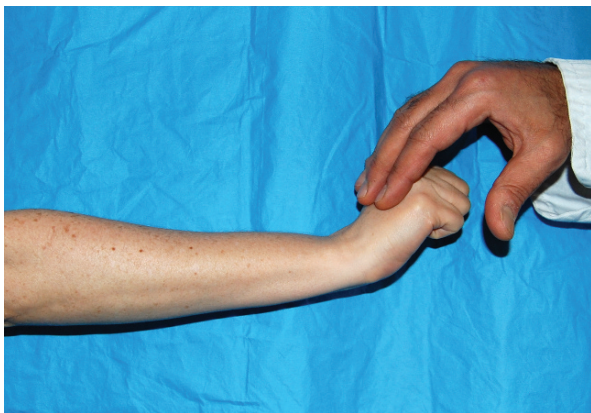

FIGURE 4.9. Assessing dorsiflexors of the wrist.

### **C6 Nerve Root Compression**

C5-6 disc herniation\* or other pathology

Sensory deficit

Lateral forearm, thumb and index finger

Muscle weakness

Biceps

Wrist extensors

Reflex changes

Brachioradialis

\*Most common

### **C7 Nerve Root**

Exits between C6-7 vertebrae.

Wrist flexors, long finger extensors and triceps are tested.

To test the wrist flexors, the patient is asked to flex the wrist and flex the elbow to 90° while the arm is held tightly at the side. The examiner stabilizes the forearm with one hand and exerts pressure to extend the wrist with other hand (Figure 4.10).

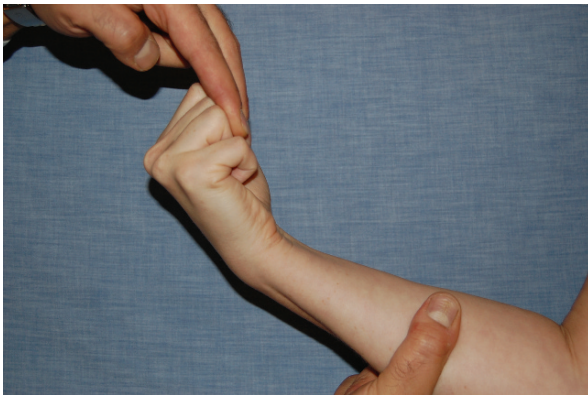


FIGURE 4.10. Assessing flexors of the wrist.

To test the long finger extensors, the patient is asked to extend the fingers and maintain the position with the wrist in neutral. The examiner stabilizes the forearm with one hand and exerts pressure just distal to the metacarpophalangeal joints to flex the fingers (Figure 4.11).



FIGURE 4.11. Assessing long finger extensors.

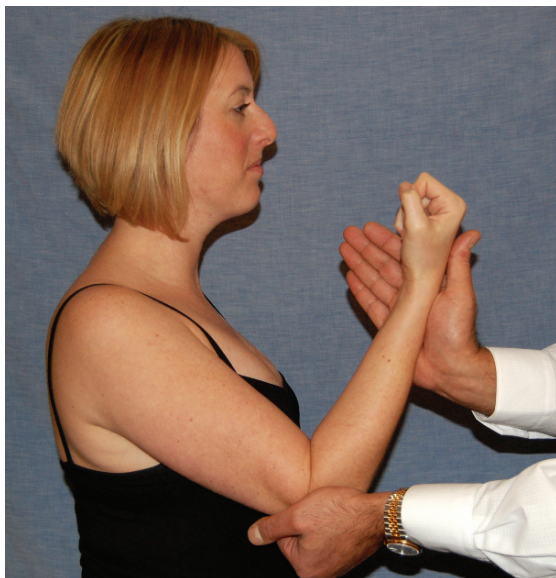

FIGURE 4.12. Assessing the triceps.

To test the triceps, the patient is asked to flex the elbow to  $90^\circ$  and maintain the position. The examiner supports the elbow with one hand and holds the wrist with the other hand and attempts to flex the elbow (Figure 4.12).

### **C7 Nerve Root Compression**

C6-7 disc herniation or other pathology

Sensory deficit

Middle finger

Muscle weakness

Triceps

Wrist flexors

Long finger extensors

Reflex changes

Triceps

### **C8 Nerve Root**

Exits between C7-T1 vertebrae.

Digital flexors are tested.

To test the digital flexors, the examiner places his index, middle and ring finger in the patient's palm and asks the patient to make a fist and squeeze as tightly as possible.

### C8 Nerve Root Compression

C7-T1 disc herniation or other pathology

Sensory deficit

Little and ring finger, ulnar border of palm and medial forearm

Muscle weakness

Finger flexors

Reflex changes

None

### T1 Nerve Root

Exits between T1–T2 vertebrae.

Interosseous muscles as a group, or first dorsal interosseous are tested.

To assess the interosseous muscles, the patient is asked to spread the fingers and hold the position. The examiner then exerts pressure to the index and little fingers to push them back together (Figure 4.13).

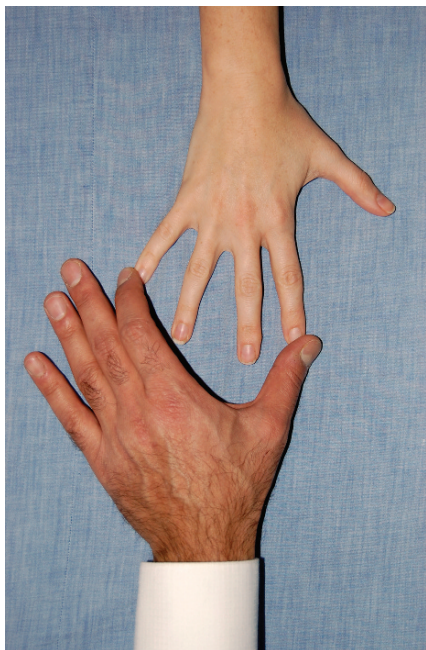


FIGURE 4.13. Assessing the interosseous muscles.



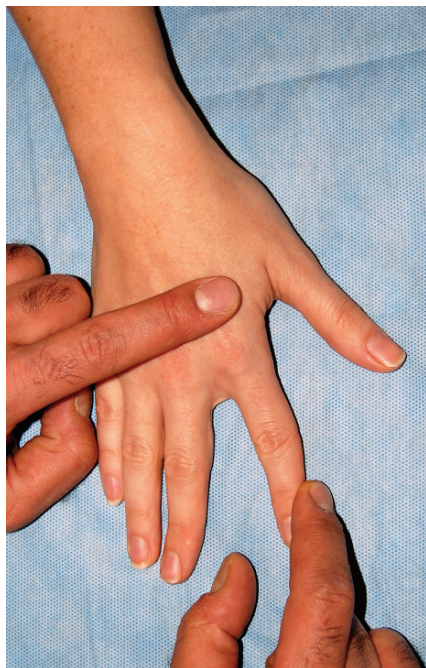

FIGURE 4.14. Assessing the first dorsal interosseous.

Alternatively to test the first dorsal interosseous, the examiner presses his index finger against the radial border of the patient's index while with the other hand he feels for the muscle contraction (Figure 4.14).

### **T1 Nerve Root Compression**

T1–T2 disc herniation or other pathology

Sensory deficit

Medial arm

Muscle weakness

Dorsal interossei

Abductor digiti minimi

Reflex changes

None



## Sensory Testing

The sensory distribution of upper limbs and trunk should be tested. Remember there is wide area of overlap between the dermatomes and varies between individuals.

- C3 dermatome: neck
- C4 dermatome: shoulder tip
- C5 dermatome: middle of deltoid and lateral epicondyle
- C6 dermatome: thumb
- C7 dermatome: middle finger
- C8 dermatome: little finger
- T1 dermatome: medial elbow
- T2 dermatome: medial arm
- T3 dermatome: axilla
- T4 dermatome: nipple
- T5-8 dermatome: chest wall
- T9-12 dermatome: abdominal wall (umbilicus is T10)

## Reflexes

### Biceps Reflex for C5 Nerve Root

The examiner hold patient's elbow while placing his thumb on the patient's biceps tendon. Patient's forearm should rest on examiner's forearm. The examiner then taps his thumb with the hammer (Figure 4.15). Contracture of the biceps is felt and often seen.

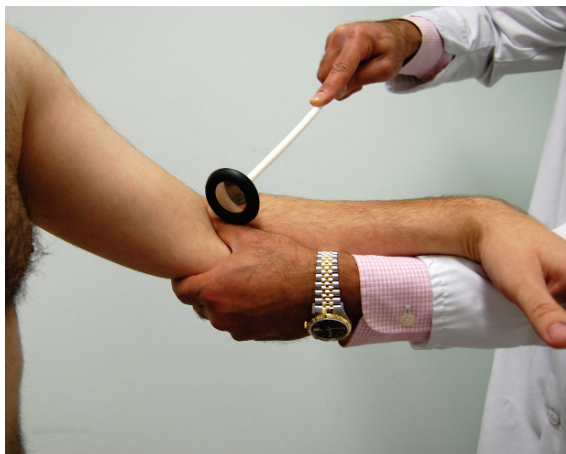

FIGURE 4.15. Eliciting biceps reflex.

**Brachioradialis Reflex for C6 Nerve Root**

The patient's forearm rests on the examiner's forearm in a neutral rotation, hence the radial border of the forearm is facing upward. The examiner then taps about 5 cm above the radial styloid (Figure 4.16). Contracture of the brachioradialis produces quick upward movement of the forearm.

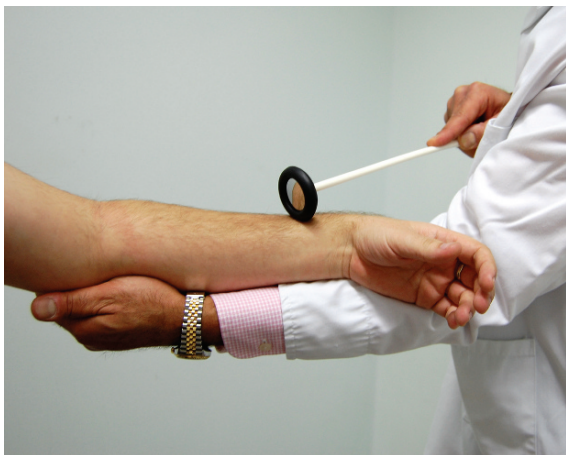

FIGURE 4.16. Eliciting brachioradialis reflex.

**Triceps Reflex for C7 Nerve Root**

The patient is in a position of 90° shoulder abduction and 90° of elbow flexion while examiner supports the arm and patient is asked to relax completely. The examiner then taps the triceps tendon just above the olecranon (Figure 4.17). A visible contraction of the triceps is usually associated with slight extension of the elbow.

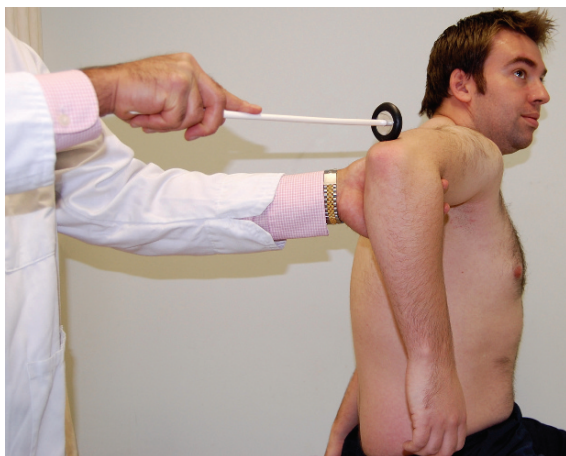


FIGURE 4.17. Eliciting triceps reflex.

## Special Testing

### Superficial Skin Reflexes

- Abdominal reflex – performed to assess reflexes of T7-L1 segments. Light stroke of quadrant of abdomen contracts underlying muscle (Figure 4.18). For T7–T10 stroke above umbilicus and for T10–L1 stroke below umbilicus. Normally umbilicus moves toward quadrant. Absence of this reflex may indicate upper motor neurone lesion or thoracic radiculopathy (unilateral loss).
- Anal reflex (S2-4) – light touch or pin prick of perianal skin contracts external anal sphincter.
- Bulbocavernosus reflex (S3-4) – squeeze glans/clitoris or traction on catheter contracts external anal sphincter. It heralds the end of spinal shock.

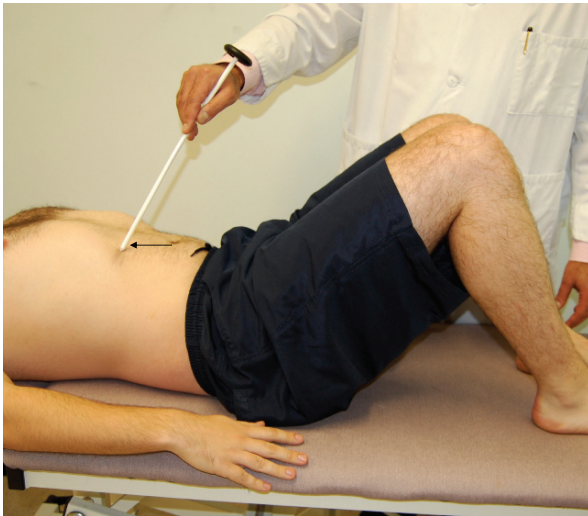


FIGURE 4.18. Eliciting the abdominal reflex. Note the direction of the stroke.

**Spurling's Maneuver (Foraminal Compression Test)**

This maneuver attempts to narrow the intervertebral foramen, which may lead to radicular symptom. Test is done by axial cervical compression with slight extension, side bending and rotation to the side of complaint (Figure 4.19). In a positive test, the patient notes pain radiating in the arm toward which the head is side flexed during compression. Axial pain alone is considered a negative test. This test should not be performed if there is suspicion of bony injury or instability.

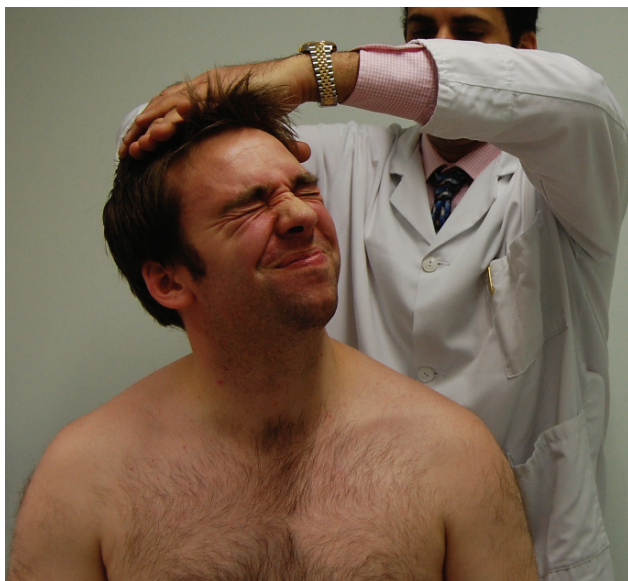

FIGURE 4.19. Spurling's maneuver

**Babinski Test (Plantar Reflex)**

A common test for myelopathy. The examiner strokes the lateral border of sole of the foot firmly and observes the toes (Figure 4.20).

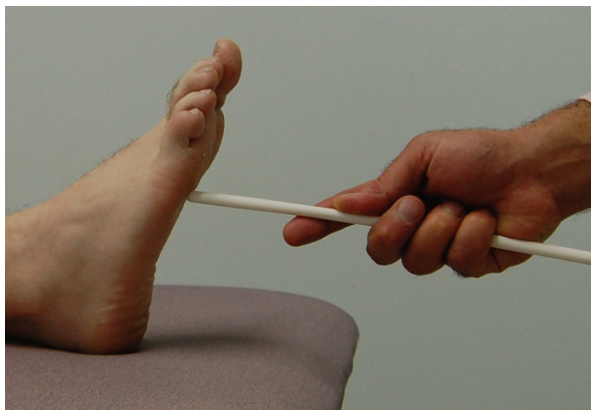

FIGURE 4.20. Eliciting the Babinski (plantar) reflex.

Positive Babinski's reflex → big toe extends and the other toes fan out

Negative Babinski's reflex → all toes flex

In foot amputee patients, the examiner holds the distal subcutaneous part of the patient's tibia firmly between index and thumb and run his hand upward on the tibia. Contracture of tensor fascia lata is considered as a positive test.

**Clonus**

Clonus is a sign of myelopathy. Clonus is a repetitive, rhythmic contraction of a muscle when attempting to hold it in a stretched state. It is a strong, deep tendon reflex that occurs when the CNS fails to inhibit it. With patient seated on the edge of exam table, examiner will grab the forefoot and do an active dorsiflexion in a quick stroke. If positive, foot contracts more than 3 times in a rhythmic plantar flexion which is called clonus. 3 contractures or less is considered normal.

**Hoffmann's Sign**

Specific test for of cervical myelopathy. A flick to the pulp of the index finger to extend the DIPJ is followed by flexion of the thumb and index finger in a positive test.

**L'hermitte's Sign**

Although less specific, it is also used for diagnosis of cervical myelopathy. With the patient in seated position, the neck and hip are flexed simultaneously (Figure 4.21). Positive test is an electric shock sensation down the spine to the lower limb.

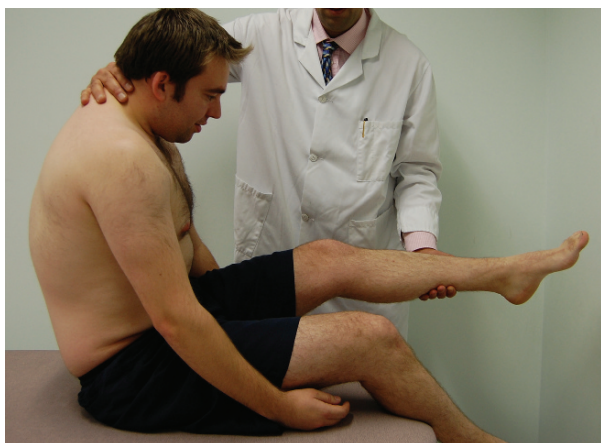

FIGURE 4.21. L'hermitte's sign.



**Roos Test**

A test for thoracic outlet syndrome. It is performed with the patient positioning his shoulders in abduction and external rotation of  $90^\circ$  with elbow flexion at  $90^\circ$ . The patient then opens and closes his hands for one minute (Figures 4.22 and 4.23). Reproduction of symptoms during the test or progressive numbness and heaviness is considered a positive test for thoracic outlet syndrome.

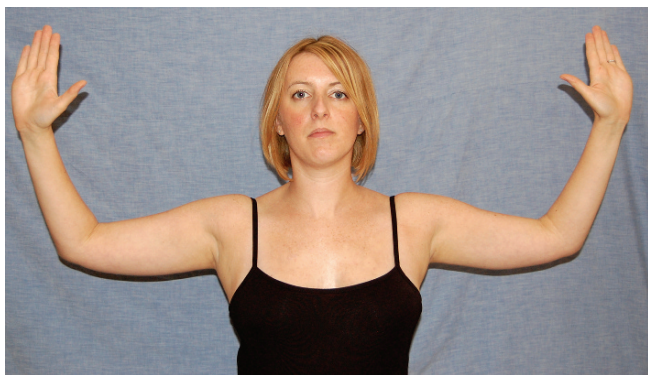

FIGURE 4.22. Roos test.

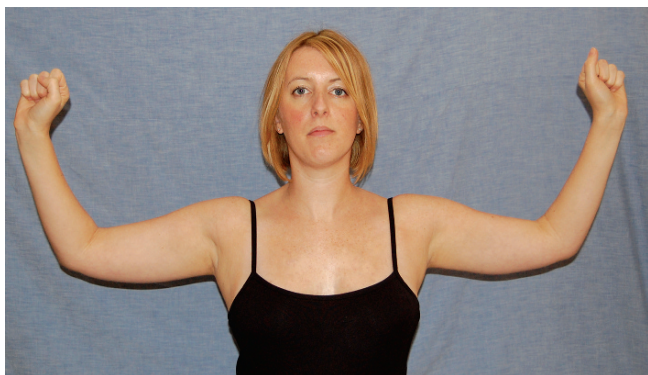

FIGURE 4.23. Roos test. The patient opens and closes the hands for one minute.



This test is performed to differentiate cervical radicular pain and thoracic outlet syndrome. Test is performed with the patient in seated position and hands on thighs. The examiner palpates the radial pulse as the patient is instructed to inhale and hold his breath, hyperextends the neck and turn the head toward the affected side. Examiner may abduct (15°), extend and externally rotate the arm for confirmation of result. If the radial pulse on that side is markedly or completely obliterated, the test is positive and suggests the diagnosis of thoracic outlet syndrome. If a cervical rib is suspected feel the supraclavicular fossa and listen for a bruit.

## LISTEN

Fall from height/road traffic accident → fractures/ligamentous injury

Twisting, bending or lifting injury → back strain  
→ herniated disc  
→ fracture in osteoporotic patient

Children  
Congenital /developmental disorders → spondylolysis  
→ spondylolisthesis  
→ primary tumor

- Herniated disc
- Spondylolisthesis
- Segmental instability
- Acute fractures
- Strains

Stenosis  
Spondyloarthropathy  
Facet syndrome  
Metastatic disease

**Pain****Site of Pain**

Back pain, leg pain, or both. Ask specifically which pain is predominant.

Back pain > leg pain:

Back strain

Segmental instability

Spondyloarthropathy

Infection

Tumor

Leg pain > back pain

Herniated disc

Stenosis

Unilateral → prolapse disc

Bilateral → central disc prolapse

→ metabolic/systemic disease

In spondylolisthesis, a combination of radicular and claudication symptoms are seen.

**Type of Pain**

Aching pain → degenerative changes, stenosis

Sharp radiating pain → herniated disc

Night/rest pain → usually not mechanical in origin. In patients with no history of trauma, other causes, such as bone tumor, should be ruled out.

**Onset of Pain**

Sudden onset → herniated disc

→ infection

→ tumor

Gradual onset → stenosis

→ spondylosis

→ rheumatoid arthritis

→ inflammatory arthropathy

→ spondylolisthesis

**Aggravating Factors:**

Coughing, sneezing ( $\uparrow$  intrathecal pressure)  $\rightarrow$  herniated disc

Activity/brisk walking  $\rightarrow$  stenosis, vascular claudication

### Differentiating Between Neurological and Vascular Claudication

Activity	Neurological claudication	Vascular Claudication
Walking	Thigh, calf pain, heaviness of whole leg	Calf pain
Symptoms	Pain+ paraesthesia	Pain only
Relieving position	Sitting/flexion	Standing still

**Relieving Factors**

Pain relieved by activity  $\rightarrow$  ankylosing spondylitis

Pain relieved by sitting/flexion  $\rightarrow$  spinal stenosis

**Numbness or Paresthesia**

May be associated with radiculopathy. It gives clue to the level of nerve root lesion:

Inguinal  $\rightarrow$  L1

Groin/medial thigh  $\rightarrow$  L2

Anterior thigh  $\rightarrow$  L3

Anteromedial leg  $\rightarrow$  L4

Lateral leg/dorsum foot  $\rightarrow$  L5

Sole /lateral foot  $\rightarrow$  S1

Back of thigh  $\rightarrow$  S2

Buttock  $\rightarrow$  S3

**Weakness of Legs**

Herniated disc

Stenosis

**Difficulty in walking**  $\rightarrow$  herniated disc  
 $\rightarrow$  stenosis  
 $\rightarrow$  myelopathy

**Deformity**

ankylosing spondylitis  
scoliosis  
spondylolisthesis

**Bowel or Bladder Dysfunction** → **cauda equina syndrome, myelopathy**

*Note: Cauda equina syndrome is a large central disc prolapse that may compress several root of the cauda equina. L4-5 disc prolapse is often the offending structure. It is one of the few orthopedic emergencies.*

**Cauda Equina Syndrome**

Mode of onset: acute, insidious  
Pain: perianal, back of the thighs and legs  
Motor deficit: legs and feet  
Motor loss: bladder (retention), bowel incontinence  
Sensory deficit: Perianal (saddle anesthesia)  
Reflex loss: cremasteric

**LOOK****Skin Abnormalities**

Dimple, or hair tuft → spina bifida  
Abnormal pigmentation → neurofibromatosis (up to 4 café-au-lait spots are normal)  
Back/posterior trunk/limbs muscle wasting.

**Scars**

Comments on location  
Surgical or traumatic  
Healed with primary or secondary intention

**Alignment****From Behind**

Shoulder and iliac crest level, if asymmetric → scoliosis  
If patient deviated to one side → list due to herniated disc  
If patient stands with one leg flexed → herniated disc on that side  
→ limb length discrepancy

List: lateral deviation of spine

Scoliosis: triplanar deformity with lateral, anteroposterior and rotational component. Lateral curvature is more easily apparent.

In a well compensated scoliosis the examiner should also look at the spinous processes.

Forward Bending (Adam's Test): This maneuver makes the deformity easier to detect. The examiner asks the patient to bend forward as far as possible (Figure 4.24). This maneuver maximizes the rib prominence (rib hump). The rib hump is reflection of the rotational component of scoliosis and it appears on the convex side of the curve.

The examiner also should observe the alignment of the spine while the patient is seated. In a sitting position, the structural scoliosis could still be seen whereas compensatory or postural scoliosis disappears.

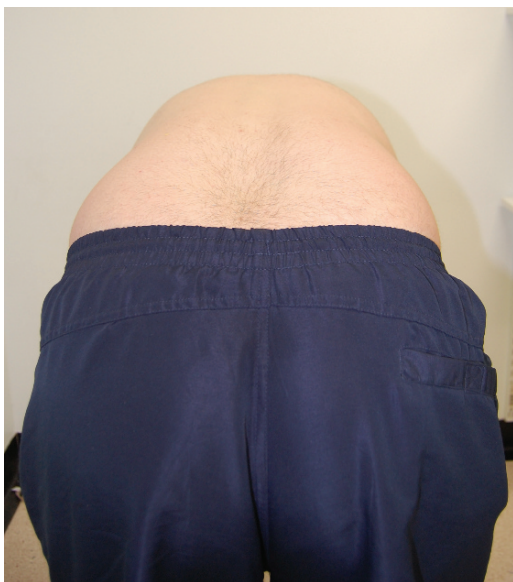

FIGURE 4.24. Forward bending (Adam's test).

**From Side**

Normal: lordosis of cervical spine, kyphosis of thoracic spine and lordosis of lumbar spine. Base of occiput rests directly above the sacrum.

Hyperlordosis → fixed flexion deformity of hips

→ spondylolisthesis

→ primary thoracic kyphosis

Decreased lordosis → disc lesions (muscle spasm)

→ spondylitis

→ ankylosing spondylitis

→ Flat-back syndrome; following a long thoracolumbar fusion for scoliosis (with older instrumentation which corrected only coronal deformity)

Gibbus → collapse of vertebra due to

tuberculosis

tumor

fracture (rare)

**Abnormal Gaits****Stooped Gait → kyphosis deformity or central stenosis**

Most lumbar stenosis patients tend to ambulation with stooped forward gait which increases the spinal canal diameter and relieves symptoms.

**Antalgic Gait → radiculopathy**

Patient puts as little weight as possible on the affected side. A patient with sciatica tend to walk with hip more extended and knee more flex to reduce the tension on the nerve root.

**Foot Drop or Slap Foot Gait → L5-S1 disc lesion**

The feet are either dragged on the ground during swing phase or it hit the ground on each step.

**Ataxic Gait → broad based unsteady**

Myelopathy subsequent to cervical /thoracic stenosis,

Alcohol abuse

Vestibular and cerebellar pathology

It would be very useful if you ask the patient to walk on his heels and then on tip toes. Heel walking tests the power of dorsiflexors of the ankle, especially the tibialis anterior muscle. Inability to perform this test indicates weakness of the tibialis anterior (L4 root), which may be caused by L3-4 disc prolapse. Toe walking tests the power of gastrocnemius complex (Figure 4.25). Inability to toe walk indicates weakness of the gastrocnemius complex (S1 root), which may be caused by L5-S1 disc prolapse.

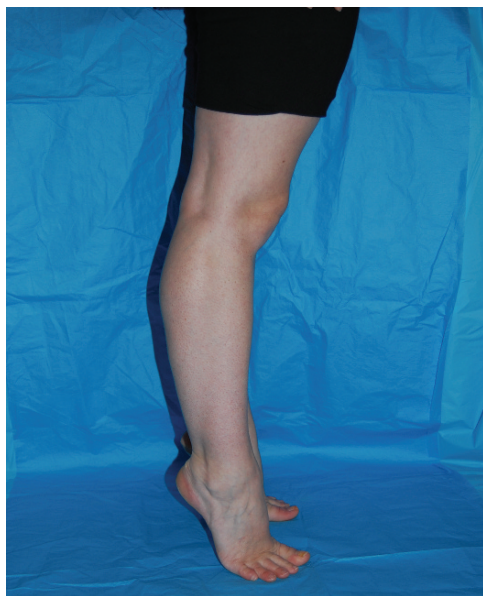

FIGURE 4.25. Assessing the power of the gastrocnemius complex by toe walking.

## FEEL

### Standing Position

#### Spinous Process

- Palpate the tip of spinous processes along the length of the spine. Feel for any tenderness or abnormal step deformity (spondylolisthesis). As a guide, an imaginary line between the two iliac crest passes between L4–L5 spinous processes.
- Localize the position of tender points to bony structure and surrounding muscles.
- Feel for temperature in the skin and for consistency of any lumps (bony, muscle spasm).

### Prone Position

#### Facet Joints

Ask patient to relax the lumbar muscles. Lateral to the spinous processes on either side, facet joints are located deep to the muscle. In patients with spinal deformity, the tip of convexity and point of convexity often demonstrate tender facets.

#### Sacroiliac Joint

It is a complex joint and the posterior joint (syndesmosis) is palpable in prone position.

#### Sacrum and Coccyx

Extending the examination of lumbar spine caudally, sacrum could be palpated easily. The spinous processes are less distinct distally and S2 lines up with the two posterosuperior iliac spine (PSIS) (posterior dimples). The most caudate aspect of the sacrum is the sacral hiatus which is easy to palpate in thin adults or pediatric population. Distal to it, is the sacrococcygeal joint and the coccyx bones (fused).



## MOVE

Best assessed by actively instructing the patient on the movement required. Deficits in flexion/extension/lateral bend needs to be noted.

### **Flexion and Extension**

#### **Flexion**

“Touch your toes.” Note level reached (knees/shin/toes). Normally finger tips reach to within 10cm of the floor. During flexion the normal lumbar lordosis should be obliterated or even go into slight kyphosis. If lumbar flexion is limited, the hip would compensate and flex instead.

Schober's test is used to quantify lumbar flexion. A horizontal line is drawn at the level of the PSIS and a second line 10 cm above this (Figures 4.26 and 4.27). Flexion should increase the distance by at least 5 cm. Most of the lumbar pathologies cause reduction in amount of flexion.

Examiner must observe how patient returns to upright position. Some patients develop sudden pain associated with jerky movement half way to upright position. Patient describes it as "catching." This, if present, indicates segmental instability.

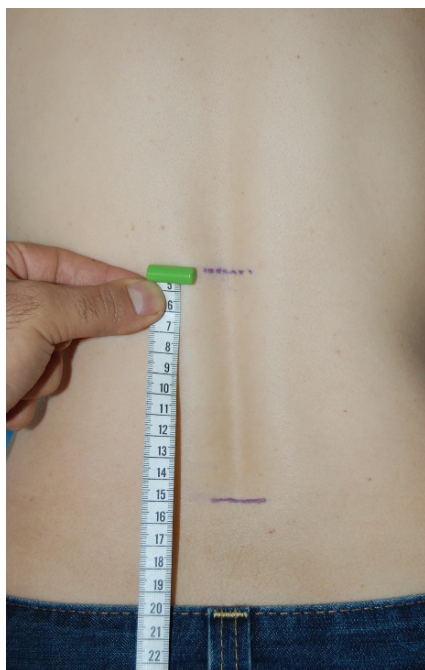


FIGURE 4.26. Schober's test. Initial marking.

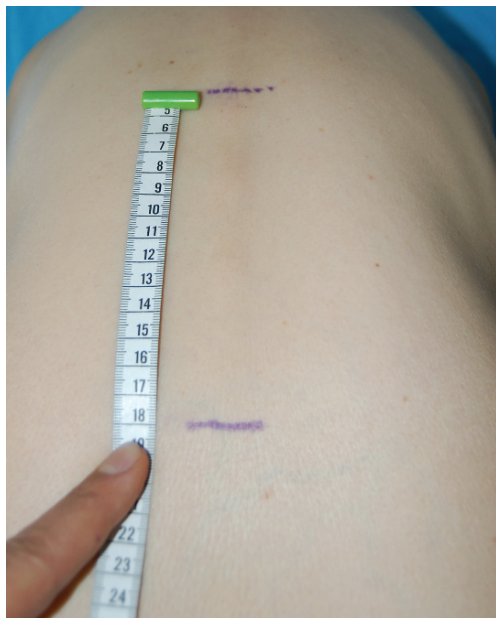


FIGURE 4.27. Schober's test. Patient bends forward and measurement is taken.

### Extension

"Lean backward" (support from behind to prevent fall). Quantify the degree of extension by estimating the angle between trunk and vertical line. Normal 30°. Extension is limited and/or painful in:

- Facet joint arthropathy

- Spondylosis

- Tumor/infection of posterior structure

**Lateral Flexion**

“Slide your hand down the outside of your leg.” Note level reached (Figure 4.28) (mid-thigh/knee). Lateral bending is limited and/or painful in herniated disc (bending toward the lesion)

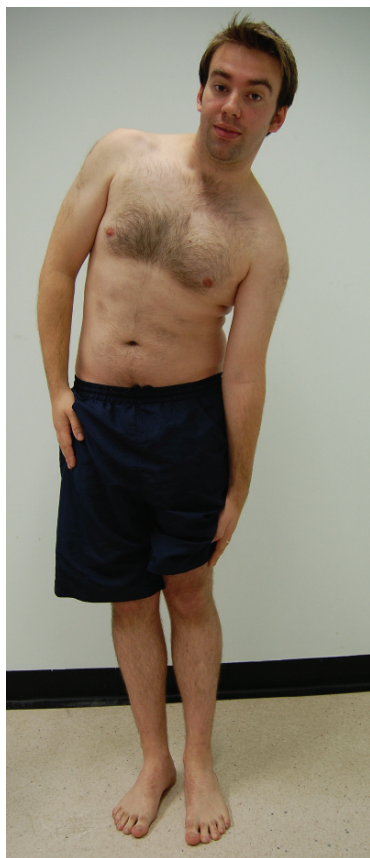

FIGURE 4.28. Lateral flexion.

### Muscle Testing

Examination of the muscles is done to determine the involved nerve root level.

*Note: In lumbar spine the nerve root transverse the respective disc space **above** the named vertebral body. It exits the respective foramen under the pedicle (Figure 4.29). Usually herniated discs impinge on the **traversing** nerve root.*

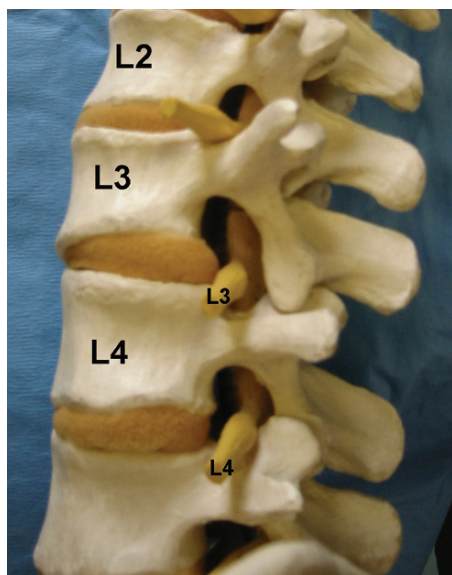


FIGURE 4.29. Exiting nerve roots.

**L2 Nerve Root**

Exits between L2-3 vertebrae.

Indicates herniated disc (rarely) at L1-2 or pathological condition localized to the L2 foramen.

Iliopsoas muscle is tested.

While the patient is seated at the side or end of the examination table with the knees at 90° of flexion. The patient is asked to lift off the knee while examiner exerts pressure over the knee (Figure 4.30).

Alternatively while patient is supine, flex the knee and hip to 90° and ask the patient to flex the hip further while you apply resistance to the knee.

**L2 Nerve Root Compression**

L1-2 herniated disc (rare). Fracture, infection, tumor localize to L2 foramen

Sensory deficit

Anteromedial thigh

Muscle weakness

Iliopsoas

Reflex changes

None

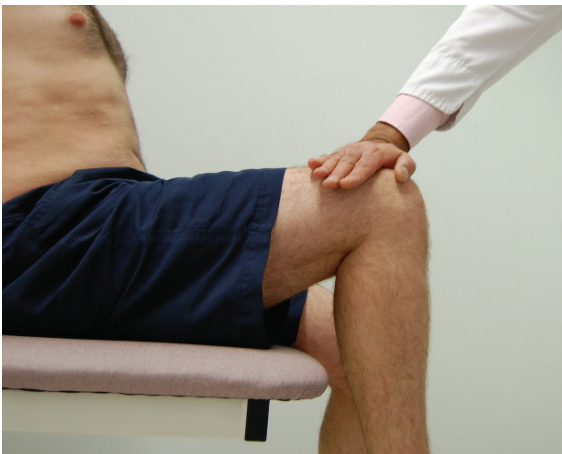

FIGURE 4.30. Assessing the power of iliopsoas.

### L3 Nerve Root

Exits between L3-4 vertebrae.

Indicates L2-3 herniated disc or pathological condition localized to L3 foramen.

Quadriceps muscle is tested. In supine positions, put your forearm under the knee joint and with the other hand apply resistance while patient is instructed to extend the knee.

In sitting position: Stabilize the thigh with one hand and then apply resistance while patient is instructed to extend the knee (Figure 4.31). Feel for the contracture of the muscle with your stabilizing hand.

### L3 Nerve Root Compression

L2-3 herniated disc or other pathology localize to L3 foramen

Sensory deficit

Anterior thigh

Muscle weakness

Quadriceps

Reflex changes

None

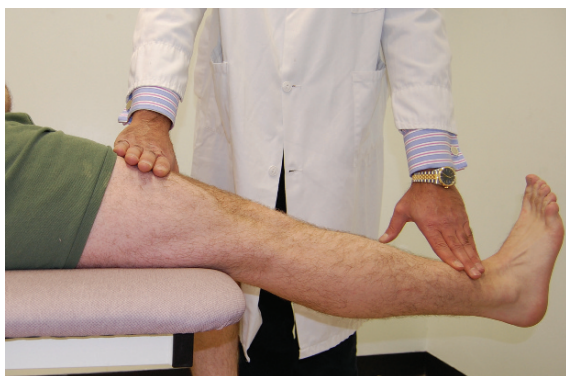

FIGURE 4.31. Assessing the power of quadriceps.

**L4 Nerve Root**

Exits between L4-5 vertebrae.

Indicates L3-4 herniated disc or pathological condition localize to L4 foramen.

The tibialis anterior muscle is tested.

Hold the heel. Put the foot in inversion and dorsiflexion and ask the patient to maintain this position. Then try to evert and plantar flex the foot by pressure over the first metatarsal head and shaft (Figure 4.32). If the muscle is profoundly weak, you must feel for muscle contracture.

Alternatively, in supine position, ask the patient to pull his toes toward his nose and hold the position. The examiner then presses down on the foot trying to plantar flex the ankle. Another method is to ask the patient to heel-walk; inability to perform on symptomatic side as a sign of weakness in L4 myotome.

**L4 Nerve Root Compression**

L3-4 disc herniation or other pathology localize to L4 foramen

Sensory deficit

Anteromedial leg

Muscle weakness

Tibialis anterior

Reflex changes

Patella tendon

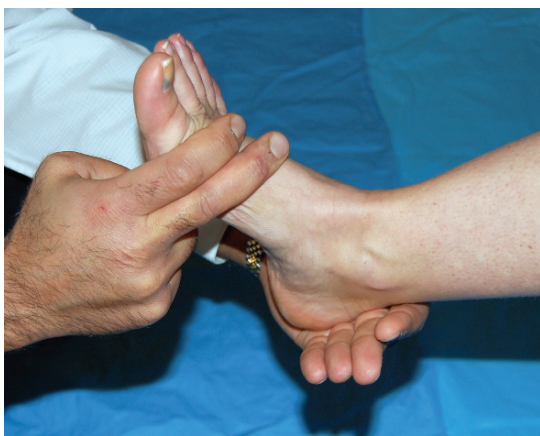

FIGURE 4.32. Assessing the power of tibialis anterior.



### L5 Nerve Root

Exits between L5-S1 vertebrae.

Indicates L4-5 herniated disc or pathological condition localize to L5 foramen.

The extensor hallucis longus muscle is tested.

Hold the heel. Ask the patient to dorsiflex the big toe and maintain this position while the examiner applies opposite force by placing a finger on the nail and tries to plantar flex the big toe (Figure 4.33).

### L5 Nerve Root Compression

L4-5 disc herniation\* or other pathology localize to L5 foramen

Sensory deficit

Lateral leg and dorsum foot/big toe

Muscle weakness

Extensor hallucis longus

Gluteus medius

Reflex changes

Medial hamstring

\*Most common

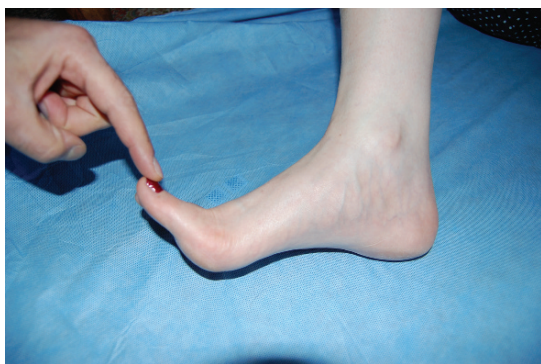

FIGURE 4.33. Assessing the power of extensor hallucis longus.

**S1 Nerve Root**

Exits at S1 foramen.

Indicates L5-S1 herniated disc or pathological condition localize to S1 foramen.

Gastrocsoleus complex is tested.

Hold the heel. Ask the patient to plantar flex the ankle and maintain this position while the examiner applies opposite force to the metatarsal heads and tries to dorsiflex the ankle.

Alternatively ask the patient to toe-walk and look for inability to perform on the symptomatic side as a sign of S1 myotome weakness.

**S1 Nerve Root Compression**

L5-S1 disc herniation or other pathology localise to S1 foramen

Sensory deficit

Posterior calf, lateral side and plantar foot

Muscle weakness

Gastrocsoleus complex

Gluteus maximus

Reflex changes

Achilles tendon

**S2, 3, 4 Nerve Roots**

These nerves may be compressed or injured by fractures or tumors of the sacrum. A spinal cord injury at higher level most commonly affects these nerve roots. These nerves supply the bowel and bladder. Urinary retention is a common finding.

Motor testing for these nerves are done by performing a rectal examination. If normal tone is present, a resistance is felt as the sphincter yields. On instruction the patient should be able to squeeze the examiner's finger with the external anal sphincter.

Perianal area is tested for sensory deficit.

**Sensory Testing**

The sensory distribution of lower limbs and trunk should be tested.

Remember there is wide area of overlap between the dermatomes and varies between individuals.

- L1: inguinal
- L2: anteromedial thigh
- L3: anterior thigh
- L4: anteromedial leg
- L5: lateral leg and dorsum foot/big toe
- S1: posterior calf, lateral malleolus, dorsal foot
- S2: posterior thigh
- S3: buttocks
- S4: perineum
- S5: perianal

### Reflexes

#### Patella Tendon Reflex for L4 Nerve Root

Sit the patient at the edge of the examination table with legs hanging off the edge. The examiner taps the middle of patellar tendon while the other hand rests on the quadriceps muscle to feel the contracture (Figure 4.34).

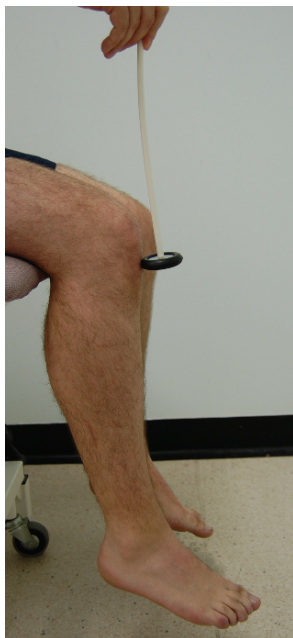

FIGURE 4.34. Eliciting the patella tendon reflex.

**Medial Hamstring Reflex for L5 Nerve Root**

In prone position, patient is instructed to flex the knee to about 60° while examiner holds the knee and places the thumb over the semitendinosus tendon and asks the patient to relax the leg in examiners forearm. The examiner then taps the thumb with neurological hammer (Figure 4.35). The contracture of muscle can be felt by thumb and often slight flexion of knee can be seen.

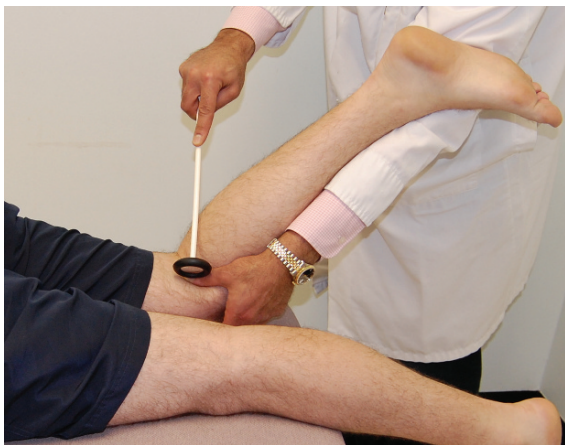

FIGURE 4.35. Eliciting medial hamstring reflex.

**Achilles' Tendon Reflex for S1 Nerve Root**

Dorsiflex the ankle passively and then tap the tendon gently with the neurological hammer (Figure 4.36). Sudden involuntary plantar flexion of the foot is taken as positive.

Alternatively, the examiner dorsiflexes the ankle with his fingers placed on the metatarsal region on the sole of the patient's foot. Then the examiner taps his own fingers (Figure 4.37). This induces the same response with a normal tendon reflex.

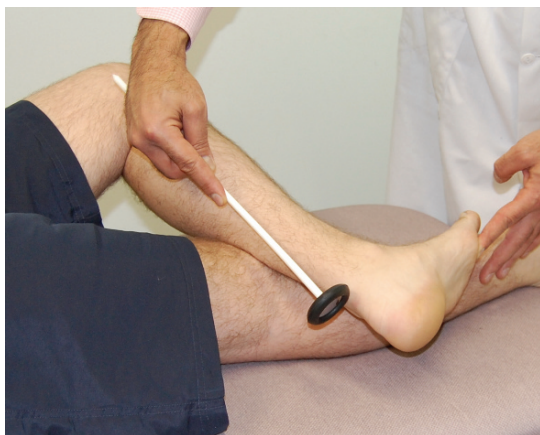

FIGURE 4.36. Eliciting the Achilles' tendon reflex.

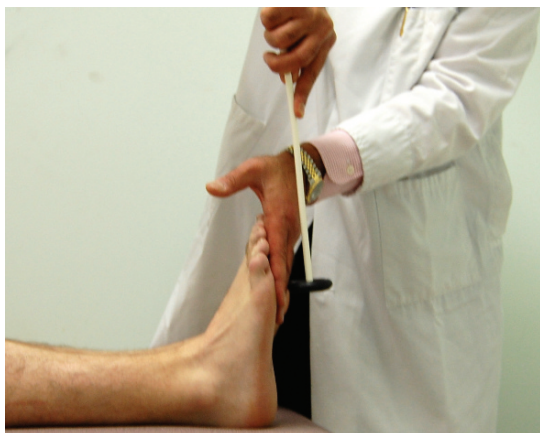

FIGURE 4.37. Alternative method for eliciting the Achilles' tendon reflex.

**Anal Reflex (S2-4)**

Light touch or pin prick of perianal skin contracts the external anal sphincter.

If absent → cauda equina

**Cremasteric Reflex**

This reflex is elicited by lightly stroking the superior and medial part of the thigh in a downward direction. The normal response is a contraction of the cremaster muscle that pulls up the scrotum and testis on the side stroked. Assesses T12.

Absent in:

Cauda equina

Spine injury of T12, L1, L2

*In case of acute spinal injury only*

**Bulbocavernosus Reflex (S3-4)**

The external anal sphincter contracts on squeezing the glans penis / clitoris or traction on catheter. It heralds the end of spinal shock and detectable in 24 or 48 hours after injury.

**Proprioception**

It is tested by repeated change of the joint position in the lower extremity. Ask patient to close his eyes. Hold the proximal phalanx of great toe from sides and move the distal phalanx up or down a few times and stop randomly (Figure 4.38). Ask the patient to identify the direction to which the toe has been moved.

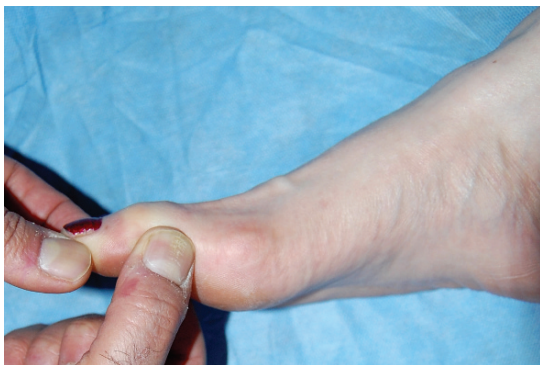

FIGURE 4.38. Proprioception.

## **Coordination**

Assess the gait. Can expose central cause, chronic alcohol abuse, infarct, cord compression. If myelopathy suspected the following tests should be performed.

### **Babinski Test**

The examiner strokes the lateral border of sole of the foot firmly and observes the toes.

Positive Babinski's reflex → big toe extends and the other toes fan out

Negative Babinski's reflex → all toes flex

In foot amputee patients, the examiner holds the distal part of the patient's shin firmly between index and thumb and run his hand upward. subcutaneous part of the patient's tibia firmly between index and thumb and run his hand upward on the tibia. Contracture of tensor fascia lata is taken as a positive test.

### **Clonus**

Clonus is a repetitive, rhythmic contraction of a muscle when attempting to hold it in a stretched state. It is a strong, deep tendon reflex that occurs when the CNS fails to inhibit it. With the patient seated on the edge of the examination table, the examiner holds the foot and does an active dorsiflexion in a quick stroke. If positive, the foot contracts more than three times in a rhythmic plantar flexion which is called clonus. Fewer than three contractions are considered normal.

## Special Tests

### **Straight Leg-Raising Test (SLR)**

A test to identify lumbar nerve root irritation. With both legs relaxed and knees extended, the examiner will lift one leg straight up supporting the heel with the palm of the hand (Figure 4.39). Test is considered positive if pain radiates below the knee joint. The angle between the leg and the examination table is then measured.

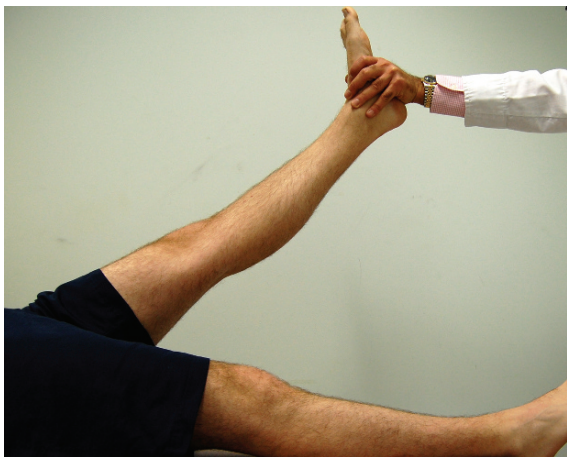

FIGURE 4.39. Straight leg-raising test.



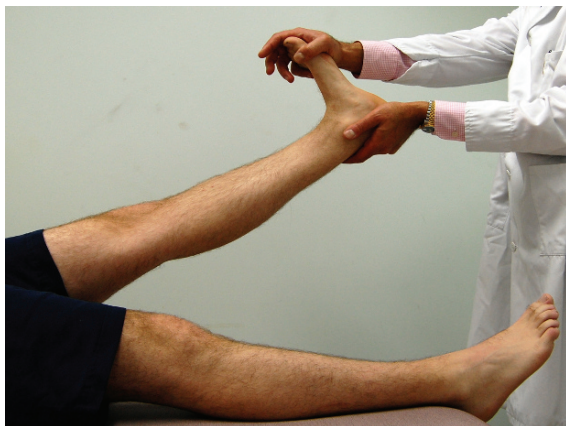

FIGURE 4.40. Lasègue's test.

Once positive, slowly decrease in angle of leg elevation until pain disappears. At this time, dorsiflex the foot (Figure 4.40) and symptoms will redevelop confirming the nerve tension (Lasègue's test).

This test is important if the patient's symptoms exacerbates in 30–70° of leg elevation. Pain generated over 70° of leg elevation in most cases is not a radicular pain.

Alternatively, it can be done in a sitting position. It is performed with the patient sitting upright on the examination table and knees flexed on the edge. Active knee extension in this position often reproduces nerve root tension and pain.

#### **Crossed Straight Leg Raising Test**

The examiner performs the SLR test on the asymptomatic side. The test is positive if patient's pain exacerbated in the symptomatic side. It is highly sensitive and specific test for L4-5 disc prolapse.

**Femoral Stretch Test**

This is to assess the compression on L2, L3 or L4 nerve roots. While the patient prone and knee flexed to 90°, the examiner lifts the patient's thigh to extend the hip (Figure 4.41). Reproduction of radicular pain in anterior thigh is positive.

Alternatively it can be done in lateral position. Patient needs to lie on unaffected side with straight back, slight flexed hips and knees. Examiner will extend the knee on the affected side, and then extend the hip for 15° followed by full flexion of the knee to stretch the femoral nerve. Pain in the anterior thigh is a positive test.

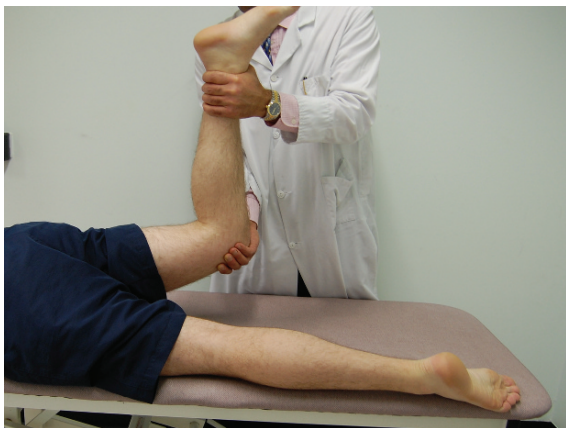

FIGURE 4.41. Femoral stretch test.

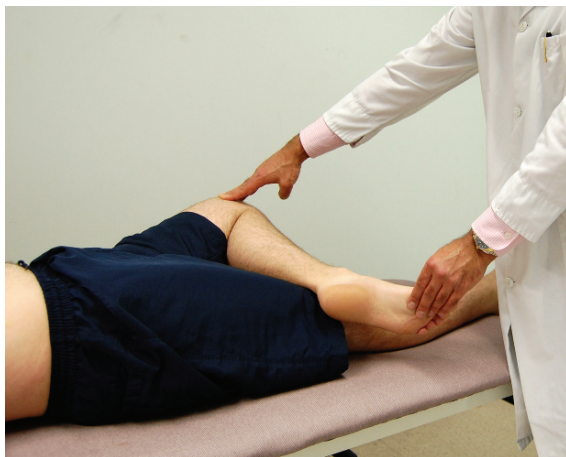

FIGURE 4.42. FABER maneuver (Patrick's Test).

#### **FABER Maneuver (Patrick's Test)**

Performed to differentiate lumbar radiculopathy versus intrinsic hip pathology.

The patient is placed in a supine position and asked to put the hip in a figure four position (**F**lexion + **A**bduction + **E**xternally **R**otation). The examiner stabilizes the opposite ASIS while gently pressing down on the contralateral knee (Figure 4.42). Location of the pain points toward the pathology:

Anterior groin pain → hip arthritis  
→ Iliopsoas pathology

Posterior hip pain → sacroiliac pathology

#### **Abdominal Examination**

Feel for masses (distended neurogenic bladder or abdominal aortic aneurysm which may cause back pain and associated vascular claudication) and PR for sensation, anal tone, and prostate.

**Vascular:** Feel all peripheral pulses to exclude intermittent vascular claudication which can mimic symptoms of spinal disorder.

**Waddell's Signs:** Inappropriate signs and symptoms are important to know while examining a patient. A group of five signs first described by Waddell may indicate nonorganic component to the pain but cannot exclude an underlying organic pain.

**Signs of functional overlay:**

1. Nonanatomical tenderness with light touch
2. Unable to straight leg raise but can sit up on couch with knees extended
3. Pressure on top of head (axial load) or spinal rotation or superficial stimulation of lumbar skin (pinching) increases back pain
4. Widespread (regional) weakness / stocking anesthesia
5. Overreaction

# Chapter 5

## Hip

---

### LISTEN

#### Mechanism of Injury (If Applicable)

Certain mechanisms of injury result in characteristic patterns of structural damage.

##### Common Examples

Direct force to the flexed knee (dashboard injury) → posterior dislocation of the hip  
→ central fracture dislocation

Severe abduction/rotation force → anterior dislocation of the hip

Fall on the greater trochanter → fractured neck of femur

#### Pain

##### Site of Pain

Groin and the front of the thigh → hip pain

Lateral aspect of the thigh → trochanteric bursitis

Pain in the buttock → referred pain from spine

Pain felt generally in the knee → referred pain from the hip

##### Causes of Groin Pain in Adults

Osteoarthritis

Avascular necrosis

Stress fracture

Adductor tendinitis

Traumatic osteitis pubis

What activity brings on the pain?

What are the relieving factors?

### **Type of Pain**

Aching pain → degenerative arthritis

Pain during activity → structural abnormality

Pain after activity → inflammatory arthropathy, tendinosis,

Night pain → usually not mechanical in origin. In patients with no history of trauma, other causes, such as primary or metastatic bone tumor, should be ruled out.

Does the pain cause any restriction to activity?

Quantify (in meters, blocks, miles or kilometers) how far the patient can walk.

Does the pain wake the patient from sleep? At night the protective muscle spasm is removed and hence movements can cause severe pain.

### **Limp**

Most commonly due to:

- Limb length discrepancy
- Abductor weakness
- Instability
- Hip pain

### **Stiffness**

Common and nonspecific in many pathological conditions.

*Prolonged* morning stiffness is seen in:

- Rheumatoid arthritis
- Ankylosing spondylitis
- Other inflammatory arthropathies

### **Clicking (Snapping)**

Patient may report that the hip slips out of the joint. This is seldom, if ever, the case.

Causes:

- Slipping of the iliotibial band over the greater trochanter
- Psoas bursitis
- Detachment of acetabular labrum

## LOOK (PATIENT STANDING)

### Facing Patient

#### Position of Shoulders and Trunk

Position of hip, knee, and ankle

On standing, an imaginary line should pass through the center of the hip, center of the patella, and through the second toe.

#### Common Patterns of Posture

Flexion, abduction, external rotation → synovitis of the hip  
→ effusion of the hip

Flexion, adduction and internal rotation → arthritis

External rotation → Coxa vara

#### Position of the ASIS (Anterior Superior Iliac Spine)

ASIS lower than other side → abduction deformity (leg appears long)

ASIS higher than other side → adduction deformity (leg appears short)

#### Short Limb Stance

If one leg is shorter, equinus of the ankle joint on the affected side and flexion of the knee on the opposite side help to balance the inequality.

Are the lower limbs symmetrical in length and girth?

### From the Side (Looking at the Affected Side)

#### Lumbar Spine

Increased lumbar lordosis → fixed flexion deformity of the hips

#### Buttocks

Atrophy of buttocks → neurological disorders such as poliomyelitis

## Position of the Knees

### From Behind

#### Position of the Shoulders

Asymmetry in level of shoulders → scoliosis  
→ limb length discrepancy  
→ fixed deformities of the hip

#### Is the Spine Straight?

If scoliosis is present, comment on the direction of the convexity of the curve.

#### Buttock Creases

#### Popliteal Creases

#### Muscle Bulk: Thighs/Legs

Atrophy → poliomyelitis

#### Charcot-Marie-Tooth

Hypertrophy → muscular dystrophy

#### Skin Condition

Scars

Comment on:

Location

Surgical or traumatic

Healed by primary or secondary intention

#### Gait

**Antalgic gait** (best viewed from the side): If the hip is the cause of pain, patient tends to reduce the time of weight bearing on the affected hip. Hence the stance phase is short on the painful hip.

**Short limb gait:** The short side dips regularly and evenly.

**Trendelenburg gait:** The shoulder on the affected side dips down, the body lurches toward the affected hip. Patient exhibits a waddling gait if bilaterally present.

**Broad based and unsteady gait** → ataxia

**Drop foot, slap foot, or stepping gait:** Patient attempts to clear toes from catching on the ground. Patient is also, unable to control plantar flexion, resulting in foot “slapping” against the ground.

Causes

Weak or absent dorsiflexion.

Loss of proprioception



**Trendelenburg sign:**

This is the test for postural stability when the patient stands on one leg.

In a normal individual, the pelvis is pulled up by the abductors of the weight bearing leg. The pelvis drops on the unsupported side if the weight bearing hip is unstable (Figure 5.1). The patient has to lurch toward the weight bearing side to shift the center of gravity over the foot and avoid falling. This is called Trendelenburg lurch.

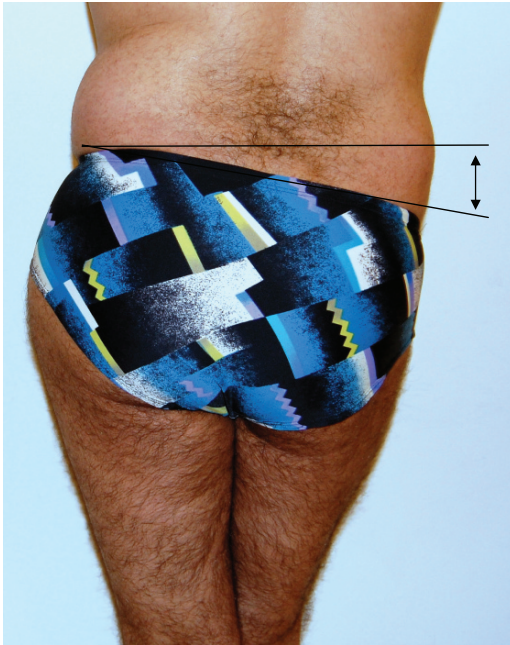

FIGURE 5.1. Weakness of abductors of the left hip.

To perform the test, face the patient. To assess the left hip, place your right hand against the left shoulder (to prevent lurching) and offer your left hand to give support (Figure 5.2). Ask the patient to lift his right leg (opposite leg to the test side) by bending the knee (Figure 5.3).

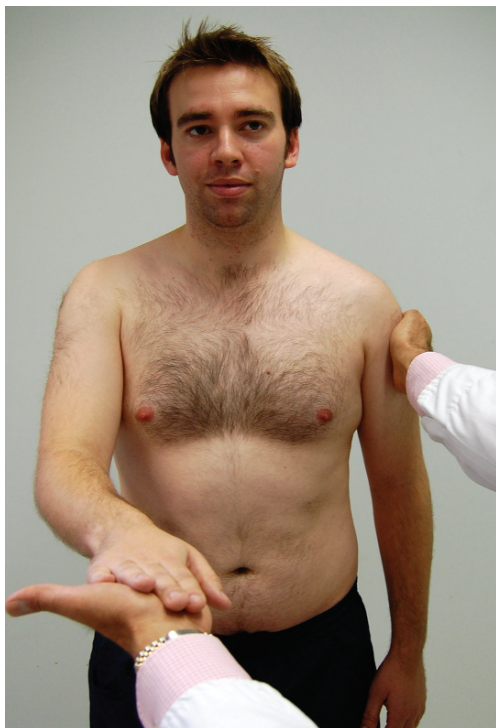

FIGURE 5.2. Position of the examiners hand for Trendelenburg test.

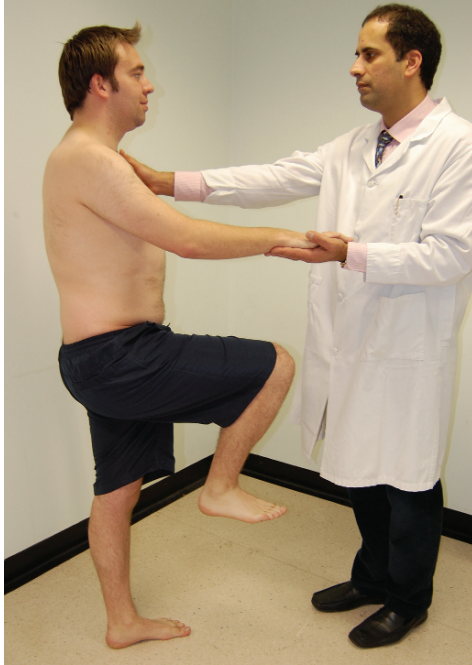

FIGURE 5.3. Trendelenburg test, assessing the left hip.

In a positive test, the examiner feels pressure on his supporting hand as the patient tries to prevent himself from falling over.

Positive Trendelenburg test → weakness of abductors  
→ dislocation / subluxation of the hip  
→ shortening of the femoral neck  
→ any painful disorder of the hip

## **LOOK (PATIENT LYING SUPINE)**

**Skin**

**Scars**

**Swelling**

**Wasting**

**Limb Attitude**

External rotation, lateral border touching the bed (Figure 5.4)

→ extracapsular fractured neck of femur

External rotation, lateral border NOT touching the bed (Figure 5.5)

→ intracapsular fractured neck of femur

→ malaligned hip replacement

Flexion, adduction, internal rotation → posterior dislocation of the hip

Flexion abduction, external rotation → anterior dislocation of the hip

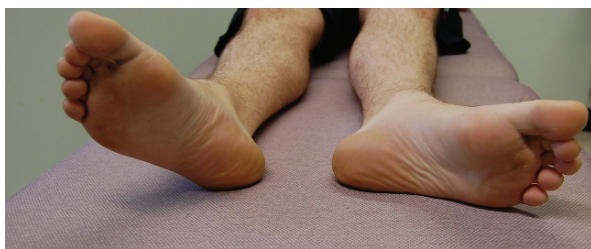

FIGURE 5.4. Extracapsular fractured neck of left femur.

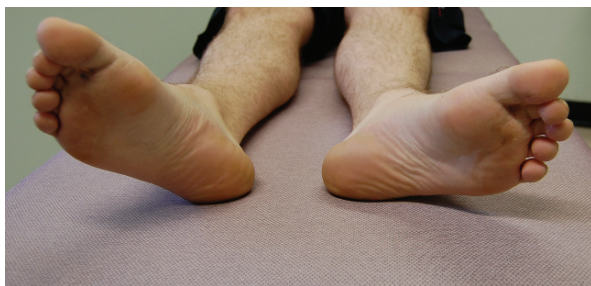


FIGURE 5.5. Intracapsular fractured neck of left femur.

### Limb Length

Look at the level of heels/ankles to detect any limb length discrepancy (Figure 5.6) and comment on the attitude of the lower limb.

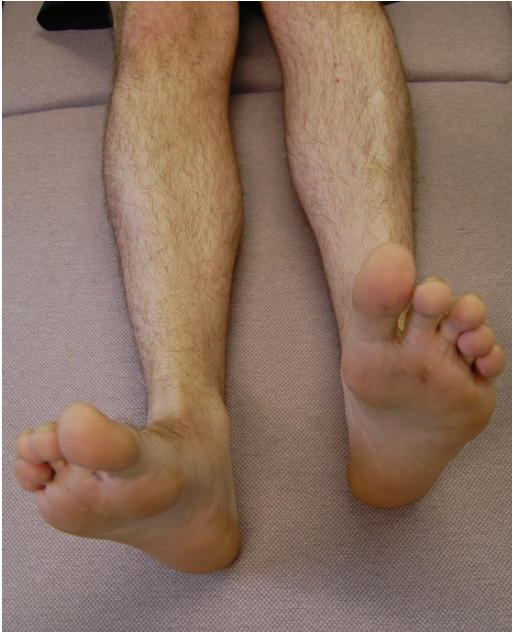

FIGURE 5.6. Limb length discrepancy.

**Galeazzi Test**

This is the test which differentiates between tibial and femoral length discrepancy.

Patient in supine position with knees flexed to  $90^\circ$  and heels together (Figure 5.7). Look from the side at the level of the knee joint. If there is discrepancy in the femur, one femur is shorter than the other (Figures 5.8 and 5.9). Likewise, the shorter tibia is readily seen (Figure 5.10).

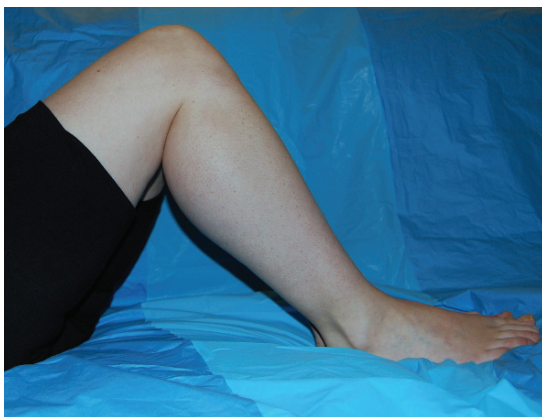


FIGURE 5.7. Galeazzi test.

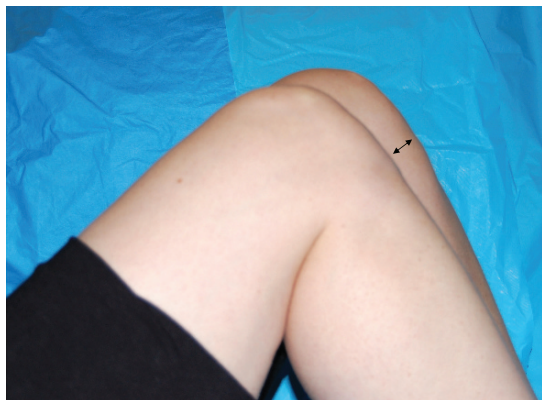

FIGURE 5.8. Femoral shortening.

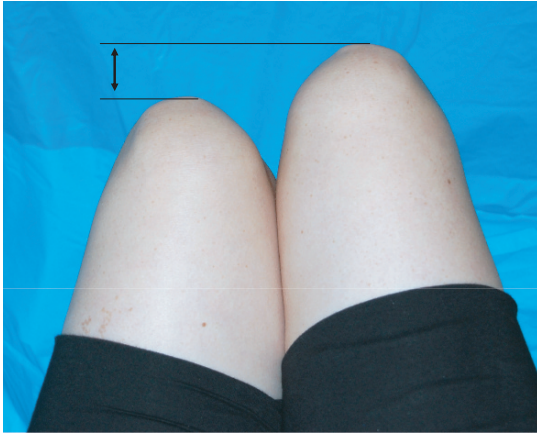


FIGURE 5.9. Femoral shortening can be also seen from the top end of the examination table.

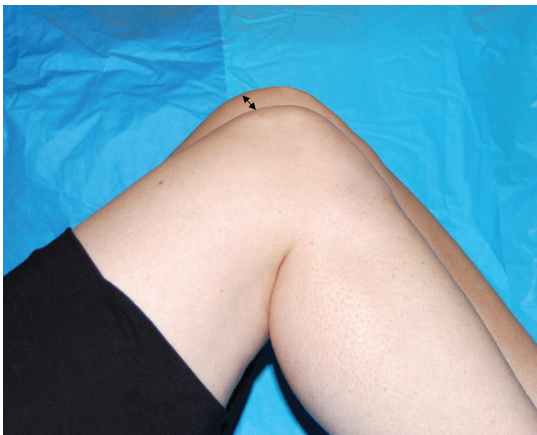

FIGURE 5.10. Tibial shortening.



## FEEL

### ASIS

The length of the iliac crest can be palpated entirely. The anterior end of the iliac crest is the anterior superior iliac spine. Alternatively the examiner can run his finger laterally on the inguinal ligament. The first bony protrusion is the ASIS.

If painful → Avulsion of sartorius

### Pubis Symphysis

Patient in supine position, the examiner palpates the lower anterior abdominal wall to feel the pubis symphysis on the midline and pubic tubercle just medial to the symphysis.

### Inguinal Ligament

This runs between the ASIS and the pubic tubercle. Pulsation of the femoral artery is felt at the midpoint of the inguinal ligament. The artery lies over the head of the femur and hence in a dislocated hip it is difficult to feel the pulse.

### Greater Trochanter

To find the greater trochanter, the examiner palpates the lateral surface of the thigh from distal to proximal. The examiner can feel the bony resistance under the finger as he palpates upward. The end of the bony resistance is the tip of the greater trochanter. To facilitate palpation, the examiner can rotate the hip, which makes the greater trochanter move under the finger.

In anterior dislocation of the hip, the tip of the greater trochanter moves posteriorly, due to external rotation of the femur, and hence is felt further away from the ASIS. In posterior dislocation of the hip, the tip of the greater trochanter moves closer to the ASIS due to internal rotation of the femur.

If painful → trochanteric bursitis  
→ piriformis syndrome



### Bryant's Triangle

The Bryant's triangle is formed by the ASIS, the greater trochanter and the vertical line dropped from the ASIS to the examination table (Figure 5.11). With the patient in supine position, feel the ASIS with your thumb and the tip of the greater trochanter with your middle finger. The distance between the tip of the greater trochanter and the imaginary line is measured for comparison. Any proximal movement of the greater trochanter causes shortening of the line.

Causes of relative shortening

Fracture of the neck of the femur

Dislocations of the hip

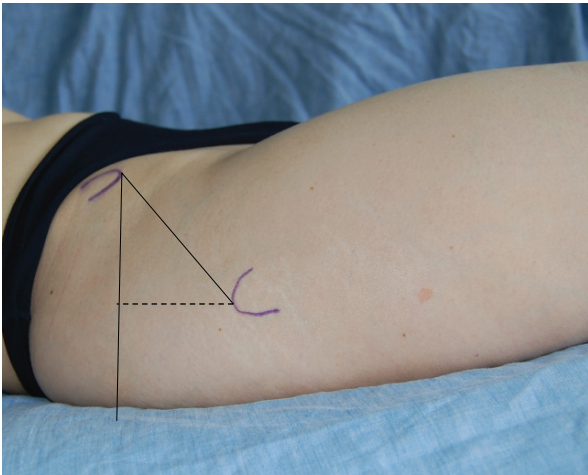


FIGURE 5.11. Bryant's triangle.

## Length Measurement

### Apparent Length Measurement

Patient in supine position and lying in repose. Measurement is done from the xiphisternum to the medial malleolus on each side (Figure 5.12).

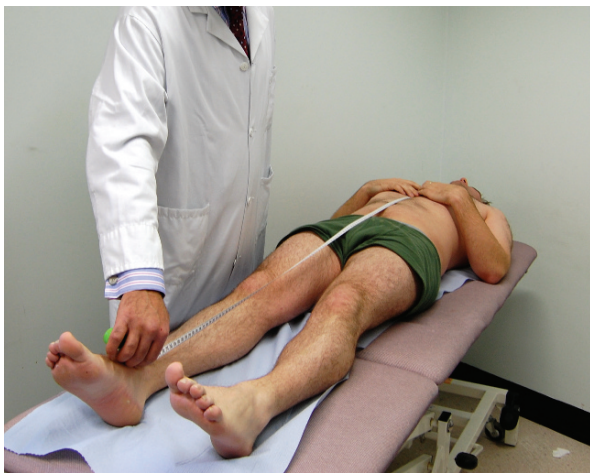

FIGURE 5.12. Apparent length measurement.

### True Length Measurement

To obtain true measurement, the pelvis should be squared, such that both ASIS are horizontal and at the same level.

In fixed adduction deformity, the ASIS of the affected side is higher than the normal hip. To square the pelvis in this situation, the examiner should move the leg of the affected hip in the direction of adduction (cross the leg).

Likewise, in fixed abduction deformity, the ASIS of the affected side is lower than the normal hip. To square the pelvis in this situation the examiner should move the leg of the affected hip in the direction of abduction.

Since the deformities are fixed, when testing for abduction and adduction of the leg no movement occurs at the hip joint and leg movement translates itself to pelvic tilt, which moves the ASIS up or down.

Once the pelvis is squared, measurement is undertaken from the ASIS to the medial malleolus on each side. The limbs should be in an identical position in relation to the pelvis.

If there is a true shortening/lengthening, the examiner must determine whether it is due to discrepancy in the tibia or the femur or both. The limb discrepancy in the femur can be either below, or above, the trochanter.

### Range of Movement

#### Flexion

In a supine position, the patient is asked to flex the hip in a straight line with the knee flexed to relax the hamstring (Figure 5.13). The examiner can assist the patient and observe the line of flexion.

Normal flexion:  $135^{\circ}$

If the hip rolls into external rotation with flexion → slipped proximal femoral epiphysis  
→ Retroverted femoral neck

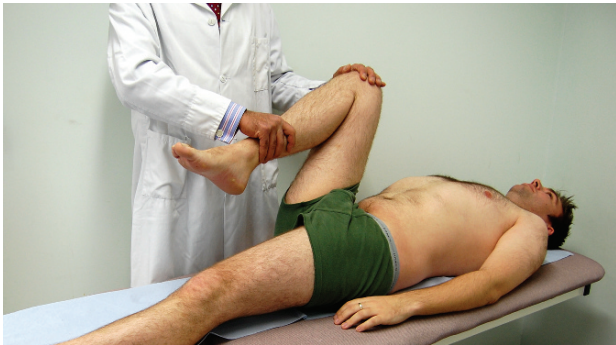

FIGURE 5.13. Flexion of the right hip.

**Abduction**

With the patient in a supine position and the pelvis squared, spread the fingers of one hand over both of the ASIS, ensuring the pelvis is horizontal, and to check for any movement. Then abduct the leg and measure the range of abduction (Figure 5.14). Examiners with delicate hands can place one hand over the opposite ASIS to detect any movement.

An alternative method of testing is to put one leg over the edge of the bed to ensure the pelvis is stabilized and then to measure the range of abduction in the opposite hip (Figure 5.15).

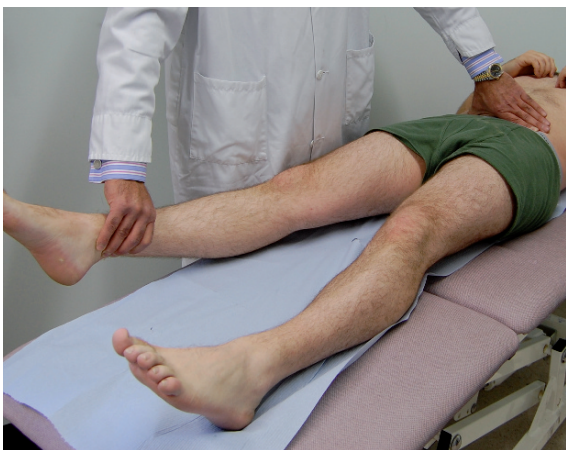

FIGURE 5.14. Abduction of the right hip.

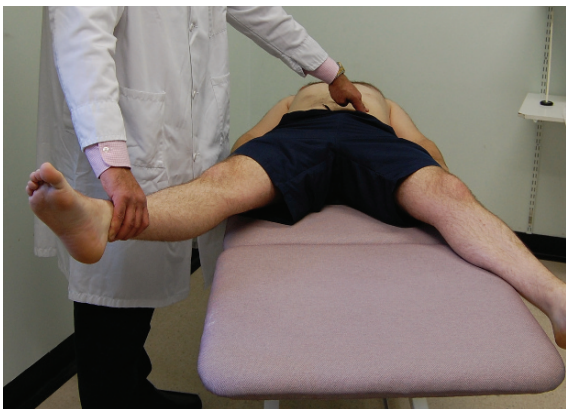

FIGURE 5.15. Abduction of the right hip.

An experienced examiner can stand at the foot end of the examination table and hold both legs at the same time and check for the range of movement simultaneously. Any rocking of the pelvis is felt in the opposite leg. This is often a subtle movement to detect.

Normal range: 0–45°

### Adduction

With the patient in a supine position and the pelvis squared, place the leg of the opposite side you want to examine over the edge of the bed to stabilize the pelvis and make room for manoeuvre of the leg you want to assess for adduction. Feel both ASIS with one hand and then bring the leg into adduction and note the measurement.

Normal range: 0–30°

### Rotation

With the patient supine, the examiner grasps both the ankles and rotates the legs inward and outward to measure the internal and external rotation of the hip by looking at the patella (an imaginary line from the center of the patella) (Figure 5.16).

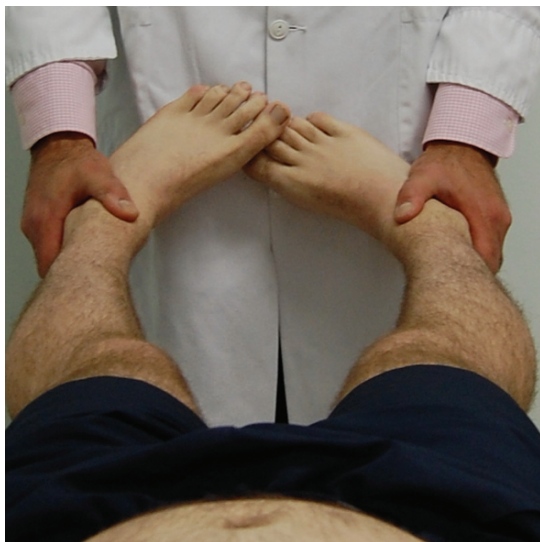

FIGURE 5.16. Internal rotation of the hips.

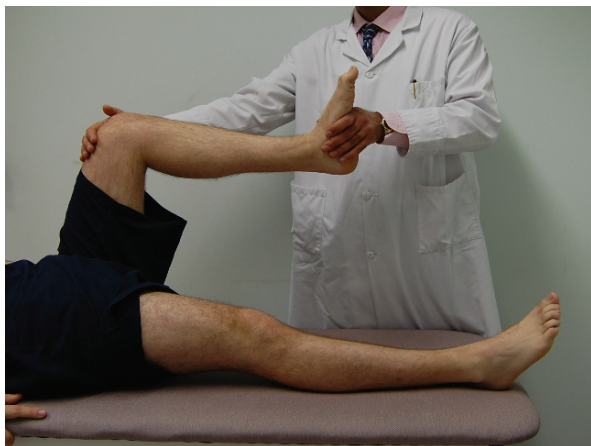

FIGURE 5.17. Measuring the rotation of the left hip in flexion.

Repeat the test for rotation with the knee and hip held in 90° of flexion. The tibia is used as a goniometer (Figure 5.17).

Normal range

IR: 0–30°

ER: 0–50°

↑IR + ↓ER → excessive anteversion of the femur

Painful IR in flexion → degenerative changes in the hip

### **Sectoral Sign**

If internal rotation is restricted with the hip in flexion but is full in extension, pathology in the anterosuperior part of the femoral head is suspected.

**Extension:** With the patient in a prone position, the examiner stabilizes the pelvis with one hand, while the leg is brought into extension. The test can also be done in a lateral position (tested side up).

Normal range 0–30°

**MOVE****Muscle Testing****Iliopsoas (Femoral Nerve L2, L3, L4)**

Primary hip flexor, assisted by rectus femoris and sartorius. The patient sits on the edge of the examination table and is asked to raise the thigh, with the knee flexed, while the examiner applies resistance to the distal thigh to assess the power (Figure 5.18). If the patient is able to lift his thigh off the table, the power is at least 3.

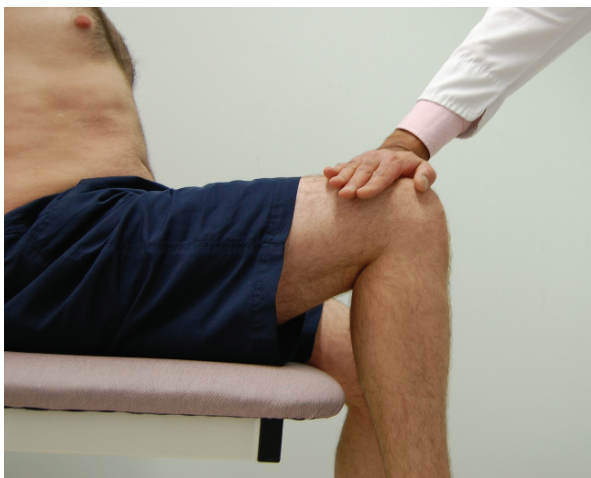

FIGURE 5.18. Assessing the power of iliopsoas.



**Gluteus maximus (Inferior Gluteal Nerve S1, 2)**

Primary hip extensor, assisted by hamstrings. Patient in prone position, asked to bend the knee and lift off the thigh from the examination table while the examiner applies downward force to the distal thigh to push the thigh to the table.

**Gluteus Medius (Superior Gluteal Nerve L5, S1)**

Primary abductor of the hip, assisted by gluteus minimus and tensor fascia lata.

Patient in lateral position, (lying on the unaffected side). The examiner instructs the patient to abduct the leg and maintain the position while downward pressure is applied to the distal thigh (Figure 5.19).

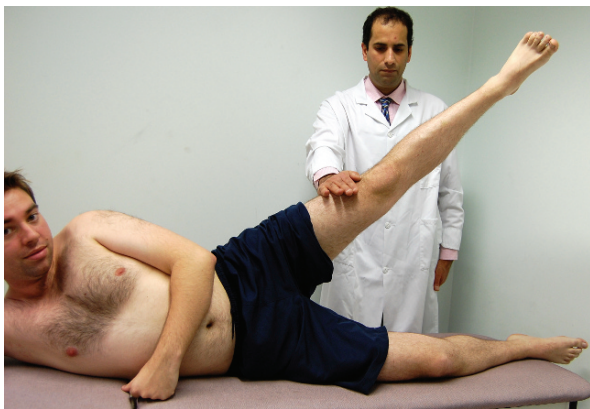

FIGURE 5.19. Assessing the power gluteus medius.



### Adductors

Adductor longus, brevis and magnus, and gracilis (obturator nerve L2, 3, 4)

(Tested as a group.) Patient in supine position. The examiner abducts the leg with the knee in extension and maintains the position. The patient is asked to bring the leg toward the midline (Figure 5.20).

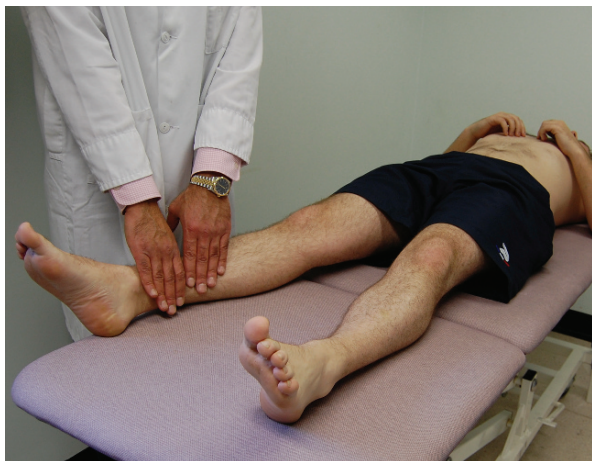

FIGURE 5.20. Assessing the power of adductors.

### Sensation

The only nerve specific to the hip joint to be tested is the lateral femoral cutaneous nerve. It enters the thigh 1–2 cm medial to the ASIS. It supplies the skin over the proximal to middle portion of the anterolateral thigh.

Compression of the nerve near the ASIS is called *meralgia paresthetica*. The nerve cannot be palpated but a positive Tinel's sign may confirm the diagnosis.

The complete neurological examination of the lower limb is covered in spine chapter.

## Pulses

### Popliteal Artery

Deep structure in the middle of the popliteal fossa. With flexion of the knee and deep palpation, the pulse can be felt.

### Dorsalis Pedis

To palpate, ask the patient to extend the big toe and observe the extensor hallucis longus tendon. It can be felt just lateral to the EHL and proximal to the prominence of the metatarsocuneiform joint.

## Special Tests

### Thomas' Test

This is the test to determine the flexion deformity of the hips. In the presence of flexion deformity at the hip joint, exaggerated lumbar lordosis brings the hip level to the ground and maintains an upright position.

To perform the test, with the patient in a supine position, the examiner places his hand under the lumbar spine. Then the patient is asked to flex both hips as far as possible (Figure 5.21). The lumbar lordosis is now eliminated, and the examiner feels the

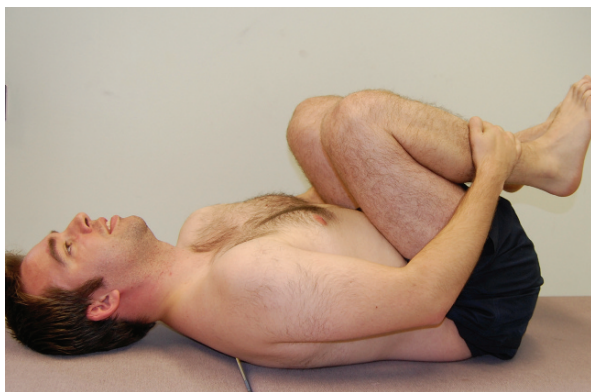

FIGURE 5.21. Thomas' test. Note obliteration of the lumbar lordosis (the examiner's hand is not shown in this picture).

lumbar spine pressing on his hand, which is under the lumbar spine. The patient is asked to hold one knee fully flexed with both hands to maintain the flexion at the hip joint. The other leg is now brought down to the table. If a flexion deformity is present, the leg cannot reach the table and the angle between the posterior aspect of the thigh and the examination table is read as the angle of flexion deformity (Figure 5.22). The test is then repeated for the other hip.

Flexion deformity of each hip is assessed separately by the above method. Each hip may be in a different degree of deformity.

If the patient is unable to flex both hips at the same time, the examiner flexes one hip and asks the patient to hold the knee with both hands to maintain the flexion of the hip joint. The other hip is brought to about 60° degrees of flexion and then lowered down toward the examination table for measurement of the flexion deformity.

If there is fixed flexion of the knee joint, the examiner should bring the patient down the examination table so the knees are off the table and then the test can be performed in the usual manner.

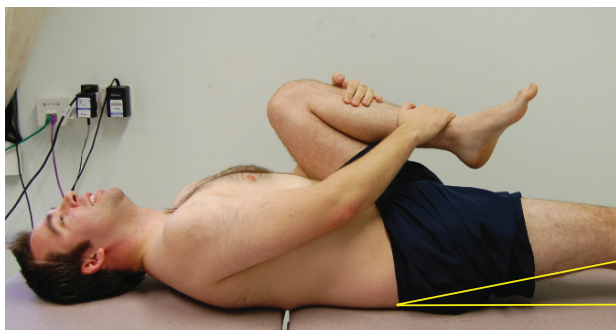

FIGURE 5.22. Thomas' test. The angle of flexion deformity is shown.

**FABER Maneuver (Patrick's Test)**

Performed to differentiate lumbar radiculopathy versus intrinsic hip pathology. The patient, in a supine position, is asked to put the hip in a figure four position (**F**lexion + **AB**duction + **E**xternal **R**otation). The examiner stabilizes the opposite ASIS, while gently pressing down on the contralateral knee (Figure 5.23). Location of the pain points toward the pathology:

Anterior groin pain → hip arthritis  
→ iliopsoas pathology

Posterior hip pain → sacroiliac pathology

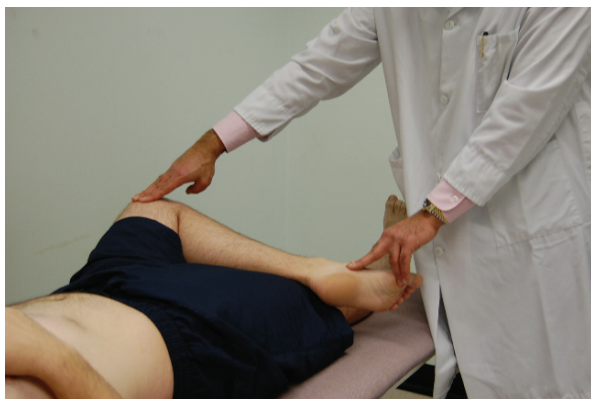

FIGURE 5.23. FABER maneuver (Patrick's test).

**Ely's Test**

This test is to assess the rectus femoris for tightness. With the patient in a prone position, the examiner flexes each knee in turn (Figure 5.24). If rectus femoris tightness is present, the hip on the same side flexes, which is seen as lifting of the buttock.

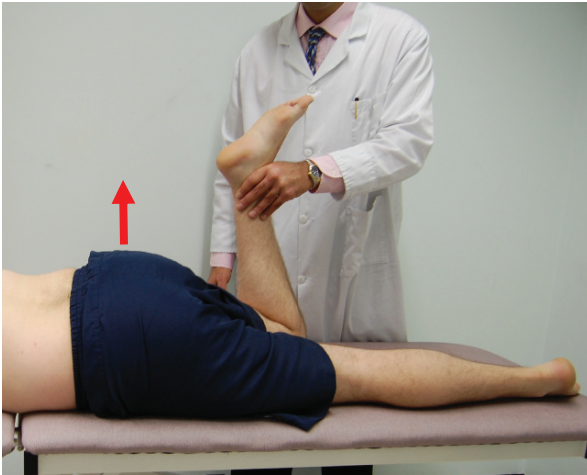

FIGURE 5.24. Ely's test.

**Ober's Test**

This test is to assess the tensor fascia lata (iliotibial band) for contracture. The patient is in the lateral position, with the affected side up and flexion of the hip and knee on the other side to increase stability. The examiner then abducts and extends the upper leg and slowly lowers the limb (Figure 5.25). In the presence of a contracture, the leg does not fall to the examination table and remains abducted.

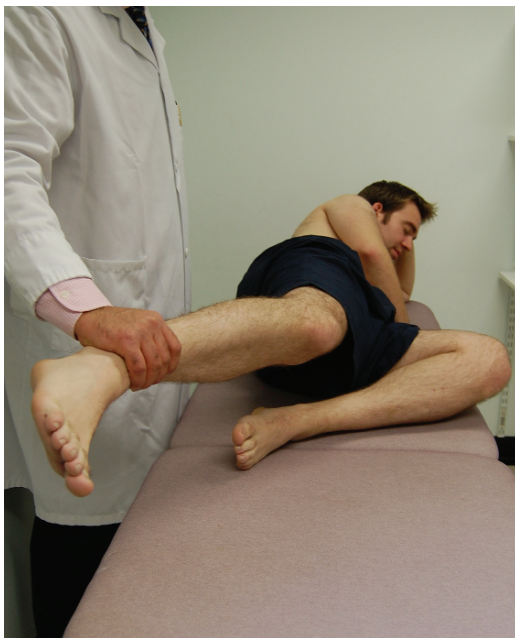

FIGURE 5.25. Ober's test.

### Labral Test

With the patient in a supine position, the hip is flexed beyond  $90^\circ$  and then adducted and internally rotated.

If painful, an anterior tear of the acetabular labrum is suspected.

### Piriformis Test

With the patient in a lateral position, with the affected side facing up, the examiner flexes the knee to  $90^\circ$  and the hip to  $45^\circ$ . He then pushes the knee toward the examination table (internal rotation) while stabilizing the pelvis with the other hand (Figure 5.26).

If painful  $\rightarrow$  piriformis tendinitis

Development of radiating pain  $\rightarrow$  piriformis syndrome

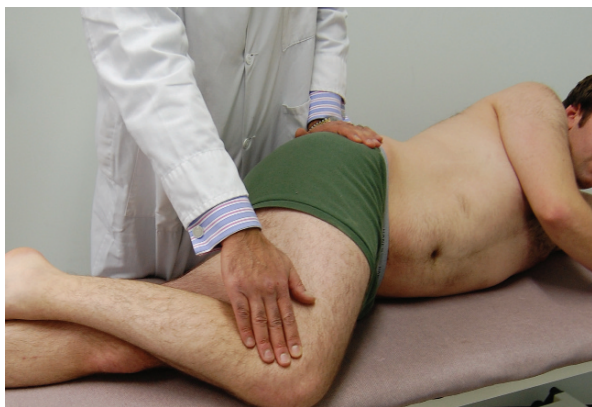

FIGURE 5.26. Piriformis test.

### Stinchfield's Test

This test is for assessment of hip joint pathology. The patient in supine position is asked to straight leg rise with the knee in extension.

Inability to perform the test (with preceding trauma)  $\rightarrow$  fractured neck of femur

Pain during the test  $\rightarrow$  hip joint pathology

# Chapter 6

## Knee

---

### LISTEN

#### **Mechanism of Injury (If Applicable)**

Patients usually remember the position of their limbs/feet at the time of injury. Certain mechanisms of injury result in characteristic patterns of structural damage.

#### **Common Examples**

Valgus force → medial collateral ligament rupture. If the force continues, medial meniscus injury and, with further force, anterior cruciate ligament (ACL) rupture

Varus force → lateral collateral ligament

Hyperextension force → ACL

Fall on to flexed knee/ dashboard injury → posterior cruciate ligament (PCL)

Forceful internal rotation → lateral meniscus injury

Forceful external rotation → medial meniscus injury

Hyperflexion (squatting) → meniscus injury (posterior horn)

Could the patient walk immediately after the injury?

The patient is unlikely to be able to walk in the following conditions:

- Most fractures

- ACL tear

- Peripheral detachment of meniscus



## Pain

### Site of Pain

Localized pain (to which the patient can point with a finger)→meniscus injury

Generalized pain→degenerative changes  
→patellofemoral joint degeneration

What activity brings on the pain?

Relieving factors

### Type of Pain

Aching pain→degenerative changes

Sharp pain/catching pain→meniscus injury  
→loose body

*Note: Sharp pain and aching pain can exist together. This is usually indicative of a degenerative meniscal tear in combination of degenerative arthritis.*

Pain during activity→structural abnormality (meniscal, ACL)  
→patellar maltracking

Pain exacerbated by twisting→meniscal pathology

Pain worse going up slopes→tibiofemoral pathology

Pain worse going down slopes→patellofemoral pathology

Pain after activity→inflammatory arthropathy  
→tendinosis  
→meniscal pathology

Morning pain→inflammatory arthropathy

Rest/night pain→usually not mechanical in origin, however sometimes seen in advanced osteoarthritis. In patients with no history of trauma, other causes, such as bone tumor, should be considered.

Does the pain cause any restriction to activity? Quantify (in meters, blocks, miles, or kilometers) how far the patient can walk. Does the pain wake the patient from sleep? At night the protective muscle spasm is removed and hence movements can cause severe pain.

## Swelling

### Generalized

If it developed immediately (within minutes) after a trauma → hemarthrosis

Causes

- ACL tear
- Intra-articular fracture
- Patellar dislocation/subluxation
- Periarticular fractures
- Peripheral meniscus tear

If it developed the next day (within hours) after a trauma → serous effusion

Causes

- Meniscus tear
- Articular cartilage injury

With no preceding trauma

Causes

- Osteoarthritis
- Inflammatory arthritis, including rheumatoid arthritis
- Septic arthritis
- Chondrocalcinosis
- Loose body
- Pigmented villonodular synovitis (PVNS)

Explore the first time pain or swelling occurred: it may be many years prior to recent complaint.

### Localized

Anterior aspect of the knee

Prepatellar bursitis: The bursa is over the anterior portion of patella

Infrapatellar bursitis: The bursa is over the infrapatellar tendon.

Lateral aspect of the knee

Lateral meniscal cyst

Posteromedially

Semimembranosus bursitis

Posteriorly

Baker cyst

Popliteal aneurysm (rare cause)

Other causes for swelling

- Ganglion
- Neuroma
- Lipoma

Osteophytes  
Osgood–Schlatter’s disease

**Stiffness**

After Activity  
Arthritis  
Meniscal tear  
ACL tear

Rest Stiffness/Early Morning Stiffness  
Rheumatoid arthritis and other inflammatory arthropathy  
Osteoarthritis

**Locking /Catching**

Loose body  
Meniscal tear  
Patellar instability  
In true “locking” the patient can flex the knee from the angle of locking but is unable to extend. Structures causing loss of extension (loose body, displaced torn menisci) tend to be jammed in the intercondylar notch.  
In pseudo locking, the patient is unable to either extend or flex the knee.

**Giving Way**

Is the patient able to run/change direction during running?

Causes

ACL tear  
Patellar instability  
Pain due to any cause in the knee joint

## LOOK

### Alignment

Ask the patient to stand facing you (patellae facing forward). In this position the patient should be able to keep the knees and feet together (Figure 6.1).

Normally there is physiological valgus present which measures  $5^{\circ}$  in men and  $7^{\circ}$  in women on a radiograph. The following variations may be unilateral or bilateral:

In a varus knee, the feet are together but the knees are apart (Genu Varum)

#### Causes

- Osteoarthritis and collapse of medial compartment
- Angular deformity following old fracture femur or tibia
- Blounts disease

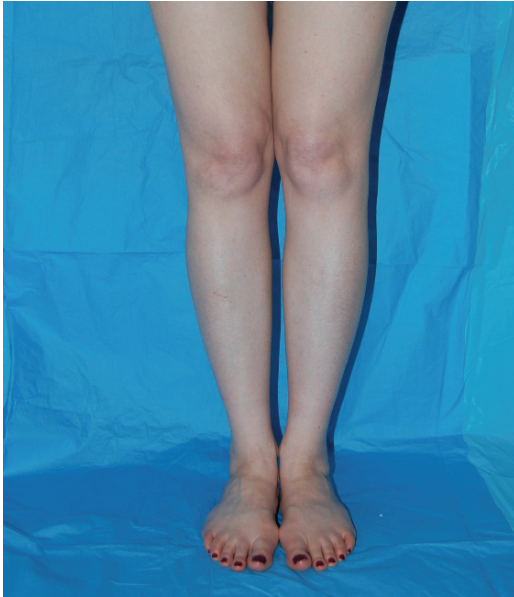


FIGURE 6.1. Normal alignment.

In a valgus knee, the knees are together but the feet stay apart (Genu Valgum).

*Note: In obese people, the thighs can sometimes not be brought together, which may produce false excessive valgus.*

**Causes**

Arthritis (usually rheumatoid arthritis) and collapse of lateral compartment

Angular deformity following old fracture of femur or tibia

**Flexion (Must Be Viewed from the Side)**

The patient stands with knee in various degree of flexion.

In slight flexion, the knee joint's capacity to accommodate fluid is maximal.

**Hyperextension (Must Be Viewed from the Side)**

If present, one should note whether it is unilateral or bilateral (Figure 6.2).

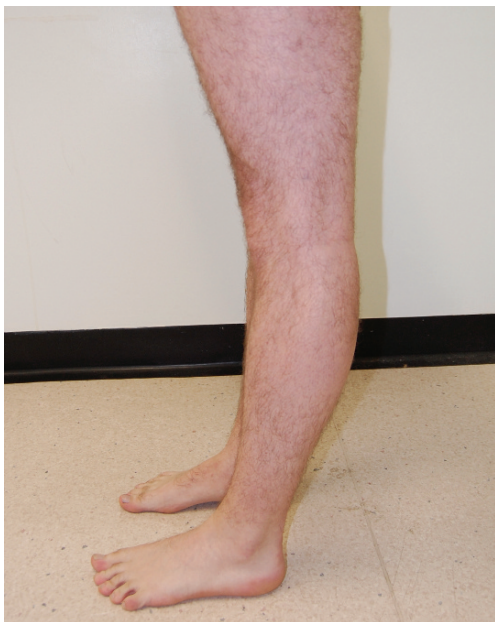

FIGURE 6.2. Hyperextension of the knee joints.

This is often seen in women with generalized ligamentous laxity.

Pathological

posterolateral capsular injury

Larsen's syndrome

### **Position of Hip and Ankle**

When standing, an imaginary line should pass through the center of the hip, center of the patella and through the second ray of the foot.

### **Skin Condition**

Redness → inflammation intra or extra articular. The periphery of the discoloration needs to be marked.

Loss of hair → neurological involvement

### **Scars**

Comment on

Position

Surgical or traumatic

Healed with primary or secondary intention

### **Swelling/Bursa**

#### **Generalized**

#### **Localized**

Anterior aspect of the knee

Prepatellar bursitis

Infrapatellar bursitis

Lateral aspect of the knee

Lateral meniscal cyst

Posteromedially

Semimembranosus bursitis

Posteriorly

Baker's cyst

Popliteal aneurysm (rare cause)

Other causes for swelling

Ganglion

Osteophytes

Osgood-Schlatter's disease Swelling/tenderness at the tibial tuberosity

### Muscle wasting of thighs/legs

Vastus medialis is the first muscle to atrophy following injury or inactivity and the last muscle to recover following rehabilitation.

### Popliteal fossa

Scars

Swelling

### Patella position

Normally the patellae are facing in  $40^\circ$  of external rotation. The examiner should look at the patella first, then at the hip and foot and check for external rotation of the tibia.

Squinting patella: when the patellae are facing each other.

#### Causes

Excessive external rotation of the tibia:

With normal femoral anteversion, the lower limb goes into external rotation with the feet externally rotated. Usually the patient tries to walk with internal rotation of the hip to make the feet face forward and hence conceal the deformity. This produces squinting patella.

Excessive femoral anteversion: The lower limb goes into external rotation. To conceal the deformity patients walk with internal rotation of the hip. In turn, this causes internal rotation of the feet. Secondary external rotation of the tibia may make the feet point forward.

**Patellar height:** The patient should sit on the edge of the examination table, with the knees facing the examiner. In 90° of flexion the patella should face directly forward (Figure 6.3).

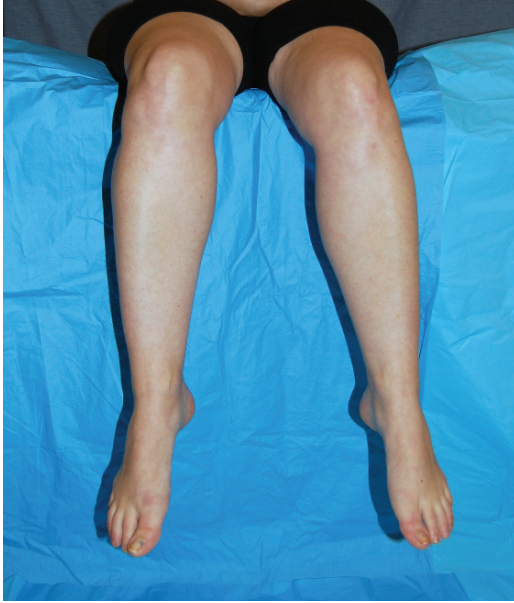


FIGURE 6.3. Assessing the patella height.



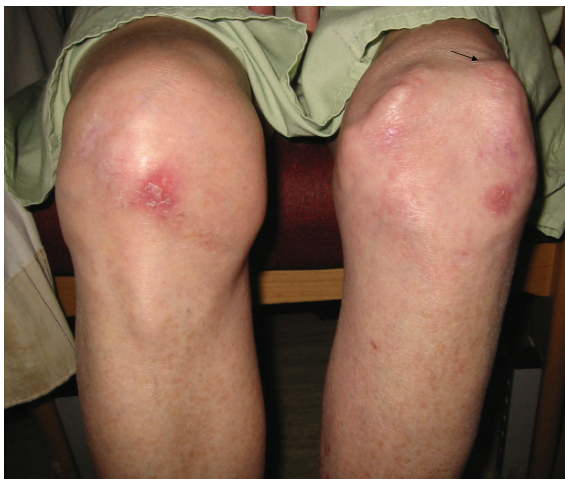

FIGURE 6.4. Patella alta in an untreated rupture of patellar tendon.

**Patella alta:** The patella faces at an angle toward the ceiling (Figure 6.4).

**Causes**

- Long patellar tendon
- Acute rupture of patellar tendon

**Patella baja (infra):** The patella is lower than usual. Difficult to assess unless very severe, but comparison to the normal side is helpful.

**Causes**

- Trauma
- Surgery

**Patella size**

**Patella magna:** very large patella. This can be either a normal variation or caused by excessive osteophyte formation due to osteoarthritis.

**Patella parva:** very small patella.

**Patella shape:** Irregularity may be due to trauma or a bipartite patella.

**Gait**

**Varus Thrust**

The knee goes into increased varus on weight bearing as the opposite foot is in lift off position.

**Causes**

- Advanced arthritis of the knee, with collapse of the medial compartment
- Posterolateral ligament complex injury (varus recurvatum thrust)
- ACL injury

**Vaglus Thrust**

The knee goes into increased valgus on weight bearing as the opposite foot is in lift off position.

**Causes**

- Advanced arthritis and collapse of lateral compartment

**Antalgic Gait (Best Viewed from the Side)**

If the knee is the cause of the pain, the patient tends to reduce the time of weight bearing on the affected knee. Hence the stance phase is quick on the painful knee.

**Stiff Knee Gait (Best Viewed from the Side)**

The knee is kept in extension during the whole gait cycle. Since the functional length of the limb is longer with the knee in extension, the affected limb swings outward and the body shuffles during the swing phase.

**Causes**

- Pain in the tibiofemoral articulation or patellofemoral joint
- Weak or paralyzed quadriceps (e.g.: old poliomyelitis)

*Note: In severe weakness or paralysis of the quadriceps, patients push the knee into hyperextension or recurvatum in order to prevent it from collapsing during the stance phase.*

**Flexed Knee Gait (Best Viewed from Side)**

The knee is kept in a certain degree of flexion during the gait cycle. Since the functional length of the limb is shorter in flexion, the affected limb can take shorter strides and, instead of heel first, the foot hits the ground flat. The gait has a characteristic up and down movement.

**Cause**

- Flexion contracture of the knee

**Q Angle**

The quadriceps angle or, in short, the “Q angle” is the angle between the longitudinal axis of quadriceps muscle and the patellar tendon and reflects the angle of quadriceps muscle force.

The patient should be facing the examiner in a standing position, with both hip and foot in neutral position. A line is then drawn from the anterior superior iliac spine (ASIS) to the center of the patella and a second line from the center of the patella to the tibial tubercle (Figure 6.5). The angle between the two lines represents the Q angle.

Alternatively, and with experience, one can place the goniometer on the center of the patella and adjust the limb of goniometer to point to the direction of the ASIS and tibial tubercle.

Normal values

14° in men

17° in women

Average 15° in normal individual

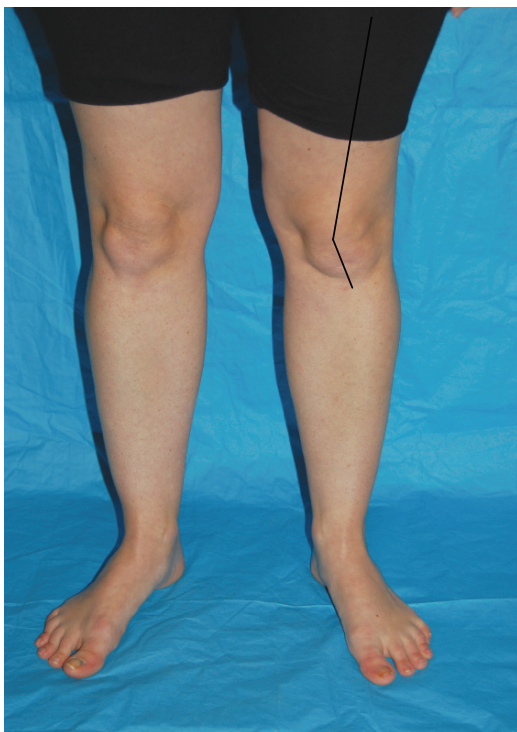

FIGURE 6.5. Q angle.

Causes of increased Q angle

Genu valgum

Excessive femoral anteversion

Excessive external tibial torsion

Lateral displacement of tibial tubercle

Causes of decreased Q angle

Habitual subluxation of patella

Patella alta

### Range of Movement

While the patient is on the examination table, ask him to lift his leg off the bed. In so doing, you have tested the active extension of the knee. If the patient is able to extend the knee fully off the table, the power is at least 3 in the MRC grade. If the patient is unable to extend fully, note the degree of flexion the knee is in and how much this is short of full extension. Then try to passively extend the knee.

If you can bring the knee to full extension, the difference between active and passive extension is expressed as “**extension lag.**”

Age and extensor mechanism lesions

Tibial Tubercle: 10

Patellar tendon: 20s

Patella: 30s

Quadriceps tendon: 50s

Quadriceps muscle: 70s

Causes of extension lag

Pain

Weakness of quadriceps or rupture

Rupture of the extensor mechanism can result in an inability to straight leg raise. The weakest point along the mechanism from tibial tubercle to quadriceps muscle is age-related (tubercle 10y patella tendon 20y patella 30y quadriceps tendon 50y quadriceps muscle 70y) Tender palpable gaps may be felt following direct or indirect injury (Figure 6.6).

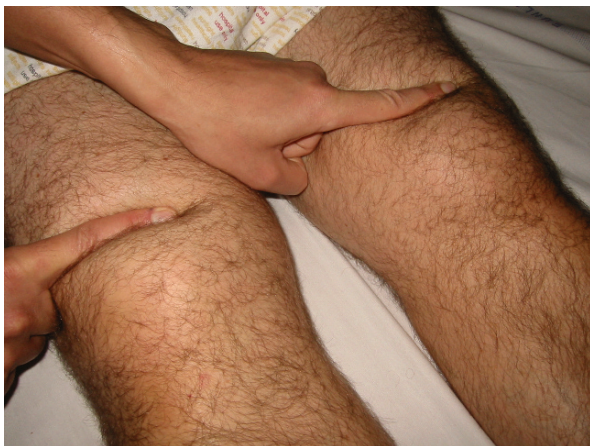

FIGURE 6.6. Bilateral quadriceps rupture.

If full passive extension is not possible, then flexion deformity is fixed and expressed as **fixed flexion deformity**. From this point ask the patient to flex the knee as far as possible and compare to the other side.

Causes of flexion deformity

Pain

Swelling

Arthritis

Mechanical block (lesion in intercondylar notch)

Displaced meniscus tear

Loose body

Stump of torn ACL

Another method to assess flexion deformity: The examiner asks the patient to lie in a supine position, and lifts the feet by holding the heels. Note whether both knees are at the same level or not. Alternatively, ask the patient to try to trap the examiner's hand behind the knee against the couch to detect subtle fixed flexion. Hyperextension is normal in many individuals, especially if symmetrical.

If flexion deformity is in doubt, the prone hanging test can be preformed.

The patient lies down in a prone position at the end of the table while the knees are beyond the edge of the table. The examiner measures the difference between the heights of the heels (Figure 6.7). Each 1 cm difference roughly corresponds to 1° of knee flexion deformity.

**Flexion:** First ask the patient to flex the knee as far as possible. Then try to passively flex the knee if the range of flexion is not full. Always compare to the other side.

*Note: At some point it is useful to put your hand over the knee during one cycle of flexion and extension and feel for crepitus, which is usually present in arthritis.*

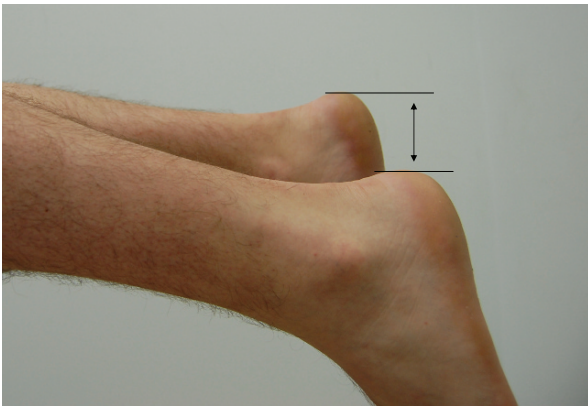


FIGURE 6.7. Measurement of fixed flexion deformity.

## FEEL

### Skin Temperature

Run the back of your fingers from mid calf to mid thigh. In this way an examiner can compare the temperature of normal skin and feel the rise of temperature if present.

Causes of rise in temperature

Septic arthritis

Bursitis

Acute attack of gout

### Effusion/Swelling

An effusion is an increase in the amount of fluid inside the joint. The most commonly performed tests for effusion are:

#### Cross Fluctuation

Patient in supine position. The examiner compresses and empties the suprapatellar pouch with the contralateral hand while the other hand straddles the front of the joint below the patella. The examiner then squeezes with each hand alternately (Figure 6.8). In a positive test, the fluid impulse transmitted across the joint is felt (for large effusion).

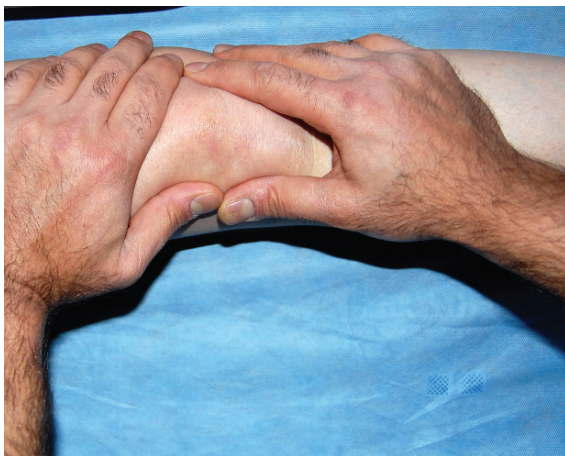

FIGURE 6.8. Cross fluctuation.

**Patellar Tap**

Patient in supine position with the knee extended. The examiner compresses and empties the suprapatellar pouch with one hand while with the index finger of other hand pushes the patella sharply posterior toward the femur (Figure 6.9). In a positive test the patella can be felt striking the femur and bouncing off again (for moderate and large effusions).

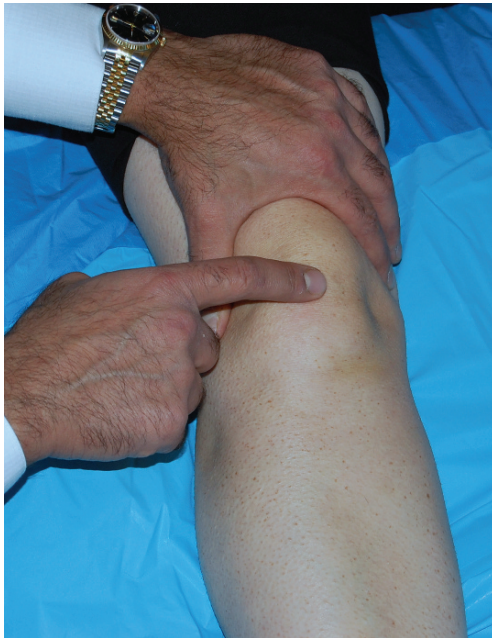

FIGURE 6.9. Patellar tap.



**Patellar Hollow Test**

The patient is sitting at the edge of the examination table with the knee in 90° of flexion. In the normal knee, a hollow appears lateral to the patellar ligament (Figure 6.10) and disappears with further flexion. With presence of excess fluid, the hollow fills and disappears at a lesser angle of flexion. (For minimal effusion)

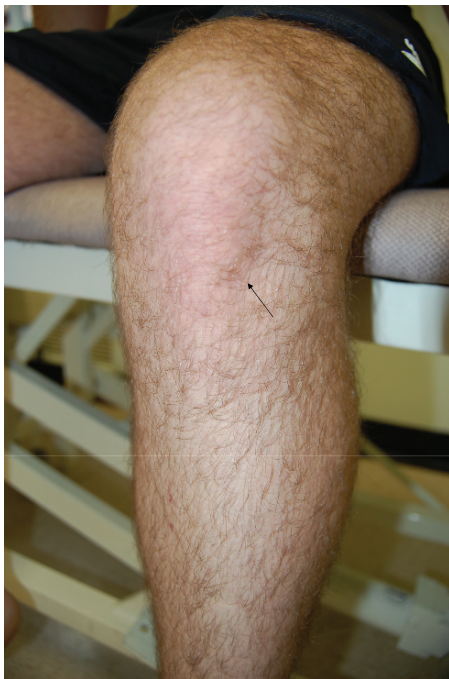

FIGURE 6.10. Normal hollow lateral to the patellar ligament.

**Synovial Thickening**

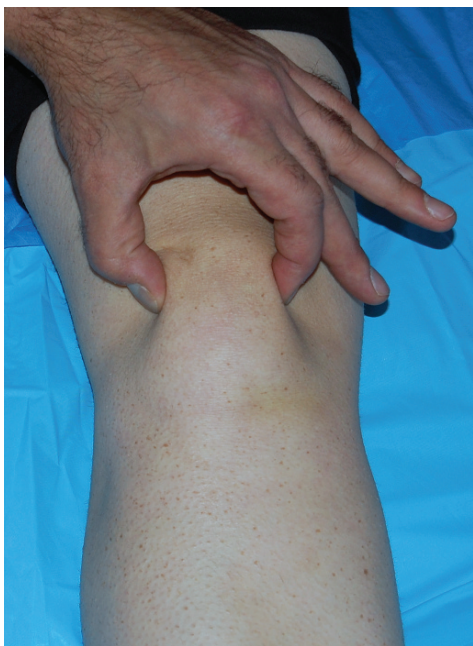
The supra patellar pouch has a horseshoe shape. Run the tip of your fingers over the edge of the pouch (Figure 6.11). If synovial hypertrophy is present, the fold of thickened synovium at the edge can be rolled under the fingers and feels like a cord-like structure.

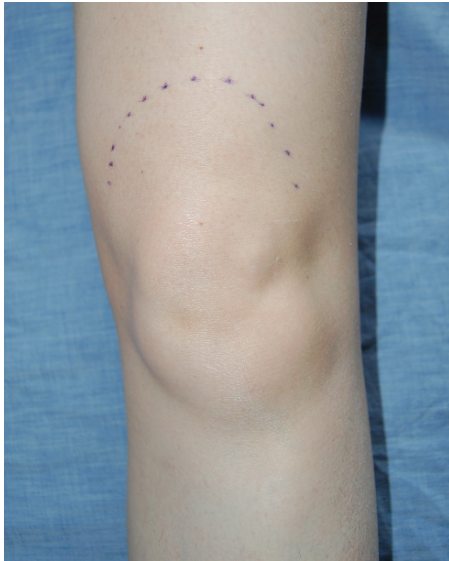

FIGURE 6.11. Boundary of suprapatellar pouch.

In gross synovial thickening, a boggy or spongy swelling can be felt around the knee joint, especially either side of and just above the patella and may make it difficult to “pick up the patella” between the examiner’s thumb and index finger (Figure 6.12).

A large tense effusion may appear similar to excessive synovial hypertrophy.



**FIGURE 6.12.** Picking up the patella is difficult in synovial hypertrophy.

## Medial Side

### Medial Joint Line

Patient is on the examination table with the knee in 90° of flexion. This causes the femur to roll back on the tibia and makes the anterior joint line more accessible. With the tip of the index finger, palpate the joint line anteriorly and press repeatedly toward the posterior aspect along the medial rim of the tibia. The medial meniscus becomes more prominent with internal rotation of the tibia.

Tenderness of the medial joint line is often symmetrical in normal knees. Unilateral tenderness is more likely to represent a pathological cause.

### Anterior Joint Line Tenderness

The anterior joint line tenderness is non specific. Probably the only exception to this occurs in a locked knee due to displaced bucket handle tear of meniscus.

Medial and posterior joint line tenderness → meniscus pathology  
→ medial compartment  
osteoarthritis

Medial compartment joint line tenderness exacerbated by

varus stressing when flexing the knee (Heatley agony test) → medial compartment osteoarthritis

flexion and tibial rotation → medial meniscal injury

### Medial Collateral Ligament

Feel the medial epicondyle (the femoral attachment of MCL) and palpate distally and obliquely toward its tibial attachment. It crosses the medial joint line and hence tenderness at this point can be due to either MCL or medial meniscus injury.

Opening of the medial joint line by applying valgus force in:

30° of flexion → isolated MCL injury (painful in acute injuries)

full extension → MCL and ACL tear

**Semitendinosus (ST), Gracilis, and Semimembranosus(SM)**

All 3 tendons are situated posteromedially. To palpate them, knee should be in flexion.

**Semitendinosus:** Most posterior and inferior, more prominent in resisted flexion (Figure 6.13). Round tendon.

**Gracilis:** Anterior and medial to ST, more prominent in resisted internal rotation. Round tendon.

**Semimembranosus:** Deep and between ST and Gracilis, remains muscular to its insertion.

Bursitis of this tendon is more prominent in knee extension and disappears in flexion.

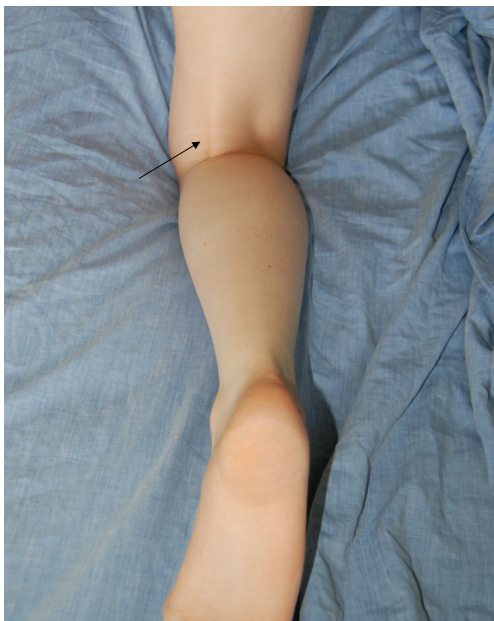


FIGURE 6.13. Semitendinosus tendon.

## Lateral Side

### Lateral Joint Line

Patient is on the examination table with the knee in 90° of flexion. This causes the femur to roll back on the tibia and makes the anterior joint line more accessible. With the tip of the index finger or thumb, palpate the joint line anteriorly and press repeatedly toward the posterior aspect along the lateral rim of the tibia (Figure 6.14).

Anterior joint line tenderness → Nonspecific

Lateral and posterior joint line tenderness → meniscus pathology  
→ lateral compartment  
osteoarthritis

Lateral compartment joint line tenderness exacerbated by

Valgus stressing when flexing the knee → Lateral compartment  
osteoarthritis

Flexion and tibial rotation → Lateral meniscal injury

*Note: Valgus stress while flexing from full extension causing pain medially is indicative of medial ligament synovitis and often indicates a medial meniscal tear or partial medial ligament injury.*

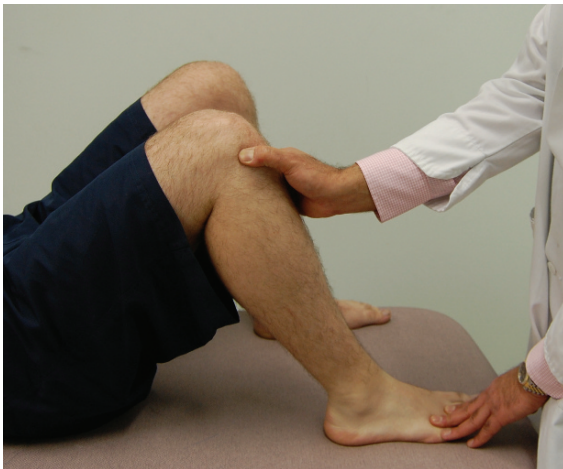

FIGURE 6.14. Palpation of the lateral joint line.

**Lateral Collateral Ligament**

Ask the patient to put the leg in a figure four position. The LCL is easily palpable between the lateral femoral epicondyle and the head of the fibula (Figure 6.15)

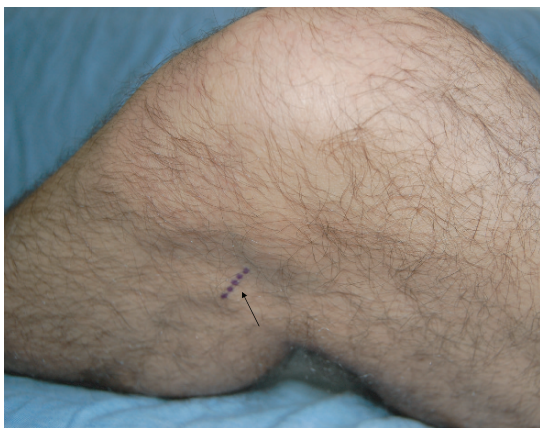

FIGURE 6.15. Lateral collateral ligament.

**Biceps Femoris Tendon**

With flexion of the knee, the biceps femoris tendon becomes prominent and it can be felt near the fibular head. Ask the patient to flex against the resistance while palpating the tendon. Biceps tendinitis is occasionally a cause of pain in the lateral aspect.

**Popliteal Fossa**

Patient in prone position on the examination table with knee in flexion.

**Popliteal or Baker's Cyst**

Usually a painless and mobile swelling, veering to the medial side of the fossa. More prominent with the knee in extension. Sometimes it is possible to empty the contents of the cyst into the knee joint with gentle and uniform pressure.

Occasionally pulsatile swellings (Popliteal aneurysm) and tumors arising from the neurovascular structure are felt in this area.

Cysts may also be felt adjacent to the posterior knee tendons.

**Patella**

Patient is in supine position. With knee extended and quadriceps fully relaxed, the patella is usually quite mobile for further examination.

**Mobility**

Normally the patella should move half of its width medially and one third of its width laterally (Figure 6.16).



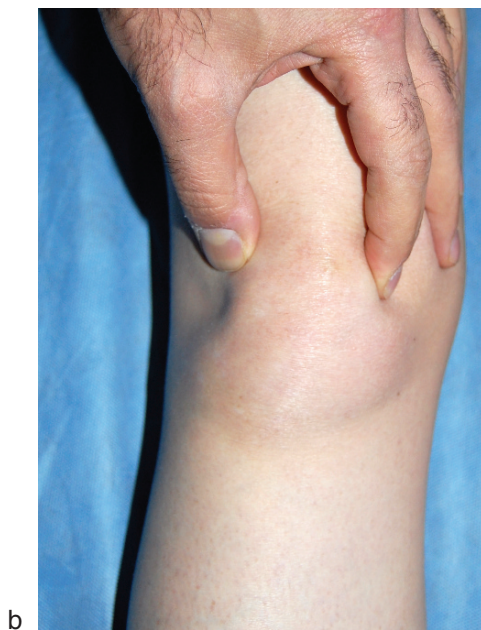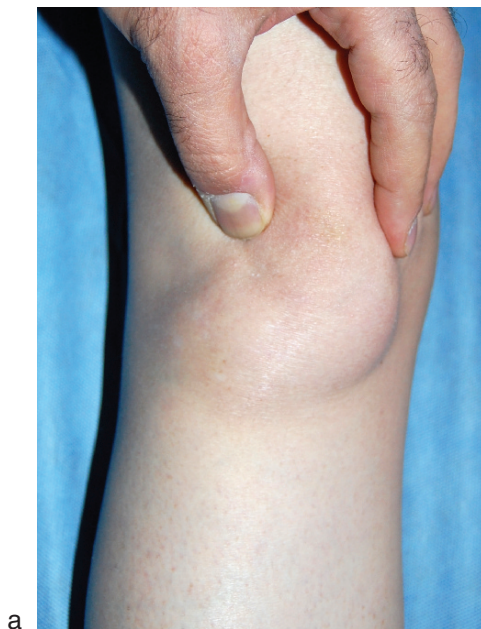


FIGURE 6.16. (a) Medial displacement of the patella. (b) Lateral displacement of the patella.

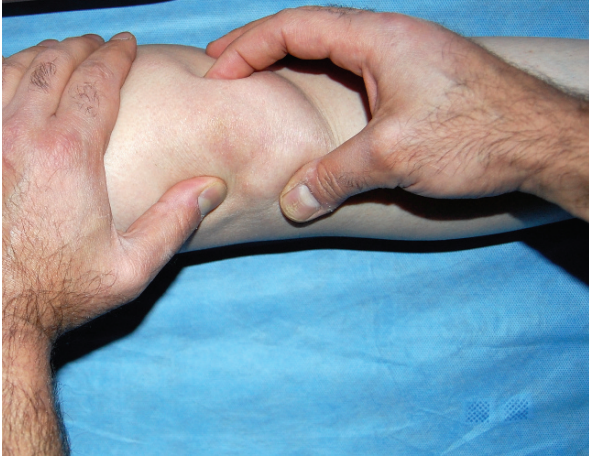

FIGURE 6.17. Palpation of the medial facet.

### **Medial Facet**

With one thumb, move the patella medially and, with the index finger of the other hand, palpate the under surface of the medial facet (Figure 6.17).

### **Lateral Facet**

With one thumb, move the patella laterally and, with the index finger of the other hand, palpate the under surface of the lateral facet.

### **Pathological Medial Plica**

This is sometimes the source of pain in the medial/anteromedial side of the knee joint. With the patient supine and the knee in 30° of flexion, it may be palpated as a band or simply a tender area running between the patella and medial femoral condyle.

**MOVE****Muscle Testing****Quadriceps (Femoral Nerve L2, L3, L4):**

In a supine position: Put one forearm under the knee joint and, with the other hand, apply resistance while the patient is instructed to extend the knee.

In a sitting position: Stabilize the thigh with one hand and then apply resistance, while the patient is instructed to extend the knee (Figure 6.18). Feel for the contracture of the muscle with your stabilizing hand.

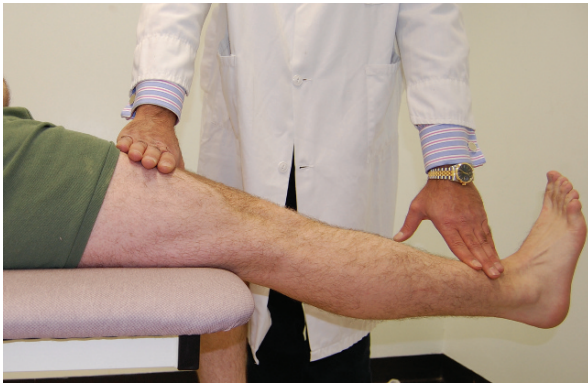

FIGURE 6.18. Assessing the quadriceps.

**Hamstrings (BF, SM, ST: Sciatic nerve L5, S1, S2) and Gracilis (Obturator nerve L2-L3)**

Tested as a group.

**In a supine position:** Hold the hip at 60° of flexion and stabilize the knee with one hand. With the other hand, hold the leg above the malleoli and apply resistance, while the patient is instructed to flex the knee.

**In a prone position:** The patient is instructed to flex the knee and hold the flexed position at about 60° while the examiner applies resistance with one hand. The other hand should be placed on the muscle to feel the contracture (Figure 6.19).

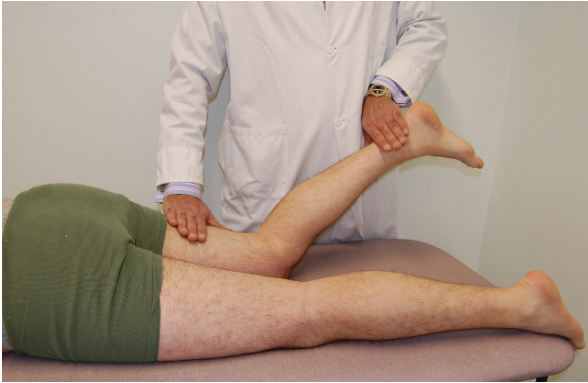

FIGURE 6.19. Assessing the hamstrings.

**Muscle Wasting**

Measure the thigh circumference. In a supine position, mark a point 15 cm above the superior pole of the patella on both thighs and measure the circumference of both thighs at this point with a tape.

### Sensation

The only nerve specific to the knee joint to be tested is the infrapatellar nerve (infrapatellar branch of saphenous nerve). It runs medial to lateral just inferior to the patella but its course is highly variable. It often gets injured in longitudinal midline incisions and leaves an anesthetic patch lateral to the surgical scar (Figure 6.20). Occasionally it is also injured by a direct fall on to the knee.

The neurological examination of the lower limb is covered in spine chapter.

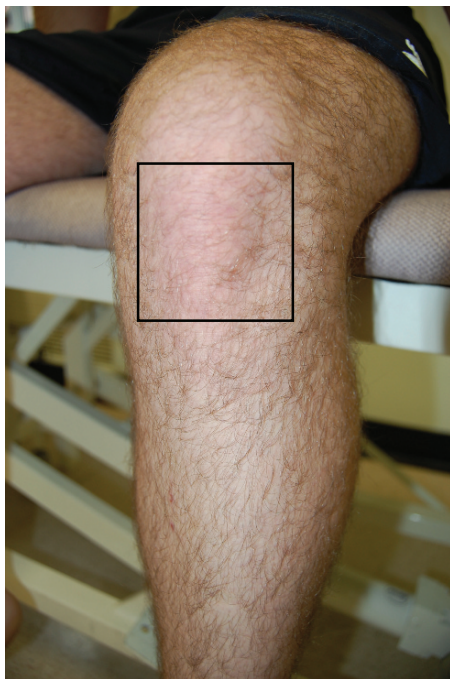


FIGURE 6.20. Sensory distribution of the infrapatellar nerve.

## Pulses

### Popliteal Artery

Deep structure in the middle of the popliteal fossa. With flexion of the knee and deep palpation, the pulse can be felt.

### Dorsalis Pedis Artery

Ask the patient to extend the big toe and observe the extensor hallucis longus tendon. It can be felt just lateral to the EHL and proximal to the prominence of the metatarsocuneiform joint.

## Special Tests

### Meniscal Test

#### McMurray's Test

Patient in supine position flexes the knee as far as possible. One hand supports the knee in such a way that the thumb and index finger are on the medial and lateral joint lines respectively. The other hand grasps the foot.

To test the medial meniscus, external rotation force is applied to the foot, with varus stress to the knee joint to close the medial compartment and then the knee is passively extended (Figure 6.21). If the patient complains of pain or a click is heard (rare), the test is considered positive for a medial meniscal tear.

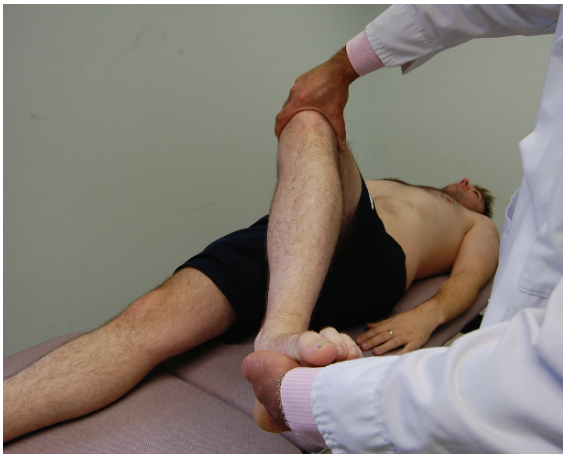

FIGURE 6.21. McMurray's test. Assessing the medial meniscus.

To test the lateral meniscus, internal rotation force is applied to the foot, with valgus stress to the knee joint in order to close the lateral compartment and then the knee is passively extended (Figure 6.22). If the patient complains of pain or a click is heard (rare), the test is considered positive for a lateral meniscal tear.

*If full flexion is not possible, McMurray's test can still be performed but lesions of the posterior horn of meniscus can not be tested.*

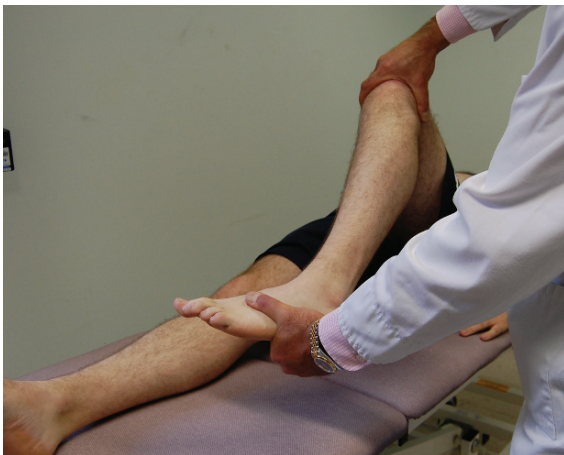

FIGURE 6.22. McMurray's test. Assessing the lateral meniscus.



**Steinmann's first test**

Sudden external rotation of the foot with the knee in 90° of flexion can cause pain in the medial compartment, which is suggestive of a medial meniscal tear (Figure 6.23).

Sudden internal rotation of the foot with the knee in 90° of flexion can cause pain in the lateral compartment, which is suggestive of lateral meniscal tear.

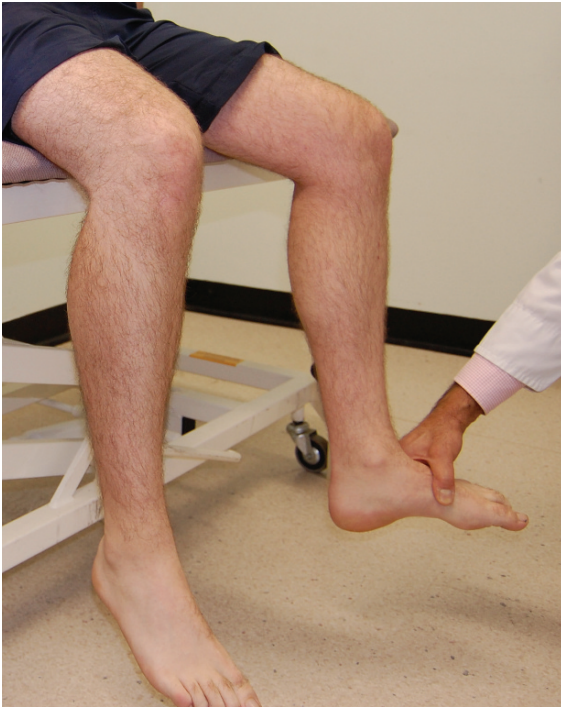

FIGURE 6.23. Steinmann's first test for medial meniscus.



**Anterior/Posterior Instability**

First the examiner must ascertain that there is no posterior sag on the affected knee. With the patient supine, flex the knees to 90° while keeping the knees and ankles together. The examiner can then observe the tibial tubercles from the side. Both tibial tubercles should be at the same level. In the case of posterior cruciate ligament rupture, the tibia sags posteriorly and the tibial tubercle appears less prominent and posterior to the normal side.

**Anterior Drawer Test**

The patient should be supine with knees flexed to 90°. The feet are stabilized in a neutral position and the examiner sits at the forefeet of the patient.

Ask the patient to relax. With the index fingers of both hands, feel the hamstring tendons and check if the muscles are relaxed before you manipulate the knee.

Grasp the knee with both hands; the tip of your thumbs should be just below the joint line (Figure 6.24). Then pull the tibia forward. The amount of anterior translation of tibia and quality of end point is assessed.

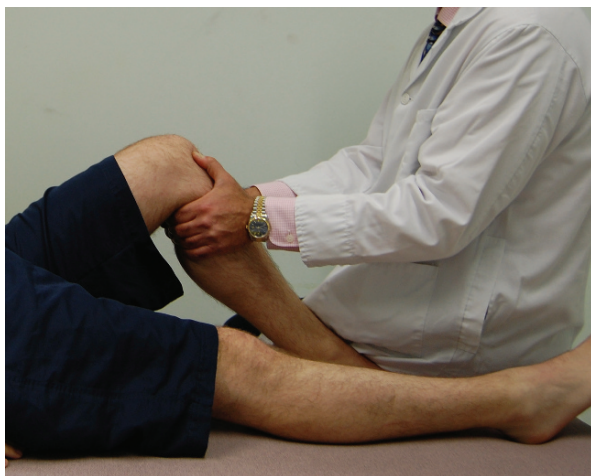

FIGURE 6.24. Anterior drawer test.

Normal knee → A few millimeters of anterior translation with a firm end point (stops suddenly)

ACL rupture → 5 mm or more of anterior translation with a soft end point

Always compare the affected side with the normal side.

False negative test

Spasm of hamstring muscle due to pain

Torn posterior horn of medial meniscus (wedged against femoral condyle)

Hemarthrosis

False positive test

Undetected PCL rupture

### **Lachman's Test**

This is a very sensitive test for ACL rupture. The patient is in a supine position. The examiner grasps the thigh with one hand and with the other hand grasps the tibia at the level of the tibial tubercle and brings the knee to 30° of flexion (Figure 6.25). The hand on the thigh both stabilizes it and also feels for the hamstring tightness. Once the thigh is stabilized, the hand holding the tibia pulls it forward and the amount of anterior translation of tibia on the femur is measured and the quality of the end point is noted.

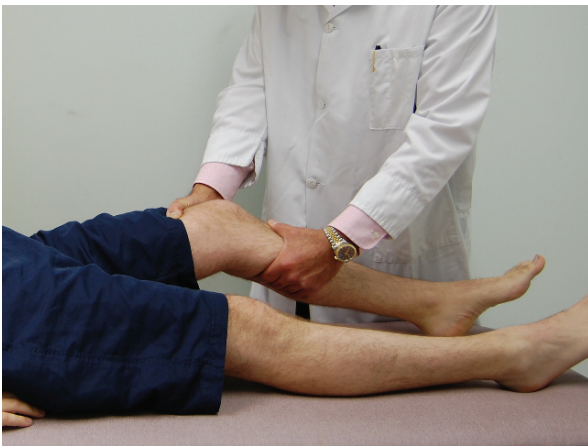

FIGURE 6.25. Lachman's test.

**Pivot Shift Test**

With the patient in supine position with their leg relaxed in full extension, the examiner should hold the foot with his ipsilateral hand and exert an internal rotation and axial force to the ankle (Figure 6.26). The examiner then exerts an anterior and medial directed force to the fibula head with his contralateral hand, generating a valgus strain on the knee and subluxing the lateral tibial plateau forward (Figure 6.27). The gentle displacing forces on the tibia are maintained as the knee is slowly flexed. If the lateral tibial plateau has been subluxed, indicating ACL deficiency and rotational instability, it will slip (or clunk) back into its normal position as the knee flexes thus demonstrating a positive test. Most patients will tolerate the demonstration of a positive test in the clinic as long as gentle forces are used initially and slowly increased.

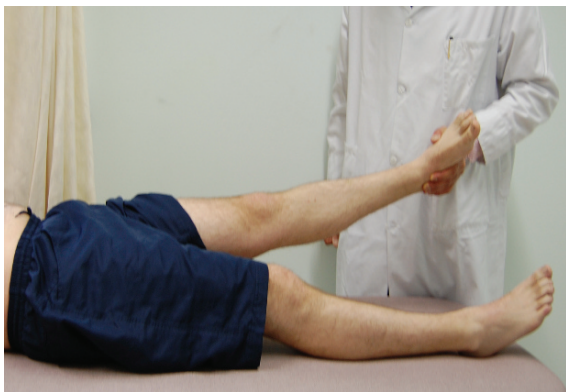

FIGURE 6.26. Pivot shift test. Starting position.

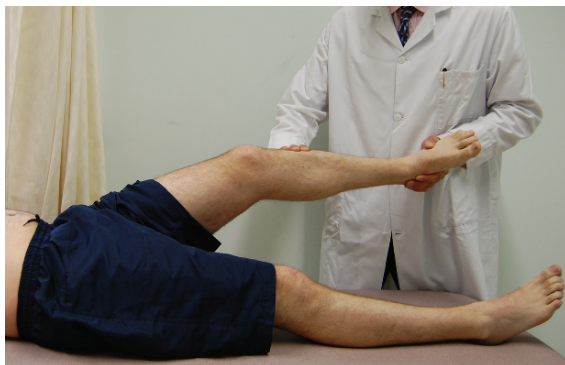

FIGURE 6.27. Pivot shift test. See text.

### Posterior Drawer Test

The starting position is the same as for the anterior drawer test. Patient in supine position, with knees flexed to  $90^\circ$ . The foot is in neutral position and the examiner sits at the forefoot of the patient to stabilize it. Grasp the knee with both hands; the tip of your thumbs should be just below the joint line. Then push the tibia backward. The amount of anterior translation of the tibia and the quality of the end point is assessed.

Normal knee  $\rightarrow$  No posterior translation

PCL rupture  $\rightarrow$  Posterior translation (may be very subtle translation); usually associated with *firm* end point

### Posteromedial/Posterolateral instability

#### Slocum Test

It is convenient to do the Slocum test immediately after the anterior drawer test.

After completion of the anterior drawer test, put the foot in  $15^\circ$  of external rotation and repeat the anterior drawer test and compare it with the anterior translation of the tibia with the foot in a neutral position. Then put the foot in  $30^\circ$  of internal rotation and repeat the anterior drawer test and compare it with the anterior translation of the tibia with the foot in a neutral position.

Anterior translation greater when the foot in external rotation → Posteromedial injury

Anterior translation greater when the foot in internal rotation → Posterolateral injury.

### **Dial Test**

This is another method for the demonstration of posterolateral instability.

The patient is in a supine or prone position (this test can be done after inspection of popliteal fossa as patient is already in prone position), with knees in 30° of flexion and knees and feet together. Examiner then externally rotates both feet passively and compares the amount of external rotation (Figure 6.28).

Increased external rotation → Posterolateral instability

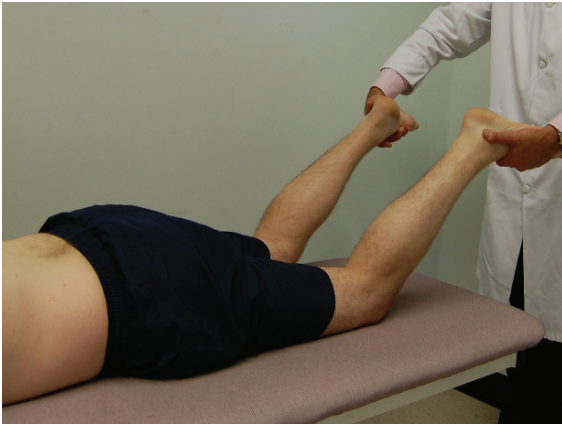

FIGURE 6.28. Dial test.

## Varus/Valgus

The measurement of varus/valgus deformity (if present), should be done now with the help of a goniometer.

Place the limbs of the goniometer on the thigh along the axis of the femur and of the tibia and read the angle. Also check if deformity is fixed or correctable. Apply the opposite force to direction of deformity (i.e. valgus force to varus deformity and varus force to valgus deformity).

If the deformity is correctable, the knee can be brought to neutral alignment. Keep in mind that deformity may be correctable in full or partially and both can co-exist together.

### Varus /Valgus Instability Test

This is to check the integrity of the medial and lateral collateral ligament.

The patient is relaxed in a supine position. The examiner holds the leg in his axilla, with the knee in 20° of flexion. With both hands, the tibia is held firmly in such a way that the thumbs are on either side of the patellar tendon and the index fingers are placed on the femoral attachments of the medial and lateral femoral condyles (Figure 6.29). Then valgus force (for MCL) and varus force (for LCL) is applied and the amount of opening is noted.

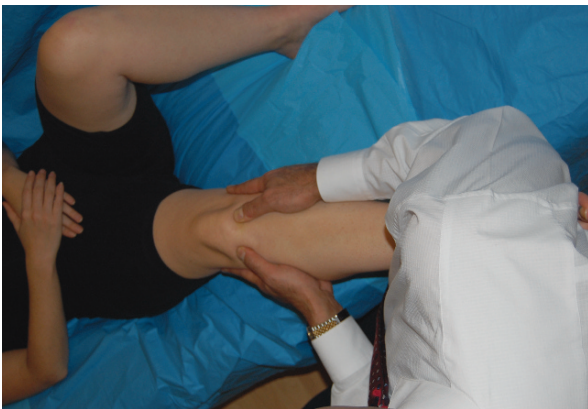

FIGURE 6.29. Varus and valgus stability test.

## Patellar Tracking

### J Sign

The patient is sitting at the edge of the examination table and can freely flex and extend the knee. The examiner faces the patient and observes the movement of the patella as the patient flexes and extends the knee repeatedly. Quadriceps contraction in full extension may cause lateral subluxation of the patella and a reduction in the Q angle in patients with a tendency to subluxation or patella dislocation is referred to as the J sign. This indicates lateral patellar tracking. In some cases, putting a dot at the center of the patella is useful.

### Patellar Apprehension (Fairbank's) Test

This test demonstrates patellar instability under controlled conditions. The patient is in a supine position and relaxed. The patella is pushed as laterally as possible by the examiner (Figure 6.30) and the patient is asked to flex the knee slowly. With a positive history of subluxation or dislocation, the patient is unwilling to flex the knee beyond a certain angle and it creates an apprehension in the patient that the kneecap is going to dislocate, or the patient may feel that the leg is going to break.

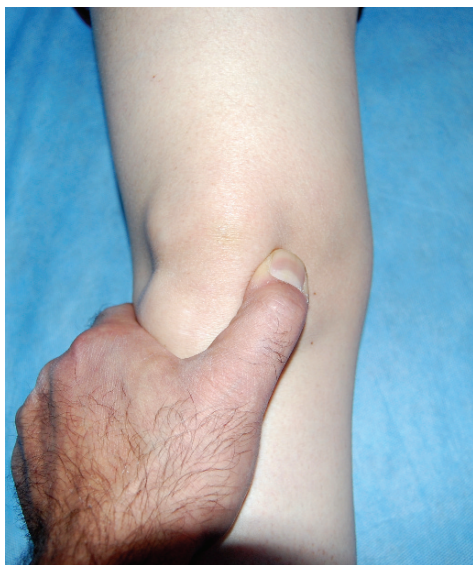

FIGURE 6.30. Apprehension test. Starting position.

**Patellar Grinding**

Hold the patella with the thumb and index finger and gently press it down and move it medially and laterally. At the same time look at the patient's face to see in which direction, medial or lateral, pain is produced. This usually demonstrates a defect in the articular cartilage of the patellofemoral joint.

*This test might be painful and is best done at the end of examination.*

**Clark's Test**

Stabilize the patella gently by putting your index finger over the superior pole of the patella (Figure 6.31). Ask the patient to contract the quadriceps by pushing the knee down. If pain is produced, it is suggestive of arthritis of the patellofemoral joint with concomitant synovitis in the suprapatellar pouch.

*This test might be painful and is best done at the end of examination.*

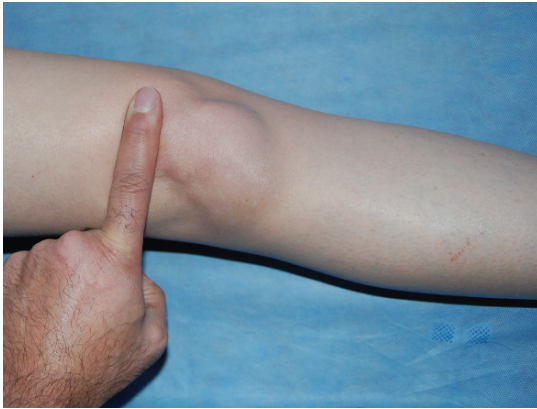

FIGURE 6.31. Clark's test.



**Wilson Test**

This is a test for osteochondritis dissecans.

A patient in a supine position is asked to flex the knee to 90°. The examiner then holds the foot and internally rotates the leg and gently extends the knee completely. If a classic lesion of osteochondritis dissecans (located on the lateral aspect of the medial femoral condyle adjacent to the intercondylar notch) is present, it impinges against the ACL and produces pain as the internally rotated knee reaches terminal degrees of extension. External rotation of the knee should eliminate the pain.

# Chapter 7

## Foot and Ankle

---

### **LISTEN**

#### **Mechanism of Injury (If Applicable)**

Patient usually remembers their position at the time of injury. Certain mechanisms of injury result in characteristic patterns of structural damage.

##### **Common Examples**

Inversion → anterior talofibular ligament

→ calcaneofibular ligament

→ 5th metatarsal base fracture

→ fracture of the anterior process of the calcaneus

Eversion → deltoid ligament

→ syndesmosis ligaments

Hyperdorsiflexion → talar fracture

→ dislocation of peronei tendon

Hyperplantar flexion → Fracture of lateral tubercle of the posterior process of the talus

#### **Pain**

##### **Site of Pain**

Localized pain (to which the patient can point with a finger)

Medial side → deltoid ligament injury

→ fracture of medial malleolus

→ tibialis posterior tendinitis

Lateral side → calcaneofibular ligament injury

→ fracture of lateral malleolus

Generalized pain → degenerative changes  
→ osteochondritis dissecans  
→ nerve injury (e.g. superficial peroneal nerve traction injury)  
→ complex regional pain syndrome

What activity brings on the pain?

### **Pain Increased**

Weight bearing → arthritis, fractures

Wearing footwear → bunion, fixed deformities/hallux rigidus

Walking on uneven ground → subtalar involvement, peroneal tendons

Walking on even ground → any part of the foot can cause this

Walking uphill/ going upstairs → anterior impingement

Walking downhill/ going down stairs → posterior impingement

### **Relieving Factors**

Wearing boot or brace reduces the pain → instability, fractures

### **Type of Pain**

Aching pain → degenerative changes

Sharp/catching pain → mechanical pain, ligament sprain, loose body

Pain during activity → structural abnormality (ligament sprain), arthritis

Pain after activity → inflammatory arthropathy, tendinosis, arthritis

Rest pain → usually not mechanical in origin, however sometimes seen in advanced arthritis. Peripheral nerve injury, lumbar spine or complex regional pain syndrome are other possibilities. In patients with no history of trauma, other causes, such as bone tumor, should be ruled out.

Does pain cause any restriction on activity? Quantify (in meters, blocks, miles or kilometers) how far the patient can walk.

Does the pain wake the patient from sleep? At night the protective muscle spasm is removed and hence movements can cause severe pain.

**Swelling****Generalized Swelling**

If it developed within minutes after a trauma

Fracture

Ligament sprain

Contusion

If developed within hours after a trauma or if the patient first notices it the next day

Articular cartilage injury

Ligament sprain

With no trauma

Osteoarthritis

Inflammatory arthropathy, including rheumatoid arthritis

Septic arthritis

AVN of talus/ navicular

Cardiovascular (e.g., congestive heart failure)

Deep venous thrombosis

Lymphatic condition

Tumor (including abdominal tumor compressing vena cava or iliac vessels)

**Localized Swelling**

Medial side → deltoid ligament injury

→ fracture of medial malleolus

→ tibialis posterior tendinitis

Lateral side → calcaneofibular ligament injury

→ fracture of lateral malleolus

→ peroneal tendons

**Stiffness**

After activity → arthritis

Rest stiffness/early morning stiffness → rheumatoid arthritis and  
other inflammatory  
arthropathy  
→ osteoarthritis

## LOOK

The patient should remove shoes and socks and trousers should be rolled up to the knee joint. Ideally the hip joint should be visible.

### Alignment

Ask the patient to stand facing you.

Normally the foot is in slight external rotation from the sagittal axis of the body (Figure 7.1). This is called the Fick angle (Normal range  $5^{\circ}$ – $18^{\circ}$ ).

Rotation abnormalities can arise from various locations: (Adapted from Tachdjian)

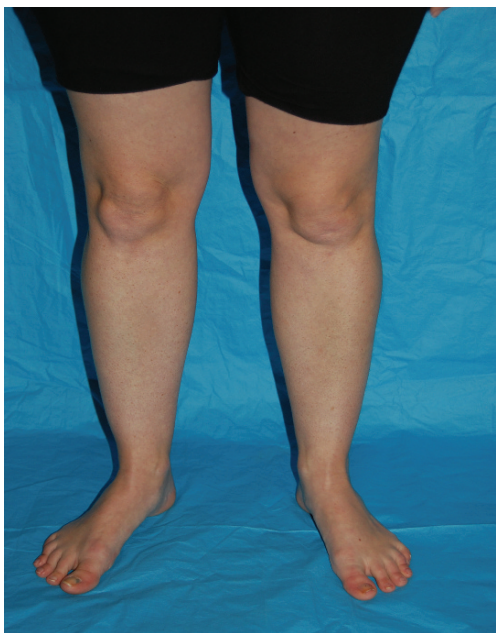


FIGURE 7.1. Fick angle.

**Causes of Toe in**

Foot-ankle → pronated feet

→ metatarsus varus

→ talipes varus and equinovarus

Leg-knee → tibia vara (Blount's disease) and developmental genu varum

→ excessive internal tibial rotation

→ genu valgum with compensatory internal rotation of tibia to shift the center of gravity medially

Femur-hip → excessive femoral anteversion

→ spasticity of internal rotators of the hip (cerebral palsy)

**Causes of Toe out**

Foot-ankle → pes valgus (contracture of triceps surae)

→ talipes calcaneovalgus

→ congenital convex pes planovalgus

Leg-knee → excessive external tibial rotation

→ congenital absence / hypoplasia of fibula

Femur-hip → excessive femoral retroversion

→ flaccid paralysis of internal rotators of the hip

Now look at the foot and ankle from the front (patient is standing)

Big toe: Normally this should be pointing directly forward.

Hallux valgus: Big toe deviates away from body midline (Figure 7.2).

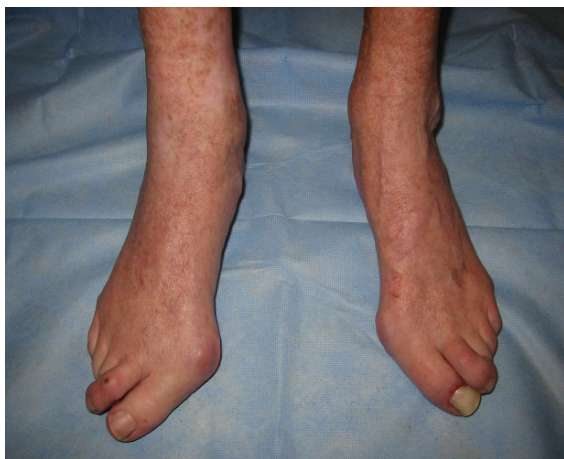

FIGURE 7.2. Hallux valgus.

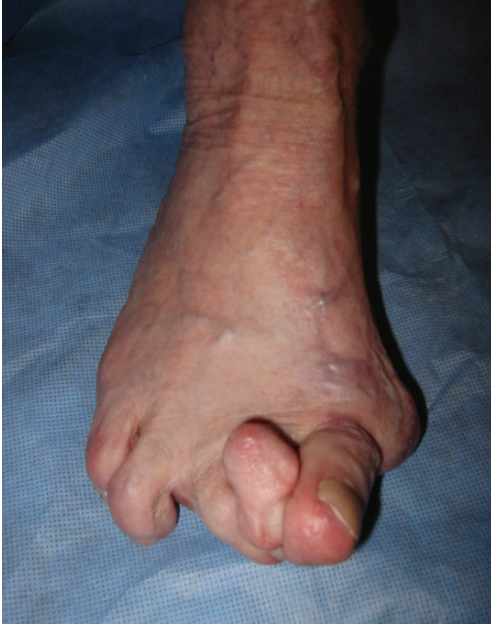

FIGURE 7.3. Pronation of the big toe.

#### Other associated features

Great toe pronation: The medial side of toenail is closer to the floor (Figure 7.3).

Medial bunion: this may be inflamed and is often painful

Clawing of second toe (crossover toe) (Figure 7.3).

#### **Hallux Varus**

Big toe deviates toward the midline. Deformity usually occurs at the 1st metatarsophalangeal joint.

#### Causes

Traumatic

Iatrogenic

Complication of hallux valgus operations

Complication of lateral sesamoidectomy

## Lesser Toes

### Hammer Toe

Flexion of proximal interphalangeal joint (Figure 7.4). The position of the distal interphalangeal joint is irrelevant and it may be straight, flexed or hyperextended. Callus usually found on dorsal PIP joint (Figure 7.5).

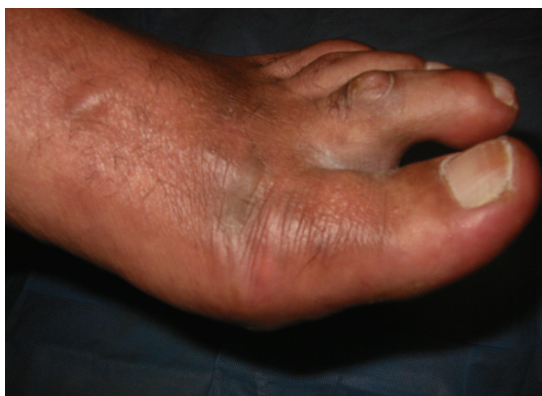

FIGURE 7.4. Hammer toe.

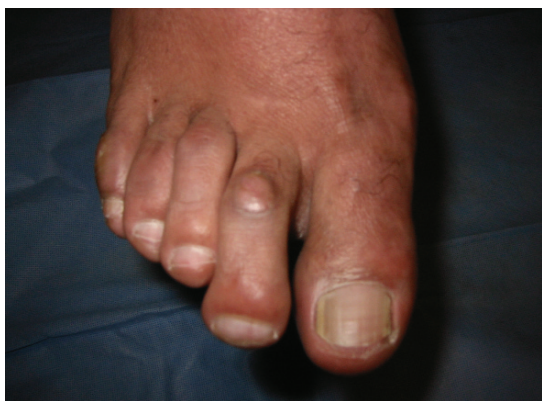

FIGURE 7.5. Callus formation on the dorsum of PIP joint of the second toe.



### Causes

- Footwear (most common)
- Inflammatory arthritis
- Neuromuscular diseases (Charcot-Marie-Tooth disease, Friedreich's ataxia, cerebral palsy, myelodysplasia, multiple sclerosis, and degenerative disc disease)
- Foot compartment syndrome
- Idiopathic

### Mallet Toes

Flexion deformity of distal interphalangeal joint (Figure 7.6). Corn or callus may be seen on the tip of the toe or dorsal DIP joint.

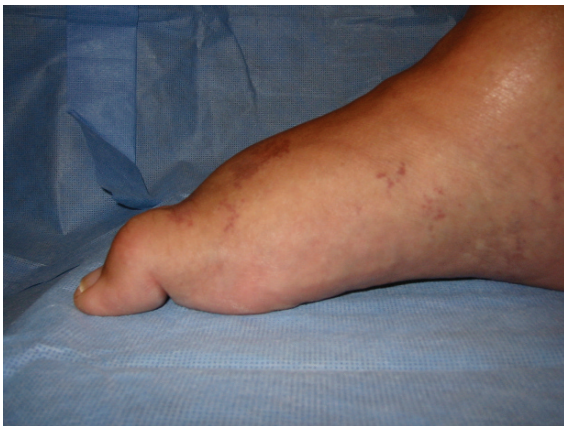
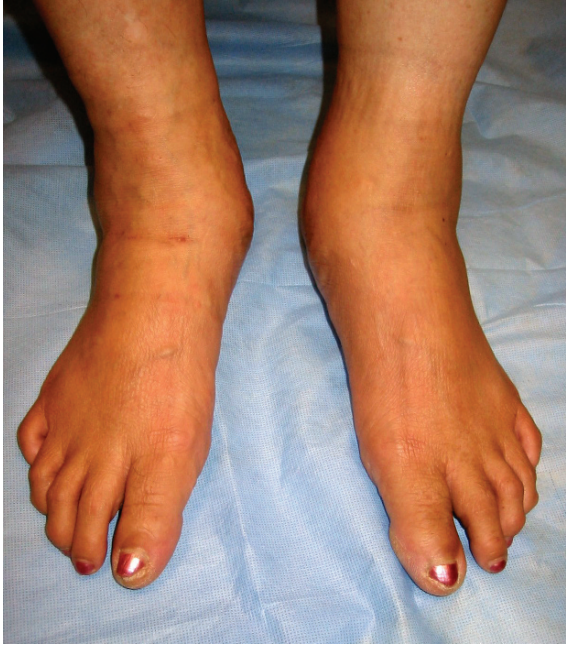
FIGURE 7.6. Mallet toe. Also note the low medial longitudinal arch.  
(a) Mallet toes.



a

FIGURE 7.6. Cont'd.

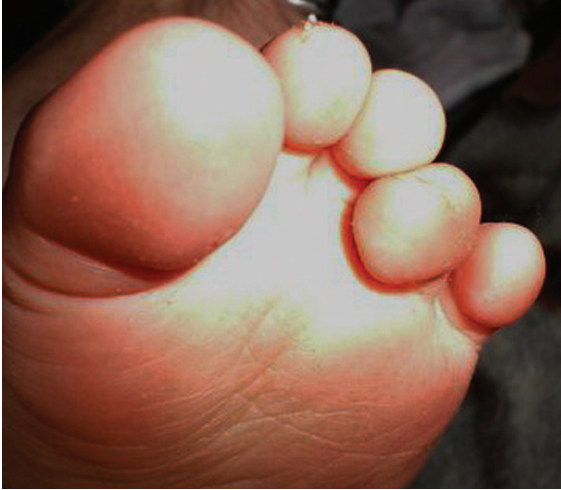

FIGURE 7.7. Curly 4th toe.

#### **Causes**

Footwear

Idiopathic

In children, mallet toe is secondary to a tight flexor (curly toe Figure 7.7)

#### **Claw Toes**

Hyperextension of metatarsophalangeal joint and flexion of proximal and distal interphalangeal joints.

Usually multiple toes in both feet, can be rigid or flexible with callus formation on dorsal PIP joint.

#### **Causes**

Muscle imbalance between the intrinsics and extrinsics  
(Weakness or paralysis of interossei and lumbrical muscles)

Metabolic diseases (diabetes most common)

Neuromuscular diseases

Associated with pes cavus

Idiopathic

**View the Ankle and Foot from Side**

Normally the ankle should be at a right angle with the tibia. The weight distribution is usually between the calcanium, the 1st and the 5th metatarsal.

**Pes Cavus**

Pes cavus is a condition in which the medial longitudinal arch is unduly high (Figure 7.8).

Causes:

- Neuromuscular
- Muscular dystrophy
- Charcot-Marie-Tooth disease
- Polyneuritis
- Spinal tumor
- Congenital
  - Arthrogryposis
  - Residual club foot
- Idiopathic
  - Trauma
  - Crush injury
  - Residual compartment syndrome
  - Malunion of fractures of the foot

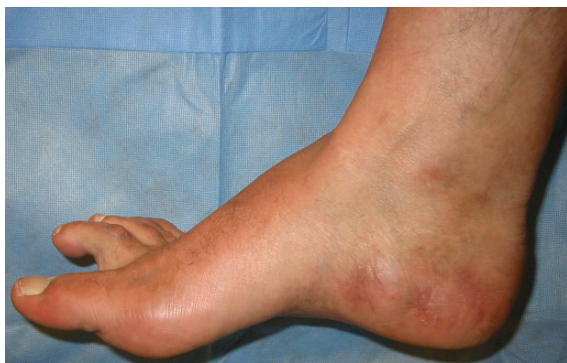

FIGURE 7.8. Pes cavus

### **Pes Planus**

Pes planus or flat foot is a condition in which the medial longitudinal arch is depressed or collapsed (Figure 7.6).

#### **Causes**

##### **Congenital**

- Flexible → tendoachilles tightness
- Rigid → tarsal coalition
- Vertical talus (rocker bottom foot)
- Arthrogryposis

##### **Acquired**

- Tibialis posterior dysfunction
- Rheumatoid arthritis
- Charcot's neuroarthropathy (Rocker bottom foot) (Figure 7.9)
- Trauma

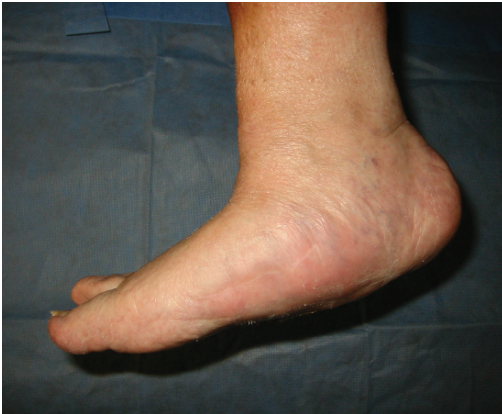

FIGURE 7.9. Rocker bottom foot.

**From Behind****Hindfoot Alignment**

Angle is formed by drawing a line bisecting the calf and another line bisecting the heel (Figure 7.10).

Normal angle  $\rightarrow$   $5^{\circ}$  to  $10^{\circ}$  of Valgus

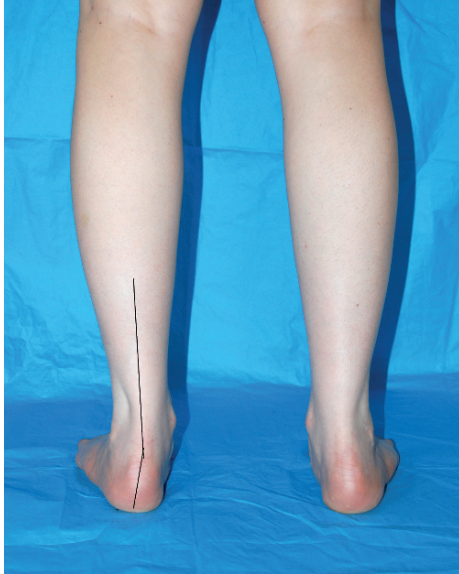

FIGURE 7.10. Hindfoot alignment.

Increased Valgus angle (Figure 7.11)

Advanced degenerative or rheumatoid arthritis

Posterior tibial tendon dysfunction

Ankle or pilon fracture malunion

Charcot's arthropathy

Valgus talar tilt secondary to failed deep deltoid ligament

Tarsal coalition

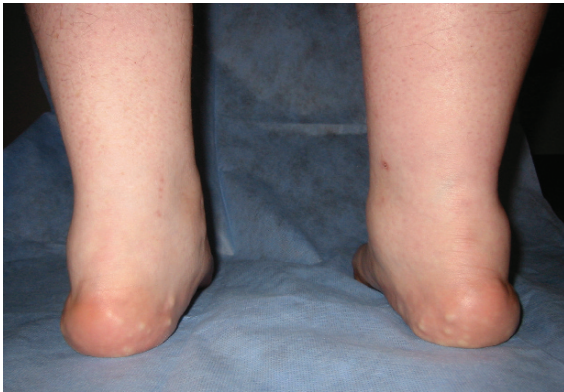
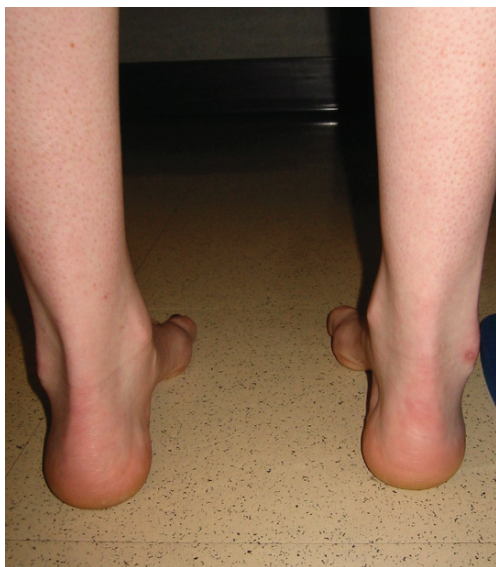
FIGURE 7.11. Valgus heels.

**Varus inclination (Figure 7.12)**

Idiopathic (most common)  
Malunited calcaneus/ankle fractures  
Clubfoot  
Neurological disorder  
Charcot-Marie-Tooth  
Poliomyelitis



**FIGURE 7.12.** Varus heel.



**“Too Many Toes” Sign**

Only one or two toes should be visible from behind. If more are seen it is said that the too many toes sign is present (Figure 7.13)

Causes

- Forefoot abduction secondary to
- Tibialis posterior dysfunction
- Lisfranc injury
- Charcot arthropathy of the midfoot

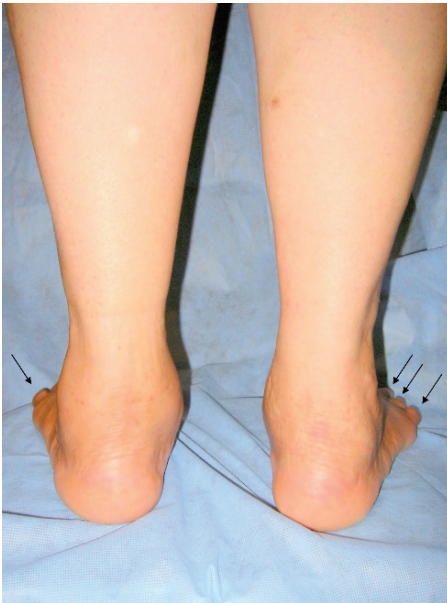

FIGURE 7.13. Too many toes are visible on the right.

Look at the sole

Callosities

Ulceration → diabetic foot (Figure 7.14a)

Neurological condition including Charcot's foot

Swellings (Figure 7.14b)

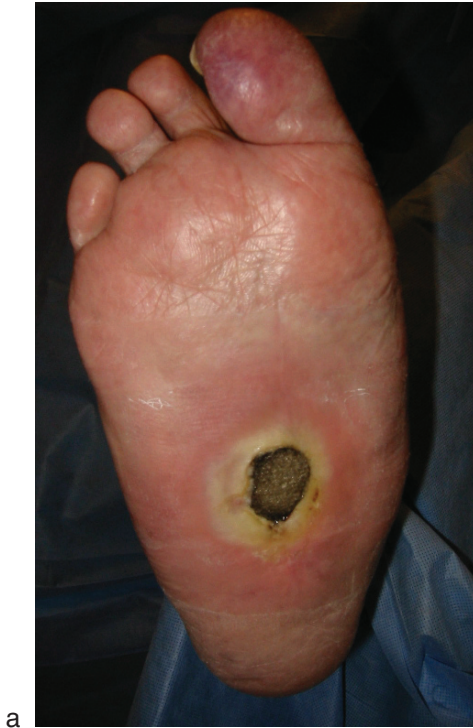

FIGURE 7.14. (a) Ulceration of the sole of the foot. (b) Unusually large rheumatoid nodule. (c) Psoriasis. Note the nail changes.

**Skin Condition** (Figure 7.14c)

Callosities

Corn

Color changes/ischemia

Loss of hair → neurological involvement

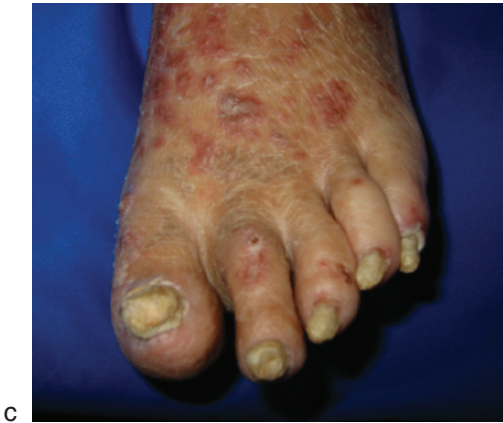
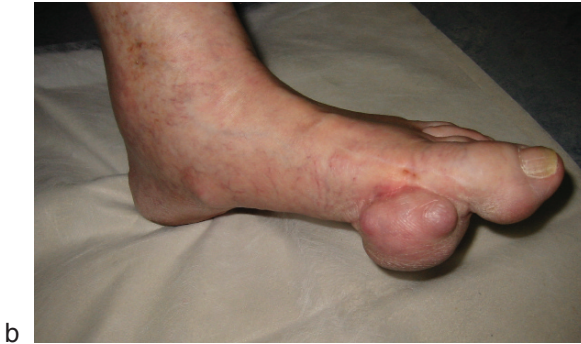
FIGURE 7.14. Cont'd.

**Scars**

Comment on

Position

Surgical or traumatic

Healed with primary or secondary intention

**Ankle swelling**

Generalized

Inflammatory arthropathies (including rheumatoid arthritis),  
osteoarthritis

osteochondral lesion

pigmented villonodular synovitis (PVNS) and other tumors

hemorrhagic

crystal-induced arthropathies (including gout)

Localized

Anterior aspect → tibialis anterior tendon pathology

Anterolateral aspect → anterior talofibular ligament injury

→ soft tissue tumor (including ganglion,  
lipoma)

All of the above are causes of generalized ankle swelling.

Lateral aspect → Fractures, including residual swelling from old  
injuries

→ lateral collateral ligament sprain

Medial aspect ankle → sprain of deltoid ligament

→ fractures, including residual swelling from  
old injuries

→ thrombophlebitis

→ posterior tibial tendon dysfunction

Posterior aspect → retrocalcaneal bursitis

Look at either side of Achilles tendon just proximal to its insertion.

When swelling is present, you see fullness on either side of the  
tendon (Achilles *tendinitis*).

In Achilles *tendinosis* nodule or fusiform enlargement of midsub-  
stance of tendon is seen which is usually associated with tendon  
degeneration.

**Posterolateral ankle**

Peroneal tendon pathology

Posterior impingement (os trigonum, posterior talus injury)

**Causes for Dorsal Foot Swelling**

Stress fracture  
Arthritic conditions  
Ganglion cyst  
Osteophytes  
Tumor

**Muscle Wasting of Legs/Size of the Foot**

Muscle wasting of legs is best seen from behind by comparing the girth of the calves. If different, measure around both sides 20 cm above the medial malleolus.

**Gait****Antalgic Gait (Best Viewed from the Side)**

If the ankle is the cause of the pain, the patient tends to reduce the time of weight bearing on the affected ankle. Hence the stance phase is quick on the painful ankle.

**Drop Foot, Slap Foot, or Stepping Gait**

Patient attempts to clear toes from catching on the ground. Also, patient unable to control plantar flexion resulting in foot “slapping” against the ground.

Cause

Weak or absent dorsiflexion  
Loss of proprioception

**Stiff Knee Gait (Best Viewed from the Side)**

The ankle is kept in a fixed angle during all the gait cycle. The affected limb swings outward and body shuffles during the swing phase.

Causes

Pain in the tibiofemoral articulation or patellofemoral joint  
Weak or paralyzed quadriceps (old poliomyelitis)

*Note: In severe weakness or paralyzes of quadriceps, a patient pushes the knee into hyperextension or recurvatum in order to prevent it from collapsing during stance phase.*

**Flexed Knee Gait (Best Viewed from the Side)**

The knee is kept in a certain degree of flexion during the gait cycle. Since the functional length of the limb is shorter in flexion, the affected limb can take shorter strides and, instead of heel first, the foot hits the ground flat. The gait has a characteristic up and down movement.

**Cause**

Flexion contracture of the knee

**FEEL**

Patient is seated on the edge of the examination table.

**Skin Temperature**

Run the back of your fingers from dorsum of the foot to mid calf. In this way an examiner can compare the temperature of normal skin and feel the rise of temperature if present.

Causes of rise in temperature:

- Septic arthritis
- Bursitis
- Crystal induced arthropathies
- Cellulitis
- Charcot arthropathy

**Anterior aspect**

Tibialis anterior tendon

Ask the patient to dorsiflex the ankle. Tibialis anterior can be seen and palpated at the level of ankle as it crosses the joint. It is the largest and most medial tendon at the joint level.

**Medial Cuneiform**

Trace the tibialis anterior tendon to its insertion at the base of the first metatarsal and first cuneiform.

**Extensor Hallucis Longus Tendon**

This is the next big tendon over the dorsum of the foot and at the level of the ankle joint. Ask the patient to extend the big toe, the tendon becomes prominent just lateral to the tibialis anterior tendon (Figure 7.15).

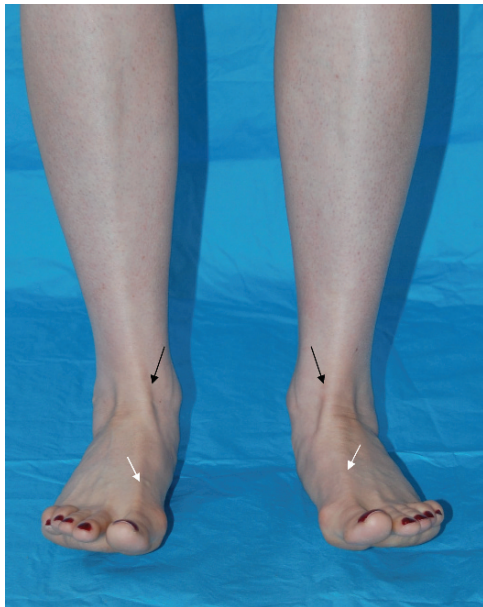


FIGURE 7.15. Tibialis anterior tendon (*black arrows*); Extensor hallucis longus tendon (*white arrows*).

**Dorsalis Pedis Artery**

This is a continuation of the anterior tibial artery which, after crossing the ankle joint, becomes the dorsalis pedis. To palpate, ask the patient to extend the big toe and observe the extensor hallucis tendon. It can be felt just lateral to the EHL and proximal to the prominence of the metatarsocuneiform joint (Figure 7.16).

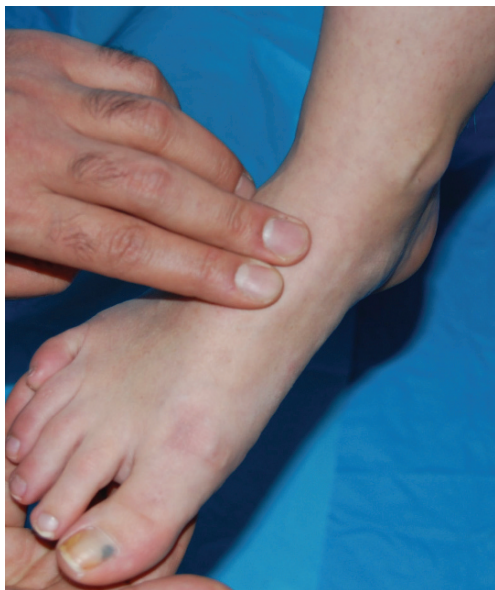

FIGURE 7.16. Palpation of dorsalis pedis artery.

**Extensor Digitorum Longus Tendon**

Ask the patient to dorsiflex the toes. It becomes prominent at the ankle joint lateral to the EHL tendon.

**Medial Side****Medial Malleolus**

It is the most prominent structure on the medial side of the ankle joint. Check for tenderness (fracture/nonunion) of the medial malleolus.



**Deltoid Ligament**

Broad structure attached to the tip of the medial malleolus, which runs inferiorly and both anteriorly and posteriorly. It is often difficult to define the edges but tenderness (especially upon eversion of the calcaneus) may be due to sprain/rupture of the ligament.

Within the depression between the medial malleolus and the Achilles tendon posteriorly lie the following structures: tibialis posterior tendon, flexor digitorum longus tendon, posterior tibial artery and nerve, and flexor hallucis longus tendon (the order can be remembered with the mnemonic: **T**all **D**octors **A**re **N**ever **H**ungry).

**Tibialis Posterior Tendon**

This is the largest tendon behind the medial malleolus. It becomes more prominent with plantar flexion and inversion of the foot (Figure 7.17).

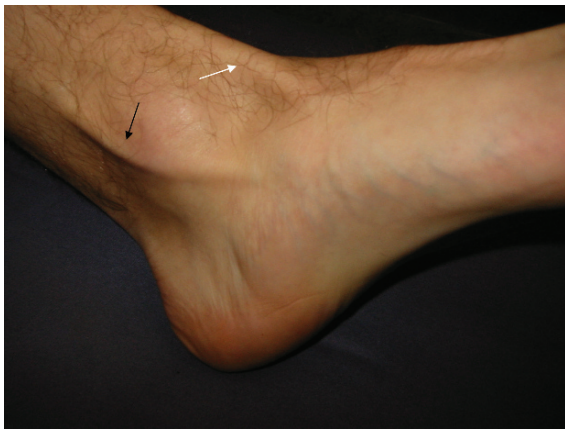

FIGURE 7.17. Tibialis posterior tendon (*black arrow*). Tibialis anterior tendon (*white arrow*) is also visible.

**Flexor Digitorum Longus Tendon**

This is the next tendon to the tibialis posterior tendon. It becomes more easily palpable when applying resistance to the toes which you have asked the patient to flex. Movement of the tendon is felt if either side of the Achilles tendon is held between the thumb and index finger.

*Note: In the case of synovitis of the tendons behind the medial malleolus, palpation may give a clue as to the origin of the pain. Apart from the tibialis posterior tendon, the other tendons are difficult to palpate.*

**Flexor Hallucis Longus**

This has the lowest-lying muscle belly of the extrinsics. Notice that when the foot is held dorsiflexed, the range of dorsiflexion of great toe diminishes as the FHL muscle belly is forced into the tendon sheath where it is vulnerable to tendinitis (Thomassen's sign).

**Posterior Tibial Artery**

The pulse can usually be palpated by gentle pressure roughly half way between the posterior border of the medial malleolus and the Achilles tendon while the foot is relaxed. It can be difficult to find at times, but persevere before you conclude it is not palpable. It is the main blood supply of the foot. Its absence usually indicates arterial insufficiency.

**Tibial Nerve**

This lies behind the posterior tibial artery and follows its course to the foot. It divides into a calcaneal branch and the medial and lateral plantar nerves. Although it can be difficult to palpate as an isolated structure, its course has clinical significance; if entrapped behind the flexor retinaculum direct pressure over the nerve just behind the medial malleolus is produced and direct percussion over the nerve (Tinel's test) may be positive.

**Tarsal Tunnel Syndrome**

Causes

- Swelling and inflammation
- Ankle deformities
- Severe pes planus
- Valgus deformity of the heel
- Mass effect: lipoma, ganglion cyst, Varicosities

**Sustentaculum Tali**

This can be palpated one finger breath plantarward from the distal end of the medial malleolus. Spring ligament attaches to the Sustentaculum tali.

**Lateral Plantar Nerve**

Entrapment of the first branch of the LPN between the deep fascia of the abductor hallucis and quadratus plantae may lead to chronic heel pain on the medial side (Baxter's nerve syndrome). Pain can be elicited in the entrapped nerve by palpating about 2.5 cm below the medial malleolus over the proximal aspect of the abductor hallucis muscle belly (Figure 7.18).

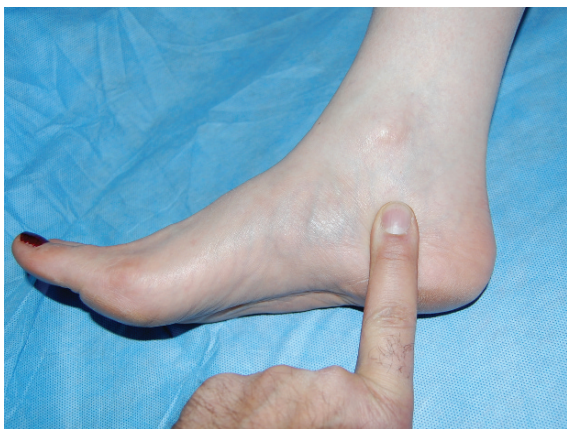

FIGURE 7.18. Site of entrapment of lateral plantar nerve.

**Medial Head of Talus**

This can be easily palpated 1 cm distal to the anterior edge of the medial malleolus in line with the first metatarsal. Abduction and adduction of the forefoot make the gap between the talus and navicular palpable.

**Medial Navicular Tubercle**

This is distal to the head of the talus if palpated from proximal to distal. Abduction and adduction of the forefoot make the gap between the talus and navicular palpable.

### **Medial Plantar Nerve**

Can be entrapped at master knot of Henry (where the flexor hallucis longus and flexor digitorum longus tendons cross over) giving rise to pain on the medial side of the arch (jogger's foot). Pain can be elicited from the entrapped nerve by palpating the region of Henry's knot (plantar to the 1st TMT joint) (Figure 7.19).

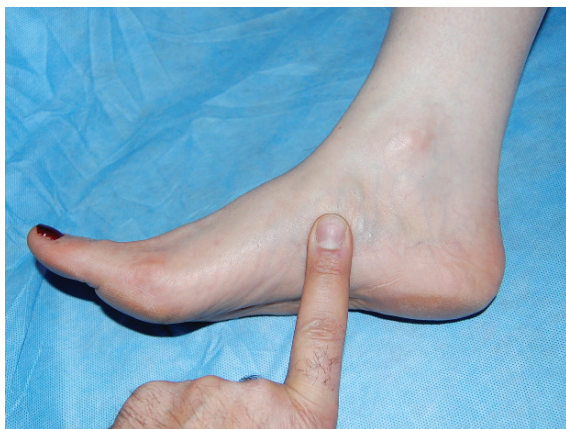

FIGURE 7.19. Site of entrapment of medial plantar nerve.

### **Head of the First Metatarsal**

This forms the ball of the foot. It articulates distally with the phalanx of the great toe to form the metatarsophalangeal joint. It is often painful in gout and bunions.

If the 1st metatarsal is traced proximally, the metatarsocuneiform (or 1st tarsometatarsal) joint can be palpated. Forward and backward movement of the joint makes palpation easier

### **Lateral Side**

#### **Lateral Malleolus**

This forms the distal end of the fibula, and extends distal and lies posterior to the medial malleolus

#### **Anterolateral Dome of Talus**

Place your thumb over the anterior part of the lateral malleolus and then plantar flex the foot. You can feel the anterolateral portion of the talus move under your thumb.

**Sinus Tarsi**

Sinus tarsi is the space between the lateral talus and the calcaneus. It is situated one finger breath anterior to the tip of the lateral malleolus. Contraction of the extensor digitorum brevis can be felt if the patient extends his toes.

**Anterior Inferior Tibiofibular Ligament**

Run your finger about 1 cm above and medial to the lateral malleolus at the level of the ankle joint. The ligament cannot be felt as a distinct structure but it is often tender with injuries to the tibiofibular syndesmosis.

**Anterior Talofibular Ligament**

The ligament cannot be felt distinctly but tenderness is often elicited over the sinus tarsi, especially upon inversion of the foot.

**Calcaneofibular Ligament**

This runs from the tip of the lateral malleolus posteriorly to the lateral wall of the calcaneus. Again, it is not palpated as a distinct structure easily but it becomes tender in severe ankle sprain after rupture of the anterior talofibular ligament.

**Posterior Talofibular Ligament**

This is attached to the posterior edge of the lateral malleolus and passes posteriorly to the lateral tubercle on the posterior edge of the talus. Again, this ligament cannot be felt distinctly but tenderness especially upon inversion is due to the sprain or rupture.

**Peroneus Longus and Brevis Tendons**

These pass behind the lateral malleolus, the brevis tendon being closer to the bone. Peroneus longus passes plantar to the cuboid in the cuboid tunnel (where an os peroneal may be present) to insert in the plantar base of the first metatarsal. Peroneus brevis inserts into the base of the 5th metatarsal. Both tendons become more prominent upon resisted eversion of the foot. The tendons can dislocate anteriorly, which is palpable and, at times, audible.

**5th Metatarsal Base and Head**

Palpate the base of 5th metatarsal for tenderness. Trace the shaft of the 5th metatarsal distally. Inflammation of the bursa overlying the lateral aspect of the 5th metatarsal is called tailor's bunion.

## **Sole of the Foot**

### **Sesamoid Bones**

Passively dorsiflex the big toe and press firmly on the first metatarsal. Sesamoid bones may not be felt distinctly, however tenderness may be evident.

Causes of tenderness

- Fracture
- Sesamoiditis
- Arthritis

### **Metatarsal Heads**

Place your thumb over the plantar surface and your index finger over the dorsum of the metatarsal head. Movement of the each toe makes the palpation of the joint easier.

Causes of tenderness

- Sinovitis → instability
- Inflammatory conditions
- Dorsal subluxation/dislocation
- Freiberg's disease → tenderness of the second metatarsal head is most common

## **Morton's Neuroma**

Pain from Morton's neuroma is in the **plantar forefoot**. The neuroma is most commonly located between the 3rd and 4th metatarsal heads (80% to 90%) or 2nd and 3rd metatarsal heads. The pain is often worsened by footwear and relieved by removing the shoe. Other symptoms include numbness or paresthesia in the toe(s) and the sensation that the patient is walking on a pebble or crumpled sock. Tenderness to compression (Mulder's sign) in the second or third web space can be due to a painful neuroma.

### **Plantar Fascia**

Feel the plantar fascia, which is a tough structure extending from metatarsal heads to the calcaneal tuberosity. Dorsiflexion of the big toe makes the medial band of the fascia taut and easier to palpate. Pain at its insertion to the calcaneal tuberosity can be associated with plantar fasciitis.

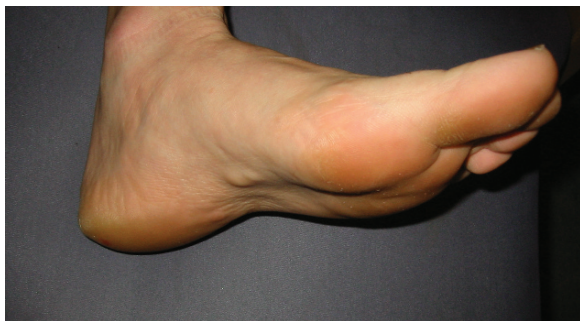

FIGURE 7.20. Nodules over the plantar fascia.

Nodule on the sole of the foot may be due to benign fibromatosis (Figure 7.20)

### **Heel**

The Achilles' tendon inserts to the posterior tuberosity of the calcaneus.

#### **Subcutaneous (Pre-Achilles) Bursa**

This lies between overlying skin and the insertion of the Achilles tendon. Pinch and lift the skin at the insertion and the bursa is between your fingers. Inflammation of this bursa is one of the causes of pain in this area.

#### **Retrocalcaneal Bursa**

The retrocalcaneal bursa is situated between the posterior tuberosity of the calcaneus and the anterior surface of the Achilles tendon. Tenderness over the insertion as well as on both sides of the Achilles tendon may be due to bursitis.

If pain is elicited only at the insertion, insertional tendinosis of the Achilles tendon may be the cause. Note: often tendinosis and bursitis coexist.

**Haglund's Deformity**

This is a prominence over the dorsoposterior calcaneal tuberosity (Figure 7.21) that can lead to retrocalcaneal bursitis with rubbing against the heel counter of a shoe.

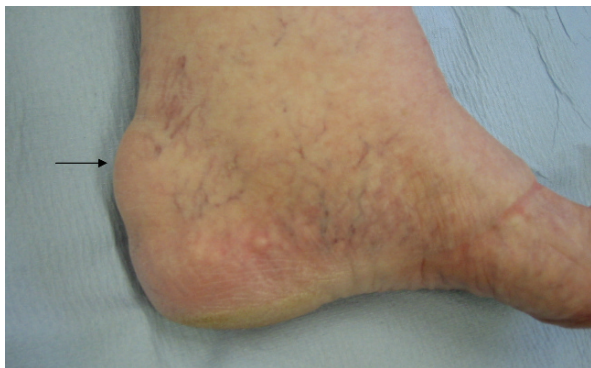


FIGURE 7.21. Haglund's deformity.



**Range of Movement**

With the patient standing facing you, ask him to stand on tiptoes (Figure 7.22), on the heel (Figure 7.23), on the outer (Figure 7.24), and then on the inner border of the foot (Figure 7.25) and compare the range of movement with the other side. This is active range of movement.

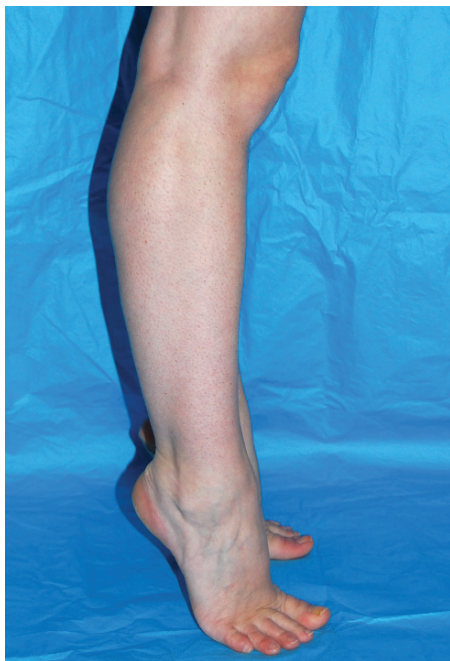

FIGURE 7.22. Active plantarflexion.

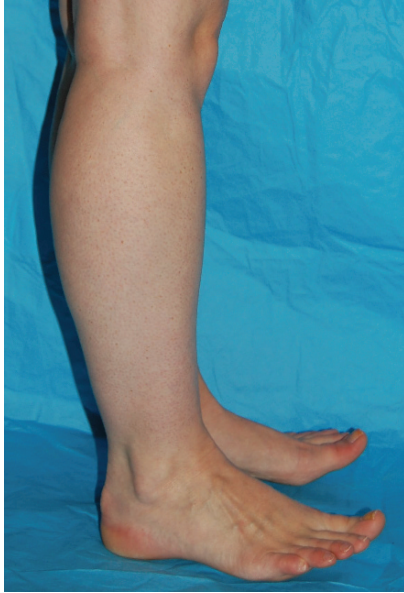


FIGURE 7.23. Active dorsiflexion.

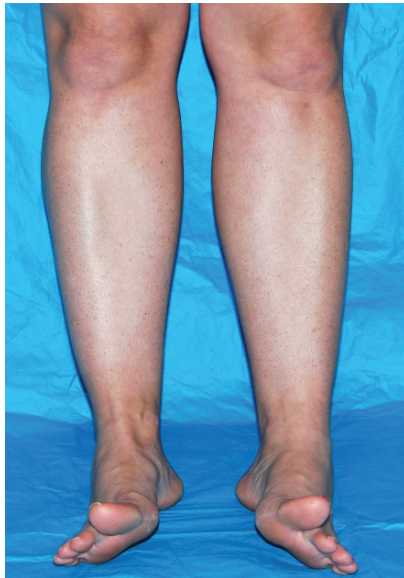


FIGURE 7.24. Active inversion.

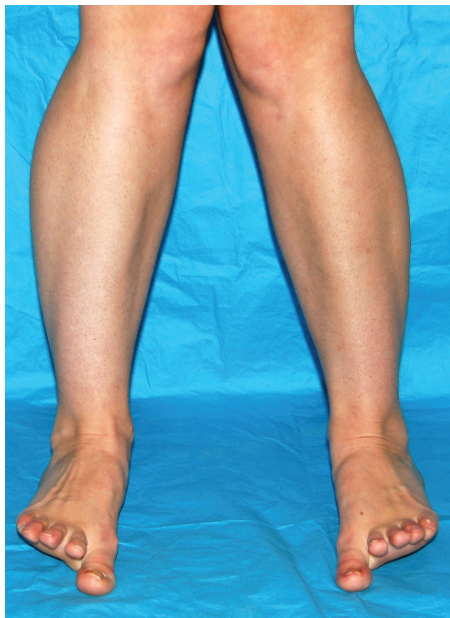

FIGURE 7.25. Active eversion.

With the patient sitting on the examination table, check the passive range of movement:

Dorsiflexion and plantar flexion occur at the ankle joint primarily and the subtalar joint secondarily.

Inversion and eversion occur at the subtalar joint, talonavicular joint, and calcaneocuboid joint.

Abduction and adduction occur at the transverse-tarsal joints (Talonavicular and calcaneocuboid).

### Dorsiflexion

Hold the heel in the neutral position and the forefoot in inversion and dorsiflex the foot to the maximum degree (Figure 7.26)

Normal dorsiflexion:  $20^{\circ}$

Causes of reduction of dorsiflexion

Contracture of posterior structures:

Gastrocnemius

Soleus

Impingement

Osteophytes over the anterior rim of the tibia/ neck of talus

Inflamed synovium or other soft tissue

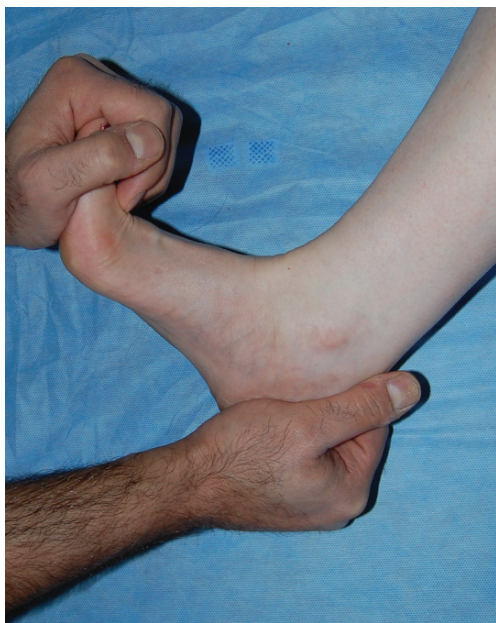

FIGURE 7.26. Passive dorsiflexion.

Injury to tibiofibular syndesmosis  
Prolonged immobilization in equinus  
Ankle sprain/fracture

Note: To differentiate between contractures of the gastrocnemius and soleus, repeat dorsiflexion of the ankle with the knee in full extension and with the knee in 90° of flexion.

With gastrocnemius contractures → more dorsiflexion of the ankle is possible with the knee in flexion

With soleus contractures → the position of the knee does not affect the amount of dorsiflexion

### **Plantar Flexion**

Hold the heel in the neutral position and the forefoot in inversion and plantar flex the foot to the maximum degree (Figure 7.27).

Normal plantar flexion is 50°.

Causes of reduced plantarflexion

Contracture of the anterior capsule  
Following ankle fracture/trauma  
Posterior impingement  
Ankle instability  
os trigonum

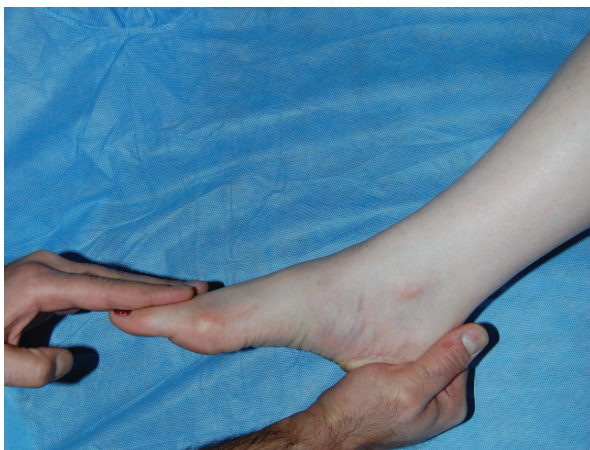

FIGURE 7.27. Passive plantarflexion.

**Abduction and Adduction of Forefoot**

Hold the midfoot with one hand and move the forefoot medially and laterally (Figures 7.28 and 7.29). 5° of movement in each direction is normal.

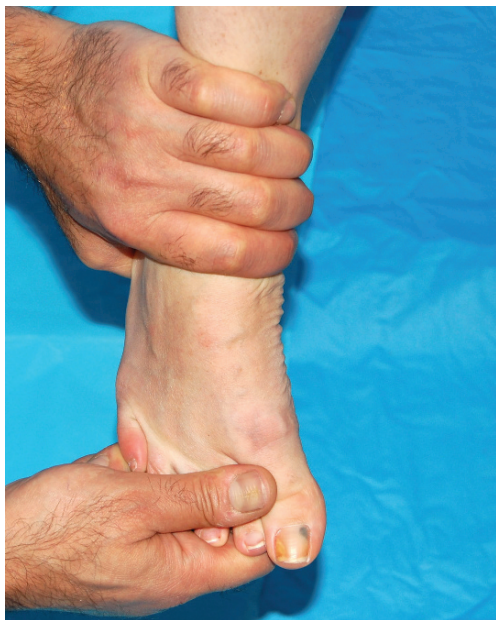

FIGURE 7.28. Adduction of the forefoot.

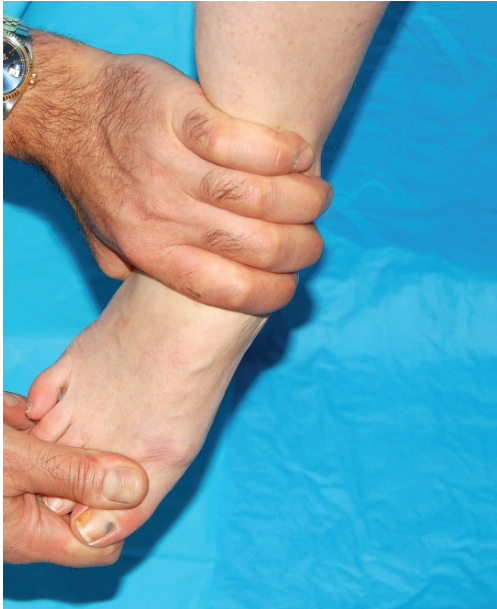

FIGURE 7.29. Abduction of the forefoot.



**Great toe**

Metatarsophalangeal joint: The examiner holds the foot with one hand and with the other hand passively dorsiflex and plantar flexes the big toe (Figures 7.30 and 7.31).

Normal range:

Dorsiflexion 70°

Plantarflexion 40°

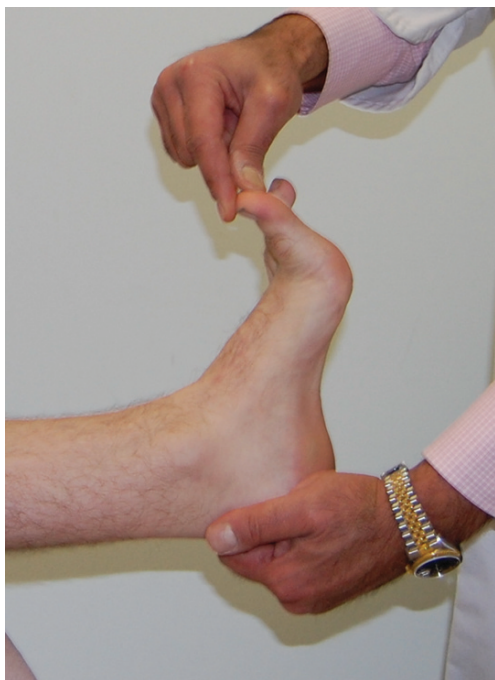

FIGURE 7.30. Dorsiflexion of the big toe.



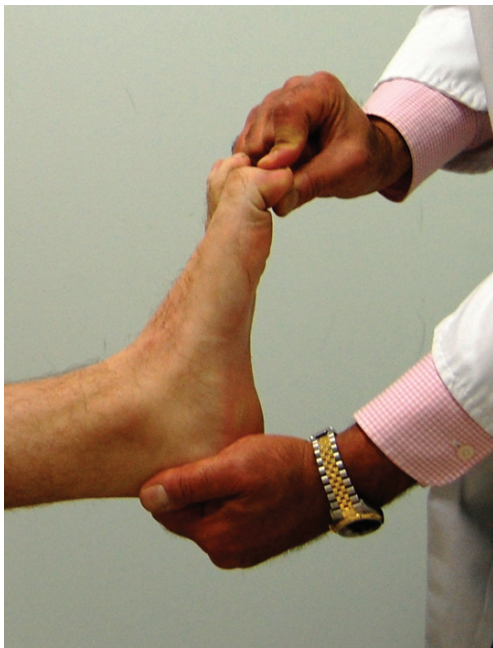

FIGURE 7.31. Plantarflexion of the big toe.

### **Hallux Rigidus**

Degenerative arthritis of the 1st MTP joint usually produces a dorsal and/or lateral osteophytes which limits the movements. Hallux limitus implies loss of motion of the 1st MTP joint without arthritic change.

### **Interphalangeal Joint**

The examiner holds the proximal phalanx of the big toe with one hand and then move the distal phalanx with the other hand.

Normal range:

Dorsiflexion 0° (to neutral)

Plantarflexion 90°

**Lesser Toes**

The range of movement is measured in the similar way used in the big toe.

Normal range:

	Dorsiflexion	Plantar flexion
MTPJ	40°	40°
PIPJ	0°	30°
DIPJ	30°	60°

**Muscle Testing: Quick Functional Tests**

Ask patients to walk on their:

Heels → dorsiflexor: tibialis anterior muscle

Tip toes → plantar flexors: gastrocnemius and soleus complex

Lateral border → foot invertors: tibialis posterior

Medial border → foot evertors: peronei

**Individual muscle testing**

Ankle dorsiflexors

Tibialis anterior

Extensor Hallucis Longus

Extensor Digitorum Longus

With the patient is in a sitting position

**Tibialis anterior (Deep peroneal nerve L4)**

Hold the heel. Put the foot in inversion and dorsiflexion and ask the patient to maintain this position. Then try to evert and plantar flex the foot by applying pressure over the first metatarsal head and shaft (Figure 7.32). If the muscle is profoundly weak, you must feel for muscle contracture.

**Causes of weakness**

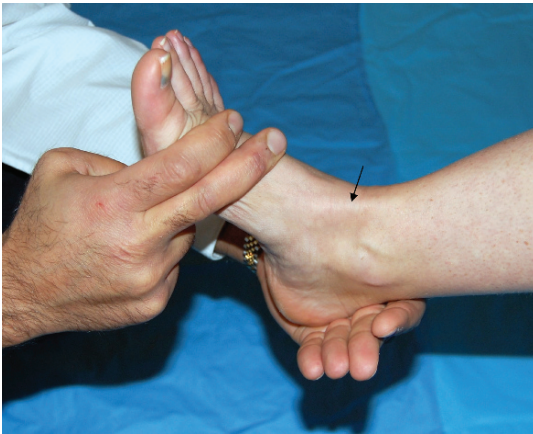Lumbar radiculopathy (L4)

Poliomyelitis

Common peroneal nerve palsy

Deep peroneal nerve palsy

Laceration of the tendon



**FIGURE 7.32.** Tibialis anterior. The tendon is visible at the ankle joint (arrow).

### Extensor Hallucis Longus (Deep peroneal nerve L5)

Hold the heel. Ask the patient to dorsiflex the big toe and maintain this position while the examiner applies opposite force by placing a finger on the nail and trying to plantar flex the big toe (Figure 7.33)

To assess the extensor hallucis brevis as well as EHL, place your finger proximal to the interphalangeal joint and apply opposing force to extension (Figure 7.34).

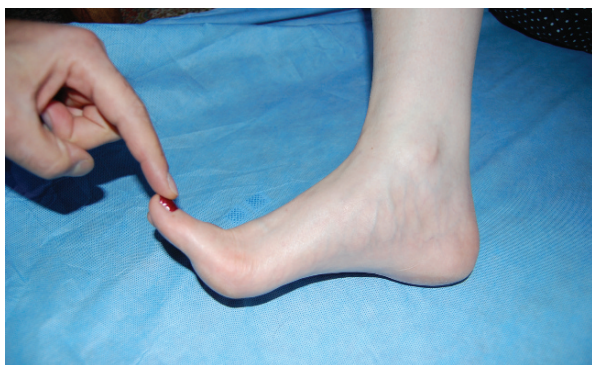

FIGURE 7.33. Assessment of Extensor hallucis longus.

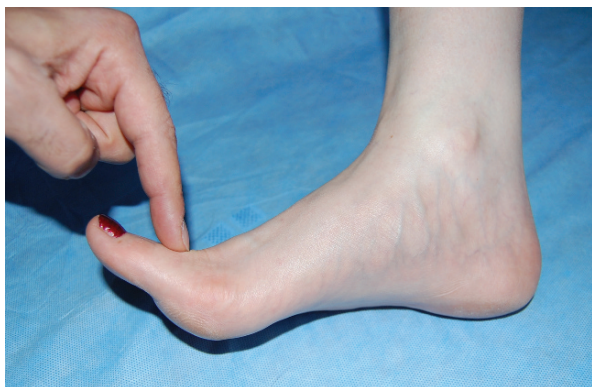

FIGURE 7.34. Assessment extensor hallucis brevis and EHL.

### Causes of weakness

- Lumbar radiculopathy (L5)
- Common peroneal nerve palsy
- Deep peroneal nerve palsy
- Laceration of the tendon
- Poliomyelitis

### Extensor digitorum longus (Deep peroneal nerve L5)

Hold the heel. Ask the patient to dorsiflex the toe and maintain this position while the examiner applies opposite force by placing his fingers on the toes and trying to plantar flex them (Figure 7.35). The contracture of Extensor Digitorum Brevis, which is active along with the EDL, can be felt in the sinus tarsi.

### Causes of weakness

- Lumbar radiculopathy (L5)
- Common peroneal nerve palsy
- Deep peroneal nerve palsy
- Laceration of the tendon
- Poliomyelitis

### **Plantar flexors**

- Gastrocnemius complex
- Flexor hallucis longus
- Flexor digitorum longus

### Gastrocnemius complex (tibial nerve S1)

Hold the heel. Ask the patient to plantar flex the ankle and maintain this position while the examiner applies opposite force to the metatarsal heads and tries to dorsiflex the ankle.

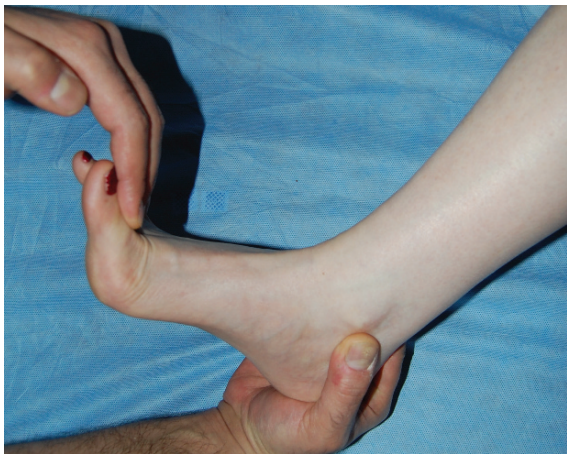

FIGURE 7.35. Assessment of extensor digitorum longus.

### Causes of weakness

Lumbar radiculopathy (S1)

Sciatic nerve palsy

Tibial nerve injury

Flexor hallucis longus (tibial nerve L4 through S3) and flexor digitorum longus (tibial nerve L4 through S3)

These two muscles are tested together; due to tendinous cross-connections.

Hold the heel. Ask the patient to curl up the toes and maintain this position while the examiner tries to dorsiflex the toes with his fingers.

### Causes of weakness

Lumbar radiculopathy (S1)

Sciatic nerve palsy

Tibial nerve injury

### **Invertors of the foot**

Tibialis posterior

Tibialis anterior

Flexor digitorum longus

Flexor hallucis longus

Tibialis posterior (Tibial nerve L5)

Hold the heel. Ask the patient to plantar flex and invert the foot as much as possible and maintain this position. Apply eversion force to the medial side of the first metatarsal (Figure 7.36). With the thumb of the other hand, the tendon should be palpated behind the medial malleolus.

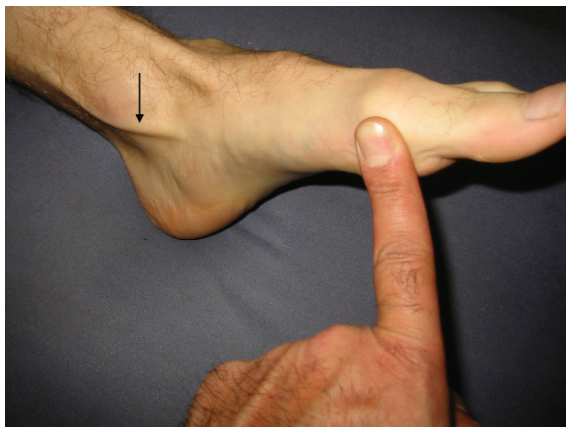


FIGURE 7.36. Tibialis posterior tendon (arrow).

Alternatively, stand behind the patient and ask him to stand on tip toes (offer support to maintain the balance) and observe the calcaneus. With normal tibialis posterior function and subtalar joint, the calcaneus should invert as the patient stands on his tiptoes (Figures 7.37 and 7.38).

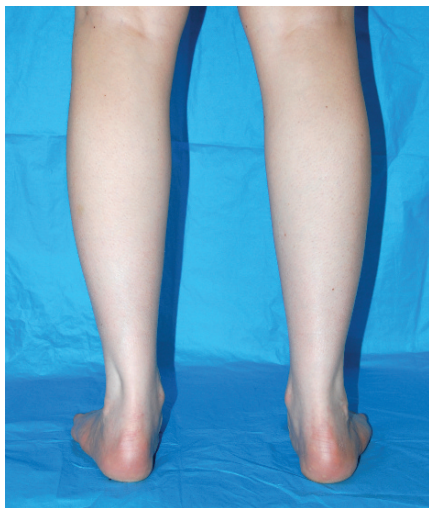


FIGURE 7.37. Assessment of tibialis posterior tendon. See text.

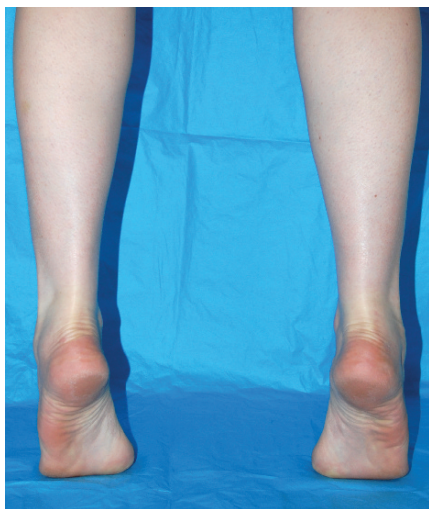

FIGURE 7.38. Assessment of tibialis posterior. See text.



### Causes of weakness

- Tendinitis

- Rupture

The other muscles have been already covered in this chapter.

### **Evertors of the Foot**

Peroneus brevis (superficial peroneal nerve S1) and peroneus Longus (superficial peroneal nerve S1)

These two muscles are tested together.

Hold the heel. Ask the patient to plantar flex and evert the foot as much as possible and maintain this position. Apply inversion force to the base and lateral border of the 5<sup>th</sup> metatarsal (Figure 7.39). With the thumb of the other hand, the tendon should be palpated behind the lateral malleolus.

Caused of weakness

- Lumbar radiculopathy L5

- Injury to superficial peroneal nerve

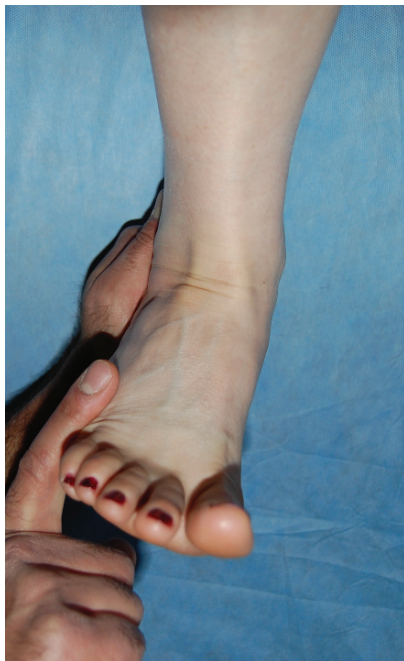

FIGURE 7.39. Assessment of peroneus longus and peroneus brevis.



### Muscle Wasting

Check the leg circumference. In the supine position, mark a point 25 cm above the medial malleolus on both legs and measure the circumference of the legs at this point with a measuring tape.

### Sensation

The sensory distribution of the foot and ankle and lower leg should be tested.

**L4 dermatome:** Medial side of the foot, medial malleolus and medial side of the leg and medial side of the knee

**L5 dermatome:** dorsum of the foot, lateral side of the leg

**S1 dermatome:** Lateral side of the foot and lateral malleolus

The peripheral distributions are as follows (Figure 7.40):

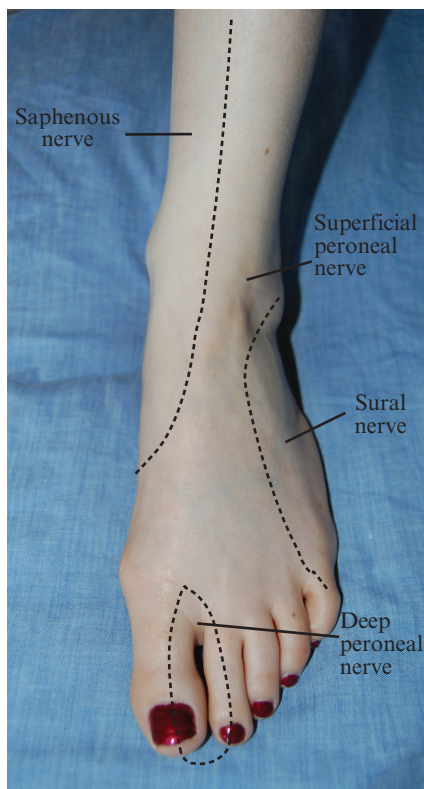


FIGURE 7.40. Sensory distribution of the foot.

**Saphenous nerve:** medial side of the foot, medial malleolus and medial side of the leg and medial side of the knee

**Superficial peroneal nerve:** dorsum of the foot (Except the first web space, which is supplied by the deep peroneal nerve)

**Sural nerve:** lateral side of the foot and lateral malleolus

## Reflexes

### Achilles Tendon Reflex (S1)

Dorsiflex the ankle passively and then tap the tendon gently with the neurological hammer. Sudden involuntary plantar flexion of the foot is taken as positive.

Another method is to dorsiflex the ankle with your fingers placed on the metatarsal region on the sole of the patient's foot. Then tap with your own finger (Figure 7.41). It induces the same response with a normal tendon reflex.

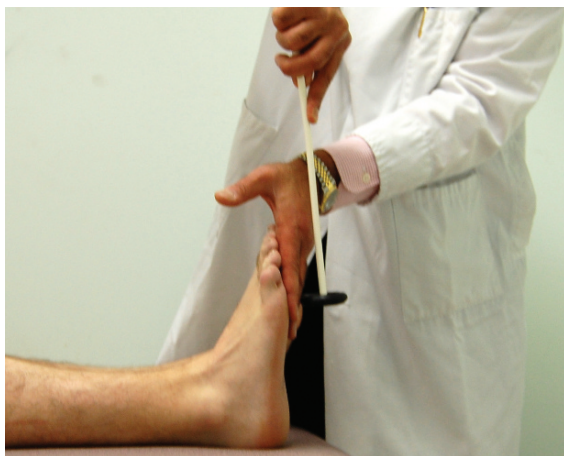

FIGURE 7.41. Ankle reflex.

## Special Tests

### Anterior Drawer Test

Patient sitting on the edge of the table with the foot relaxed. Hold the heel while the other hand stabilizes the leg just above the ankle joint. Dorsiflex and planter flex the ankle to make sure the ankle joint is relaxed. Then pull the heel forward and feel the amount of translation (Figure 7.42). If the difference between anterior translation of the normal and the injured side is more than 5 mm, the anterior talofibular ligament is likely to be injured.

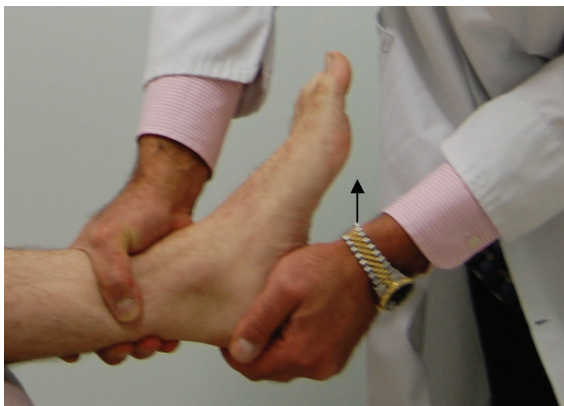


FIGURE 7.42. Anterior drawer test. *Arrow* shows the direction of force.

**Jack Test**

This is a test to differentiate between a flexible and rigid flat foot.

While the patient is standing, note the medial arch. Dorsiflex the big toe (Figure 7.43) and note if there is any difference in the height of the medial arch:

In flexible flatfoot, dorsiflexion of the big toe results in reconstitution of the medial arch.

In rigid flat foot dorsiflexion of the big toe does not have any effect on the height of medial arch.

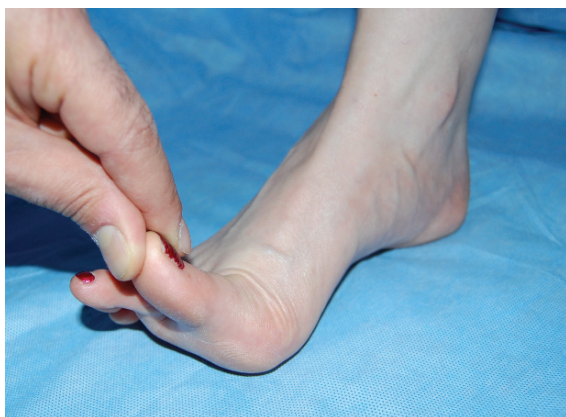

FIGURE 7.43. Jack test.

**Thompson's Test**

This is a test to confirm the diagnosis of Achilles tendon rupture.

Patient in prone position with the feet off the end of the table or kneeling on a chair with the feet off the end of the chair (Figure 7.44). Then squeeze the calf on the normal side and note the amount of plantar flexion. The absence of plantar flexion on the injured side indicates a rupture of the Achilles tendon. A palpable gap is often felt about 5 cm above the insertion of the Achilles tendon.

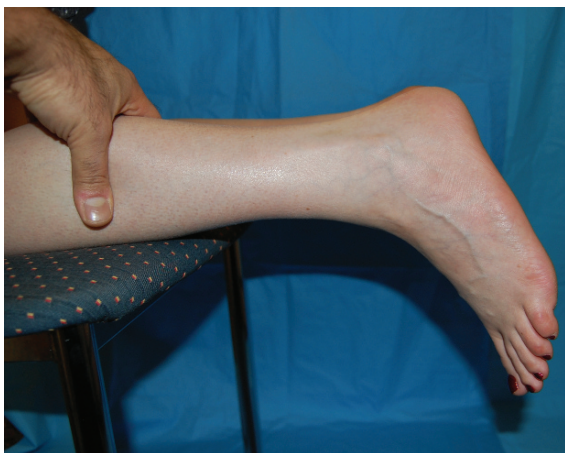

FIGURE 7.44. Thompson's test.

**Drawer Test of Lesser MTP Joints**

This test is performed to examine for instability of the lesser MTP joints; an often-overlooked cause of forefoot pain. Place the thumb and index finger, dorsal and plantar respectively, over the metatarsal neck. Then grip the proximal phalanx in similar fashion with the opposite hand. Translate the proximal phalanx dorsally, while stabilizing the metatarsal with the other hand. Comparisons with other MTP joints on the same and opposite foot are helpful. Pain associated with laxity that reproduces the patient's symptoms is likely to be secondary to instability.

**Squeeze Test**

A test for distal ankle syndesmosis injury. Squeeze the tibia and the fibula together at the midshaft. If pain is reproduced at the level of the distal ankle syndesmosis, then injury is suspected

**External Rotation Test**

A test for distal ankle syndesmosis injury. The examiner stabilizes the leg with the knee flexed at 90 degrees, while externally rotating the foot. If pain is reproduced at the level of the distal ankle syndesmosis, then injury is suspected. It is found to have the highest inter-rater correlation.

**Mulder's Sign**

This is a test for painful Morton's neuroma. Grasp the forefoot just behind the head of the 1st and 5th metatarsals and place the index finger and thumb of the opposite hand dorsal and plantar to the web space respectively (as if to pinch it) Then, compress the forefoot with modest force (Figures 7.45 and 7.46). A palpable and, at times, an audible "click" may be elicited (Mulder's "click").

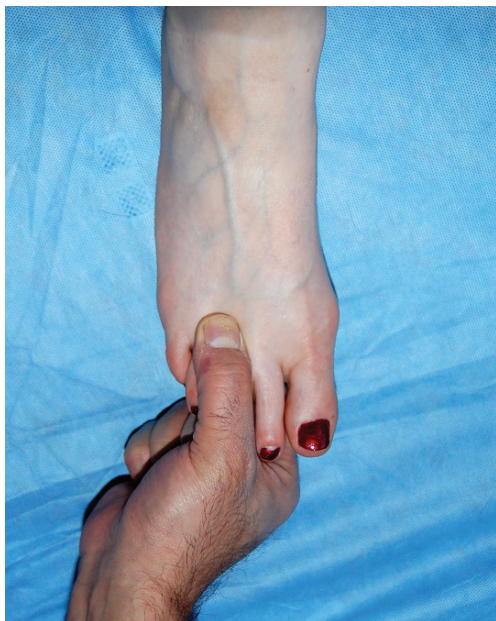

FIGURE 7.45. Mulder's sign. First step.

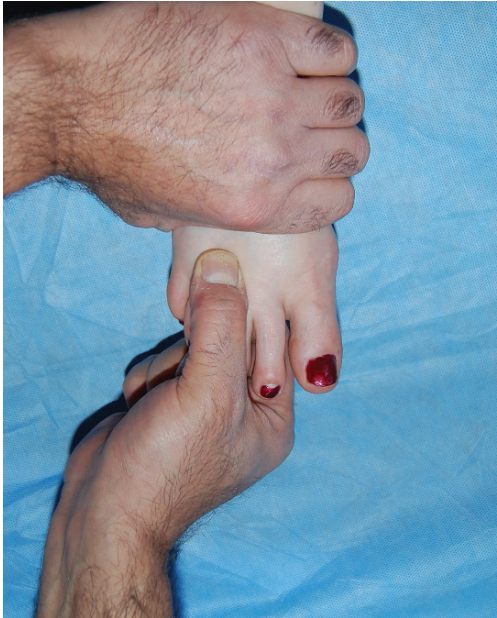

FIGURE 7.46. Mulder's sign. Final step.

# Index

---

## A

Abdominal reflex, 156

Abdominal wall, T9-12 and,  
135, 153

### Abduction

external rotation in, 15

of forefoot, 295–296

of hip, 204–205

internal rotation in, 17

in shoulder, 13–14

of thumb, 105

Abductor digiti minimi, 115

hypotenar eminence and,  
117

muscle insertion for, 122

T1 and, 152

Abductor pollicis, 115, 118

muscle insertion for, 122

Abductor pollicis brevis (APB),

105, 111

Abductor pollicis longus

(APL), 97, 102

muscle insertion for, 105

Abductor tendinitis, groin

pain and, 189

Acetabular labrum, 190

Achilles' tendon, 288

reflex, 307

S1 and, 181

tendinitis in, 277

ACJ. *See* Acromioclavicular  
joint

ACL. *See* Anterior cruciate  
ligament

Acromioclavicular joint (ACJ),  
10

arthritis of, 1

dislocation of, 1

O'Brien's test and, 36

subluxation of, 5

tests for, 38

Acromion, 11

Active dorsiflexion, 291

Active eversion, 292

Active inversion, 291

Active plantarflexion, 290

Adam's test, 165

### Adduction

of forefoot, 295

of hip, 205

in shoulder, 14

Adductor brevis, 209

Adductor gracilis, 209

Adductor longus, 209

Adductor magnus, 209

Adhesive capsulitis, 1, 3

Adson's test, 161

Anal reflex, 156

S2-4 and, 182

Anatomical snuffbox, 88–89

Ankle, 259–310

hip and, knee and, 223

injury mechanisms for, 259

muscle testing for, 298–305

pain sites for, 259

range of movement for,  
290–292

special tests for, 308–310



- Ankle (cont.)  
  swelling in, 261, 277
- Ankylosing spondylitis, 135, 136  
  chest expansion and, 145  
  relieving factors for, 163  
  stiffness and, 190
- Antalgic gait, 192, 227  
  foot and, 278
- Anterior apprehension test, 34  
  Jobe's relocation test and, 34  
  pectoralis major and, 34
- Anterior cruciate ligament (ACL), 217  
  Lachman's test for, 251
- Anterior dislocation, of elbow, 39
- Anterior drawer test, 250–251  
  for foot, 308
- Anterior inferior tibiofibular ligament, 286
- Anterior interosseous nerve, 105
- Anterior joint line tenderness, 237
- Anterior talofibular ligament, 277, 286
- Anterolateral dome,  
  of talus, 285
- APB. *See* Abductor pollicis brevis
- Ape hand deformity, 82
- Apex of the olecranon, 46
- APL. *See* Abductor pollicis longus
- Arcade of flexion,  
  of fingers, 65
- Arcade of Frohse, 44
- Arthritis. *See also*  
  Osteoarthritis;  
  Rheumatoid arthritis;  
  Septic arthritis  
  of ACJ, 1  
  of glenohumeral joint, 1, 13  
    grind test and, 131  
    of hip, 191  
    of MTP, 298  
    of radiohumeral joint, 44
- Arthrogryposis, pes cavus and, 269
- ASIS, 191, 200
- Ataxia, 192
- Avascular necrosis (AVN)  
  groin pain and, 189  
  of lunate, 62  
  swelling from, 261
- AVN. *See* Avascular necrosis
- Avulsion of sartorius, 200
- Axilla, T3 and, 135, 153
- B**
- Babinski test, 158, 183
- Baker cyst, 219, 241
- Beighton's score, for  
  hypermobility, 31
- Benediction hand deformity, 81
- Biceps  
  C6 and, 147  
  muscle testing of, 53  
  reflex of, C5 and, 153
- Biceps femoris tendon, 240
- Biceps tendon, 48
- Bishop's hand, 81
- Bladder dysfunction, 136
- Blount's disease, 221, 263
- Bouchard's nodes, 70
- Boutonniere deformity, 74
- Bowel dysfunction, 136
- Brachial artery, 48
- Brachial plexus injury, 1, 77
- Brachioradialis, 55, 97–98  
  muscle insertion for, 105  
  muscle testing of, 55  
  reflex of, C6 and, 154
- Bryant's triangle, 201
- Bulbocavernosus reflex, 156  
  S3-4 and, 182
- Bunnell test, 132

Bursitis  
in elbow, 40  
of greater trochanter, 200  
in knee, 219, 223  
psoas, 190  
skin temperature and,  
232, 279  
subacromial, 11  
Buttocks, poliomyelitis  
and, 191

## C

C1-2, pain in, 134  
C2-3, pain in, 134  
C3, neck and, 135, 153  
C3-4-5, pain in, 134  
C4, shoulder and, 135, 153  
C5, 146  
biceps and, reflex of, 153  
deltoid and, 153  
deltoid muscles and,  
135, 146  
elbow and, 135  
nerve root, 146  
C6  
biceps and, 147  
brachioradialis reflex  
and, 154  
nerve root, 147-148  
thumb and, 135, 153  
wrist and, 147  
C6-7-T1, pain in, 134  
C7  
fingers and, 149  
middle finger and, 135, 153  
nerve root, 148-150  
triceps and, 150  
reflex of, 155  
wrist and, 148  
C8  
fingers and, 151  
little finger and, 135, 153  
nerve root, 150-151  
Café-au-lait spots, 136

Calcaneofibular ligament, 286  
Callosities, 275, 276  
Camptodactyly, 86  
Capitellum  
fracture of, 39  
osteochondritis of, 39  
Caput ulnae, 62, 72  
Carpal tunnel syndrome, 62  
Modified Durkan's  
test for, 124  
Tinel's test for, 125  
Carpometacarpal joint  
(CMCJ), 70  
grind test for, 131  
osteoarthritis of, 71  
Carrying angle, 41-42  
Catching  
in knee, 220  
in lumbar spine, 170  
Cauda equina syndrome, 164  
Cellulitis, skin temperature  
and, 279  
Cerebral palsy, 263  
Cervical rib, 161  
Cervical spine  
extension in, 141  
flexion in, 140  
herniated disc in, 140  
lateral flexion of, 142  
lateral rotation of, 143  
lordosis of, 166  
rheumatoid arthritis in, 140  
spondylosis of, 135, 140  
stenosis of, 135  
Cervical/thoracic spine,  
133-161  
congenital deformities of,  
133  
fractures of, 133  
gait and, 138  
injury mechanisms of, 133  
muscle testing for, 146-152  
pain sites for, 134  
paresthesia in, 135

- Cervical/thoracic spine (cont.)  
  scars and, 136  
  special tests for, 156–161  
  stiffness in, 135
- Charcot arthropathy  
  of midfoot, 274  
  skin temperature and, 279
- Charcot-Marie-Tooth disease,  
  96, 192  
  pes cavus and, 269  
  varus heel and, 273
- Chest expansion, ankylosing  
  spondylitis and, 145
- Chest wall  
  asymmetry of, 137  
  T5-8 and, 135, 153
- Chondrocalcinosis, 219
- Clark's test, 257
- Clavicle, 5, 10
- Claw hand, 77–78
- Claw toes, 268  
  pes cavus and, 268
- Clicking, 190
- Clinodactyly, 87
- Clonus, 183  
  myelopathy and, 158
- Club foot  
  pes cavus and, 269  
  varus heel and, 273
- Club hand, 87
- CMCJ. *See* Carpometacarpal  
  joint
- Cobbler's fracture, 61
- Coccyx, 168
- Colle's fracture, 61  
  EPL and, 103
- Congenital deformities  
  of cervical/thoracic spine, 133  
  of hands, 83–87  
  of lumbar spine, 161
- Congestive heart failure, 261
- Coracoclavicular ligament, 10
- Coracoid, 10
- Corn, 276
- Coronal plane, 13
- Cremasteric reflex, T12 and,  
  182
- Crossed straight leg raising test,  
  185
- Cross fluctuation, 232
- Crush injury, pes cavus and,  
  269
- Crystal induced arthropathies,  
  skin temperature and, 279
- Cubital tunnel syndrome, 39
- Cubitus valgus, 42
- Cubitus varus, 42
- D**
- Deep venous thrombosis, 261
- Deltoid, C5 and, 153
- Deltoid ligament, 281
- Deltoid muscles, 5, 6, 22–23  
  C5 and, 135, 146
- Demyelination, 97
- Dermatomes, 153
- Diabetes, 275  
  claw toes and, 268
- Diabetes mellitus, 97
- Dial test, 254
- DIPJ. *See* Distal  
  interphalangeal joint
- Disc prolapse, 162
- Dislocation  
  of ACJ, 1  
  of elbow, 39  
  of hip, 189, 196  
  of MCPJ, 93  
  scapholunate, 62  
  of shoulder, 1
- Distal interphalangeal joint  
  (DIPJ), 70  
  deformity of, 73  
  mallet toes and, 266
- Distal radioulnar joint, 90
- Dorsal interossei, 115,  
  119–120  
  muscle insertion for, 122

T1 and, 151–152  
 Dorsalis pedis artery, 210, 281  
   knee and, 247  
 Dorsiflexion  
   of foot, 293–294  
   of great toe, 297  
   of wrist, 93  
 Dowager's hump, 137–138  
 Drawer tests, 31–32  
   of MTP, 310  
 Drop arm sign, 27  
 Drop foot, 192, 278  
 Dupuytren's contracture, 66  
 Dupuytren's disease, 71

## E

ECRB. *See* Extensor carpi  
   radialis brevis  
 ECRL. *See* Extensor carpi  
   radialis longus  
 ECU. *See* Extensor carpi  
   ulnaris  
 EDC. *See* Extensor digitorum  
   communis  
 EDM. *See* Extensor digiti  
   minimi  
 EHL. *See* Extensor hallucis  
   longus  
 EIP. *See* Extensor indicis  
   proprius  
 Elbow, 39–59  
   anterior dislocation of, 39  
   bursitis in, 40  
   C5 and, 135  
   extension in, 49  
   flexion in, 49  
   gout in, 42  
   hyperextension of, 50  
   hyperflexion of, 50  
   injury mechanisms of, 39  
   muscle testing for, 53–57  
   obesity and, 42  
   osteoarthritis in, 39, 40  
   pain sites in, 39

  posterior dislocation of, 39  
   pronation of, 50–51, 52, 56  
   range of movement in,  
     49–52  
   rheumatoid arthritis in, 40  
   septic arthritis in, 40, 42  
   special tests for, 57–59  
   stiffness in, 40  
   supination of, 50–51, 56  
   synovitis in, 45  
   T1 and, 135, 153  
   tendinosis in, 40  
 Ely's test, 213  
 Enchondroma, 65  
 EPB. *See* Extensor pollicis  
   brevis  
 Epicondyles, bony  
   prominences of, 46–47  
 EPL. *See* Extensor pollicis  
   longus  
 Erb's palsy, 3  
 Extension  
   of cervical spine, 141  
   of elbow, 49  
   of hip, 206  
   of lumbar spine, 171  
   of thoracic spine, 144  
 Extensor carpi radialis brevis  
   (ECRB), 97, 99  
   muscle insertion for, 105  
 Extensor carpi radialis longus  
   (ECRL), 97, 99  
   muscle insertion for, 105  
 Extensor carpi ulnaris (ECU),  
   97, 100  
   muscle insertion for, 105  
 Extensor digiti minimi (EDM),  
   97, 102  
   muscle insertion for, 105  
 Extensor digitorum communis  
   (EDC), 97, 101  
   muscle insertion for, 105  
 Extensor digitorum longus,  
   281, 302

Extensor hallucis brevis, 301  
Extensor hallucis longus  
  (EHL), 177, 247, 280, 301  
Extensor indicis proprius  
  (EIP), 97, 102  
  muscle insertion for, 105  
Extensor pollicis brevis (EPB),  
  97, 104  
  muscle insertion for, 105  
Extensor pollicis longus  
  (EPL), 97  
  Colle's fracture and, 103  
  muscle insertion for, 105  
  radial nerve and, 121  
  rheumatoid arthritis and,  
    103  
External rotation, 14–16  
  in abduction, 15  
External rotation lag test, 29  
External rotation test, 311

## F

FABER maneuver, 187  
  for hip, 212  
Facet joint, 139, 168  
Facet syndrome, 161  
Fairbank's test, 256  
FCR. *See* Flexor carpi radialis  
FCU. *See* Flexor carpi ulnaris  
FDP. *See* Flexor digitorum  
  profundus  
FDS. *See* Flexor digitorum  
  superficialis  
Femoral shortening, 198–199  
Femoral stretch test, 186  
FHL. *See* Flexor hallucis  
  longus  
Fick angle, 262  
5th metatarsal, 286  
Fingers  
  arcade of flexion of, 65  
  C7 and, 149  
  C8 and, 151  
  fracture of, 65

  normal rotational alignment  
    of, 65  
  rheumatoid arthritis of, 65  
  swelling of, 70–72  
Finklestein's test, for de  
  Quervain's disease, 126  
First dorsal interosseous,  
  atrophy of, 71  
First metatarsal, 285  
Fixed flexion deformity,  
  230–231  
Flexed knee gait, 227, 278  
Flexion  
  of cervical spine, 140  
  of elbow, 49  
  of hip, 203  
  of knee, 222  
  of lumbar spine, 169  
  of thoracic spine, 144  
Flexion deformity, 230–231  
Flexor carpi radialis (FCR),  
  105, 107  
  muscle insertion for, 114  
Flexor carpi ulnaris (FCU),  
  90, 116  
  muscle insertion for, 122  
  ulnar nerve and, 115  
Flexor digiti minimi brevis,  
  115  
  muscle insertion for, 122  
Flexor digitorum longus, 283  
Flexor digitorum profundus  
  (FDP), 64, 105, 110  
  little finger and, 116  
  median nerve and, 121  
  muscle insertion for, 114,  
    122  
  ring finger and, 116  
  ulnar nerve and, 115, 121  
Flexor digitorum superficialis  
  (FDS), 64, 105, 109  
  muscle insertion for, 114  
Flexor hallucis longus (FHL),  
  283

- Flexor pollicis brevis (FPB),  
105, 113  
muscle insertion for, 114  
ulnar nerve and, 115
- Flexor pollicis longus (FPL),  
105  
muscle insertion for, 114
- Flexor tendon sheath  
infection, 65
- Flexor tenovaginitis, 62
- Foot, 259–310  
alignment of, 262–264  
ankle in, 261  
and antalgic gait, 278  
anterior drawer test for, 308  
dorsiflexion of, 293–294  
and gait, 278  
heel of, 288–289  
injury mechanisms for, 259  
muscle testing for, 298–305  
muscle wasting in, 278  
pain sites for, 259  
pronation of, 263–264  
range of movement for,  
290–292  
scars on, 277  
sensory distribution  
of, 306–307  
sole of, 287–288  
special tests for, 308–310  
stiffness in, 261  
stress fracture in, 278  
swelling in, 261
- Foraminal compression test,  
157
- Forefoot  
abduction of, 295–296  
adduction of, 295
- Forward flexion, of shoulder,  
12
- FPB. *See* Flexor pollicis brevis
- FPL. *See* Flexor pollicis longus
- Fracture  
of capitellar, 39  
of cervical/thoracic spine, 133  
of fingers, 65  
of lumbar spine, 161  
of neck of femur, 196  
of olecranon, 39  
osteoporosis and, 133  
of radial head, 39, 44  
of supracondylar, 39  
malunited, 42
- Freiberg's disease, 287
- Froment's test, 127–128
- Fungal infection, of nails, 69
- Funnel chest, 137
- ## G
- Gait  
cervical/thoracic spine and,  
138  
foot and, 278  
hip and, 192–195  
knee and, 226–229  
lumbar spine and, 166–167
- Galeazzi test, 198
- Gamekeeper's thumb, 61
- Ganglion, 65, 72  
in knee, 219
- Garrod's pad, 71
- Gastrocnemius complex, 167
- Genu valgum, 222, 263
- Genu varum, 263
- Gerber's lift off test, 25
- Giant cell tumor, of tendon  
sheath, 65
- Gibbus, 137–138  
of lumbar spine, 166
- Glenohumeral joint, arthritis  
of, 1, 13
- Glenoid labrum, 36
- Gluteus maximus, 208
- Gluteus medius, 177, 208
- Golfer's elbow, 39
- Gout, 39, 277  
in elbow, 42  
skin temperature and, 232

Gouty tophi, 40, 70  
Gracilis, 238  
Greater trochanter, 190, 200  
    bursitis of, 200  
Great toe  
    dorsiflexion of, 297  
    plantarflexion of, 297  
    pronation of, 264  
Grind test, 90  
    arthritis and, 131  
    for CMCJ, 131  
Groin pain, 189  
Guyon's canal, 91

## H

Haglund's deformity, 289  
Hallux rigidus, 298  
Hallux valgus, 263  
Hallux varus, 264  
Hamate, 91  
Hammer toe, 265–266  
    PIPJ and, 265  
Hamstrings, 245  
    medial hamstring reflex,  
        180  
Hands, 61–132  
    congenital deformities of,  
        83–87  
    injury mechanisms in, 61–62  
    neurological disorders of,  
        96–123  
    psoriasis of, 69  
    range of movement of, 96  
    swelling of, 65, 70–72  
Hawkins' test, 30  
Heberden's nodes, 70  
Heel  
    of foot, 288–289  
    valgus, 272  
    varus, 273  
Henry's knot, 285  
Herniated disc, 133  
    in cervical spine, 140  
    in lumbar spine, 161

    weakness from, 135  
Hindfoot alignment, 271–273  
Hip, 189–215  
    abduction of, 204–205  
    adduction of, 205  
    ankle and, knee and, 223  
    arthritis of, 191  
    dislocation of, 189, 196  
    extension of, 206  
    FABER maneuver for, 212  
    flexion of, 203  
    gait and, 192–195  
    injury mechanisms of, 189  
    knees and, 192  
    lumbar spine and, 191  
    muscle testing for, 207–209  
    pain sites of, 189  
    range of movement of,  
        203–206  
    rotation of, 205–206  
    stiffness in, 190  
    synovitis of, 191  
Hoffmann's sign, 159  
Hook of hamate, 61, 91  
Hyperextension  
    of elbow, 50  
    of knee, 217, 222–223  
    of MCPJ, 77, 81  
Hyperflexion  
    of elbow, 50  
    of knee, 217  
Hypermobility  
    Beighton's score for, 31  
    sulcus sign and, 33  
Hypoplasia, of tibia, 263  
Hypothenar eminence, 66, 68  
    abductor digiti minimi and,  
        117

## I

Iliopsoas, 174, 207  
Inferior laxity, 33  
Infrapatellar nerve, 246  
Infraspinatus, 8, 28–29

Inguinal ligament, 200  
 Instability tests, for shoulder,  
   31–35  
 Internal rotation  
   in abduction, 17  
   of shoulder, 16–17  
 Interphalangeal joint (IPJ),  
   70, 298  
   deformity of, 73  
 Intrinsic minus, 77–78  
 Intrinsic plus hand, 79  
 IPJ. *See* Interphalangeal joint

## J

Jack test, 309  
 Jobe's relocation test, 27, 35  
   anterior apprehension test  
     and, 34  
 J sign, 256

## K

Kanavel's signs, 65  
 Kienböck's disease, 88  
 Kiloh-Nevin sign, 129  
 Kirk Watson test, 130  
 Klumpke palsy, 77  
 Knee, 217–258  
   alignment of, 221–222  
   bursitis in, 219, 223  
   catching in, 220  
 Knee  
   dorsalis pedis artery and,  
     247  
   flexion of, 222  
   ganglion in, 219  
   hip and ankle and, 223  
   hips and, 192  
   hyperextension of, 217,  
     222–223  
   hyperflexion of, 217  
   injury mechanisms of, 217  
   lipoma in, 219  
   locking in, 220  
   muscle testing for, 244–245

  neuroma in, 219  
   obesity and, 222  
   osteoarthritis of, 219, 221  
   pain sites of, 218  
   popliteal artery and, 247  
   range of movement in,  
     229–231  
   scars and, 223  
   septic arthritis of, 219  
   special tests for, 247–254  
   stiffness in, 220  
   swelling of, 219–220,  
     223–226, 232–236  
   synovial thickening in,  
     235–236  
   valgus stress test for, 255  
   varus stress test for, 255  
 Kyphosis, 136, 137–138  
   of thoracic spine, 166

## L

L2, 174  
 L3, 175  
 L4, 176  
   patella tendon reflex and,  
     179  
 L5, 177  
   medial hamstring reflex and,  
     180  
 Labral test, 215  
 Lacertus fibrosus, 48  
 Lachman's test, for ACL, 251  
 Lasègue's test, 185  
 Lateral collateral ligament  
   (LCL), 240  
   varus stress test for, 255  
 Lateral compartment  
   osteoarthritis, 239  
 Lateral epicondylitis, 39, 42  
   provocative test for, 59  
 Lateral facet, 243  
 Lateral flexion  
   of cervical spine, 142  
   of lumbar spine, 172



- Lateral joint line, 239
- Lateral malleolus, 285
- Lateral meniscus, 217
- Lateral pivot shift test, 59
- Lateral plantar nerve (LPN), 284
- Lateral rotation, of cervical spine, 143
- Latissimus dorsi, 21
- LCL. *See* Lateral collateral ligament
- Length measurement, 202–203
- Lesser toes, 265, 298
- L'hermitte's sign, 159
- Limb length, 197
- Limp, 190
- Lipoma, in knee, 219
- Lisfranc injury, 274
- Lister's tubercle, 89
- Little finger
  - C8 and, 135, 153
  - FDP and, 116
  - myelopathy and, 136
- Locking, in knee, 220
- Loose body, 219
- Lordosis, 137
  - of cervical spine, 166
  - of lumbar spine, 166
- LPN. *See* Lateral plantar nerve
- Lumbar spine, 161–188
  - catching in, 170
  - congenital deformities of, 161
  - extension of, 171
  - flexion of, 169
  - fracture of, 161
  - gibbus of, 166
  - herniated disc in, 161
  - hip and, 191
  - injury mechanisms of, 161
  - lateral flexion of, 172
  - lordosis of, 166
  - metastatic disease of, 161
  - muscle testing of, 173
  - pain sites of, 162
  - paresthesia in, 163
  - reflexes of, 179–182
  - scars and, 164
  - special tests for, 184–188
  - spondylolisthesis of, 162
  - stenosis of, 161
    - relieving factors for, 163
- Lumbricals, 114, 119–120
  - muscle insertion for, 122
  - ulnar nerve and, 115
- Lunate, AVN of, 62
- Luxatio erecta, 3
- Lymphadenopathy, 142
- Lymph node biopsy, 4
- M**
- Macroductyly, 85
- Mallet finger, 61, 73
- Mallet thumb, 73
- Mallet toes, 266–268
  - DIP and, 266
- Mannerfelt-Norman syndrome, 83
- MCL. *See* Medial collateral ligament
- McMurray's test, 247–248
- MCPJ. *See* Metacarpophalangeal joint
- Medial collateral ligament (MCL), 237
  - valgus stress test for, 255
  - synovitis in, 239
- Medial cuneiform, 279
- Medial epicondyle, 46
- Medial epicondylitis, 39
- Medial epiphysis, premature closure of, 42
- Medial facet, palpation of, 243
- Medial hamstring reflex, L5 and, 180
- Medial head, of talus, 284
- Medial joint line, 237

- Medial malleolus, 281
  - Medial meniscus, 217
  - Medial navicular tubercle, 284
  - Medial plantar nerve, 285
  - Median nerve, 48, 55–56, 105
    - FDP and, 121
  - Medical Research Council (MRC), grading scale of, 18
  - Meniscus, 217
    - test for, 247–248
  - Meralgia paresthetica, 209
  - Metacarpophalangeal joint (MCPJ), 70
    - Bunnell test for, 132
    - deformity of, 76
    - dislocation of, 93
    - hyperextension of, 77, 81
    - rheumatoid arthritis of, 71
    - subluxation of, 93
    - synovitis of, 71
  - Metastatic disease, 133
    - of lumbar spine, 161
  - Metatarsal heads, 287
  - Metatarsocuneiform joint, 247
  - Metatarsophalangeal joint (MTP), 297
    - arthritis of, 298
    - drawer tests of, 310
  - Metatarsus varus, 263
  - Midcarpal osteoarthritis, 62
  - Middle finger, C7 and, 135, 153
  - Midfoot, Charcot arthropathy of, 274
  - Modified Durkan's test, for carpal tunnel syndrome, 124
  - Morton's neuroma, 287, 311
  - MRC. *See* Medical Research Council
  - MS. *See* Multiple sclerosis
  - MTP. *See* Metatarsophalangeal joint
  - Mucous cyst, 65
  - Mulder's sign, 311–312
  - Multiple sclerosis (MS), 97
  - Muscle testing
    - for ankle, 298–305
    - of biceps, 53
    - of brachioradialis, 55
    - for cervical/thoracic spine, 146–152
    - for elbow, 53–57
    - for foot, 298–305
    - for hip, 207–209
    - for knee, 244–245
    - for lumbar spine, 173
    - of PQ, 55–56
  - Muscle testing
    - of PT, 55–56
    - for shoulder, 18–19
    - of triceps, 54
  - Muscle wasting, 245
    - in foot, 278
  - Muscular dystrophy, 192
    - pes cavus and, 269
  - Musculocutaneous nerve, 48, 53
  - Myelopathy, 136
    - clonus and, 158
    - little finger and, 136
- N**
- Nails, 69
    - fungal infection of, 69
  - Napoleon belly press test, 26
  - Neck
    - C3 and, 135, 153
    - stiff, 137
  - Neck of femur, fracture of, 196
  - Neer's sign, 29
  - Neer's test, 30
  - Negative lag test, 25
  - Neurofibromatosis, 136

Neurological disorders  
  of hands, 96–123  
  of wrist, 96–123

Neuroma, in knee, 219  
Nipple, T4 and, 135, 153

## O

Ober's test, 214

Obesity  
  elbow and, 42  
  knees and, 222

O'Brien's test, 36–37  
  ACJ and, 36

Olecranon  
  fracture of, 39  
  into olecranon fossa, 52

Olecranon bursa, 40

Olecranon fossa, 45  
  olecranon into, 52

Opponens digiti minimi, 115,  
  117  
  muscle insertion for, 122

Opponens pollicis, 105, 112  
  muscle insertion for, 114

Os acromiale, 11

Osgood-Schlatter's disease,  
  223

"O" sign, 129

Osteoarthritis  
  of CMCJ, 71  
  in elbow, 39, 40  
  groin pain and, 189  
  in knee, 221  
  of knee, 219  
  lateral compartment, 239  
  pisotriquetral, 62, 90  
  radioulnar, 62  
  in shoulder, 3  
  of SST, 62  
  swelling from, 261

Osteochondritis, of  
  capitulum, 39

Osteochondritis dissecans, 258

Osteophytes, 223

Osteoporosis, fractures and,  
  133

## P

Palmar flexion, of wrist, 94

Palmar interossei, 115, 121  
  muscle insertion for, 122

Palmaris longus (PL), 105, 108  
  muscle insertion for, 114

Palpation  
  of medial facet, 243  
  of radial head, 43–44  
  of ulnar nerve, 46

Paresthesia  
  in cervical/thoracic spine,  
    135  
  in lumbar spine, 163

Paronychia, 69

Patella  
  height of, 225  
  lateral displacement of, 242  
  medial displacement of, 242  
  mobility of, 241  
  position of, 224  
  size of, 226

Patella alta, 226

Patella baja, 226

Patellar apprehension test,  
  256

Patellar grinding, 257

Patellar hollow test, 235

Patellar tap, 233

Patellar tracking, 256–258

Patella tendon reflex, L4 and,  
  179

Patellofemoral joint, 257

Pathological medial plica, 243

Patrick's test. *See* FABER  
  maneuver

PCL. *See* Posterior cruciate  
  ligament

Pectoralis major, 25  
  anterior apprehension test  
  and, 34

- Pectus carinatum, 137  
 Pectus excavatum, 137  
 Peroneus brevis, 286, 305  
 Peroneus longus, 286, 305  
 Pes cavus, 269  
     claw toes and, 268  
 Pes planus, 270  
 Pes valgus, 263  
 Piano key test, 131  
 Pigeon chest, 137  
 Pigmented villonodular  
     synovitis (PVNS), 219, 277  
 PIPJ. *See* Proximal  
     interphalangeal joint  
 Piriformis syndrome, 200  
 Piriformis test, 215  
 Pisiform, 90, 91  
 Pisotriquetral osteoarthritis,  
     62, 90  
 Pivot shift test, 252–253  
 PL. *See* Palmaris longus  
 Plantar fascia, 287–288  
 Plantarflexion, 294  
     of great toe, 297  
 Plantar reflex. *See* Babinski  
     test  
 Pointing finger sign, 64  
 Poliomyelitis, 96  
     buttocks and, 191  
 Polydactyly, 84  
 Polyneuritis, pes cavus  
     and, 269  
 Popliteal aneurysm, 219  
 Popliteal artery, 210  
     knee and, 247  
 Popliteal cyst, 241  
 Popliteal fossa, 224, 240  
 Posterior apprehension  
     test, 35  
 Posterior cord syndrome, 138  
 Posterior cruciate ligament  
     (PCL), 217  
     posterior drawer test for,  
         253  
 Posterior dislocation  
     of elbow, 39  
     of shoulder, 1  
 Posterior drawer test,  
     for PCL, 253  
 Posterior interosseous nerve,  
     44, 97  
 Posterior talofibular ligament,  
     286  
 Posterior tibial artery, 283  
 Posterolateral ankle, 277  
 Posterosuperior iliac spine  
     (PSIS), 168  
 PQ. *See* Pronator quadratus  
 Pronation  
     of elbow, 50–51, 52, 56  
     of foot, 263–264  
     of great toe, 264  
 Pronator quadratus (PQ),  
     105, 106  
     muscle insertion for, 114  
     muscle testing of, 55–56  
 Pronator teres (PT), 105, 106  
     muscle insertion for, 114  
     muscle testing of, 55–56  
 Proprioception, 182  
 Provocative test, for lateral  
     epicondylitis, 59  
 Proximal interphalangeal joint  
     (PIPJ), 70  
     Bunnell test for, 132  
     deformity of, 73, 86  
     hammer toe and, 265  
     synovitis of, 71  
 PSIS. *See* Posterosuperior iliac  
     spine  
 Psoas bursitis, 190  
 Psoriasis, of hands, 69  
 PT. *See* Pronator teres  
 Pubis symphysis, 200  
 PVNS. *See* Pigmented  
     villonodular synovitis  
 Pyogenic flexor tenosynovitis,  
     65

**Q**

- Q angle, 227–229
- Quadriceps, 175, 244
  - rupture of, 230
- de Quervain's disease,
  - 62, 72, 88
  - Finklestein's test for, 126

**R**

- Radial club hand, 87
- Radial deviation, of wrist, 95
- Radial head
  - fracture of, 39, 44
  - palpation of, 43–44
  - subluxation of, 39
- Radial nerve, 54, 55
  - EPL and, 121
- Radial styloid process, 88
- Radial tunnel syndrome,
  - 39, 44
- Radiocarpal osteoarthritis, 62
- Radiohumeral joint,
  - arthritis, 44
- Radioulnar osteoarthritis, 62
- Range of movement
  - for ankle, 290–292
  - in elbow, 49–52
  - for foot, 290–292
  - of hands, 96
  - of hip, 203–206
  - in knee, 229–231
  - in shoulder, 11
  - for wrist, 93–96
- Residual compartment
  - syndrome, pes cavus
  - and, 269
- Retrocalcaneal bursa, 288
- Reverse prayer position, 94
- Rheumatoid arthritis
  - in cervical spine, 140
  - in elbow, 40
  - EPL and, 103
  - of fingers, 65
  - of MCPJ, 71

- in shoulder, 3
- stiffness and, 190
- swelling from, 261
- in wrist, 72
- Rhomboid, 21
- Rib hump, 165
- Ring finger, FDP and, 116
- Rocker bottom foot, 270
- Roos test, 160
- Rotation
  - of hip, 205–206
  - of thoracic spine, 144
- Rotator cuff, 25–29
  - tear of, 1, 13
- Rowe's sign, 16

**S**

- S1, 178
  - Achilles' tendon reflex and,
    - 181
- S2, 178
- S2-4, anal reflex and, 182
- S3, 178
- S3-4, bulbocavernosus reflex
  - and, 182
- S4, 178
- Sacroiliac joint, 168
- Sacrum, 168
- Sagittal plane, 12
- Saphenous nerve, 246, 307
- Scaphoid nonunion,
  - 62, 88, 89
- Scapholunate dislocation, 62
- Scaphotrapeziotrapezoid (SST), osteoarthritis of, 62
- Scapula, 6–9
- Scarf test, 38
- Scars, 4
  - cervical/thoracic spine and,
    - 136
  - on foot, 277
  - knee and, 223
  - lumbar spine and, 164
  - ulnar nerve and, 68

- Scheuermann's disease,  
136, 137
- Schober's test, 170–171
- SCJ. *See* Sternoclavicular joint
- Scoliosis, 136, 164, 165
- Sectoral sign, 206
- Semimembranosus (SM), 238
- Semitendinosus (ST), 238
- Septic arthritis  
in elbow, 40, 42  
of knee, 219  
skin temperature and, 232,  
279
- Serratus anterior, 20
- Sesamoid bones, 287
- Short limb gait, 192
- Shoulder, 1–38  
abduction in, 13–14  
adduction in, 14  
age and, 1  
C4 and, 135, 153  
forward flexion of, 12  
injury mechanisms of, 1  
instability tests for, 31–35  
internal rotation of, 16–17  
muscle testing for, 18–19  
osteoarthritis in, 3  
pain sites in, 2  
posterior dislocation of, 1  
range of movement in, 11  
rheumatoid arthritis in, 3  
special tests for, 29–38  
stiffness in, 3
- Sinus tarsi, 286
- Skiers, 61
- Skin temperature, 232, 279
- SLAP. *See* Superior Labrum  
Anterior to Posterior
- Slap foot, 192, 278
- Slocum test, 253–254
- SLR. *See* Straight leg-raising  
test
- SM. *See* Semimembranosus
- Smith's fracture, 61
- Snowboarders, 61
- Spina bifida, 136
- Spine, 133–188. *See also*  
Cervical/thoracic spine;  
Lumbar spine
- Spinous process, 139, 168
- Spondylolisthesis, 133  
of lumbar spine, 162
- Spondylosis, 133  
of cervical spine, 140  
weakness from, 135
- Sprengel's deformity, 4, 6
- Springy block, 52
- Spurling's maneuver, 157
- Squeeze test, 311
- SST. *See*  
Scaphotrapeziotrapezoid
- ST. *See* Semitendinosus
- Steinmann's first test, 249–250
- Stenosing tenovaginitis. *See* de  
Quervain's disease
- Stenosis, 133  
of cervical spine, 135  
of lumbar spine, 161  
relieving factors for, 163
- Stepping gait, 192, 278
- Sternoclavicular joint (SCJ),  
6–7, 9
- Stiff finger, 64
- Stiff knee gait, 227, 278
- Stiff neck, 137
- Stiffness  
ankylosing spondylitis and,  
190  
in cervical/thoracic spine,  
135  
in elbow, 40  
in foot, 261  
in hip, 190  
in knee, 220  
rheumatoid arthritis and,  
190  
in shoulder, 3
- Stinchfield's test, 215

- Straight leg-raising test (SLR), 184–185
  - Stress fracture
    - in foot, 278
    - groin pain and, 189
  - Subacromial bursitis, 11
  - Subacromial impingement tests, 29–30
  - Subcutaneous bursa, 288
  - Subluxation
    - of ACJ, 5
    - of MCPJ, 93
    - of radial head, 39
  - Subscapularis, 25–26
  - Sulcus sign, 33
    - hypermobility and, 33
  - Superficial peroneal nerve, 307
  - Superficial skin reflexes, 156
  - Superior Labrum Anterior to Posterior (SLAP), 36
  - Supination, of elbow, 50–51, 56
  - Supracondylar, fracture
    - of, 39
    - malunited, 42
  - Suprapatellar pouch, 235
  - Suprascapular nerve palsy, 9
  - Supraspinatus, 8, 27
  - Sustentaculum tali, 284
  - Swan neck deformity, 73
  - Swelling
    - in ankle, 261, 277
    - from AVN, 261
    - of fingers, 70–72
    - in foot, 261
    - of hands, 65, 70–72
    - in knee, 219–220, 223–226, 232–236
    - from osteoarthritis, 261
    - from rheumatoid arthritis, 261
    - of wrist, 72
  - Syndactyly, 83
  - Syndesmosis, 168
  - Synovial thickening, in knee, 235–236
  - Synovitis, 71
    - in elbow, 45
    - of hip, 191
    - in MCL, 239
    - of MCPJ, 71
    - of PIPJ, 71
    - in wrist, 72
- T**
- T1
    - abductor digiti minimi and, 152
    - dorsal interossei and, 151–152
    - elbow and, 135, 153
    - nerve root, 151–152
  - T2, 153
  - T3, axilla and, 135, 153
  - T4, nipple and, 135, 153
  - T5–8, chest wall and, 135, 153
  - T9–12, abdominal wall and, 135, 153
  - T10, umbilicus and, 153
  - T12, cremasteric reflex and, 182
  - Tailor's bunion, 286
  - Talipes calcaneovalgus, 263
  - Talipes equinovarus, 263
  - Talipes varus, 263
  - Talus
    - anterolateral dome of, 285
    - medial head of, 284
  - Tarsal tunnel syndrome, 283
  - Tendinitis
    - abductor, groin pain and, 189
    - in Achilles' tendon, 277
  - Tendinosis, in elbow, 40
  - Tendon sheath, giant cell tumor of, 65
  - Tennis elbow, 39

- Teres minor, 28–29  
 TFCC. *See* Triangular fibrocartilage complex  
 Thenar muscles, 66–67  
 Thomas' test, 210–211  
 Thompson's test, 310  
 Thoracic outlet syndrome, 160, 161  
 Thoracic spine  
   extension of, 144  
   flexion of, 144  
   kyphosis of, 166  
   rotation of, 144  
 Thumb  
   abduction of, 105  
   C6 and, 135, 153  
 Thumbs up sign, 121  
 Tibia, hypoplasia of, 263  
 Tibialis anterior muscle, 167, 176, 300  
 Tibialis anterior tendon, 279  
 Tibialis posterior tendon, 281, 303–305  
 Tibial nerve, 283  
 Tibial shortening, 198–199  
 Tinel's sign, 125, 209  
 Tinel's test  
   for carpal tunnel syndrome, 125  
   for ulnar nerve, 59  
 Tip of the olecranon, 45  
 "Too many toes" sign, 274  
 Torticollis, 137, 142  
 Trapezium, 89  
 Trapezius muscles, 4, 6, 11  
 Traumatic osteitis pubis, groin pain and, 189  
 Trendelenburg gait, 192–195  
 Triangular fibrocartilage complex (TFCC), 62  
   lesions of, 90  
 Triceps  
   C7 and, 150  
   muscle testing of, 54  
   reflex of, C7 and, 155  
 Trigger finger, 91–92  
**U**  
 UCL. *See* Ulnar collateral ligament  
 Ulnar abutment, 62  
 Ulnar clawing, 80  
 Ulnar collateral ligament (UCL)  
   injuries of, 39, 61  
   stability of, 132  
 Ulnar deviation, of wrist, 95  
 Ulnar drift, 76  
 Ulnar head, 90  
 Ulnar lumbricals. *See* Lumbricals  
 Ulnar nerve  
   FCU and, 115  
   FDP and, 115, 121  
   FPB and, 115  
   lumbricals and, 115  
   palpation of, 46  
   scars and, 68  
   Tinel's test for, 59  
 Ulnar paradox, 80  
 Ulnar styloid fracture, 62  
 Ulnar tunnel syndrome, 62  
 Umbilicus, T10 and, 153  
**V**  
 Valgus heels, 272  
 Valgus stress test, 58  
   for knee, 255  
   for MCL, 255  
   synovitis in, 239  
 Valgus thrust, 227  
 Varus heel, 273  
   club foot and, 273  
 Varus stress test, 57  
   for knee, 255  
   for LCL, 255  
 Varus thrust, 226–227  
 Vaughn-Jackson syndrome, 75  
 Villonodular synovitis, 65



Volkmann's ischemic  
contracture, 77

## **W**

Waddell's signs, 187

Wartenberg's sign, 136

Wilson test, 258

Wrist, 61–132

    C6 and, 147

    C7 and, 148

    dorsiflexion of, 93

    injury mechanisms in,  
        61–62

    neurological disorders of,  
        96–123

    palmar flexion of, 94

    radial deviation of, 95

    range of movement for,  
        93–96

    rheumatoid arthritis in, 72

    swelling of, 72

    synovitis in, 72

    ulnar deviation of, 95

Wrist drop, 82

## **X**

Xiphisternum, 202

## **Z**

Z thumb, 75