

Vipul R. Patel
Manickam Ramalingam
Editors

Operative Atlas of Laparoscopic and Robotic Reconstructive Urology

Second Edition

EXTRAS ONLINE



Springer

Operative Atlas of Laparoscopic and Robotic Reconstructive Urology

Vipul R. Patel • Manickam Ramalingam
Editors

Operative Atlas of Laparoscopic and Robotic Reconstructive Urology

Second Edition

 Springer

Editors

Vipul R. Patel
Florida Hospital Global Robotics Institute
Celebration
Florida
USA

Manickam Ramalingam
PSG Hospitals
Coimbatore
Tamil Nadu
India

ISBN 978-3-319-33229-1 ISBN 978-3-319-33231-4 (eBook)
DOI 10.1007/978-3-319-33231-4

Library of Congress Control Number: 2017941050

© Springer International Publishing Switzerland 2017

This work is subject to copyright. All rights are reserved by the Publisher, whether the whole or part of the material is concerned, specifically the rights of translation, reprinting, reuse of illustrations, recitation, broadcasting, reproduction on microfilms or in any other physical way, and transmission or information storage and retrieval, electronic adaptation, computer software, or by similar or dissimilar methodology now known or hereafter developed.

The use of general descriptive names, registered names, trademarks, service marks, etc. in this publication does not imply, even in the absence of a specific statement, that such names are exempt from the relevant protective laws and regulations and therefore free for general use.

The publisher, the authors and the editors are safe to assume that the advice and information in this book are believed to be true and accurate at the date of publication. Neither the publisher nor the authors or the editors give a warranty, express or implied, with respect to the material contained herein or for any errors or omissions that may have been made. The publisher remains neutral with regard to jurisdictional claims in published maps and institutional affiliations.

Printed on acid-free paper

This Springer imprint is published by Springer Nature
The registered company is Springer International Publishing AG
The registered company address is: Gewerbestrasse 11, 6330 Cham, Switzerland

*This book is fondly dedicated
to our teachers and trainees
who inspired us
and
our patients
for their immense faith.*

Foreword by Jacques Marescaux



The art of surgery has been profoundly reshaped over the last decades and has moved towards the creation of a precise paradigm. Computer science, robotics, and advanced imaging have spurred quantum leaps and have led to radically improved surgical outcomes. As key opinion leaders, Dr. Vipul Patel and Dr. Manickam Ramalingam have accomplished considerable work with this second edition of this *Operative Atlas of Laparoscopic and Robotic Reconstructive Urology*. This cutting-edge book provides state-of-the-art and evidence-based references as well as outstanding comprehensive descriptions supported by an extensive iconography. The authors are known to be at the forefront of the developments of minimally invasive robotic prostatectomies. Dr. Patel has personally performed 10,000 cases, which represent a major achievement, and his surgical expertise and authoritative excellence have given rise to the writing of this atlas. I would like to congratulate the authors who deserve praise for their outstanding work, and I hope that the same spirit of excellence inspires readers.

Chairman, Institute of Image Guided Surgery,
IHU Strasbourg, Strasbourg, France

Prof. Jacques Marescaux
President, IRCAD

Foreword by Ganesh Gopalakrishnan



An operative surgical atlas is usually a once-in-a-lifetime achievement.

Drs. Vipul Patel and Manickam Ramalingam have been consistently shattering this myth. They have come out with another more brilliant edition of laparoscopic and robotic reconstructive urology. The horizons of robotic surgery are being widened daily, and this edition has included these newer advances. There is a whole section on robotic renal transplantation.

The pictures and videos are of excellent quality and give the impression of watching the procedure live. This is a must have book in every teaching department of urology and should also don the bookshelves of aspiring and confirmed robotic surgeons so that they can continue to learn and innovate.

My congratulations to Drs. Vipul Patel and Manickam Ramalingam.

Prof. of Urology, Vedanayagam Hospital
Coimbatore, India

Ganesh Gopalakrishnan

Preface

“It is not the strongest of the species that survives, nor the most intelligent that survives. It is the one that is the most adaptable to change.” Charles Darwin

Since the first edition of our book in 2009, “a lot of water has flown under the bridge.” Eight years is an “era” in medical field. The pace of growth in medical field is phenomenal. Improvement in the surgical gadgets, techniques, and treatment modalities has become a day-to-day affair. Since the advent of surgical robots, robot-assisted laparoscopic surgeries have become the treatment of choice in urological procedures like radical prostatectomy.

One of the primary changes we have made in this edition is to include chapters on respective robot-assisted approaches for laparoscopic procedures. This makes this edition a comprehensive atlas on minimally invasive reconstructive surgery. Pervading use of laparoscopy by many urologists has expanded its indication. Thus, in the laparoscopic approach, chapters have been added on diverticulocystoplasty, gastrocystoplasty, buccal mucosal graft ureteroplasty, nipple valve reimplantation, intracorporeal ileal ureter, intra corporeal neobladder, and intra corporeal ileal conduit. Robot-assisted renal transplantation and radical cystectomy with intracorporeal ileal conduit and neobladder are some of the highlights in the chapters on robot-assisted approaches.

Almost all the operative images have been edited and newer HD images have been provided wherever feasible. This provides the readers a precise, high-resolution image and helps them to comprehend the operative anatomy better. Continuing the tradition of the previous edition, this book also gives importance and more space to the images than the written text. However, relevant text is provided wherever necessary, to understand the technique.

Eminent authors and surgeons in laparoscopic and robotic surgery have contributed the chapters for this book. We are ever grateful to them for having dedicated their precious time and effort for providing the operative images and text.

As quoted by Scott A. Reighard, “Tomorrow is another opportunity to improve yourself”; we hope we have improved our book from the previous edition to the present one, with the opportunity given to us by the Almighty.

Coimbatore, India
Celebration, Florida, USA

Manickam Ramalingam
Vipul R. Patel

Acknowledgment

We are truly grateful to our colleagues M.G. Pai, Kallappan Senthil, Anandan Murugesan, and Hariharan Palayapalayam Ganapathi for their unstinted support and invaluable contribution.

I wish to thank the following authors for sharing their knowledge so generously and making this atlas possible by illustrating appropriately. Their sincere efforts are commendable. We editors are ever grateful to them.

Authors:

Abhay Rane
Ajay Rane
Ananthakrishnan Sivaraman
Allen Sim
Chandrasekar Biyani
Christian Schwentner
David Albala
Daniel Glassman
Eric D. Schadler
R.T. Dharmendra
George P. Abraham
Hariharan Palayapalayam Ganapathi
Jayapriya Jayakumaran
Jean-Luc Hoepffner
Kesava Pillai Subramonian
C. Mallikarjuna
N. Mallikarjuna Reddy
Mohan K. Abraham
Mohan S. Gundeti
Anandan Murugesan
Murugesan Manoharan
Mahesh R. Desai
Marina Yiasemidou
Mizar G. Pai
Mohammad Hadi Radfar
Nagesh Kamat
Nian Zeng
Nicholas Raison
Peter Wiklund
Prashanth Kulkarni
Prakash Johnson
Pranjal Modi
Prokar Dasgupta
Howard Lau
Robert I. Carey

Rajiv Yadav
Rajesh Ahlawat
Jean-Luc Hoffpner
Jens J. Rassweiler
Kallappan Senthil
Krishnasamy Selvarajan
Raj Patel
Renukadevi R.
G.Rajamani
Said Abdallah Al-Mamari
Sejal D. Patel
Sara L. Best
Sara Faisel
Sam B Bhayani
Suma Natarajan
Shrenik Shah
Sanjay Kulkarni
Shailesh Shah
Nasser Simforoosh
Vaikundam Srinivasan

I am grateful to my technical team for their unstinted untiring effort in completing this endeavor:

K.M. Nachimuthu
Vijayan Ramalingam
Jayanthi Manoj Kumar
Ramesh
S.P. Kanagaraj

I sincerely thank the support rendered by the trustees, administrators, anesthetic and surgical colleagues, and operating room staffs of PSG Hospital, Ganga Hospital, G.K.N.M. Hospital, V.G. Hospital, Kongunadu Hospital, and K.G. Hospital Coimbatore. My special thanks are due to my friends K.C. Venkatesh, C.R. Rajeswaran, Haseeb, Sheeba, V. Venkatesh, P. Viswanathan, and S.N. Bala Shanmugam.

I whole heartedly thank Kallappan Senthil, Hariharan Palayapalayam Ganapathi, and Anandan Murugesan for their assistance in editing and patient proofreading.

This book would not have been possible without the continued encouragement of our family members.

Coimbatore, India
Florida, USA

Manickam Ramalingam
Vipul R. Patel

Contents

Part I Introduction

- 1 Surgical Robotics: Past, Present and Future** 3
Hariharan Palayapalayam Ganapathi, Gabriel Ogaya-Pinies,
Travis Rogers, and Vipul R. Patel
- 2 Entry and Exit: Transperitoneal Laparoscopic and Robotic Approach** 13
Sara Faisel and David M. Albala
- 3 Basic Techniques in Retroperitoneoscopy** 31
Manickam Ramalingam, Kallappan Senthil, and Anandan Murugesan
- 4 Instruments in Laparoscopic Reconstructive Urology** 39
Marina Yiasemidou, Daniel Glassman, and Chandra Shekhar Biyani

Part II Reconstructive Procedures of Kidney and Pelvi Ureteric Junction

- 5 Laparoscopic Pyeloplasty** 51
Manickam Ramalingam, Kallappan Senthil, George P. Abraham,
C. Mallikarjuna, Kesava Pillai Subramonian, R. Vijay, and G. Datson
- 6 Robotic Laparoscopic Pyeloplasty** 95
Hariharan Palayapalayam Ganapathi, Gabriel Ogaya-Pinies, Travis Rogers, and
Vipul R. Patel
- 7 Laparoscopic Ureteropyelostomy** 107
Manickam Ramalingam, K. Selvarajan, Kallappan Senthil, G. Rajamani,
and R.T. Dharmendra
- 8 Laparoscopic Ureterocalicostomy** 117
Manickam Ramalingam, Kallappan Senthil, Mizar G. Pai, and Anandan Murugesan
- 9 Laparoscopic Heminephrectomy for Duplex System** 125
Manickam Ramalingam, Kallappan Senthil, and Mizar G. Pai
- 10 Robot Assisted Laparoscopic Upper Pole Heminephroureterectomy** 133
V. Sripathi, Rajiv Padankatti, and Pavai Ganesan
- 11 Laparoscopic Management of Renal Cystic Disease** 141
Kallappan Senthil, N. Sivasankaran, Anandan Murugesan,
and Manickam Ramalingam
- 12 Laparoscopic Pyelolithotomy** 151
Kallappan Senthil, N. Sivasankaran, Anandan Murugesan, Mizar G. Pai,
and Manickam Ramalingam
- 13 Laparoscopic Anatomic Nephrolithotomy** 159
Nasser Simforoosh and Mohammad Hadi Radfar

14 Laparoscopic Partial Nephrectomy	165
Howard M.H. Lau, Peter Penkoff, Nian Zeng, and Yinong Niu	
15 Robot Assisted Laparoscopic Partial Nephrectomy	185
Sam Bhayani	

Part III Reconstructive Procedures of the Ureter

16 Laparoscopic Ureteroureterostomy	195
Manickam Ramalingam, Shailesh A. Shah, Prashanth Kulkarni, Kallappan Senthil, Anandan Murugesan, and Mizar G. Pai	
17 Robot Assisted Uretero Ureterostomy for Retrocaval Ureter	219
Prakash Johnson	
18 Laparoscopic Ureteric Reimplantation	225
Manickam Ramalingam, Kallappan Senthil, K. Selvarajan, Shrenik Shah, Mohan K. Abraham, and Anandan Murugesan	
19 Robotic Ureteric Reimplantation	259
Raj Patel and Ananthakrishnan Sivaraman	
20 Laparoscopic Boari Flap Ureteric Reimplantation	273
Manickam Ramalingam, Kallappan Senthil, and Anandan Murugesan	
21 Robot Assisted Boari Flap Ureteric Reimplantation	281
Anandan Murugesan and Rajiv Yadav	
22 Retroperitoneoscopic Ureterolithotomy	287
Kallappan Senthil and P. Rajendran	
23 Laparoscopic Ureterolysis	291
Sanjay B. Kulkarni	
24 Laparoscopic Intracorporeal Ileal Ureter	297
Allen Sim and Christian Schwentner	
25 Laparoscopy Assisted Ileal Ureter	303
Manickam Ramalingam, Kallappan Senthil, Nagesh Kamat, and P. Khandarwal	

Part IV Reconstructive Procedures of the Urinary Bladder

26 Laparoscopic Repair of Bladder Injuries	311
Manickam Ramalingam, V. Venkatesh, and Amudha Giridhar	
27 Laparoscopic Bladder Diverticulectomy	317
Manickam Ramalingam, Kallappan Senthil, and Mizar G. Pai	
28 Robot Assisted Laparoscopic Diverticulectomy	325
Vipul R. Patel and Hariharan Palayapalayam Ganapathi	
29 Laparoscopic Repair of Vesicovaginal Fistula	331
Manickam Ramalingam, C. Mallikarjuna, and Suma Natarajan	
30 Robotic-Assisted Vesico-Vaginal Fistula Repair	343
Jayapriya Jayakumaran, Hariharan Palayapalayam Ganapathi, Ravimohan Mavaduru, and Sejal D. Patel	
31 Laparoscopic Repair of Vesicouterine Fistula	351
Manickam Ramalingam, Kallappan Senthil, R. Renukadevi, and Vijayanthi Raja	

32	Laparoscopic Partial Cystectomy	359
	Renuka Ramalingam, Kallappan Senthil, and Mahesh R. Desai	
33	Robotic Partial Cystectomy for Urachal Tumours	373
	Arvind Ganpule and Mahesh R. Desai	
34	Laparoscopic Excision of Patent Urachus	379
	Kallappan Senthil and Manickam Ramalingam	
35	Laparoscopic Autoaugmentation of Bladder	387
	Manickam Ramalingam and K. Selvarajan	
36	Laparoscopic Ileocystoplasty	391
	Manickam Ramalingam, Kallappan Senthil, and Anandan Murugesan	
37	Laparoscopy Assisted Ileocystoplasty	401
	Manickam Ramalingam, Kallappan Senthil, and Anandan Murugesan	
38	Laparoscopic Undiversion with Augmentation Cystoplasty	407
	Manickam Ramalingam, Kallappan Senthil, Anandan Murugesan, and Mizar G. Pai	
39	Laparoscopic Ureterocystoplasty	415
	Manickam Ramalingam and Kallappan Senthil	
40	Laparoscopic Diverticulocystoplasty	435
	Manickam Ramalingam and Kallappan Senthil	
41	Laparoscopic Gastrocystoplasty	441
	Manickam Ramalingam, Kallappan Senthil, Anandan Murugesan, and T.S. Balashanmugam	
42	Laparoscopic Repair of Colovesical Fistula	447
	Manickam Ramalingam, K. Selvarajan, and Kallappan Senthil	
43	Laparoscopic Mitrofanoff Procedure	453
	N. Mallikarjuna Reddy	
44	Laparoscopy Assisted Ileocystoplasty with Mitrofanoff Procedure (Yang Monti Technique)	459
	Manickam Ramalingam, Kallappan Senthil, and Anandan Murugesan	
45	Robotic-Assisted Laparoscopic Mitrofanoff Appendicovesicostomy (RALMA)	469
	Eric D. Schadler, Vignesh T. Packiam, and Mohan S. Gundeti	
46	Laparoscopic Radical Cystectomy with Intracorporeal Ileal Conduit	483
	Nian Zeng and Yinong Niu	
47	Laparoscopy Assisted Ileal Conduit (in Neurogenic Bladder)	493
	Manickam Ramalingam and Kallappan Senthil	
48	Robot Assisted Radical Cystectomy with Intracorporeal Ileal Conduit	499
	Anandan Murugesan, Gagan Gautam, and Rajesh Ahlawat	
49	Laparoscopic Radical Cystectomy and Intracorporeal Ileal Neobladder	513
	Allen Sim and Christian Schwentner	
50	Laparoscopy Assisted Ileal Neobladder	527
	Manickam Ramalingam, Kallappan Senthil, Anandan Murugesan, and Mizar G. Pai	

51 Robotic Assisted Intracorporeal Neobladder Reconstruction: Surgical Technique	535
Murugesan Manoharan, Ahmed Saeed Goolam, Nikhil Vasdev, and Peter Wiklund	

Part V Reconstructive Procedures on Prostate

52 Laparoscopic Radical Prostatectomy: The Descending Technique (Saint-Augustine Clinic, Bordeaux, France).	549
Saïd Abdallah Al-Mamari and Jean-Luc Hoepffner	
53 Transperitoneal Ascending Laparoscopic Radical Prostatectomy.	561
Jens J. Rassweiler, Klein Jan, Fiedler Marcel, and Goezen Ali Serdar	
54 Robotic Assisted Radical Prostatectomy.	581
Hariharan Palayapalayam Ganapathi, Gabriel Ogaya-Pinies, Travis Rogers, and Vipul R. Patel	
55 Laparoscopic Madigan Prostatectomy	593
Nian Zeng	
56 Laparoscopic Excision of Seminal Vesicle Cyst	601
Manickam Ramalingam and Kallappan Senthil	

Part VI Reconstructive Procedure of the Undescended Testis

57 Laparoscopic Surgery for Undescended Testis	609
K. Selvarajan and Kallappan Senthil	

Part VII Single-Site Reconstructive Surgery

58 Laparoendoscopic Single-Site Reconstructive Surgery.	619
Abhay Rane and Sara L. Best	

Part VIII Kidney Transplantation

59 Laparoscopic Kidney Transplantation	629
Pranjal Modi	
60 Robot Assisted Renal Transplantation	639
Anandan Murugesan, Prasun Ghosh, and Rajesh Ahlawat	

Part IX Reconstructive Surgery for Uterine and Vaginal Prolapse

61 Laparoscopic Pelvic Floor Repair for Anterior Compartment Prolapse	651
Jean-Luc Hoepffner, Richard Gaston, and Thierry Piechaud	
62 Laparoscopic Sacrocolpopexy in Vault Prolapse	659
Ajay Rane, Jay Iyer, and Harsha Ananthram	
63 Robotic-Assisted Sacrocolpopexy for Comprehensive Repair of Multi-compartment Vaginal Vault Prolapse	667
Robert I. Carey, Jayapriya Jayakumaran, Celso Silva, Sejal D. Patel, and Hariharan Palayapalayam Ganapathi	

Part X Training in Laparoscopic and Robotic Reconstructive Surgery

64 Simple Novel Methods of Skill Transfer in Laparoscopic Urology Training . . .	677
Manickam Ramalingam, K. Selvarajan, and Kallappan Senthil	
65 Robotic Training and Validation	705
Nicholas Raison, Catherine Lovegrove, Kamran Ahmed, and Prokar Dasgupta	

Index.	711
-------------------------	-----

Contributors

George P. Abraham Department of Urology, PVS and Lakeshore Hospital, Cochin, Kerala, India

Mohan K. Abraham, MS, MCh, MBBS Department Paediatric Surgery, School of Medicine, Kochi, Kerala, India

Rajesh Ahlawat, MBBS, MS, MNAMS, MCh, FIMSA Division of Urology and Renal Transplant, Fortis Escorts Kidney and Urology Institute, New Delhi, India

David M. Albala, MD Division of Urologic Surgery, Duke University Medical Center, Durham, NC, USA

Said Abdallah Al-Mamari Urology Department, Saint-Augustine Clinic, Bergonié Oncological Institute, Bordeaux, France

Anandan Murugesan, MBBS, MS, MCh Department of Urology, PSG Institute of Medical Sciences and Research, Coimbatore, Tamil Nadu, India

Harsha Ananthram James Cook University, Townsville, QLD, Australia

T.S. Balashanmugam Department of the General Surgery, PSG Hospitals, Peelamedu Coimbatore, Tamil Nadu, India

Sara L. Best, MD Department of Urology, University of Wisconsin School of Medicine and Public Health, Madison, WI, USA

Sam Bhayani Faculty Practice Plan, Washington University School of Medicine, St. Louis, MO, USA

Chandra Shekhar Biyani, FRCS(Urol), FEBU Department of Urology, St. James's University Hospital, Leeds, UK

Robert Carey, MD, PhD, FACS Department of Urology, Florida State University College of Medicine, Sarasota, FL, USA

Prokar Dasgupta, MSc, MD, DLS, FRCS, FEBU MRC Centre for Transplantation, King's College London, London, UK

George Datson Lakeshore Hospital, Cochin, Kerala, India

Mahesh R. Desai MUPH, Nadiad, India

R.T. Dharmendra Department of Pediatric Surgery, Coimbatore Medical College, Coimbatore, Tamil Nadu, India

Sara Faisel BS – Research Coordinator, Associated Medical Professionals, Syracuse, NY, USA

Hariharan Palayapalayam Ganapathi University of Central Florida College of Medicine, Global Robotics Institute, Florida Hospital Celebration Health, Orlando, FL, USA

Pavai Ganesan, MS, MCh Department of Pediatric Surgery, PSG Medical College & Research Institute, Coimbatore, India

Arvind Ganpule MUPH, Nadiad, India

Richard Gaston Clinique Saint-Augustin, Avenue Dares, Bordeaux, France

Gagan Gautam Urologic Oncology & Robotic Surgery, Max Institute of Cancer Care, New Delhi, India

Prasun Ghosh Medanta Hospitals, New Delhi, India

Amudha Giridhar GKNM Hospital, Papa Nayaken Palayam, Coimbatore, Tamil Nadu, India

Daniel Glassman Department of Surgery, Hull Royal Infirmary, Hull, UK

Jean-Luc Hoepffner Surgeon, Lap and Robotic Oncological Urologic Surgery, Clinique Saint-Augustin, Avenue Dares, Bordeaux, France

Jay Iyer James Cook University, Townsville, QLD, Australia

Klein Jan Department of Urology Medical School Ulm, University of Ulm, Ulm, Germany

Jayapriya Jayakumaran Center for Reproductive Medicine, Orlando, FL, USA

Prakash Johnson Sunderland Royal Hospital, Sunderland, UK

Nagesh Kamat, MCh(Uro) Kamats Kidney Hospital, Baroda, Gujarat, India

Kamran Ahmed Institute of Kidney Diseases, Ahmadabad, India

P. Khandewal, MS, MCh(Uro) Kamat Hospital, Baroda, India

Prashanth Kulkarni Department of Urology, Narayana Health, Bangalore, Karnataka, India

Sanjay B. Kulkarni, FRCS Kulkarni Endosurgery Institute and Reconstructive Urology Centre, Pune, India

Howard M.H. Lau, MBBS (Syd.), FRACS (Urol.) Western Sydney University, Sydney, NSW, Australia

Westmead Private Hospital, Sydney, NSW, Australia

Catherine Lovegrove MRC Centre for Transplantation, King's College London, London, UK

C. Mallikarjuna Asian Institute of Nephrology and Urology, Hyderabad, Telangana, India

Fiedler Marcel Department of Urology, SLK Kliniken Heilbronn, University of Heidelberg, Heilbronn, Germany

Ravimohan Mavaduru Post Graduate Institute of Medical Education and Research (PGIMER), Chandigarh, India

Mohan S. Gundeti, MBBS, MCh, FEBU, FRCS, FEAPU Section of Urology, Department of Surgery, University of Chicago Medicine, Comer Children's Hospital, Chicago, IL, USA

Pranjal Modi Institute of Kidney Diseases, Ahmadabad, India

Suma Natarajan Department of Obstetrics and Gynecology, Ganga Women and Child Centre, Coimbatore, Tamil Nadu, India

Yinong Niu Chayo Yang Hospital, Beijing, China

- Gabriel Ogaya-Pinies** University of Central Florida College of Medicine, Global Robotics Institute, Florida Hospital Celebration Health, Orlando, FL, USA
- Vignesh T. Packiam, MD** Section of Urology, Department of Surgery, University of Chicago Medicine, Comer Children's Hospital, Chicago, IL, USA
- Rajiv Padankatti, DNB, DNB** Apollo Children's Hospital, Chennai, India
- Mizar G. Pai** Urology clinic, Gowtham annexe, Coimbatore, Tamil Nadu, India
- Raj Patel** Apollo Hospitals, Chennai, India
- Sejal D. Patel** Center for Reproductive Medicine, Orlando, FL, USA
- Vipul R. Patel** University of Central Florida College of Medicine, Global Robotics Institute, Florida Hospital Celebration Health, Orlando, FL, USA
- Peter Penkoff, MBBS, FRACS** Westmead Private Hospital, Sydney, NSW, Australia
- Thierry Piechaud** Clinique Saint-Augustin, Avenue Dares, Bordeaux, France
- Mohammad Hadi Radfar** Department of Urology, Urology and Nephrology Research Center, Shahid Labbafinejad Hospital, Shahid Beheshti University of Medical Sciences, Tehran, Iran
- Nicholas Raison, MBBS, BSc, MRCS** MRC Centre for Transplantation, King's College London, London, UK
- Vaijayanthi Raja** Balaji Nursing Home, Coimbatore, Tamil Nadu, India
- G. Rajamani** Department of Pediatric Surgery, Coimbatore Medical College, Coimbatore, Tamil Nadu, India
- P. Rajendran, MCh(Uro)** Madhava Hospital, Pondicherry, India
- Manickam Ramalingam** PSG Hospitals, Coimbatore, Tamil Nadu, India
- Renuka Ramalingam** Urology Clinic, Gowtham Annexe, Coimbatore, Tamil Nadu, India
- Abhay Rane, OBE, MS, FRCS, FRCS(Urol)** East Surrey Hospital, Surrey, UK
- Ajay Rane** James Cook University, Townsville, QLD, Australia
- Jens J. Rassweiler, MD** Department of Urology, SLK Kliniken Heilbronn, University of Heidelberg, Heilbronn, Germany
- N. Mallikarjuna Reddy** JJ Childrens Kidney and Urology Clinic, Global Hospitals Lakdikapul, Hyderabad, India
- R. Renukadevi** Urology Clinic, Gowtham Annexe, Coimbatore, Tamil Nadu, India
- Travis Rogers** University of Central Florida College of Medicine, Global Robotics Institute, Florida Hospital Celebration Health, Orlando, FL, USA
- Eric D. Schadler, MD** Section of Urology, Department of Surgery, University of Chicago Medicine, Comer Children's Hospital, Chicago, IL, USA
- Christian Schwentner** Department of Urology, Eberhard-Karls University, Tuebingen, Germany
- K. Selvarajan, MCh** Paediatric Surgery, K.G. Hospital and Postgraduate Institute, Coimbatore, India
- Kallappan Senthil, MCh(Urol, FRCS)** Gowtham Annexe, Coimbatore, India

Goezen Ali Serdar Department of Urology, SLK Kliniken Heilbronn, University of Heidelberg, Heilbronn, Germany

Shailesh A. Shah, MBBS, MS, MCh, FICA Department of Urology, Bodyline Hospitals, Ahmedabad, Gujrat, India

Shrenik Shah Civil Hospital, Ahmedabad, India

Allen Sim, MBBCh BAO(NUI), MRCS, FAMS, FRCS Department of Urology, Singapore General Hospital, Singapore, Singapore

Nasser Simforoosh Department of Urology, Urology and Nephrology Research Center, Shahid Labbafinejad Hospital, Shahid Beheshti University of Medical Sciences, Tehran, Iran

Ananthakrishnan Sivaraman Apollo Hospitals, Chennai, Tamil Nadu, India

N. Sivasankaran Urology Clinic, Gowtham Annexe, Coimbatore, India

V. Sripathi, MS, MCh, FRACS Division of Pediatric Urology, Apollo Children's Hospital, Chennai, India

Kesava Pillai Subramonian University Hospital Birmingham, Birmingham, UK

V. Venkatesh V G Hospital, Coimbatore, Tamil Nadu, India

R. Vijay PVS Hospitals, Cochin, Kerala, India

Rajiv Yadav Medanta - The Medicity Hospital, Gurgaon (Delhi, NCR), Haryana, India

Marina Yiasemidou Leeds Institute of Biomedical and Clinical Sciences, University of Leeds, Leeds, UK

Nian Zeng Department of Urology, Chayo Yang Hospital, Capital Medical University, Beijing, China

Part I

Introduction

Hariharan Palayapalayam Ganapathi,
Gabriel Ogaya-Pinies, Travis Rogers, and Vipul R. Patel

1.1 Introduction

The evolution of robots in surgical practice is an intriguing story that spans cultures, continents and centuries. The idea of reproducing himself with the use of a mechanical robot has been in man's imagination in the last 3000 years. However, the use of robots in medicine has only 30 years of history. Surgery has traditionally required larger incisions to allow the surgeon to introduce his hands into the body and to allow sufficient light to see the structures being operated on. Surgeon directly touched and felt the tissues and moved the tip of the instruments. However, innovations have radically changed the performance of surgical procedures in operating room by digitization, miniaturization, improved optics, novel imaging techniques, and computerized information systems. These surgical procedures can be done by manipulating instruments from outside the patient, by looking at displays of direct electronic images of the target organs on the monitor. The robot completes the transition to the Information Age. The surgeon is immersed in this computer-generated environment (called "virtual reality," term coined by Jaron Lanier, 1986) and sends electronic signals from the joysticks of the console to the tip of the instruments, which mimic the surgeon's hand movements [1].

This chapter highlights the history of the robotic surgical platform, the current place of robot assisted surgery and the future emerging trends in robotic surgery.

1.2 History of Robotics

The first automated machine was built probably in 1300 BCE, when Amenhotep erected the statue of King Memnon, which emitted sound when sunlight fell on it at dawn [1]. King-shu Tse (500 BCE) in China designed a flying magpie and a wooden horse that can jump. In 400 BCE, Archytas of Tarentum in Greece, the father of mechanical engineering, designed a wooden bird which was propelled by steam. The philosophy of automation was first expounded by Aristotle in the fourth century BCE. Archimedes (287–212 BC) invented many mechanical systems that are used in robotics today. Automaton were described in Alexandria, Roman province of Ptolemaic Egypt. Ctesibius of Alexandria (250 BC) designed the 'clepsydra' an accurate continuously working water-clock with moveable figures on it. Heron of Alexandria (10–70 AD) made several automaton, including animated statues.

In 1901, between the islands of Crete and Kythera, a diver found the remnants of "The Antikythera Device, a mechanical computer which most likely calculated the position of the sun, moon or other celestial bodies. It dates back 2000 years and is considered to be of Greek origin. Medieval times featured the era of Automaton, moving human-like figures run by hidden mechanisms. The clock jack was a mechanical figure that could strike time on a bell with its axe.

In 1495, Leonardo da Vinci, the genius Italian sculptor, painter, architect, engineer, anatomist and mathematician designed the first humanoid robot (Fig. 1.1), "the mechanical knight" that can sit up, wave its arms, and move its head via a flexible neck while opening and closing its jaw [2]. In 1645, Blaise Pascal invented a calculating machine, the Pascaline, one of it is in display in the Des Arts et Metiers Museum in Paris.

In the eighteenth century, miniature automaton became popular as toys that can move like humans or small animals. John Brainerd created the Steam Man used to pull wheeled carts in 1865 and its electric vision the "Electric Man" was

H.P. Ganapathi (✉) • G. Ogaya-Pinies • T. Rogers • V.R. Patel
University of Central Florida College of Medicine, Global
Robotics Institute, Florida Hospital Celebration Health,
410 Celebration Place, Orlando, FL 34747, USA
e-mail: hari.uro@gmail.com




Fig. 1.1 Humanoid automaton, designed by Leonardo da Vinci, it is believed to be able to perform several human-like motions

built by Frank Reade Jr in 1885. The Industrial Revolution of the late eighteenth century led to the development of complex mechanics and electricity that paved the way for robotic advancement and its application in surgery.

1.3 Evolution of Surgical Robot

The term “robot” was first used in a play called “R.U.R.” or “Rossum’s Universal Robots” (from Czech *robota* meaning “forced work”) by the Czech writer Karel Capek in 1921 [3]. The term robotics was first adopted by Isaac Asimov, a scientist and writer in 1941 and refers to the study and use of robots. However robot is scientifically defined as ‘*a re-programmable, computer controlled mechanical device equipped with sensors and actuators*’. An important early concept in robotic surgery was ‘telepresence’. Telepresence robotic arms were developed in 1951 by Raymond Goertz, while working for the Atomic Energy Commission (USA) and this was used to handle hazardous radioactive material. This marked a major milestone in force feedback (haptic) technology. In 1961 George Devol and Joseph Engelberger developed the first industrial robot called Unimate for General Motors [4]. As a result, Engelberger has been called the ‘father of robotics’. These successful experiments were determining factors for the introduction of robotics in all other industrial areas around the world. Hence, the labor intensive or dangerous tasks, especially those that required high precision were performed by the industrial robot.



Fig. 1.2 Unimate PUMA 200 first robot used in a surgical intervention during a stereotactic brain biopsy

1.3.1 Pre-programmable Robot

In 1978 Victor Scheinman developed the Programmable Universal Manipulation Arm (PUMA – Fig. 1.2), and this became widely used in industrial operations. In 1985 Kwok used PUMA to perform neurosurgical biopsies [5]. *Its accuracy and success* led to its application in urology surgeries at the Imperial College in London, in 1988. This robot was substituted in prostate surgery by the surgeon-assistant robot for prostatectomy (SARP) and the prostate robot (PROBOT – Fig. 1.3), and in urological procedures by UROBOT. These robots had to be preprogrammed based on the fixed anatomic landmarks of each patient.

1.3.2 Robotic Telesurgery

The United States mission to put man on Mars led NASA’s Ames Research Center to develop research projects to perform long-distance surgeries in astronauts. Michael McGreevey, Stephen Ellis, and Scott Fischer developed a head-mounted display (HMD) that consisted of tiny television monitors attached to a helmet immersed in a three-dimensional (3D) environment. HMD combined with data gloves, created by



Fig. 1.3 The PROBOT was able to performed precise and repetitive cone shaped cuts of the prostate following an pre-establish plan

Jaron Lanier, allowed the user to interact with the virtual world. The computer scientist, Scott Fischer, and the plastic surgeon, Joseph Rosen, produced the first idea of telepresence surgery to perform remote surgeries in space. They achieved it by combining SRI telemanipulator with the HMD and data glove. The telepresence surgery was not technically feasible. The HMD was replaced with monitors and the data gloves with handles for controllers at the surgeon's console.

The US military assigned Richard Satava to be program manager for Advanced Biomedical Technologies of the government-run Defense Advanced Research Projects Agency (DARPA). Philip Green, at the Stanford Research Institute (SRI), and the military surgeon Richard Satava joined and developed an operating system for instrument telemanipulation, the "Satava and Green Telepresence system" with the goal of improving surgical capabilities on the battlefield. DARPA provided grant for the development of a robotic system the 'Bradley 557A' that could "virtually" take the surgeon to the front lines to provide medical assistance to wounded soldiers in the battlefield. A pivotal point for the Green Telepresence Surgery System came in 1994 when Jon Bowersox, the medical scientist for the program, performed an intestinal anastomosis on ex-vivo porcine intestine using a wireless microwave connection [6].

1.3.3 Robodoc

ROBODOC (Fig. 1.4) robot was designed to mill bone to precisely fit a prosthesis in hip replacement surgery, which improves the bonding of the bone to the prosthesis [7]. This first generation of surgical robots was notable for performing image-guided precision tasks, which preoperatively requires



Fig. 1.4 ROBODOC used for the first time in 1988, during a total hip replacement

the surgeon to view CT images and select the appropriate implant and its placement. The surgeon must participate in the registration of the pre-operative images by locating anatomical landmarks to synchronize the CT images with the physical patient. In August 2008, ROBODOC obtained FDA approval for total hip arthroplasty and is currently the only FDA-approved robot for orthopedic surgery.

1.3.4 Automated Endoscopic System for Optimal Positioning (AESOP)

The evolution of surgical robots has led to a current generation of real-time telemanipulators. Yulun Wang received funding from DARPA and designed a robotic arm to hold a laparoscopic camera. His company, Computer Motion, commercialized the AESOP (the robotic laparoscopic camera holder – Fig. 1.5), which was later used in the ZEUS robot.



Fig. 1.5 AESOP® (Automated Endoscope System for Optimal Positioning), is a voice-activated robot used to hold the endoscope

The system was designed to assist the surgeon by taking control of the laparoscopic camera and responding to voice commands [8]. The Food and Drug Administration (FDA) approved AESOP in 1994 as an endoscopic camera manipulator, eliminating the need of an assistant to perform this task. It became the first robot to assist surgeons in operating room [9].

1.3.5 Zeus

Wang obtained funding from DARPA to develop a robot capable of reproducing the movements of the arms of the surgeon. As a result, the Zeus system was created with arms and surgical instruments controlled by the surgeon. The FDA cleared ZEUS in October 2001 to assist in the control of blunt dissectors, retractors, graspers, and stabilizers during laparoscopic and thoracoscopic surgeries.

ZEUS (Fig. 1.6) has three robotic arms that are mounted on the operating table, one of which is AESOP. The other two arms of ZEUS are the extension of the left and right arms of the surgeon. Surgeons sit at a console and wear special glasses that create a three-dimensional image. The ZEUS robotic surgical system was first used in a fallopian tube anastomosis at the Cleveland Clinic, Ohio, USA, in July 1998 [10]. On September 3, 2001, ZEUS was used for the first-ever transatlantic telesurgery (“Operation Lindbergh”). Using a fiber-optic cable running from a ZEUS console in New York, USA, to the robot operating on the patient in Strasbourg, France, Marescaux successfully performed a telerobotic cholecystectomy [11]. This was a major landmark for surgery. In 2003, the Computer Motion, Inc., merged with Intuitive Surgical Inc. and discontinued the development of the ZEUS.

1.3.6 da-Vinci Surgical System

H. Moll, a surgeon and an entrepreneur, acquired the license to the telepresence surgical system and created Intuitive Surgical company which commercialized the prototype into the da Vinci robot (Fig. 1.7), the master–slave device. There are four main components to da Vinci (Fig. 1.8): the surgeon console, patient-side cart, EndoWrist Instruments, and Insite Vision System with high resolution 3D Endoscope and Image Processing Equipment. The surgeon sits at a remote console, and directly controls the motion of instruments in the surgical field on the other side of the room. A computer monitors surgeon’s hand position which is sampled at over 1300 times per second as the case proceeds. Using motion sensor information and kinematic models of the master and slave, the computer system computes, the actuator drive commands necessary to move the robot arms and provide feedback. Technical improvements, such as highly magnified 3D vision, precisely controlled EndoWrist instruments with seven degrees of freedom, magnification of the image up to 10×, physiologic tremor filtering, motion scaling of up to 5:1, and better ergonomics made the robotic platform more attractive for surgeons to use da Vinci. In 2000 the da Vinci obtained FDA approval for general laparoscopic procedures and became the first operative surgical robot in the US. In 2004, the SRI, International team, received funding from DARPA for the project called “trauma-pod” (TP). This was the first phase of a multiphase program to develop an “operating room with the patient being the only human in the surgical cell” and conducted the first successful demonstration in 2007. With modifications (Figs. 1.9 and 1.10a, b) da-Vinci is currently the most widespread robotic surgical system, with more than 3400 units sold [12] and more than 600,000 surgical procedures performed worldwide [13].




Fig. 1.6 The ZEUS Robotic Surgical System (ZRSS) was a medical robot designed to assist in surgery, originally produced by the American robotics company Computer Motion

1.4 Future Trends and Challenges in Surgical Robotics

1.4.1 Haptics

The existing da Vinci platform does not provide haptic feedback to the surgeon. Surgeons must use visual cues of the tissues and objects (instruments, suture, etc.) as they are being handled to derive estimated forces. This is a big concern for robotic surgery. Hence, providing haptic feedback will be the next step for robotic surgery. Some researchers have demonstrated that overlaying color markings on tissues or warning sounds that alarm as forces applied exceed certain thresholds can improve surgical performance. Researchers have created specialized grippers that can attach to the jaw of the existing instruments to provide haptic feedback. The forces that a robot experiences during the course of a surgery can be converted to electrical signals that can then distort the shape of telemanipulators, so that the surgeon receives some form of touch sensation feedback.

Research is ongoing to create Virtual fixtures or “no-go” zones by altering software of the robot to limit the movements of the surgical instruments (Microsoft’s Kinect video technology incorporation into the Raven’s software). These could be used to protect vital structures or oncologic margins from being violated through routine robotic dissection.

Virtual fixture technology is also being explored for automation of certain repetitive steps, such as throwing a suture line once the line is marked out by the surgeon.

1.4.2 Visual Feedback

Nonhaptic technologies utilise embedding nonhaptic sensors such as microscopic size LED (light-emitting diodes as in pulse oximeter) into the tips of the instruments, to provide information about tissue oxygenation and blood flow data to the surgeon. The clinical relevance is that instead of haptic feedback, a more valuable metric might be whether the forces applied are causing tissue ischemia. The Surgeon’s Operating Force-feedback Interface Eindhoven (SOFIE) robot from the Netherlands is a portable surgical robot that incorporates haptics into the system [14].

Tissue-specific fluorescent-tagged antibodies (fluorophores) that can target specific tumor cells (tumor paint) promise to be another feedback. Cancers can be visualized with hyperspectral imaging sensors. Incorporating the visual data from the tumor paint to software control algorithms, the surgical robot can prevent a surgeon from inadvertent tumor violation during extirpation. These “virtual fixtures” can be used for creating “no-fly” or “no-go” zones to avoid dangerous structures such as delicate vasculature and tissues.

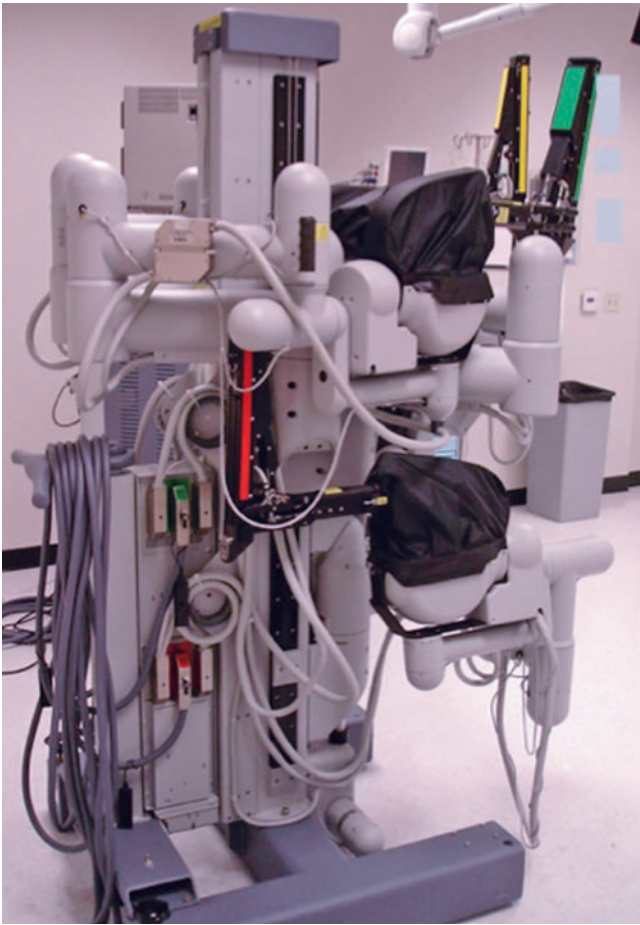


Fig. 1.7 da Vinci Standard System, model approved by the FDA in the year 2000

1.4.3 Advancement in Vision

Visual enhancement systems can further enhance the operator's vision, importing anatomic overlay and heads-up displays. It can also offer an array of 'optical biopsy' capabilities such as confocal microscopy, optical coherent tomography (OCT) and others, enabling real-time microscopy, even molecular imaging.

1.4.4 Image Integrated Surgery

Anatomic and physiologic data can be integrated into the operative field. Preoperative or intraoperative imaging (e.g., CT, MRI, or ultrasound imaging) information can be integrated, registered, with the surgical device, so that the imaging information can be fused with the computer visual field. This provides the potential for visual overlays of anatomy, function, even tumor mapping, such that the surgeon could 'see into' the tissues. In this environment, the surgeon would never need to disengage to look at MRI images. Virtual barriers could be mapped into the operative field, identifying 'no fly zones'.

This information could be used to guide surgical procedures intraoperatively, or to simulate a proposed procedure. The surgical workstation may also be augmented with audio capabilities to alert the surgeon to data coming from outside of the camera field of view. Surgeon might call in other experts in the field when a critical or unexpected situation occurs.

1.4.5 Miniaturization

Future electromechanical technology may allow robots to be miniaturized to the point where they can enter the human body and perform surgery by remote control, or even autonomously. These intraluminal microrobot or multiple tiny robots can be inserted intra-abdominally, intrathoracically or even through natural orifices as a "squad" of robots each with a specific function (camera, light source, grasper, retractor, electrocoagulator) and the surgeon, acting like a commander, regulating the motion of the multiple robots. These microrobots can be inserted into body via a single port. This will save a lot of time that is wasted on the preparation, docking, and undocking of the robots. Moreover, this will be a true single-port surgery as compared to the currently practiced single-port techniques (which are truly multiple port, single incision surgeries). Such extreme miniaturization would require extensive reworking of current surgical paradigms. Next-generation micro-instruments are being constructed using microelectromechanical systems devices (MEMS) which are less than a millimeter in size. The advantage of MEMS is that both the sensors and actuators can be included on a single instrument. This will provide haptic feedback to the surgeon. These smaller endoscopes and instruments may find use in fetal robotic surgery in the future.

1.4.6 Improved Mobility

Current robots work best when the surgical field is limited to a relatively small area, such as a single quadrant of the abdomen. Future devices will need improved flexibility so that they can easily be deployed to access entire body cavities without reconfiguration. Mobility of the robotic device itself is also an issue – current devices are large and difficult to move, and do not lend themselves to use outside an operating room environment, such as in the battlefield. Mobility of robotic devices will improve as they miniaturization improves and the footprint of the devices becomes smaller.

1.4.7 Independent/Autonomous Robotic Surgery

Automation in future robots will start with that of routine tasks, such that robot completes the suture line if the surgeon

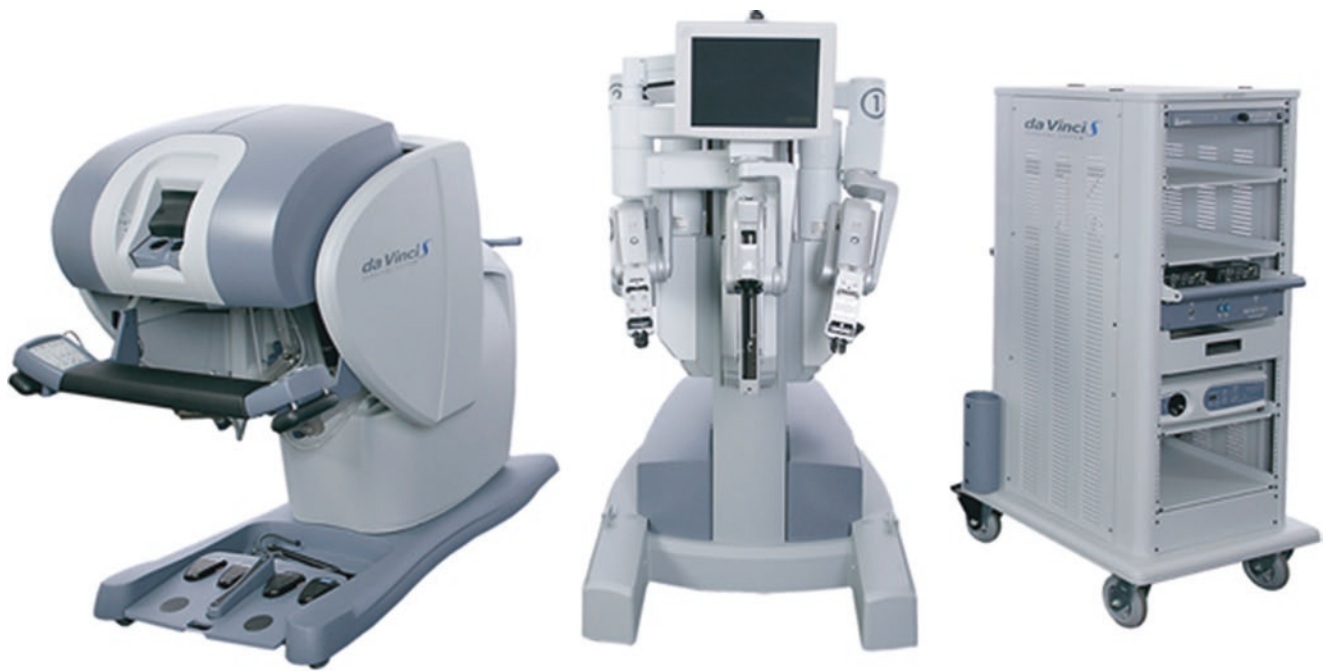

Fig. 1.8 The three components of the da-Vinci S (Intuitive Surgical, Sunnyvale, California), released in 2006: surgeon console, patient-side cart and the image- processing vision cart

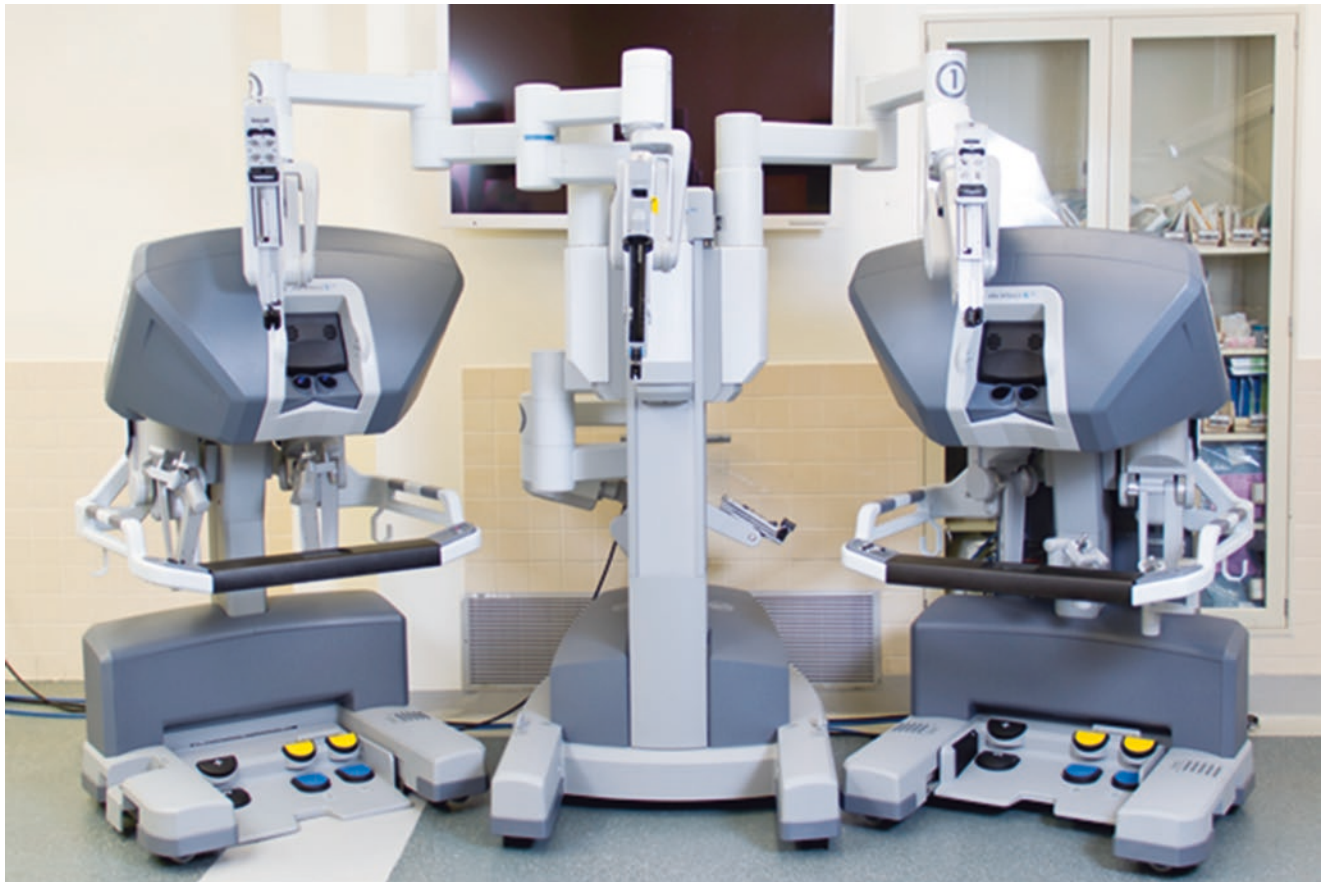

Fig. 1.9 The da Vinci Si dual console (Intuitive Surgical, Sunnyvale, California) allows a surgical mentor to teach with both the mentor and the trainee working at a surgeon console simultaneously

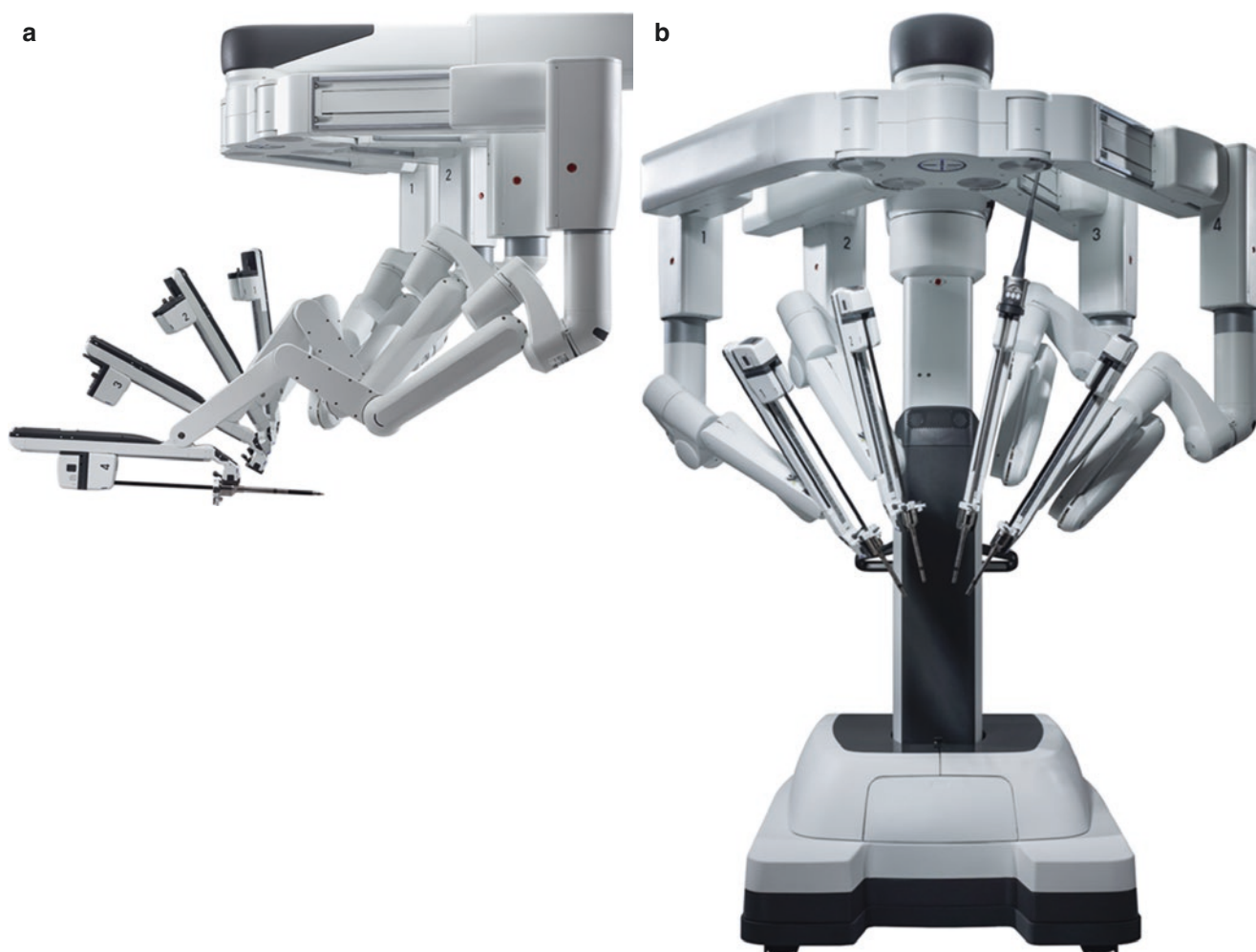


Fig 1.10 da Vinci Surgical System Xi model released in 2014. (a) Overhead boom with lighter arms, the arms rotate as a group. (b) Laser target to facilitate the docking and the 8 mm endoscope

indicates a start and a finish point. Robots can use “artificial intelligence” to learn from the surgeon operating the device. They can become skilled assistants in the future. If a robot acquires technical or cognitive knowledge from a large group of surgeons, it can serve as a computerized “colleague” to provide technical assistance in routine or unusual operative situations [15].

1.4.8 Surgical Team Robotic Augmentees

Future devices can augment human capability, task performance, and enhance the surgical team. ‘Penelope’ is a commercially available robot to replace the scrub technicians. By incorporating the tool changer (scrub nurse) and supply dispenser (circulating nurse) into the current robotic system, along with the electronic control of current anesthesia machines, it will be possible to eliminate all the humans

from the OR except for the patient. This can reduce 61 % of the OR cost. Contamination with dust, bacteria, and other microscopic particles will be dramatically controlled in the OR with no people.

1.4.9 Operating Room Integration

An operating room can become a computer system, with surgical robots integrated into perioperative workflow and process. Integrated computerized tracking of surgical activity, workflow, use of materials, devices, consumables, can enhance task performance, quality of care, and ultimately patient safety. All items are tracked and automatically accounted for, and their locations within the OR are known at all times by the use of radio frequency identification tags. Thus, turnaround time can be dramatically reduced.

1.4.10 Latency in Signal Transmission

The major concern with tele/remote surgery is the latency of the signals as the data are transmitted in compressed form. Any procedures with more than 300-ms latency have significant increase in error. There are techniques (e.g., move-and-wait, very slow motions, low-fidelity video transmission) that help the surgeon to compensate this delay. Experiments controlling the Raven robot between Seattle and a NASA underwater habitat off the coast of Florida using regular internet connectivity showed that the latency for robotic instrument movements was manageable. The challenge is in video transmission. The da Vinci system has exceptional optics that provide high-definition three-dimensional video, and the majority of the digital signal between the da Vinci components are in the form of video data. Either lesser video quality or improved video compression technologies required to be incorporated into future robotic systems to afford effective telesurgical capabilities.

1.4.11 Signal Security

The accuracy and signal's integrity is vital to successful and safe telesurgery. Multiple transmission pathways would be required for redundancy of signal in the event that one or two signals were impeded. Additional safeguards will be required beyond signal security if we are to rely on telesurgical practice. If a signal is hacked or corrupted by an ill intention hacker and if movements of the instruments are suddenly discordant with the primary surgeon's pattern, machine learning algorithms may be able to identify and the system may ask for verification of identity before allowing the surgeon to proceed.

1.5 Conclusion

Initially robotic surgery was a fantasy that existed only in the minds of science fiction writers, but today it is a scientific fact. The robotic technology is still in its infancy. But the rate of innovation holds great promise for the rapid advancement of patient care. There is no doubt that the future of robotics in

surgery is full of surprises. This technology is rapidly developing in a smarter and faster way, similar to the way that minimally invasive surgical instrumentation progressed from the 1990s to the present. For these developments to be truly relevant in surgery, the surgeon has to collaborate with technical developers, and find areas in their own specialties where these technologies will be useful. Similar to the advent of minimally invasive surgery, it is foreseeable that robotic technology will change surgical paradigms in the decades to come.

References

1. Chauhan S, Coelho RF, Kalan S, Satava RM, Patel VR. Evolution of robotic surgery: past, present, and future. In: Patel VR, editor. *Robotic urologic surgery*. 2nd ed. London: Springer; 2012. p. 3–10.
2. Yates DR, Vaessen C, Roupert M. From Leonardo to da Vinci: the history of robot assisted surgery in urology. *BJU Int*. 2011;108(11):1708–13. doi:10.1111/j.1464-410X.2011.10576.x; discussion 1714.
3. Kalan S, Chauhan S, Coelho RF, Orvieto MA, Camacho IR, Palmer KJ, Patel VR. History of robotic surgery. *J Robotic Surg*. 2010;4:141–7. doi:10.1007/s11701-010-0202-2.
4. Patel V, editor. *Robotic urologic surgery*. 1st ed. London: Springer; 2007. p. 2.
5. Kwoh YS, Hou J, Jonekheere EA, Hayall S. A robot with improved absolute positioning accuracy for CT guided stereotactic brain surgery. *IEEE Trans Biomed Eng*. 1988;35:153.
6. Bowersox JC, Shah A, Jensen J, Hill J, Cordts PR, Green PS. Vascular applications of telepresence surgery: initial feasibility studies in swine. *J Vasc Surg*. 1996;23:281–7.
7. Cowley G. Introducing 'Robodoc'. A robot finds his calling – in the operating room. *Newsweek*. 1992;120:86.
8. Unger SW, Unger HM, Bass RT. AESOP robotic arm. *Surg Endosc*. 1994;8:1131.
9. Jacobs LK, Shayani V, Sackier JM. Determination of the learning curve of the AESOP robot. *Surg Endosc*. 1997;11:54–5.
10. Falcone T, Goldberg J, Garcia-Ruiz A, Margossian H, Stevens L. Full robotic assistance for laparoscopic tubal anastomosis: a case report. *J Laparoendosc Adv Surg Tech A*. 1999;9:107–13.
11. Marescaux J, Leroy J, Gagner M, et al. Transatlantic robot-assisted telesurgery. *Nature*. 2001;413(6854):379–80.
12. Leal Ghezzi T, Campos Corleta O. 30 Years of robotic surgery. *World J Surg*. 2016;40:2550–7.
13. Intuitive surgical 2014 Annual Report.
14. Bogue R. Robots in healthcare. *Ind Robot*. 2011;38:218Y223.
15. Herron DM, Marohn M. A consensus document on robotic surgery prepared by the SAGES-MIRA Robotic Surgery Consensus Group. Society of American Gastrointestinal and Endoscopic Surgeons. <http://www.sages.org>.

Entry and Exit: Transperitoneal Laparoscopic and Robotic Approach

2

Sara Faisel and David M. Albala

2.1 Introduction

It is imperative for a surgeon performing a laparoscopic and/or robot-assisted procedure to follow the basic principles of entry and exit to ensure a safe outcome. Engaging in shortcuts may have a strong potential to convert a relatively straightforward procedure into a formidable venture.

Most of the organs in the genitourinary system lie within the retro-peritoneum or in the extraperitoneal space. The retro-peritoneum can be entered either directly or transperitoneally. The choice of the appropriate approach depends upon the operation to be performed, the patient's body habitus and the skills of the surgeon. Most urologic laparoscopic and robotic procedures can be safely accomplished via a transperitoneal approach, which has the advantage of familiar anatomy with ample landmarks to orient the surgeon, however, it does expose the abdominal viscera to a potential risk of injury and adhesion formation.

2.2 Indication

Laparoscopic and robotic urologic surgery can be divided into three categories: ablative, diagnostic and reconstructive. Ablative procedures are, by far, most commonly performed in adults, while limited diagnostic studies are more often performed in children. Reconstructive procedures are the most technically challenging and require advanced laparoscopic skills. With the advancement in techniques and instrumentation, many reconstructive urologic procedures are becoming more common. The indications are the same as open surgery and at the present time, almost all open urological procedures have been performed laparoscopically and more recently, robot assisted.

S. Faisel

BS – Research Coordinator, Associated Medical Professionals,
1226 East Water Street, Syracuse, NY 13210, USA

D.M. Albala (✉)

M.D. – Medical Director, Associated Medical Professionals,
1226 East Water Street, Syracuse, NY 13210, USA
e-mail: dalbala@ampofny.com

2.3 Contraindication

The list of contraindications is fast shrinking and is dependent upon the surgeon's skills. However, for a majority of urologists, the major contraindications can be categorized as follows:

1. *Infectious states*
 - (a) Peritonitis
 - (b) Abdominal wall infection
 - (c) Sepsis
2. *Anatomic*
 - (a) Bowel obstruction
 - (b) Multiple adhesions
 - (c) Large abdominal aortic aneurysm
 - (d) Abdominal wall/umbilical hernia
 - (e) Near term pregnancy
 - (f) Morbid obesity
3. *Systemic factors*
 - (a) Severe cardiopulmonary disease
 - (b) Uncorrected coagulopathy

2.3.1 Preparation

The preparation for surgery begins with obtaining an informed consent. This discussion should include the alternative treatment options available to the patient as well as the risks and benefits of each treatment. The possibility of conversion to an open procedure should always be discussed.

We routinely give a mechanical and antibiotic bowel preparation to all patients undergoing laparoscopic kidney and bladder procedures. This maneuver helps with the bowel dissection and mobilization by minimizing visual interference. Antibiotic bowel preparation reduces the morbidity should a bowel perforation occur during the procedures.

2.4 Techniques for Safe Trocar Insertion

2.4.1 Primary Trocar

The first trocar is usually used to introduce the pneumoperitoneum and can be inserted by either a closed or open technique. The technique used is usually based on the experience of the surgeon.

2.4.2 Closed Technique

The pneumoperitoneum is established by the closed technique using a Veress needle. This is a 14-gauge needle that is 12–15 cm in length as shown in Fig. 2.1.

It has an outer beveled tip that cuts through the tissue. The blunt tip stylet of the inner cannula is retractable and serves as a safety mechanism. In Fig. 2.2, the mechanism of entry of the Veress needle is demonstrated. As the needle traverses the fascia and enters the peritoneum, the blunt tip springs forward upon entering an open space. This blunt stylet protects the abdominal contents from the sharp outer cannula. Before the introduction of the Veress needle into the abdomen, it can be confirmed that the mechanism is intact as shown in Fig. 2.3.

The most favored site for introduction of the Veress needle is at the level of the umbilicus. It is at this level that the fascia layers are most tethered, making penetration into the abdomen easier. However, if this site is not available because of a previous scar or hernia, other sites may be used. To introduce the Veress needle into the abdomen, a periumbilical, vertical incision is made. The incision is lengthened to ensure that it can accommodate the outer diameter of the trocar; this helps to prevent excess force being placed on the trocar during insertion.

Problem: A too large or too small skin incision.

Solution: To ensure that the incision is the correct length, take the outer cannula of the trocar and make an impression on the skin. This serves as a guide for the length of the incision.

The Veress needle is then advanced at a right angle to the fascia, simultaneously lifting the abdominal wall away from the underlying viscera by using towel clips as shown in Figs. 2.4 and 2.5.

As the needle advances through the fascia and the peritoneum, two distinct pops may be felt. The first pop occurs when the abdominal wall fascia is traversed and a second pop is associated with an audible click as the inner cannula springs forward upon entering the peritoneum.

Problem: Insufflation within omentum giving a bubbly appearance as shown in Fig. 2.6.

Solution: After inserting the secondary trocar, a nick can be made to deflate the bubbly appearing omentum.

Problem: Injury to deep structures including great vessels.

Solution: Deep penetration of the Veress needle into the abdominal cavity should be avoided to minimize the risk of great vessel injury.

To check for correct placement of the needle, a 10 cc syringe with saline is attached to the Veress needle. Initially, it is aspirated to look for blood, enteric contents, or air. After

this, saline is irrigated to see if free flow into the abdomen is possible. The syringe barrel is then removed and the saline in the Veress needle should flow freely into the abdomen because of negative pressure as shown in Fig. 2.7.

If this does not occur, the needle is in the wrong position and should be removed.

Problem: Blood is present in the aspirate – if blood is aspirated from the Veress needle, a vascular injury is suspected.

Solution: The needle should be removed and replaced. Once access is obtained, the puncture site as well as the retro-peritoneum should be inspected for evidence of vascular injury or expanding hematoma. During this time, if the patient becomes hemodynamically unstable and vascular control is not feasible laparoscopically, emergency laparotomy should be performed.

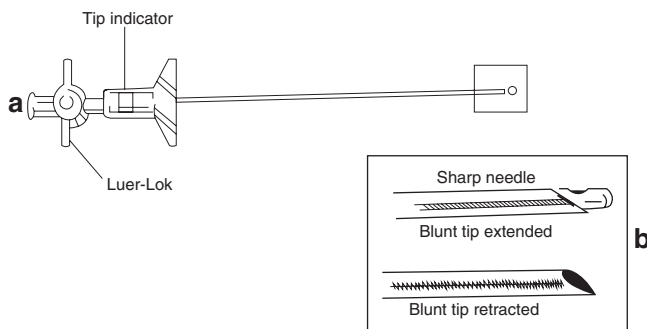


Fig. 2.1 The Veress needle is 14-gauge and 12–15 cm in length

Problem: Excessive air or enteric contents are present in the aspirate. In this situation, an enteric injury is suspected.

Solution: The needle is left in place, as it might be difficult to isolate the site of injury if the needle is removed and also result in further spillage of enteric contents. A new access site should be chosen for laparoscopic access and the initial needle placement can be confirmed and any perforation repaired. The decision to repair the injury laparoscopically or via an open approach is based on the experience of the surgeon and the extent of the injury. In most cases, the Veress needle is a forgiving instrument and does not require repair. Patients should be given antibiotics for a few days.

Although these complications are rare (occurring in 0.05–0.2 % of cases), they do require vigilance (1).



Fig. 2.2 The mechanism of a Veress needle entry is demonstrated in this illustration. As the needle is introduced to the abdominal cavity, the blunt stylet protects the abdominal contents from the sharp outer cannula

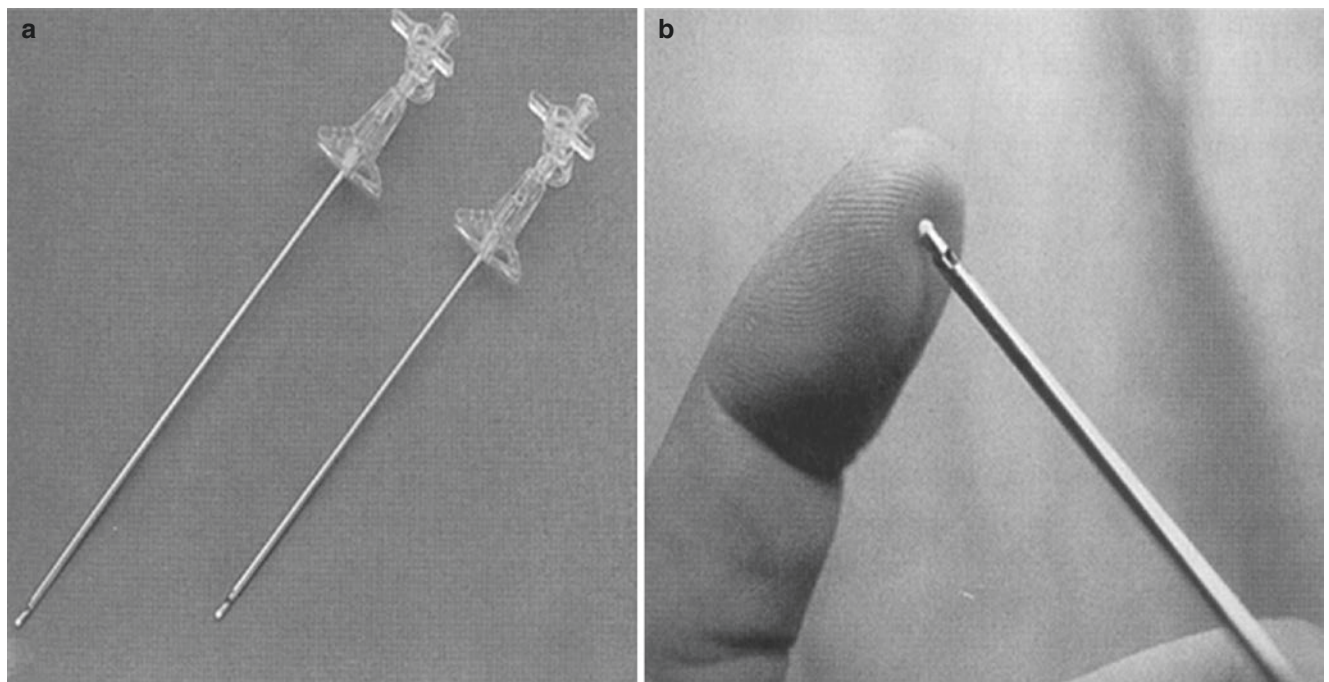


Fig. 2.3 (a) The length of the Veress needle may vary between 12–15 cm. (b) The Veress needle is shown with the obturator extended

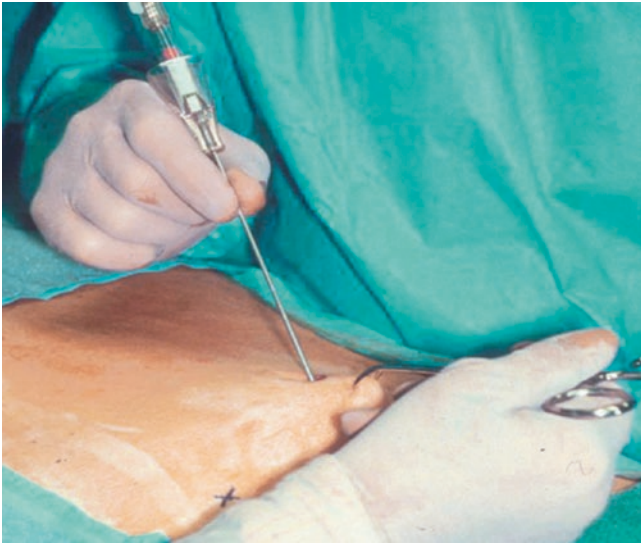

Fig. 2.4 Using towel clips, the Veress needle was introduced into the abdominal cavity

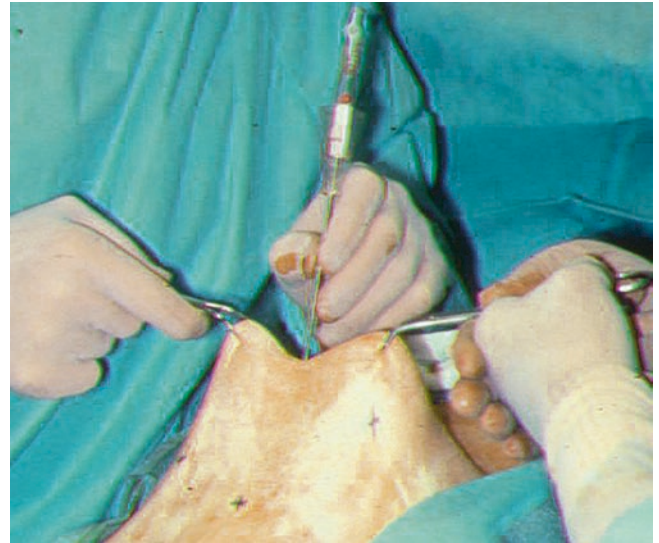


Fig. 2.5 By lifting the abdominal cavity away from the underlying viscera, the abdominal contents are protected

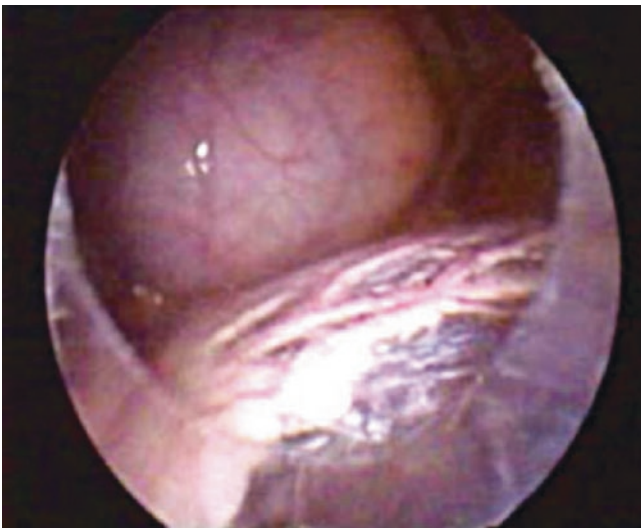

Fig. 2.6 Insufflation within the omentum gives a bubbly appearance as shown in this illustration

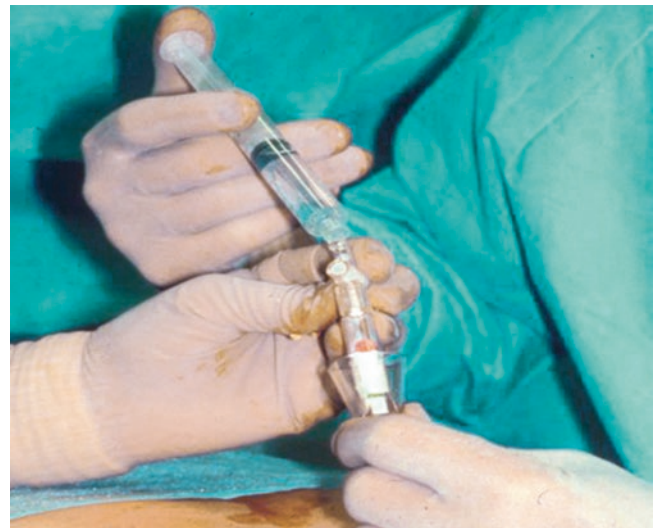

Fig. 2.7 After the abdominal cavity has been entered with the Veress needle, a syringe with fluid is used to perform the drop test

2.4.3 Open Technique

In an attempt to increase the safety for insertion of the initial trocar, Hasson introduced a method to obtain laparoscopic access through an open technique. This technique is especially useful when a patient has undergone previous abdominal surgeries.

A semicircular incision is created around the umbilicus. An alternate position may be chosen in certain situations, usually lateral to rectus muscle, and in a way to avoid major vascular structures of the abdominal wall as shown in Fig. 2.8.

Using a combination of two army-navy retractors, the subcutaneous fat is cleared from the fascia. A small 1–2 cm

incision is created within the fascia after placing stay sutures. These sutures are used as a purse string to prevent the gas leakage during the case and to help with the closure of the defect at the end of the case. Following this, the peritoneum is identified, grasped between two clamps, and incised sharply. Entry to the abdominal cavity is confirmed visually and by placing a finger into the cavity. The Hasson cannula is then inserted into the abdominal cavity.

The Hasson cannula has three parts: the outer sheath, a blunt obturator, and a cone that is movable along the sheath that may be locked into position. The cannula also has wings at the base of the trocar's outer sheath where the fascial sutures can be wrapped and locked as shown in Fig. 2.9.

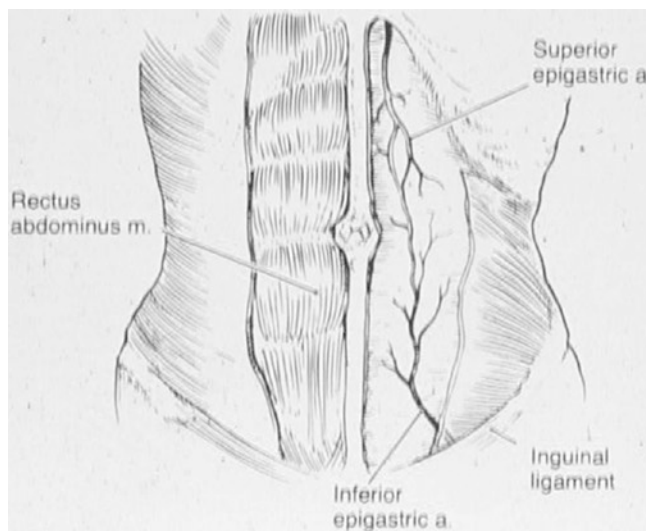


Fig. 2.8 The abdominal wall structures are noted in this illustration. Note where the inferior and superior epigastric artery is in relation to the rectus abdominis muscle

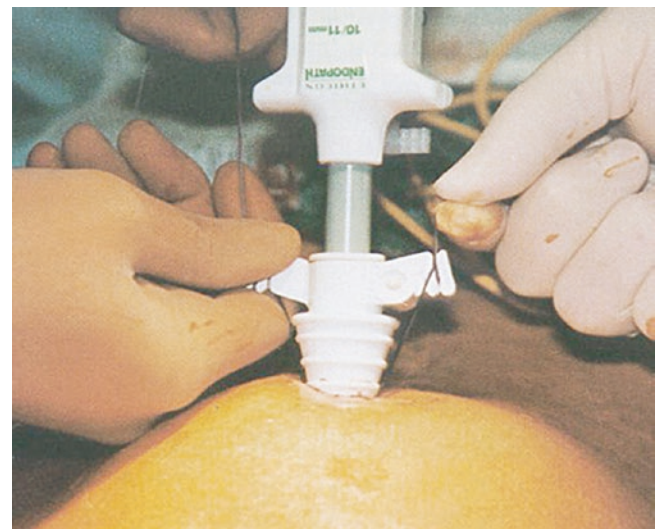


Fig. 2.9 A Hasson cannula is inserted into the abdominal cavity. The cannula has wings at the base of the trocar's outer sheath where the fascial sutures can be wrapped and locked

2.5 Technique of Creation of Pneumoperitoneum

2.5.1 Technique for Creation of the Pneumoperitoneum Using a Veress Needle

Once it has been established that no injury has occurred during the insertion of the Veress needle, one can then progress to insufflating the abdomen. The flow of carbon dioxide gas through the tubing is then confirmed by placing the end of the tube in a water filled container. The tubing is then attached to the Veress needle. The initial intra-abdominal pressure should be <8 mmHg and the flow of gas between 1 and 2 l/min. Satisfactory establishment of the pneumoperitoneum can be checked by watching a gradual rise in the intra-abdominal pressure to 15 mmHg. Percussion over all four quadrants will also confirm establishment of the pneumoperitoneum as shown in Fig. 2.10.

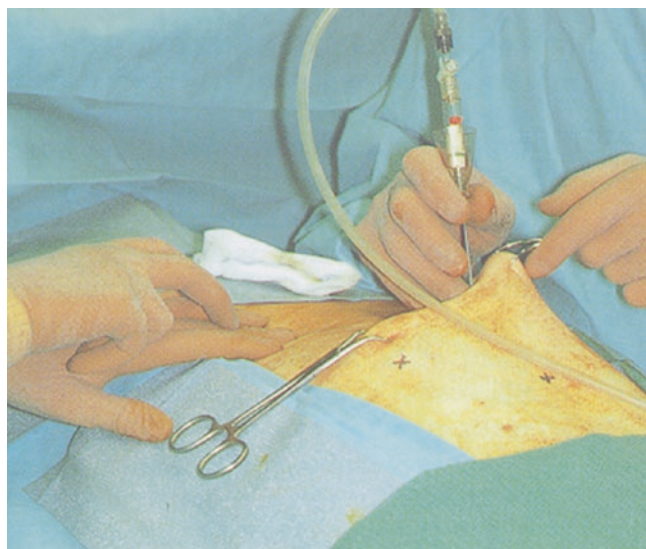


Fig. 2.10 Percussion over all four quadrants also confirms establishment of the pneumoperitoneum

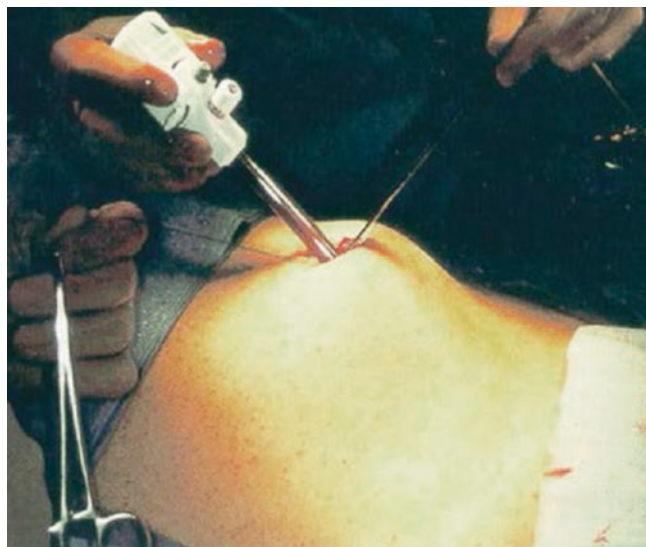

Fig. 2.12 It is helpful to simultaneously lift the abdominal wall sutures with the non-dominated hand during trocar insertion

Once the pneumoperitoneum has been established and the patient's hemodynamic status is confirmed to be stable by the anesthesiologist, the flow of the gas can be increased.

A 10/12 mm trocar is then inserted after withdrawing the Veress needle. The trocar should be held in the palm, with the index finger extended down the shaft to gain maximum control. This is shown in Fig. 2.11.

Trocars should be inserted by rotating the trocar clockwise and anticlockwise alternatively same time applying a steady downward force; it is helpful to simultaneously lift the abdominal wall with the non-dominant hand or towel clips as shown in Fig. 2.12.

Once in position, the inner cannula of the trocar is removed immediately, the gas tubing is reattached to the new cannula and the laparoscope is placed to ensure proper placement and to inspect the abdomen to visually confirm the safe entry.

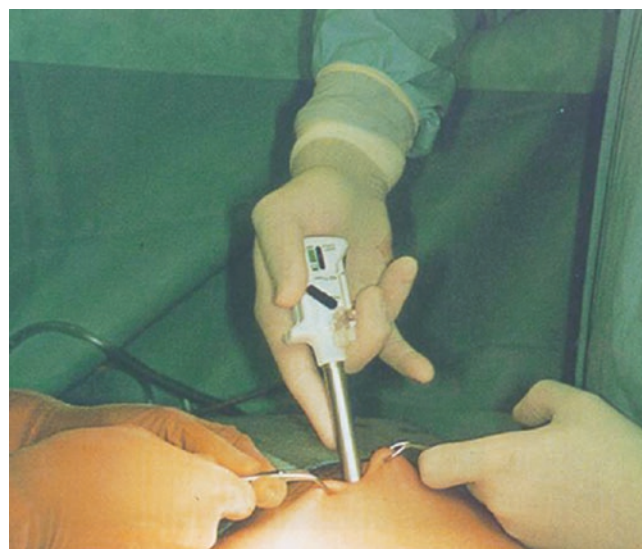


Fig. 2.11 The trocar should be held in the palm of the hand with the index finger extended down the shaft to gain maximum control during trocar insertion

2.5.2 Technique for Creation of the Pneumoperitoneum Using the Hasson Technique

A skin incision is made at the level of the umbilicus. Using two retractors, the incision is deepened down to the level of the fascia. A vicryl suture is placed on both edges of the fascia and the fascia is then cut. Using great care, the peritoneal cavity is entered. After placing the trocar in the peritoneal cavity as shown in Fig. 2.13.

The pneumo tube is attached to the trocar and similar steps are subsequently followed as described for the closed technique.

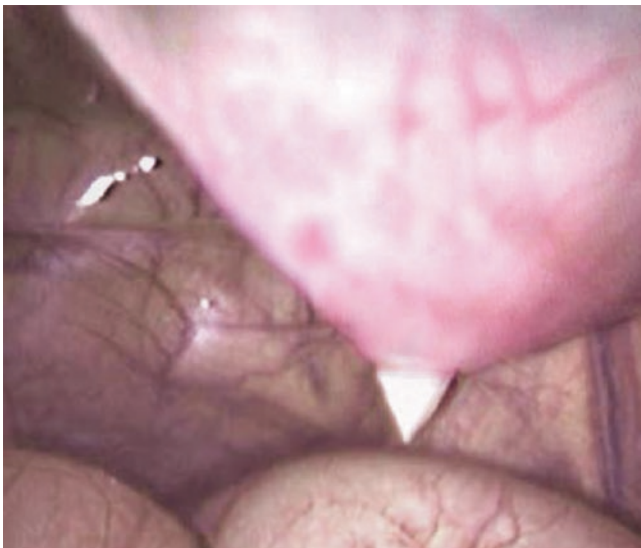


Fig. 2.13 The trocar tip is shown entering the peritoneal cavity

2.6 Insertion of Secondary Trocars

The secondary trocars may be placed either under direct vision or by palpation, with the non-dominant hand in the abdomen protecting the intra-abdominal organs in the case of hand assisted laparoscopy. The safe entry of the secondary trocar should be monitored under vision as shown in Fig. 2.14.

Problem: Vascular injury of abdominal wall resulting in blood trickle as in Fig. 2.14

Solution: After inserting the trocar, percutaneous transfixation can be done as shown in Fig. 2.15.

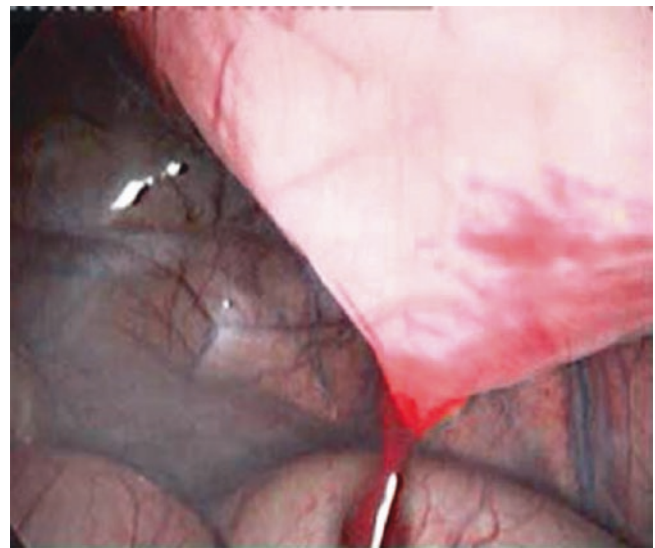


Fig. 2.14 Safe entry of secondary trocars is established under direct vision. Vascular injury to the abdominal wall vessels results in a blood trickle as illustrated in this photograph

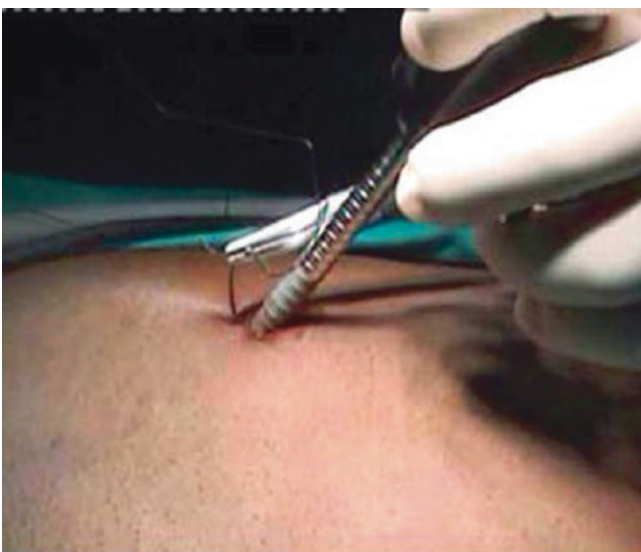

Fig. 2.15 After inserting the trocar, a percutaneous transfixation suture can be placed

2.7 Technological Advancements

To further ensure safe entry into the abdomen, many new trocar designs have been introduced. These include trocars with blades that retract upon entering the abdominal cavity, as shown in Fig. 2.15.

Blunt-tip trocars that radially dilate are also available as shown in Fig. 2.16.

These trocars separate the abdominal layers by dilating the tissues instead of cutting them. This will prevent the formation of hernias and allow for a quicker closure at the end of the case. We also found them to cause less post-operative pain.

We routinely use the “one-step” trocars that utilize a mesh-like sleeve. These are introduced with the Veress needle

and serve as a track through which a blunt-tip radially dilating trocar can be inserted. This sleeve is shown in Fig. 2.17.

Most recently, clear trocars which allow a 0° laparoscope to be placed within the tip of the trocar have been introduced. This allows the surgeon to visualize the different layers of the abdominal wall as the trocar is placed into peritoneum as shown in Figs. 2.18, 2.19, and 2.20.

In addition, a trocar that has an inflatable balloon at the tip has been used instead of a traditional cone-shaped Hasson trocar and does not need fascial sutures. Once inserted, the balloon is inflated and the base of the trocar is pressed against the skin, creating an airtight seal. A tight, secure fit allows for movement of the trocar while maintaining an airtight seal. The figure is shown in Fig. 2.20b.



Fig. 2.16 This blunt-tip trocar radially dilates the fascia during insertion

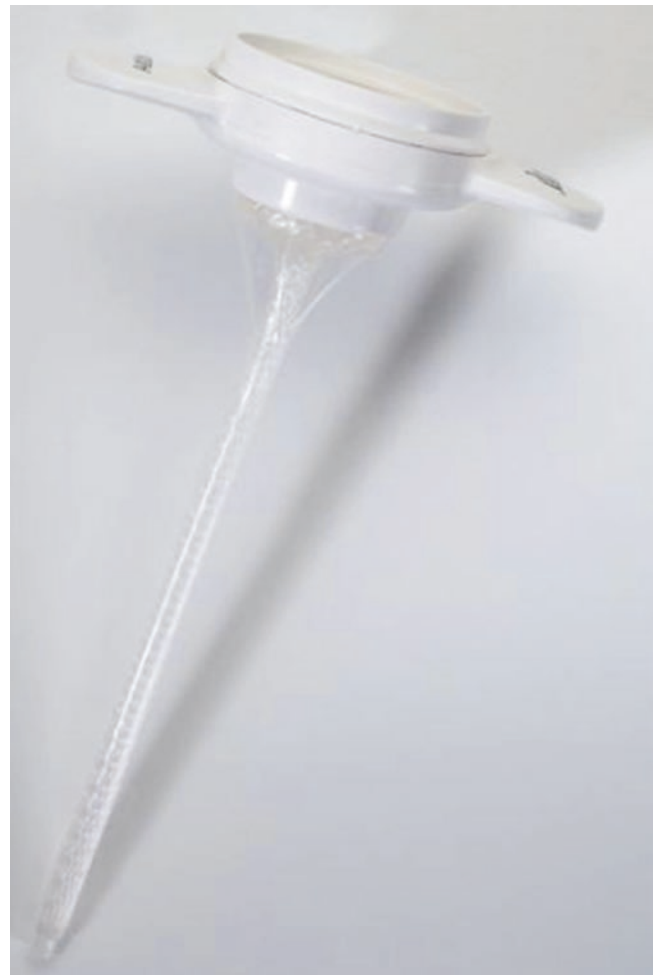

Fig. 2.17 The sleeve of a radially dilating trocar is shown in this photograph

Fig. 2.18 Clear trocars allow for a zero-degree laparoscope to be placed within the tip of the trocar. This allows visualization of the different layers of the abdominal wall as the trocar is placed into the abdominal cavity

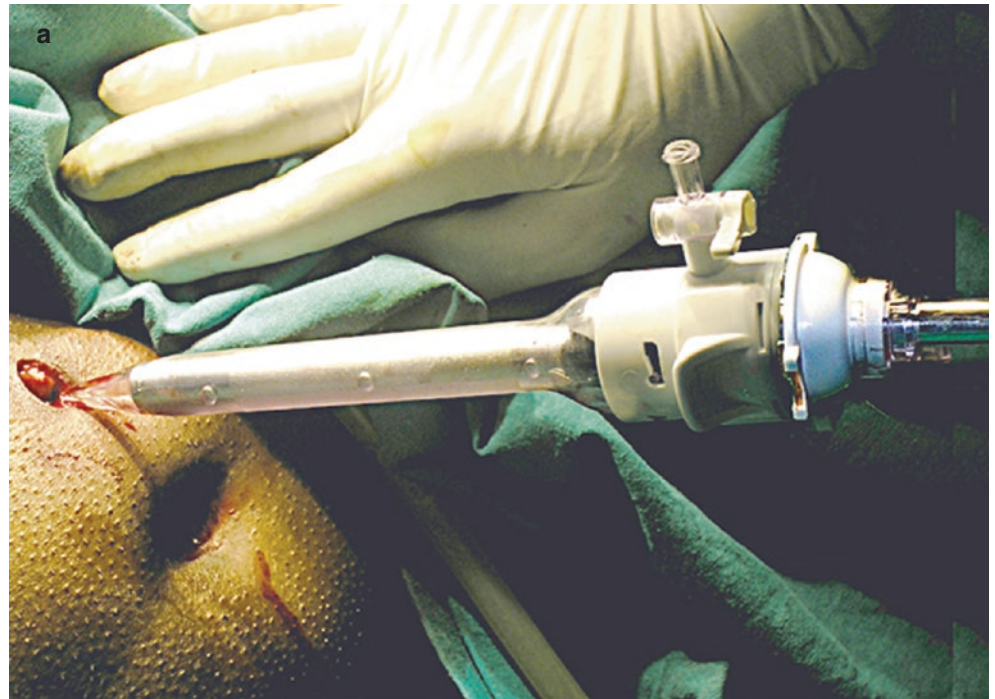



Fig. 2.19 (a) The laparoscope is introduced into the visualizing trocar. (b) The different layers of the abdominal cavity may be seen as illustrated in this schematic. (c) A photograph of the actual abdominal layers

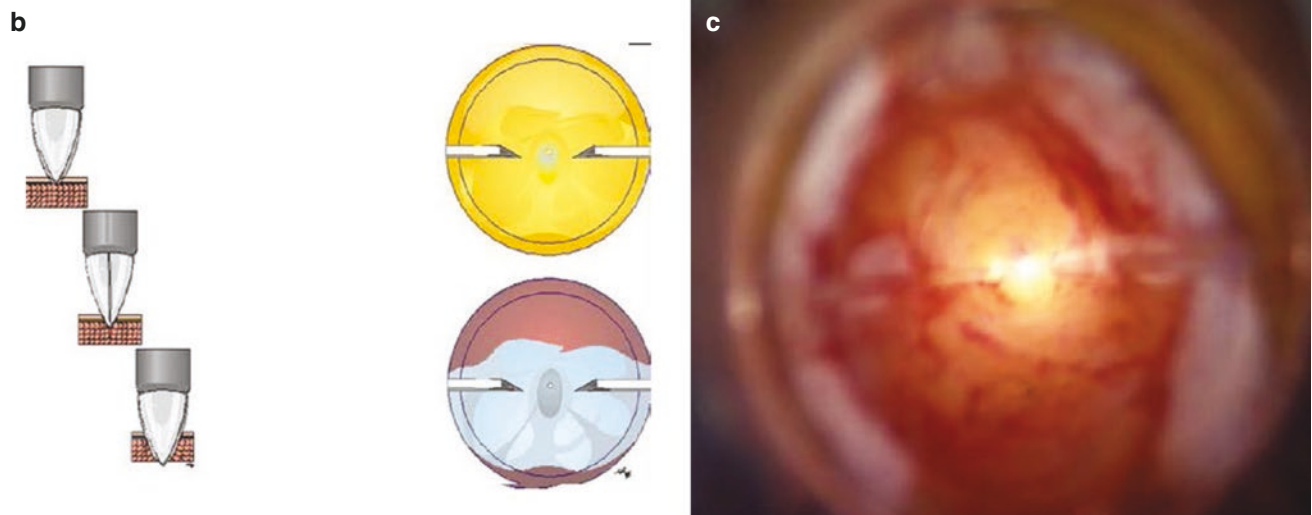


Fig. 2.19 (continued)

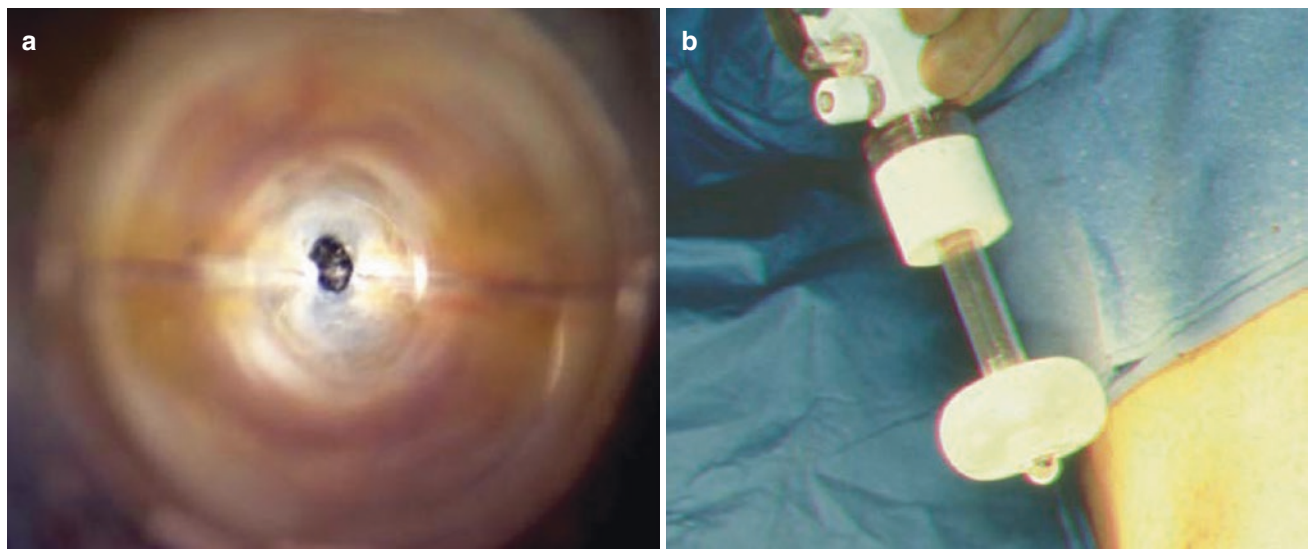


Fig. 2.20 (a) As the abdominal cavity is entered, the surgeon is able to visualize different layers of the abdominal wall. (b) The balloon is inflated at the base of the trocar and pressed against the skin creating an airtight seal for the Hasson trocar

2.8 Exiting the Abdomen

Despite the utmost care during placement of trocars, some injuries may be detected only during the exit. Before starting to remove the trocars, all instruments needle and sponges should be removed. The pressure of the pneumoperitoneum should be reduced to 5 mmHg to confirm adequate surgical hemostasis. All working trocars should be removed under vision and the exit sites inspected for any bleeding. The primary trocar is then finally removed. All trocars that are greater than 9 mm in size should have a fascial closure stitch placed to prevent a hernia. Thomson Carter needle is used for port closure under vision (Fig. 2.21a–c).

Newer fascial closure systems are available now, which help in the easier and effective port site fascial closure (Fig. 2.21d–f).

New ports and bladeless trocars have decreased the incidence of trocar site hernia to 0 % (Bhoyrul et al.). Introduction of instruments such as the endo close have served to be helpful in doing so.

This device has a spring-loaded blunt stylet mechanism. The stylet retracts as the needle is pushed through the abdominal wall and automatically advances once the peritoneum has been penetrated. The suturing device is used to close the incision. The stylet has a notched end, which is used to capture and hold suture. It is recommended to use USP suture sizes 2–0 or 0.

It is important to note that trocar location and size are variables, amongst others, that can contribute to trocar site hernia regardless of recent technological advancements.

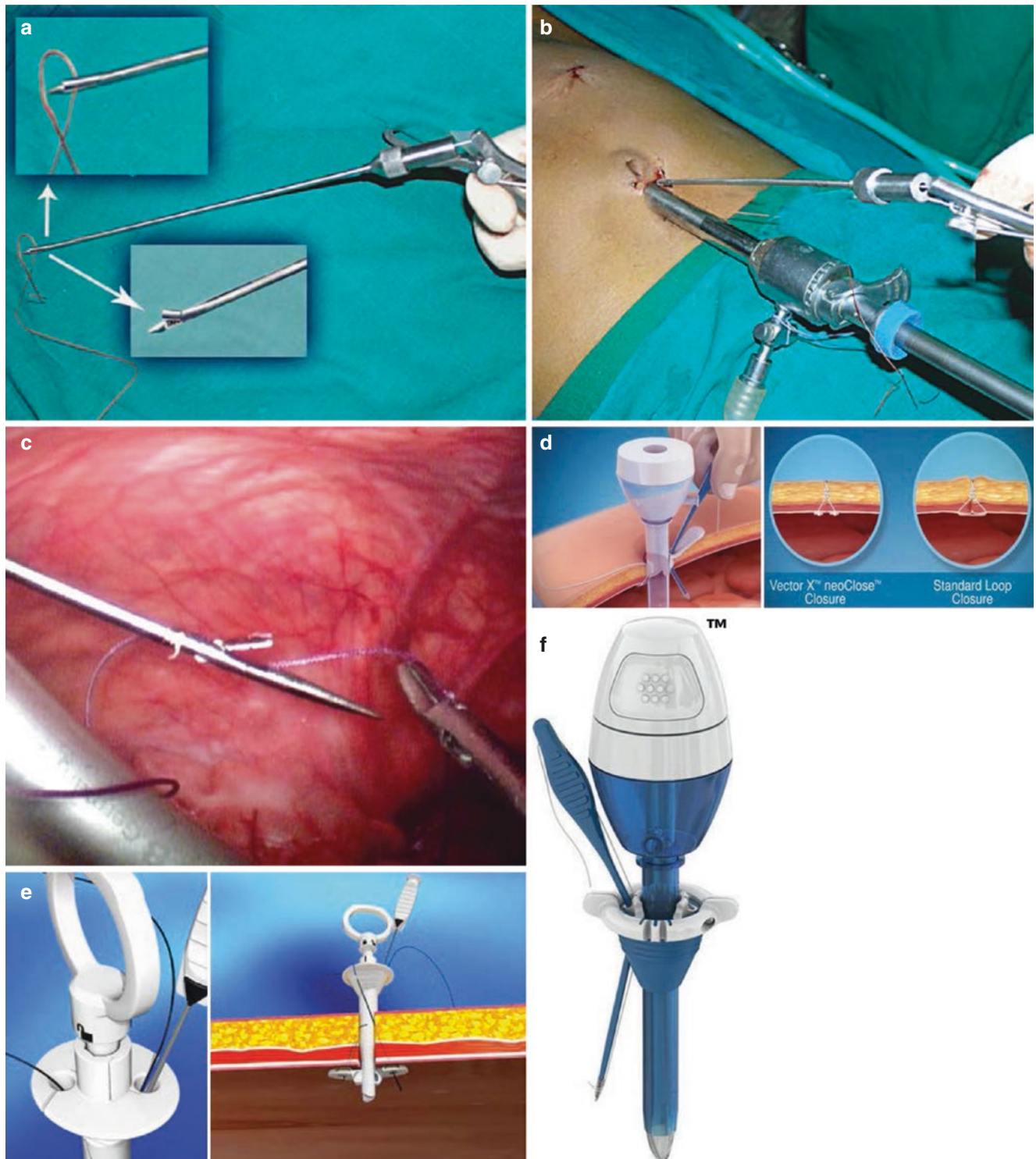

Fig. 2.21 (a) Port closure needle. (b) The port closure needle is inserted next to the trocar. (c) Endoview showing port closure needle picking up the suture. (d) NeoSurgical's Neoclose Laparoscopic Access

site closure device. (f) *Vector X™ Closure*. (e) The Weck EFX™ Endo Fascial Closure System – Port Site Closure

2.9 Useful Tips

- Know your instrument.
- Be familiar with your clip-applier and stapler.
- Be careful when using monopolar electrocautery to prevent burns.
- Work with a surgeon familiar with laparoscopic techniques.
- Always have an open surgical setup in the room.

2.10 Entry and Exit: Robotic Surgery

Robot assisted laparoscopy is an extension of laparoscopic surgery – with the assistance of a surgical robot. The basics of corporeal entry and exit are similar for both approaches. The laparoscopic entry and exit has been described in the previous section. The additional points to cover are outlined in the robotic approach, which is described here.

Difference from classical laparoscopy:

1. Space for positioning the robot
2. Possibility of clashing instrument – externally and internally

3. Position of the surgical assistant
4. Inability to change patient position peroperatively – Needs undocking of robot if necessary
5. Effective use of fourth arm retraction
6. Patient monitoring during anesthesia hampered due to abnormal position and presence of robot occupying space

2.10.1 Space for Positioning and Draping the Robot

The operating room should be large enough to accommodate the space for the surgical robot. The robot needs to be stationed slightly away from the patient when the patient is being prepared for anesthesia and being positioned. This time is utilized for draping the robotic arms. The trained staff nurse or the surgical assistant may drape the robot in the meantime. In order to prevent breach of sterility, the fourth arm may better be moved to either the right or left side before draping. The working arms are initially draped followed by the camera arm. Draping is better done with all the hinges extended, so that the drapes slide along freely. Drapes are tightly secured to maintain sterility while moving the robot.

2.10.1.1 Positioning the Patient

The patient needs to be positioned exactly without any need to change position intraoperatively since it needs undocking. The patient should also be tightly secured with belts or plasters, with paddings in pressure points, especially if the patient is to be moved to abnormal positions at the time of docking. If the patient is to be subjected to the steep Trendelenburg position, trial of positioning is done before marking the patients (Fig. 2.22).

All the tubings must be well secured since the anesthetist may have difficulty in accessing them during the procedure. Insertion of arterial and central venous catheters prior to docking is preferable. The position of the assistant and the assisting port needs to be planned to have adequate space away from the moving robotic arms, as injury to a bedside surgical assistant due to moving robotic arms is familiar.

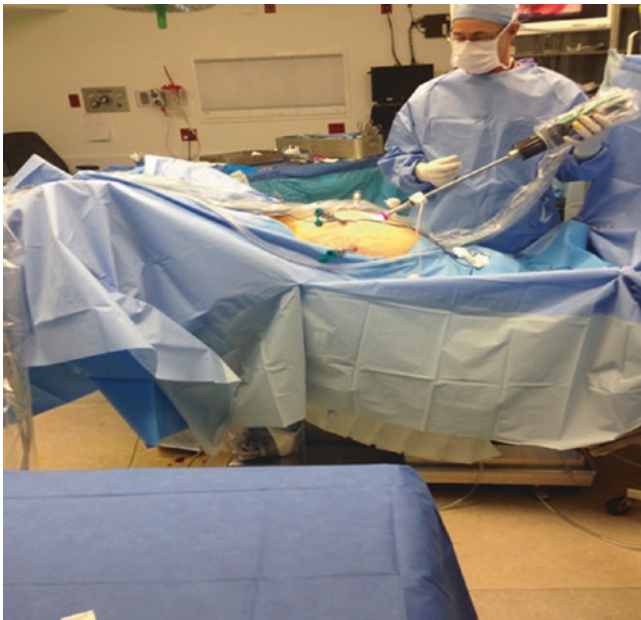

Fig. 2.22 The patient should be tightly secured to the table with belts and tape, with padding of the pressure points. If the patient is subject to a steep Trendelenburg position as illustrated in this picture, trial positioning is done before the surgical procedure is started

2.10.1.2 Port Position

The ports need to be placed in such a way that they do not clash either internally or externally. The ports are better placed after marking all the ports with adequate space between them. The robotic metal ports have three markings as shown in the picture. The port should be inserted till the broad marking is visible. Abnormal placement of the port will hinder the range of motion of the arm or slippage of port. The camera arm is docked to the 12 mm disposable port. The Ports are placed in such a way that they are at least 8 cm apart to avoid clashing of the instruments. The camera port is placed at a distance of 18–20 cm from the region of interest to have comfortable dissection. It is even better to mark the site after insufflation, to have the exact portPosition (Figs. 2.23 and 2.24)

The robot is docked depending on the type of surgery. It is mostly in between the legs of low lithotomy position for pelvic surgeries and by the side of the table in renal surgeries. In gynecological surgeries, the robot is docked beside the legs, to have an assistant for manipulation in the perineum. The important point to note is that the camera port, the central pillar of the robot and the center of the region of interest should be in a straight line to have a good lateral reach of the robotic arms.

All the arms (numbers) should be facing directly to the front at the time of docking. It eases the technique. The robotic arms are moved towards the port and they are aligned to its upper docking part with all the three axes and docked, (Figure 2.25). It is better to check that all the arms are able to be docked as shown in Figs. 2.25 and 2.26 (including the fourth arm) before starting. Since there may be difficulty, slight change of patient position may be required, particularly in the kidney lateral position.

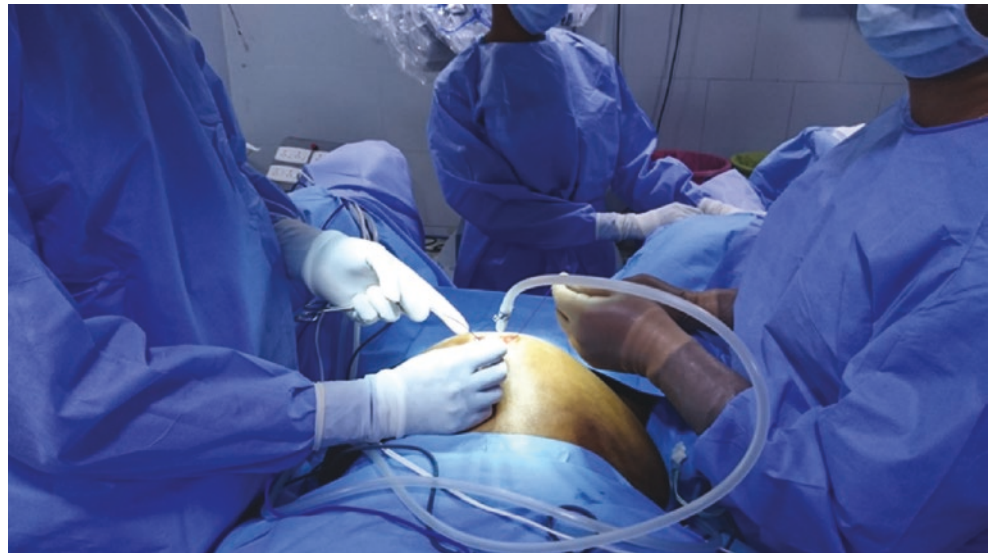The assistant ports are placed so as to have a ‘play’ for the robotic arms. They may be placed far lateral to the robotic ports. They should not be placed too close to the triangle of the robotic ports in order to have ease of assistance. The camera is inserted first followed by the other arm instruments. The camera should be handled by the assistant or the surgeon so that the tip of the instrument

being inserted should always be seen to prevent inadvertent visceral injury. Cross checking the number of uses of the instrument before inserting them is helpful. The clutches on the arms are used to move the instruments and arms till they are in a favorable position for the surgeon to operate.

These clutches are used only during insertion of the instrument for the first time. While changing the instrument, just removing and reinserting places the instrument in the previous place. The use of the fourth arm should be planned to have its maximal benefit. The undocking of the robot is done after removing all the instruments. It is

important to make sure that all the instruments are removed and the robot is undocked before it is relocated. With further advancements in technology, upgrades on the robot have found potentially new ways to overcome some of the obstacles listed above. Such upgrades include a new overhead instrument arm architecture designed to facilitate anatomical access from virtually any position, providing greater range of motion. A new endoscope creates a simpler, more compact design with improved visual definition and clarity amongst other details that can potentially change the scope of robotic surgery (Figs. 2.27, 2.28, 2.29, 2.30, 2.31, and 2.32).

Fig. 2.23 The camera port is placed at a distance of 18–20 cm from the region of interest to have enough space for the dissection. The accessory trocar positions are marked on the patient's abdomen after insufflation



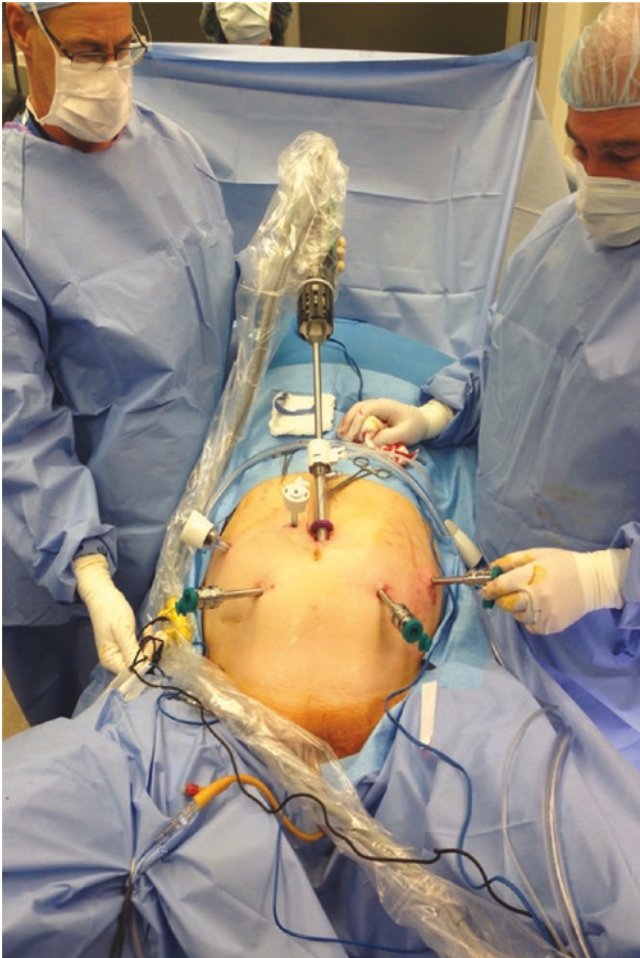

Fig. 2.24 The robotic trocars have been placed in the patient after the table has been lowered and the patient put in a Trendelenburg position



Fig. 2.25 The robot is docked on the patient

Fig. 2.26 Robotic arms docked to the trocars and instruments inserted

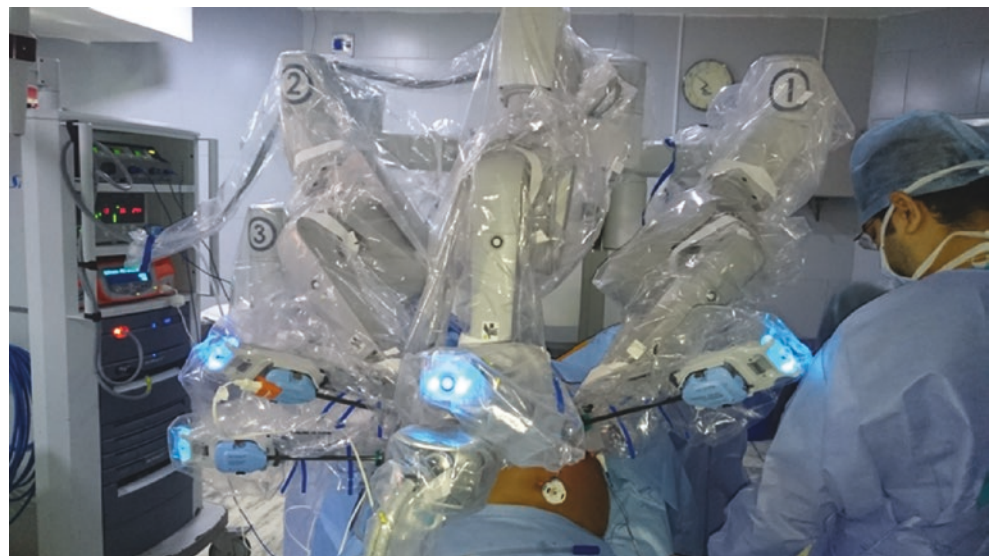


Fig. 2.27 Steep (30°) Trendelenberg position for pelvic surgeries

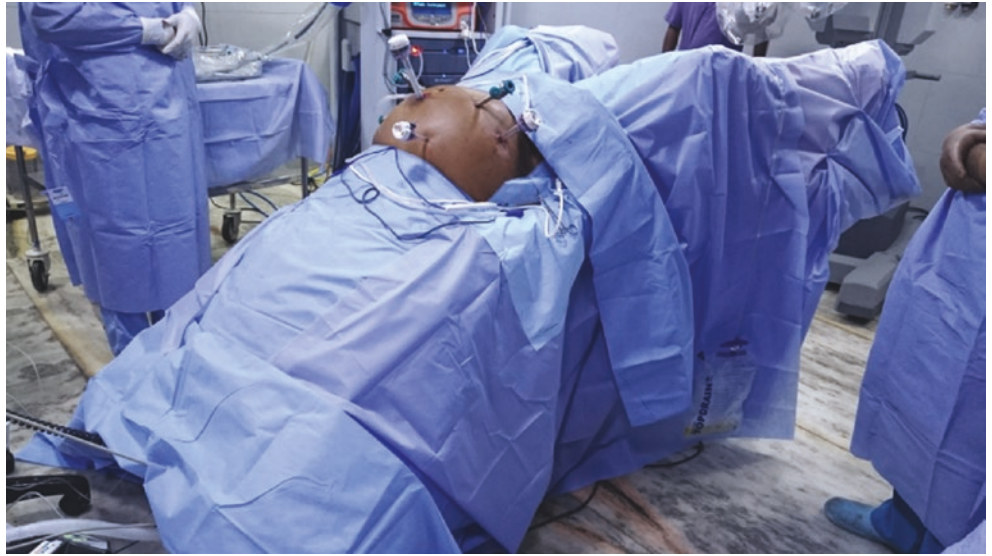

Fig. 2.28 Robot docked between thighs in low lithotomy position – for pelvic surgeries

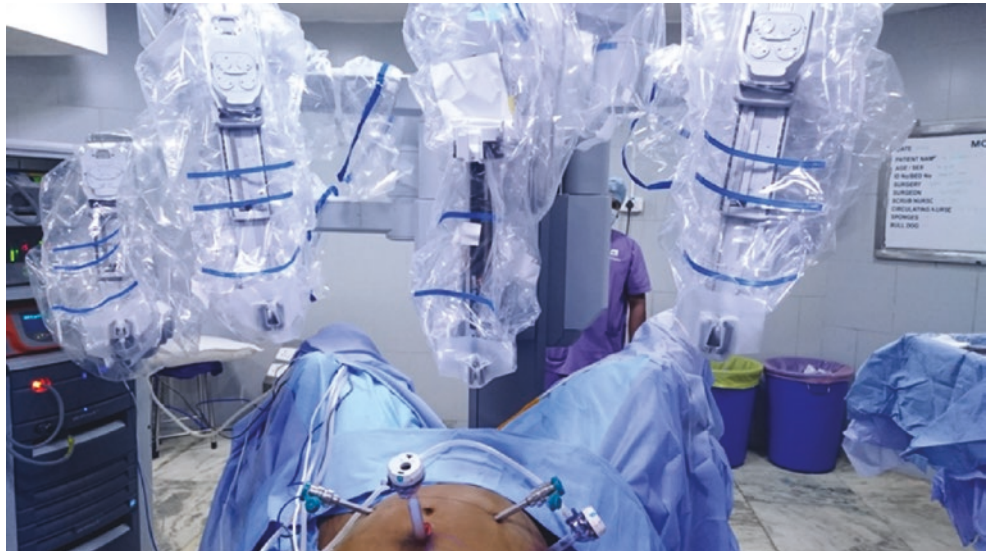

Fig. 2.29 Patient position for renal surgeries

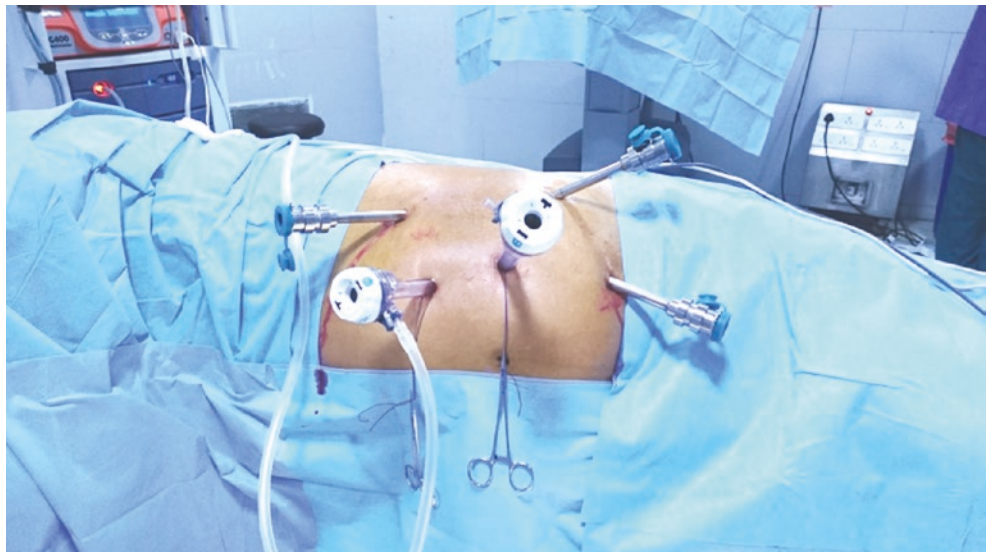


Fig. 2.30 Docking for gynaecology surgeries

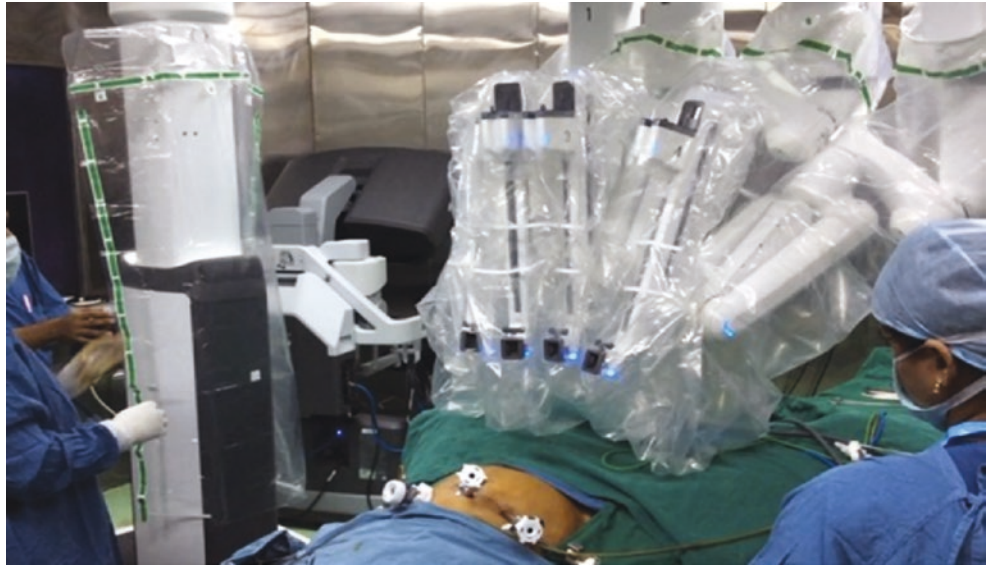

Fig. 2.31 Robot docked in position for partial nephrectomy

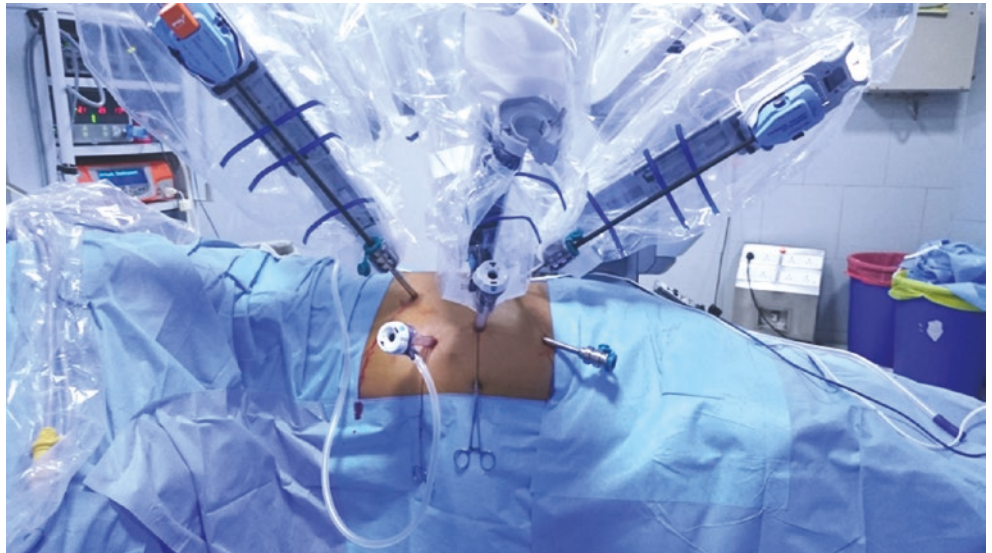
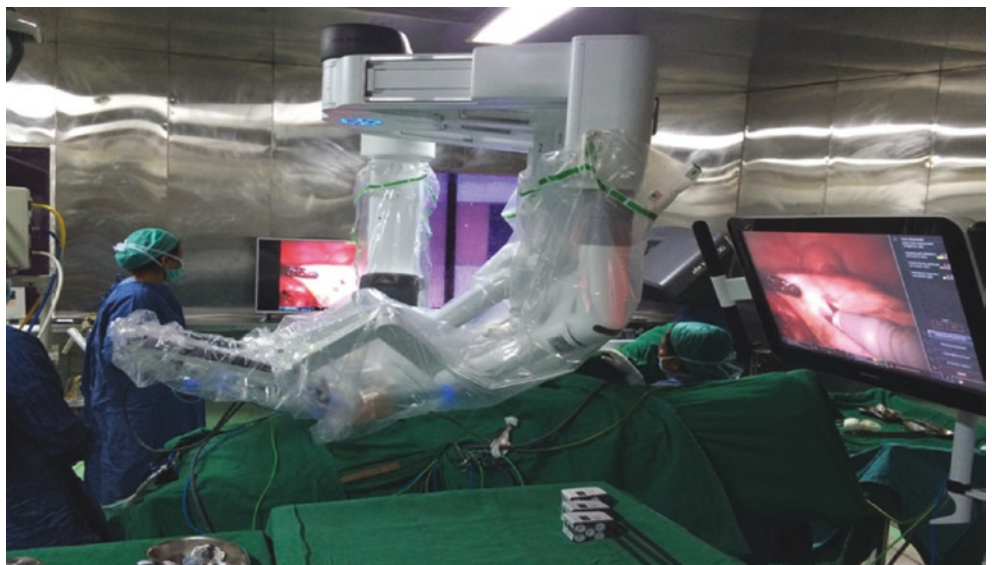


Fig. 2.32 Side docking for gynaecology surgeries



Manickam Ramalingam, Kallappan Senthil,
and Anandan Murugesan

3.1 Introduction

Retroperitoneum is a familiar space for all the Urologists. Prof. Wickham in 1979 was the first to perform retroperitoneoscopy to remove a ureteric stone. After a long period of 10–12 years it became a viable alternative to transperitoneal approach, after being popularized by Prof. Ralph Clayman [2]. Dr. Gaur [3–6] brought in a new concept of using a balloon to distend the retroperitoneal space (RPS) before pneumo insufflation that is widely practiced now. Later on a variety of retroperitoneal balloons were designed.

3.2 Techniques

Basically we approach retroperitoneal organs by

- (a) Posterior approach
- (b) Anterolateral/lateral approach

The basic difference from transperitoneal laparoscopy is that, the space is smaller and the field is a little darker.

M. Ramalingam (✉)
PSG Hospitals,
Coimbatore, India
e-mail: uroram@yahoo.com

K. Senthil
Urology Clinic, Gowtham Annexe, Coimbatore, India
e-mail: senthilsatya@hotmail.com

A. Murugesan
Department of Urology, PSG Institute of Medical Sciences and
Research, Peelamedu, Coimbatore, Tamil Nadu, India
e-mail: anandan79@gmail.com

3.3 Indications

All the procedures of kidney and ureters and a few lower tract procedures, listed below have been done retroperitoneoscopically.

- Simple Nephrectomy (Nonfunctioning kidney, Donor Nephrectomy) [1, 8–10]
- Radical nephrectomy for tumors <7 cm
- Partial nephrectomy for tumors <4 cm
- Renal Cyst – Marsupialisation [11]
- Pyeloplasty
- Pyelolithotomy for large burden stones
- Pyeloureterostomy
- Ureterolithotomy [7]
- Ureteroureterostomy in Retrocaval Ureter/Ureteric Stricture
- Ureterocalicostomy
- Nephroureterectomy

3.4 Contraindication

Retroperitoneoscopy will be difficult in those who had undergone retroperitoneal surgeries like PCNL, because adequate pneumo insufflation cannot be achieved.

3.5 Position of Patient

Patients are usually positioned in the loin position (90°) and the flank space is widened by breaking the table.

Different types of balloon trocars used for opening up the retroperitoneal space.

Balloon tip trocar and malecot tip trocars help to retain the tip of the trocar within the retroperitoneal space.

3.6 Step-by-Step Description

3.6.1 Port Placement

3.6.1.1 Entry

Primary port can be in the renal angle. Some surgeons prefer antero lateral approach, in which case the primary port can be a little anterior to the renal angle and the working ports can be on either side. Hassons trocar is preferably used to prevent pneumoleak.

Secondary ports are about 4 cm away from the primary port, complying with the triangulation concept. A fourth port may be inserted anterosuperiorly for retraction, or suction and irrigation in such a way that it does not interfere with the other instruments.

Dissection and suturing techniques are the same as in transperitoneal approach but the restricted space makes the steps a little difficult.

3.6.1.2 Specimen Retrieval

Simple custom made bag can be used in retrieving stones and other benign masses. However commercially available endocatch is preferable if it is a tumor.

3.6.1.3 Drain

Can be left through the primary or accessory port site.

3.6.1.4 Exit

Muscle layers in the primary port (10 mm) should be closed with interrupted vicryl sutures (Figs. 3.1, [3.2](#), [3.3](#), [3.4](#), [3.5](#), [3.6](#), [3.7](#), [3.8](#), [3.9](#), [3.10](#), [3.11](#), [3.12](#), [3.13](#), [3.14](#), [3.15](#), [3.16](#), [3.17](#) and [3.18](#)).

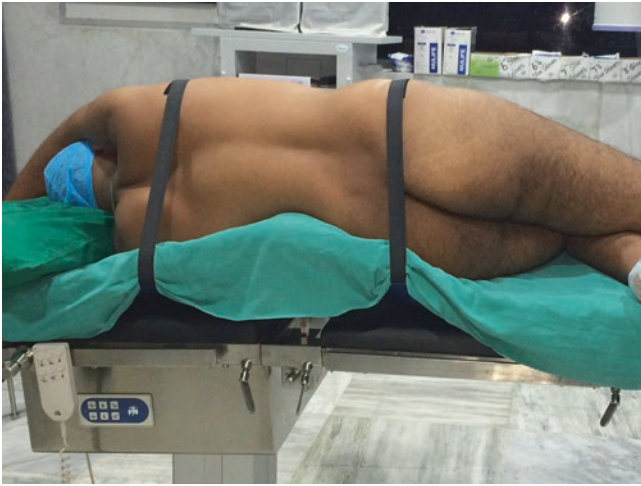

Fig. 3.1 Positioning is important in retroperitoneoscopy. Patient is placed in 90° lateral position with kidney bridge elevation at the level of tip of 12th rib. It helps in opening up the space between the pelvis and the rib cage

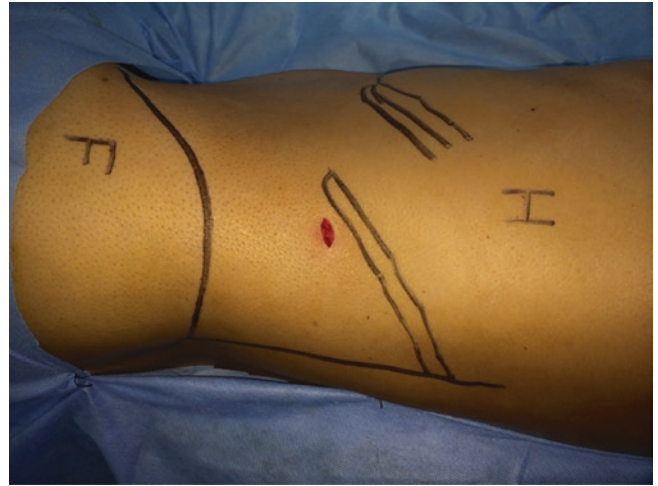

Fig. 3.2 12th (or 11th) rib, iliac crest, posterior axillary line form the important landmarks for retroperitoneoscopy. Marking them initially helps in planning the port sites. Camera port is classically placed just below the tip of the 12th rib. This incision below tip of 12th rib is used to create the retroperitoneal space

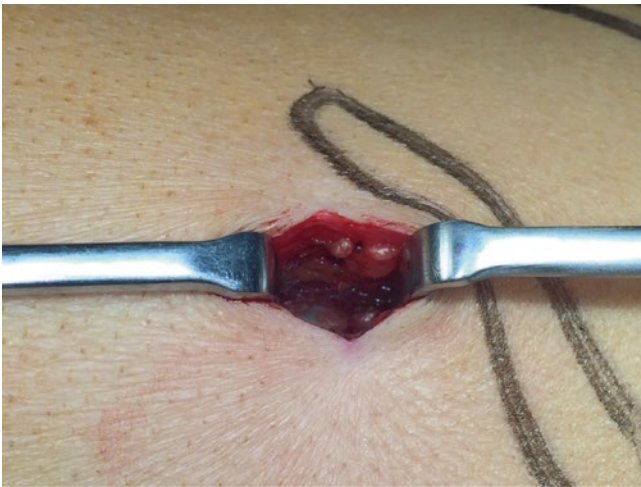

Fig. 3.3 Skin and subcutaneous tissue incised initially and white glistening lumbo dorsal fascia seen. It is incised sharply using knife or scissors

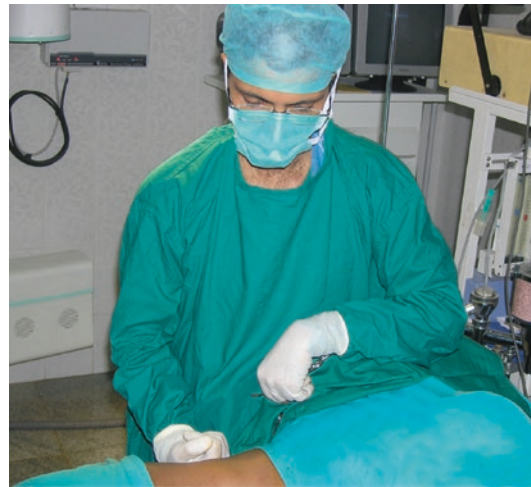

Fig. 3.4 Finger is used to create retroperitoneal space

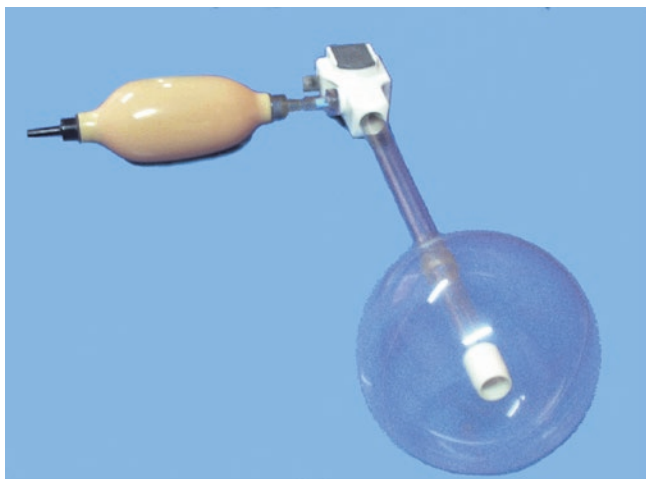


Fig. 3.5 Alternatively, spherical balloon trocar may be used to create retroperitoneal space

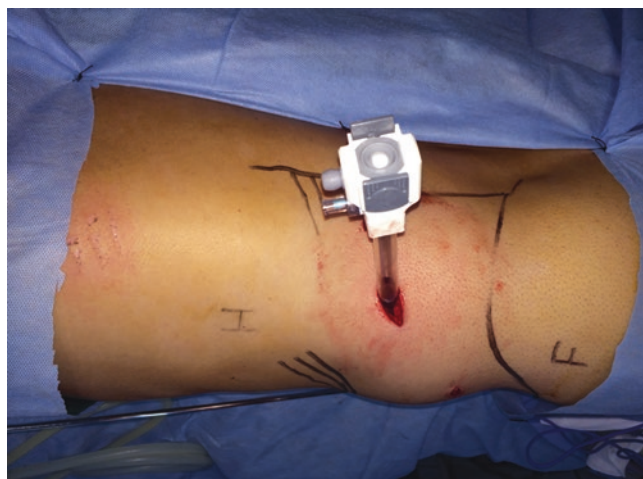

Fig. 3.6 Retroperitoneal space developed by bulb balloon trocar – Note the bulge anteriorly

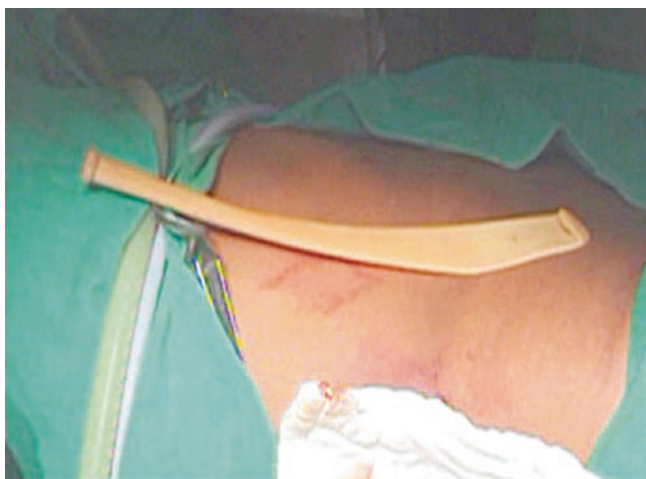

Fig. 3.7 Gaur balloon used to create retroperitoneal space – Alternative to balloon tipped trocar

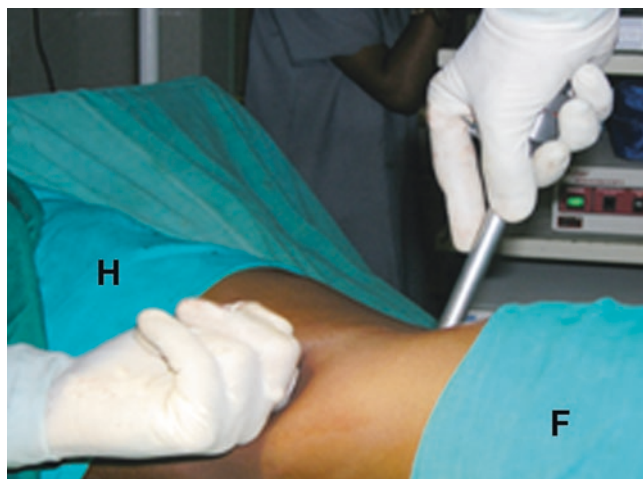

Fig. 3.8 Insertion of working ports with finger guidance prevents inadvertent injury

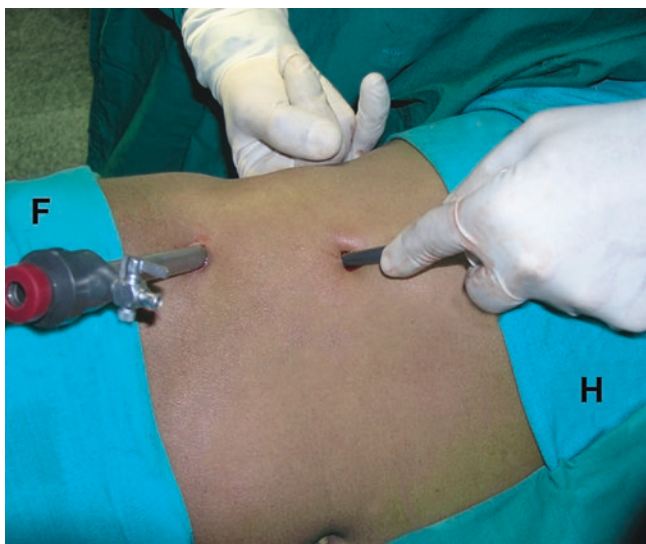

Fig. 3.9 Insetion of secondary ports – continued

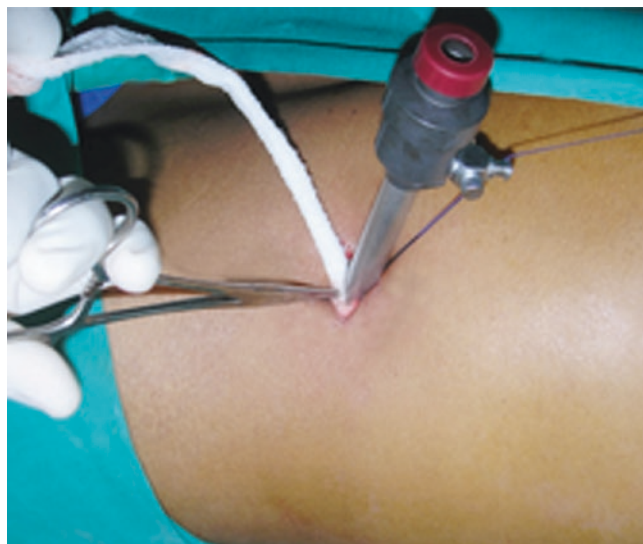

Fig. 3.10 On using conventional trocars, gas leak can be prevented by inserting paraffin soaked gauze alongside trocar




Fig. 3.11 Balloon tip trocars with retaining mechanisms (like inflatable cuff) used for camera port, since the opening is large

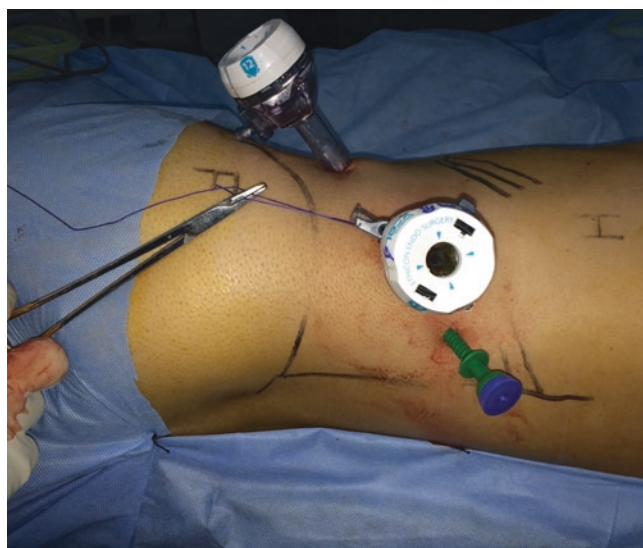

Fig. 3.12 This is the classical port position for nephrectomy, with all the ports along a straight line parallel to the rib – for better orientation

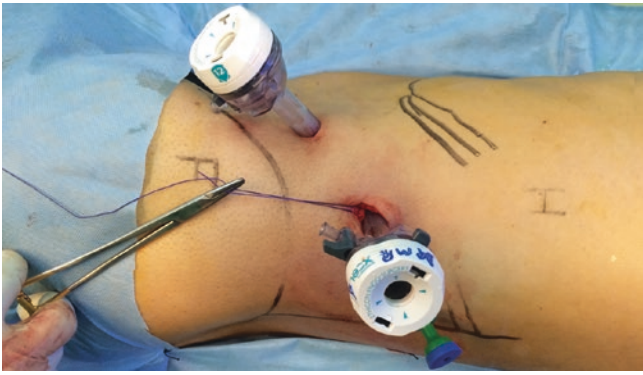

Fig. 3.13 Additionally, sutures taken through muscle and fixed to trocar prevent trocar from slipping out

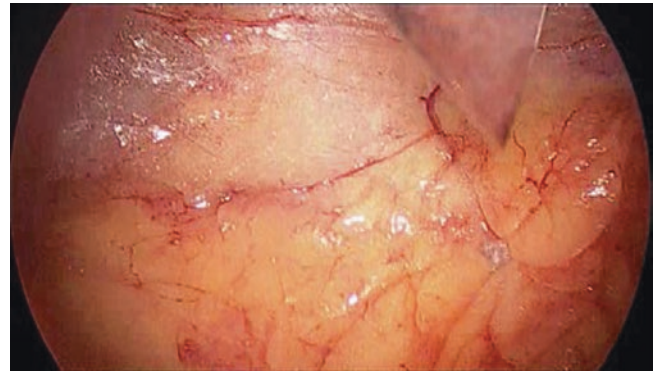


Fig. 3.14 Initial view of the retroperitoneum through camera port showing the peritoneum and psoas covered with fat

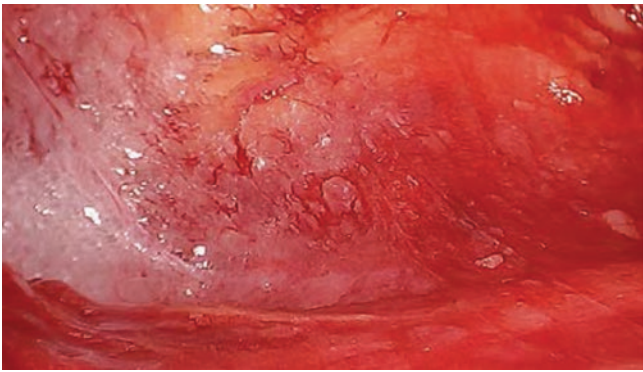

Fig. 3.15 Psoas muscle coming to view after dissection. Still peritoneum covered with fat

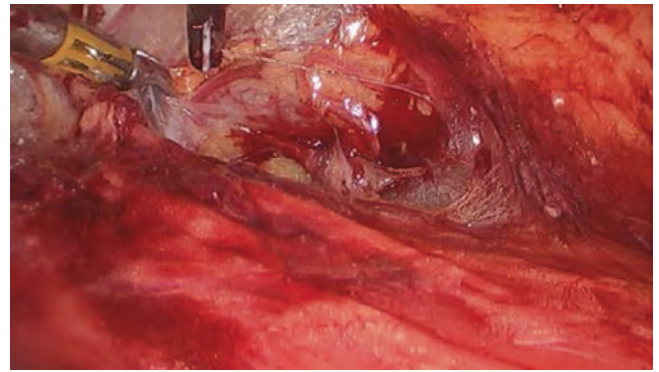


Fig. 3.16 Retroperitoneal space dissection completed. Complete extent of psoas muscle seen

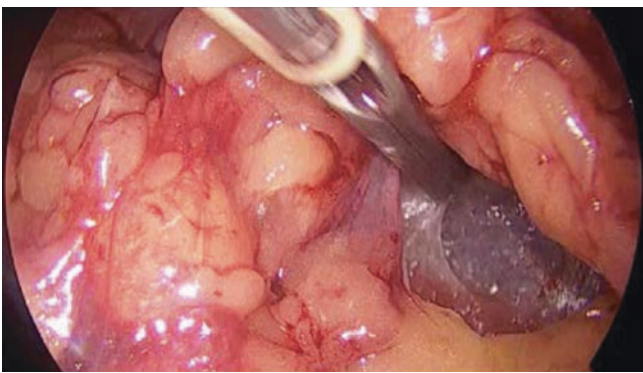


Fig. 3.17 Dissection into the Gerota's fascia can be proceeded with, if necessary after creating full retroperitoneal space

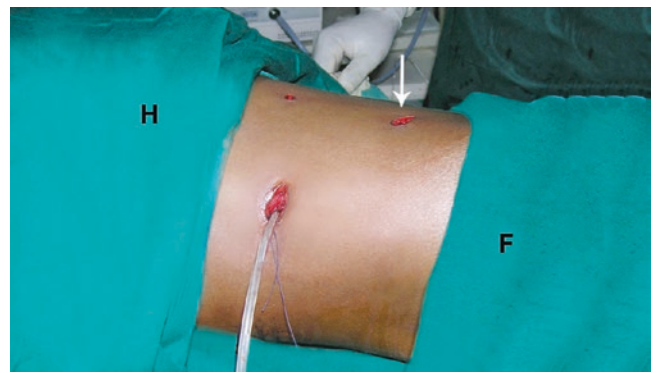


Fig. 3.18 Drain can be placed through posterior or lower port

References

1. Chandhoke PS, Galansky S, Koyle M, Kaula NF. Pediatric retroperitoneal nephrectomy. *J Endourol.* 1993; sup; 7:S138, abs P XII-12.
2. Clayman RV, McDougall EM, Kerbal K, Anderson K, Kavoussi LR. Laparoscopic nephrectomy: transperitoneal vs retroperitoneal. *J Endourol.* 1993; sup; 7: S228, abs V 116.
3. Gaur DD. Laparoscopic operative retroperitoneoscopy: use of a new device. *J Urol.* 1992;148:1137-9.
4. Gaur DD, Agarwal DK, Purohit KC, Darshane AS. Retroperitoneal laparoscopic nephrectomy: initial case report. *J Urol.* 1993;149:103-5.
5. Gaur DD. The use of Hegar's dilators in laparoscopy. *MIT.* 1993;2:333-4.
6. Gaur DD, Agarwal CK, Purohit KC, Darshane AS. Retroperitoneal laparoscopic pyelolithotomy. *J Urol.* 1994;154:927-9.
7. Harewood LM, Webb DR, Pope A. Retroperitoneal laparoscopic ureterolithotomy utilizing balloon dilation of the retroperitoneum. *J Endourol.* 1993; sup; 7:S239, abs V 160.
8. Hemal AK, Wadhwa SN, Kumar M, et al. Transperitoneal and retroperitoneal laparoscopic nephrectomy for giant hydronephrosis. *J Urol.* 1999;12:35.
9. Rassweiler JJ, Henkel TO, Potempa DM, Becker P, Alken P. Laparoscopic retroperitoneal nephrectomy. *J Endourol.* 1993; sup; 7:S230, abs V-122.
10. Rassweiler JJ, Henkel TO, Stock C, et al. Retroperitoneal laparoscopic nephrectomy and other procedures in the upper retroperitoneum using a balloon dissection technique. *Eur Urol.* 1994;25:229-36.
11. Wong HY, Griffith DP. Renal cyst marsupialization via retroperitoneoscopy. *J Endourol.* 1993; sup; 7:S228, abs V 114.

Marina Yiasemidou, Daniel Glassman,
and Chandra Shekhar Biyani

4.1 Introduction

Each surgical speciality has different requirements for instruments and the explosion in laparoscopic urology has created a market for a wide range of equipment tailored to its needs. Laparoscopic instruments vary from 1.8 to 12 mm in diameter and are usually 34–37 cm long (although length can vary from 18 to 45 cm). They may be disposable, or reusable. Most laparoscopic instruments have a basic opening and closing function and can also rotate 360°, while some also offer angulation at the tip.

Minimally invasive urological surgery is a constantly and rapidly evolving field. In terms of recent developments, special mention should be made to Robotic surgery, LaparoEndoscopic Single-site Surgery (LESS) and of course the combination of the two (R-LESS) [1, 2]. LESS was found to be at least comparable to standard laparoscopic surgery [3, 4]. It is conducted through a single incision associated with the introduction of a single port (single port technique) or a number of small incisions grouped together in one location through which the laparoscopic trocars are introduced (single incision technique). The preferred location for the incision is the umbilicus [5]. Despite LESS gaining popularity over the last few years [1], loss of triangulation may have been a limiting factor for its use. In order to overcome this, LESS was combined with robotic surgery [2].

Two other terms urologists may encounter while searching through the literature for recent advancements in laparoscopic urology are mini-laparoscopy and needlescopy. These are interchangeable terms that refer to surgery performed with 2–4 mm laparoscopic instruments [6]. Such instruments can be introduced through small punctures that do not require formal closing. Some surgeons use them as part of LESS surgery to improve triangulation. Despite the additional punctures and instruments during LESS, it is still generally considered part of single access surgery [1].

A standard minimally invasive surgery set should include the following: fenestrated grasper, blunt grasper, hooks diathermy, needle-holder, scissors, bipolar diathermy forceps, trocars and a suction/irrigation system.

Laparoscopic instruments can be categorised into four groups based on the steps in laparoscopy.

- Access
- Manipulation
 - Retraction
 - Dissection
 - Suturing
 - Suction/Irrigation
- Haemostasis
- Specimen retrieval

4.2 Access

The trocar is a tubular device through which operative access is achieved. Common components of trocars include: the sleeve, the obturator, sealing system, shield and insufflation port (Figs. 4.1, 4.2, 4.3, 4.4, 4.5, 4.6, and 4.7). Most instruments pass through 5 or 10 mm trocars. Gas leakage is prevented by sealing the trocar using a soft membrane diaphragm acting as a valve, (which may be flap, ball, or trumpet) and the trocar tip may vary. Some surgeons anchor trocars with stitches, screws, elastic bands or use balloon devices to prevent displacement.

M. Yiasemidou, MBBS, MSc, MRCS(Eng), PGCer (✉)
St. James University Hospital, 7.26 Clinical Science Building,
Beckett street, Leeds, West Yorkshire, LS9 7TF, UK
e-mail: M.Yiasemidou@leeds.ac.uk; marinayiasemidou@gmail.com

D. Glassman, BSc (Hon), MBBS, MSc, MRCS
Department of Surgery, Hull Royal Infirmary, Hull, UK

C.S. Biyani, MBBS, FRCS
Department of Urology, St. James's University Hospital,
Leeds, UK

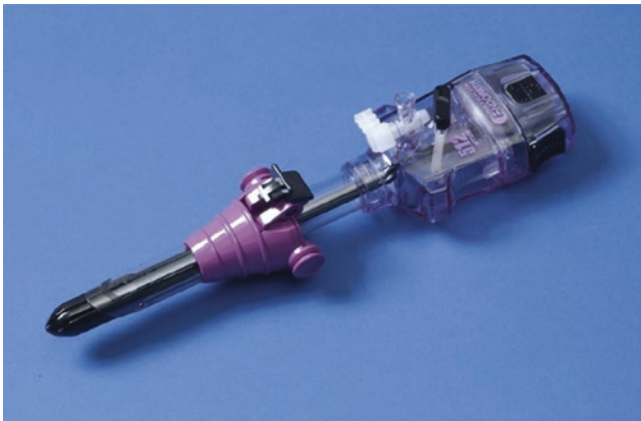


Fig. 4.1 A 12 mm blunt tip trocar (Hasson port) (primary port)



Fig. 4.2 An optiview

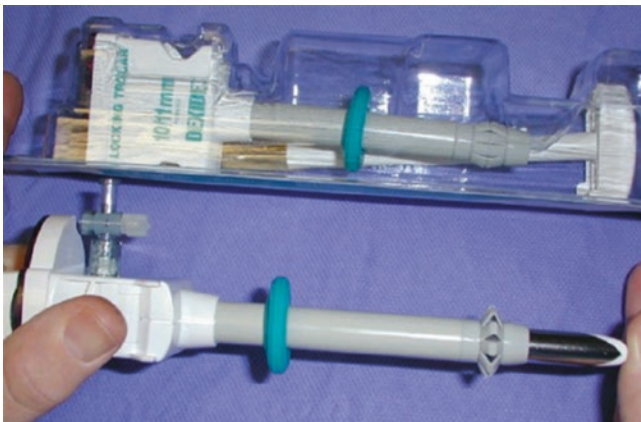

Fig. 4.3 A 10/11 mm trocar with "locking" device




Fig. 4.4 A 11 mm bladeless trocar

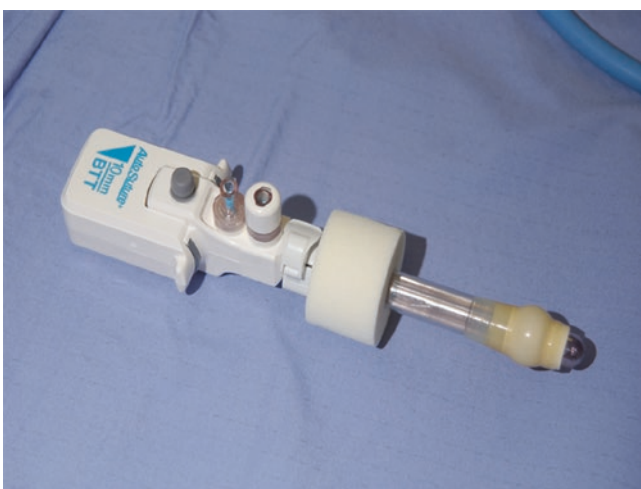

Fig. 4.5 A blunt tip trocar uses a balloon and a sliding ring to seal



Fig. 4.6 A 15 mm trocar with shielded blade

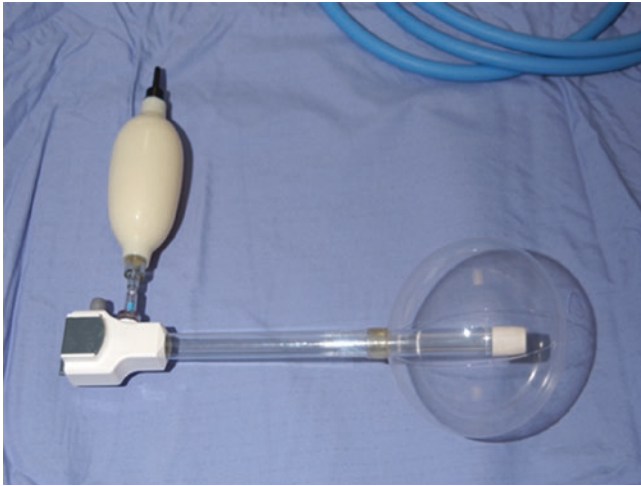


Fig. 4.7 An inflated balloon dilator

Relatively different trocars (ports) are being used in LESS surgery. Both primary and secondary access is achieved through a single site. An international review of the instruments used during LESS in urology showed that six such ports were the most popular [1]. Each of them has its own specifications (Fig. 4.8).

Depending on which technique is used (single site or not), similar access equipments are used in robotic surgery as well.

4.3 Manipulative Instruments

The variety of manipulative instruments used in laparoscopic surgery is increasing all the time. Retraction can be achieved using a wide range of tissue-holding forceps (Table 4.1), dissectors, probes and dedicated retractors (Table 4.2). These instruments are available in various sizes, shapes and forms to suit different purposes.

Grasping forceps tip can be single action or double action, atraumatic or traumatic, straight, curved, Allis, Babcock or angled (Table 4.1) and can have a locking or non-locking handle. Retraction during laparoscopy is done by applying grasping forceps, but in special circumstances, laparoscopic retractors are required. Scissors are usually used for dissection with or without diathermy. Scissors tip can be fine, curved, straight or hooked (Table 4.3). Suturing requires needle holders and at times knot drivers (Table 4.4).

The wider use of robotic surgery and LESS in Urology generated the need for new instruments (Table 4.5). New designs attempt to compensate the loss of triangulation in single site surgery. Complex surgical maneuvers can be

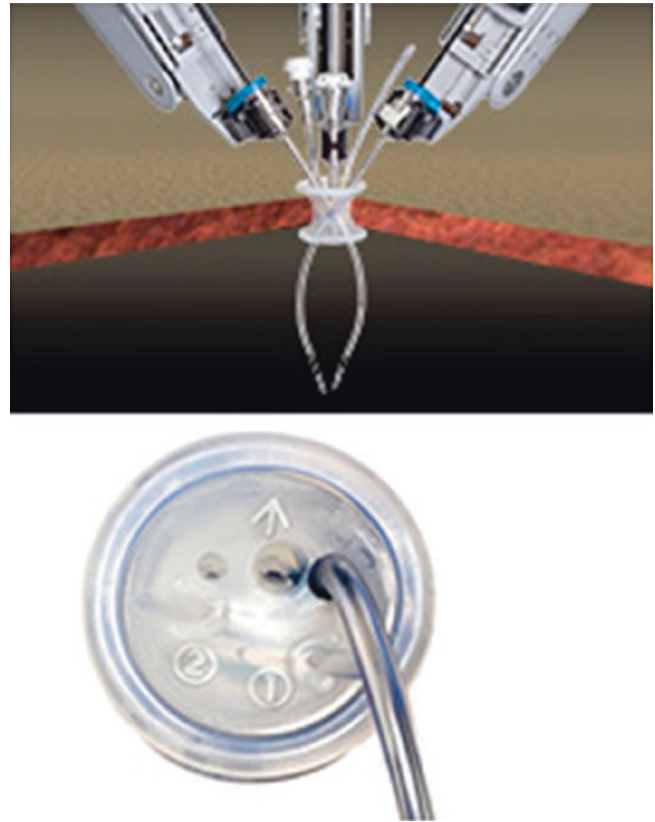

Fig. 4.8 LESS port. Replicated from <https://www.davincisurgerycommunity.com> with permission

achieved using robotic instruments which, unlike the human wrist, have a 360° range of motion (Table 4.6). The ability for more accurate movements and potentially safer surgery is enhanced by the 3D (three dimensional) visual output and the collision avoidance technology, which prevents collision between the instruments as well as the instruments and the camera both in and out of the body (Fig. 4.9). Critics however, will point out the complete lack of haptic feedback in robotic surgery.

4.4 Hemostasis

Monopolar coagulation or cutting currents using a dissecting scissors or a grasping forceps are commonly used. This type of coagulation can be delivered using hook or spatula cautery (Table 4.7). However bipolar coagulation is a safer option. A technologically advanced manner to deliver bipolar coagulation is through ENSEAL® (Ethicon, Somerville, New Jersey), a bipolar device designed to provide uniform compression within its two jaws, hence delivering a more consistent blood vessel seal. It can have straight, articulated or curved jaws.

Table 4.1 Graspers for traditional laparoscopic surgery





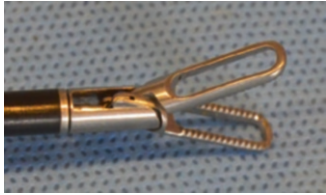
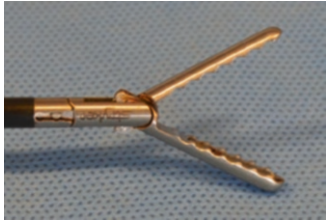

Name	Image
Atraumatic graspers	
Claw graspers	
Long atraumatic graspers	
Long Johan graspers	
Short Johan graspers	
Wave graspers	
Babcock grasper	

Table 4.2 Different types of laparoscopic dissectors


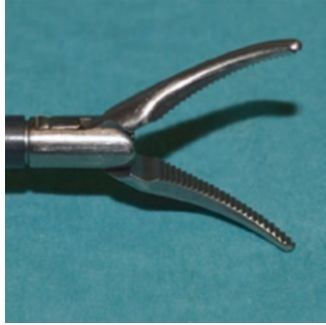

Name	Images
Dolphin nose	
Maryland	
Right angle dissector	

Table 4.3 Different types of laparoscopic scissors




Name	Image
Curved scissors	
Small curved scissors	
Hook scissors	

Table 4.4 Instruments for suturing and knot tying





Name	Images
Needle holder – different tips	
Needle holder – different handles	

Table 4.5 Different types of LESS instruments

Name	Image
SILS dissector	
SILS scissors	

The HARMONIC SCALPEL® is an ultrasonic cutting and coagulating surgical device, offering surgeons important benefits including; minimal lateral thermal tissue damage, minimal charring and desiccation, and simultaneous cutting and coagulation.

LigaSure™ Vessel Sealing Generator produces a high-current, low-voltage output that corresponds to at least four times the current of a standard electrosurgery generator, with one-fifth to one-twentieth the amount of voltage. It permanently fuses vessels up to and including 7 mm in diameter and tissue bundles without dissection or isolation. Table 4.7 demonstrates important features of various devices currently available for coagulation and cutting.

Coagulation can also be achieved by ligating, clipping or clamping a vessel. There are various types of clip applicators and clamps used for these purposes (Table 4.8).

Table 4.6 Robotic instruments. The images were kindly provided by Intuitive surgical® United Kingdom






Name	Image
Monopolar curved scissors (Intuitive surgical®)	
Hook cautery (Intuitive surgical®)	
Spatula cautery (Intuitive surgical®)	
Maryland bipolar forceps (Intuitive surgical®)	
Curved bipolar dissectors (Intuitive surgical®)	
Fenestrated bipolar forceps (Intuitive surgical®)	
Vessel sealer (Intuitive surgical®)	

Table 4.6 (continued)

Name	Image
Long curved dissectors (Intuitive surgical®)	A pair of long, curved surgical dissectors with serrated tips, attached to a black robotic arm.
Micro bipolar forceps (Intuitive surgical®)	A pair of micro bipolar forceps with small, curved tips, attached to a black robotic arm.
Small clip applier (Intuitive surgical®)	A small clip applier with a curved, hook-like tip, attached to a black robotic arm.
Large clip applier (Intuitive surgical, Sunnyvale, Sunnyvale, CA, USA)	A large clip applier with a curved, hook-like tip, attached to a black robotic arm.
Needle holder (Intuitive surgical, Sunnyvale, Sunnyvale, CA, USA)	A needle holder with a curved, hook-like tip, attached to a black robotic arm.
ProGrasp TM forceps (Intuitive surgical, Sunnyvale, Sunnyvale, CA, USA)	A pair of ProGrasp TM forceps with long, curved tips, attached to a black robotic arm.

Table 4.6 (continued)

Name	Image
Cadiere forceps (Intuitive surgical, Sunnyvale, Sunnyvale, CA, USA)	A pair of Cadiere forceps with long, curved tips, attached to a black robotic arm.
Cobra grasper (Intuitive surgical, Sunnyvale, Sunnyvale, CA, USA)	A Cobra grasper with a curved, hook-like tip, attached to a black robotic arm.
DeBakey forceps (Intuitive surgical, Sunnyvale, Sunnyvale, CA, USA)	A pair of DeBakey forceps with long, curved tips, attached to a black robotic arm.
Long tip forceps (Intuitive surgical, Sunnyvale, Sunnyvale, CA, USA)	A pair of long tip forceps with long, curved tips, attached to a black robotic arm.
Round tip scissors (Intuitive surgical, Sunnyvale, Sunnyvale, CA, USA)	A pair of round tip scissors with rounded tips, attached to a black robotic arm.
Pott's scissors (Intuitive surgical, Sunnyvale, Sunnyvale, CA, USA)	A pair of Pott's scissors with long, curved tips, attached to a black robotic arm.

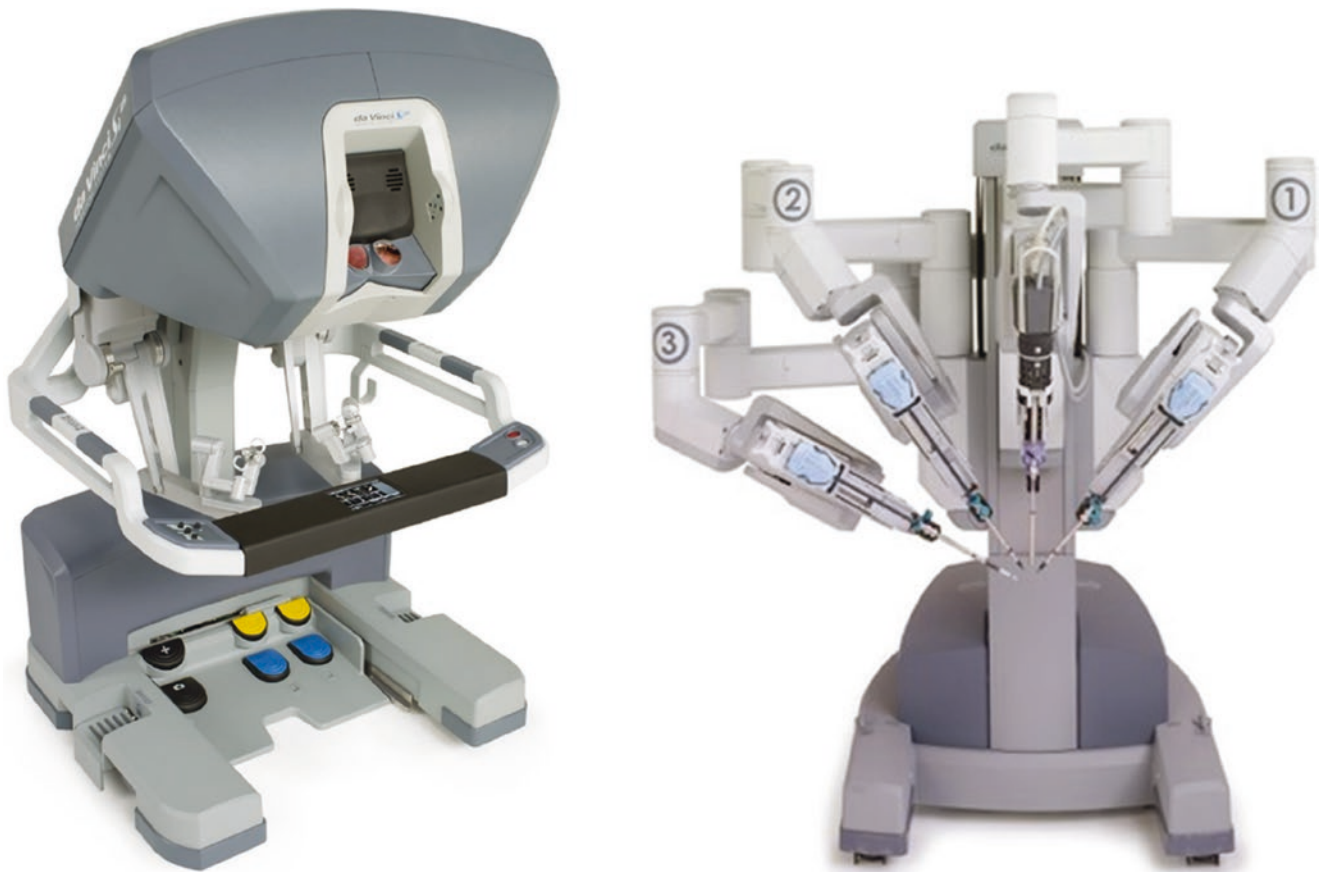


Fig. 4.9 The DaVinci® robotic system console (Images replicated with permission from Intuitive surgical® website)

Table 4.7 Coagulation devices


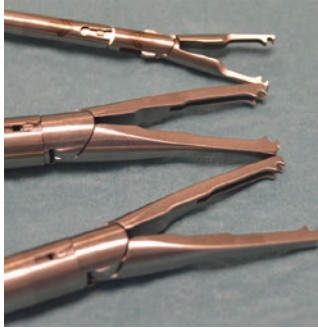

Name	Type of energy	Image
Spatula electrode	Monopolar electro cautery	
Hood electrode	Monopolar electro cautery	
Bipolar forceps	Bipolar electro cautery	
Harmonic ultrasonic device® (picture kindly provided by Intuitive surgical®)	Ultrasound waves	

4.5 Fibrin-Based Haemostatic Agents

Fibrin sealant has been used in a wide variety of clinical applications. The first commercial product Tisseel (Baxter Healthcare Corp.) was approved in 1998. Currently, several products are available with varying fibrin and thrombin concentrations (Table 4.9).

Another important instrument is the retrieval bag, a disposable device used as a receptacle for collecting and extracting tissue specimens.

Table 4.8 Various types of clip applicators and clamps

Names	Images
Hem-o-lok clip applier	
Hem-o-Lok® applicators 5, 10, 15 mm	
Clip applicators with various tips	

An ideal endoscopic bag (Fig. 4.10) for delivering intra-abdominal specimens should be (a) impermeable to fluids and be strong, (b) opened easily, (c) big enough to place the entire specimen easily, and (d) having a mechanism to quickly close the bag to prevent spillage.

A collection of organ entrapment and retrieval systems are available. Depending on the size of the tissue and whether intra-abdominal morcellation or intact organ retrieval is planned, the surgeon is able to select one among different materials and designs.

4.5.1 Lahey Bags

Lahey bags are large, sterile, transparent PVC bags. They usually measure about 50 × 50 cm with a drawstring at the neck. Although the Lahey bag can accommodate virtually any size specimen, it can be unwieldy within the confines of the closed abdomen. The material is not overly robust and can easily tear if pulled too hard with laparoscopic instruments.

4.5.2 Rip-Stop Nylon

Given the limited strength of the Lahey bags and the ease with which they can tear with manipulation, many surgeons have turned to rip-stop nylon bags.



Fig. 4.10 Specimen retrieval bag

Table 4.9 Fibrin based haemostatic agents [7]

Product name Fibrinogen	Fibrinogen concentration (mg/mL)	Thrombin concentration (IU/mL)	Factor XIII	Antifibrinolytic agent
Beriplast®P (CSL Behring, Germany)	90	500	YES	Bovine aprotinin: 1000 KIU/mL
Biocol® (LFB, France)	127	558	YES	Bovine aprotinin: 3000 KIU/mL
Bolheal® (Kaketsuken Pharmaceutical, Japan)	80	250	YES	Bovine aprotinin: 1000 KIU/mL
Evicel® – formerly Crosseal® (Omrix Biopharmaceuticals, Israel)	70	1000	NO	None
Quixil® (Omrix Biopharmaceuticals, Israel)	50	1000	NO	Tranexamic acid: 85–105 mg/mL

The originally designed LapSac (Cook Urological, Spencer, IN), which is made of two sheets of nylon with a polyurethane inner coating and polypropylene drawstring at the neck, is the least susceptible to perforation. The LapSac comes in several sizes, the largest measuring 8×10 cm (1500 mL).

Eco Sac (EMT Healthcare) is constructed from stitched rip-stop nylon coated with polyurethane. It is larger than LapSac (3100 mL) has four loops secured to the edges that make introducing and manipulating the bag much easier. We prefer the specially designed commercially available bag, which allows excellent control of the mouth of the bag and a good drawstring mechanism (Endo Catch™).

References

1. Kaouk JH, Autorino R, Kim FJ, Han DH, Lee SW, Yinghao S, et al. Laparoendoscopic single-site surgery in urology: worldwide multi-institutional analysis of 1076 cases. *Eur Urol*. 2011;60(5):998–1005. Epub 2011 Jun 12.
2. Verit A, Rizkala E, Autorino R, Stein RJ. Robotic laparoendoscopic single-site Surgery: from present to future. *Indian J Urol*. 2012;28(1):76–81. doi:10.4103/0970-1591.94962.
3. Raman JD, Bagrodia A, Cadeddu JA. Single-incision, umbilical laparoscopic versus conventional laparoscopic nephrectomy: a comparison of perioperative outcomes and short-term measures of convalescence. *Eur Urol*. 2009;55:1198–206.
4. Canes D, Berger A, Aron M, et al. Laparo-endoscopic single site (LESS) versus standard laparoscopic left donor nephrectomy: matched-pair comparison. *Eur Urol*. 2010;57:95–101.
5. Training for laparoendoscopic single-site surgery (LESS). Enrico Mattana Müllera, Leandro Totti Cavazzolaa, João Vicente Machado Grossia, Mirandolino Batista Marianob, Cláudio Moralesb, Maurício Brunb.
6. Kyriazis I, Liatsikos E. Needlescopic surgery is here (again) to stay. *European Urology today*. Dec 2013–Jan 2014. https://uroweb.org/wp-content/uploads/EUT_2013_6.pdf.
7. Amer A, Wilson C, White S, Manas D. Fibrin-based haemostatic agents for reducing blood loss in adult liver resection (Protocol). *Cochrane Library*. Available at: <http://onlinelibrary.wiley.com/doi/10.1002/14651858.CD010872/abstract>. Last retrieved: 19th Apr 2015.

Part II

Reconstructive Procedures of Kidney and Pelvi Ureteric Junction

Manickam Ramalingam, Kallappan Senthil,
George P. Abraham, C. Mallikarjuna,
Kesava Pillai Subramonian, R. Vijay, and G. Datson

5.1 Basic Principles

5.1.1 Introduction

Schuessler reported the first case of laparoscopic pyeloplasty in 1993 [1]. Since then several centres have taken it up and many large series on this procedure are available in literature. Today laparoscopic pyeloplasty is an established alternative procedure to standard open pyeloplasty [2]. The other minimally invasive alternative for pyeloplasty is endopyelotomy. Though less morbid, the success rate is around 75 % even in the best of hands. It is contraindicated in situations like the presence of crossing vessels, which may be associated in around 20 % of patients [3].

M. Ramalingam (✉)
PSG Hospitals,
Coimbatore, India
e-mail: uroram@yahoo.com

K. Senthil
Urology Clinic, Gowtham Annexe, Coimbatore, India
e-mail: senthilsatya@hotmail.com

G.P. Abraham
Department of Urology, PVS and Lakeshore Hospital,
Cochin, Kerala, India
e-mail: drgeorgepabraham@gmail.com

C. Mallikarjuna
Asian Institute of Nephrology and Urology,
Hyderabad, Telangana, India
e-mail: mallikuro7@gmail.com

K.P. Subramonian
University Hospital Birmingham, Birmingham, UK
e-mail: ksubu2000@gmail.com

R. Vijay
PVS Hospitals, Cochin, Kerala, India
e-mail: vijayrd@yahoo.com

G. Datson, MBBS, MS, M.Ch, FMAS
Lakeshore Hospital, Cochin, Kerala, India
e-mail: datsongeorge@gmail.com

5.1.2 Indications

Pyeloplasty is indicated in significant pelvi ureteric junction obstruction; in the presence of more than 10 % difference in the split renal function; infection; type II O'Reilly curve in isotope renogram and in obstruction with secondary calculus.

5.1.3 Contraindication

- (a) All general contraindications to laparoscopy
- (b) Intrarenal pelvis
- (c) Failed pyeloplasty may be a relative contraindication.

5.1.4 Patient Preparation

1. Bowel preparation
2. Antibiotics.

5.1.5 Planning of Approach

Retrograde pyelogram (RGP) is done initially to assess the exact location and length of the narrow segment and pelvic configuration. RGP also rules out other ureteric pathology. Retrograde stent placement is an option after RGP, negating the slightly difficult antegrade stenting. The disadvantage of retrograde stenting is the difficulty in introduction of the scissors for spatulating the ureter in very narrow pelviureteric junction obstruction. In some situations the preplaced stent can impede suturing. Various minimally invasive approaches and techniques are available, like transperitoneal, retroperitoneal, transmesocolic approaches; and dismembered and nondismembered techniques. Retroperitoneal approach is preferable as it is akin to open approach. However the suturing is more difficult due to reduced space and overcrowding of instruments.

5.1.6 Complications

General complications are bleeding, bowel injury and transient ileus. Early specific complications are prolonged urinary leak resulting in ileus, persisting drainage or urinoma. This may settle spontaneously or with ultrasound scan guided percutaneous nephrostomy which is retained for about 2 weeks.

Delayed complications include UPJ stenosis, which might need reoperation.

5.2 Transperitoneal Approach

Entry

Patient is placed in 70° lateral position without kidney bridge elevation. The port position is as described in the Fig. 5.71. 10 mm camera port has to be placed in the midclavicular line about 5 cm above and lateral to umbilicus for a good view. Secondary ports are placed four-finger breadth apart for triangulation. A 30° telescope may be preferable for better view from different angles

The line of Toldt is incised with either a hook dissector or ultrasonic shears. Colon is reflected medially until the ureteropelvic junction and part of the pelvis is well seen. Additional port (5–10 mm convertible) is inserted in the epigastrium or flank for the retraction or suction if the redundant bowel disturbs the vision or there is collection.

Once the pelvis and UPJ are adequately mobilised, a stay suture is taken through the pelvis to stabilise it and avoid frequent unwanted movements of the instrument. A nylon suture on a straight needle is used for this purpose. The suture is brought out through the flank.

5.2.1 Dismembered Pyeloplasty

Dismembered pyeloplasty is preferable in large pelvis with very narrow UPJ or crossing vessel. Pelvis is incised at an angle, extending from the lateral to the superomedial border. Subsequently, the narrow UPJ and redundant pelvis is excised and the ureter is spatulated on the lateral aspect for about one cm using curved scissors (through subcostal port). Suturing is started at the angle of ureteric spatulation and continued along the posterior wall. Interrupted or continuous sutures with 4–0 or 5–0 absorbable material is preferred. Ureteric stent can be passed down antegrade at this stage (either directly through subcostal port or using veress needle. Finally anterior layer is sutured and pyelotomy is closed with 4–0 interrupted or continuous locking sutures.

5.2.2 Non Dismembered Pyeloplasty

If the pelvis is not large and the UPJ is short without a crossing vessel, Fengerplasty or

Y – V plasty can be done because it is technically easier and can give equally good results. Suturing technique described earlier in transperitoneal approach can be followed.

5.2.3 Transmesocolic Pyeloplasty [9, 10]

In left sided UPJ obstruction in children and in thin adults, the dilated pelvis bulges through the mesocolon. Once the mesocolon is incised, the bulging pelvis can be pulled into the peritoneal cavity provided that the mesocolic arterial arcade is wide trans mesocolic approach can be used. Thus the UPJ can be approached without the need for colonic mobilisation. In our series of 102 patients, 49 patients underwent transmesocolic pyeloplasty. Ref: [10, 16].

The advantages are

- (a) Very good illumination as there is not much of raw area with blood clots, which can absorb light.
- (b) UPJ can be quickly accessed.

Occasional problem in this approach is injury to left colic vessel. A stay suture on the pelvis will stabilize it and prevent retraction. Rest of the procedure viz. excision of UPJ and suturing techniques are the same as described under transperitoneal approach. The mean operative time is reduced by about 15–20 min.

5.3 Retroperitoneoscopic Approach

With the patient in the 90° lateral positions, and without the kidney bridge elevated, the primary (camera) port is inserted by open technique in the renal angle i.e. lateral to erector spinae just below the tip of 12th rib.

A 1.5 cm long incision is made. A haemostat is introduced to split the muscles and the lumbodorsal fascia. The index finger is introduced through the wound into the retroperitoneal space to push away the peritoneum anteriorly, thus enlarging the potential space. The space is inflated to the required volume (150–600 ml according to the built and age of patient) using balloon technique. Alternatively commercially available balloon trocars can be used directly. This camera port has to be fixed airtight with a mattress suture to prevent gas leak. Subsequent instrument ports are introduced under vision in the anterior axillary line – one each in the subcostal area and above iliac crest. An additional 5 mm port can be placed in the subcostal area for retraction, if necessary.

The first landmark to be identified is the psoas muscle. Dissection along this plane easily leads to the ureter. If the Gerota's fascia with perinephric fat is extensive over the UPJ, it may be incised (or excised) for free movement of the hand instruments.

A preplaced stent or guidewire in ureter makes identification of ureter easier (gonadal vessel may be mistaken for ureter). UPJ and part of pelvis which need to be excised are mobilised.

5.3.1 Nondismembered Pyeloplasty

If pelvis is not very large and UPJ is short, nondismembered Y – V plasty or Fengerplasty [2] (Heineke Mikulicz) technique can be performed. One can use sharp scissors or endoknife for pyelotomy and spatulation of ureter. Suturing of anterior wall starts distally with 4–0 or 5–0 polyglactin or polydioxanone suture in an interrupted or continuous fashion. Once the anterior wall is completed, stent can be placed across the suture line (if there is no preplaced stent). Antegrade stenting can be done through an additional 3 mm port or veress needle. Subsequently the posterior layer is sutured.

5.3.2 Dismembered Pyeloplasty

This technique is similar to that of transperitoneal approach except that anterior layer is sutured first followed by the posterior layer. A peripelvic tube drain is advanced through one of the 5 mm ports. After irrigating and sucking all the collected fluids, ports are closed with 2–0 vicryl.

5.4 Special Situations

5.4.1 UPJ Obstruction in Horse Shoe Kidney

The important points to consider are the presence of isthmus and aberrant vessels. Aberrant vessels need to be dissected and preserved. The difference in the patient position and the port position is described in the figure (Fig. 5.71 in Horse shoe section). Rest of the steps are similar to the previously described transperitoneal technique.

5.4.2 UPJ Obstruction with Secondary Calculi

Various techniques can be used to remove the secondary calculi. They can be directly removed with grasper through pyelotomy. Multiple small calculi can be removed by flushing. Flexible cystoscope can be passed through one of the ports to reach the calyces and remove stones by basketing. Large stones can be dealt with by passing nephroscope through one of secondary ports to basket or grasp calculi.

5.4.3 Redopyeloplasty

The basic steps of redopyeloplasty (failed pyeloplasty), are not different from the classical transperitoneal pyeloplasty. Since open pyeloplasty is almost always retroperitoneal, retroperitoneoscopic approach may not be feasible due to extensive adhesions. So all these cases are better done by transperitoneal approach.

The adhesions around the PUJ need meticulous dissection and the surgeon should be prepared for the management of long defects. Since the UPJ is dependant and pelvis is small in secondary UPJO, non dismembered technique may be attempted (Table 5.1).

Vessel crossing UPJ, difficulties in stenting, Horse shoe kidney with UPJ obstruction and Culp flap pyeloplasty have been illustrated.

Table. 5.1 Comparison of various large series of laparoscopic pyeloplasty

References	No. Pt	Approach	Type/correction (no)	Mean hrs operative time	Mean days hospitalised follow up	Mean months	% success	No. conversions (%)	No. complications (%)
Jarrett et al. [4]	100	TP	DM (71) Y-V plasty (20, other 9)	4.4 (2–8)	3.3 (2–8)	26.4 (1–72)	96	0 (0)	13 (13)
Janetschek et al. [5]	65	RP, RP	Fengerplasty	2.1	–	25 (4–60)	98	0 (0)	7 (12)
Chen et al. [6]	57	–	DM (44), Y-V plasty (13)	4.3 (2.3–8.0)	3.3 (2–6)	17.2 (1–37)	96	0 (0)	7 (12.7)
Soulfe et al. [7]	55	TP	DM (48), Fenger plasty (7)	3.1 (1.7–4.3)	4.5 (1–14)	14.4 (6–43.6)	87	3 (5.5)	2 (4)
Eden et al. [8]	50	RP	DM (50)	2.7 (2–4)	2.6 (2–7)	18.8 (3–72)	98	2 (4)	1 (2)
Turk et al. [9]	49	RP	DM (49)	2.7 (1.5–4)	3.7 (3–6)	23.2 (1–53)	98	0 (0)	–
Ramalingam et al. [10]	129	TP (71) TM (49) RP (9)	DM (113) NDM-Fenger (12) Y-V plasty (5) Culp Plasty (6)	3.2–4	3.5 (2.7–4.6)	36 (3–68)	97 %	3	4 (6)
				1.5–2.5	3.5		100 %		
Viswajeet singh et al. [11]	112	TP, RP	DM (TP-56, RP- 56)	162±18 188±24	3.39±0.28 3.14±0.36	30.75±4.85 30.99±5.59	96.4 96.6	1 2	14.8
Moon et al. [12]	170	TP	DM	140	3.2	12	96.2 %	0.6 %	7.1 %
Castillo et al. [13]	80	TP	DM	93.2					
Singh et al. [14]	142	TP	DM	145	3.5	30	96.8 %	2 (•)	19 (•)
Inagaki et al. [15]	147	TP	106DM, 28 YV, 11 Fenger, 2 Culp	246	3.1	24	95 %	0	11 (•)

TP Transperitoneal, TM Transmesocolic, RP Retroperitoneal, DM Dismembered

5.5 Transperitoneal Dismembered Pyeloplasty

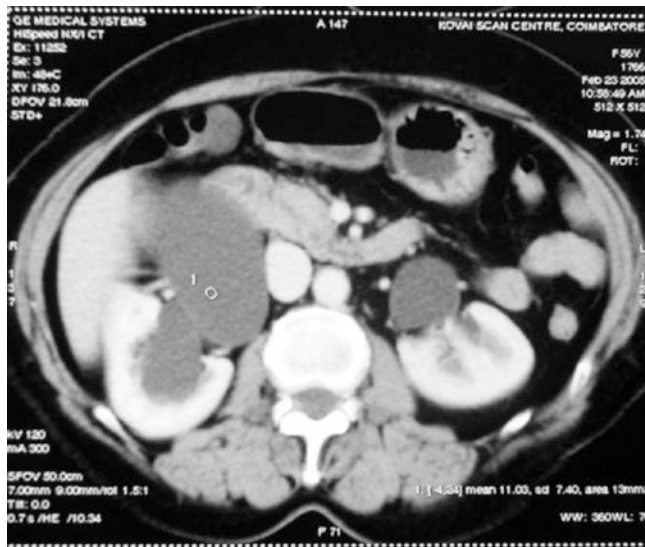


Fig. 5.1 CT image- right UPJ obstruction

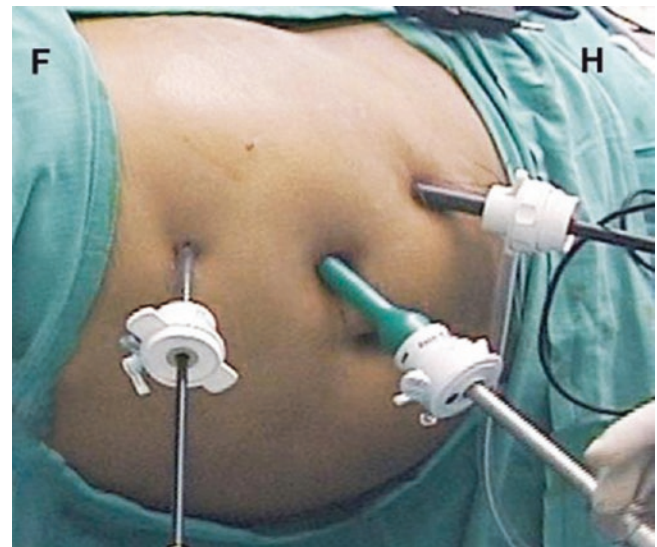


Fig. 5.2 Ports position

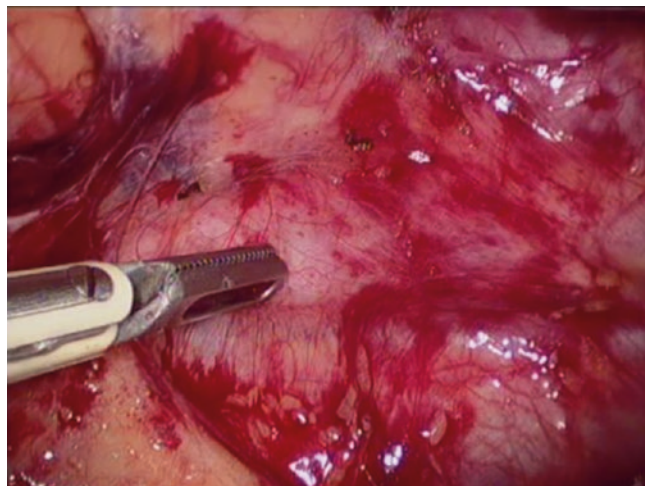


Fig. 5.3 Initial laparoscopic view showing the bulging right renal pelvis

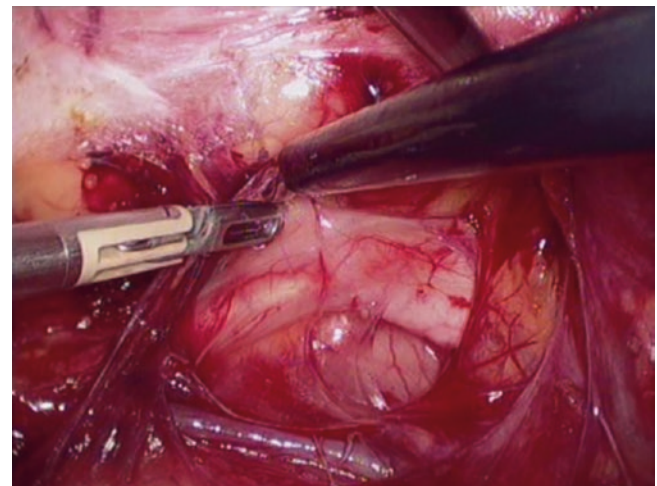


Fig. 5.4 Ureter is identified as a tubular structure, with characteristic vascular plexus, in the retroperitoneum

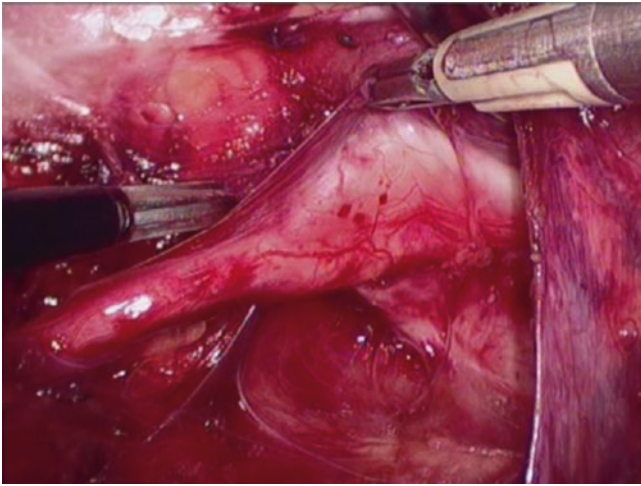


Fig. 5.5 Ureter is traced proximally till the dilated pelvis. Dissection of ureter is done outside the adventitial layer, preserving the vascular arcade

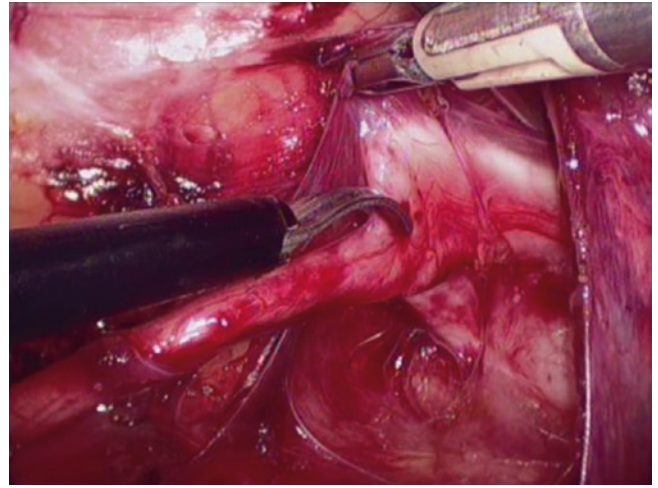


Fig. 5.6 Pelvi ureteric junction is identified as a transition between dilated pelvis and narrow ureter. Oblique pyelotomy done initially along the lateral aspect

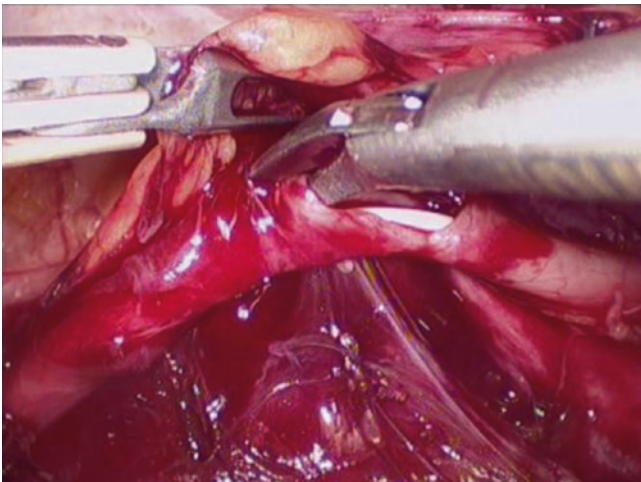


Fig. 5.7 Ureter is spatulated laterally, using curved scissors or Potts scissors

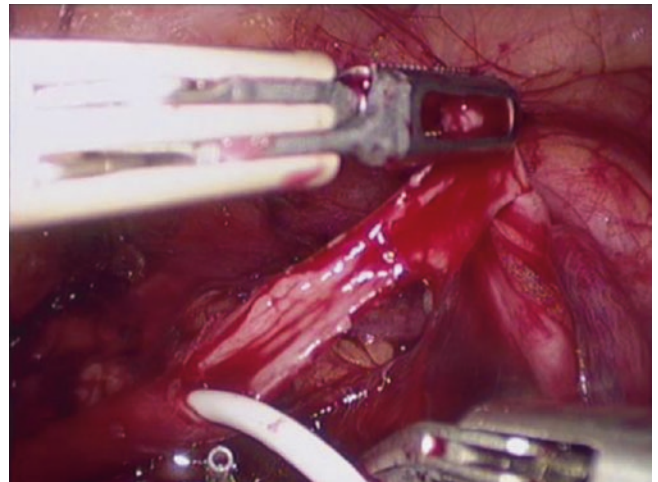


Fig. 5.8 Spatulation is complete, when the normal calibre ureter with rugosities are seen. A 'give' may be felt when spatulation extends from the narrow segment to normal segment

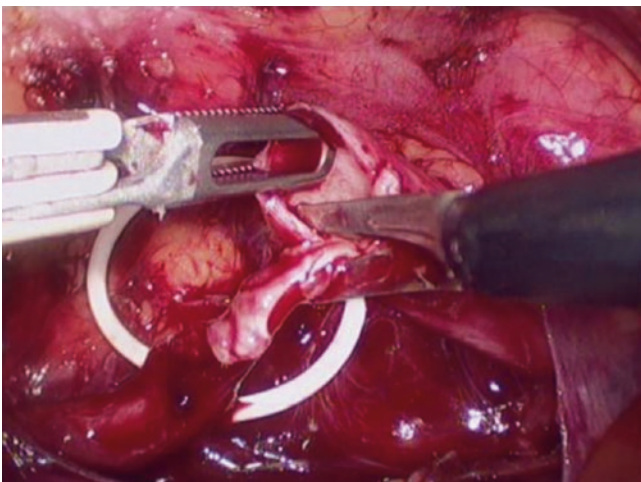


Fig. 5.9 Pyelotomy is extended with a medial spatulation. A small strip is preserved along the posterior wall for better initial orientation

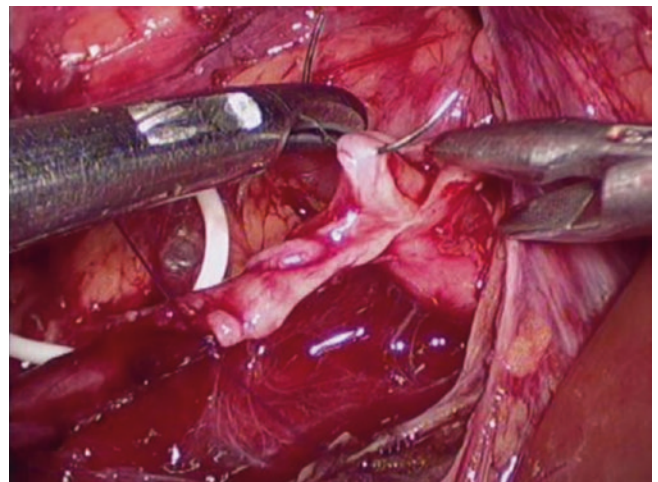


Fig. 5.10 Pelvi ureteric anastomosis started with the initial suture outside-in from the apex of pelvis using 4-0 PDS suture

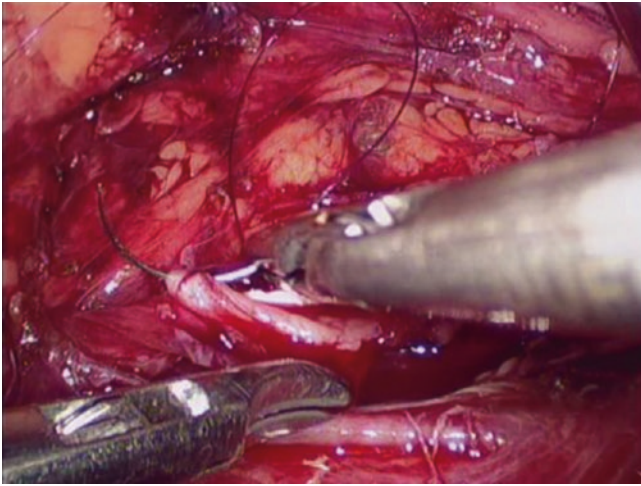


Fig. 5.11 Corresponding suture is taken through the apex of the ureteric spatulation inside-out

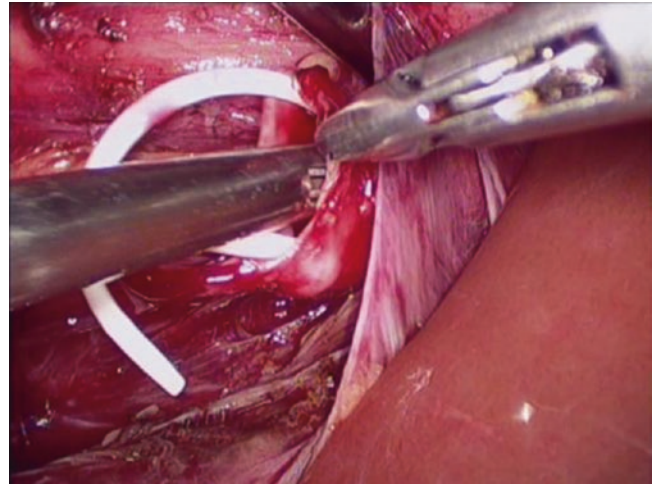


Fig. 5.12 Preplaced stent is being repositioned

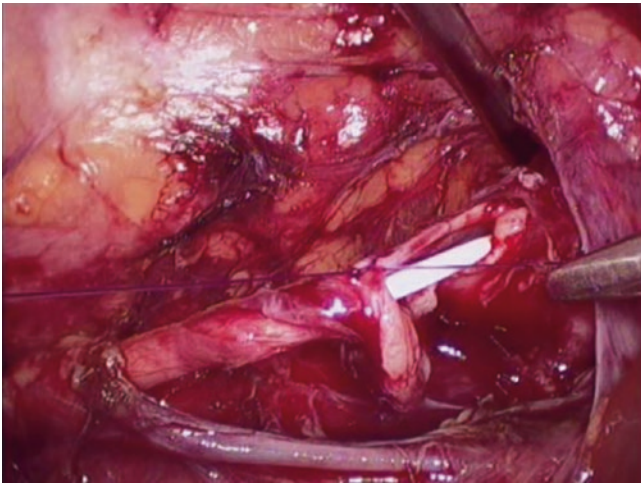


Fig. 5.13 Apical suture in place

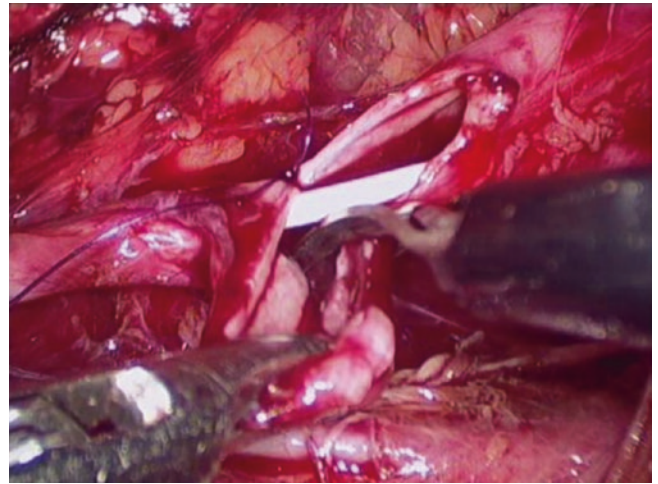


Fig. 5.14 Dividing the posterior pelvic wall strip completes division of PUA

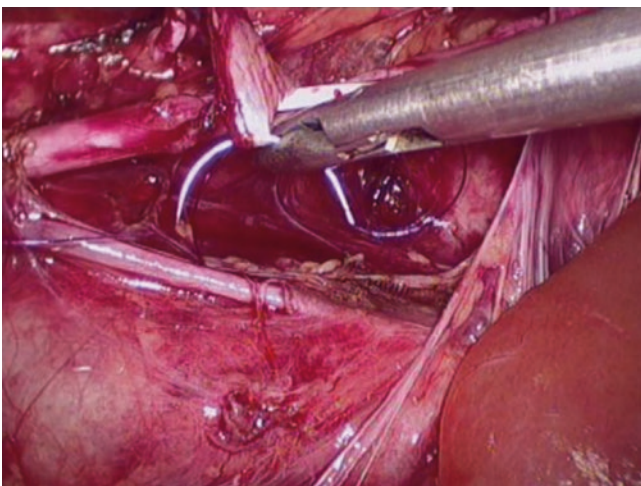


Fig. 5.15 Apical suture is continued in the posterior layer

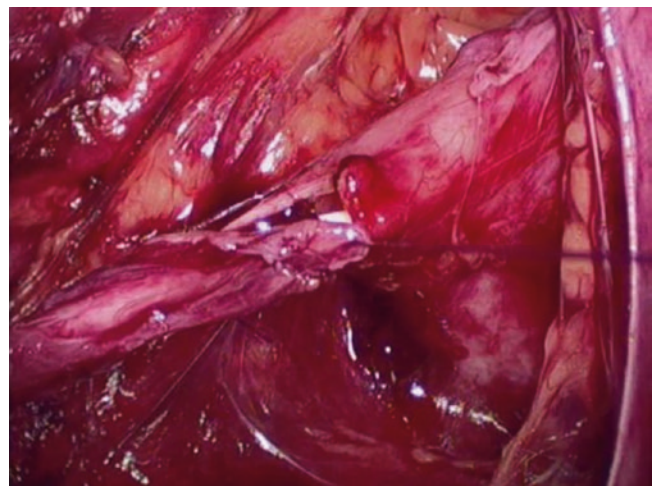


Fig. 5.16 Image shows the completed posterior wall suturing

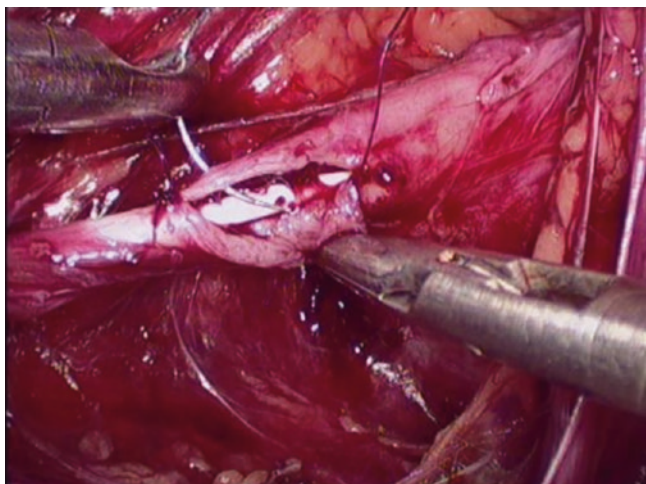


Fig. 5.17 Anterior wall suturing is done next, with the similar suture

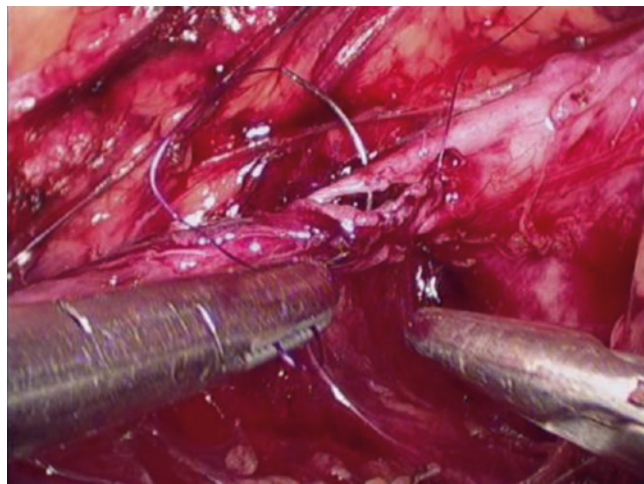


Fig. 5.18 Continuous suturing of anterior wall in progress

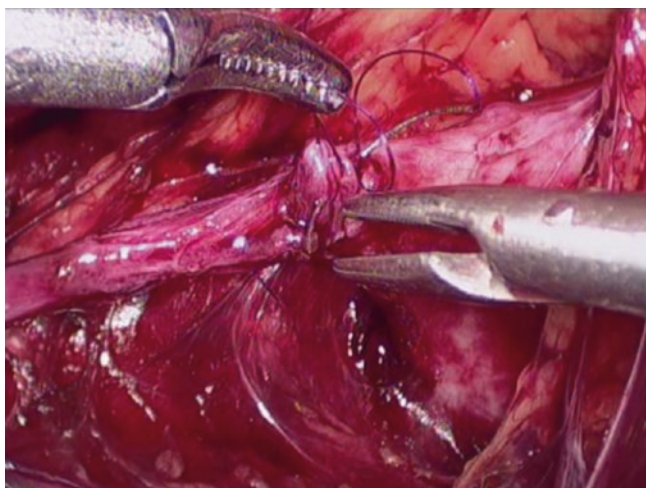


Fig. 5.19 Final stages of pelvi ureteric anastomosis

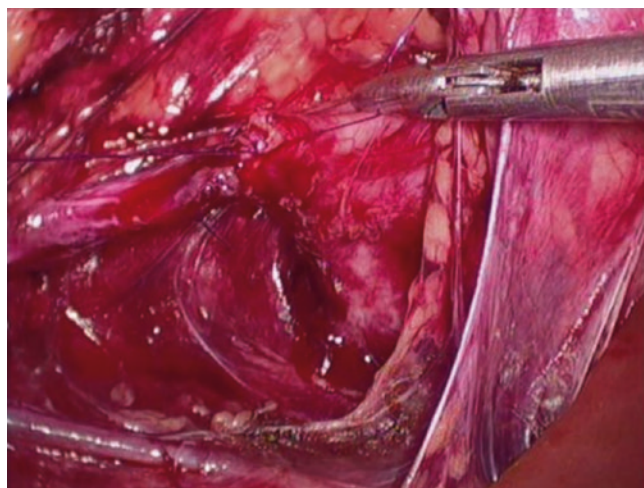


Fig. 5.20 Completed pyeloplasty

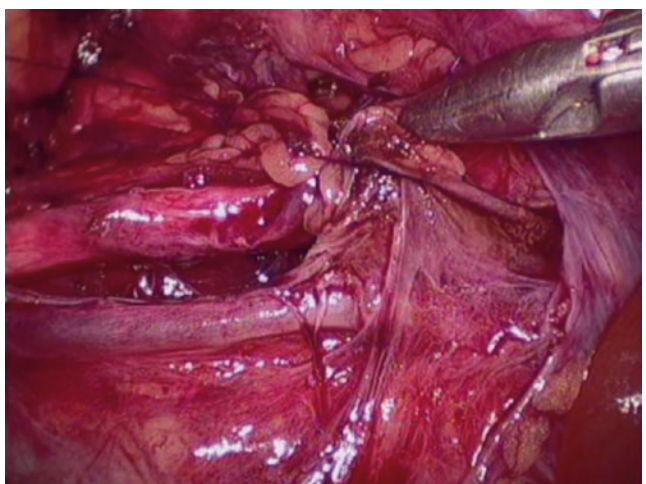


Fig. 5.21 Perinephric fat used as cover for anastomosis

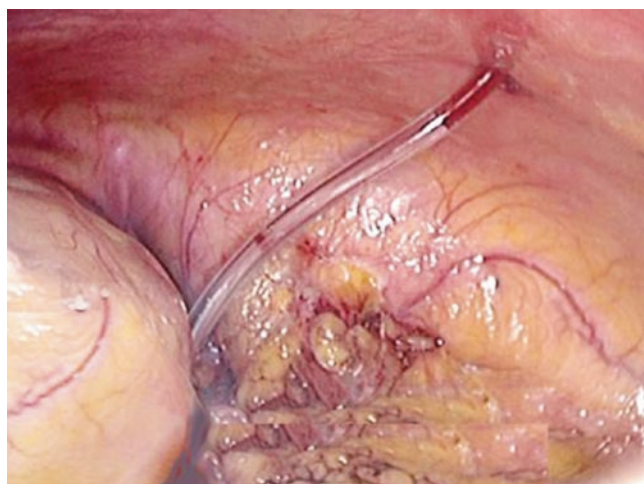


Fig. 5.22 Drain placed through lower port

5.6 Transperitoneal Non Dismembered Pyeloplasty

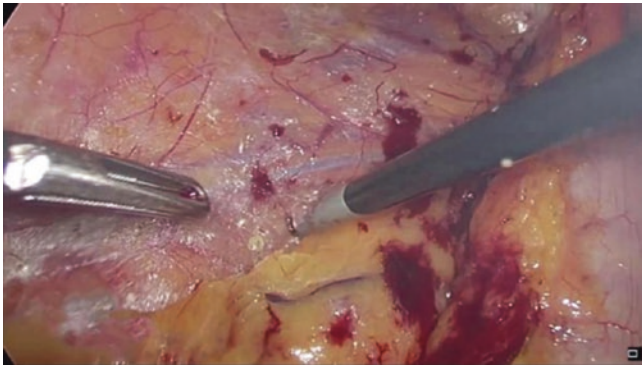


Fig. 5.23 Left colon being reflected along line of Toldt

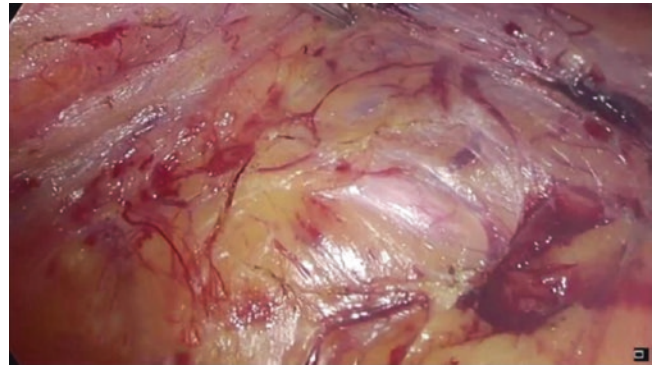


Fig. 5.24 Ureter identified in the retroperitoneum with its characteristic features

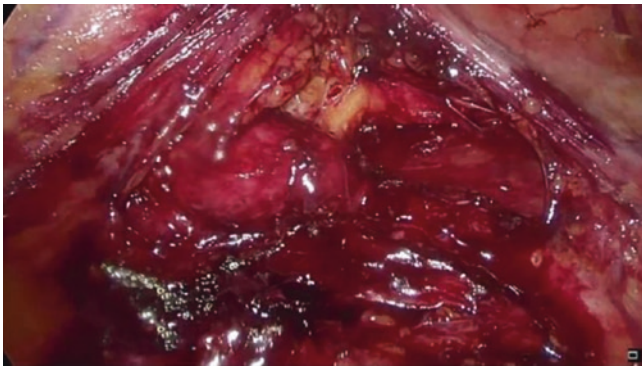


Fig. 5.25 Ureter traced proximally till pelvis

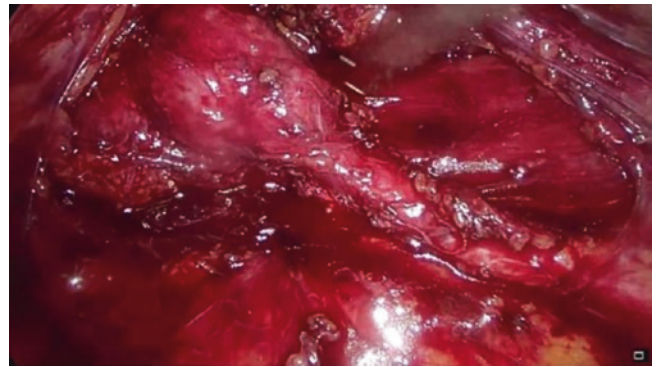


Fig. 5.26 Pelvi ureteric junction identified and dissected all around preserving adventitia around the ureter

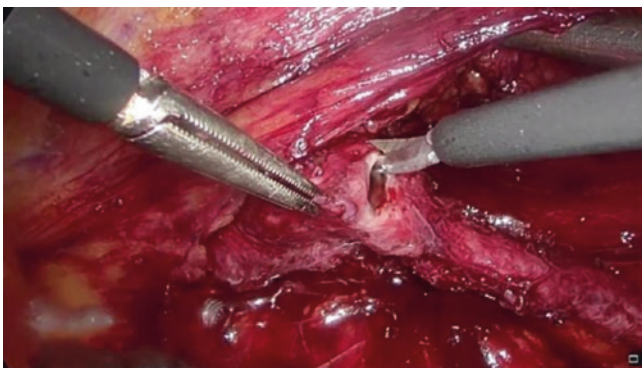


Fig. 5.27 Pyelotomy being done in the shape of 'V' with the apex of V just proximal to PUJ

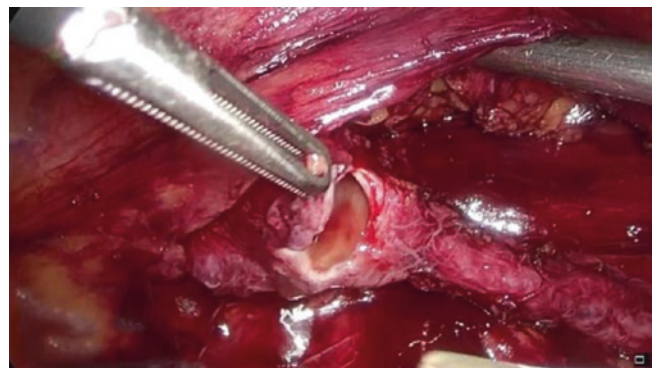


Fig. 5.28 Pyelotomy completed

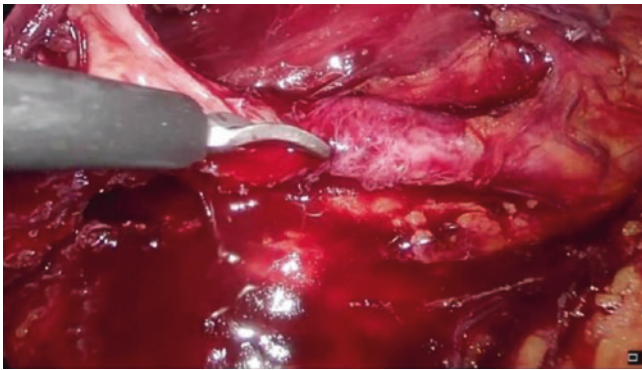


Fig. 5.29 Ureteric spatulation being done as the vertical limb of 'Y'

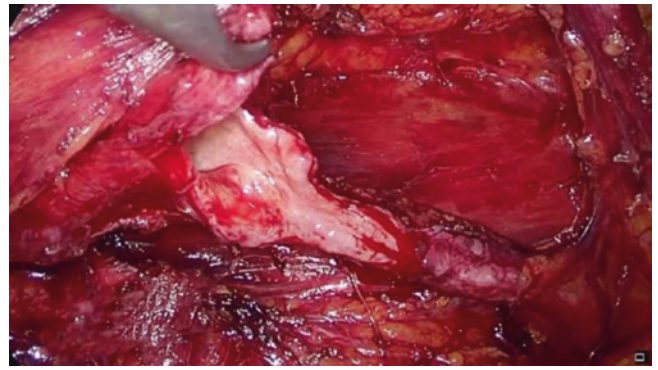


Fig. 5.30 Completed 'Y' incision

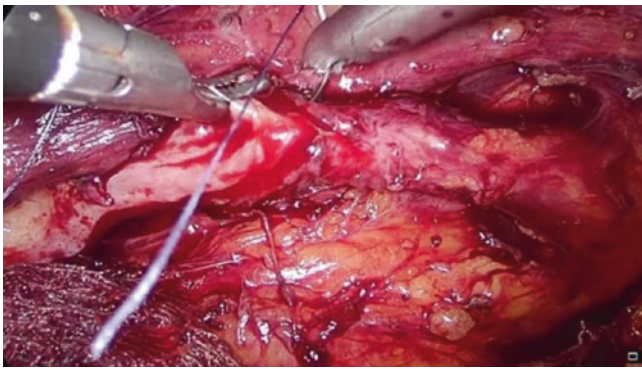


Fig. 5.31 Apical suture through the ureter with 4-0 polyglactin

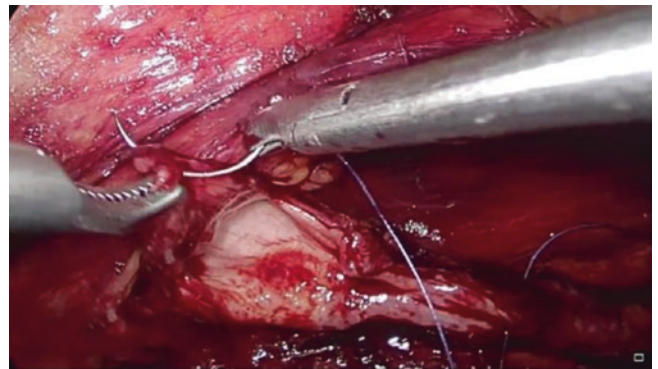


Fig. 5.32 Corresponding suture through the apex of pelvic flap

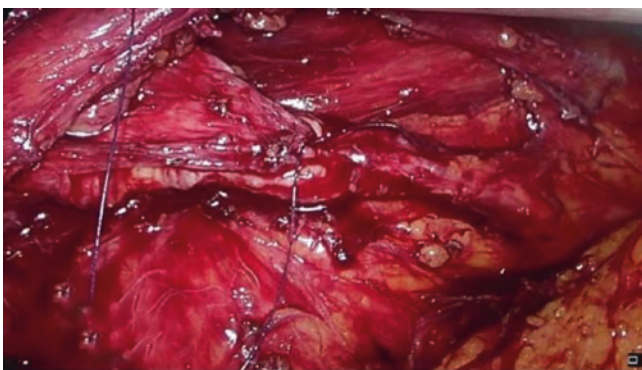


Fig. 5.33 Apical suture in place

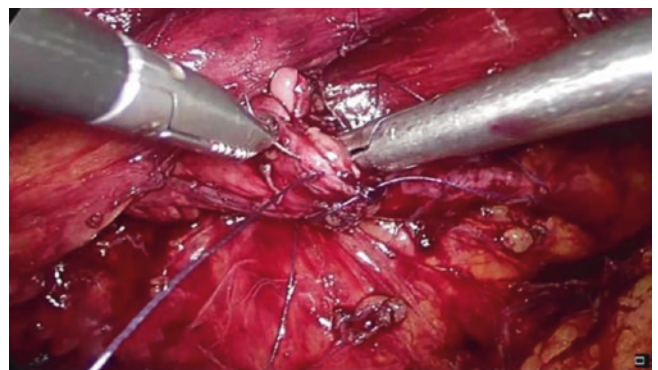


Fig. 5.34 Continuous suturing of lateral margin of flap in progress

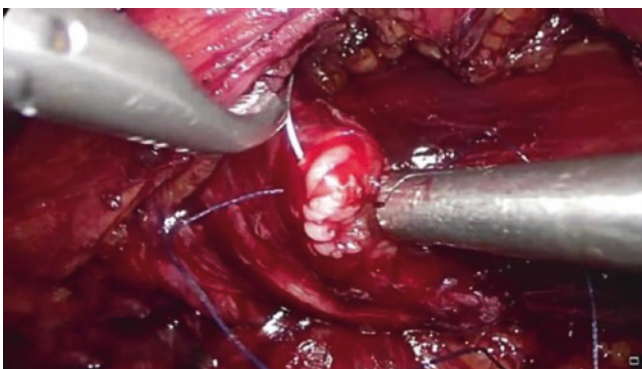


Fig. 5.35 Lateral margin suturing in progress

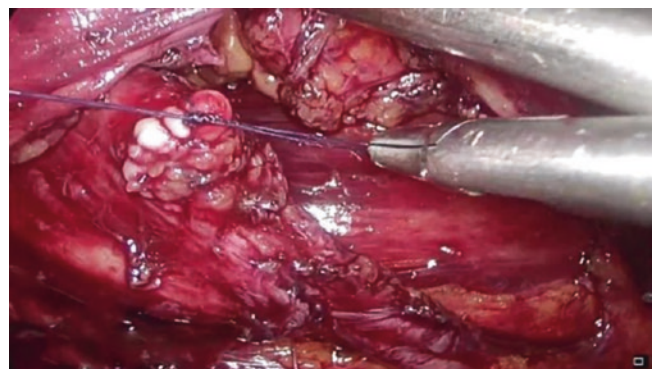


Fig. 5.36 Lateral margin suturing completed

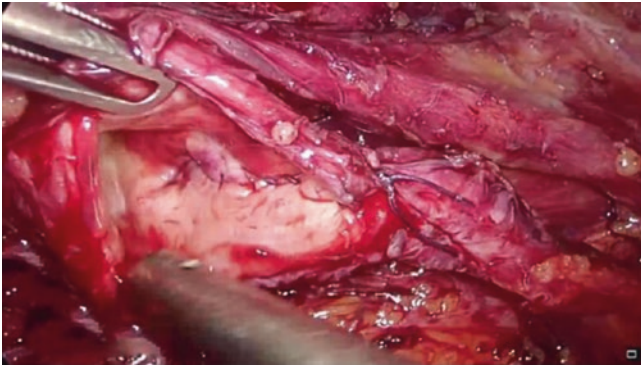


Fig. 5.37 Lateral wall suture seen through the inner aspect of pelvis

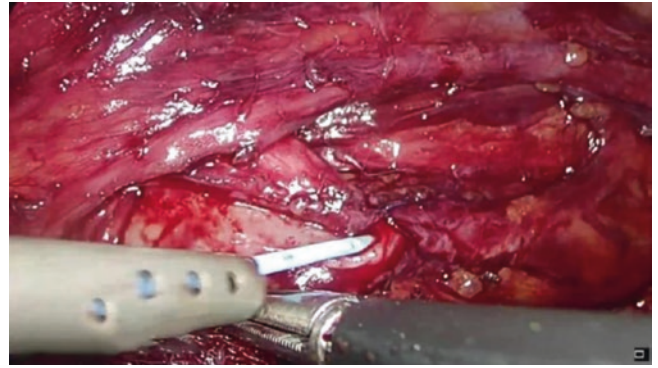


Fig. 5.38 Stent being inserted antegrade

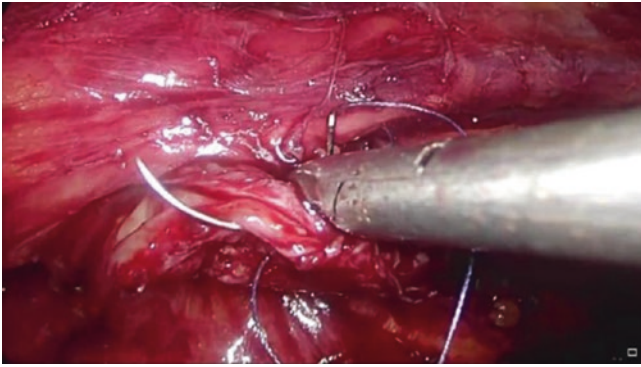


Fig. 5.39 Medial margin suturing in progress

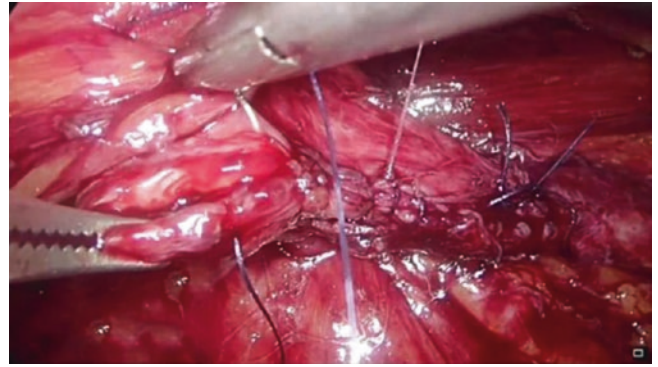


Fig. 5.40 Medial margin suturing in progress

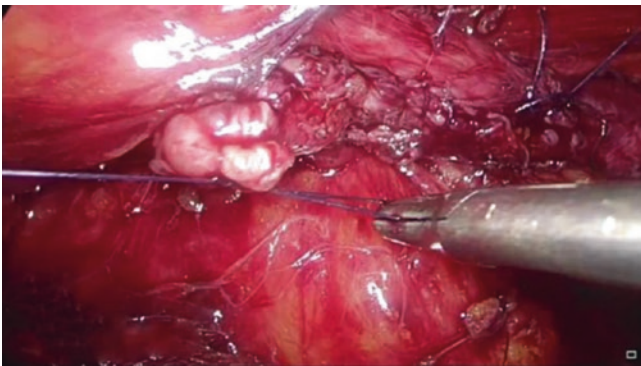


Fig. 5.41 Medial margin suturing completed

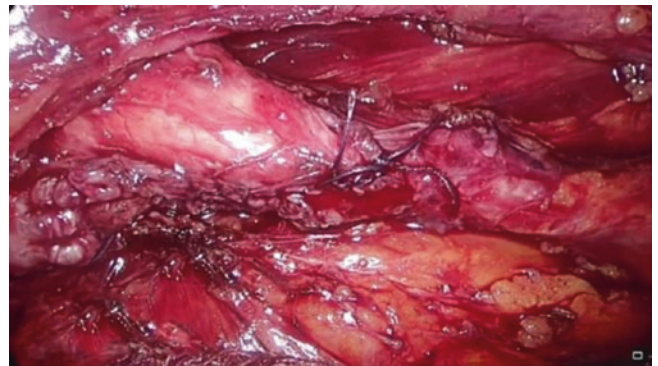
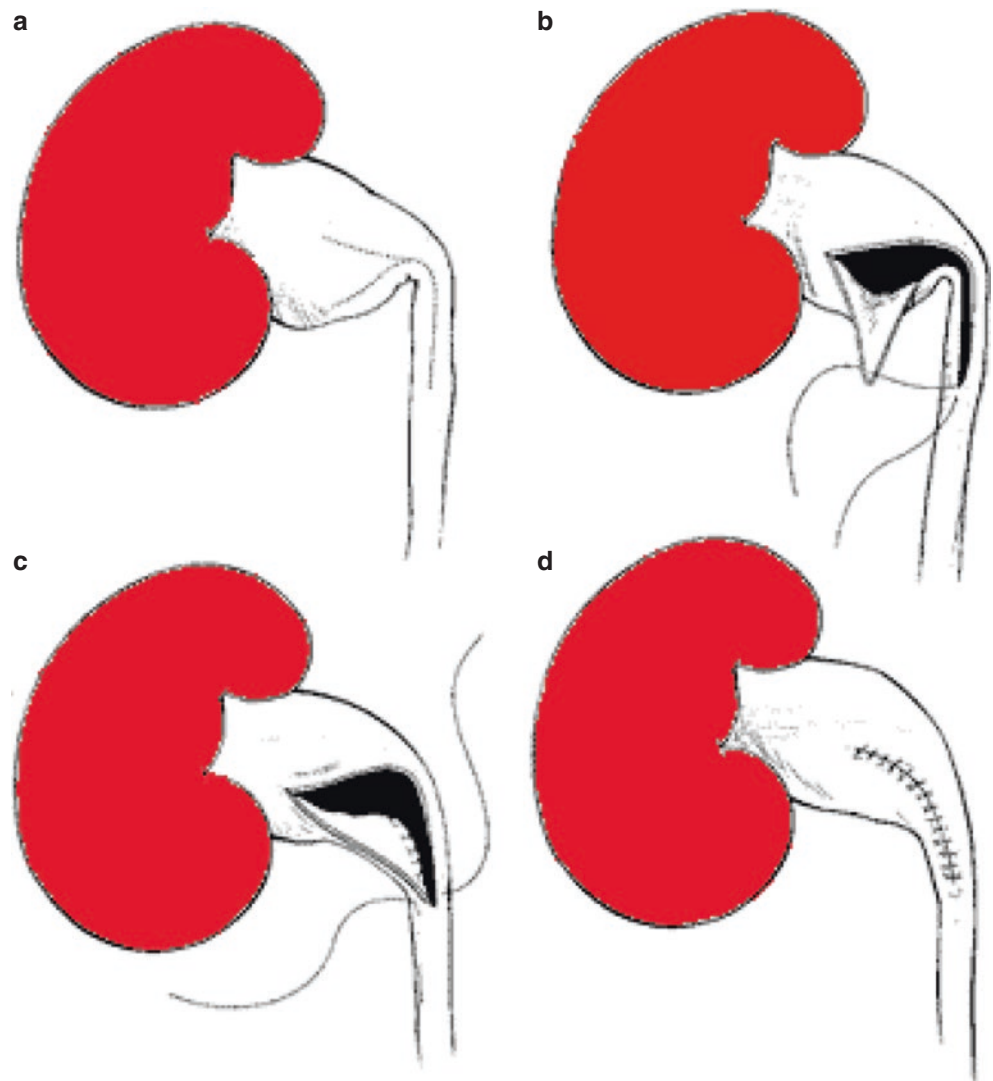


Fig. 5.42 Completed 'Y' – 'V' plasty

Fig. 5.43 Diagrammatic representation of Y – V plasty



5.7 Transmesocolic Pyeloplasty

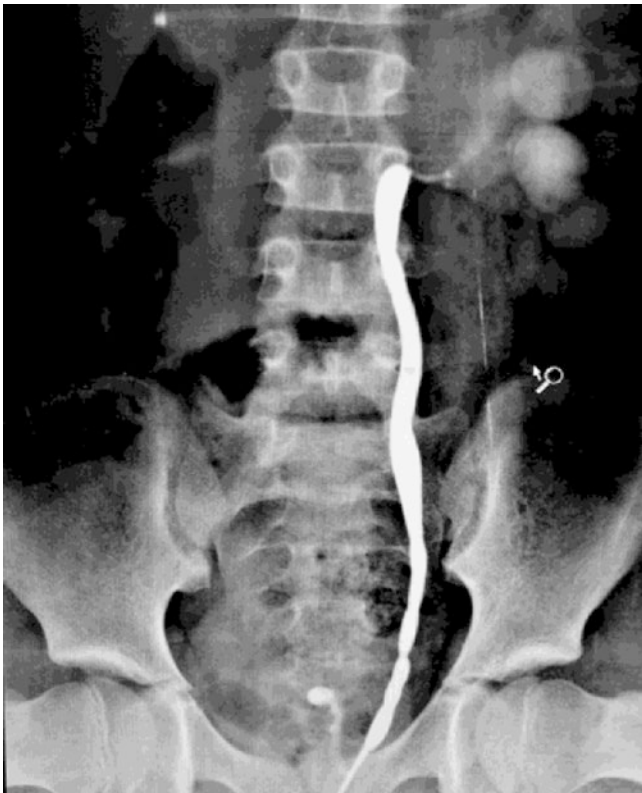

Fig. 5.44 RGP showing left UPJ narrowing

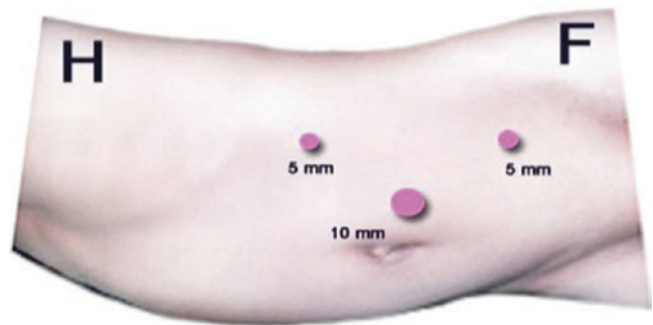


Fig. 5.45 Ports position

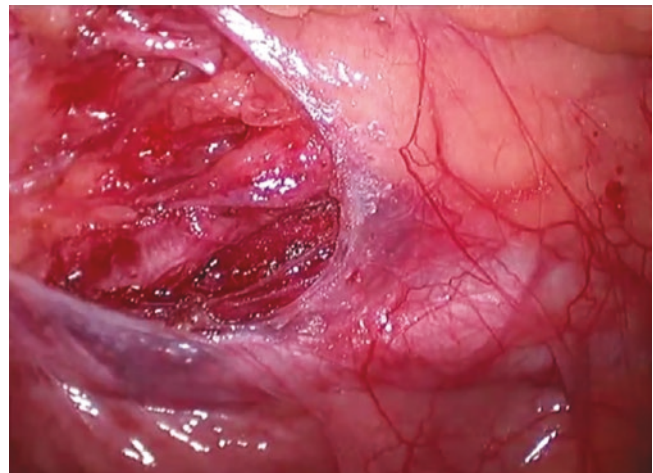


Fig. 5.47 Incision of the mesocolon over the bulge, preserving the mesocolic vessels

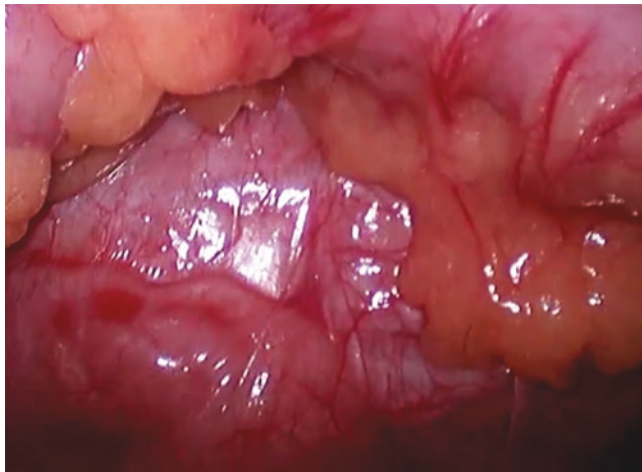


Fig. 5.46 Bulging pelvis seen through the mesocolon

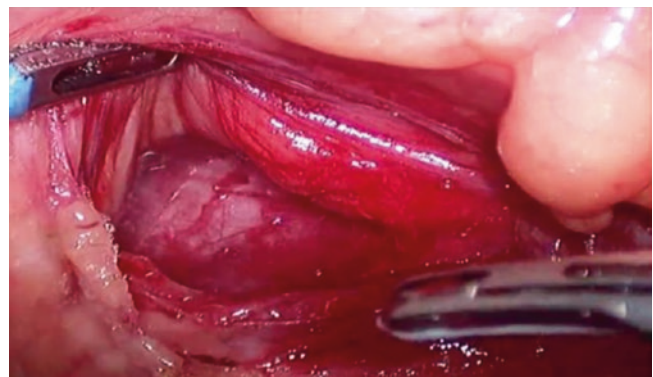


Fig. 5.48 Pelvis seen through the mesocolic window

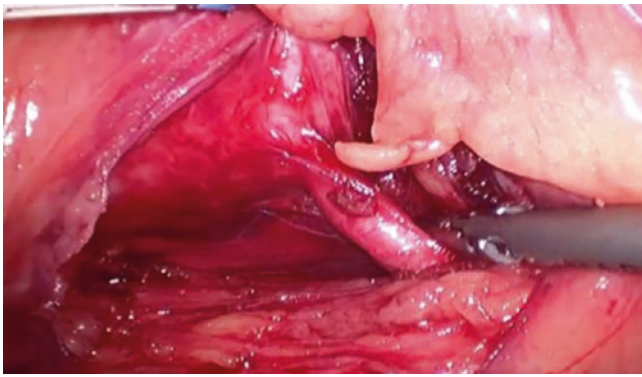


Fig. 5.49 Pelvis and upper ureter dissected through the mesocolic window and pelviureteric junction delineated

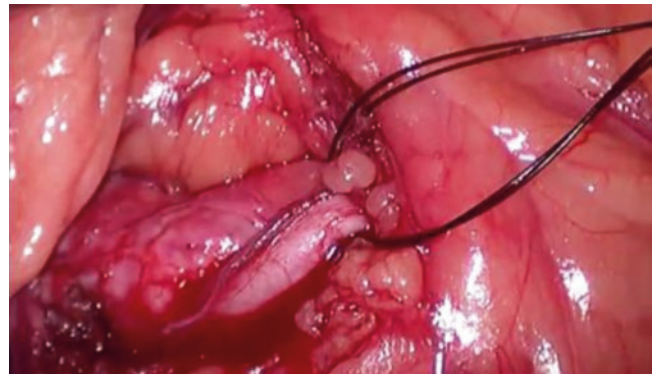


Fig. 5.50 Sling placed around the ureter for identification and retraction

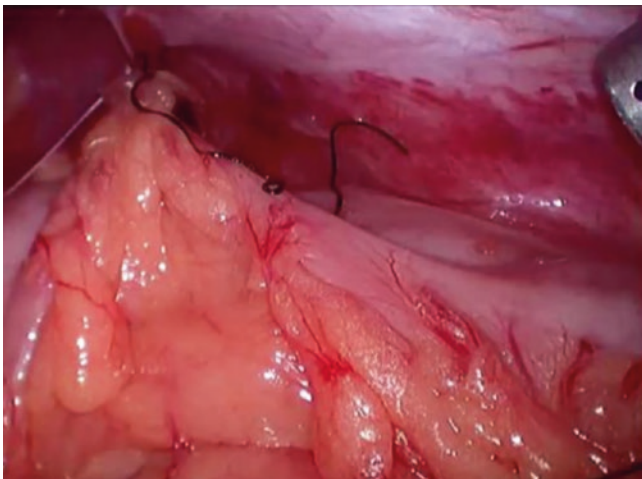


Fig. 5.51 Mesocolon tacked to the abdominal wall

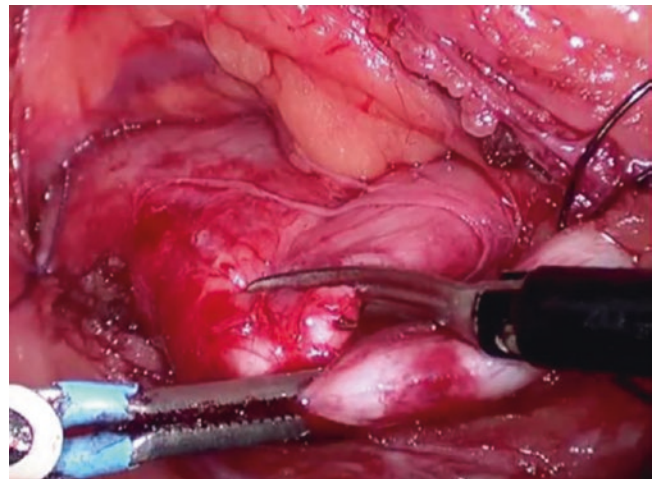


Fig. 5.52 Oblique pyelotomy in progress

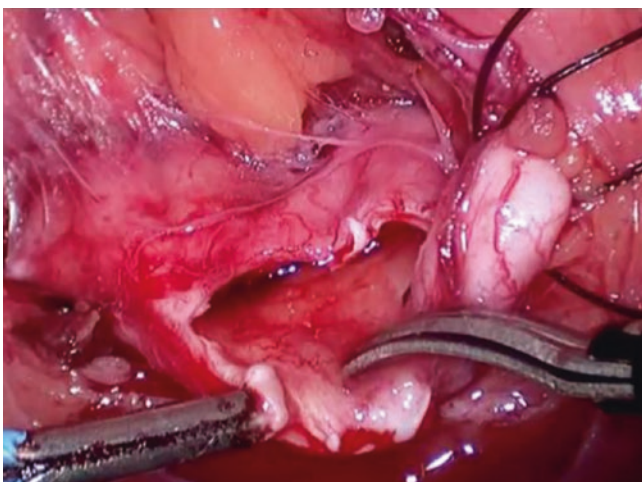


Fig. 5.53 Anterior layer of pelvis incised completely

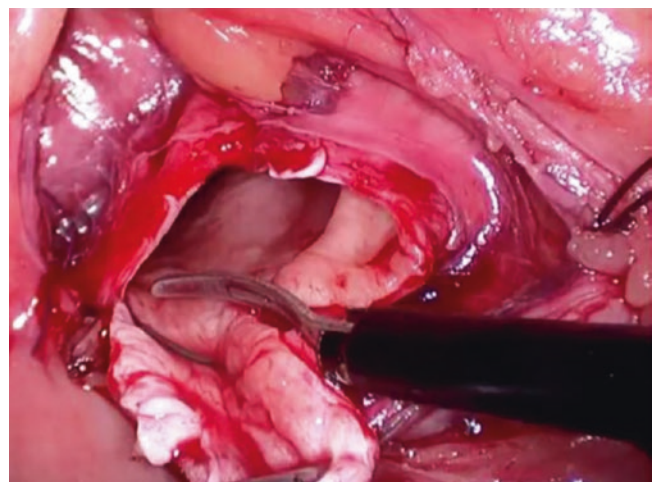


Fig. 5.54 Pyelotomy about to be completed. Note preplaced guide wire

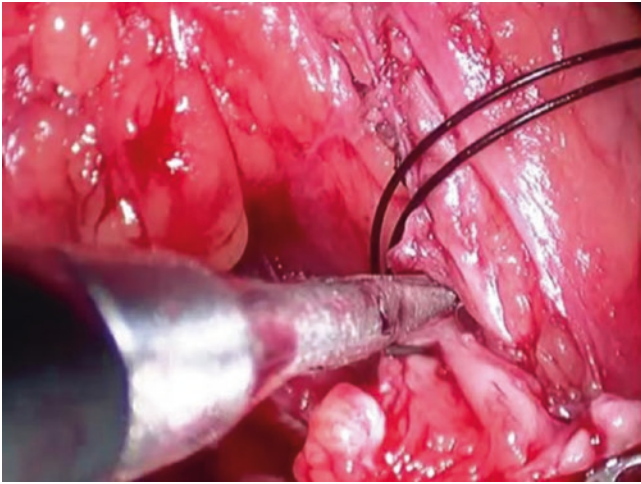


Fig. 5.55 Lateral spatulation of ureter in progress

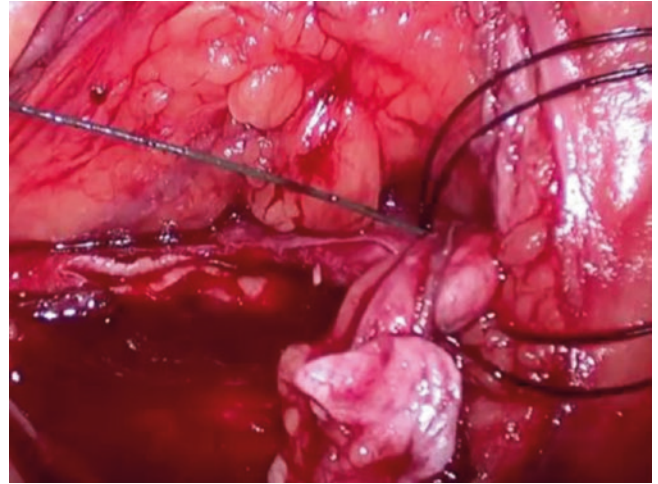


Fig. 5.56 Ureteric spatulation completed – beyond the narrowing

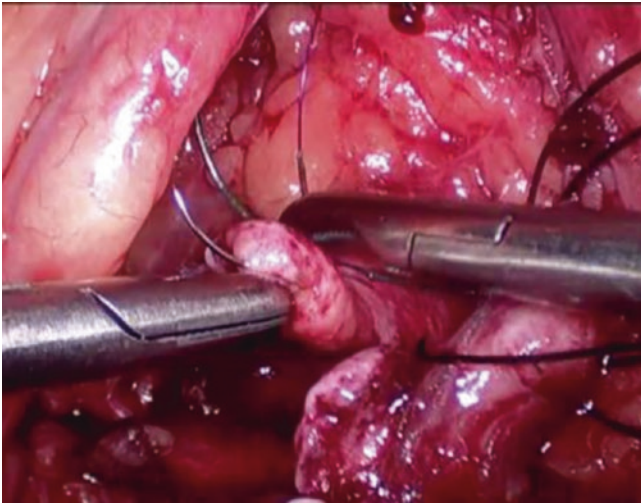


Fig. 5.57 Initial suture through the pelvis – outside-in using 4-0 Polydioxanone suture

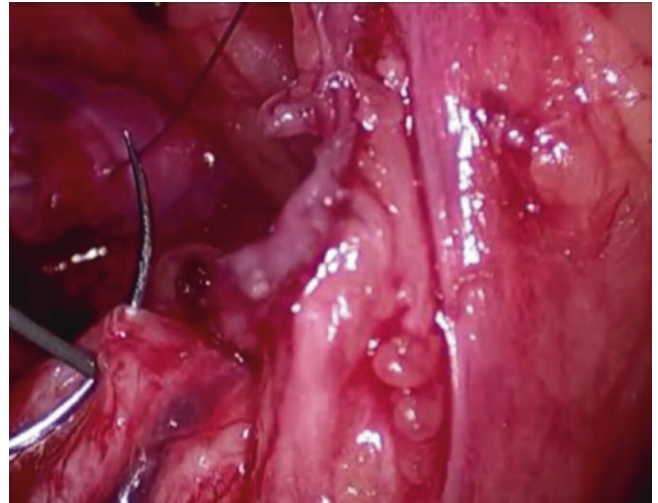


Fig. 5.58 Corresponding suture through the spatulated end of ureter

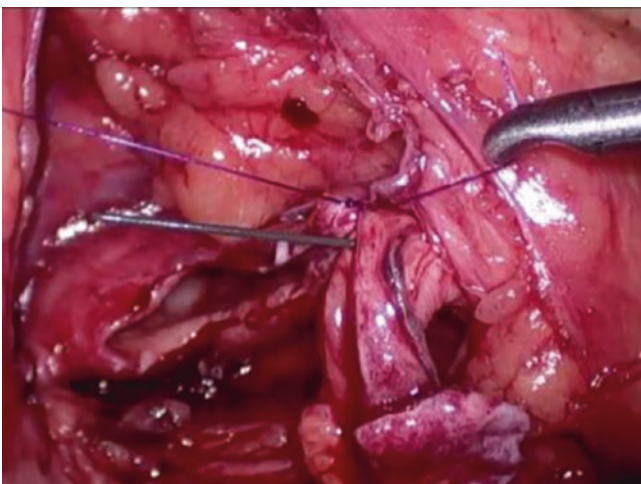


Fig. 5.59 Apical suture in place

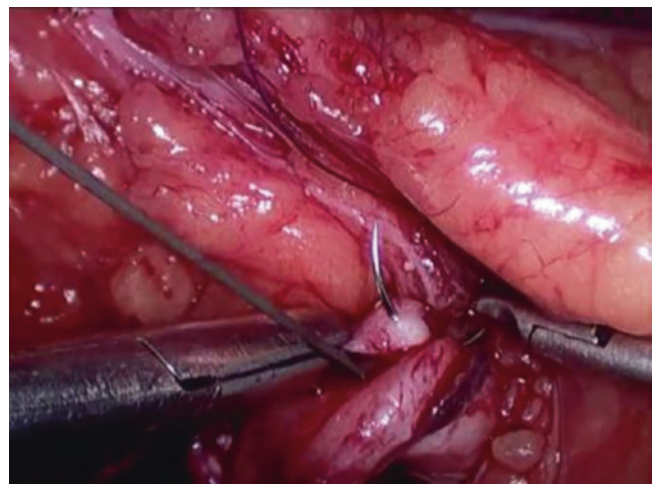


Fig. 5.60 Posterior layer suturing in progress

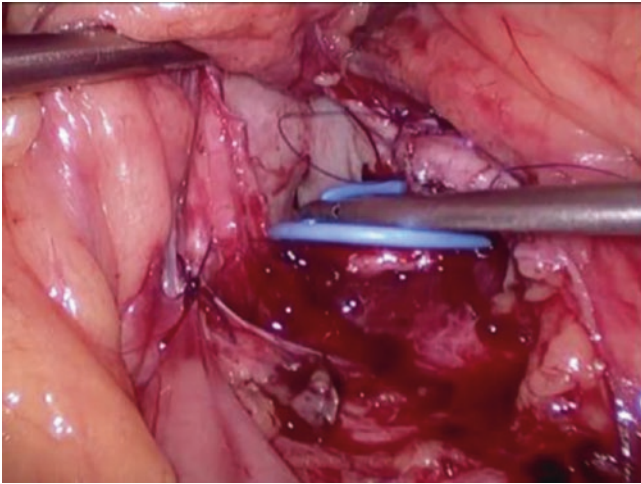


Fig. 5.61 Stent being inserted antegrade

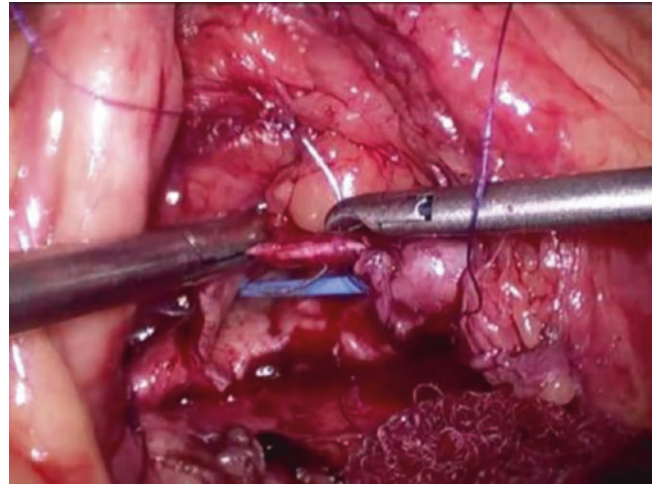


Fig. 5.62 Final suture of anterior layer in place

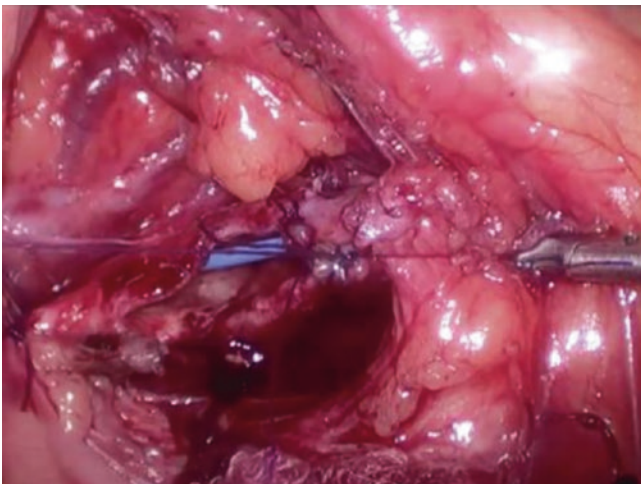


Fig. 5.63 Completed anterior and posterior uretero pelvic sutures

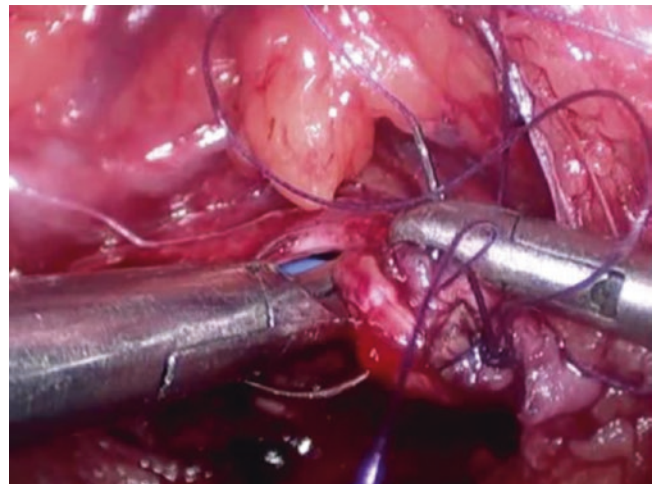


Fig. 5.64 Final suture through center of the proximal end of ureter to the pelvis

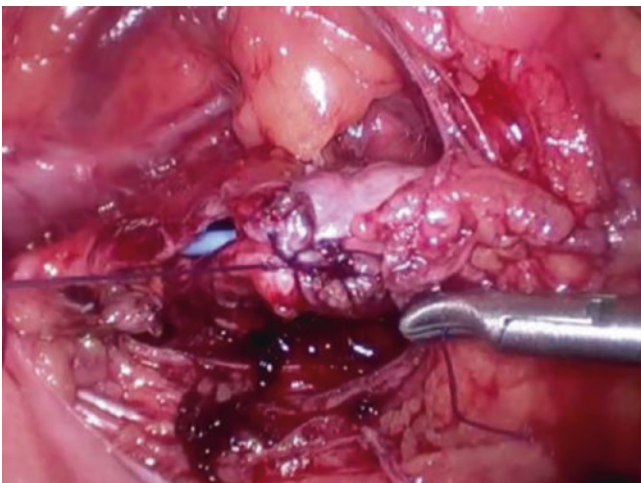


Fig. 5.65 Completed pyelo ureteric anastomosis

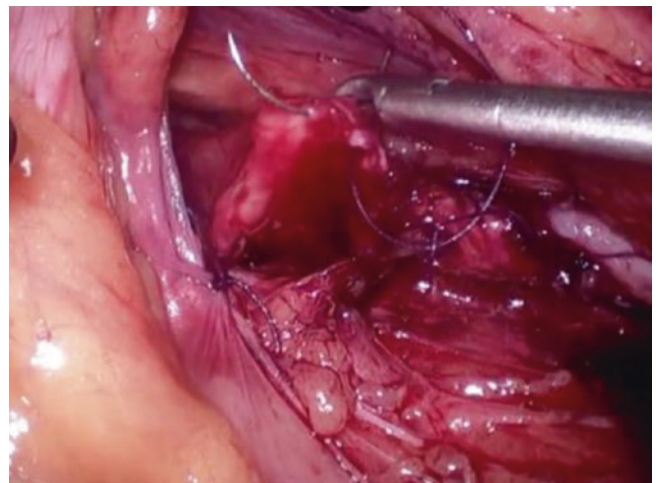


Fig. 5.66 Closure of remaining pyelotomy rent

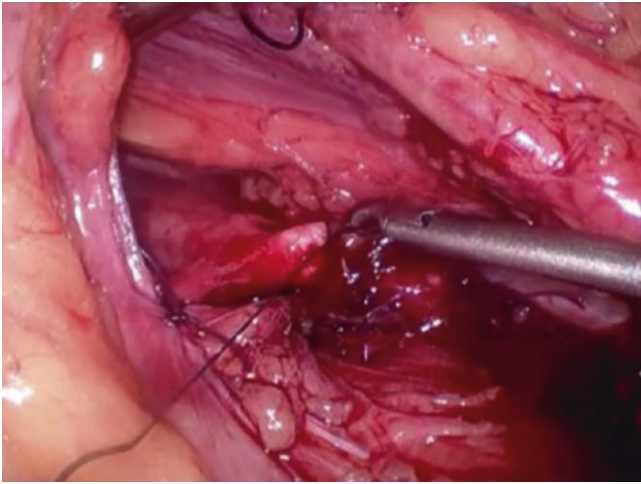


Fig. 5.67 Pyelotomy closure in progress

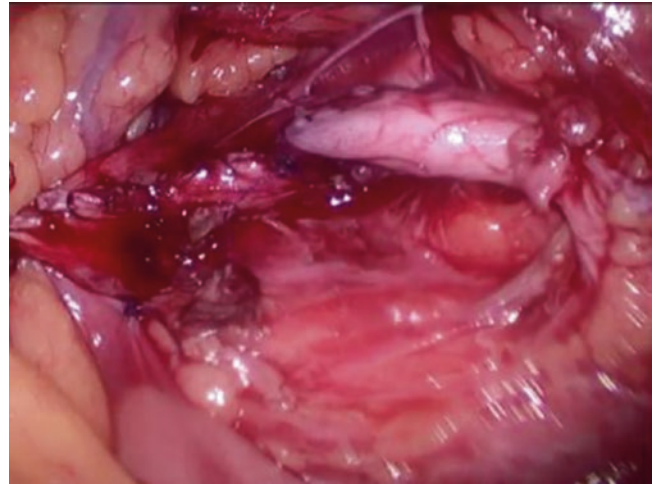


Fig. 5.68 Completed pyeloplasty

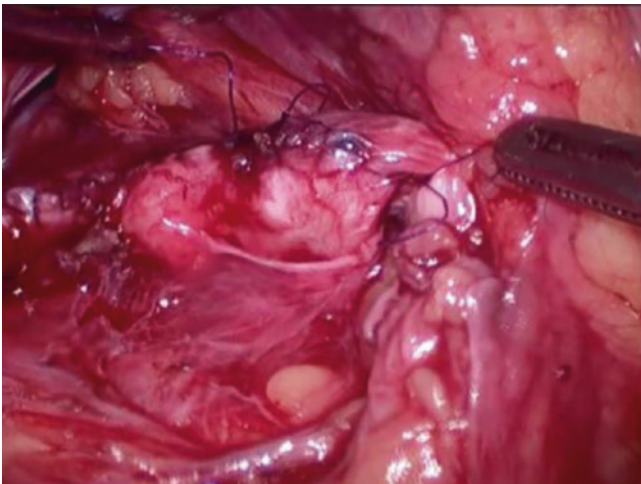


Fig. 5.69 Completed pyeloplasty

5.8 Horse Shoe Kidney with PUJ Obstruction

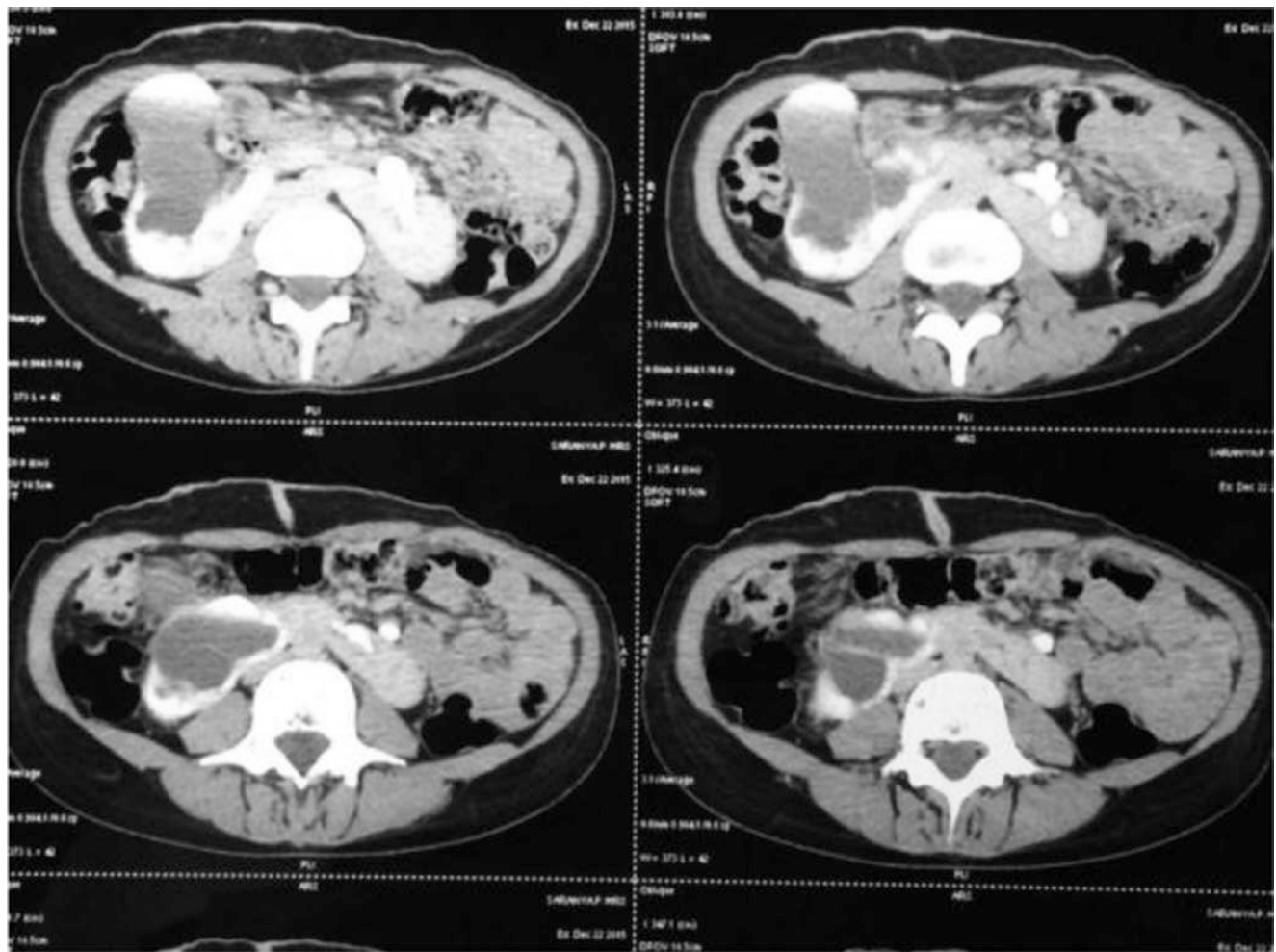


Fig. 5.70 CT showing malrotated RT moiety with PUJ obstruction of a horseshoe kidney

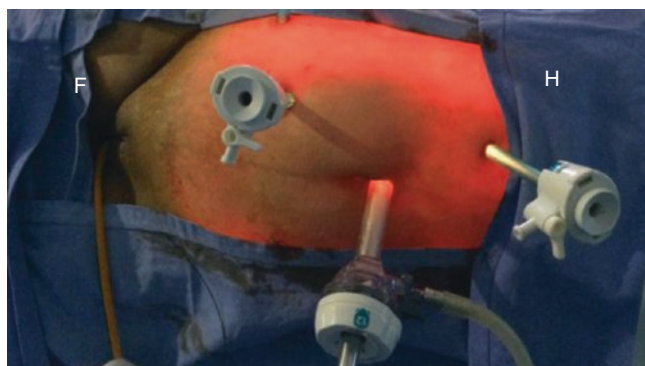


Fig. 5.71 Port placement. Camera port is at umbilicus as UPJ is at a lower and medial location

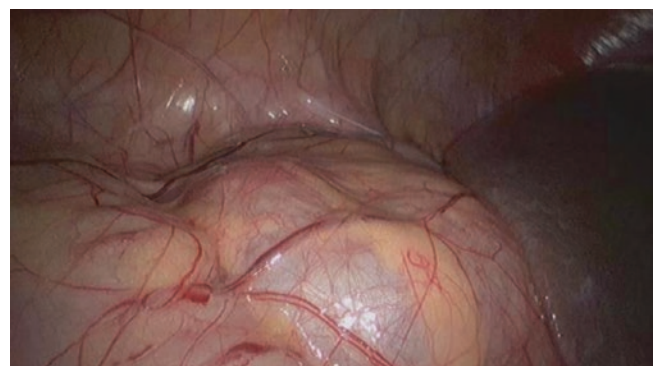

Fig. 5.72 Initial view showing the bulge caused by dilated pelvis over the lumbar region (Lower than usual)

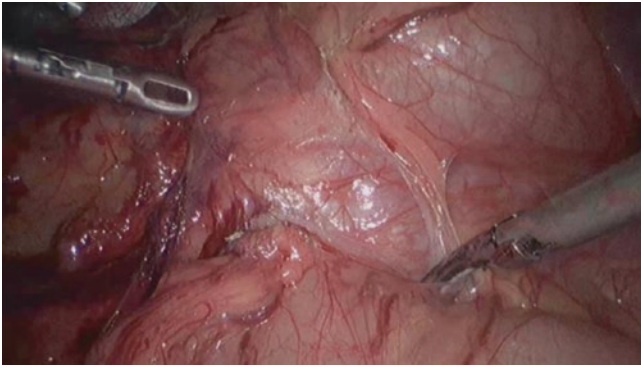


Fig. 5.73 Right colon being reflected medially along the line of Toldt to enter retroperitoneum

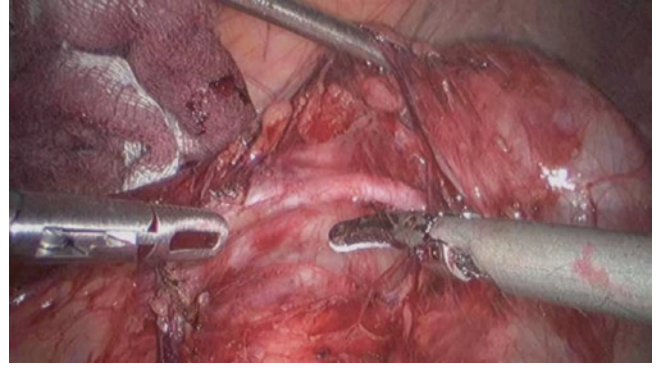


Fig. 5.74 Dilated pelvis and narrow ureter visualised

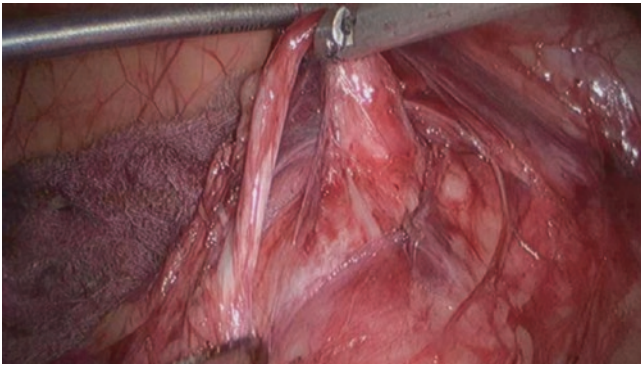


Fig. 5.75 PUJ dissected

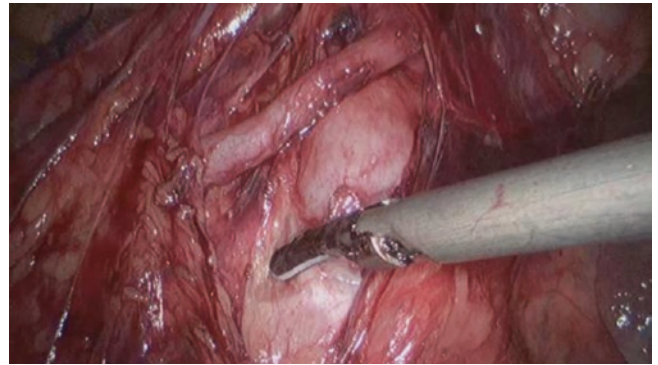


Fig. 5.76 Dilated pelvis and the isthmus part seen

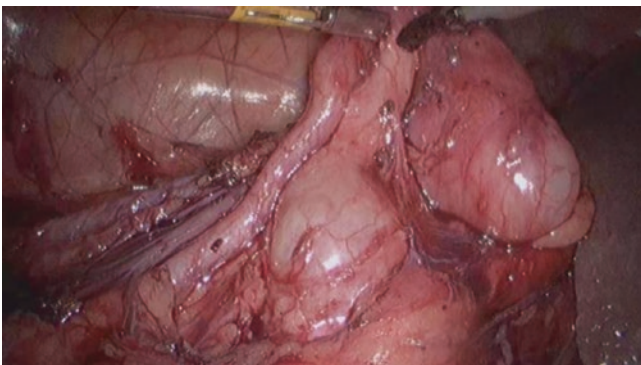


Fig. 5.77 Pelvis and grossly dilated calyces seen

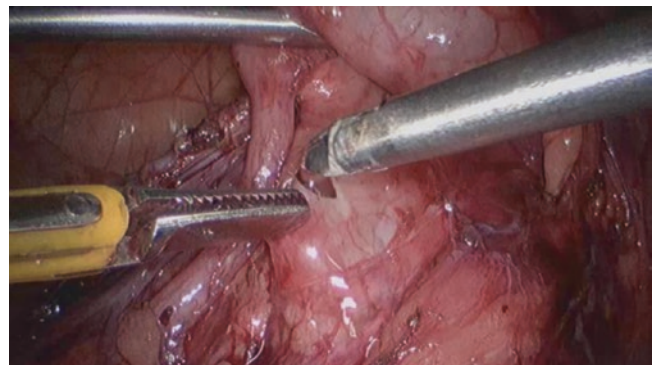


Fig. 5.78 Pyelotomy in the dependant area

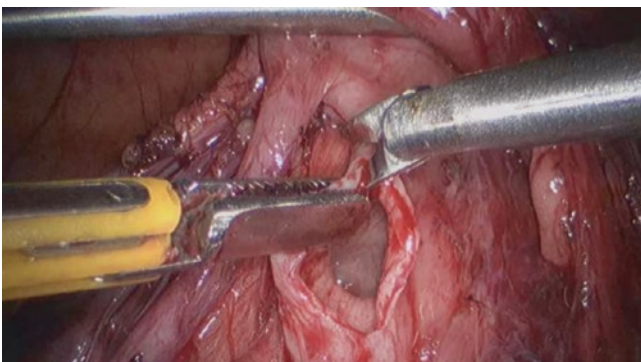


Fig. 5.79 Pyelotomy extended

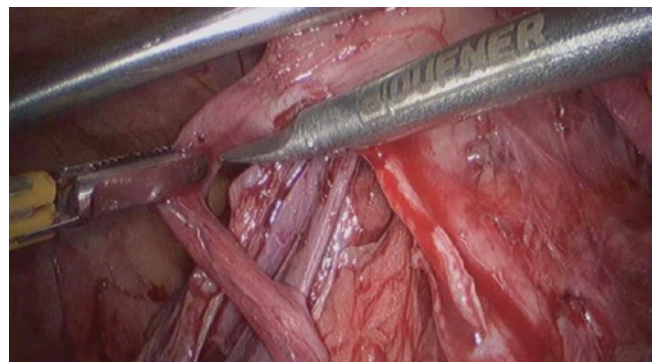


Fig. 5.80 Pyelotomy extended on to ureter in preparation for non dismembered pyeloplasty

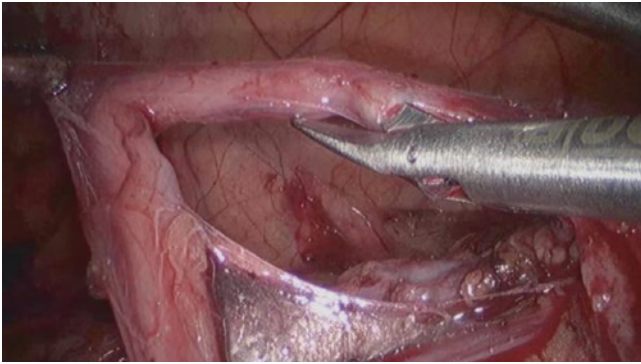


Fig. 5.81 Ureterotomy extended till normal caliber ureter

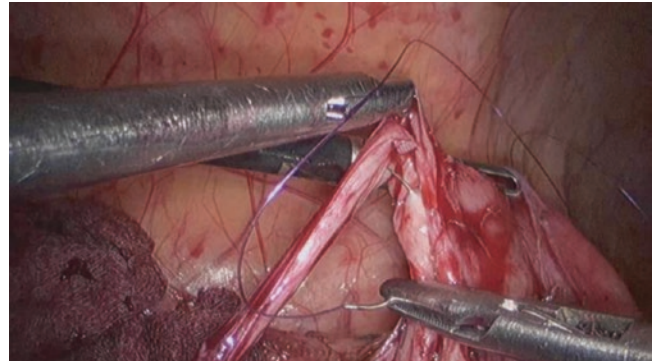


Fig. 5.82 Posterior layer suturing with 4-0 PDS suture (Non dissimembered)

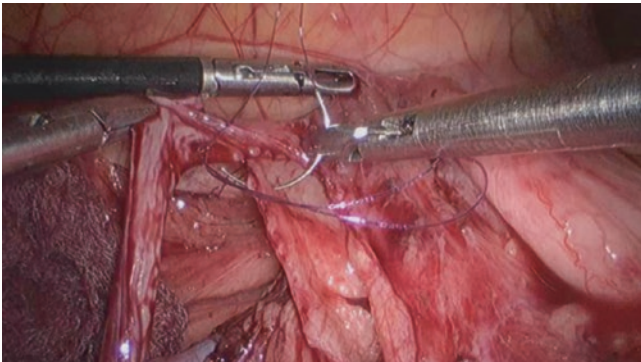


Fig. 5.83 Posterior layer suturing in progress

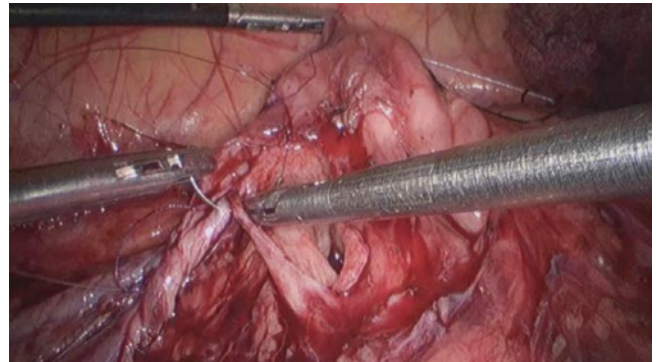


Fig. 5.84 Posterior layer suturing in progress

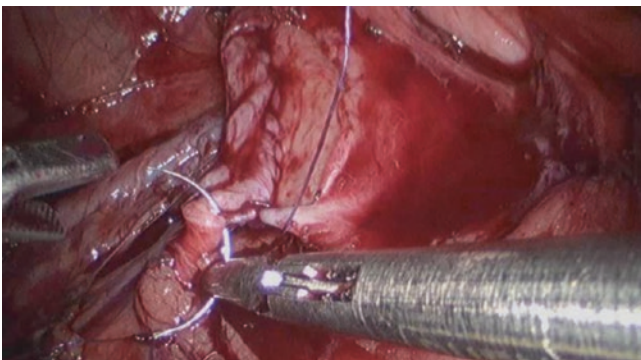


Fig. 5.85 Final sutures of posterior layer

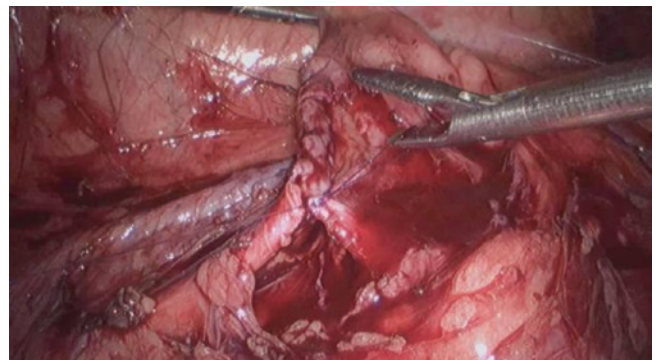


Fig. 5.86 Posterior layer suture completed

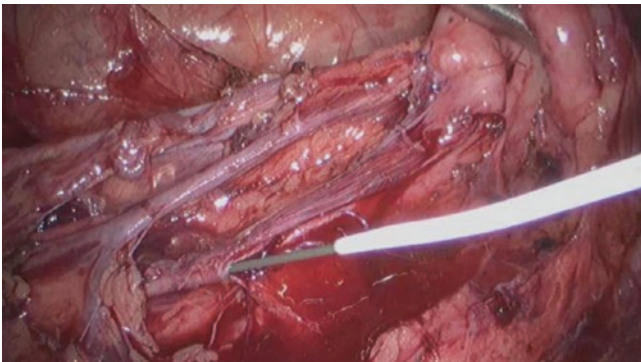


Fig. 5.87 Stent placed antegrade

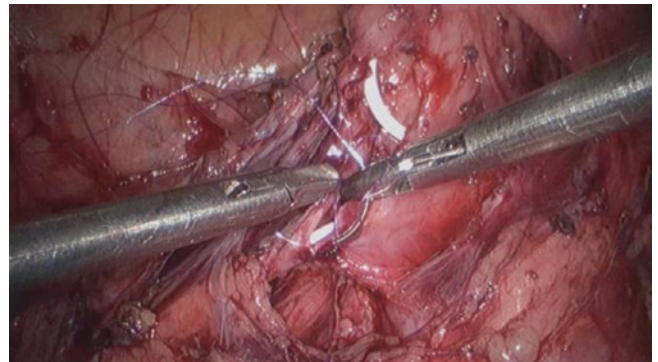


Fig. 5.88 Anterior layer suturing with same suture after knotting

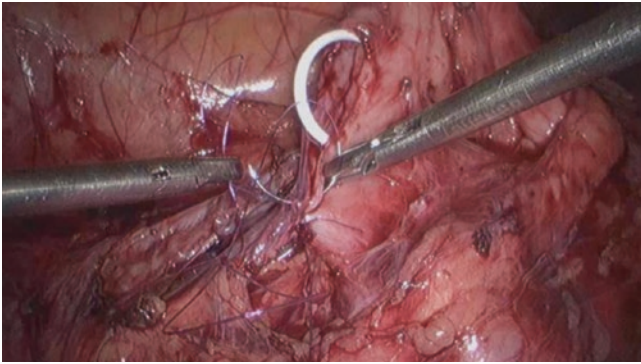


Fig. 5.89 Anterior layer suturing in progress

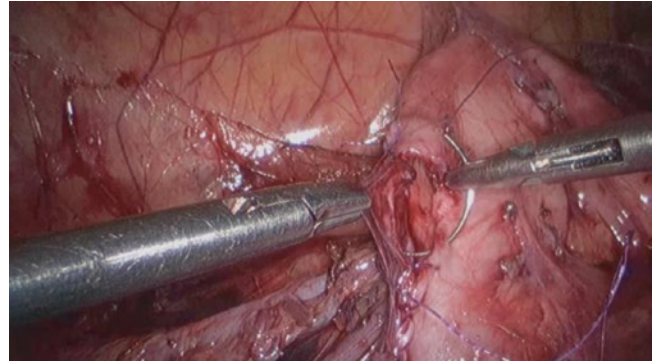


Fig. 5.90 Anterior layer suturing in progress

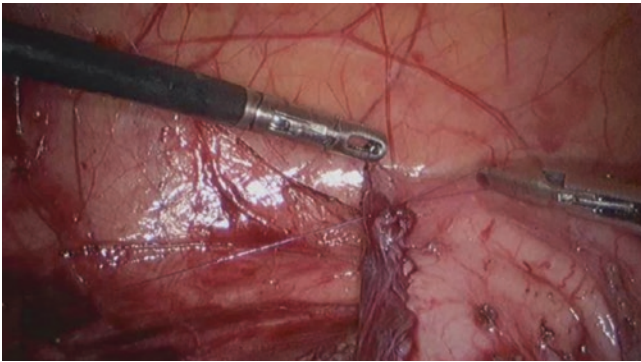


Fig. 5.91 Anterior layer suturing layer completed

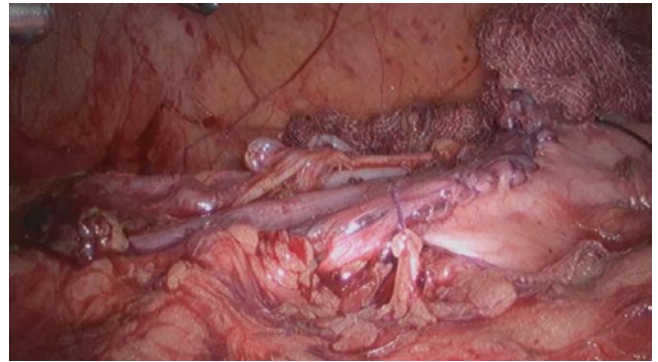


Fig. 5.92 Final view showing dependant UPJ

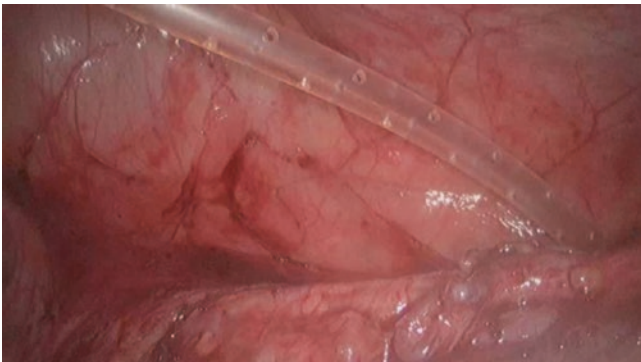


Fig. 5.93 Drain placed

5.9 Pyeloplasty in Ectopic Kidney

Fig. 5.94 CT urogram of right pelvic kidney with UPJ obstruction

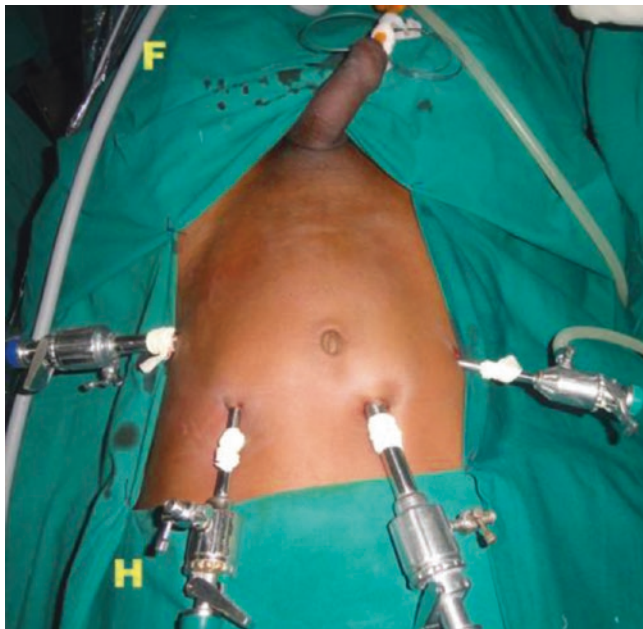
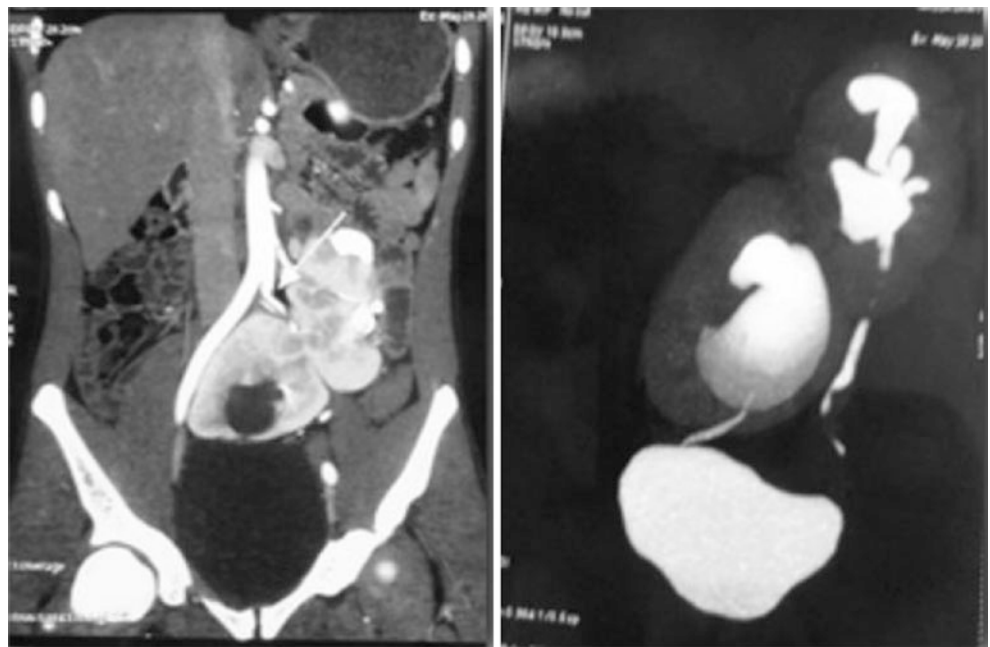

Fig. 5.95 Port positions

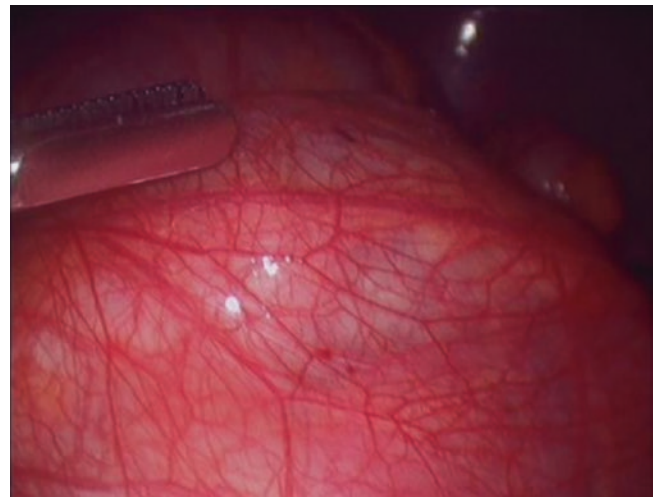


Fig. 5.96 Initial view of pelvic kidney with the bulging pelvis as seen from head end (At the level of sacral promontory)

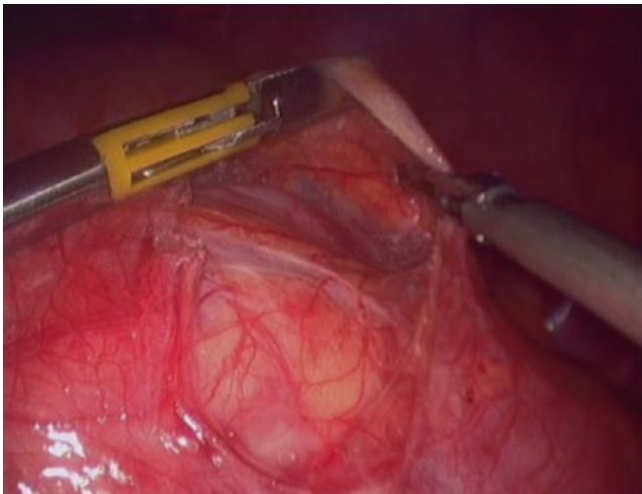


Fig. 5.97 Peritoneum over the pelvis incised

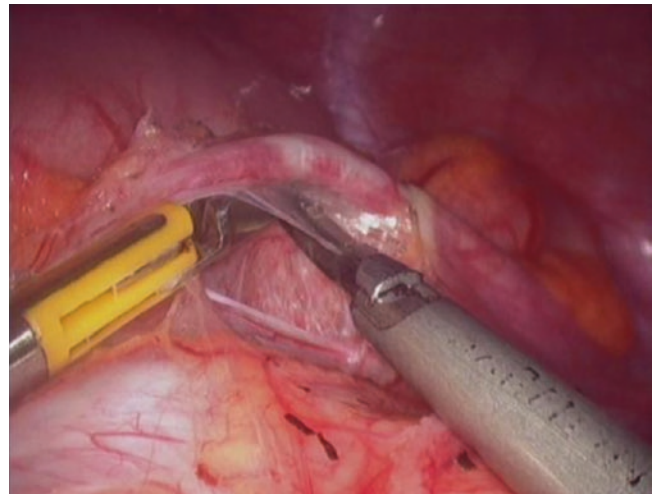


Fig. 5.98 Ureter with the ureteric catheter in situ, being dissected

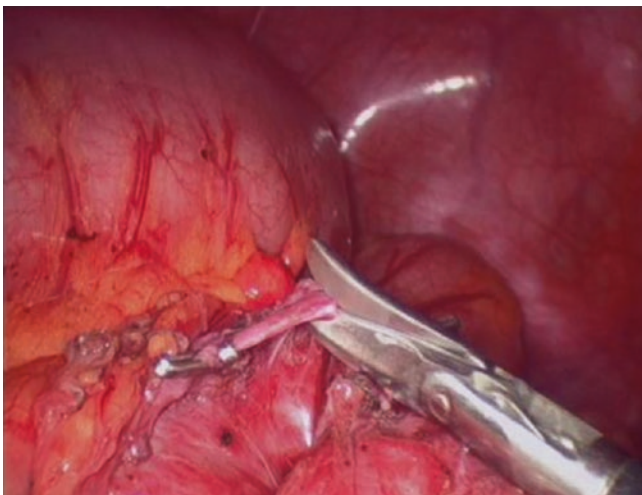


Fig. 5.99 Crossing vein divided

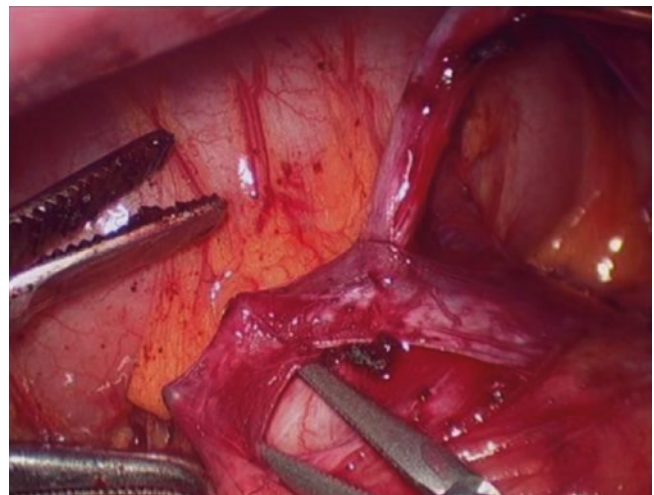


Fig. 5.100 Crossing vessel around the pelvi ureteric junction dissected

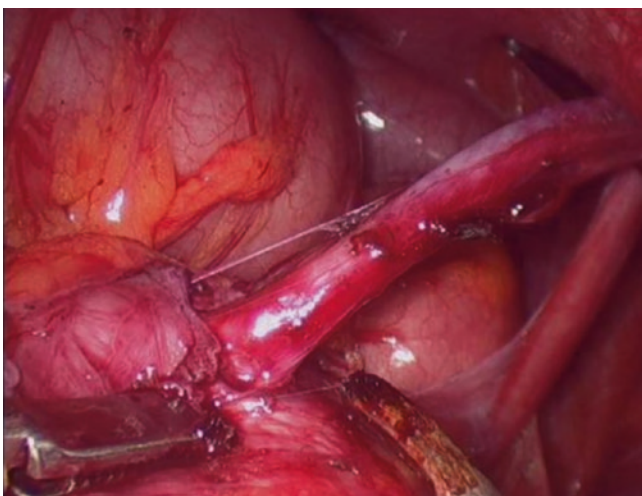


Fig. 5.101 Ureter traced proximally till pelvis

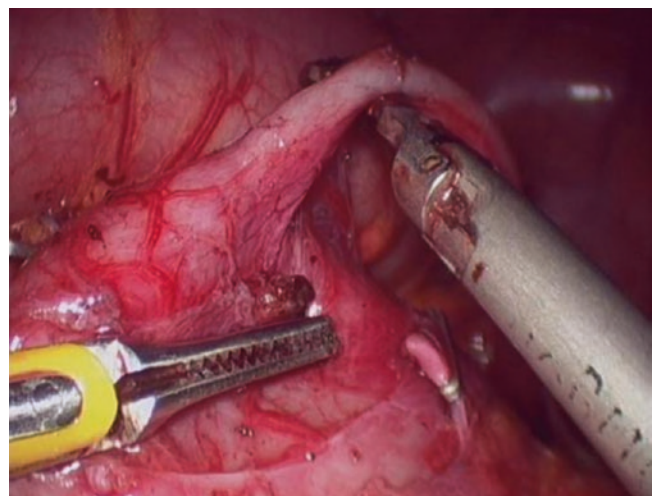


Fig. 5.102 Pelvi ureteric junction delineated all around

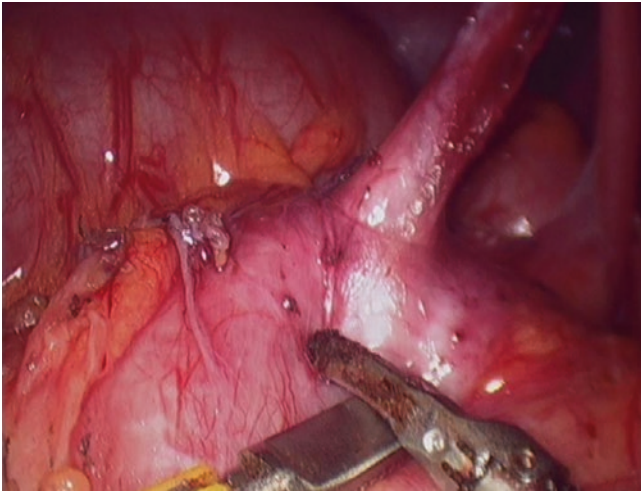


Fig. 5.103 Pelvi ureteric junction dissected

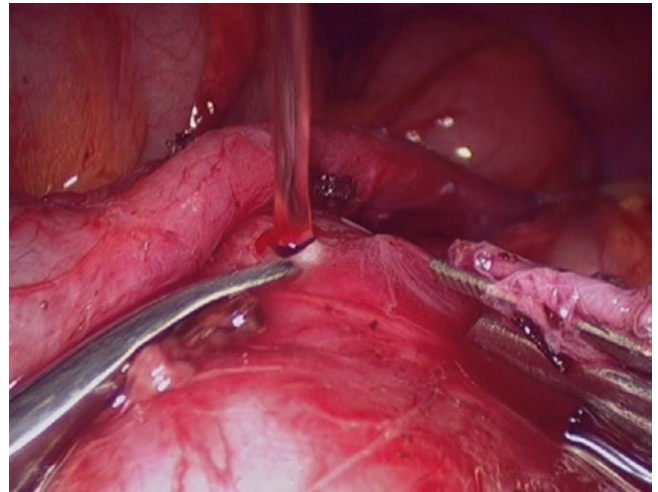


Fig. 5.104 Pylotomy started

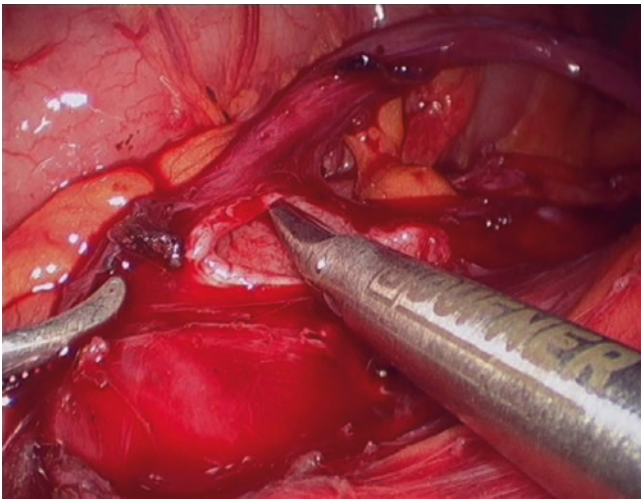


Fig. 5.105 Pylotomy completed and ureteric spatulation started

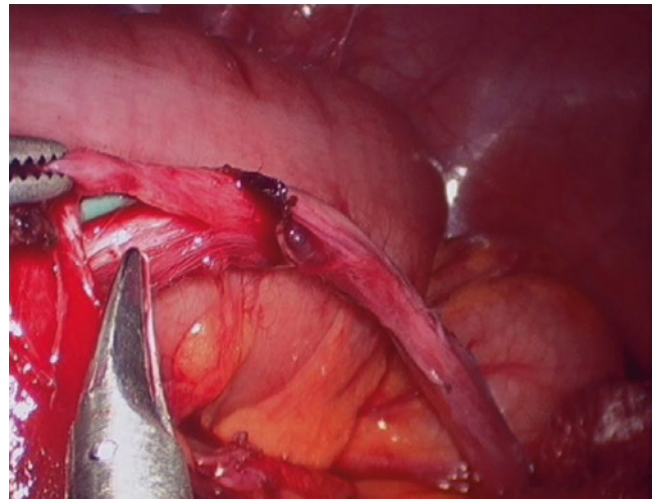


Fig. 5.106 Ureterotomy completed (UPJ not dismembered yet, for better orientation)

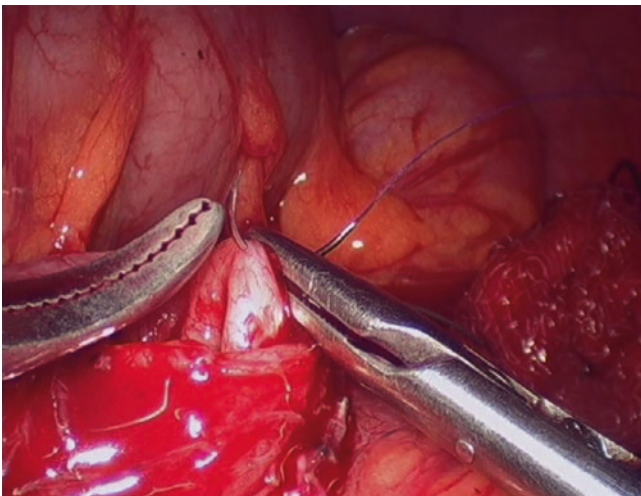


Fig. 5.107 Apical suture in the pelvis

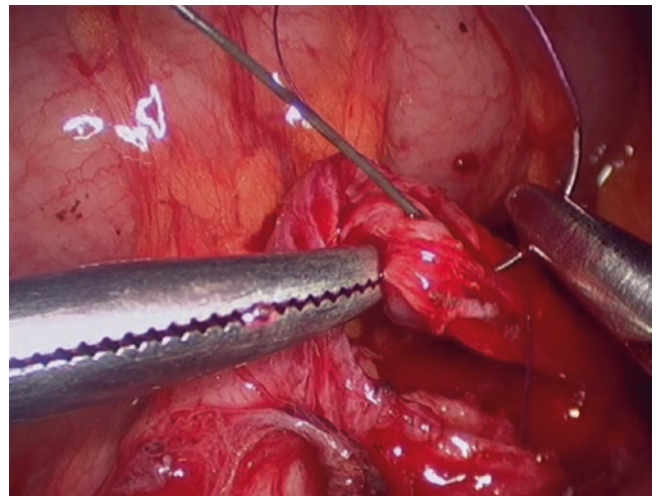


Fig. 5.108 Corresponding suture in the spatulated ureter

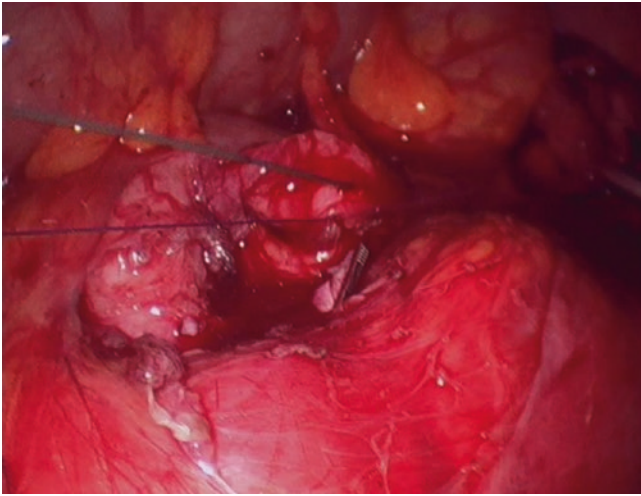


Fig. 5.109 Apical suture in place

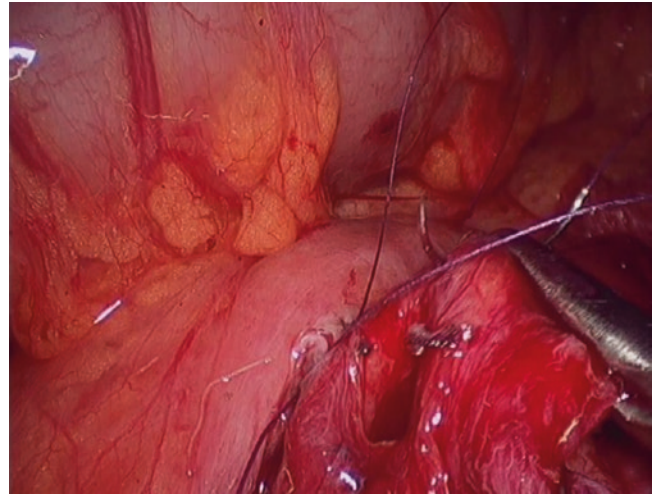


Fig. 5.110 Medial wall suturing started

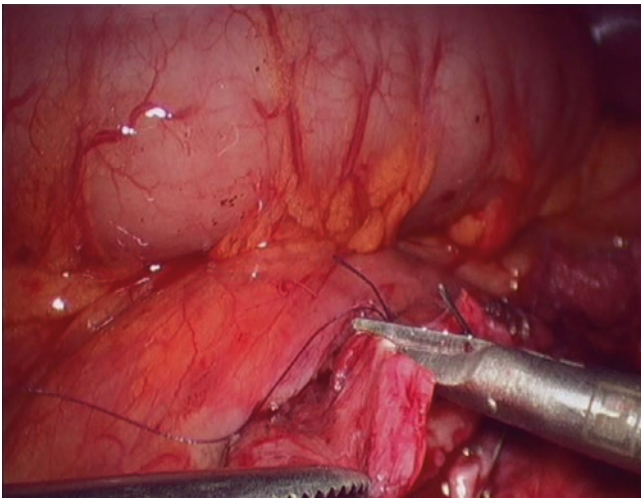


Fig. 5.111 Pelviureteric junction being divided

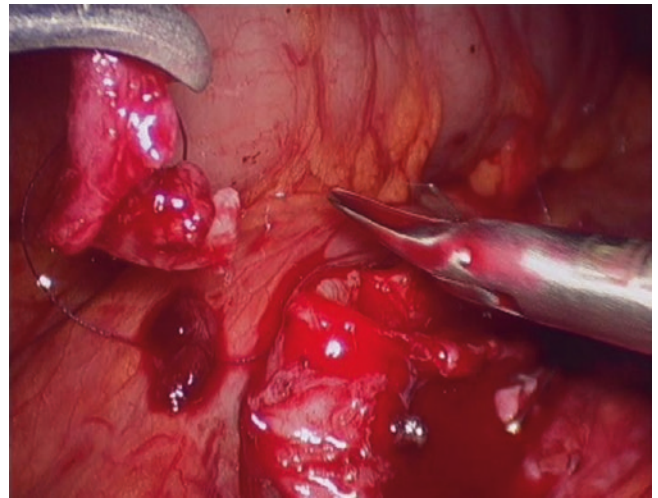


Fig. 5.112 Pelvic flap excised

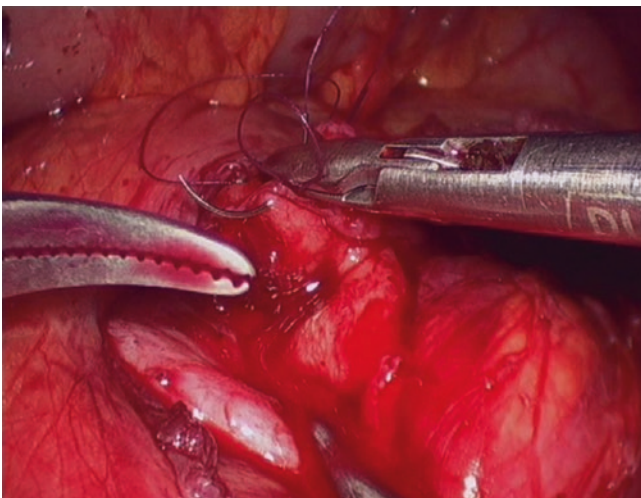


Fig. 5.113 Medial wall suturing in progress

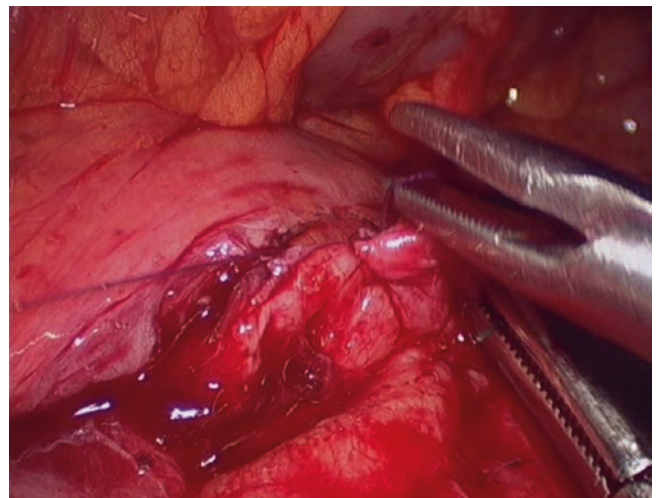


Fig. 5.114 Medial wall suturing in progress

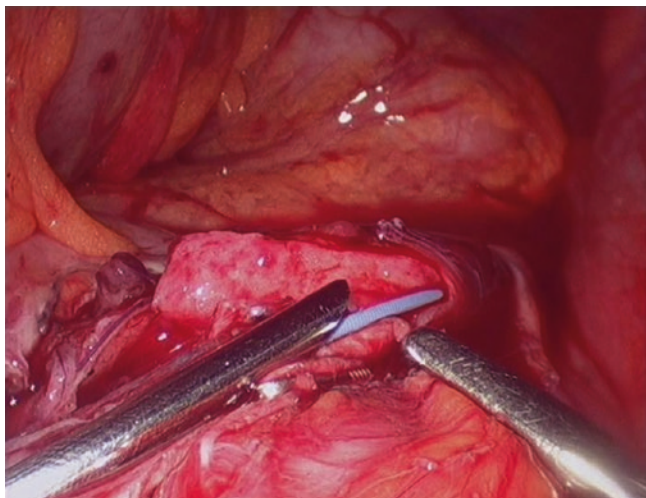


Fig. 5.115 Stent being inserted antegrade

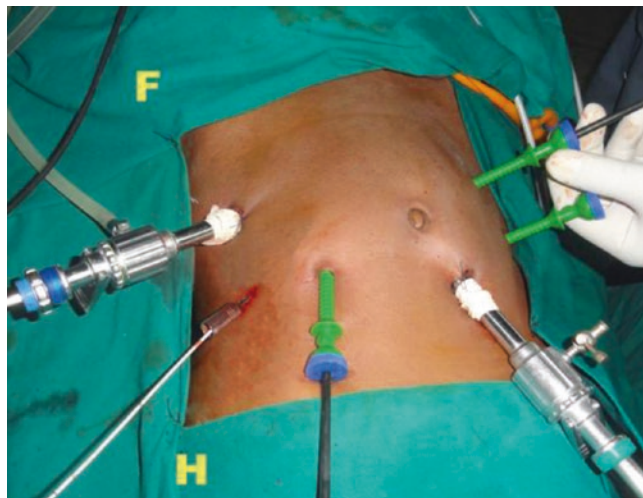


Fig. 5.116 Antegrade stenting

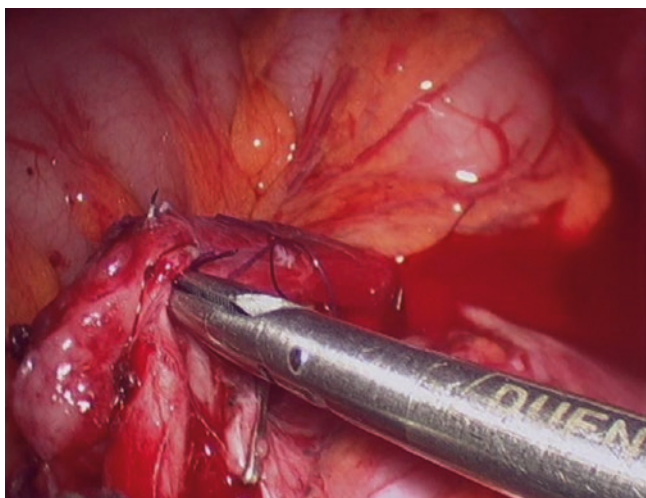


Fig. 5.117 Lateral wall suturing in progress

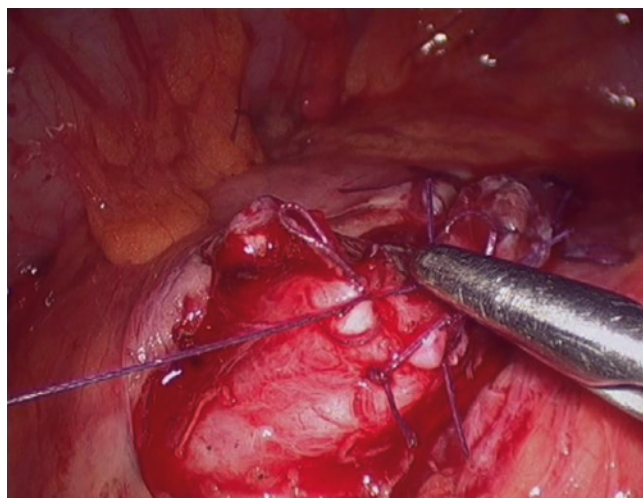


Fig. 5.118 Lateral wall suturing completed

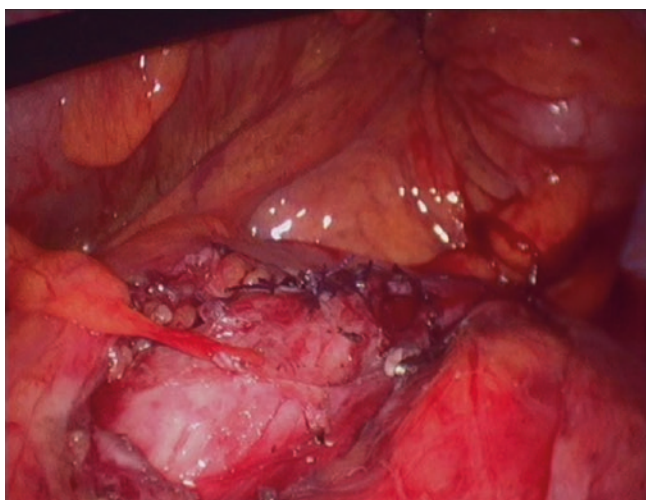


Fig. 5.119 Final view of completed pyeloplasty

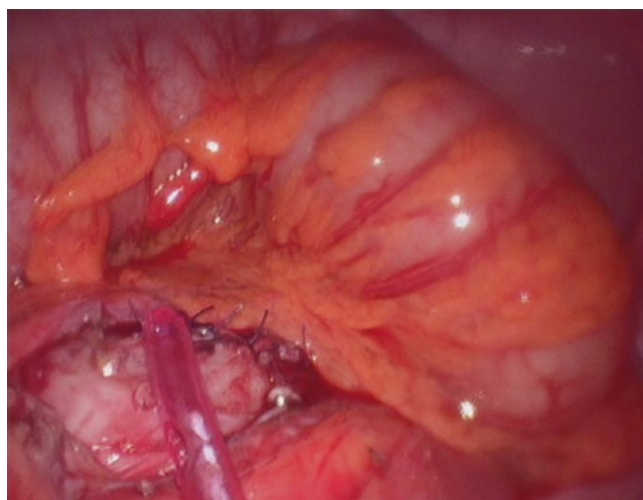


FIG. 5.120 Drain placed

5.10 Redo Lap. Pyeloplasty

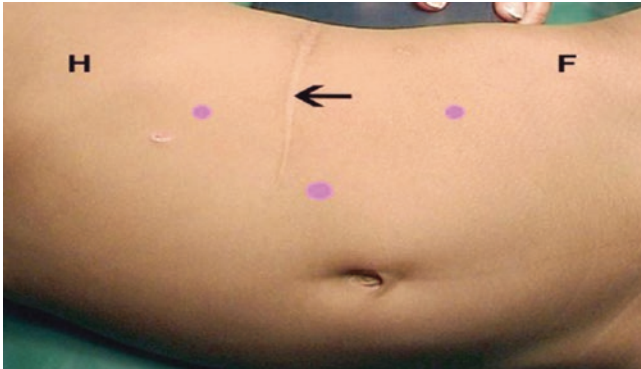


Fig. 5.121 Port position. (Scar of previous open pyeloplasty seen)

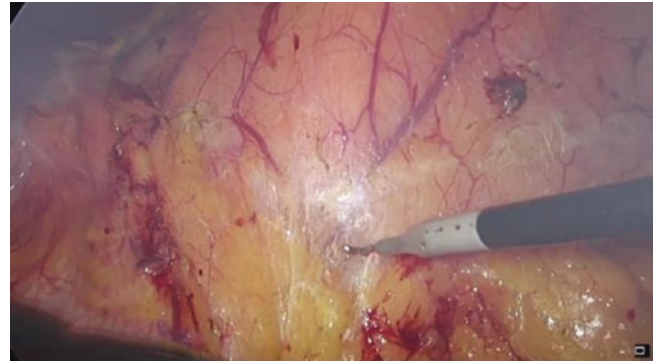


Fig. 5.122 Left colon being reflected medially and Gerota's fascia seen

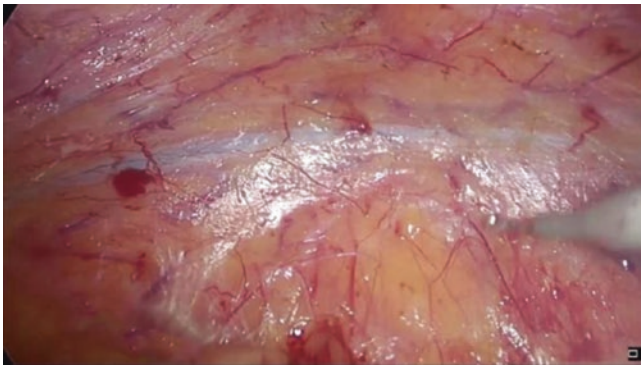


Fig. 5.123 Retroperitoneum exposed and gonadal vein is seen

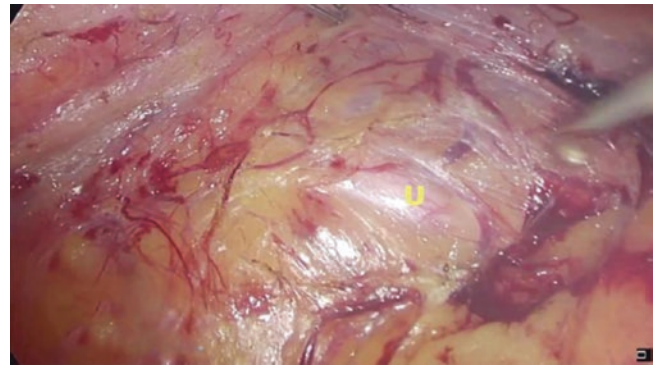


Fig. 5.124 Ureter identified with difficulty due to surrounding fibrosis and adhesions

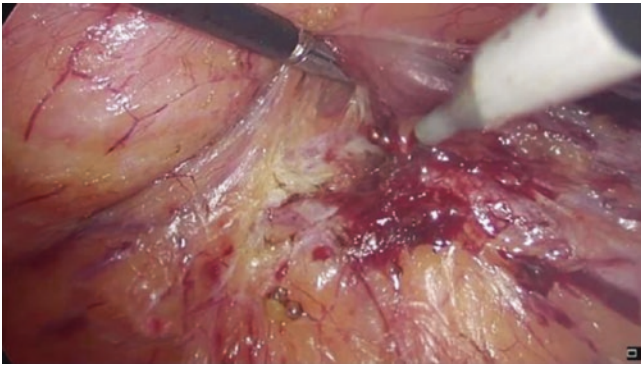


Fig. 5.125 Ureter dissected from tough pannus and fibrosis using hook diathermy (or ultrasonic shears)

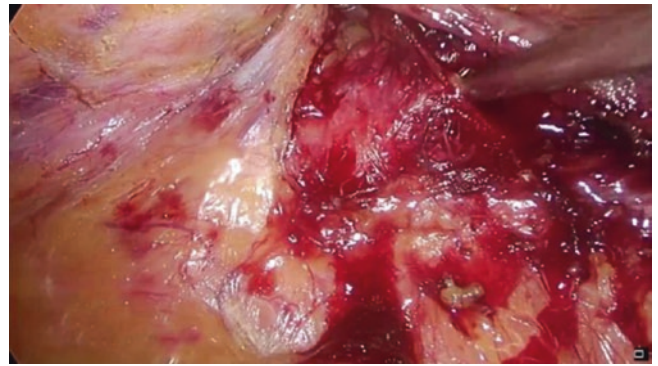


Fig. 5.126 Ureter being dissected proximally negotiating significant adhesions

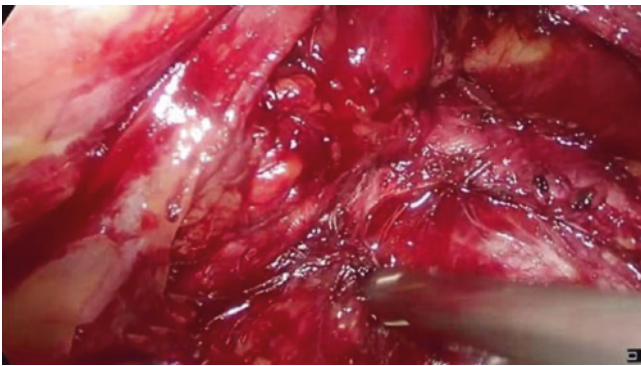


Fig. 5.127 Pelvis identified surrounded by adhesions

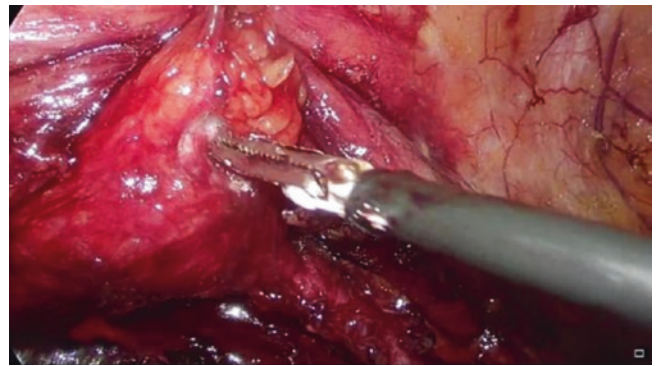


Fig. 5.128 Pelvis being dissected from surrounding pannus

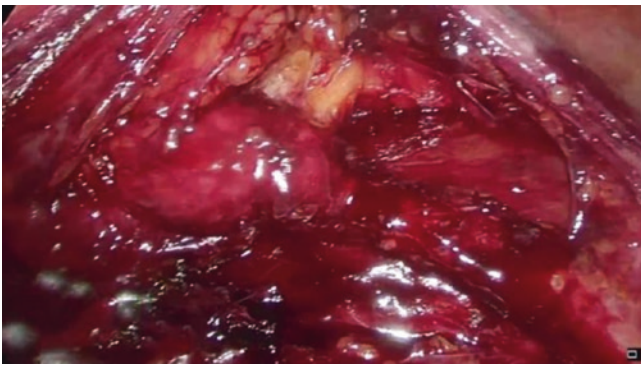


Fig. 5.129 Dissected pelvis, ureter and pelvi ureteric junction

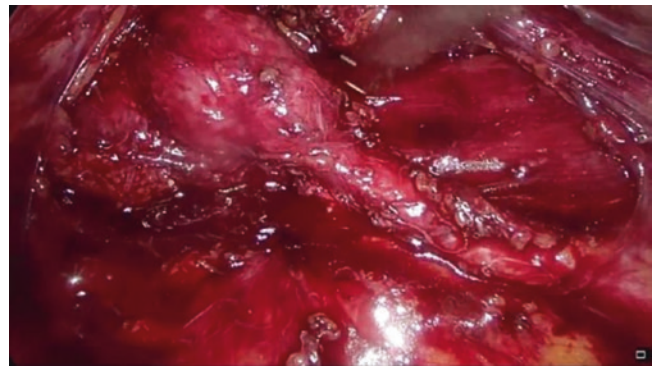


Fig. 5.130 Pelvi ureteric junction defined clearly

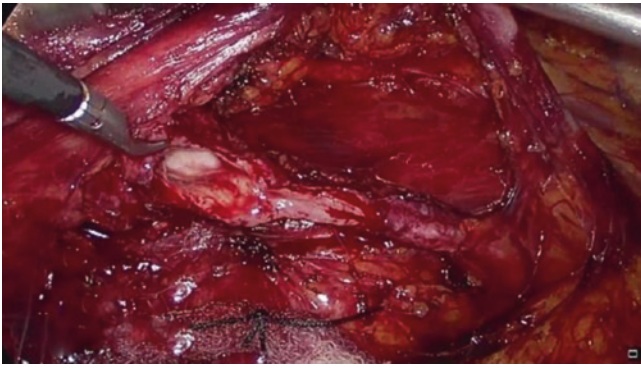


Fig. 5.131 Pyelotomy and ureterotomy done in 'Y' shape

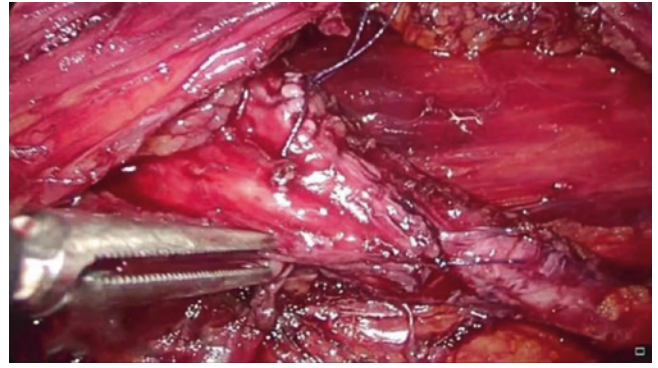


Fig. 5.132 Lateral margin suture completed

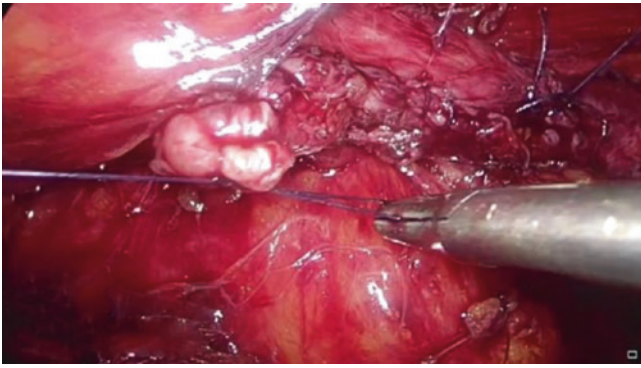


Fig. 5.133 Medial margin suture completed

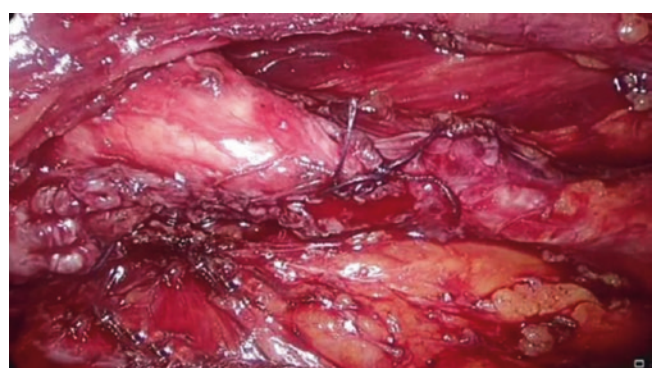


Fig. 5.134 Completed 'Y - V' plasty

5.11 Culp Flap Lap. Pyeloplasty

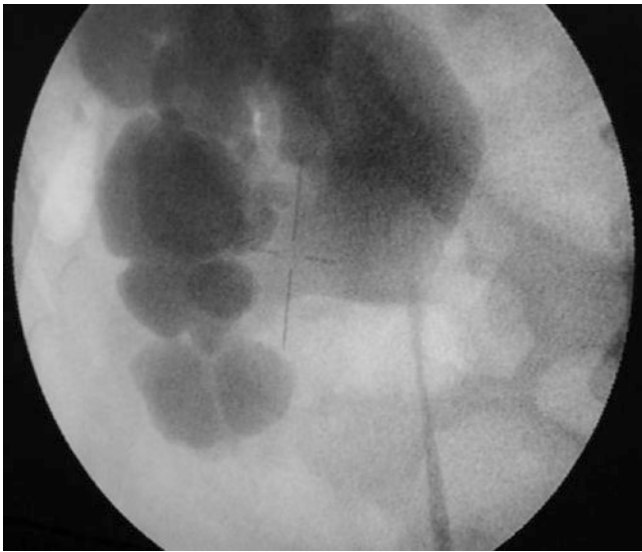


Fig. 5.135 IVU showing dilated pelvis and long segment of narrow ureter(Right)

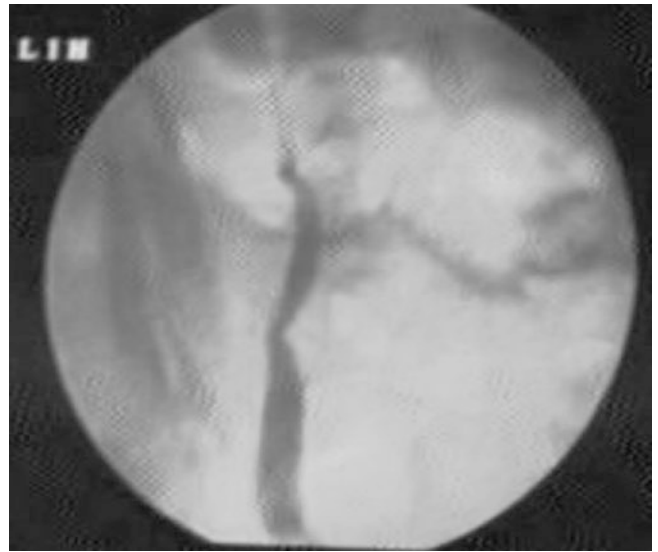

Fig. 5.136 Right RGP showing long segment narrowing of upper ureter

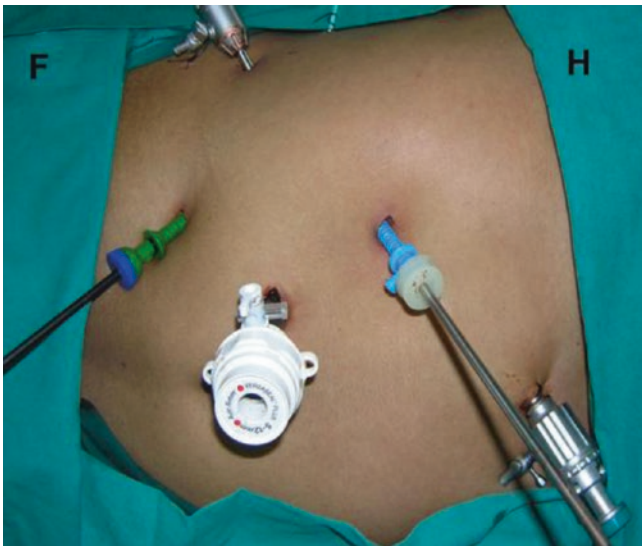

Fig. 5.137 Port position

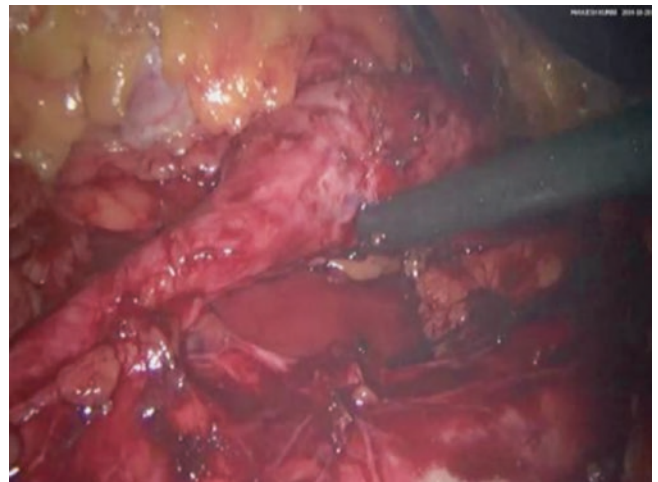


Fig. 5.138 Dilated pelvis and long narrow ureter seen

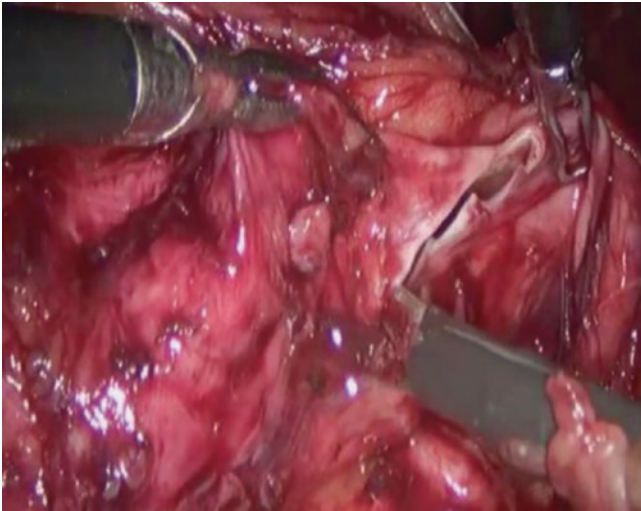


Fig. 5.139 Pyelotomy started along the medial aspect and extended inferiorly towards the ureter

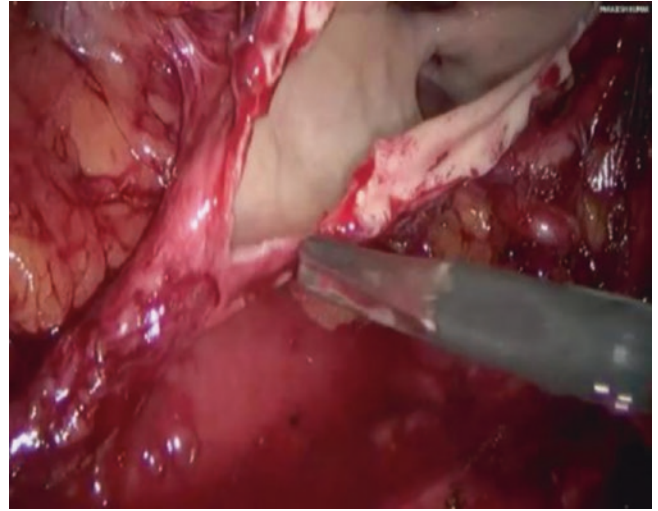


Fig. 5.140 Pyelotomy completed and ureterotomy to be started

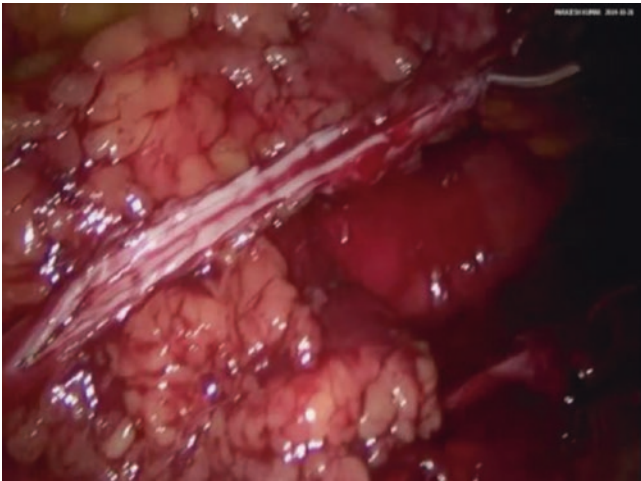


Fig. 5.141 Ureterotomy extended till normal ureter is seen

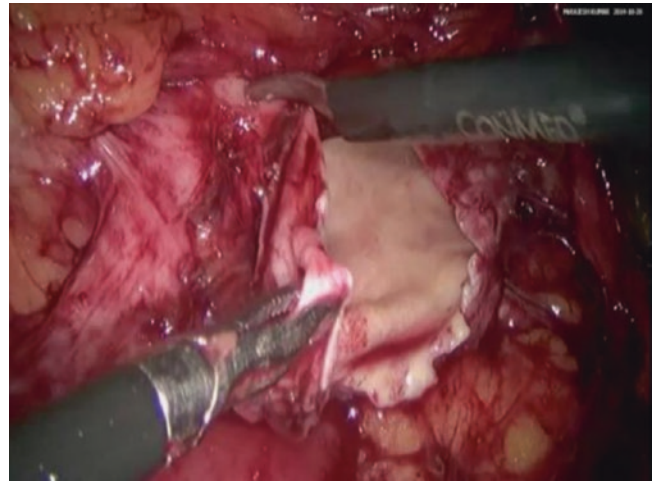


Fig. 5.142 Pelvic flap being created by extending the incision, then vertical pyelotomy on the lateral aspect (inverted U shape)

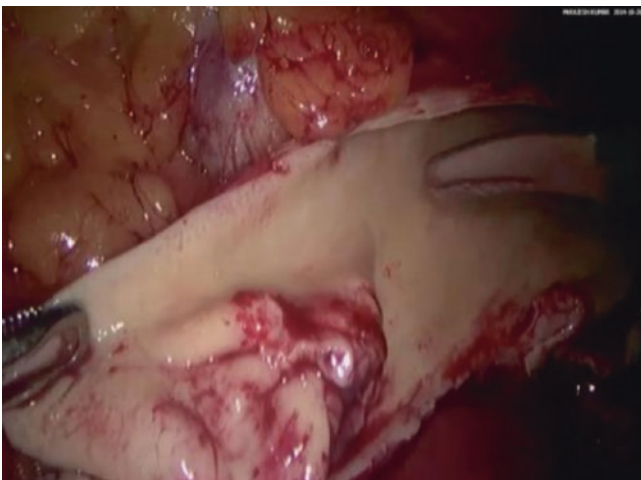


Fig. 5.143 Completed pelvic flap

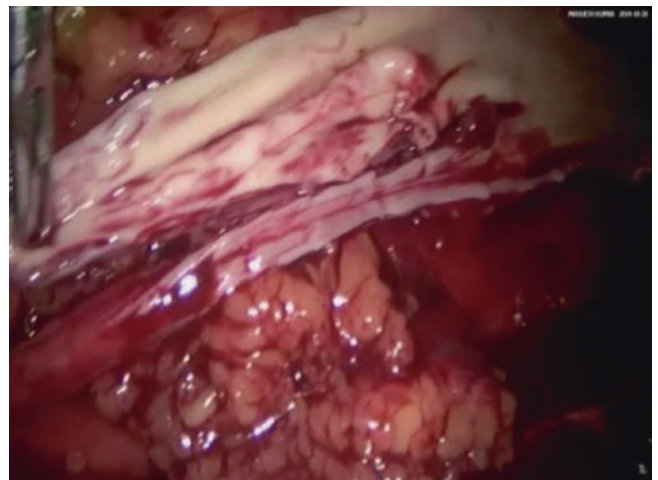


Fig. 5.144 Flap rotated down to confirm the adequacy of length

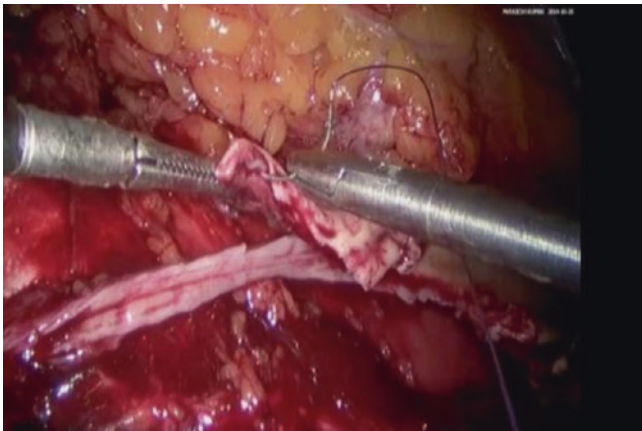


Fig. 5.145 Initial outside-in suture through apex of pelvic flap using 4-0 vicryl

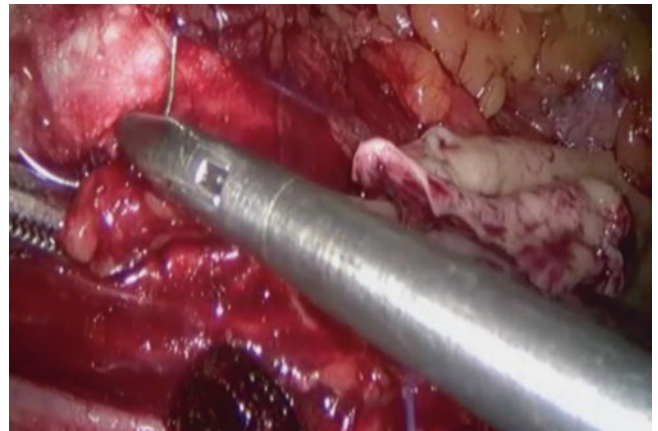


Fig. 5.146 Corresponding suture through the ureterotomy apex

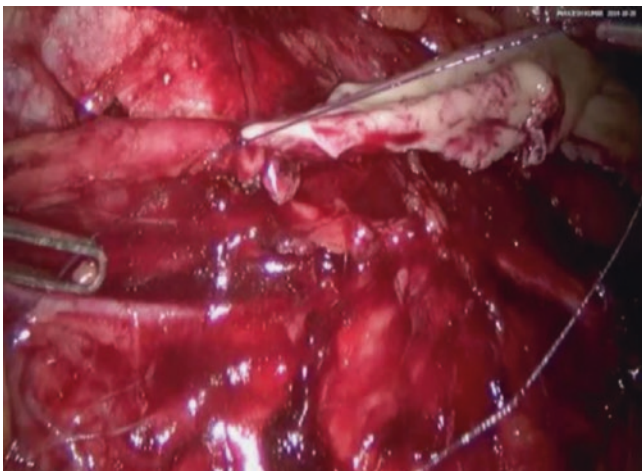


Fig. 5.147 Initial apical suture in place

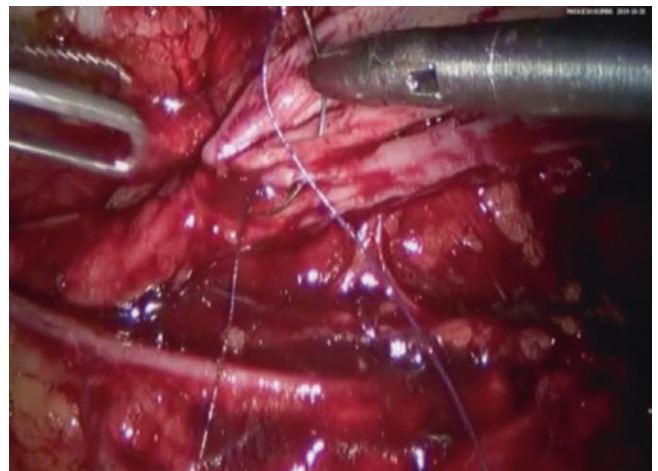


Fig. 5.148 Lateral ureterotomy edge sutured with the medial edge of pelvic flap to form the posterior layer

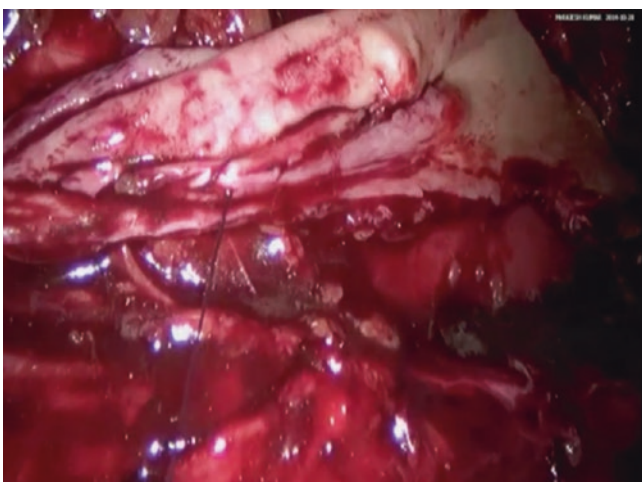


Fig. 5.149 Posterior layer suturing in progress

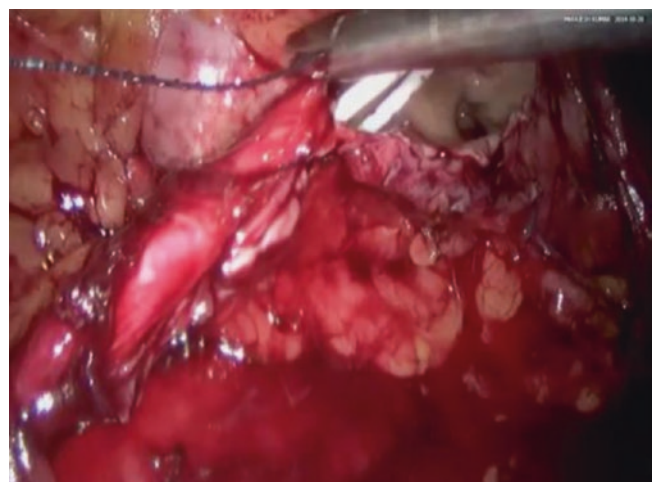


Fig. 5.150 Lateral edge of flap sutured with medial edge of ureterotomy – Anterior layer suturing in progress with 3-0 v-loc sutures

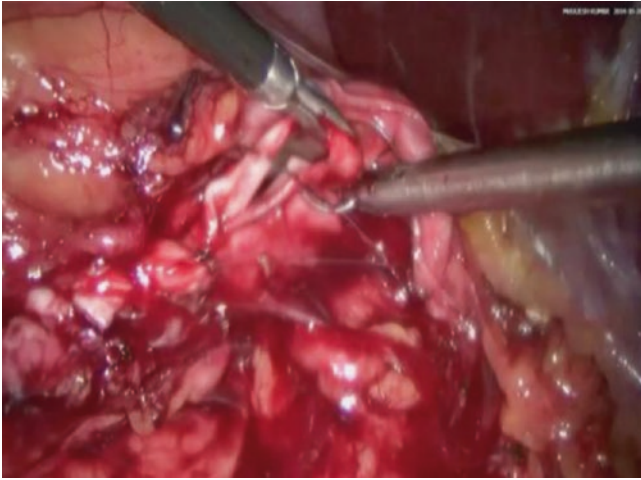


Fig. 5.151 Final part of suturing between the pyelotomy edges being done

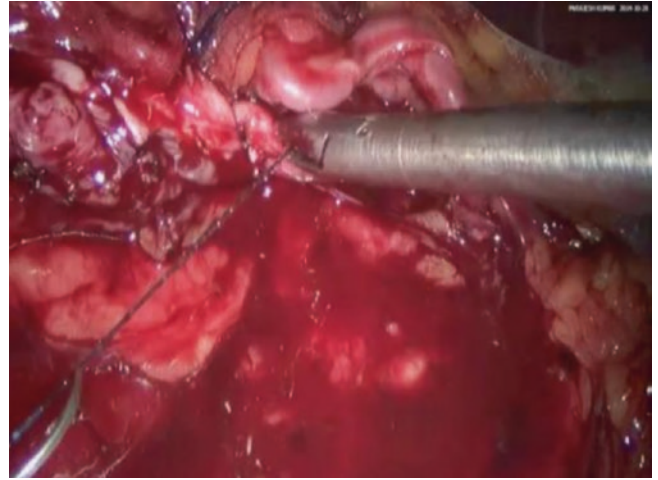


Fig. 5.152 Suturing almost complete

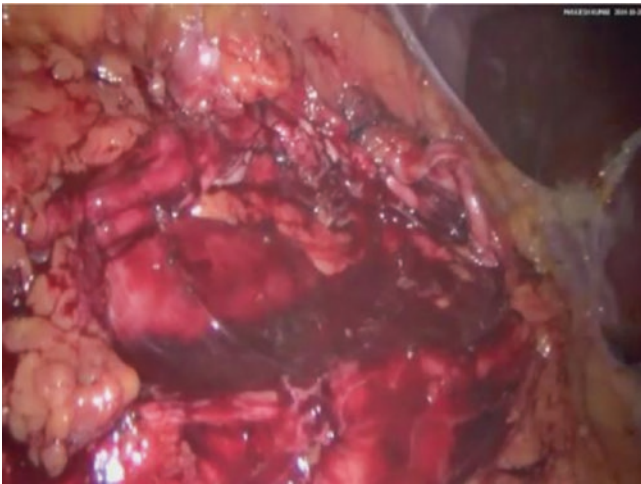

Fig. 5.153 Final view of completed flap pyeloplasty

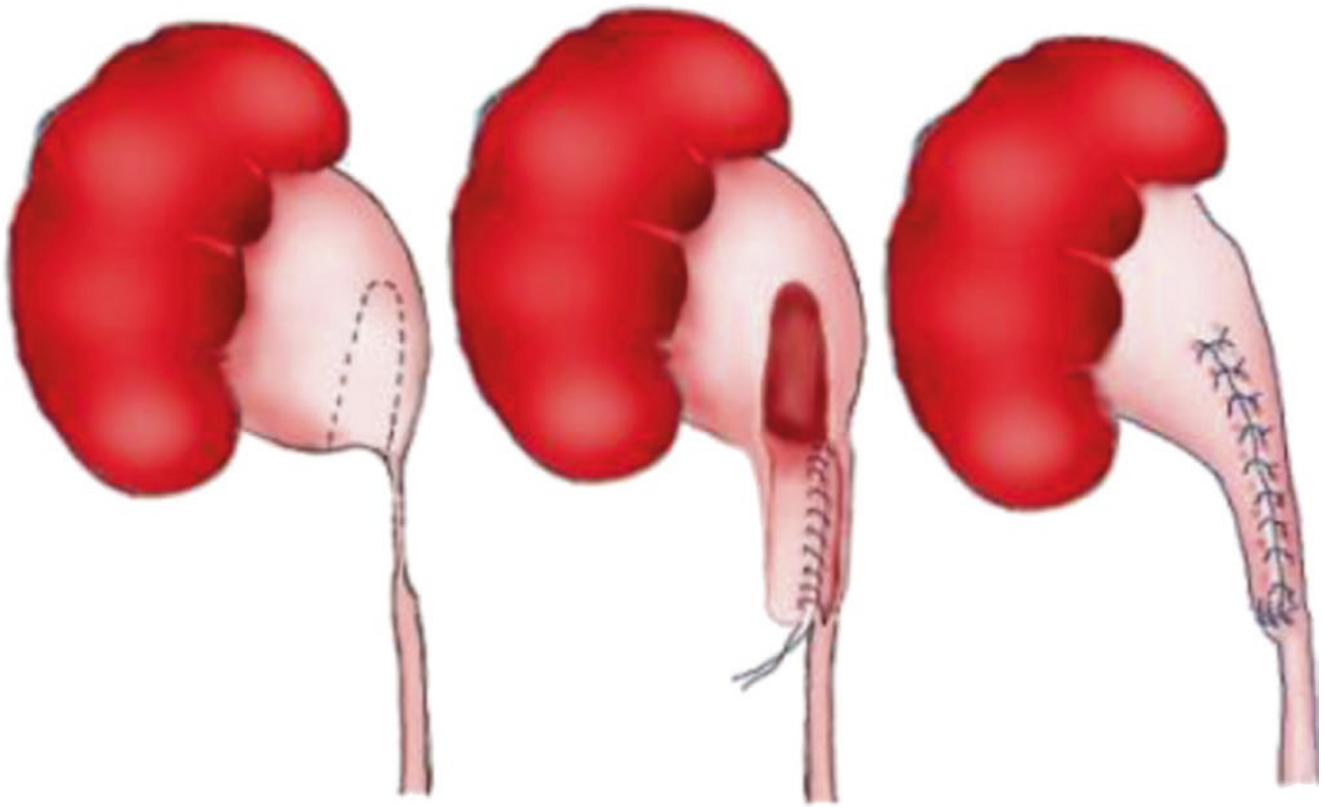


Fig. 5.154 Diagrammatic representation of Culp flap pyeloplasty

5.12 Reteroperitoneoscopic Dismembered Pyeloplasty

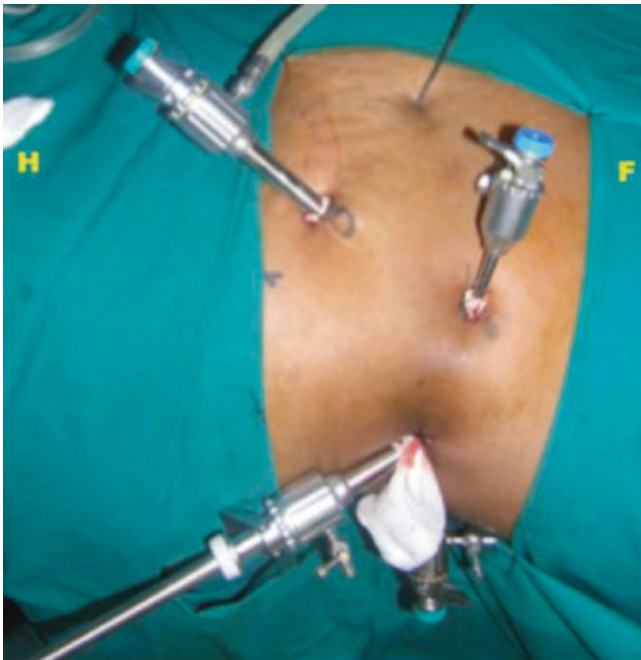

Fig. 5.155 Port placement (Right PUJ obstruction)

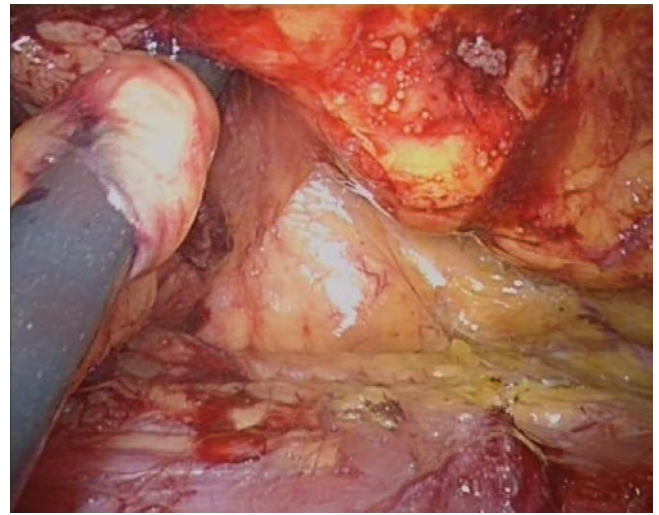


Fig. 5.156 Initial retroperitoneal dissection anterior to psoas

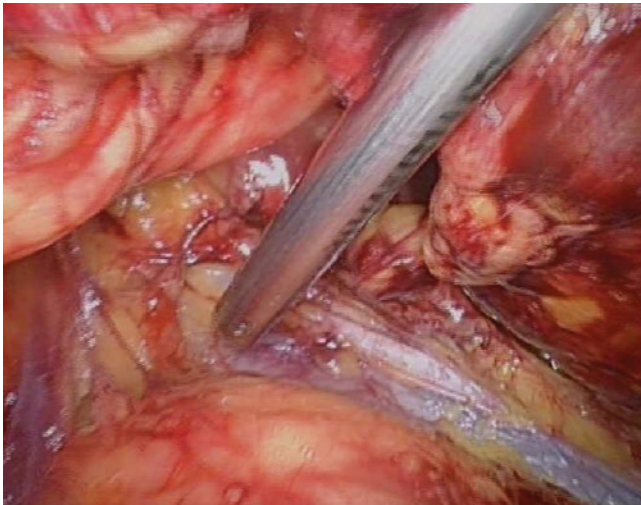


Fig. 5.157 Ureter and gonadal vein seen in the retroperitoneum

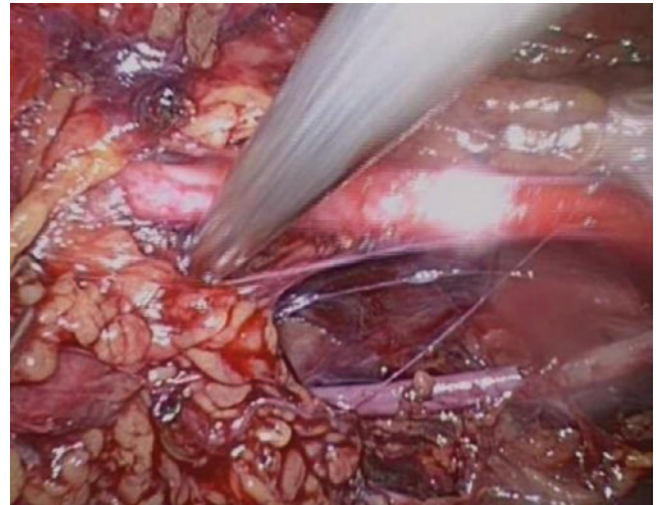


Fig. 5.158 Pelvis dissected and pexi ureteric junction delineated

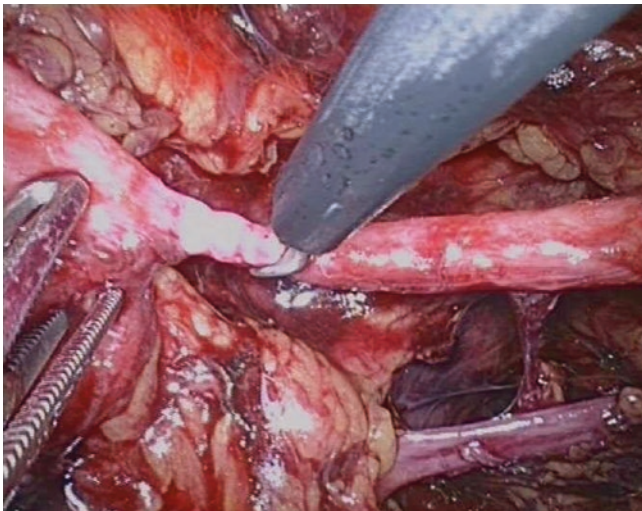


Fig. 5.159 Ureterotomy done distal to the PUJ

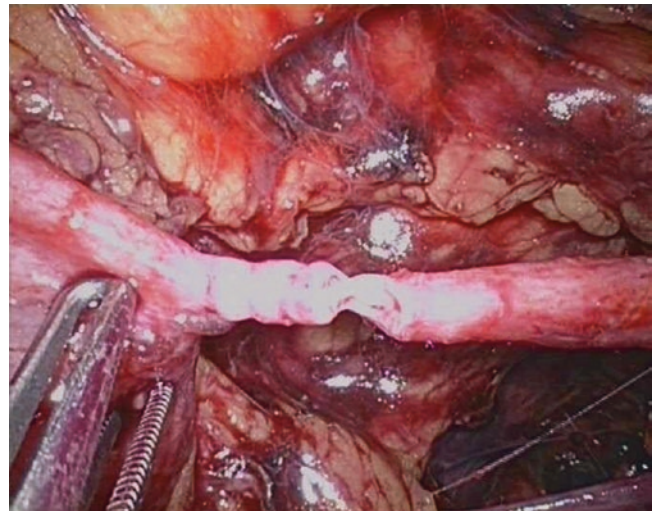


Fig. 5.160 Partial ureterotomy done – for better orientation

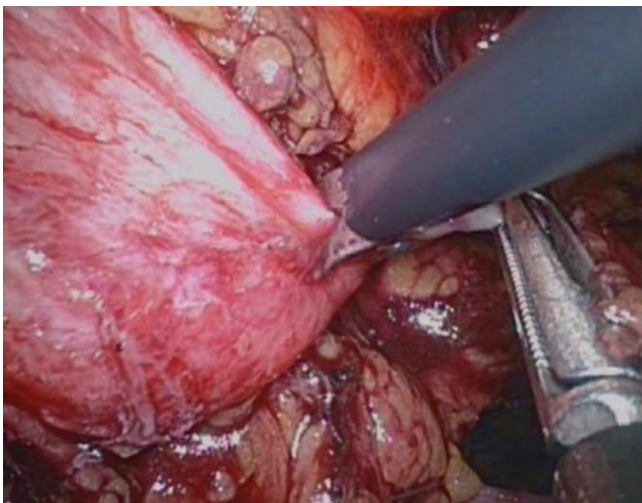


Fig. 5.161 Pyelotomy proximal to narrow PUJ

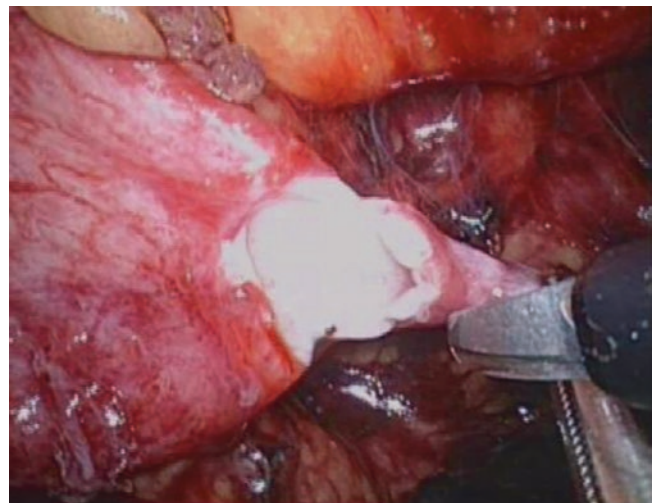


Fig. 5.162 Pyelotomy in progress

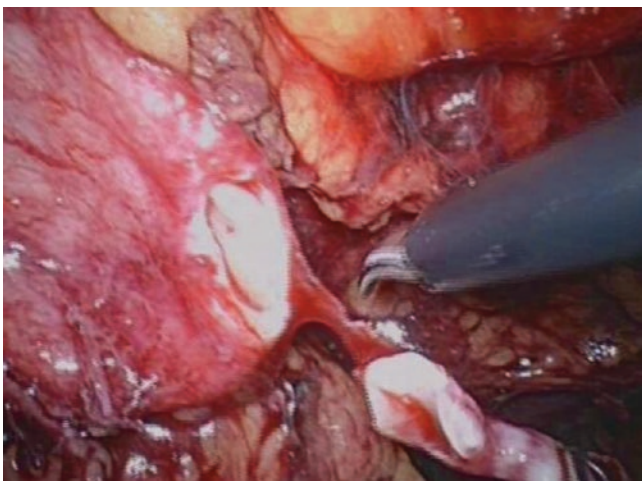


Fig. 5.163 PUJ dismembered from pelvis

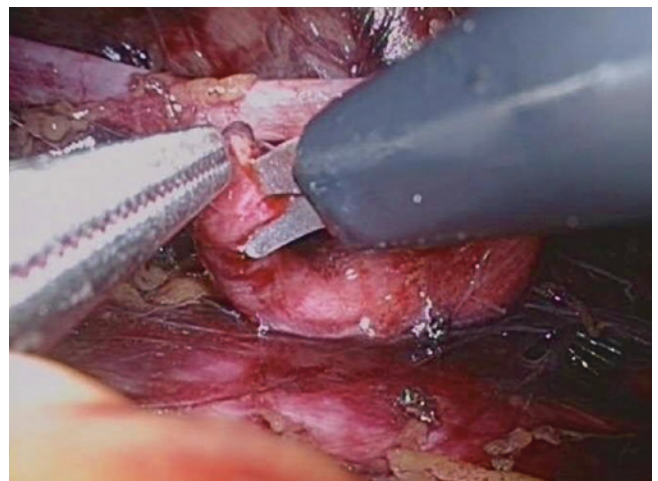


Fig. 5.164 Ureter spatulated after excision of PUJ

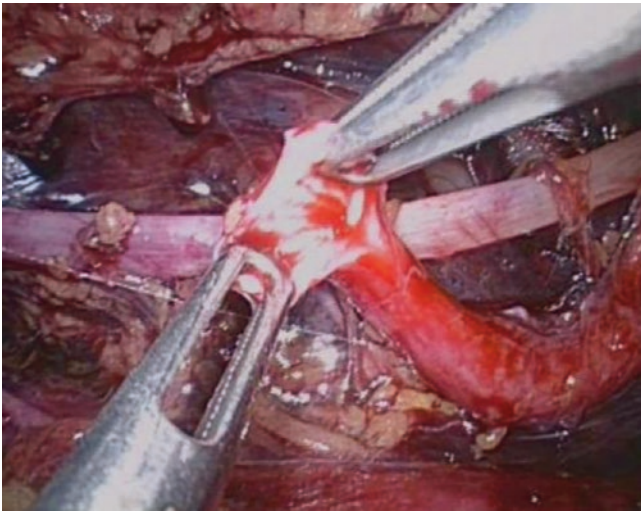


Fig. 5.165 Spatulated ureter

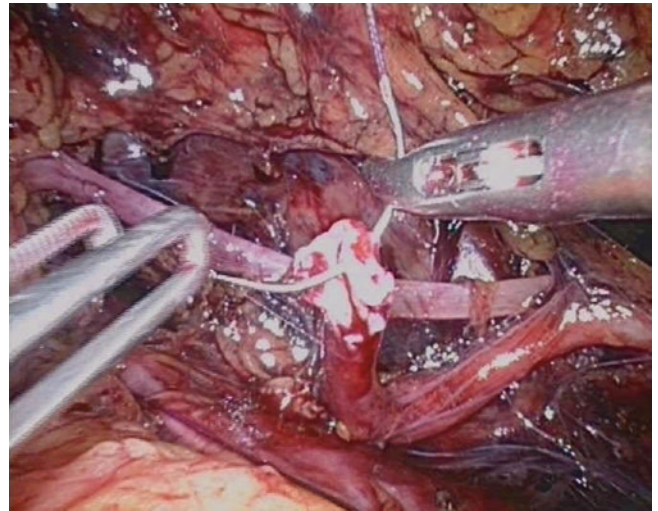


Fig. 5.166 Initial suture through the apex of spatulated ureter

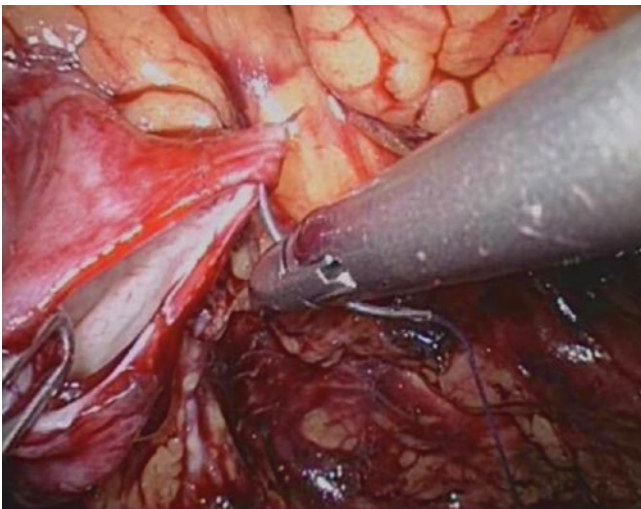


Fig. 5.167 Corresponding suture through the pelvis

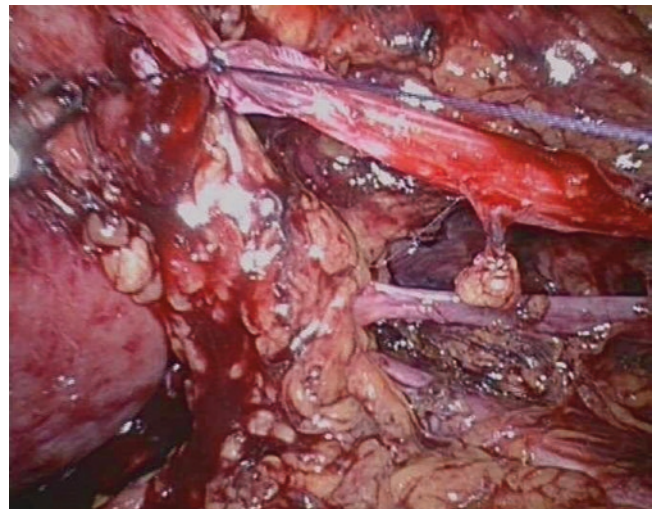


Fig. 5.168 Apical suture in place

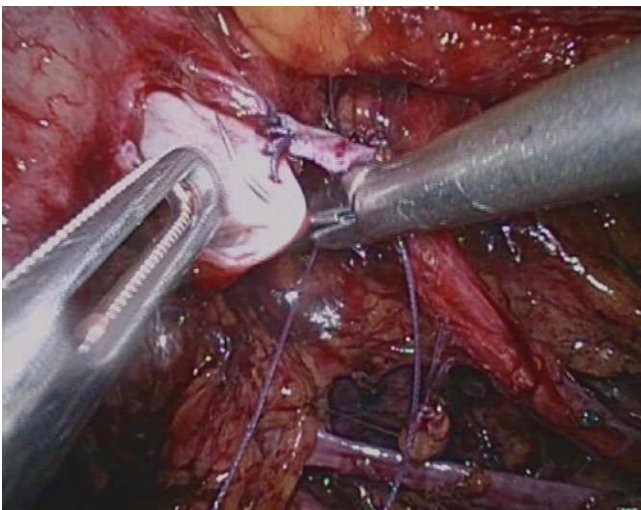


Fig. 5.169 Posterior layer suturing in progress

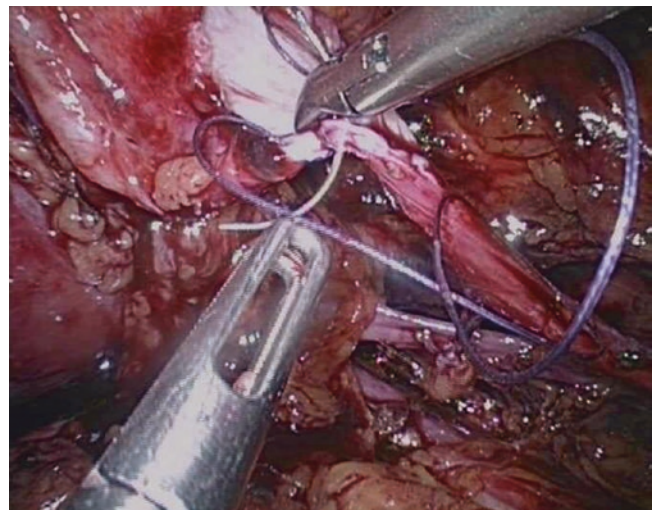


Fig. 5.170 Posterior layer suturing almost complete

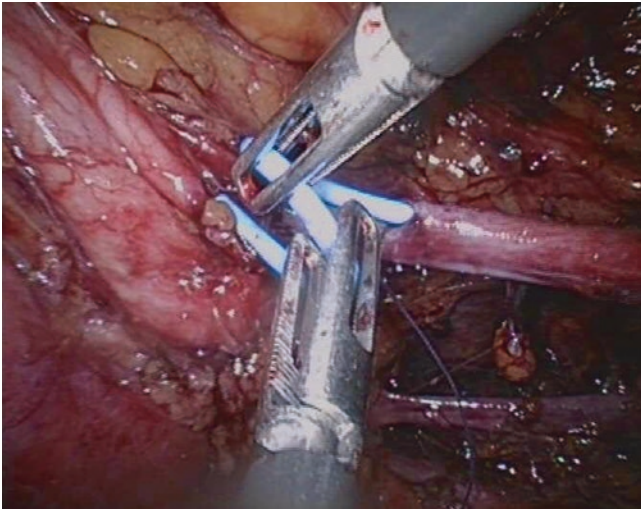


Fig. 5.171 Antegrade stenting after completion of posterior layer

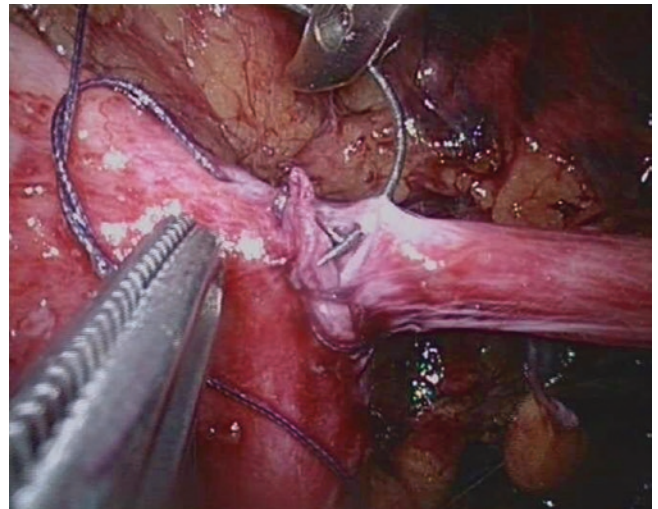


Fig. 5.172 Anterior layer suturing in progress

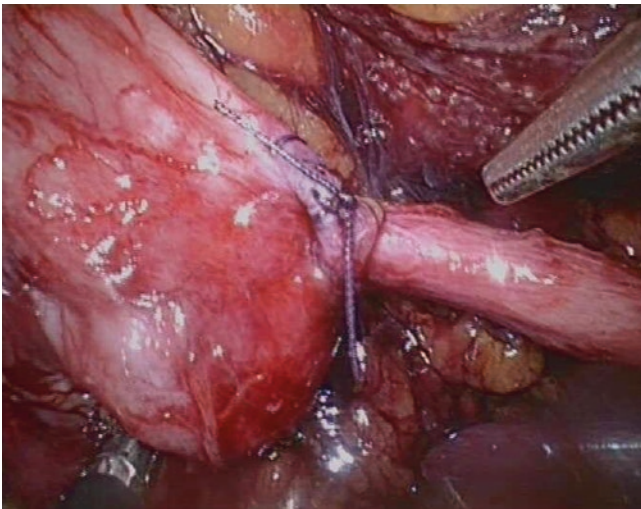


Fig. 5.173 Completed pyeloplasty

5.13 Reteroperitoneoscopic Non Dismembered Pyeloplasty

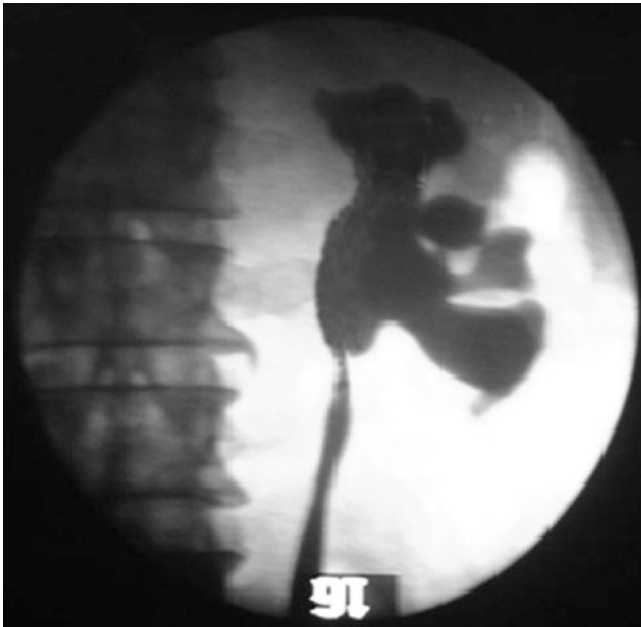

Fig. 5.174 Left RGP showing UPJ narrowing

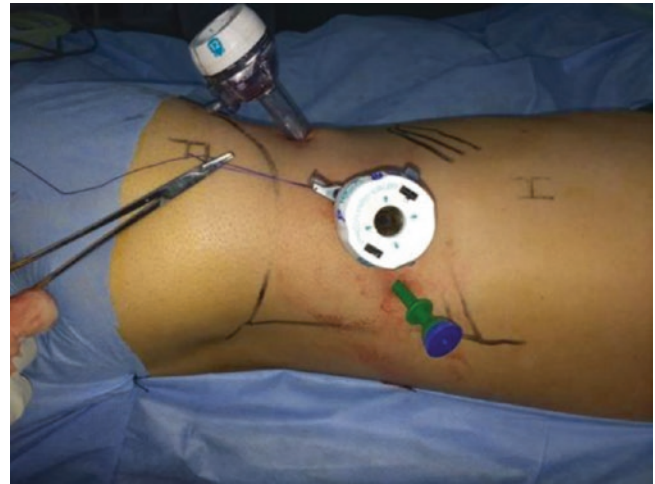

Fig. 5.175 Ports position

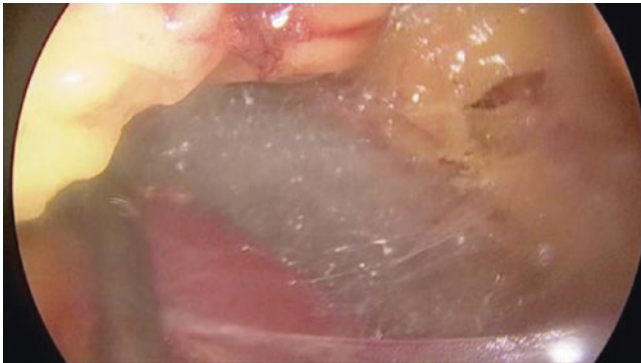


Fig. 5.176 Retroperitoneal dissection anterior to psoas

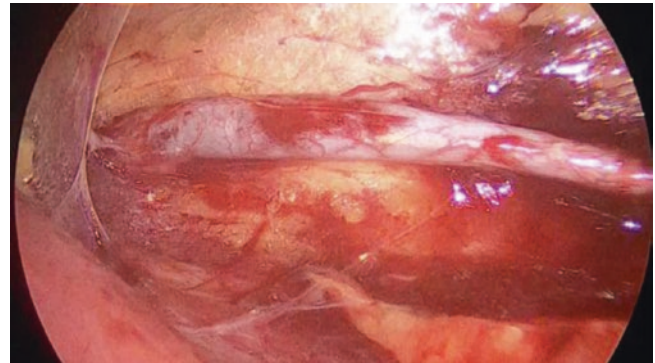


Fig. 5.177 Upper ureter being dissected

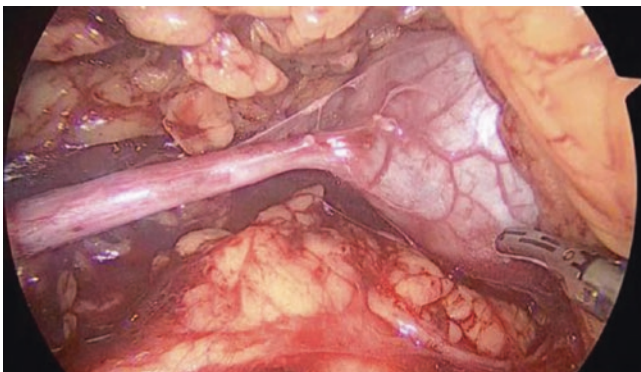


Fig. 5.178 Ureter being traced proximally till pelvis – Narrow PUIJ seen

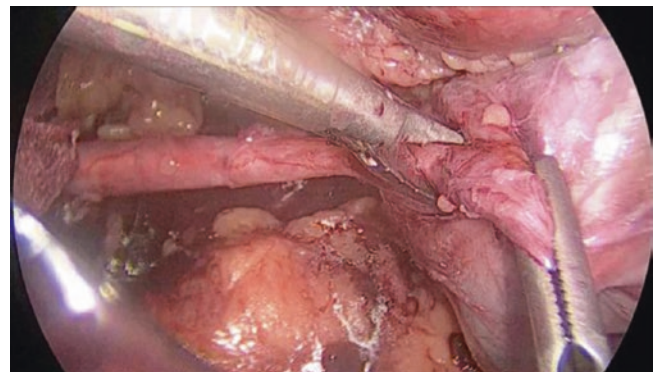


Fig. 5.179 Pelvic 'Y' flap creation started

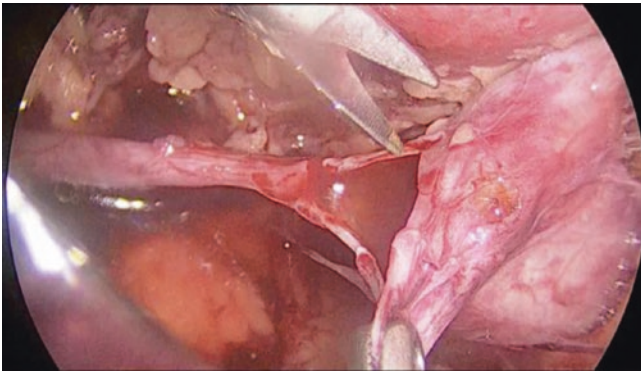


Fig. 5.180 Pelvic 'Y' flap creation in progress

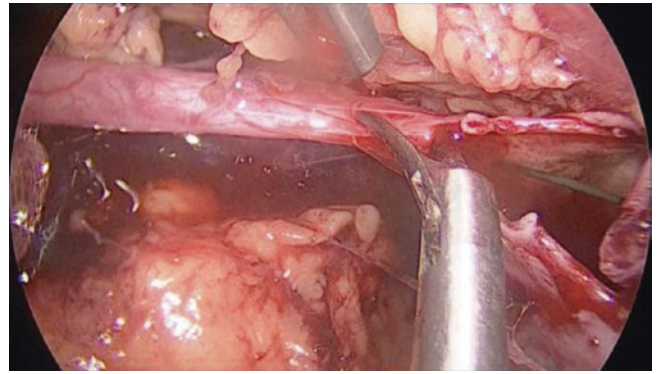


Fig. 5.181 Ureter spatulated laterally to create the vertical limb of 'Y' flap

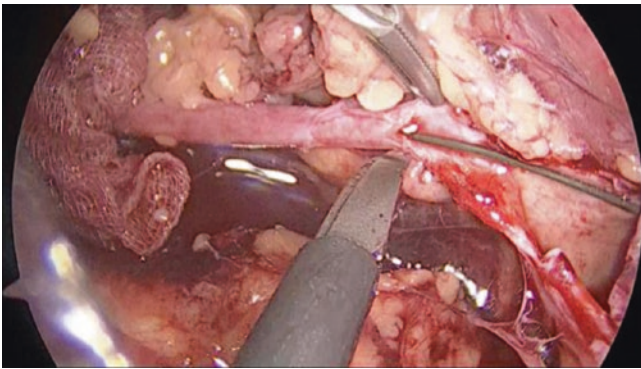


Fig. 5.182 Completed 'Y' flap

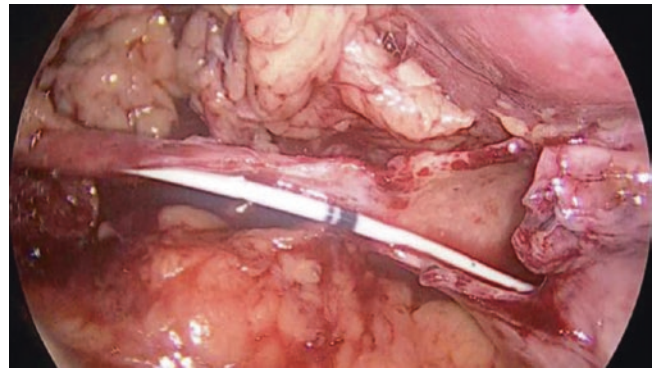


Fig. 5.183 Stent being inserted antegrade

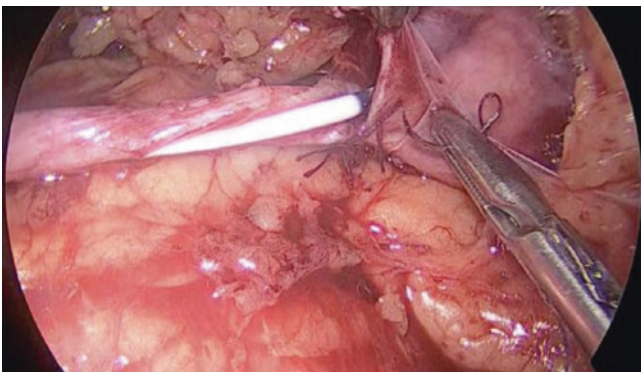


Fig. 5.184 Flap advanced downwards by placing interrupted 4-0 vicryl sutures, in the posterior layer

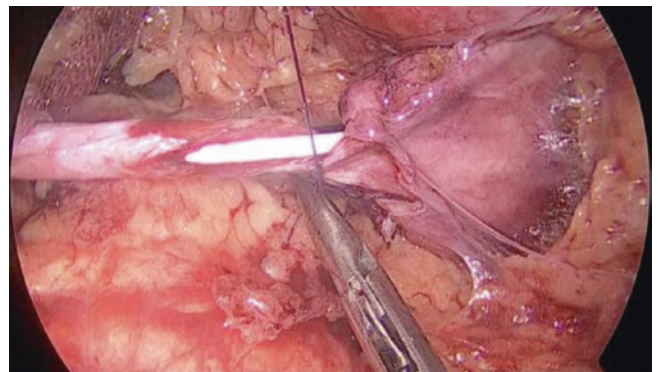


Fig. 5.185 Posterior layer suturing in progress

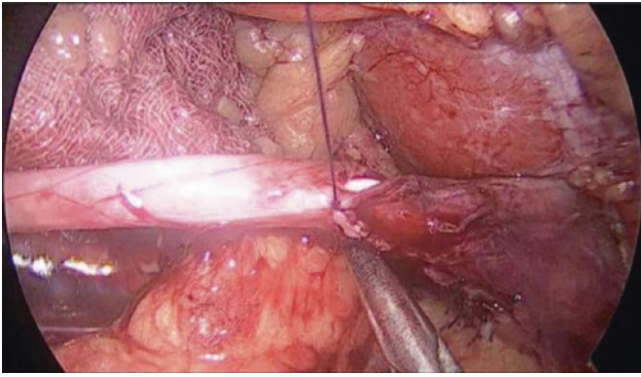


Fig. 5.186 Posterior layer suturing completed

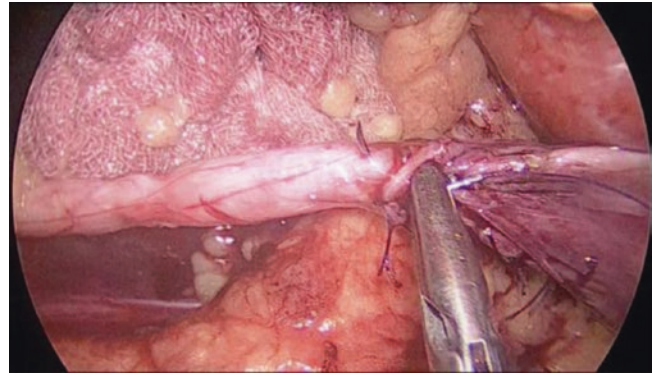


Fig. 5.187 Apex of flap sutured with the apex of ureteric spatulation

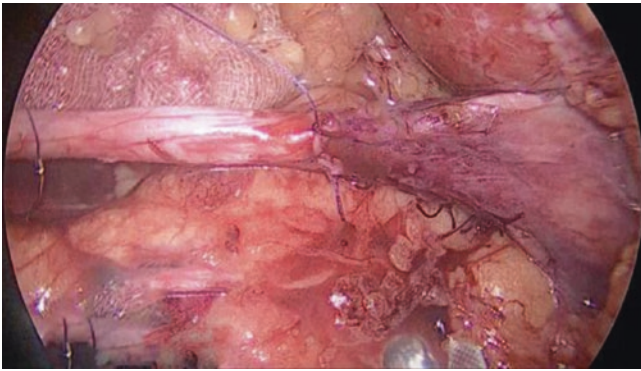


Fig. 5.188 Posterior layer and apical suture completed

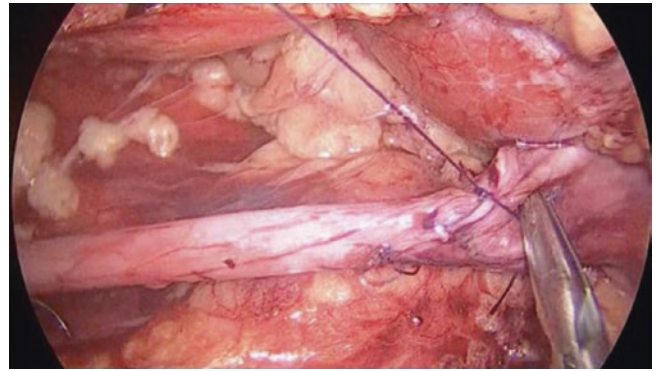


Fig. 5.189 Interrupted anterior layer suturing in progress

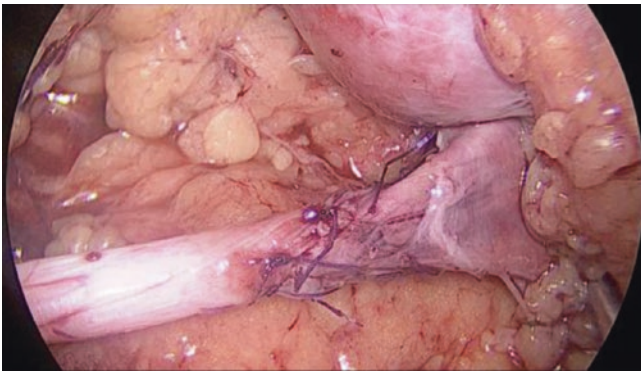

Fig. 5.190 Completed Y- V pyeloplasty

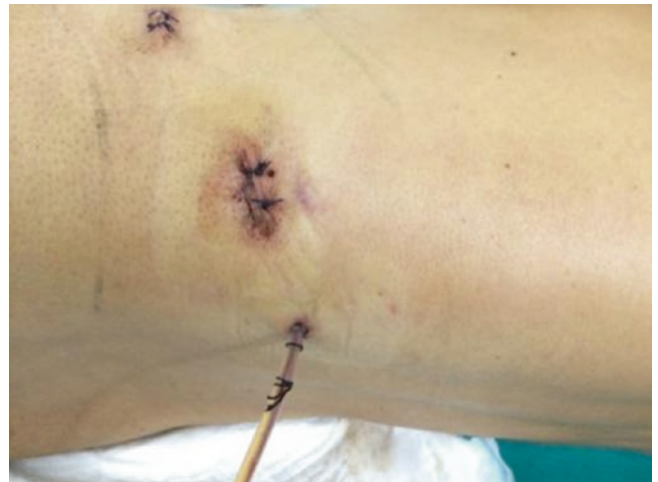

Fig. 5.191 Drain placed

5.14 Tips – Difficulty in Stent Insertion

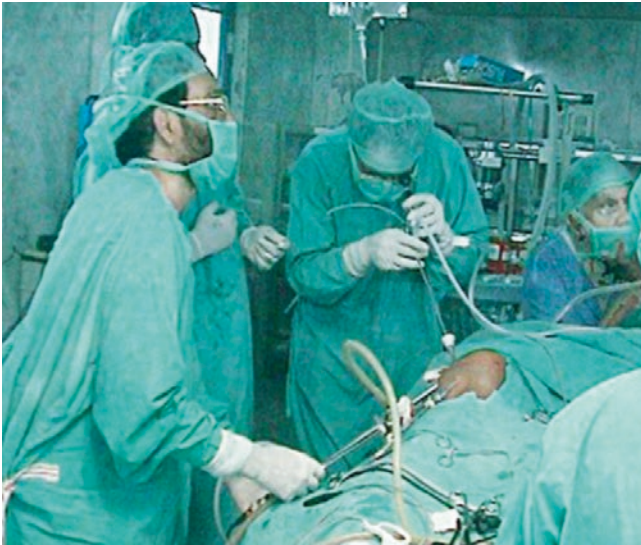

Fig. 5.192 Difficulty in stent insertion negotiated using intra operative ureteroscopy through subcostal port-external view

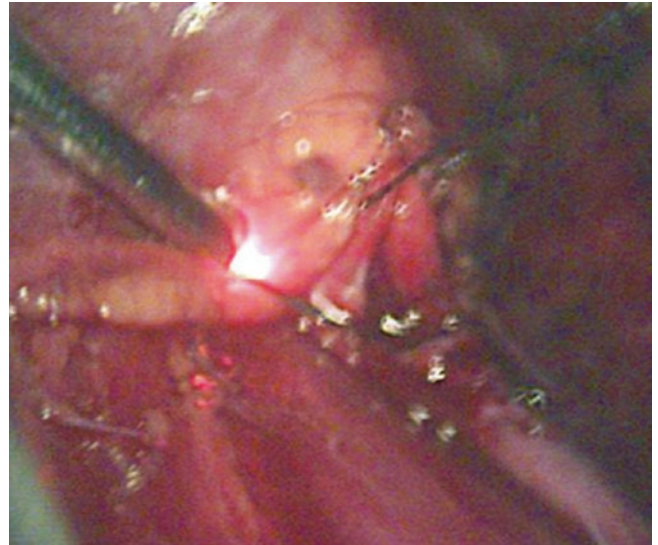


Fig. 5.193 Difficulty in stent insertion negotiated using intra operative ureteroscopy -endoview

5.15 PUJ Obstruction with Secondary Calculus

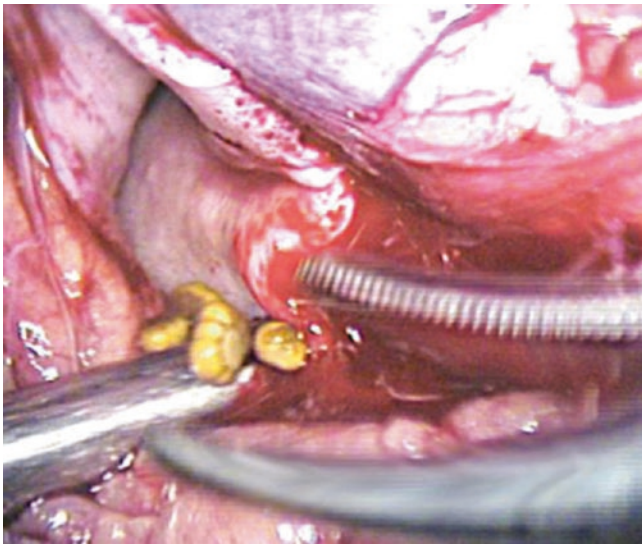


Fig. 5.194 Calculi being removed with forceps

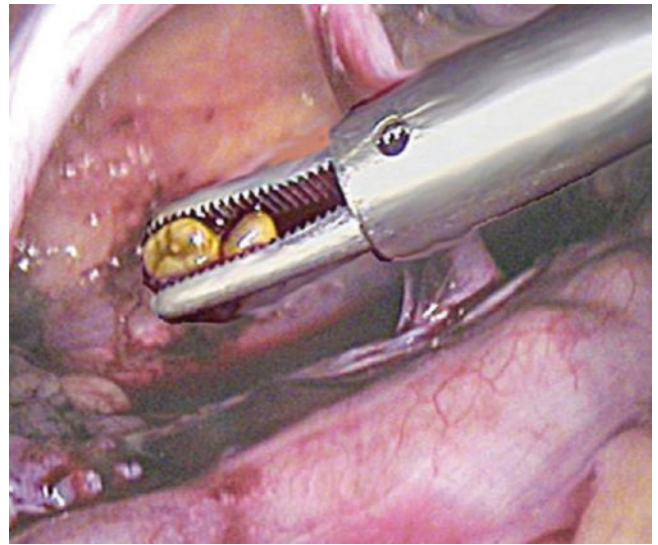


Fig. 5.195 Calculi being removed through 10 mm port

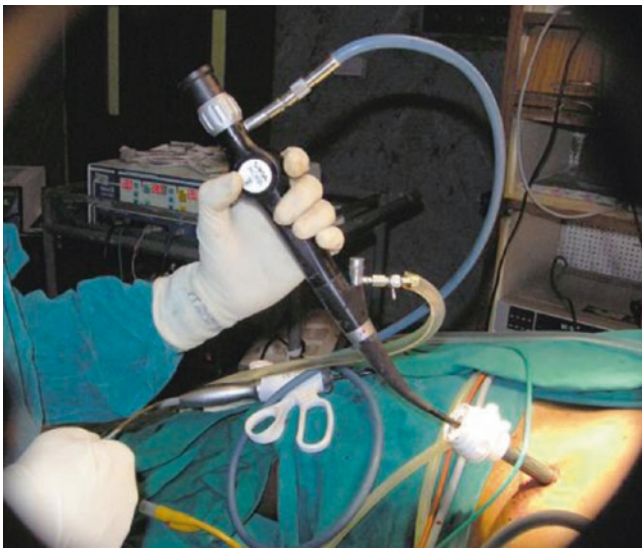


Fig. 5.196 Flexible ureteroscopy introduced through 5 mm port

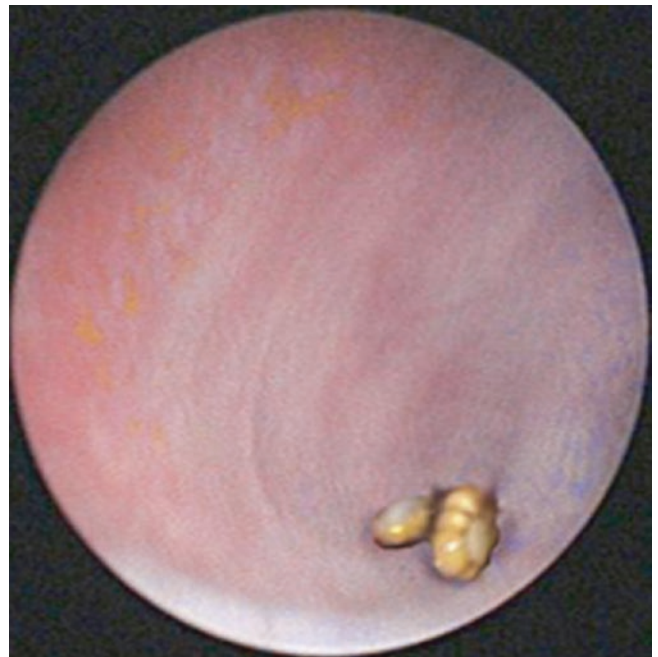


Fig. 5.197 Calculi removed using flexible ureteroscope and basket

References

- Schuessler WW, Grune MT, Tecuanhuey LV, Preminger GM. Laparoscopic dismembered pyeloplasty. *J Urol*. 1993;150(6):1795–9.
- Khan F, Ahmed K, Lee N, Challacombe B, Khan MS, Dasgupta P. Management of ureteropelvic junction obstruction in adults. *Nat Rev Urol*. 2014;11(11):629–38.
- Ekin RG, Celik O, Ilbey YO. An up-to-date overview of minimally invasive treatment methods in ureteropelvic junction obstruction. *Cent Eur J Urol*. 2015;68(2):245–51.
- Jarrett TW, Chan DY, Charambura TC, Fugita O, Kavoussi LR. Laparoscopic pyeloplasty: the first 100 cases. *J Urol*. 2002;167(3):1253–6.
- Janetschek G, Peschel R, Bartsch G. Laparoscopic fenger plasty. *J Endourol*. 2000;14:889.
- Chen RN, Moore RG, Kavoussi LR. Laparoscopic pyeloplasty. Indications, technique, and longterm outcome. *Urol Clin N Am*. 1998;25:323.
- Soulfe M, Salomon L, Patard J-J, Mouly P, Manunta A, Antiphon P, et al. Extraperitoneal laparoscopic pyeloplasty: a multicenter study of 55 procedures. *J Urol*. 2001;166:48.
- Eden CG, Cahill D, Allen JD. Laparoscopic dismembered pyeloplasty: 50 consecutive cases. *BJU Int*. 2001;88(6):526–31.
- Turk IA, Davis JW, Winkelmann B, Deger S, Richter F, Fabrizio MD, et al. Laparoscopic dismembered pyeloplasty the method of choice in the presence of an enlarged renal pelvis and crossing vessels. *Eur Urol*. 2002;42:268.
- Ramalingam M, Murugesan A, Senthil K, Pai MG. A comparison of continuous and interrupted suturing in laparoscopic pyeloplasty. *JSLs*. 2014;18(2):294–300.
- Singh V, Sinha RJ, Gupta DK, Kumar V, Pandey M, Akhtar A. Prospective randomized comparison between transperitoneal laparoscopic pyeloplasty and retroperitoneoscopic pyeloplasty for primary ureteropelvic junction obstruction. *JSLs*. 2014;18k. pii: e2014.00366.
- Moon DA, El-Shazly MA, Chang CM, Gianduzzo TR, Eden CG. Laparoscopic pyeloplasty: evolution of a new gold standard. *Urology*. 2006;67(5):932–6.
- Castillo OA, Cabrera W, Aleman E, Vidal-Mora I, Yañez R. Laparoscopic pyeloplasty: technique and results in 80 consecutive patients. *Actas Urol Esp*. 2014;38(2):103–8.
- Singh O, Gupta SS, Hastir A, Arvind NK. Laparoscopic dismembered pyeloplasty for ureteropelvic junction obstruction: experience with 142 cases in a high-volume center. *J Endourol*. 2010;24(9):1431–4.
- Inagaki T, Rha KH, Ong AM, Kavoussi LR, Jarrett TW. Laparoscopic pyeloplasty: current status. *BJU Int*. 2005;95 Suppl 2:102–5.
- Manickam R, Krishnasamy S, Kallapan S, Pai MG. Transmesocolic approach to laparoscopic pyeloplasty: our 8-year experience. *J Laparoendosc Adv Surg Tech*. 2008;18(2):194–8. doi:10.1089/lap.2007.0046.

Hariharan Palayapalayam Ganapathi,
Gabriel Ogaya-Pinies, Travis Rogers, and Vipul R. Patel

6.1 Introduction

Minimal access reconstructive surgery has evolved in a large way over past two decades. Laparoscopic pyeloplasty (LP) was first introduced in 1993 by Schuessler et al. [1]. Since then, it has rapidly become part of the urologic armamentarium for the treatment of primary ureteropelvic junction obstruction (UPJO) [2].

Laparoscopic suturing, particularly for children, is challenging and time consuming and has a steep and long learning curve because of its technical difficulty. Surgical robot with endowrist and 3D vision provides ease of suturing. The technological evolutions like better optics & instrumentation, delayed absorbable and barbed suture are further propelling the momentum of minimal access surgery. The ease of complex surgical procedures with robot assistance is ever expanding with experience. In 2005, one of the earliest series of Robotic pyeloplasty in 50 adults was reported by this author. Today, pyeloplasty is the most prevalently reported and highest volume application of robot-assisted minimally invasive surgery in children [3].

A recent study examining population weighted USA Nationwide Inpatient Sample (NIS) data reported that for the period 2008–2010, the distribution of open pyeloplasty (OP), RLP and conventional LP approaches for paediatric pyeloplasty was about 83.5 %, 13.5 % and 3 %, respectively [4]. These data also indicated that adoption of RLP has surpassed that of the conventional LP, and that RLP now comprises >80 % of minimally invasive pediatric pyeloplasties [4]. The utility of RLP seems to be preferred for older children at present, with most young children undergoing OP [4].

H.P. Ganapathi (✉) • G. Ogaya-Pinies
T. Rogers • V.R. Patel (✉)
University of Central Florida College of Medicine, Global
Robotics Institute, Florida Hospital Celebration Health,
410 Celebration Place, Orlando, FL 34747, USA
e-mail: hari.uro@gmail.com; Vipul.Patel.MD@flhosp.org

6.2 Indications for Robotic Laparoscopic Pyeloplasty

Indications for RLP are not different from open pyeloplasty. These indications include

- Increasing hydronephrosis
- Progressive deterioration of renal function
- Recurrent urinary tract infection in the setting of obstruction
- Symptoms (pain, nausea/vomiting, hematuria)

Robotics increases operative efficiency compared with conventional laparoscopy and facilitates more complex reconstructive procedures, such as ureterocalicostomy for redo surgery as well as a primary modality for extreme cases of intrarenal collecting systems. Thus, surgical robot may help to expand the indications for LP. RLP has few relative contraindications which may warrant OP.

Relative Contraindications for RLP

- Prior intra-abdominal operations
- Small intrarenal pelvis
- Long ureteral stricture
- Small infant <6 kg

When conventional laparoscopic pyeloplasty for children was first introduced, it was primarily performed on children older than 1 year, but improvements in instrumentation and surgeon experience have made laparoscopic pyeloplasty feasible in infants less than 6 months of age [5]. The robotic platform, which increases the range of motion and overcomes many limitations of laparoscopic surgery, has also been safely used to perform pyeloplasty in children 3–12 months old (6–11 kg) [6, 7].

A clear advantage in terms of hospital stay for minimally invasive over open pyeloplasty was observed only in the adult population [8].

6.3 Patient Positioning and Port Placement

Other technical aspects RAP are similar to conventional laparoscopic pyeloplasty as discussed in previous chapters of this book.

6.3.1 Surgical Tips

- Proper patient positioning with bean bag and padding
- Extra long trocar for fourth arm to reduce arms clashing
- High flow insufflators.

6.4 Comparison: Robotic Versus Conventional Laparoscopic Versus Open Pyeloplasty

Cundy et al. published a meta-analysis comparing all three methods of pyeloplasty in 2014 [8]. Amongst the studies that reported satisfactory patient age data, children in the RAP groups tended to be older than those in the LP groups (overall mean age 10.0 years for RAP vs 6.5 years for LP) and OP groups (overall mean age 8.1 years for RAP vs 7.0 years for OP). Pooled analysis identified no overall difference in

weight amongst the four studies that reported these data for RAP vs OP ($P=0.27$). The youngest patients reported were 2.0, 1.0 and 1.0 month of age amongst RAP, LP, and OP groups respectively. The smallest patients reported were 5.1, 5.9, and 4.8 kg amongst RAP, LP, and OP groups respectively.

The present meta-analysis identified no significant differences between RAP and LP or OP for primary outcome variables of operative success, requirement for re-operation, conversion rates, postoperative complications, and urinary leakage. Significant differences in favour of RAP were found for LOS (vs LP and OP). Borderline significant differences in favour of RAP were found for EBL (vs OP). OT was found to be significantly longer for RAP vs OP. Limited evidence from observational studies indicates lower opiate analgesia requirement for RAP (vs LP and OP), but considerably higher direct costs (vs OP). The main technical benefits of robot-assistance in minimally invasive surgery are consistently attributed towards the more demanding procedural steps, namely the ureteric spatulation, pelvis reduction, and uretero-pelvic anastomosis. The motion-scaled EndoWrist® instruments enable parallel alignment of scissors with the proximal ureter for more accurate and controlled linear spatulation. Similarly, the enhanced manual dexterity with these instruments and stereoscopic vision contribute to a lower degree of difficulty for the challenging task of intracorporeal suturing within small anatomical workspaces.

Overall success rates for studies comparing RAP and LP were 99.3 % and 96.9 %, respectively (Fig. 6.1a). Overall success rates for studies comparing RAP and OP were 87.3 %

and 88.5 %, respectively (Fig. 6.1b). There were no statistically significant differences in the pooled analysis of success rates.

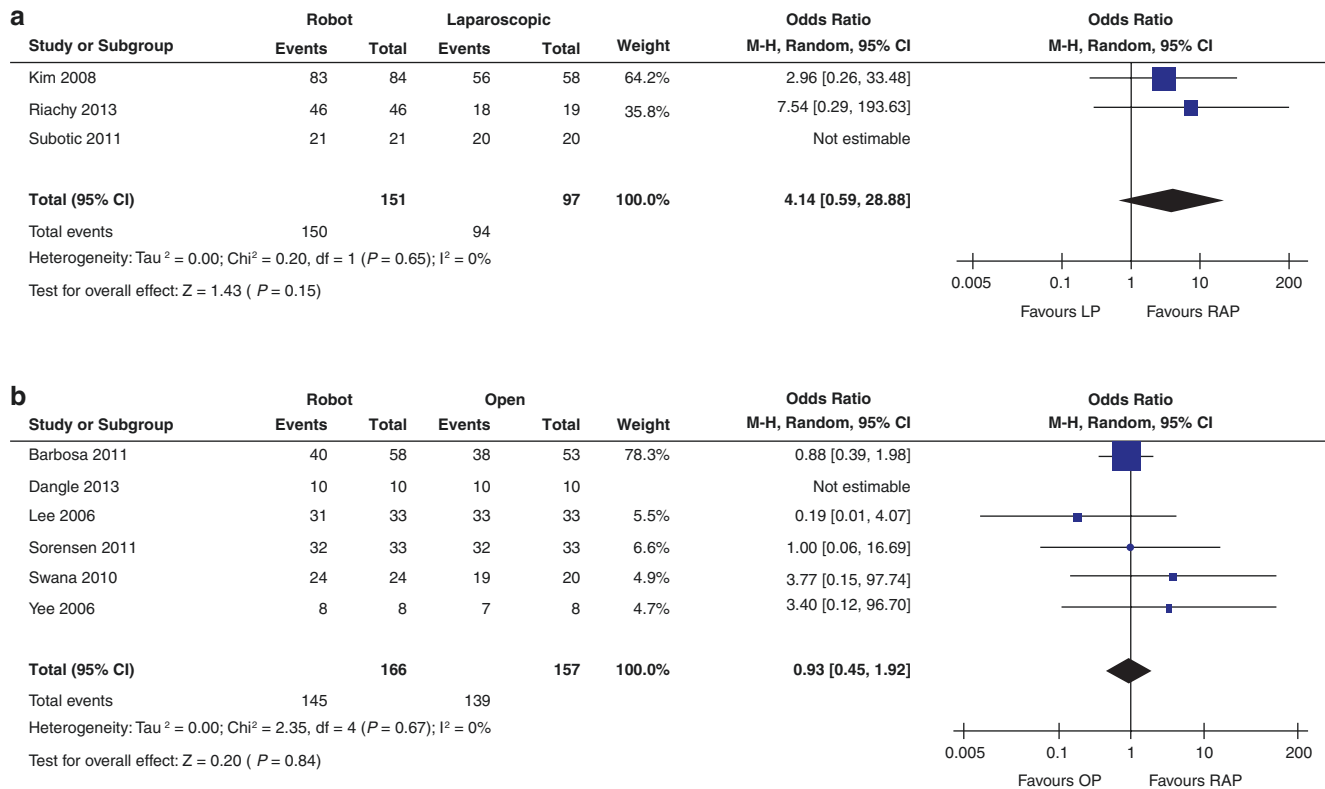


Fig. 6.1 Forest plot comparisons of overall success rates for studies comparing RLP vs LP (a) and RLP vs OP (b)

Eight studies reported data for requirement of re-operation due to recurrent PUJO. While overall re-operations rates were lower in RAP vs LP and OP, these did not reach statistical significance (Fig. 6.2).

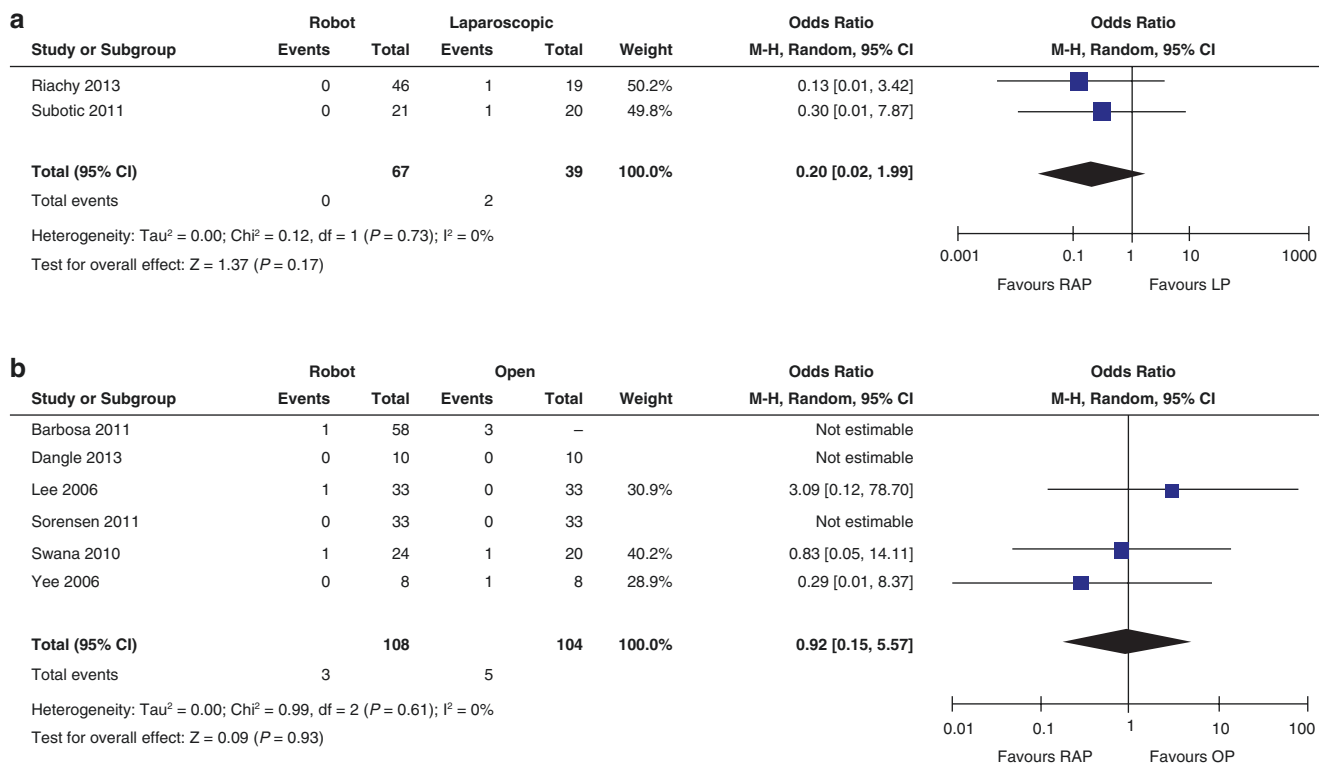


Fig. 6.2 Forest plot comparisons of re-operating rates for studies comparing RAP vs LP (a) and RAP vs OP (b)

Analysis of complications categorised into sub-groups of minor (Clavien Grade 1–2) and major (Clavien Grade 3–5) events according to the Clavien-Dindo classification

identified no significant differences between the RAP vs LP groups, and RAP vs OP groups ($P=0.47$ – 0.88) (Figs. 6.3 and 6.4).

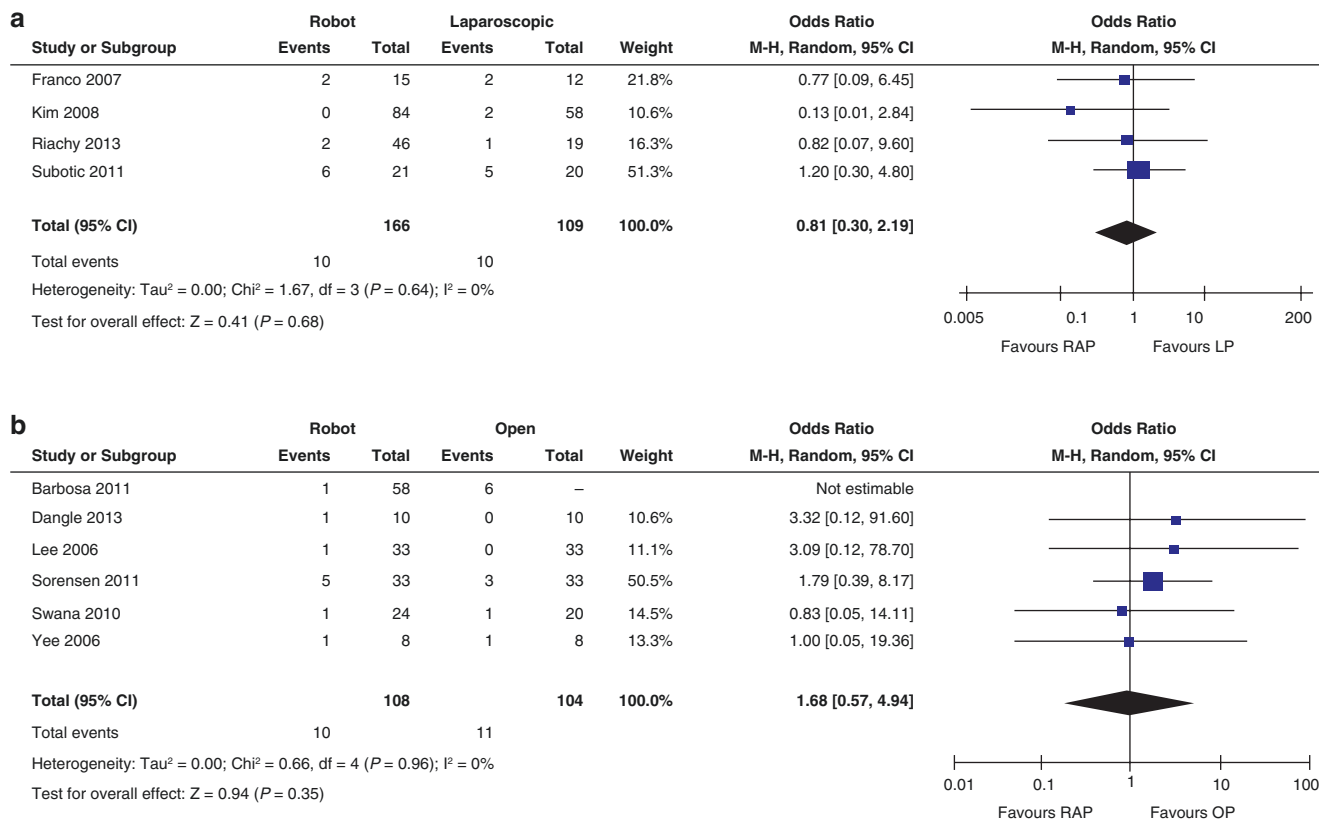


Fig. 6.3 Forest plot comparisons of Clavien Grade 1–5 postoperative complications for studies comparing RAP vs LP (a) and RAP vs OP (b)

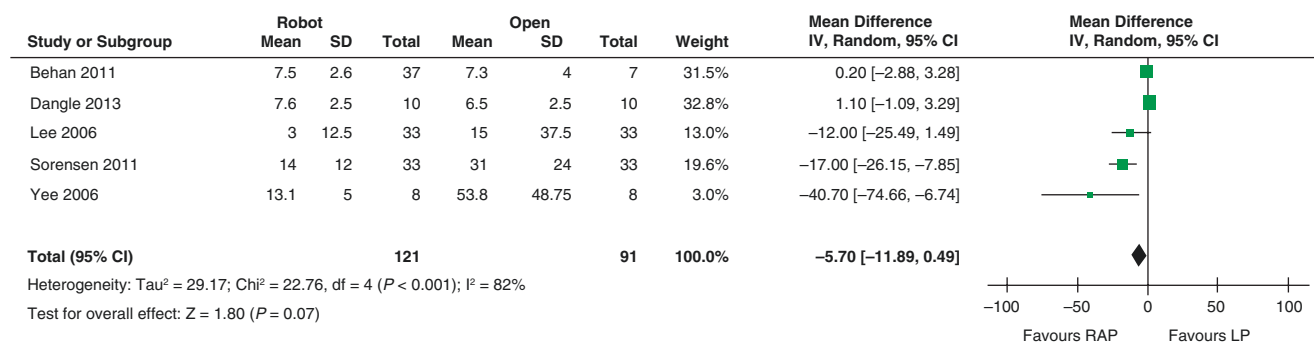


Fig. 6.4 Forest plot comparison of EBL for studies comparing RAP vs OP

Pooled analysis showed a significantly shorter overall LOS for RAP by almost one full day (Fig. 6.7b, WMD -0.75 days, 95 % CI -1.28 to -0.22 ; $P=0.005$).

Three studies reported OT for RAP vs LP. Overall, there was a 33 min shorter OT for RAP; however, this was not significant peripheral time for cystoscopy and patient re-positioning.

6.5 Conclusion

RLP has emerged as offering the advantages of conventional laparoscopy in terms of perioperative morbidity, but with a more rapid and efficient learning curve, with the potential for superior results based on the enhanced manipulation and visualization.

The main technical benefits of robot-assistance in minimally invasive surgery are consistently attributed towards the more demanding procedural steps, namely the ureteric spatulation, pelvis reduction, and uretero-pelvic anastomosis. The motion-scaled EndoWrist® instruments enable parallel alignment of scissors with the proximal ureter for more accurate and controlled linear spatulation. Similarly, the enhanced manual dexterity with these instruments and stereoscopic vision contribute to a lower degree of difficulty for the chal-

lenging task of intracorporeal suturing within small anatomical workspaces. Meta-analysis of the current literature identifies no significant differences between RAP and LP or OP for the five primary outcome variables assessed. Significant differences in favour of RAP were found for secondary outcome variables of EBL (vs OP) and LOS (vs LP and OP). OT was found to be significantly longer for RAP vs OP. Limited evidence from observational studies indicates lower opiate analgesia requirement for RAP (vs LP and OP), higher total costs for RAP vs OP, and comparable costs for RAP vs LP. Given the availability of multiple treatment options, treatment should be tailored to the individual case, which mainly depends on the anatomic conformation of UPJO as assessed pre- and intraoperatively. The adoption of robotic technology, with its precise suturing and shorter learning curve, represents an attractive option for performing minimally invasive surgery, and robotic pyeloplasty is likely to emerge as the new minimally invasive standard of care whenever this technology is available. For both laparoscopy and robotics, the technique can be modulated and tailored to the specific case according to intraoperative findings and personal surgical experience (Figs. 6.5, 6.6, 6.7, 6.8, 6.9, 6.10, 6.11, 6.12, 6.13, 6.14, 6.15, 6.16, 6.17, 6.18, 6.19, 6.20, 6.21, 6.22, 6.23, 6.24, 6.25, 6.26, 6.27, 6.28, 6.29, 6.30, 6.31, and 6.32).

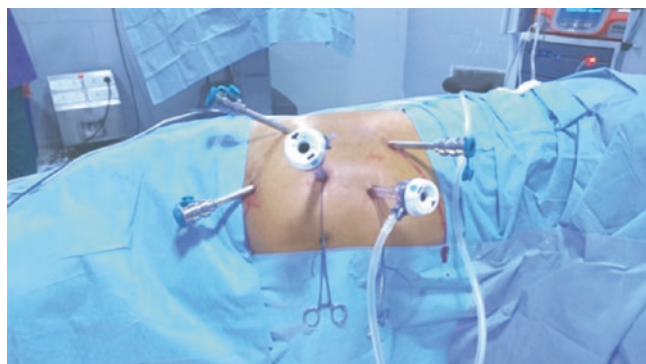

Fig. 6.5 Patient and Ports position for right side Pyeloplasty

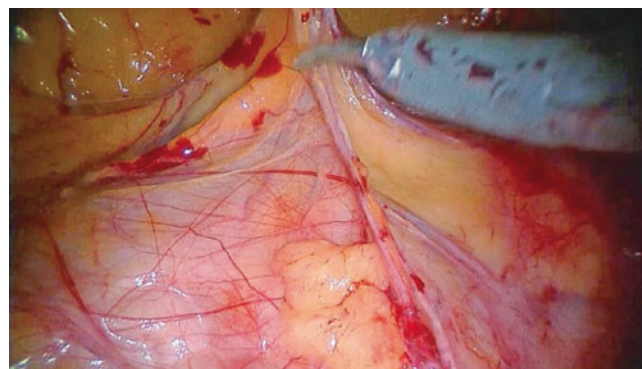


Fig. 6.6 Right colon reflected and pelvis minimally exposed

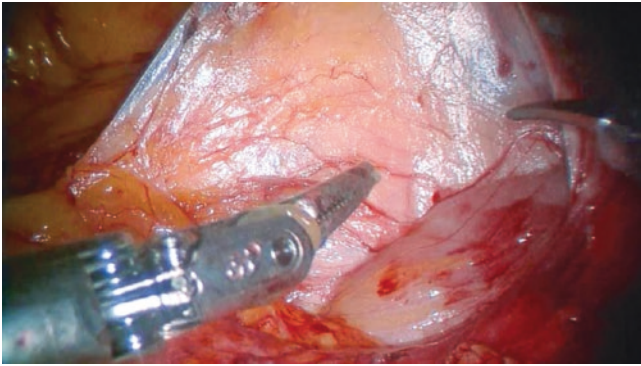


Fig. 6.7 Duodenum being kockerised

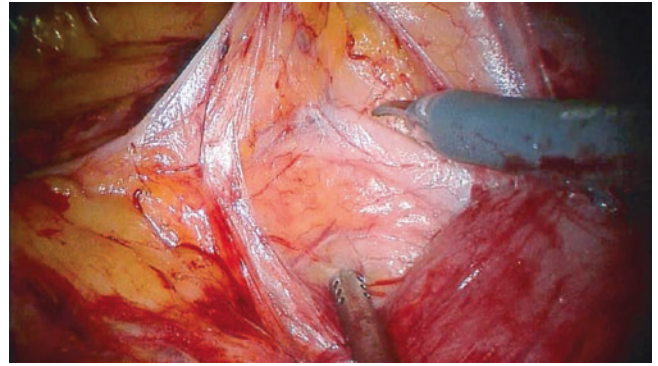


Fig. 6.8 Gonadal vein seen

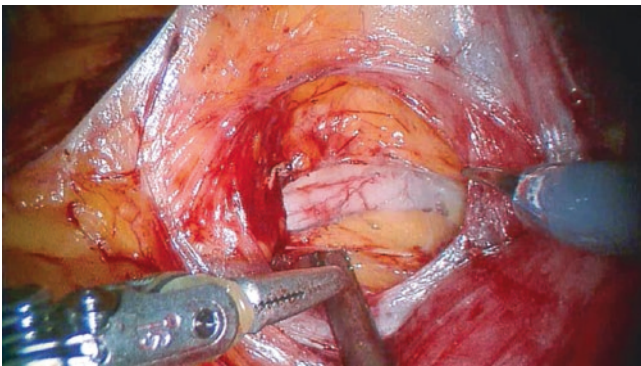


Fig. 6.9 Ureter identified

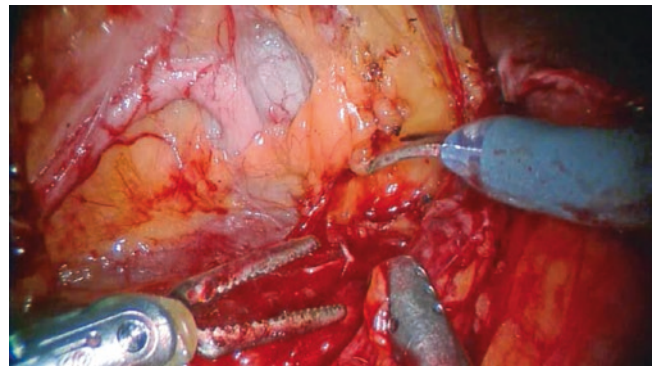


Fig. 6.10 Ureter traced proximally till pelvis

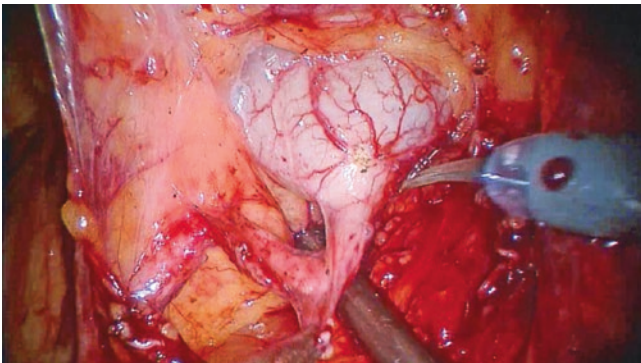


Fig. 6.11 Pelvis dissected and pelvi ureteric junction delineated

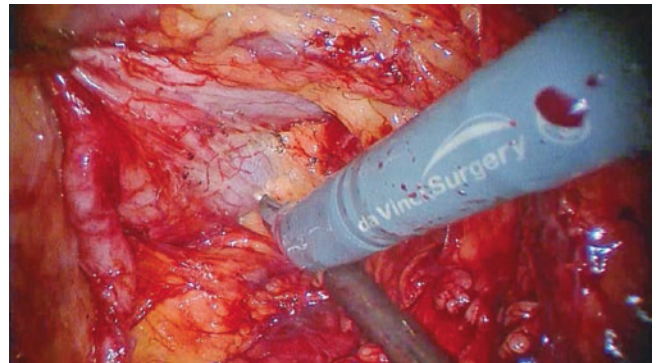


Fig. 6.12 Pelvis mobilised all around

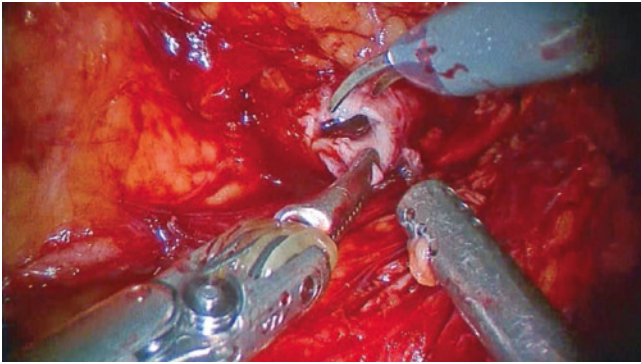


Fig. 6.13 Oblique pyelotomy started

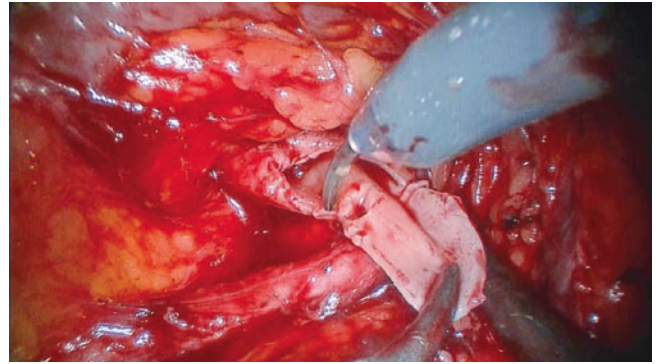


Fig. 6.14 Pyelotomy continued

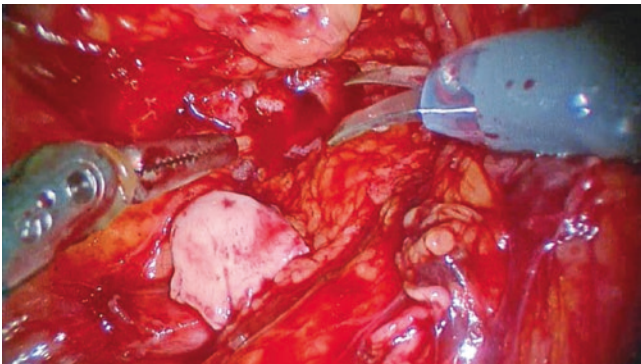


Fig. 6.15 Pelvis dismembered

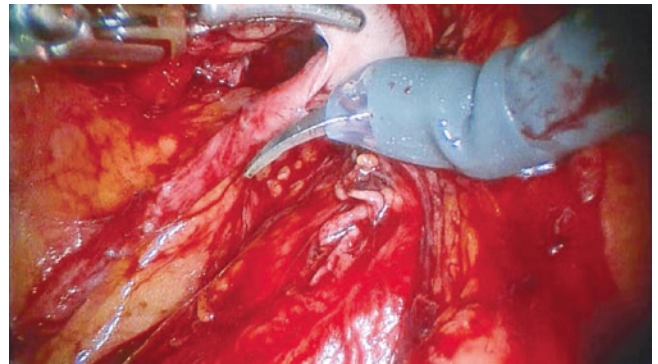


Fig. 6.16 Lateral spatulation of ureter

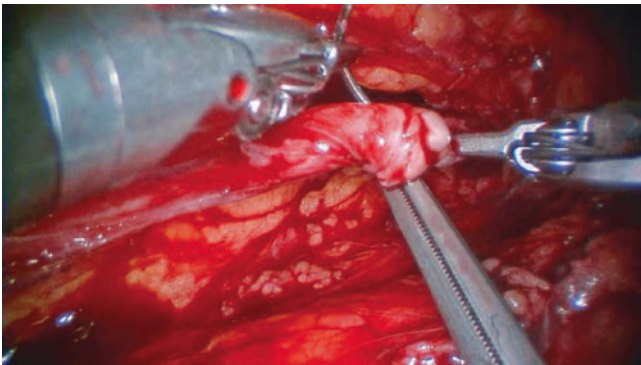


Fig. 6.17 Initial apical suture through spatulated ureter using 4-0 PDS suture

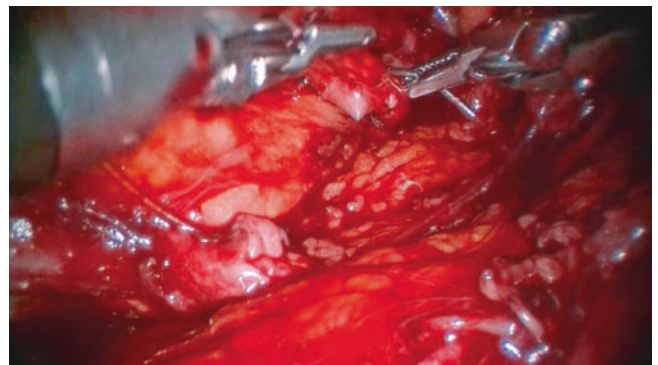


Fig. 6.18 Corresponding suture through the inferolateral aspect of pelvis

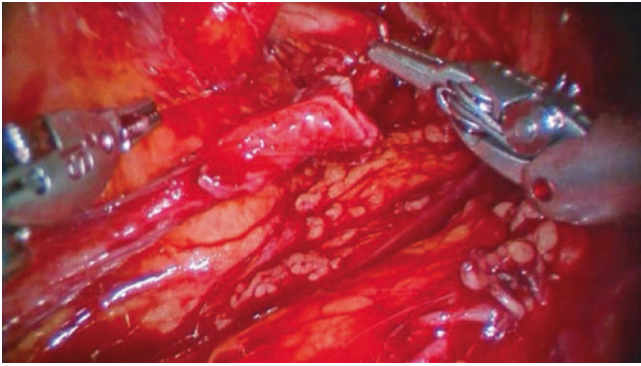


Fig. 6.19 Apical suture in place

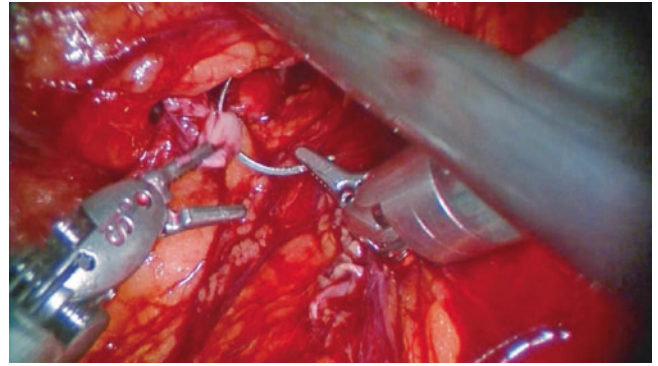


Fig. 6.20 Continuous suture of posterior layer

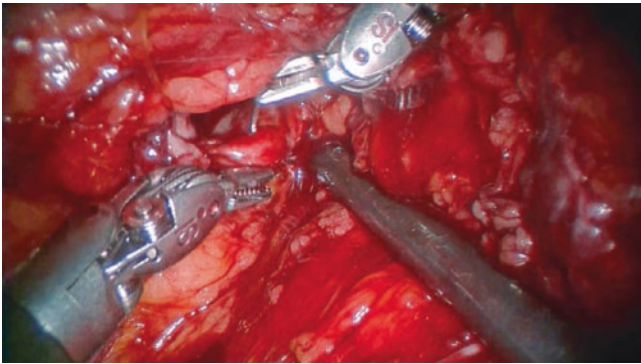


Fig. 6.21 Posterior layer suturing in progress

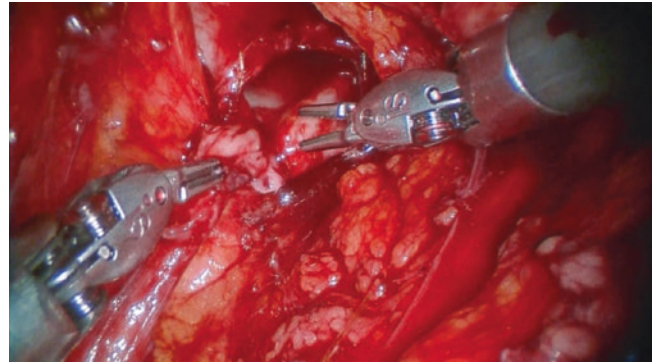


Fig. 6.22 Posterior layer completed

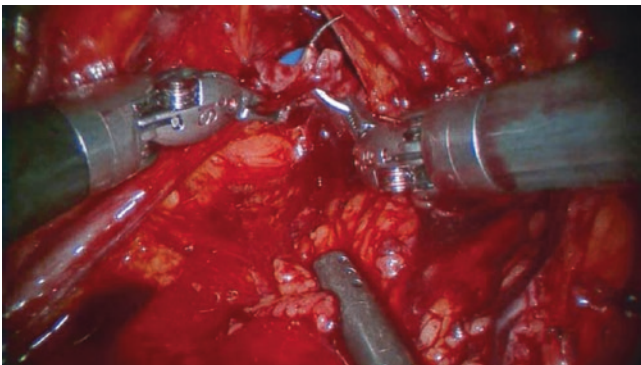


Fig. 6.23 Antegrade stenting

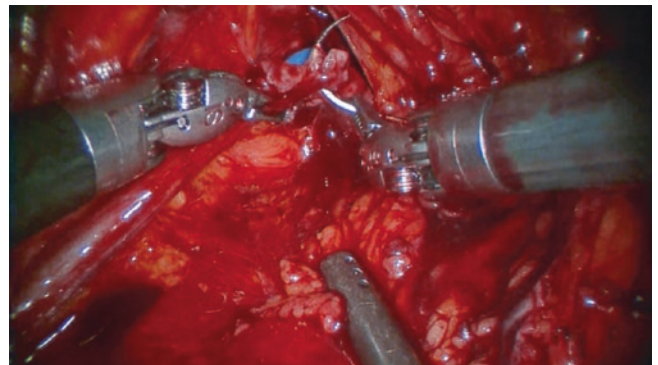


Fig. 6.24 Continuous suture in progress

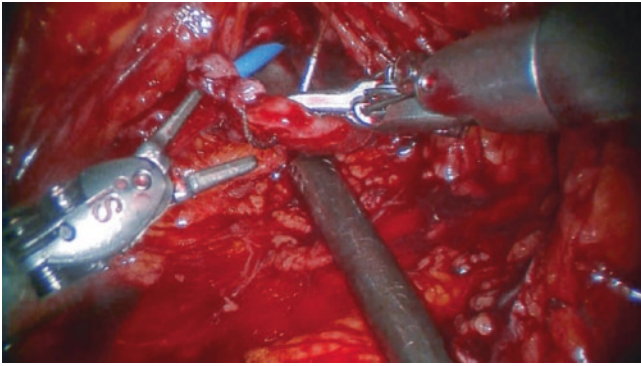


Fig. 6.25 Continuous suture in progress

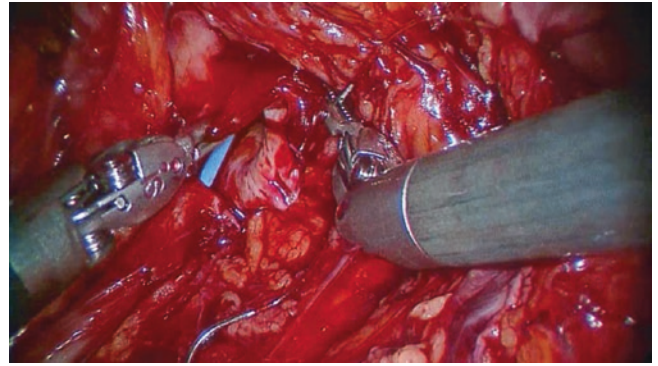


Fig. 6.26 Pyelotomy closure started proximally

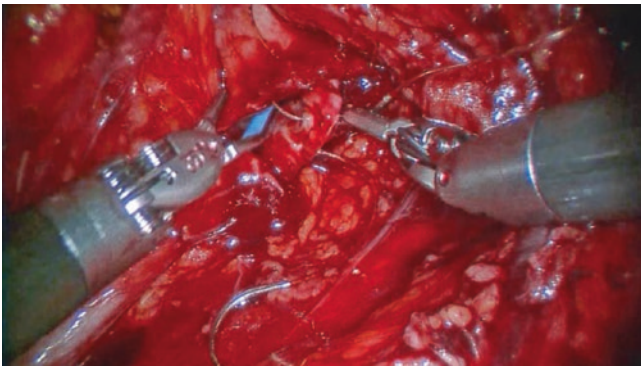


Fig. 6.27 Pelvis closure in progress

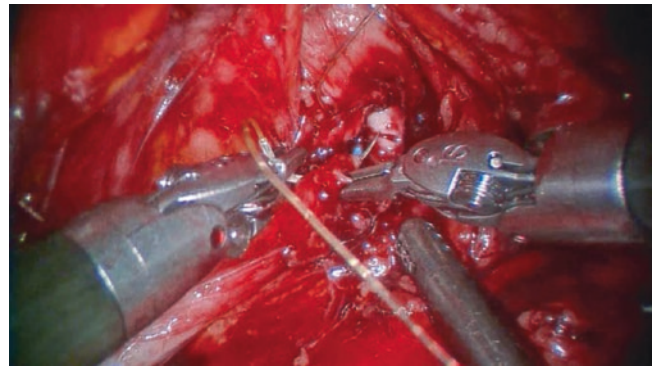


Fig. 6.28 Ureter being sutured to pelvis anteriorly

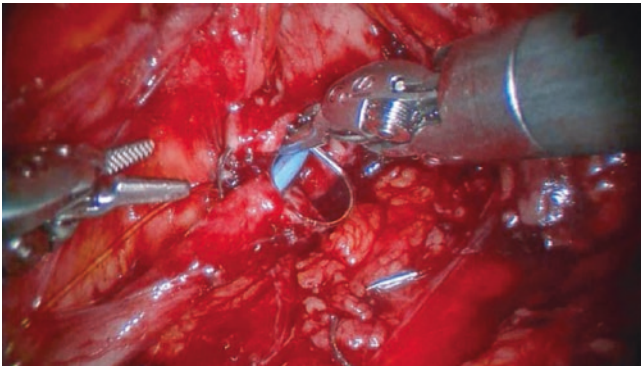


Fig. 6.29 Anterior layer suturing continued

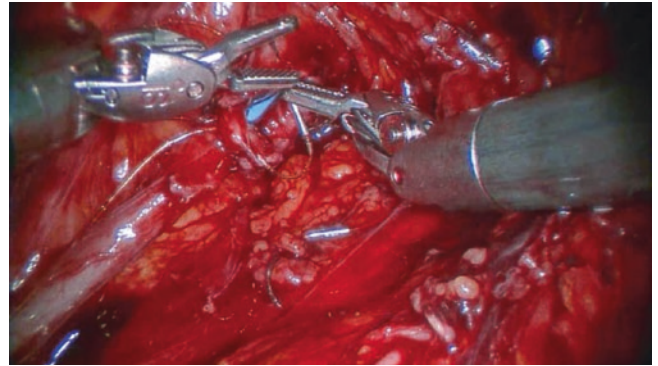


Fig. 6.30 Anterior layer suturing in progress

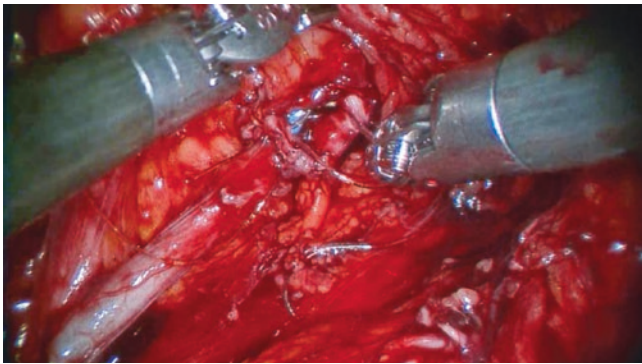


Fig. 6.31 Anterior layer suturing in progress

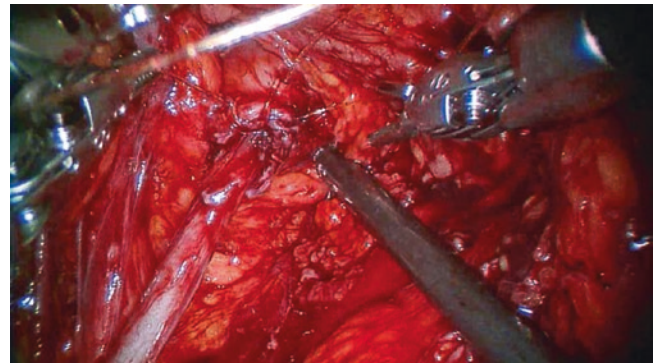


Fig. 6.32 Final anterior layer suture completed

References

1. Schuessler WW, Grune MT, Tecuanhuey LV, Preminger GM. Laparoscopic dismembered pyeloplasty. *J Urol.* 1993;150(6):1795–99.
2. Bauer JJ, Bishoff JT, Moore RG, Chen RN, Iverson AJ, Kavoussi LR. Laparoscopic versus open pyeloplasty: assessment of objective and subjective outcome. *J Urol.* 1999;162(3):692–95.
3. Cundy TP, Shetty K, Clark J et al. The first decade of robotic surgery in children. *J Pediatr Surg.* 2013;48:858–65.
4. Monn MF, Bahler CD, Schneider EB et al. Trends in robot-assisted laparoscopic pyeloplasty in pediatric patients. *Urology.* 2013;81:1336–41.
5. Kutikov A, Resnick M, Casale P. Laparoscopic pyeloplasty in the infant younger than 6 months—is it technically possible? *J Urol.* 2006;175:1477–79.
6. Bansal D, Cost NG, Bean CM, et al. Infant robot assisted laparoscopic upper urinary tract reconstructive surgery. *J Pediatr Urol.* 2014;10(5):869–74.
7. Bansal D, Cost NG, DeFoor WR Jr, et al. Infant robotic pyeloplasty: comparison with an open cohort. *J Pediatr Urol.* 2014;10:380–5.
8. Cundy TP, Harling L, Hughes-Hallett A et al. Meta-analysis of robot assisted vs conventional laparoscopic and open pyeloplasty in children. *BJU Int.* 2014;114(4):582–94.

Manickam Ramalingam, K. Selvarajan, Kallappan Senthil,
G. Rajamani, and R.T. Dharmendra

7.1 Introduction

Historically, majority of the duplication anomalies of the ureter go unnoticed as clinical manifestations of such anomalies are uncommon. Incomplete duplication of ureter with lower moiety ureteropelvic junction obstruction is quite rare. These patients present with recurrent loin pain and urinary tract infection. In cases of complete duplication, urinary tract infection may be the presenting feature [1–4]. Each patient requires individualised treatment. Management depends on several factors including the functional status of the portion of the kidney.

Laparoscopic ureteropyelostomy is a preferable option than open surgery.

70-degree tilt for the transperitoneal approach. Four ports are used, as shown in the picture. A 10 mm supra umbilical camera port, 5 mm ports in the subcostal area and right iliac fossa for hand instruments and another 5 mm flank port are inserted. Colon is reflected and retroperitoneal space dissected to identify the duplicated ureter and Y junction. The dilated pelvis of lower moiety is dissected all around. Pelvis is incised in the middle and the ureter segment till the Y junction is excised. Upper moiety ureter opposing the pyelotomy is vertically incised on the lateral aspect. Posterior layer is sutured first using 4–0 vicryl or Polydioxanon. If there is a preplaced stent, it is repositioned into upper moiety. Then anterior layer suturing is completed. If there is no preplaced stent, it can be placed antegrade.

7.2 Operative Technique

7.2.1 Ureteropyelostomy for Incomplete Duplication with Lower Moiety UPJ Obstruction

Procedure starts with retrograde pyelography under general anesthesia. Double J stent may be placed retrograde or later (antegrade). Patient is placed in right lateral position with

7.2.2 Ureteropyelostomy for Complete Duplex System

After the initial steps as described previously, the ureter which needs to be excised is dissected till the bladder or as low as possible and divided. Refluxing ureters need complete excision to prevent stump syndrome. Ectopic ureters may be divided as low as possible and the distal end laid open to prevent collection of secretions. The rest of the steps are similar.

M. Ramalingam (✉)
PSG Hospitals,
Coimbatore, India
e-mail: uroram@yahoo.com

K. Selvarajan
Paediatric Surgery, K.G. Hospital and Postgraduate Institute,
Coimbatore, India

K. Senthil
Urology Clinic, Gowtham Annexe, Coimbatore, India
e-mail: senthilsatya@hotmail.com

G. Rajamani • R.T. Dharmendra
Department of Pediatric Surgery, Coimbatore Medical College,
Coimbatore, India

7.3 Discussion

Duplication of ureter though common, may not be symptomatic. Management depends on the function of the affected moiety and whether the affected ureter is obstructed or refluxing. In incomplete duplication of ureter with a functioning moiety and ureteropelvic junction obstruction, ureteropyelostomy is the treatment of choice. In a nonfunctioning moiety heminephrectomy is done. In the presence of reflux in a completely duplicated system there are two options, ureteropyelostomy or single sheath reimplantation.

All the principles of open reconstructive surgery can be meticulously followed in laparoscopic surgery. Laparoscopic ureteropyelostomy is technically feasible, completely replicating the open technique, with minimal morbidity.

7.4 Conclusion

Though such laparoscopic reconstructive procedures are challenging, it is feasible as one gains confidence in intracorporeal suturing.

7.5 Laparoscopic Ureteropyelostomy in Complete Duplication

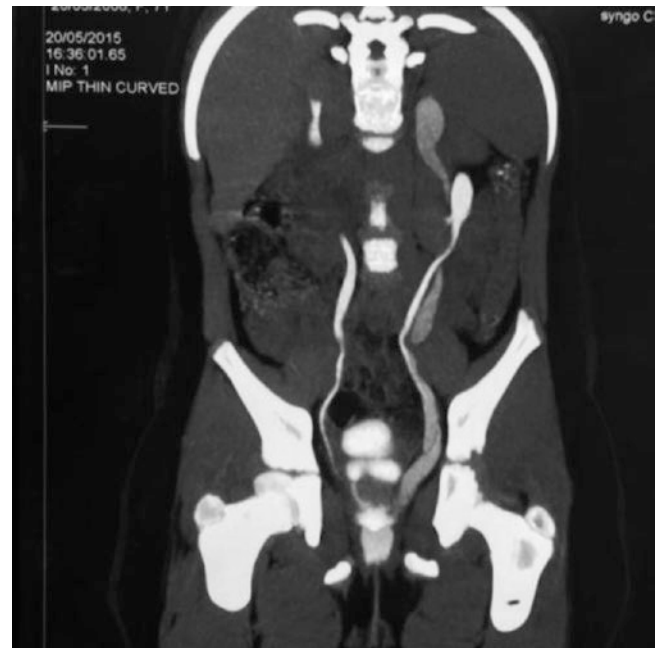

Fig. 7.1 CT Scan showing complete duplication on the left side

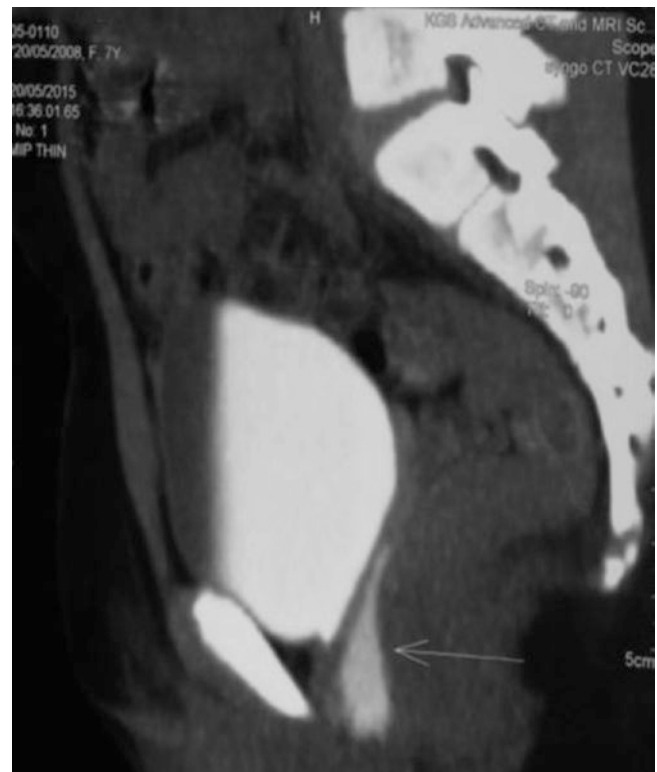


Fig. 7.2 CT scan showing ectopic upper moiety ureter ending in vagina

Fig. 7.3 Cystoscopy showing normally located lower moiety ureteric orifice on left side

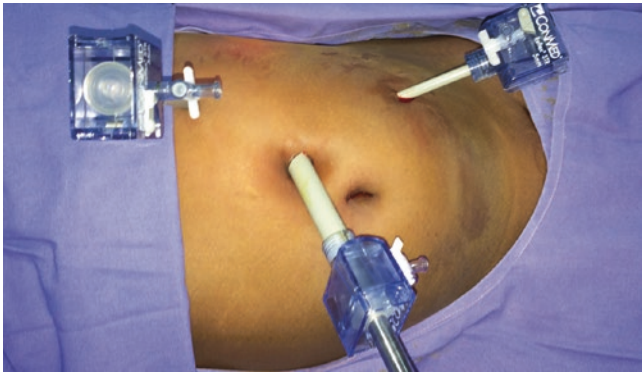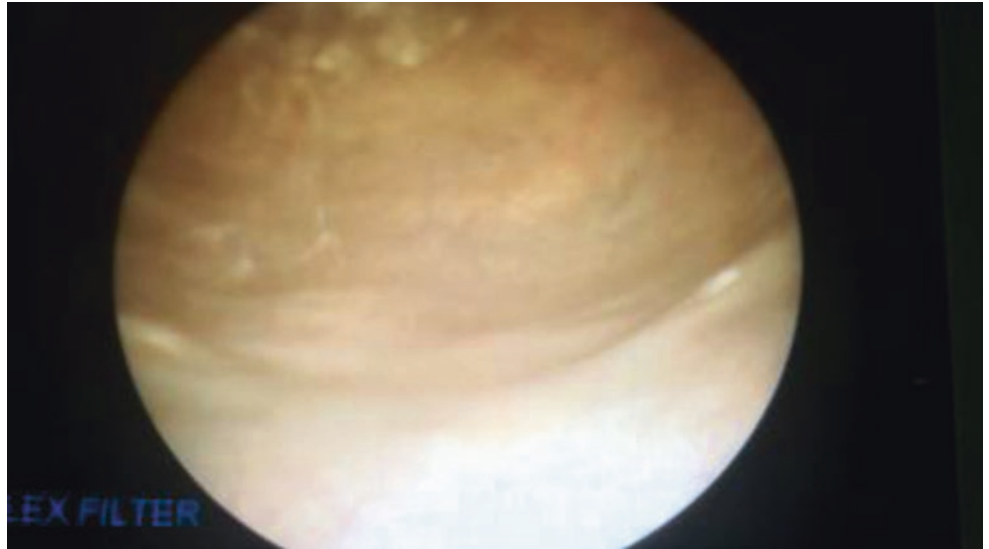


Fig. 7.4 Ports position

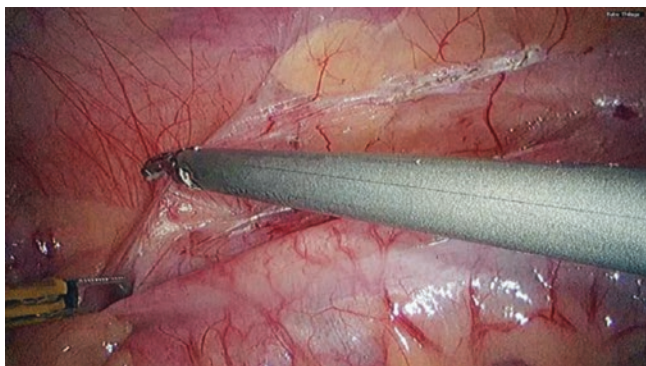


Fig. 7.5 Left colonic reflection in progress

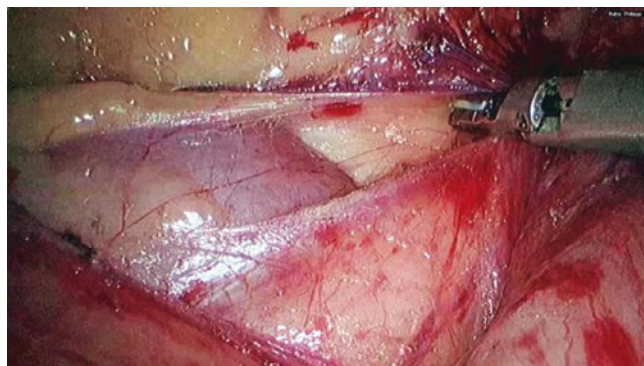


Fig. 7.6 Kidney parenchyma seen after colonic reflection

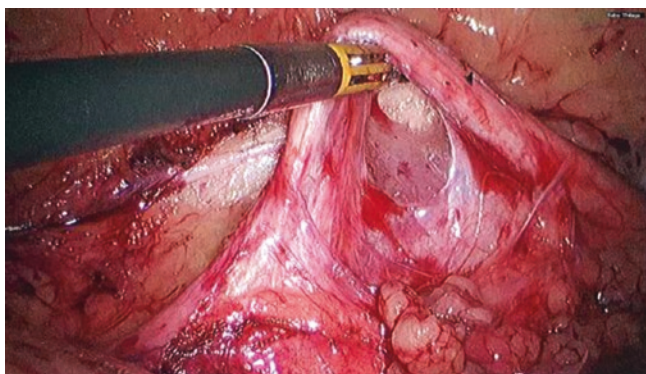


Fig. 7.7 Both ureters lifted up

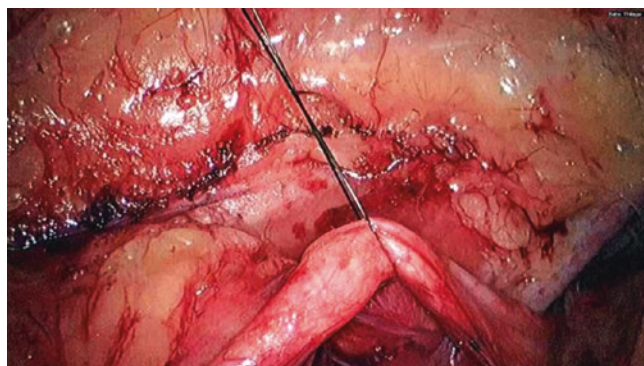


Fig. 7.8 Ureters hinged to the abdominal wall with nylon suture

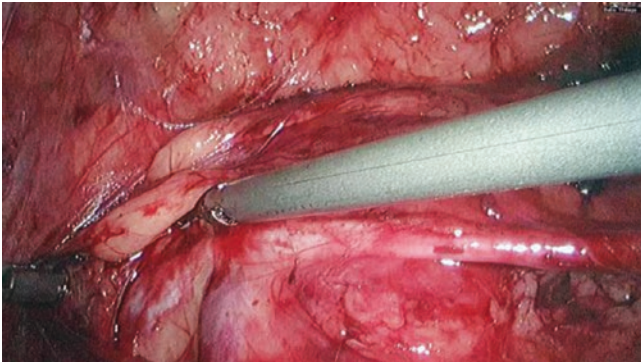


Fig. 7.9 Upper moiety ureter seen crossing over the renal vein to the upper moiety

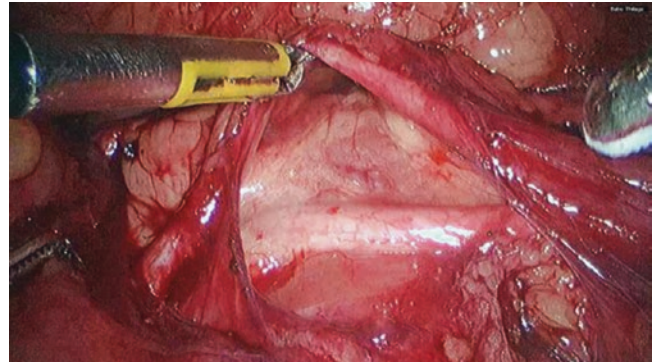


Fig. 7.10 Upper moiety ureter separated from lower moiety ureter

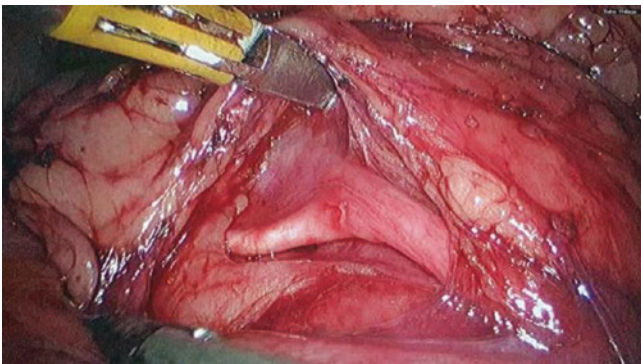


Fig. 7.11 Lower moiety pelvis seen

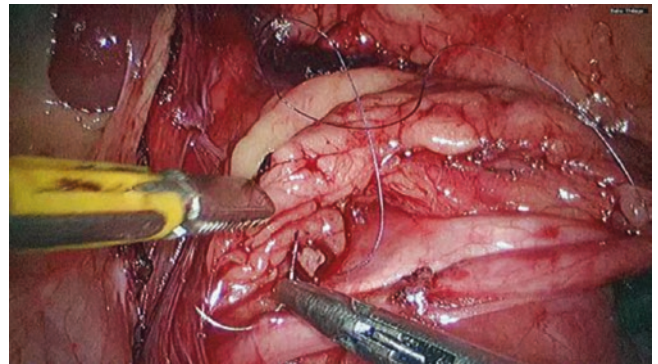


Fig. 7.12 Lower moiety pelvis being fixed to upper moiety ureter for alignment

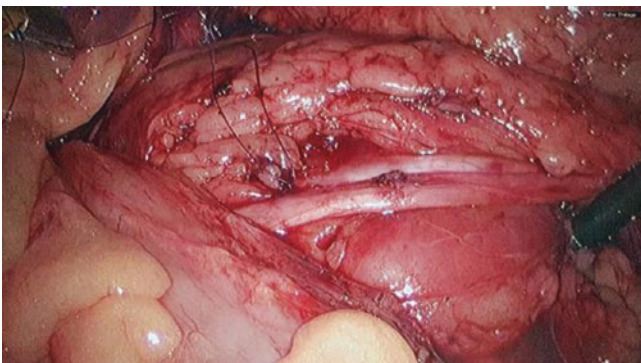


Fig. 7.13 Lower moiety pelvis aligned to upper moiety ureter

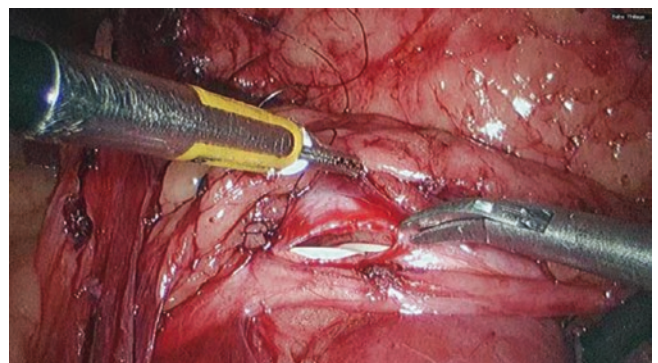


Fig. 7.14 Pyelotomy of lower moiety. Preplaced stent seen

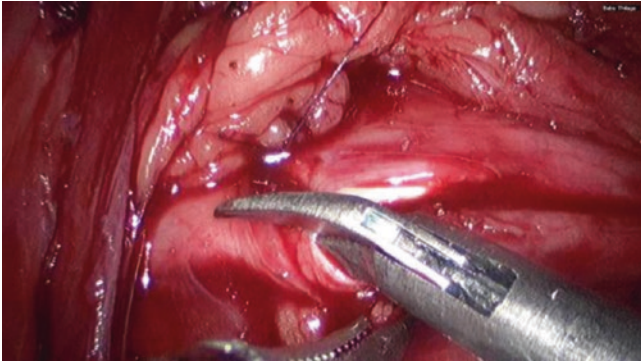


Fig. 7.15 Ureterotomy of upper moiety in alignment with pyelotomy of the lower moiety

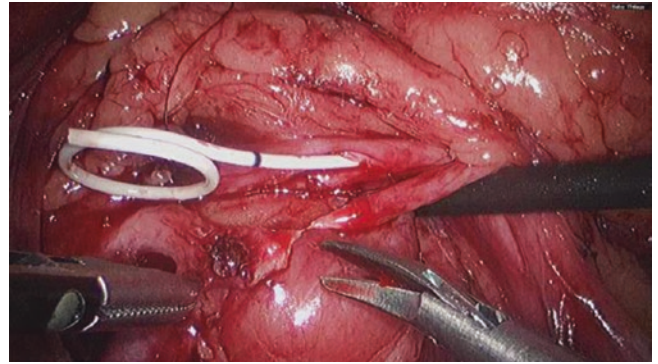


Fig. 7.16 Upper moiety ureter divided at the level of caudal end of pyelotomy of lower moiety

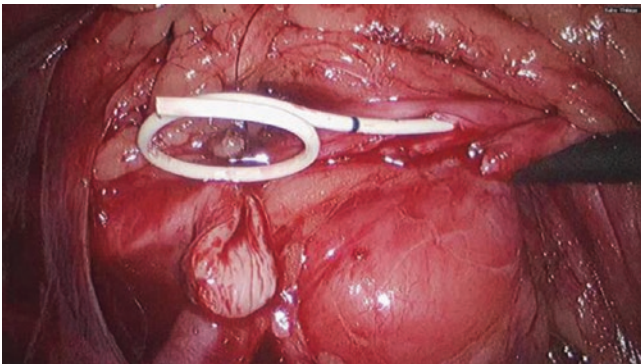


Fig. 7.17 Spatulated upper moiety ureter

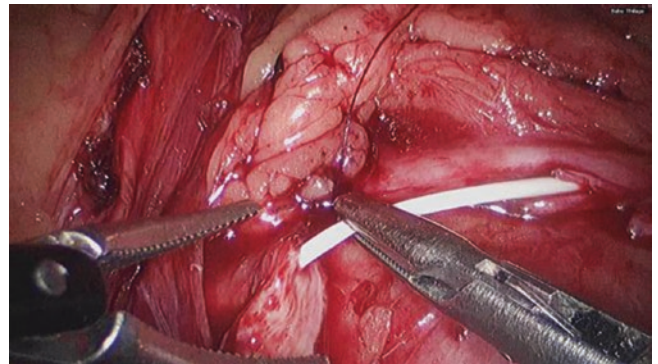


Fig. 7.18 Stent being repositioned into upper moiety

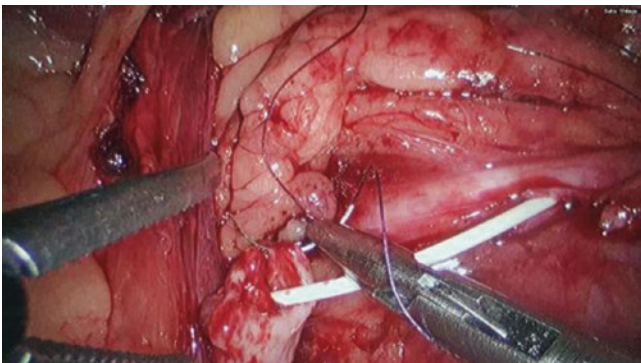


Fig. 7.19 Suturing started with 4-0 vicryl outside-in through ureter

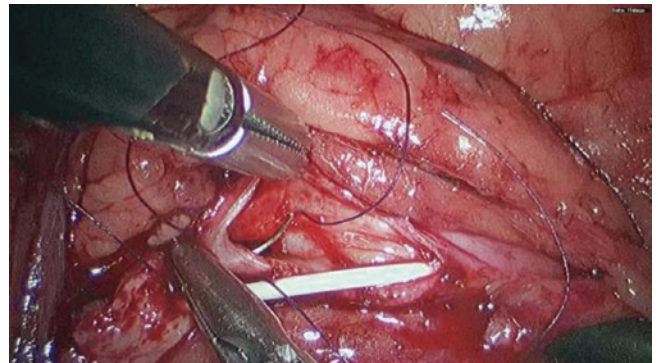


Fig. 7.20 Corresponding suture inside out of pyelotomy – apical bite

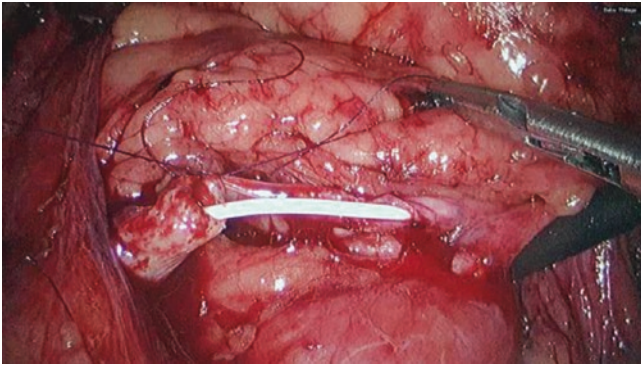


Fig. 7.21 Apical suture in place

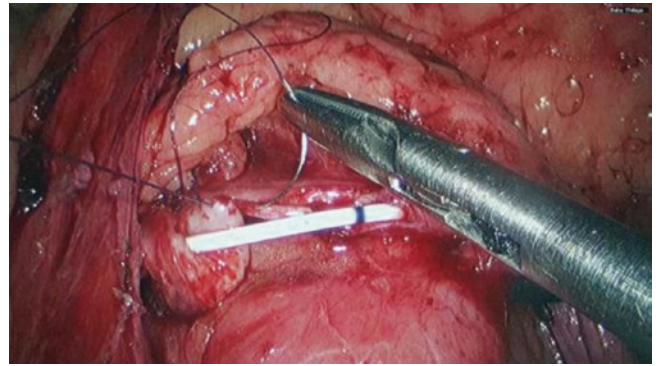


Fig. 7.22 Posterior layer suturing in progress

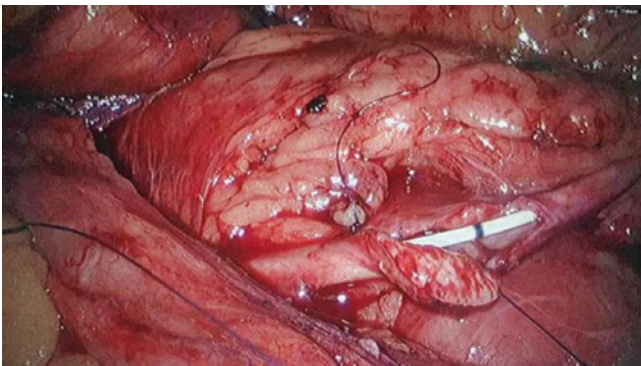


Fig. 7.23 Posterior layer suturing in progress

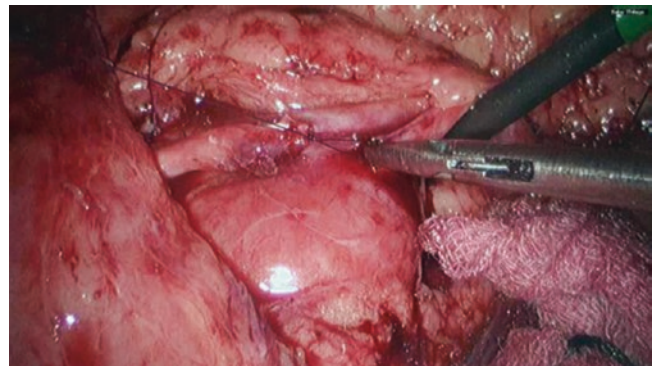


Fig. 7.24 Posterior layer completed

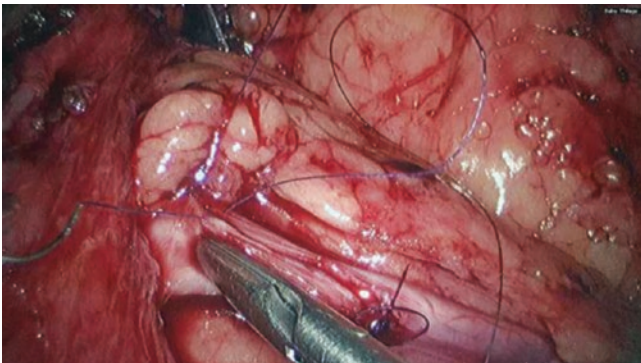


Fig. 7.25 Anterior layer suturing started

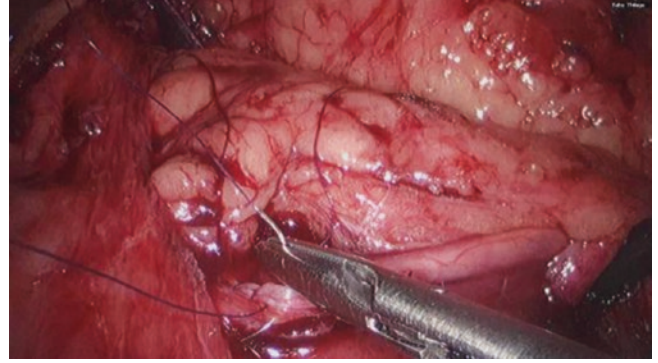


Fig. 7.26 Anterior layer suturing in progress

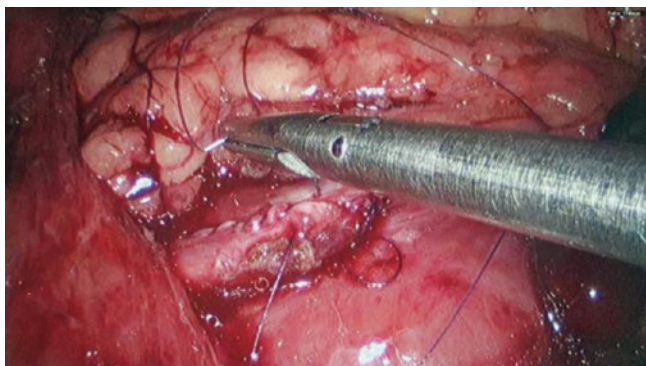


Fig. 7.27 Anterior layer in progress

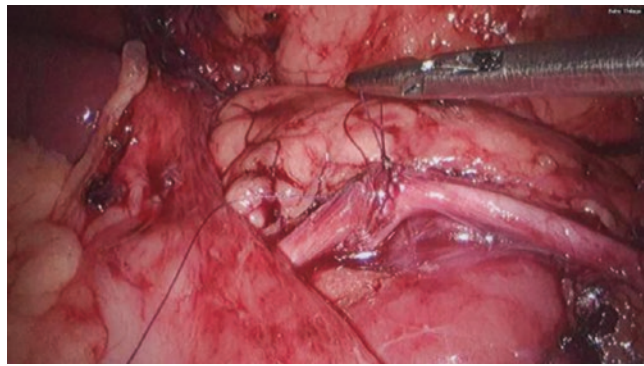


Fig. 7.28 Anterior layer completed

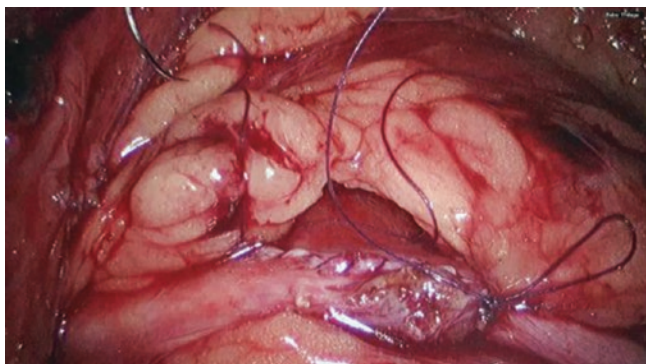


Fig. 7.29 Completed anastomosis

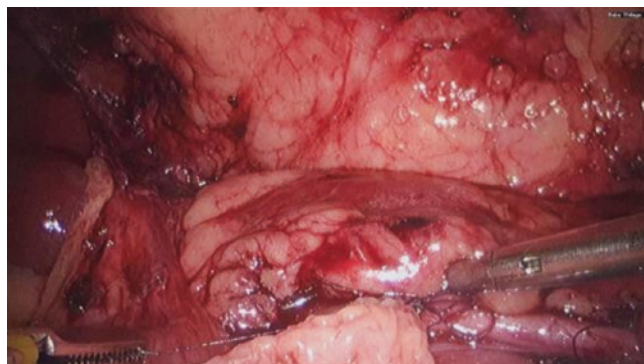


Fig. 7.30 Omental cover for anastomosis

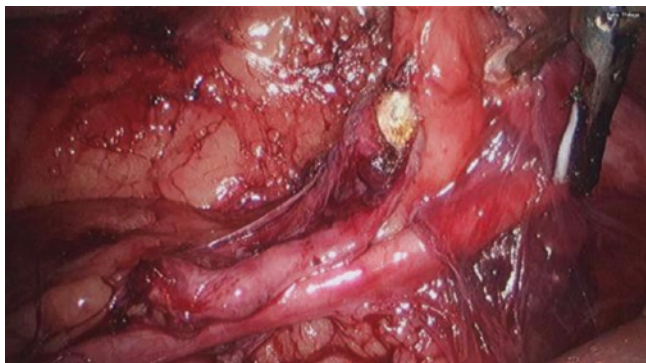


Fig. 7.31 Segment of upper moiety ureter divided and to be excised

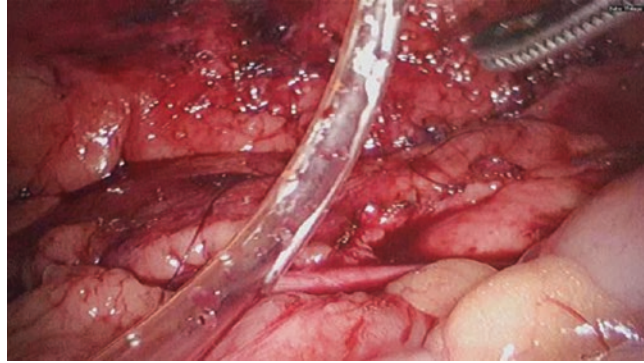
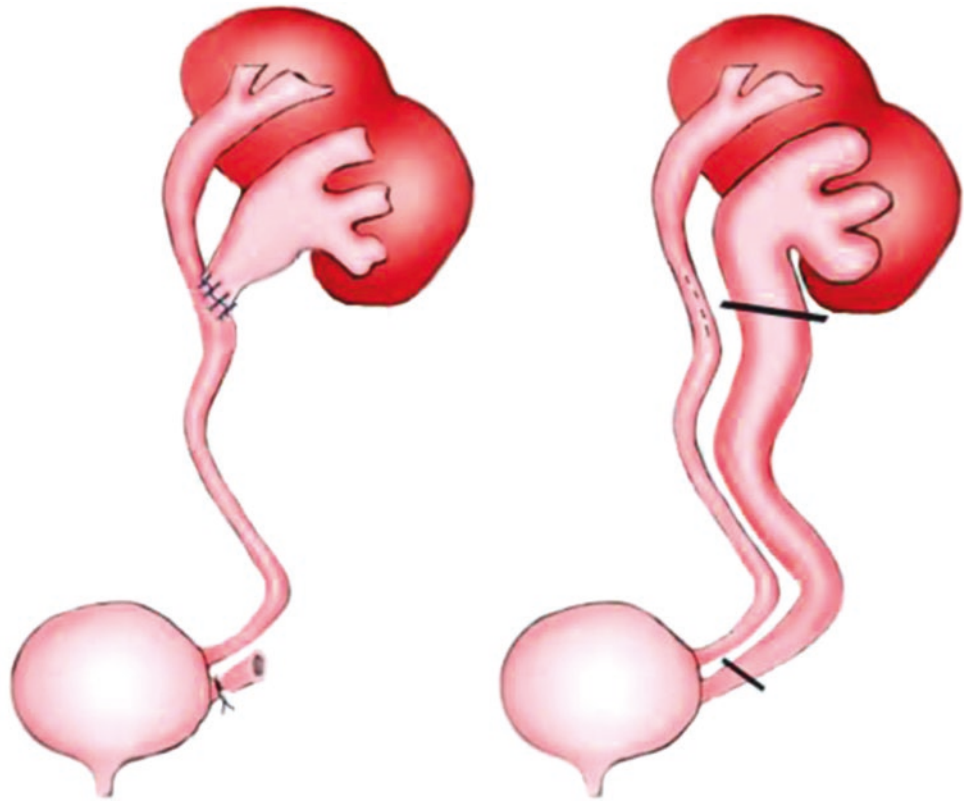


Fig. 7.32 Drain placed

Fig. 7.33 Diagrammatic representation of the procedure



References

1. Amis ES, Cronan JJ, Pfister RD. Lower moiety hydronephrosis in duplicated kidney. *Urology*. 1985;26:82.
2. Belman AB, Filmer RB, King LR. Surgical management of duplication of the collecting system. *J Urol*. 1974;112:316.
3. Caldamone AA. Duplication anomalies of the upper urinary tract in infants and children. *Urol Clin of N Am*. 1985;12:75.
4. Ramalingam M, Selvarajan K, Senthil K, Pai MG. Laparoscopic pyeloureterostomy: experience in three cases. *J Endouro*. 2006;20(2):115–8.

Manickam Ramalingam, Kallappan Senthil,
Mizar G. Pai, and Anandan Murugesan

8.1 Introduction

UPJ narrowing with an intrarenal pelvis and grossly dilated calices is a challenging problem especially in failed pyeloplasty. Uretero calicostomy is a good option in the above situation [1–3].

Newer hemostatic technologies allow better visibility and less blood loss during renal parenchymal transection, and with experience in laparoscopic suturing techniques laparoscopic ureterocalicostomy can be performed safely and effectively.

8.2 Surgical Technique

Preliminary retrograde pyelogram is done. Port position is as described in the figure. Ten millimeter primary camera port is inserted above and lateral to the umbilicus. Two 5 mm ports are inserted in the subcostal region and iliac fossa. The proximal ureter is dissected free of surrounding

structures as far proximally as possible towards the renal hilum to see if pyeloplasty is feasible. UPJ is ligated and stenotic ureter excised. The cut end of the ureter is spatulated for 1 cm. The segment of the calyx which need to be anastomosed to the ureter is identified and a button hole calicotomy is done. The posterior layer interrupted suture is completed first followed by stenting and suturing of anterior layer. Perirenal fat or omentum is tacked around the anastomotic area. Tube drain is introduced through the flank port.

8.3 Comment

Clinical application of laparoscopic ureterocalicostomy will allow patients to enjoy the benefits of a minimally invasive approach, where standard laparoscopic pyeloplasty is not technically feasible. It is a viable alternate to very major procedures like ileal ureter which has its own inherent problems.

M. Ramalingam (✉)
PSG Hospitals,
Coimbatore, India
e-mail: uroram@yahoo.com

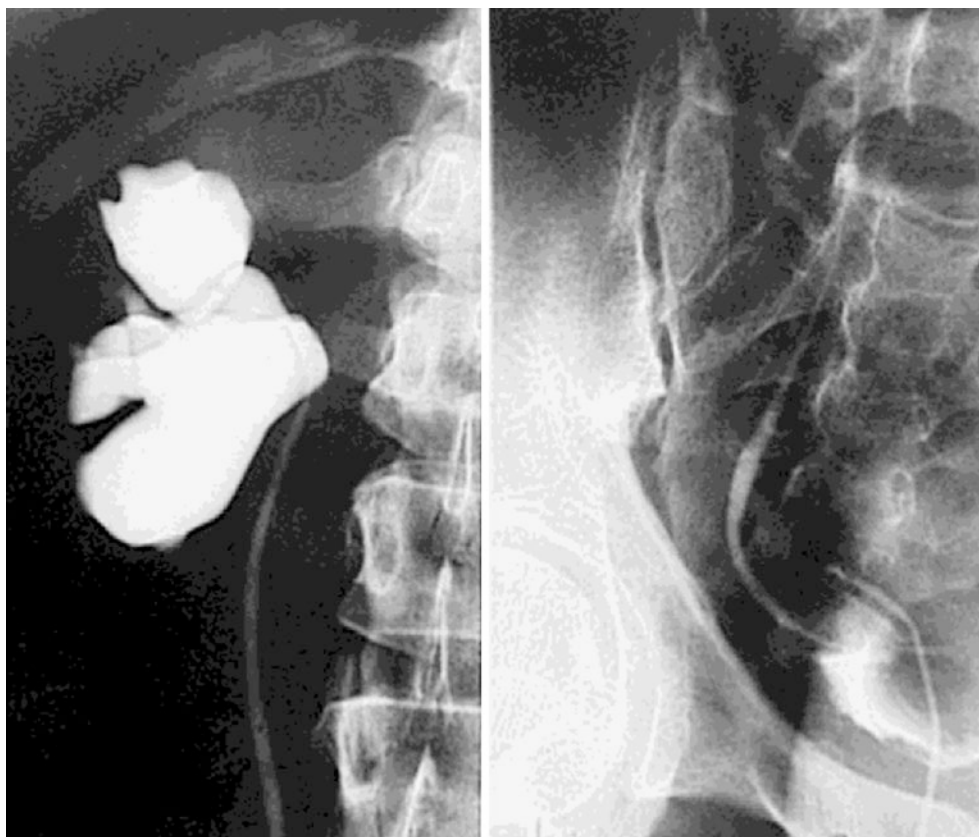
K. Senthil
Urology Clinic, Gowtham Annexe, Coimbatore, India
e-mail: senthilsatya@hotmail.com

M.G. Pai
Urology Clinic,
3/1054, Gowtham Annexe, Avinashi Road,
Coimbatore 641018, India
e-mail: mizargpai@yahoo.co.in

A. Murugesan
Department of Urology, PSG Institute of Medical Sciences and
Research, Peelamedu, Coimbatore, Tamil Nadu, India
e-mail: anandan79@gmail.com

8.4 Laparoscopic Ureterocalicostomy

Fig. 8.1 Right RGP showing grossly dilated calyx with scarred pelvis



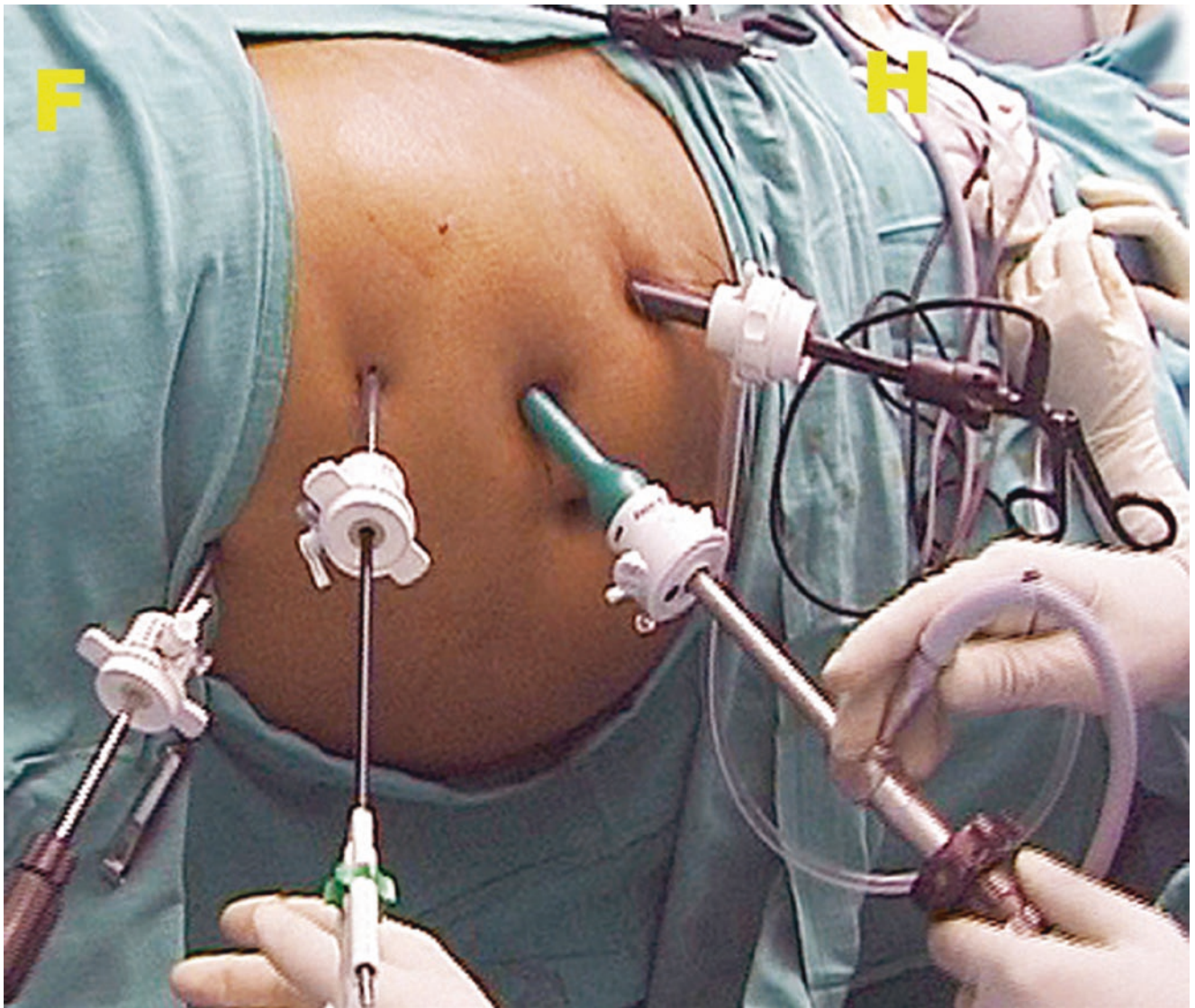


Fig. 8.2 Port position for uretero calicostomy

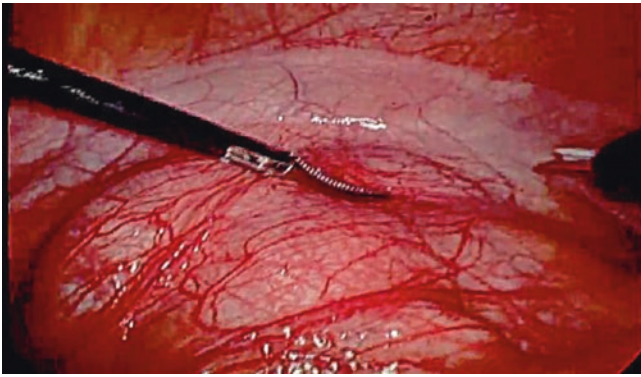


Fig. 8.3 Initial view of the right renal area showing the bulging kidney

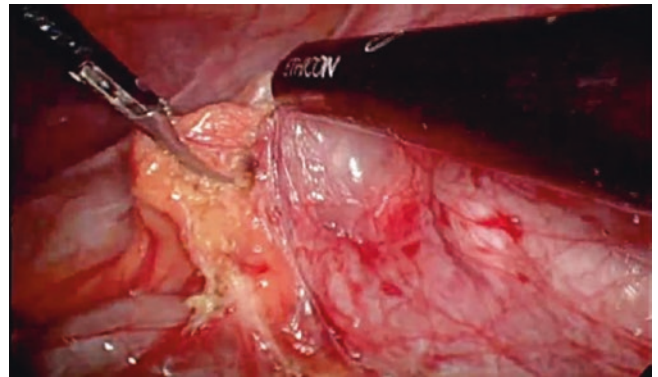


Fig. 8.4 Right Colon being reflected medially

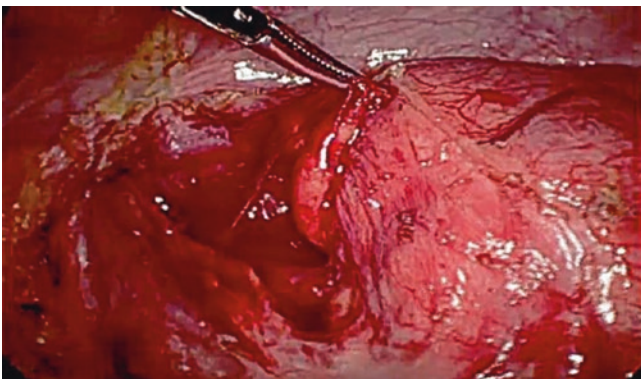


Fig. 8.5 Lower pole of the kidney dissected and freed all around

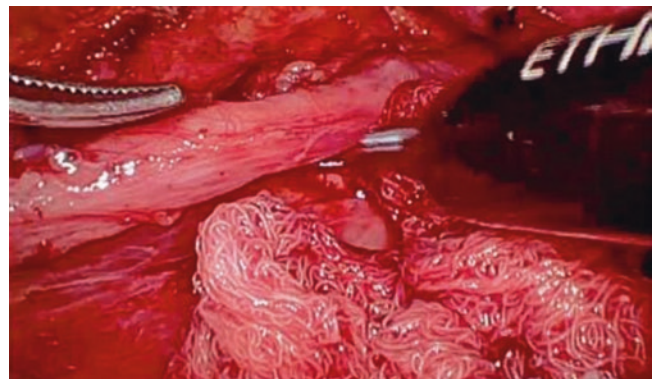


Fig. 8.6 Upper ureter being mobilised

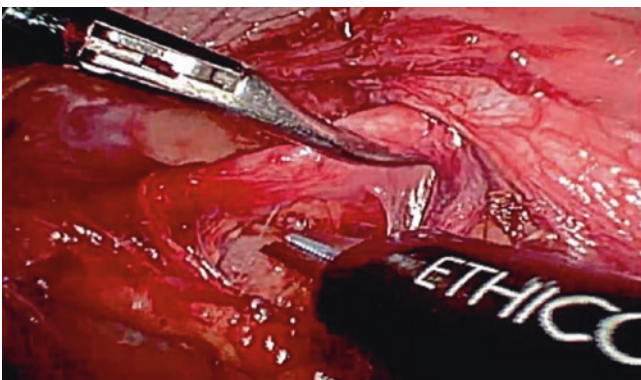


Fig. 8.7 Ureter traced proximally till the scarred intra renal pelvis

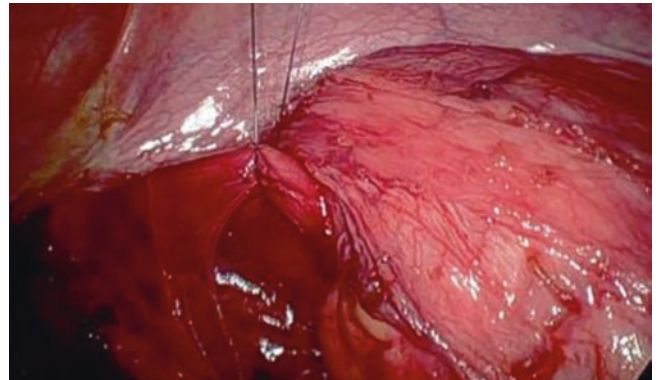


Fig. 8.8 Ureter hinged to abdominal wall

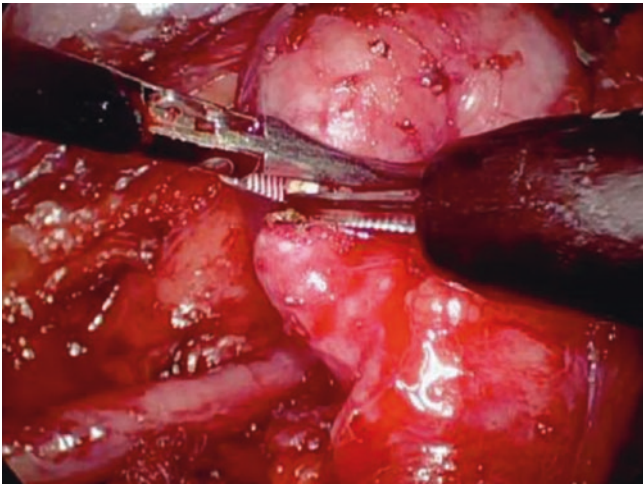


Fig. 8.9 Incision of lower calyx parallel to ureter

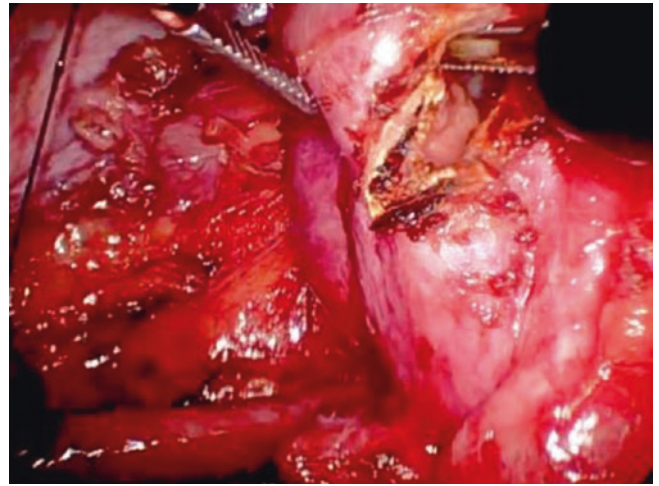


Fig. 8.10 Completed calycotomy of lower calyx

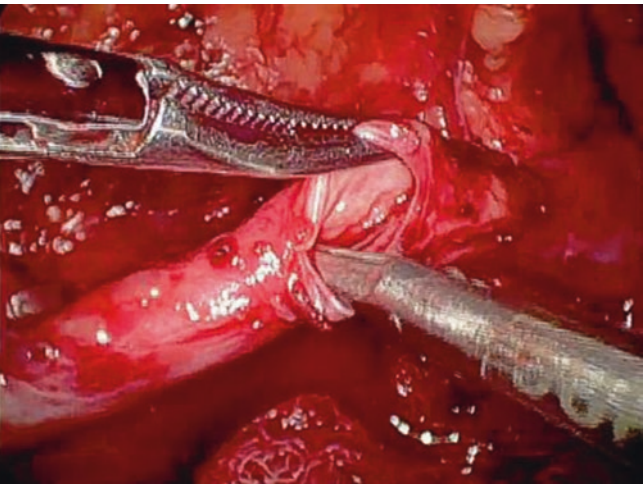


Fig. 8.11 Ureter incised vertically opposing the region of calicotomy

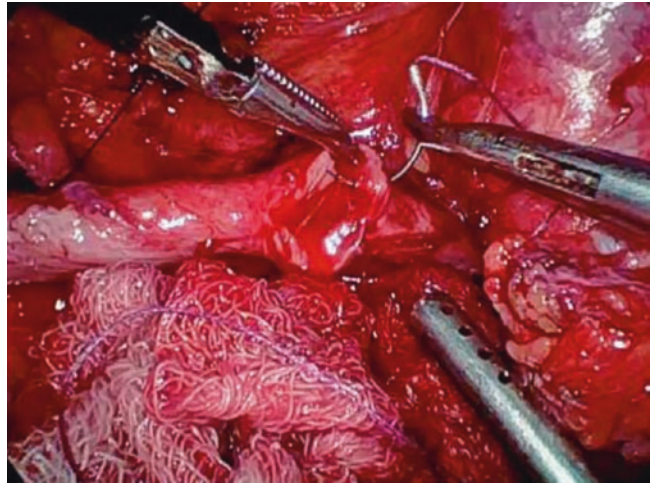


Fig. 8.12 Apical suture taken in the cranial end of ureterotomy with 4-0 vicryl

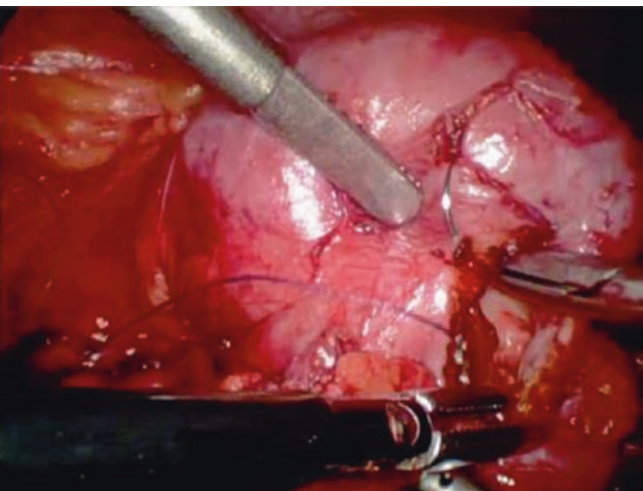


Fig. 8.13 Corresponding suture in the calicotomy

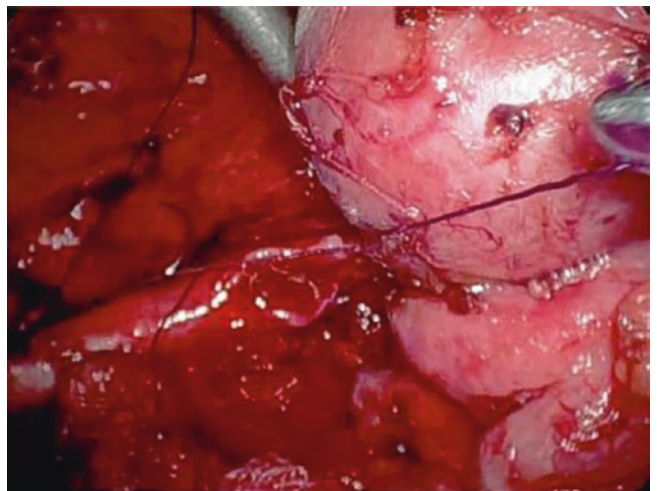


Fig. 8.14 Initial suture in place

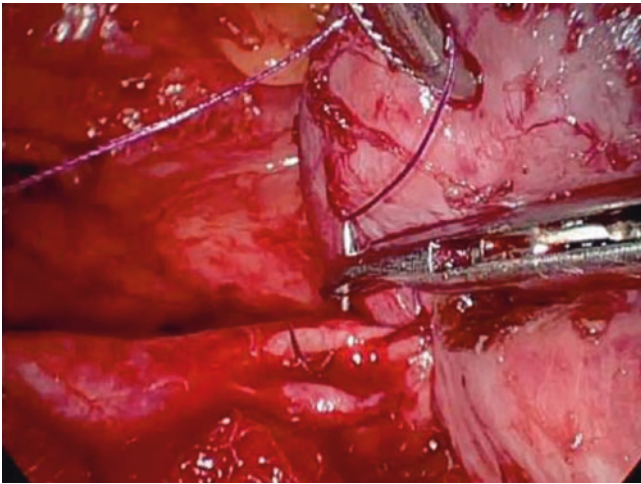


Fig. 8.15 Anterior layer suturing in progress

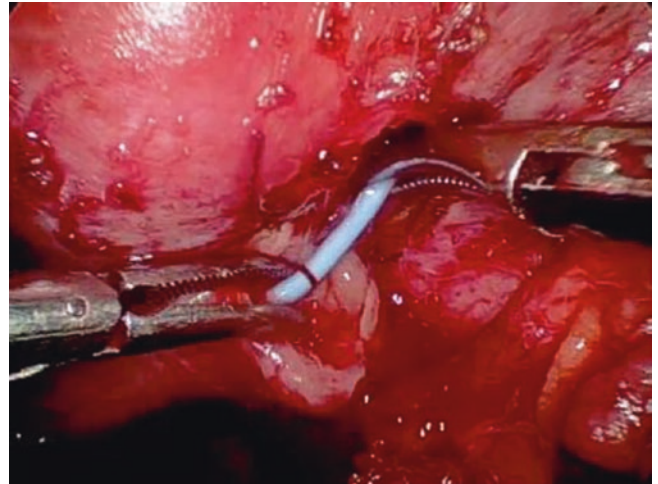


Fig. 8.16 After few sutures stent is inserted antegrade

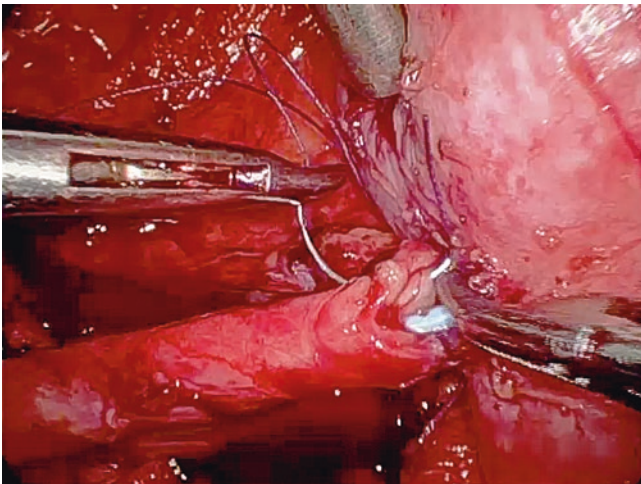


Fig. 8.17 Anterior layer suturing in progress

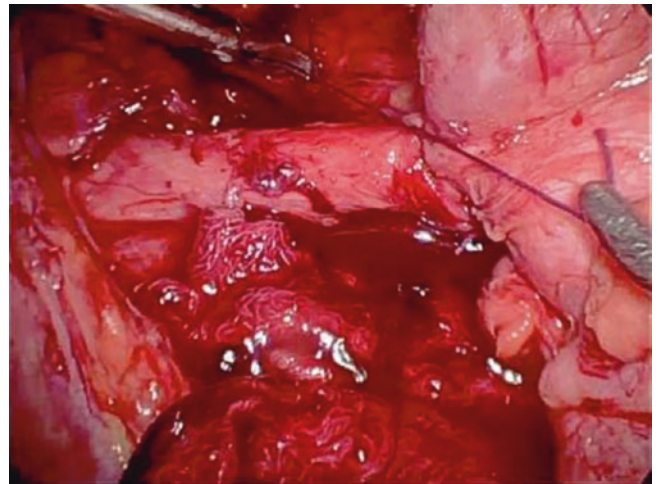


Fig. 8.18 Posterior layer suturing in progress

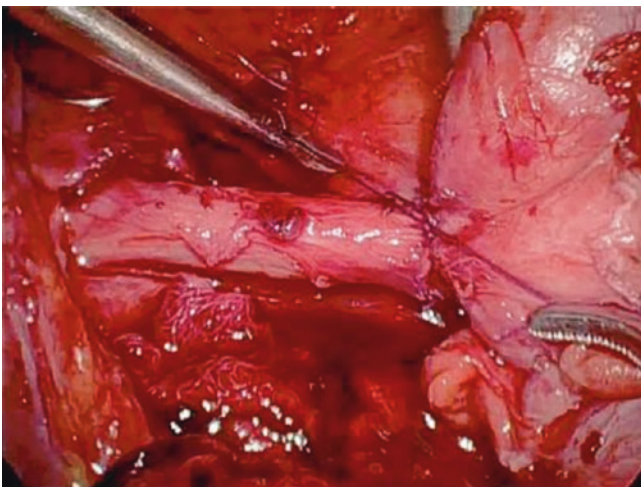


Fig. 8.19 Completed uretero calicostomy

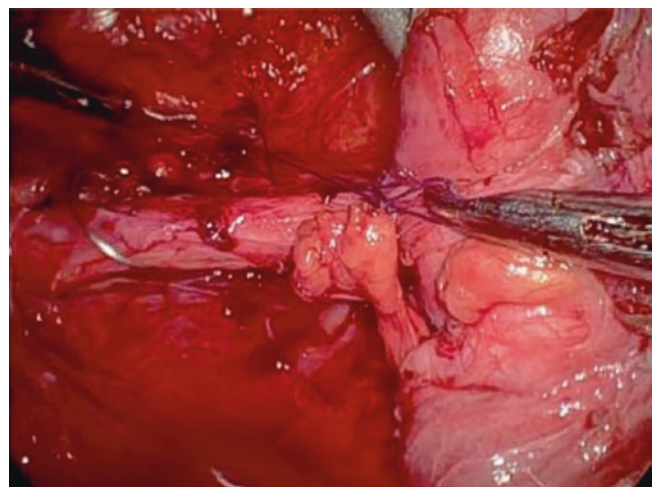


Fig. 8.20 Perinephric fat tacked to cover the anastomosis

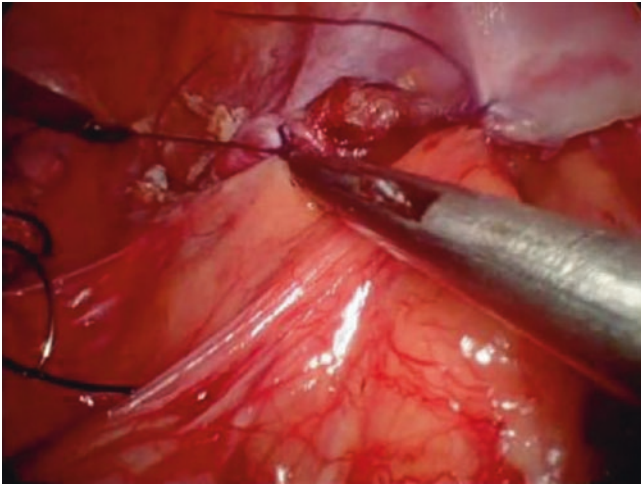


Fig. 8.21 Retroperitonealisation of uretero calicostomy area

References

1. Hawthorne NJ, Zineke H, Kelalis PP. Ureterocalicostomy: an alternative to nephrectomy. *J Urol.* 1976;115:583–6.
2. Ramalingam M, Senthil K, Selvarajan K, Pai MG. Laparoscopic ureterocalicostomy – our experience in 3 patients (abstract). *J Endourol.* 2005;19:A268.
3. Ross JH, Streem SB, Novick AC, Kay R, Montie J. Ureterocalicostomy for reconstruction of complicated pelviureter junction obstruction. *British J Urol.* 1990;65:322–5.

Laparoscopic Heminephrectomy for Duplex System

9

Manickam Ramalingam, Kallappan Senthil,
and Mizar G. Pai

9.1 Introduction and Indication

In complete renal duplication, upper moiety is obstructed and lower moiety refluxing in most instances. Nonfunctioning moieties, especially the obstructed systems need heminephrectomy. A separate vessel supplying nonfunctioning moiety makes heminephrectomy technically easier [1, 2].

9.2 Surgical Technique

Patient is placed in a 45–70° lateral position for a transperitoneal approach. It is necessary to have access from the renal area down to the pelvic cavity to excise the ureter. Ten millimeter paraumbilical camera port and at least three secondary ports (subcostal, subumbilical and epigastric or flank) are placed to have good access. After colonic mobilization, the renal vessel or the segmental branch supplying the defective moiety is clipped or ligated. Subsequently the dilated defective moiety with thin parenchyma is delineated and marked with diathermy. Then using ultracision

or electrocautery the dilated segment is excised and traced down along its ureteric segment. Additional ports may be needed to excise the lower part of the ureter. As far as possible monopolar cautery is to be avoided. Dilated ureter is ligated at the juxtahiatal level. Subsequently it is divided and whole moiety can be removed through a small muscle splitting incision in iliac fossa. A tube drain is left in for 5 days.

9.3 Conclusion

Laparoscopic heminephrectomy is a safe, feasible option for nonfunctioning moiety in duplex kidneys.

9.4 Heminephrectomy for Incomplete Duplex Kidney with Nonfunctioning Lower Moiety

9.4.1 Lower Moiety Heminephrectomy

M. Ramalingam (✉)
PSG Hospitals,
Coimbatore, India
e-mail: uroram@yahoo.com

K. Senthil
Urology Clinic, Gowtham Annexe, Coimbatore, India
e-mail: senthilsatya@hotmail.com

M.G. Pai
Urology Clinic,
3/1054, Gowtham Annexe, Avinashi Road, Coimbatore 641018,
India
e-mail: mizargpai@yahoo.co.in

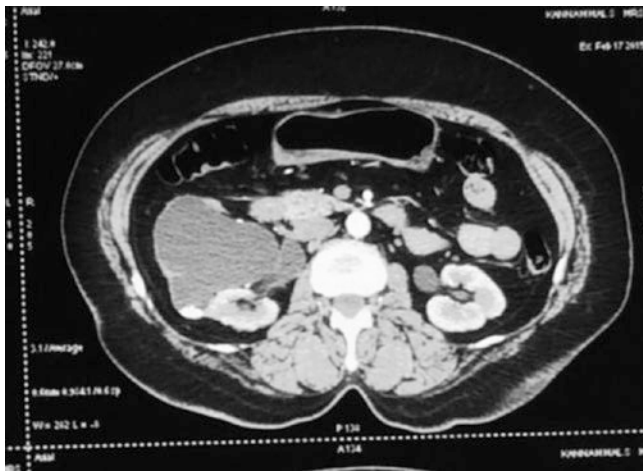

Fig. 9.1 CT scan showing non functioning lower moiety with a stone (right)

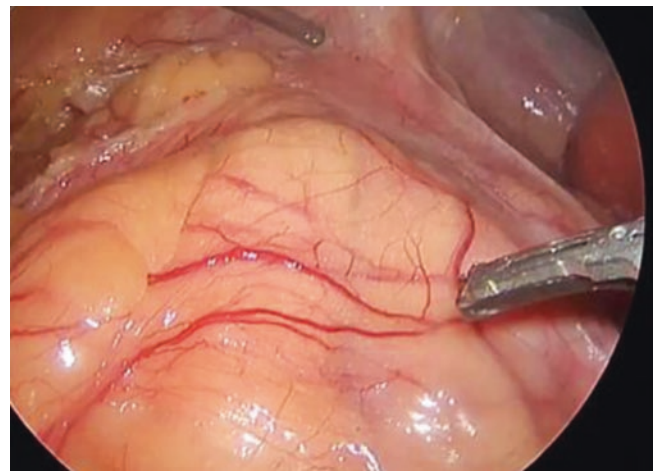


Fig. 9.2 Initial view of bulge in the right renal area

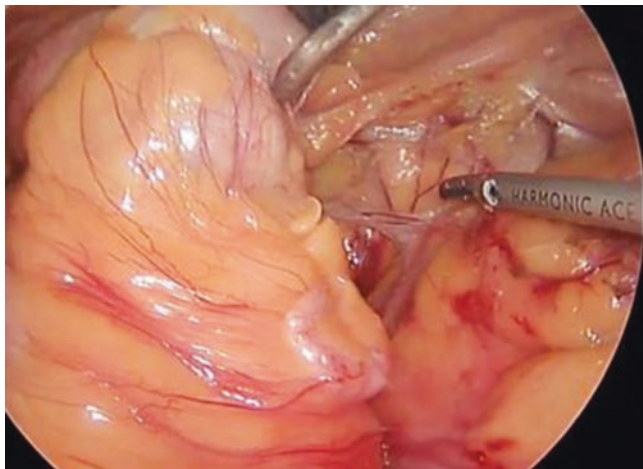


Fig. 9.3 Right colonic reflection in progress

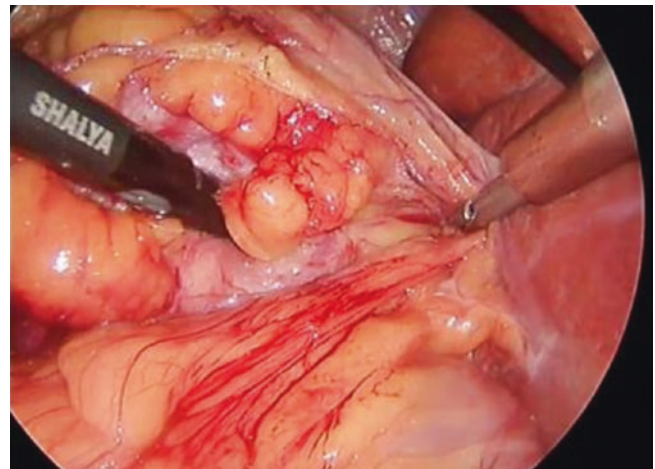


Fig. 9.4 Right colon being mobilised

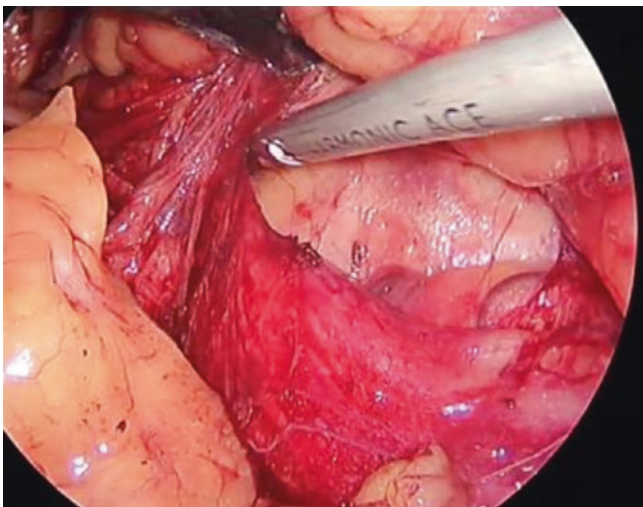


Fig. 9.5 Kocherisation in progress

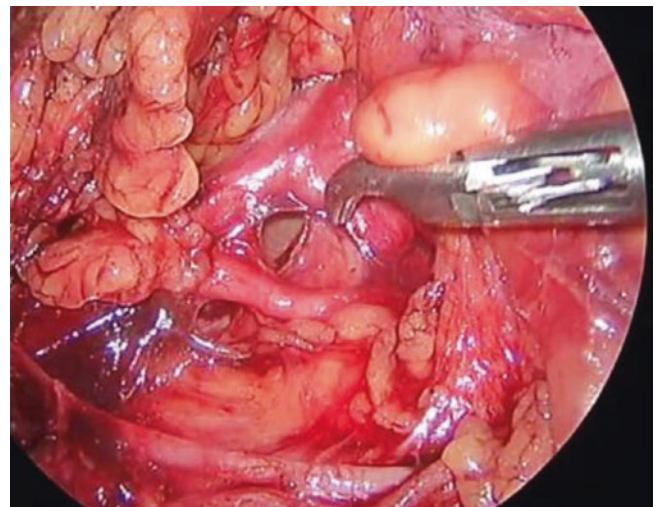


Fig. 9.6 Upper moiety and lower moiety ureters seen

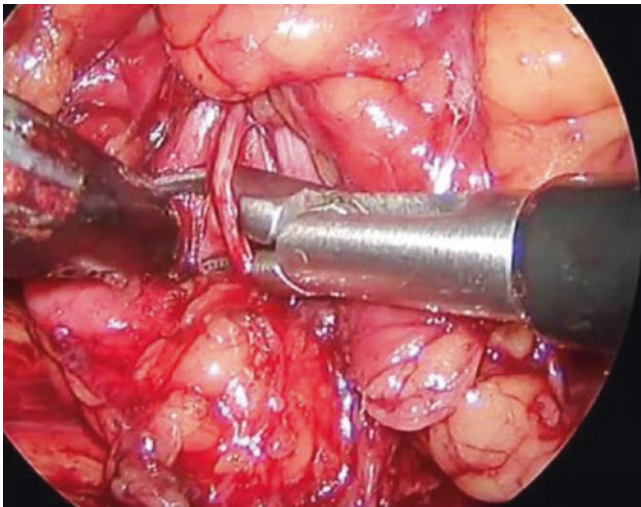


Fig. 9.7 Lower moiety artery dissected

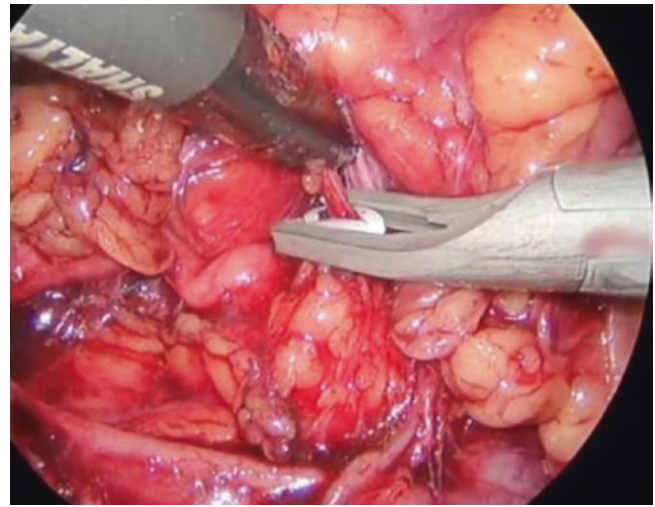


Fig. 9.8 Lower moiety artery clipped

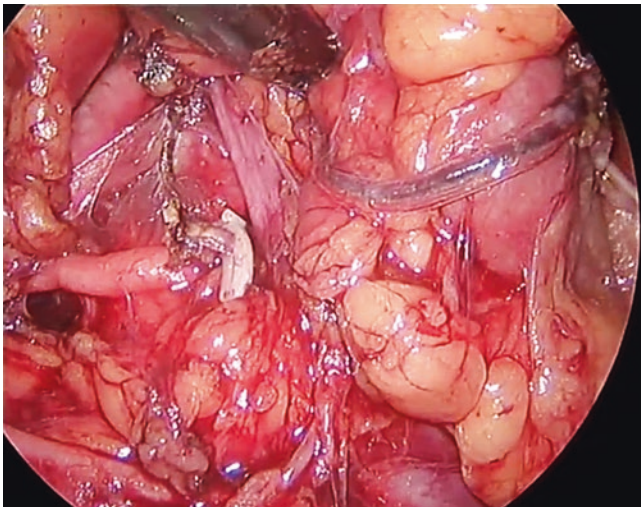


Fig. 9.9 Lower moiety artery divided

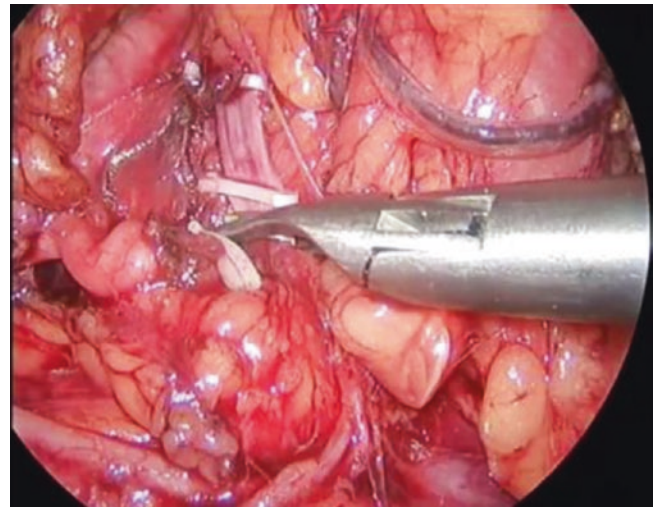


Fig. 9.10 Lower moiety vein being clipped

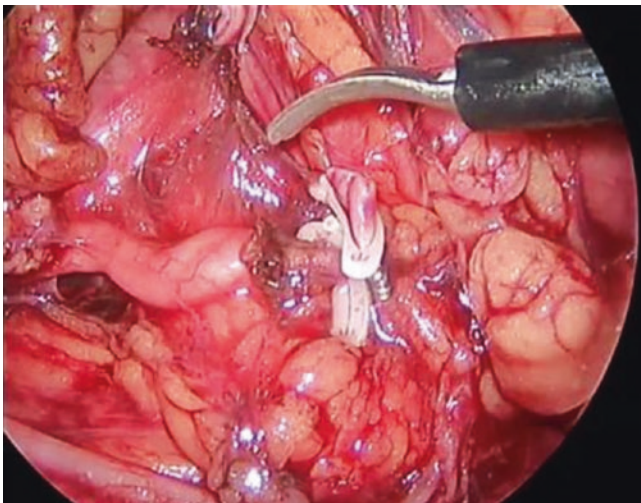


Fig. 9.11 Lower moiety vein divided

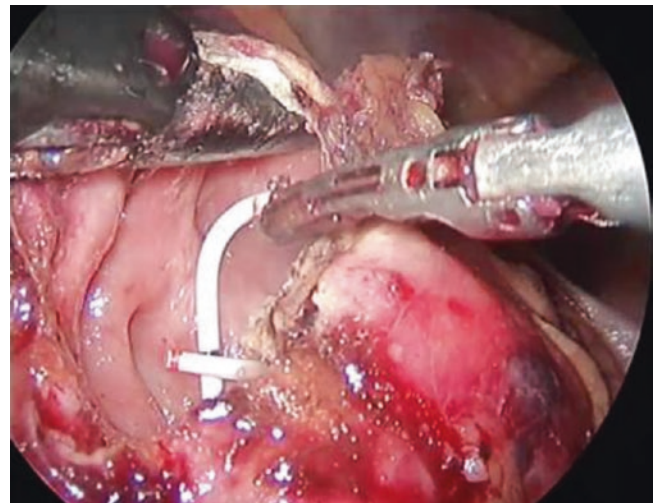


Fig. 9.12 Lower moiety divided using ultrasonic shears

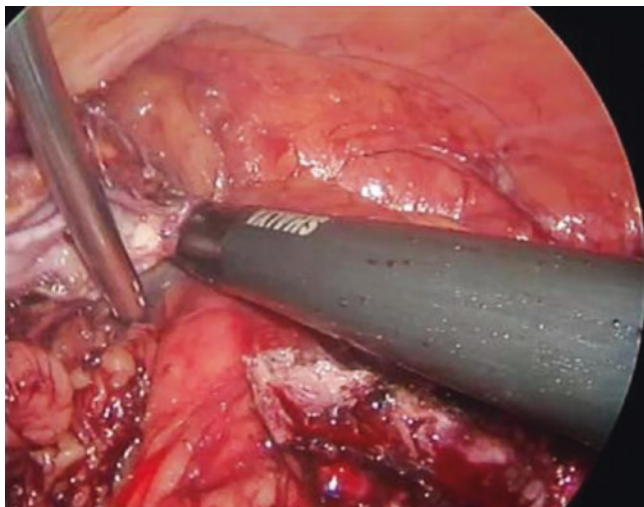


Fig. 9.13 Lower moiety being separated

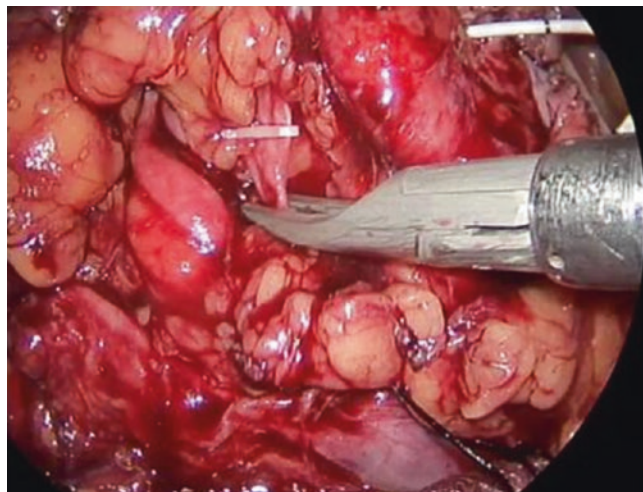


Fig. 9.14 Ureter clipped

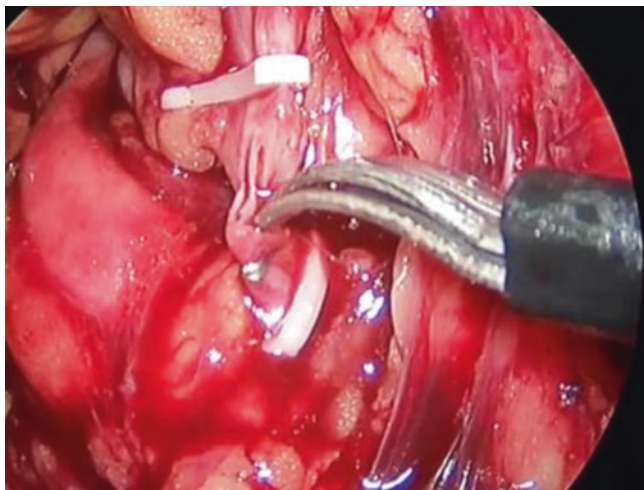


Fig. 9.15 Lower moiety ureter being divided

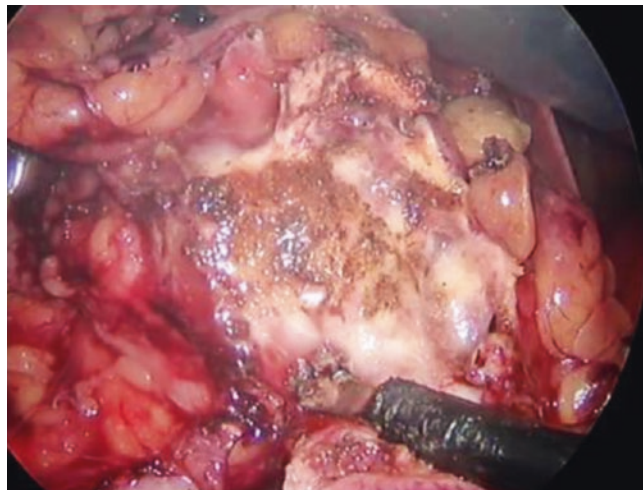


Fig. 9.16 Fulguration of residual epithelial lining

9.4.2 Upper Moiety Heminephrectomy

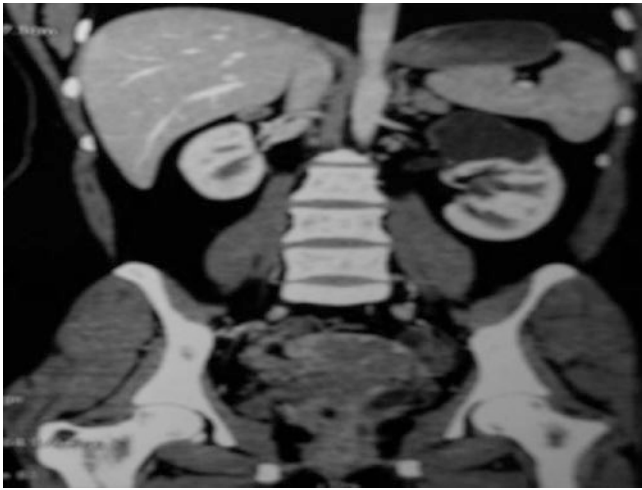


Fig. 9.17 CT showing nonfunctioning upper moiety in left duplex kidney

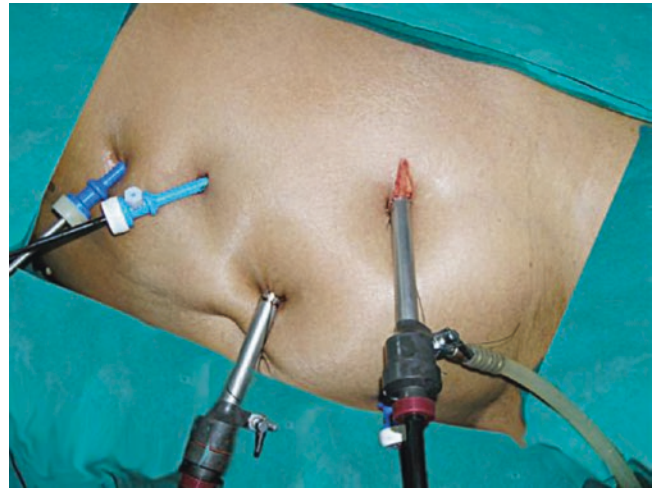

Fig. 9.18 Port position for left Heminephrectomy

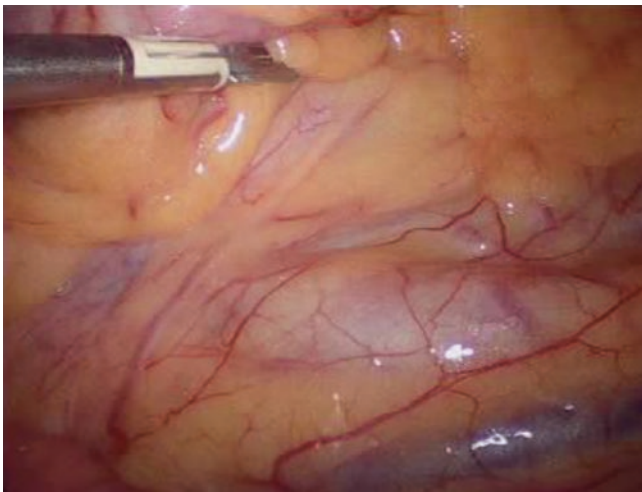

Fig. 9.19 Dilated upper moiety ureter seen

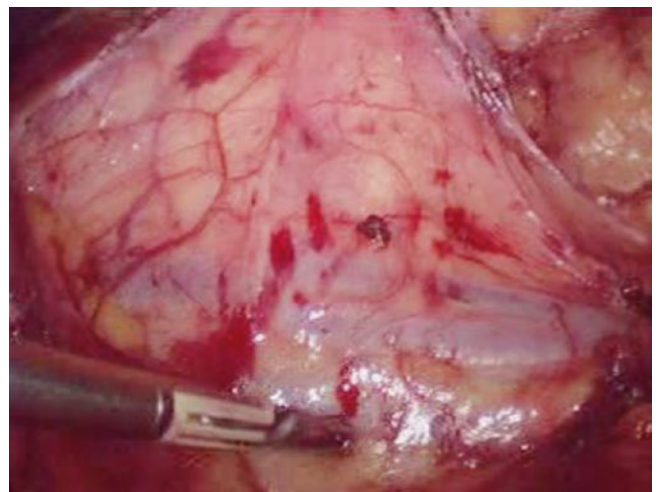


Fig. 9.20 Gonadal vein seen coursing close to the ureter

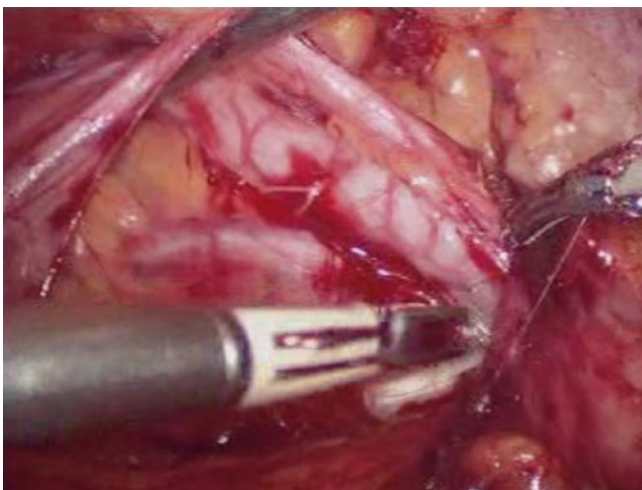


Fig. 9.21 Dilated upper moiety ureter and normal caliber lower moiety ureter dissected

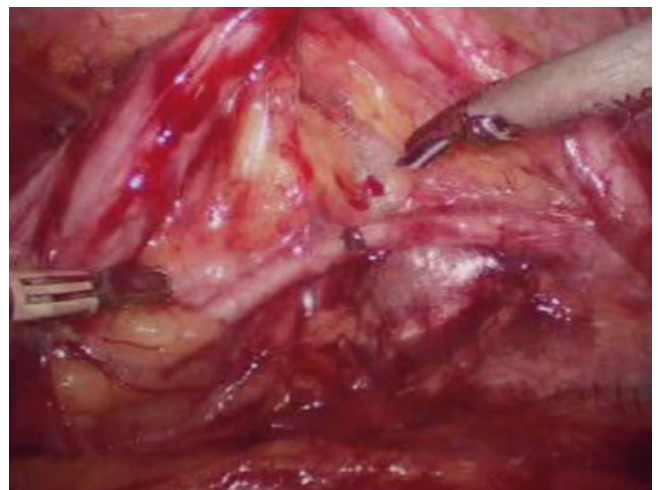


Fig. 9.22 Upper and lower moiety ureters separated

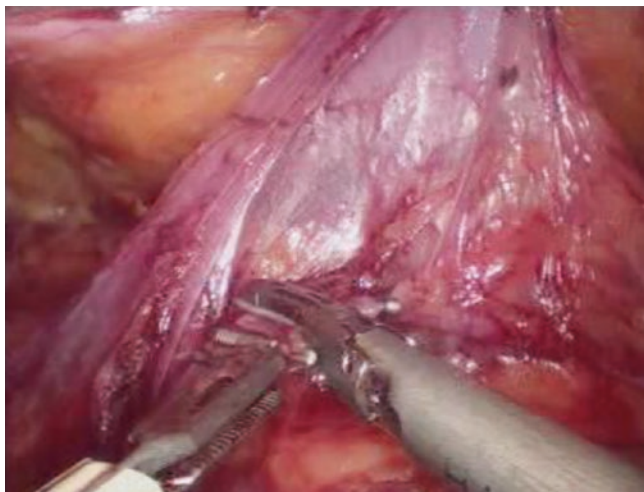


Fig. 9.23 Gonadal vein may be sacrificed, if it is hindering the dissection

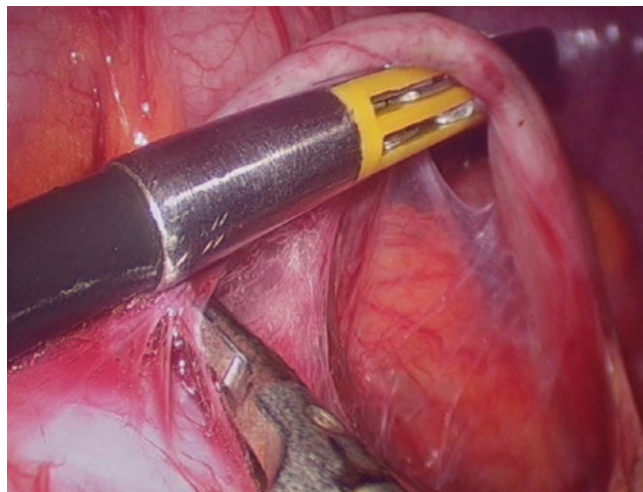


Fig. 9.24 Upper moiety ureter traced proximally till dilated pelvis

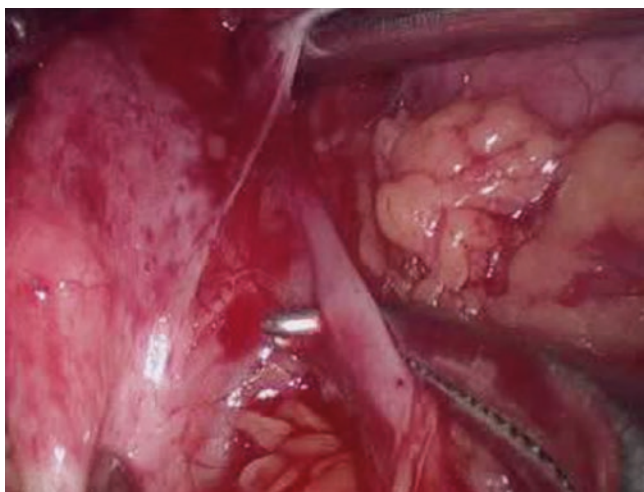


Fig. 9.25 Upper moiety artery being dissected

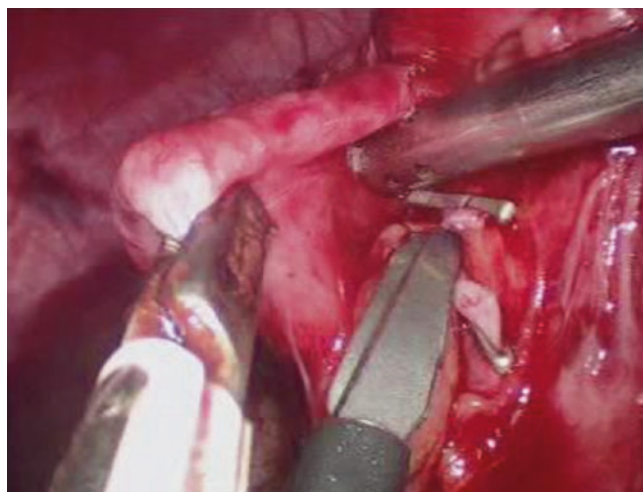


Fig. 9.26 Upper moiety artery divided

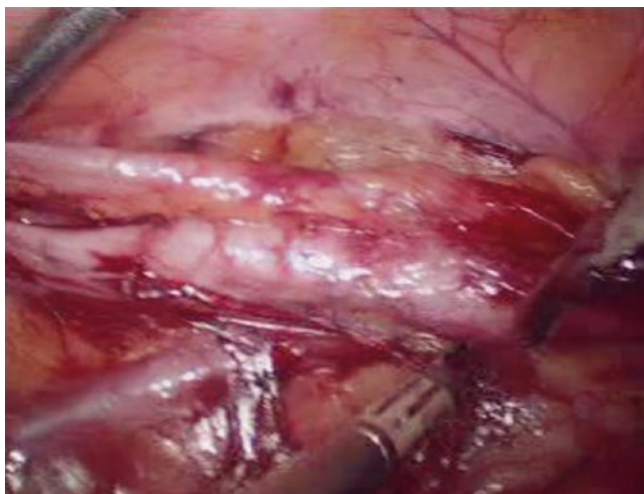


Fig. 9.27 Ureters dissected till pelvic brim

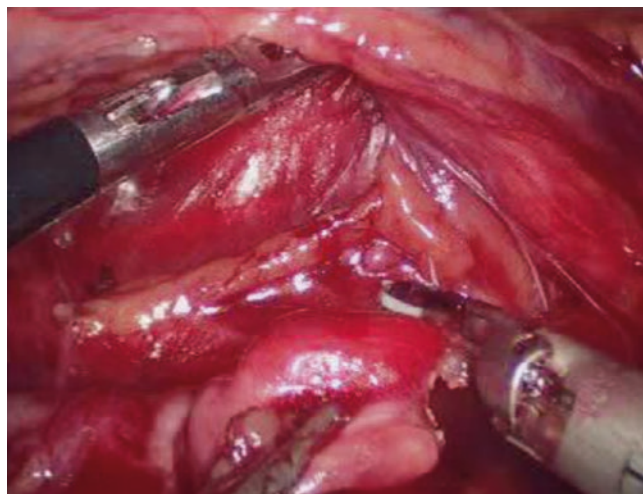


Fig. 9.28 Upper moiety ureter divided close to pelvic brim

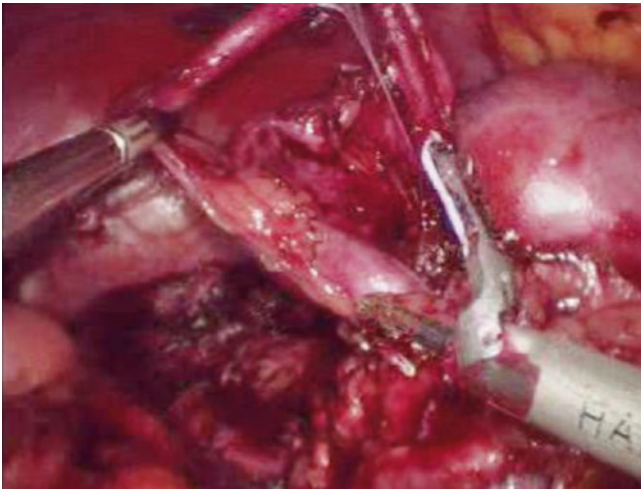


Fig. 9.29 Upper moiety ureter pulled up

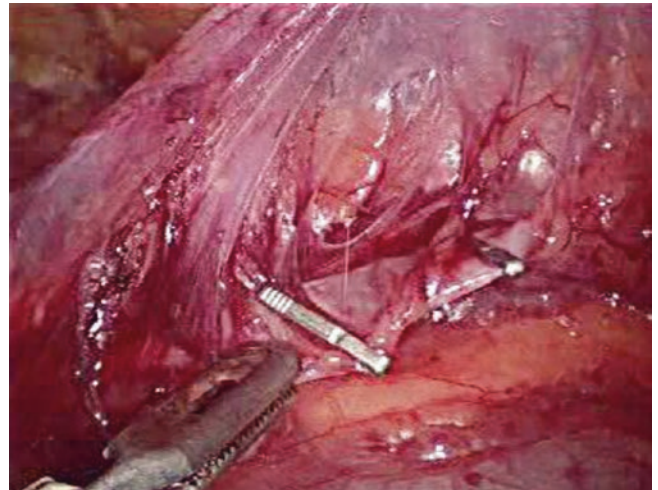


Fig. 9.30 Upper moiety vein clipped

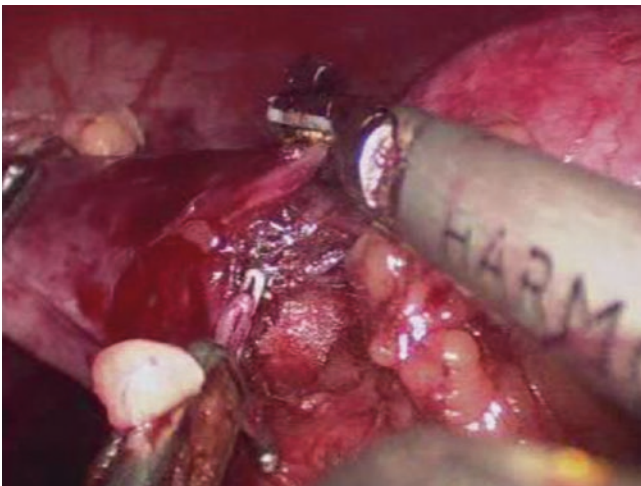


Fig. 9.31 Renal parenchyma divided using ultrasonic shears

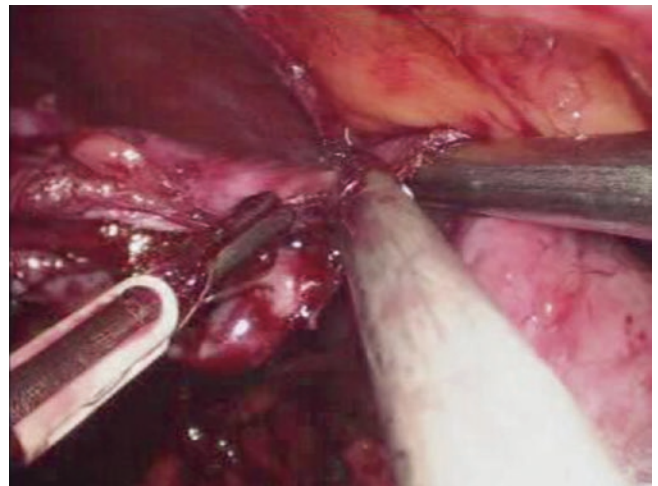


Fig. 9.32 Near completion of heminephrectomy

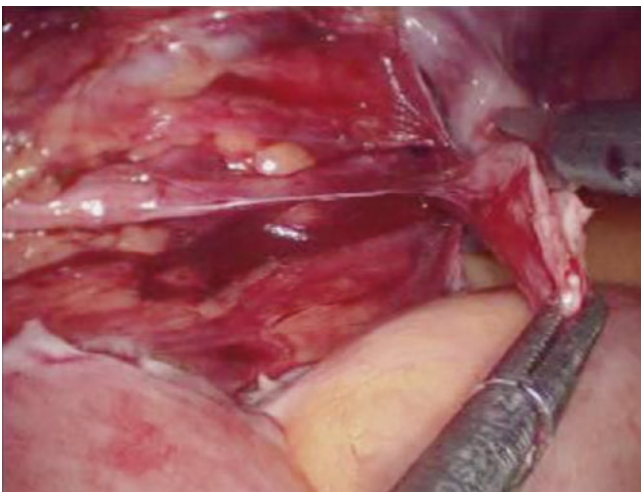


Fig. 9.33 Residual ureteric stump laid open

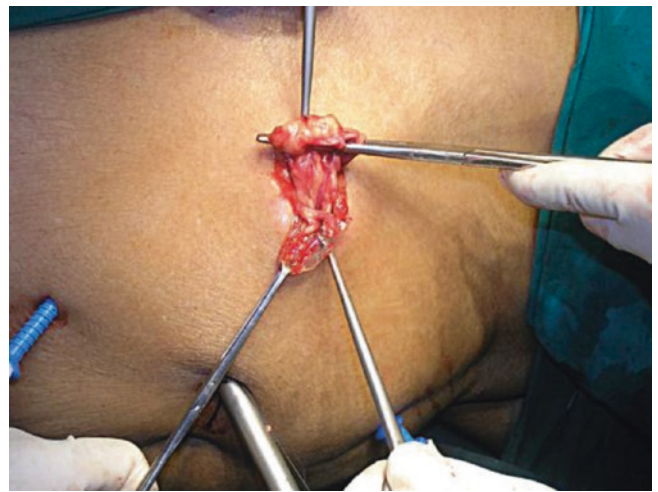

Fig. 9.34 Specimen extracted through lower lateral port site

References

1. Janetscheck G, Seibold J, Radmayr C, et al. Laparoscopic heminephrectomy in pediatric patients. *J Urol*. 1997;158:1928–30.
2. Mor Y, Goldwasser B, Ben-Chaim J, et al. Upper pole heminephrectomy for duplex system in children: a modified technical approach. *Br J Urol*. 1994;73:584.

V. Sripathi, Rajiv Padankatti, and Pavai Ganesan

10.1 Indications

Heminephrectomy in children is indicated in duplex systems, when there is no function in either the upper or lower moiety. This condition is more common in girls and usually presents with recurrent urinary infection. Child may present with continuous dribbling of urine, if the upper moiety ureter is inserted into the urethra.

10.2 Investigations

Renal ultrasound is the primary investigation. It is helpful in deciphering the features of the duplex system such as, which moiety has hydronephrosis, the parenchymal thickness, ureteral dilatation and tortuosity, urethral insertion (if ectopic) and presence of turbid urine. A DMSA or DTPA renal scan will serve to confirm the absence of function in the involved segment. MR Urogram and CT Urogram will provide the anatomical details and help to confirm the ultrasound findings.

10.3 Surgical Technique

The child is placed in the supine position at the edge of the table and securely strapped to allow table tilt. The involved side is slightly elevated (30°) to allow bowel to fall away.

Robot is docked to the patient's side with the robotic arms brought over the flank. In infants and toddlers ports are placed in the midline – 12 mm camera port at the umbilicus and two 8 mm working ports in the epigastrium and suprapubic region.

Bladder is catheterized and pressure points are padded. In older children, the working ports can be placed in the mid-clavicular line. An assistant port (5 mm) is placed between the camera port and the epigastric port to allow suction/irrigation, liver retraction, holding of traction sutures, placement of clips or feeding of sutures. Insufflation in younger children is usually kept at 3 l flow and intra-abdominal pressure is maintained at 8–10 mmHg.

Instruments used are scissors (with monopolar diathermy) on the right side and precise bipolar or Maryland forceps (with bipolar diathermy) on the left side. The colon is retracted medially after incising the white line. The dilated ureter of the affected moiety comes into view immediately. It is skeletonized, preserving all vascular adventitia on the ureter draining the normal moiety. To protect the ureter draining the normal segment, retrograde cannulation is preferred by some. At the lower pole of the kidney the dilated ureter is transected and gently teased from under the lower moiety vessels. The cut end is grasped and pulled up to stretch the vessels supplying the diseased upper moiety. The vessels are clipped (or tied) and divided. Immediately a distinct line of cleavage is seen between the dysplastic segment and the normal kidney. The dysplastic segment is now freed circumferentially prior to division. The capsule over the dysplastic segment is gently peeled back and the segment sharply divided from the normal kidney with diathermy scissor dissection or with the harmonic scalpel. Care is taken not to enter the calyces of the normal moiety. In this context it is an advantage to keep a ureteric catheter in the normal moiety pelvis. If methylene blue is injected, calyceal tears can be easily identified and repaired. If there has been previous inflammation, the dysplastic moiety may not be amenable to a clean dissection. In that case, the urothelial lining of the

V. Sripathi, MS, MCh, FRACS (✉) • R. Padankatti, DNB, DNB
Division of Pediatric Urology, Apollo Children's Hospital,
Chennai, India
e-mail: sripathi3@gmail.com; padankatti@gmail.com

P. Ganesan, MS, MCh
Department of Pediatric Surgery, PSG Medical College & Research
Institute, Off Avinashi Road, Peelamedu, Coimbatore, India
e-mail: pavaiganesan@gmail.com

dysplastic moiety may be dissected piece meal. If possible, the capsule is reapproximated with a few sutures. Drain is kept as per the discretion of the surgeon. As far as possible, the dilated tortuous ureter is excised but not aggressively pursued. Non refluxing ureters are left open while refluxing ureters are suture ligated in the pelvis [1].

Feeds are commenced within 2–3 h of surgery and child is discharged 24 h later after removal of the bladder catheter.

10.4 Followup

It is imperative to followup with Doppler renal ultrasound a month later to confirm an intact blood supply to the normal moiety. As an alternative, DMSA renal scan may be done to document function in the remnant moiety.

10.5 Outcomes

In a series of 17 robotic upper pole heminephrectomies, de novo lower moiety reflux was noted in four children. One child had a vascular injury to the upper pole during robotic

lower pole heminephrectomy necessitating removal of the upper pole [1]. In a review by Herz et al., a 94 % success rate has been reported [1]. In a recently published multi-institutional review of 60 robotic heminephrectomies a complication rate of 31 % was noted of which 10 % were Clavien-Dindo Grade 111a/b [2]. In a series of 142 patients undergoing laparoscopic heminephrectomy, 5 % were noted to have loss of the normal moiety. The causes include traction injury to the vessels supplying the normal kidney, spread of thermal injury or inadvertent injury due to complex vascular anatomy [3]. In order to avoid these injuries the use of Segmental Arterial Mapping (SAM) after intravenous injection of Indocyanine Green has been found to be useful [1].

10.6 Conclusion

Robot assisted laparoscopic heminephrectomy is an efficient procedure in the management of poorly functioning moieties.

10.7 Robot Assisted Laparoscopic Upper Pole Heminephroureterectomy

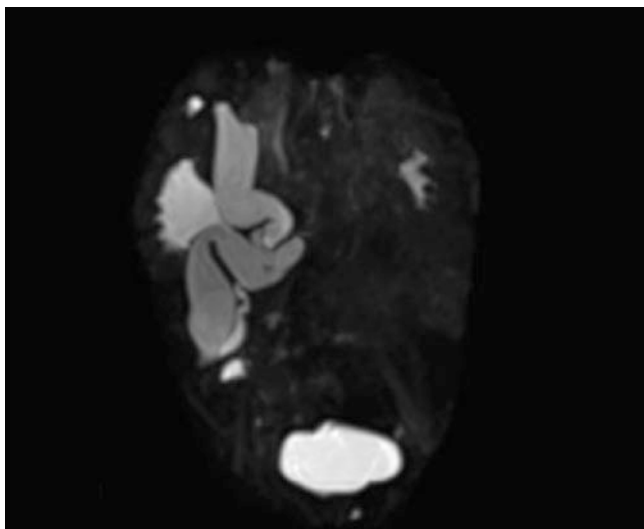
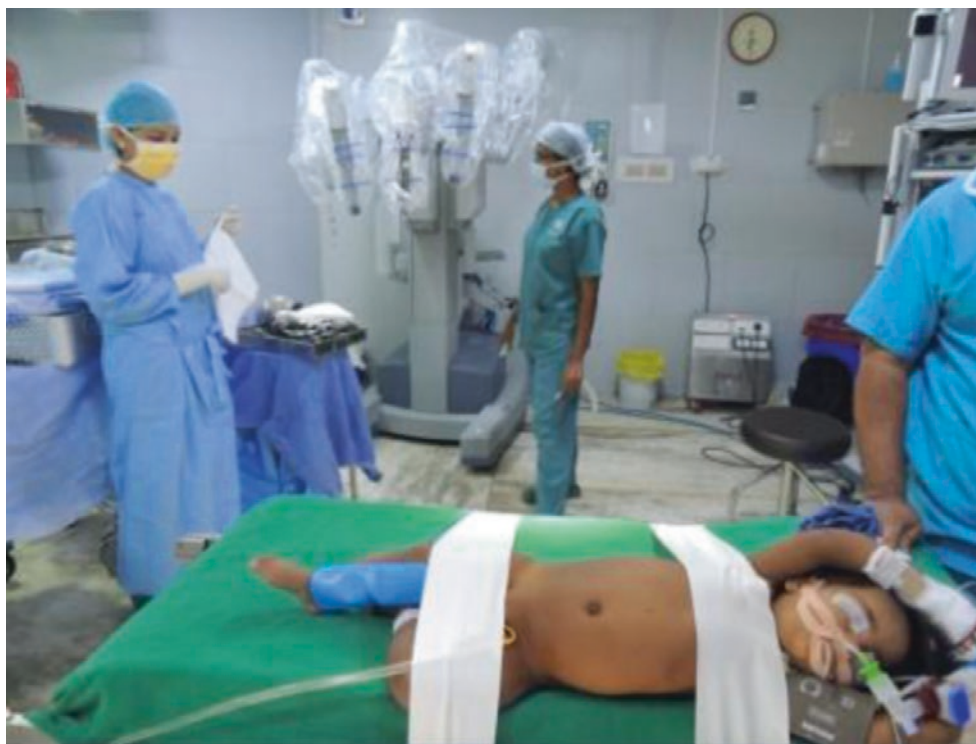

Fig. 10.1 CT urogram showing complete duplication of right side




Fig. 10.2 Renogram showing no uptake in the right upper pole

Fig. 10.3 Patient position.
Robot ready to be docked
from the right lateral aspect



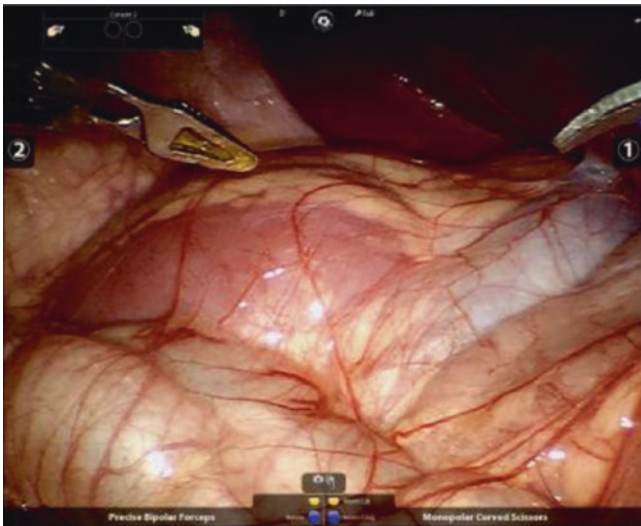

Fig. 10.4 Initial view of right renal area

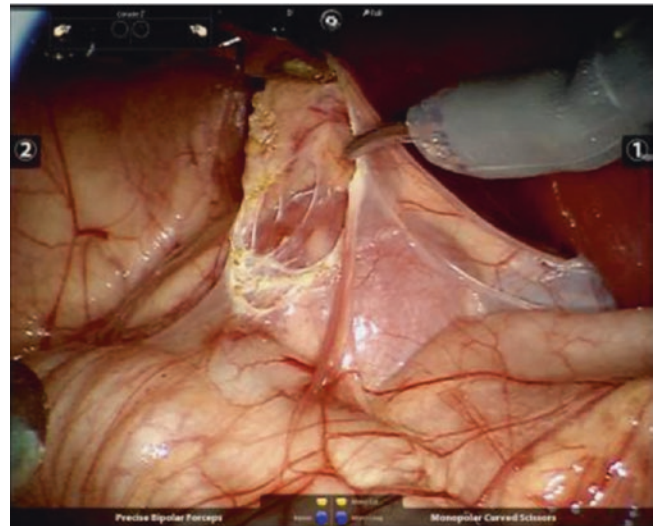


Fig. 10.5 Peritoneum incised over the kidney

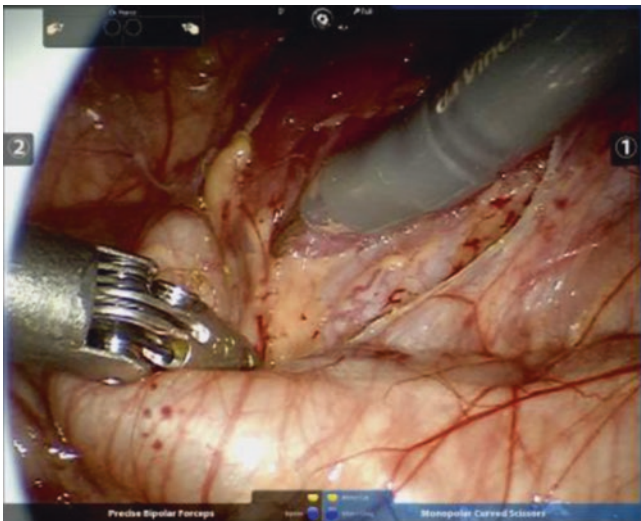


Fig. 10.6 Lower pole of kidney dissected and ureter seen

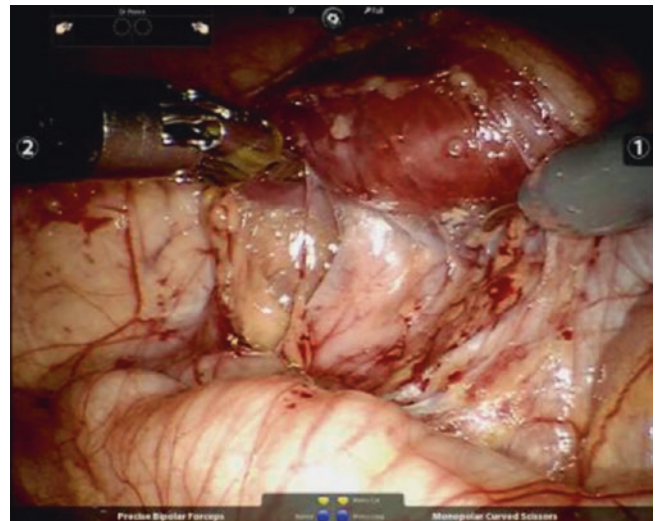


Fig. 10.7 Lower pole of kidney retracted

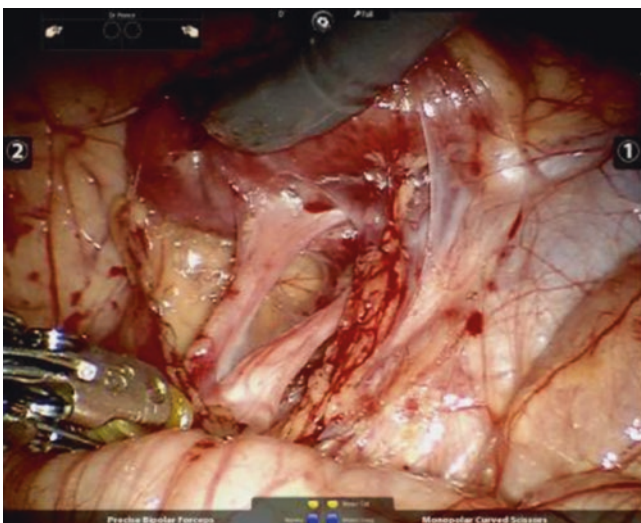


Fig. 10.8 Both ureters clearly delineated

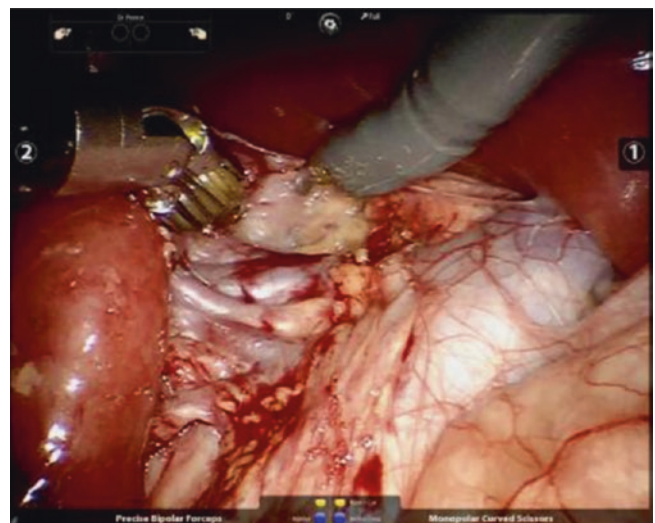


Fig. 10.9 Renal hilum being dissected

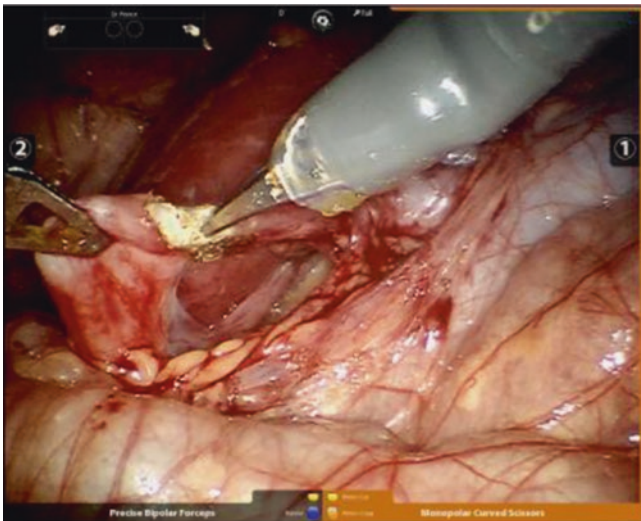


Fig. 10.10 Dilated upper moiety ureter being divided

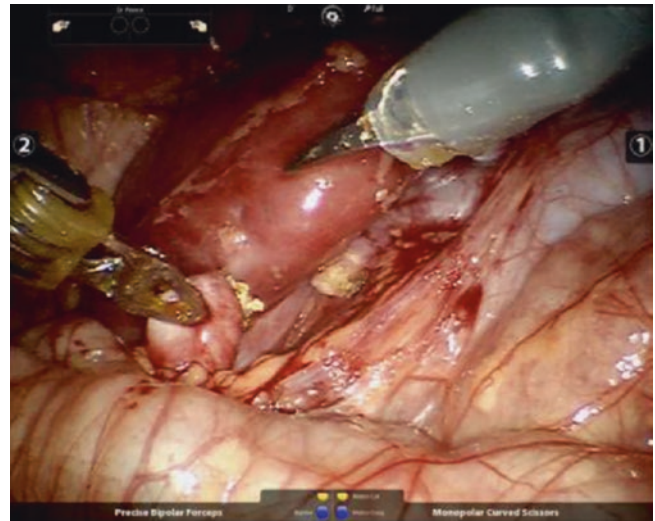


Fig. 10.11 Upper moiety ureter division complete

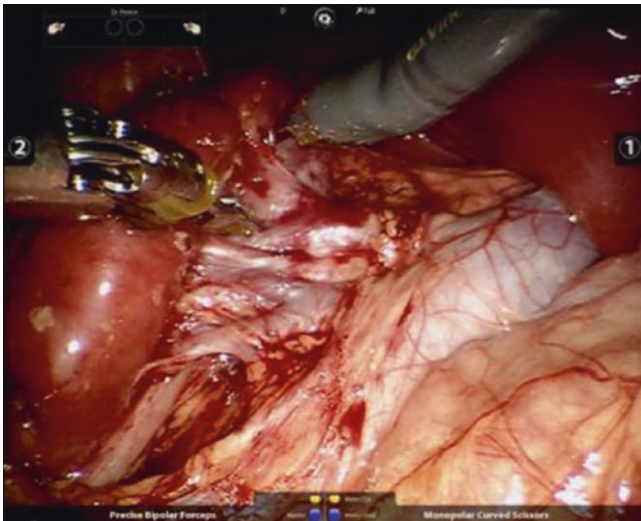


Fig. 10.12 Dissection of upper moiety pelvis above the renal hilum

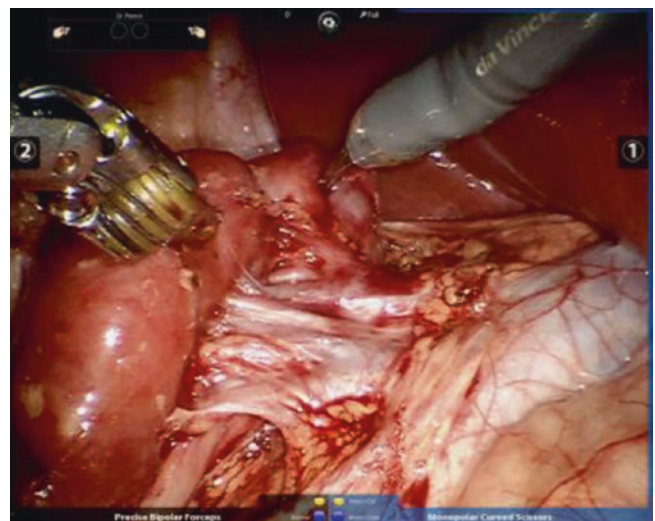


Fig. 10.13 Upper moiety completely dissected all around

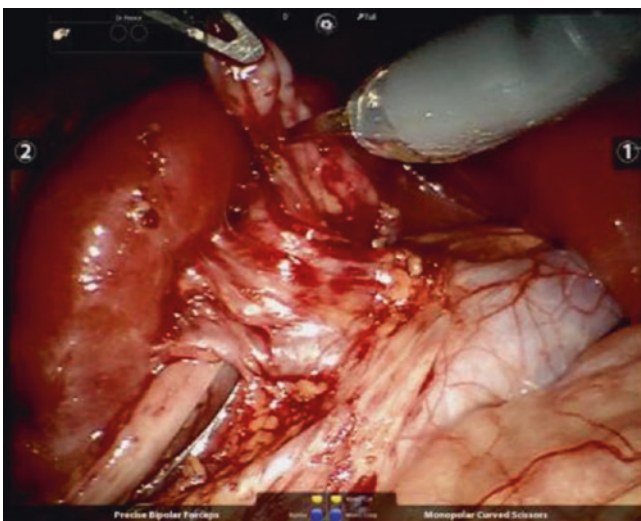


Fig. 10.14 Divided upper moiety ureter being pulled up

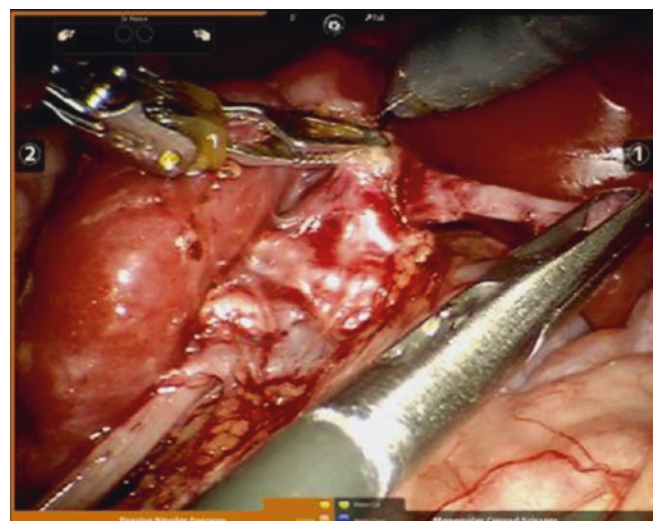


Fig. 10.15 Upper moiety vein cauterised with bipolar diathermy

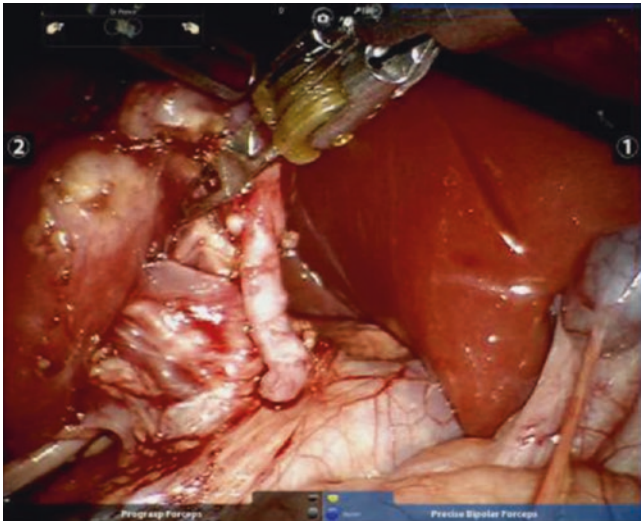


Fig. 10.16 Upper polar artery cauterised with bipolar diathermy

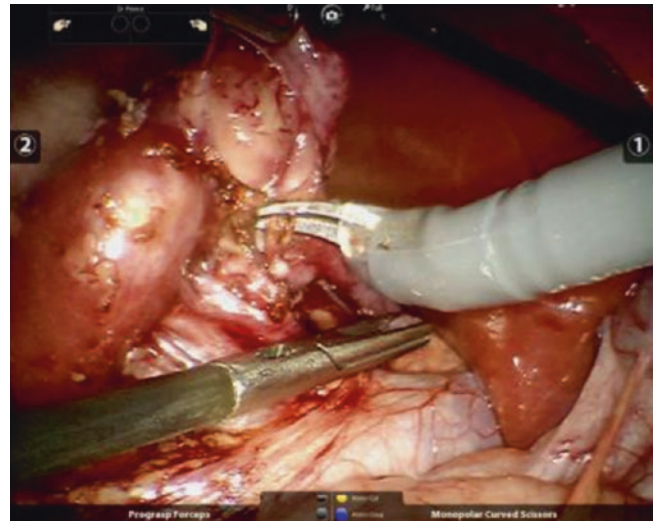


Fig. 10.17 Vein being divided

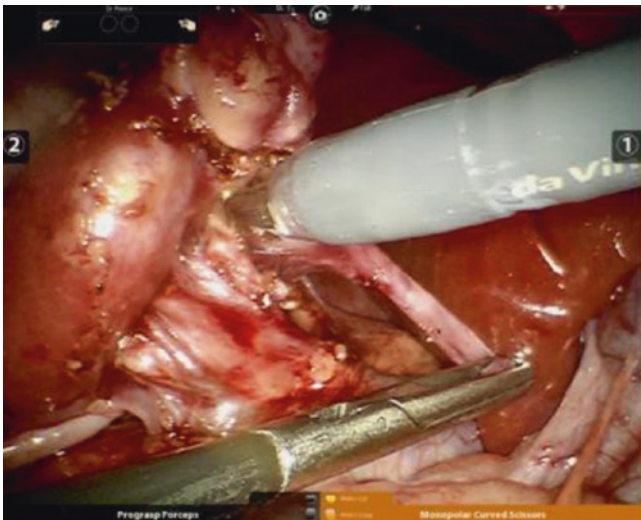


Fig. 10.18 Artery being divided

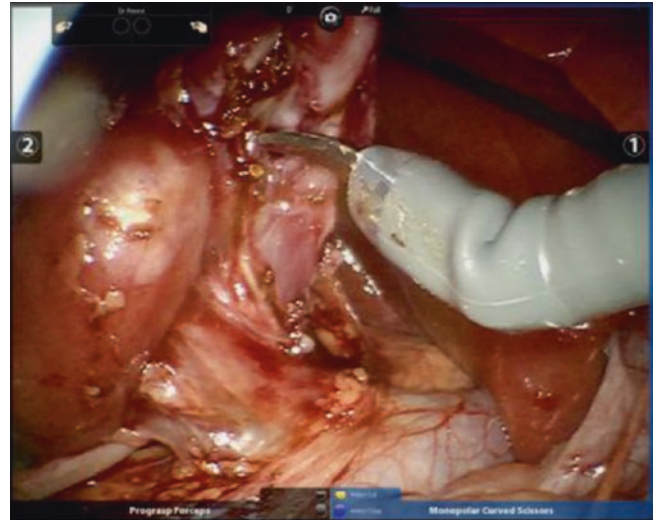


Fig. 10.19 Division of upper moiety in progress

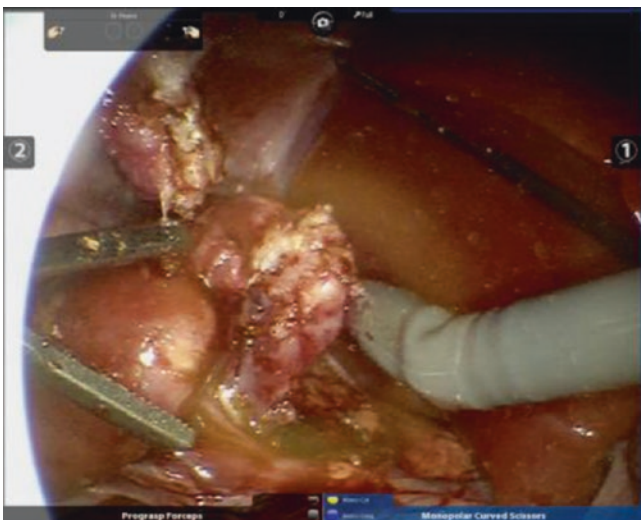


Fig. 10.20 Upper moiety separated

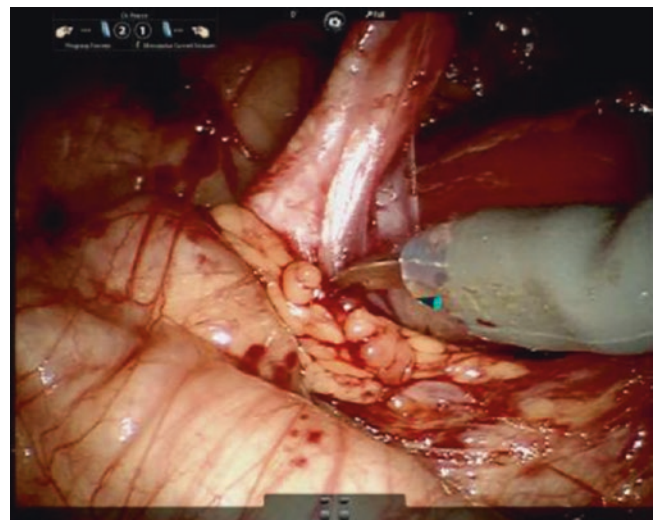


Fig. 10.21 Upper moiety ureter dissected distally

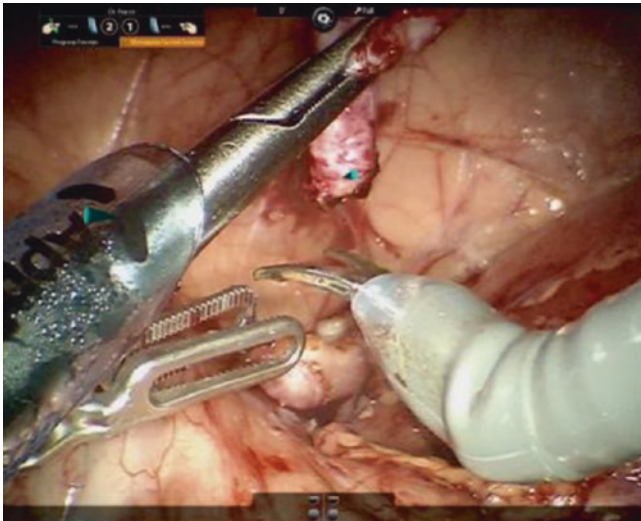


Fig. 10.22 Distal ureter divided

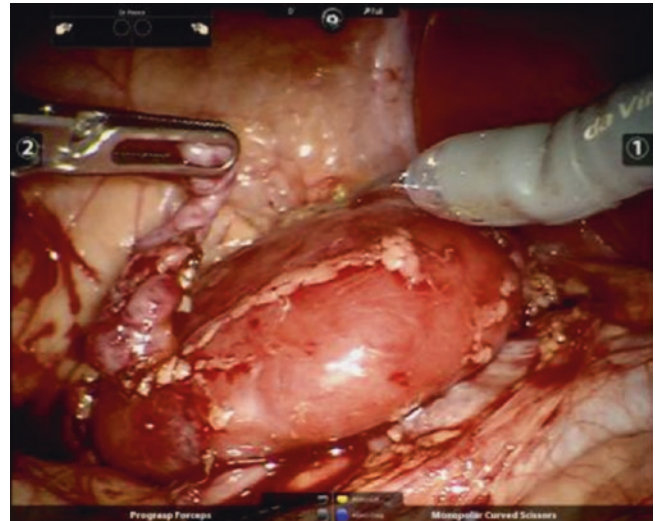


Fig. 10.23 Excised upper moiety about to be removed

References

1. Herz D, Smith J, McLeod D, Schober M, Preece J, Merguerian P. Robot-assisted laparoscopic management of duplex renal anomaly: comparison of surgical outcomes to traditional pure laparoscopic and open surgery. *J Pediatr Urol.* 2016;12:44 e.1–7.
2. Dangle PP, Akhavan A, Odeleye M, Avery D, Lendvay T, Koh CJ, Elder JS, Noh PH, Bansal D, Schulte M, MacDonald J, Shukla A, Kim C, Herbst K, Corbett S, Kearns J, Kunnavakkam R, Gundeti MS. Ninety-day perioperative complications of pediatric robotic urologic surgery: a multi-institutional study. *J Pediatr Urol.* 2016;12:1.a1–6.
3. Jayram G, Roberts J, Hernandez A, Heloury Y, Manoharan S, Godbole P, LeClair M, Mushtaq I, Gundeti MS. *J Pediatr Urol.* 2011;7:272–5.

Kallappan Senthil, N. Sivasankaran, Anandan Murugesan,
and Manickam Ramalingam

11.1 Bosniak Type I and Type II Renal Cyst

11.1.1 Introduction

Bosniak Type I and Type II renal cyst which causes pain, or compression on the collecting system need intervention.

11.1.2 Contraindication to Marsupialisation of Renal Cyst

Bosniak Type III and Type IV renal cysts need partial nephrectomy if small and peripheral, and nephrectomy if large and close to hilum.

11.1.3 Surgical Technique (Marsupialisation)

Renal cystic disease can be approached transperitoneally or retroperitoneally depending upon the location of the lesion [1–4]. Ideally infected cyst is better approached retroperitoneally to avoid contamination of the peritoneal cavity. A pre-operative contrast CT is done for better orientation.

11.1.4 Transperitoneal Approach

With the patient in 70° lateral tilt, using four ports, the position of renal bulge is assessed. Colon is mobilized adequately to expose the cyst up to its attachment with parenchyma. In case of parapelvic cyst, the kidney needs to be mobilised upto the hilum with blunt dissection taking care to avoid injury to the stretched out hilar vessels.

The cyst fluid is aspirated and sent for the cytopathology. The cyst wall is excised up to the base with electrocautery. The rest of the cyst wall is irrigated thoroughly and the interior inspected for any abnormality. Omental patch or perirenal fat is mobilized and transfixed to the excised margin of cyst.

11.2 Bosniak Type III and IV Renal Cyst (Complex Cyst)

As type III cysts can be associated with malignancy, partial nephrectomy is the ideal option. Small type IV renal cysts (<4 cm) is also managed by partial nephrectomy. As type IV cysts are cystic malignancies, large cysts need

K. Senthil (✉)
Urology Clinic, Gowtham Annexe, Coimbatore, India
e-mail: senthilsatya@hotmail.com

N. Sivasankaran
Urology Clinic,
3/1054, Gowtham Annexe, Avinashi Road,
Coimbatore 641018, India
e-mail: sivasankaranpillai@gmail.com

A. Murugesan
Department of Urology, PSG Institute of Medical Sciences and
Research, Peelamedu, Coimbatore, Tamil Nadu, India
e-mail: anandan79@gmail.com

M. Ramalingam
PSG Hospitals,
Coimbatore, India
e-mail: uroram@yahoo.com

radical nephrectomy. Preliminary insertion of retrograde catheter will be useful. The approach can be transperitoneal or retroperitoneal. The whole kidney has to be mobilized. After exposing the renal vessels, endobulldog clamp or Satinsky clamp has to be applied. If a separate branch is seen supplying the lesion, it can be clipped. Subsequently the line of demarcation appears over the renal parenchyma a few mm away from lesion. This is marked with L hook dissector.

A review of the CT Angiogram at this stage will guide the line of division deep down. Ultracision may be used for division of the parenchyma with better hemostasis. Methylene blue irrigation through a preplaced ureteric catheter will delineate the amputated calices. This aids in transfixing the calyx. Subsequently the renal parenchymal edges can be approximated with absorbable sutures. The sutured line is supported with hemostatic bolster. It is preferable to seal the raw area with omentum and leave a tube drain. At the end, the ureteric catheter is exchanged to a double pigtail stent.

11.3 Laparoscopic Marsupialisation of Cyst

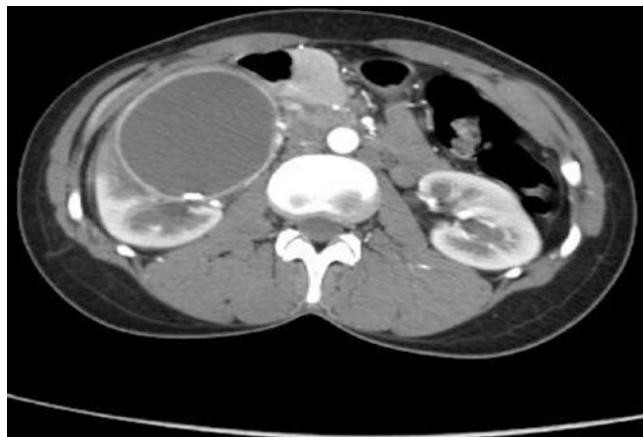

Fig. 11.1 CT Urogram showing large cyst over medial aspect of right kidney

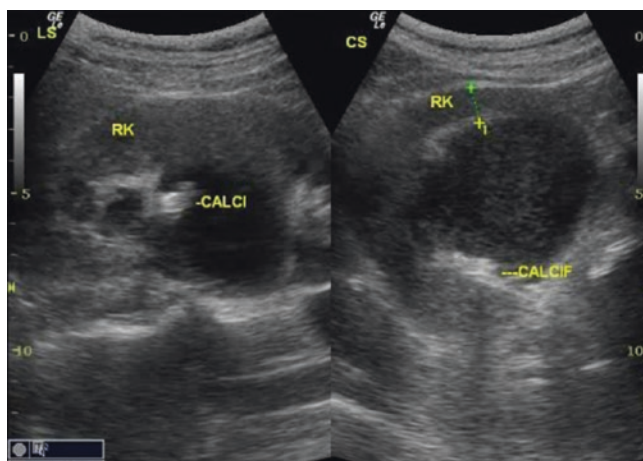


Fig. 11.2 USG showing large cyst over medial aspect of right kidney

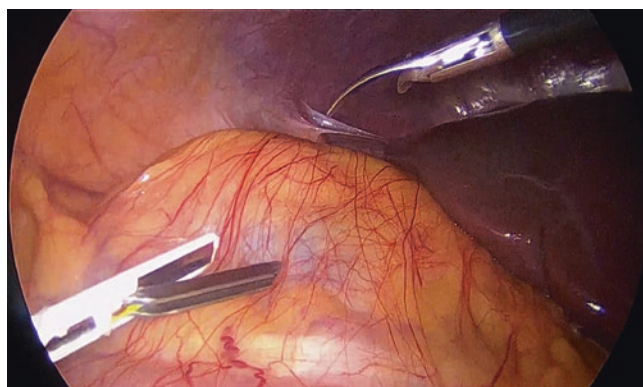


Fig. 11.3 Initial view of bulging renal cyst

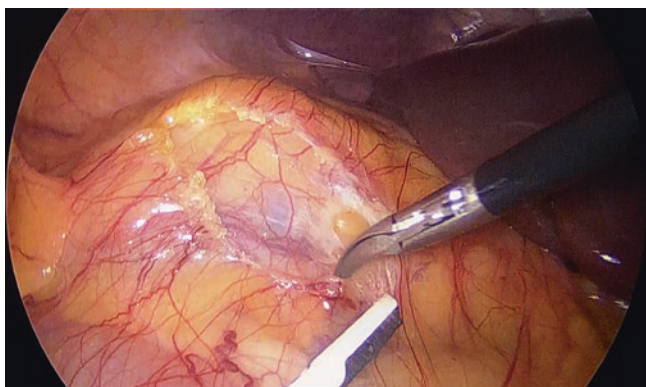


Fig. 11.4 Peritoneotomy for medial reflection of hepatic flexure

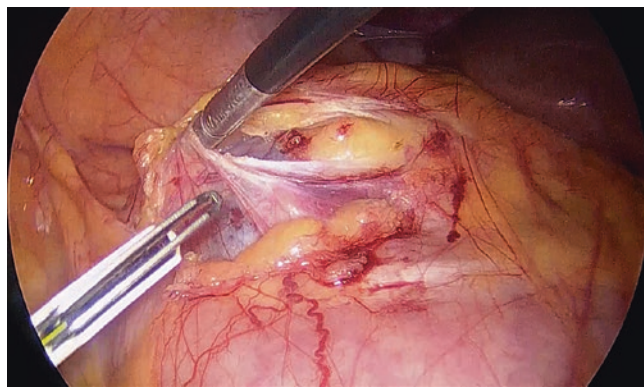


Fig. 11.5 Gerota's fascia over the cyst being opened

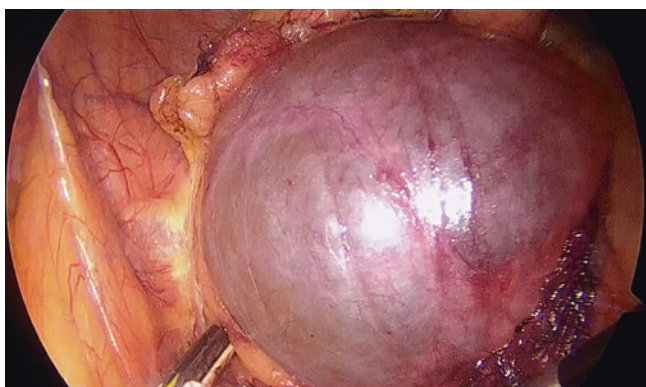


Fig. 11.6 Cyst exposed all around

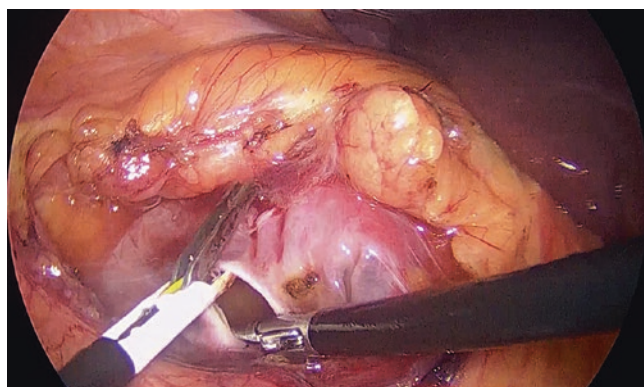


Fig. 11.7 Cyst incised and opening enlarged

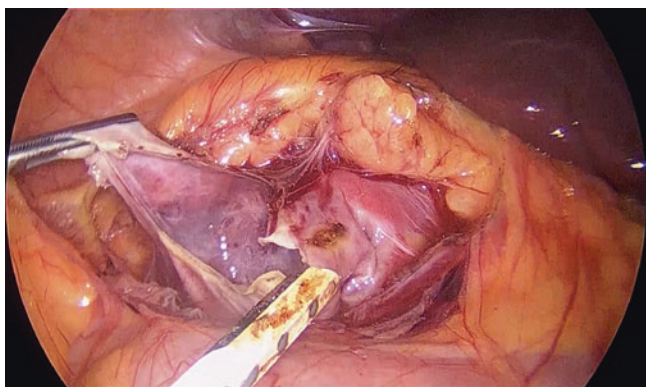


Fig. 11.8 Cyst opening enlarged almost till normal parenchyma

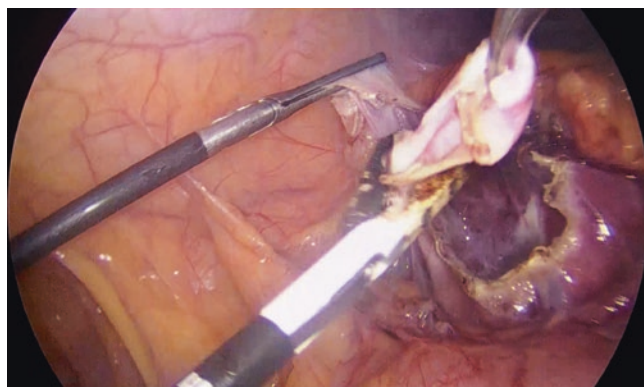


Fig. 11.9 Cyst wall being excised

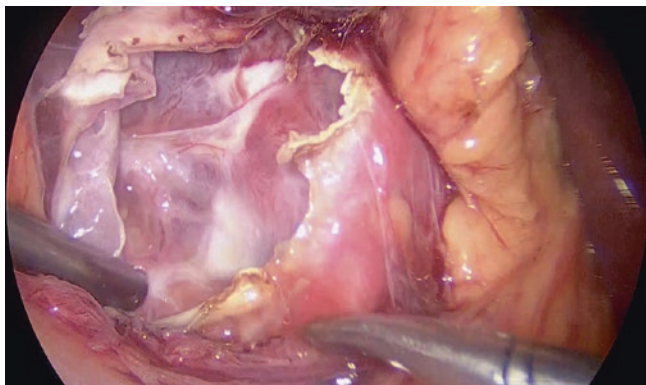


Fig. 11.10 Exposed inner layer of cyst wall inspected for any calcification or growth

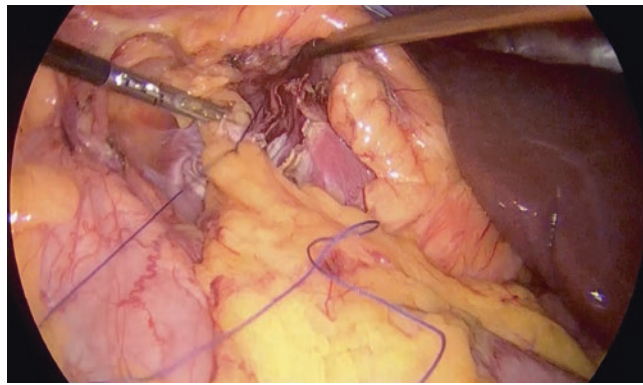


Fig. 11.11 Omentum fixed to inner layer of cyst

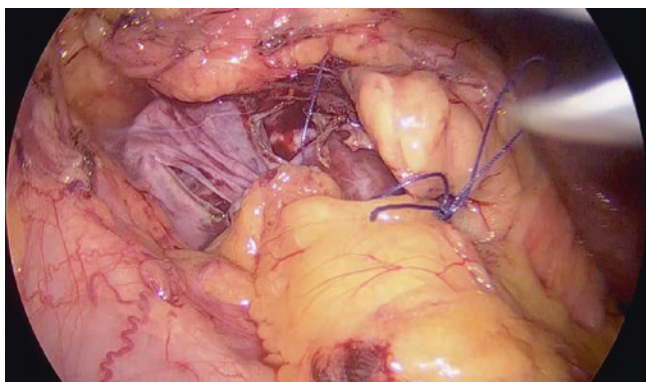


Fig. 11.12 Final view at completion

11.4 Laparoscopic Partial Nephrectomy for Complex Renal Cyst

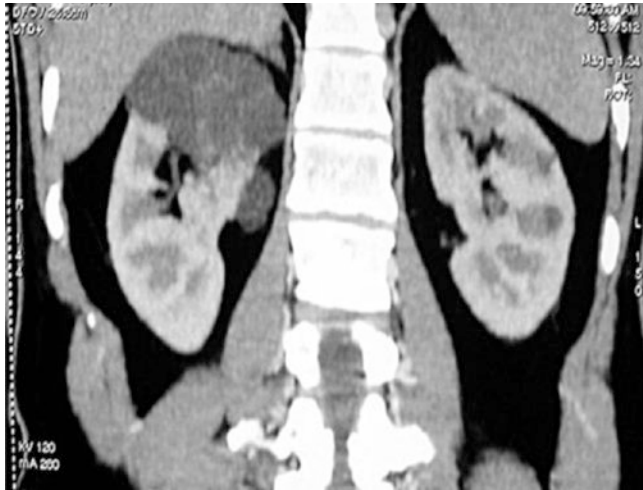

Fig 11.13 CT Scan of right kidney showing multiseptate cyst in its upper pole

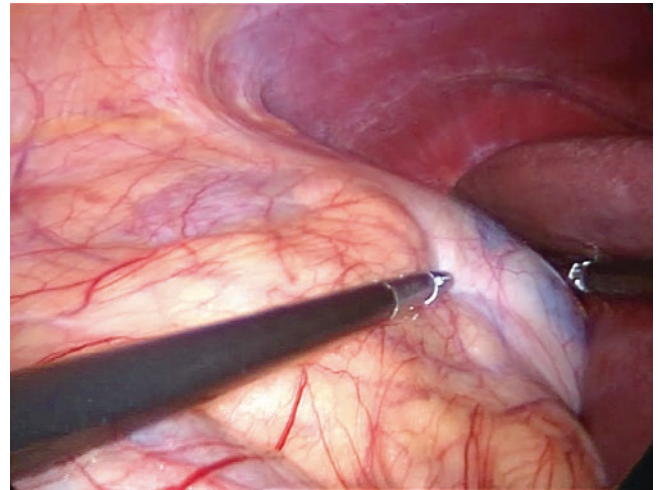


Fig 11.14 Initial view of cyst bulge in upper pole

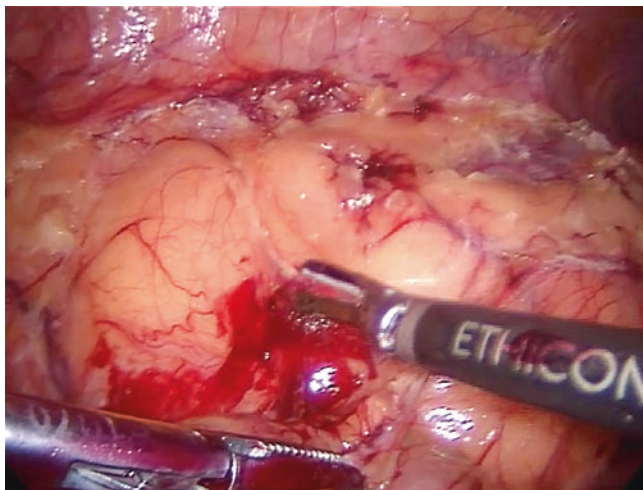


Fig 11.15 Colon reflected medially from the Gerota's fascia

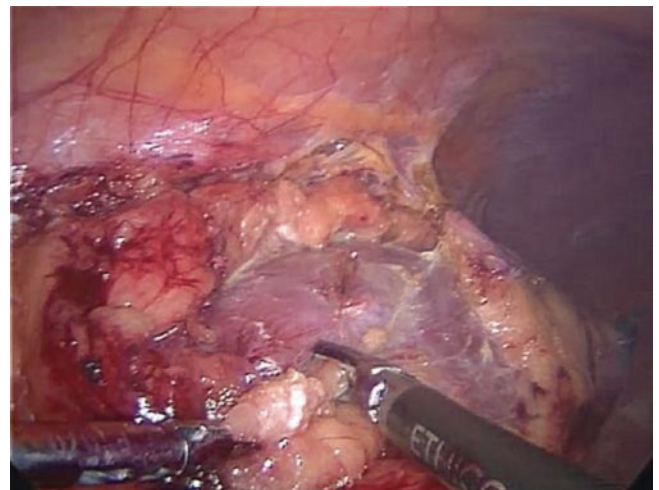


Fig 11.16 Gerota's fascia opened and perinephric fat dissected away

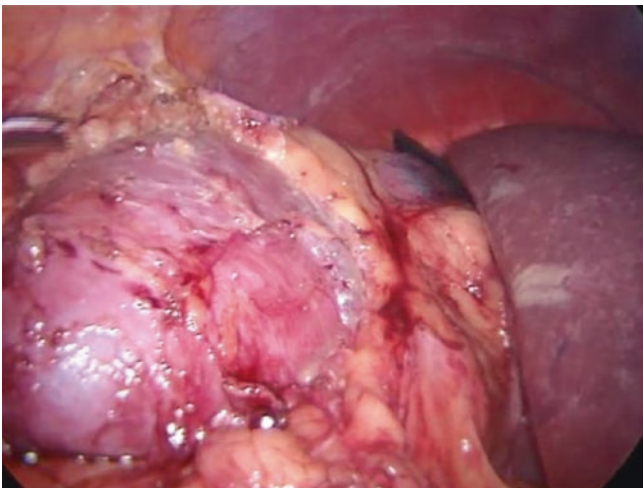


Fig 11.17 Perinephric fat cleared from lower pole

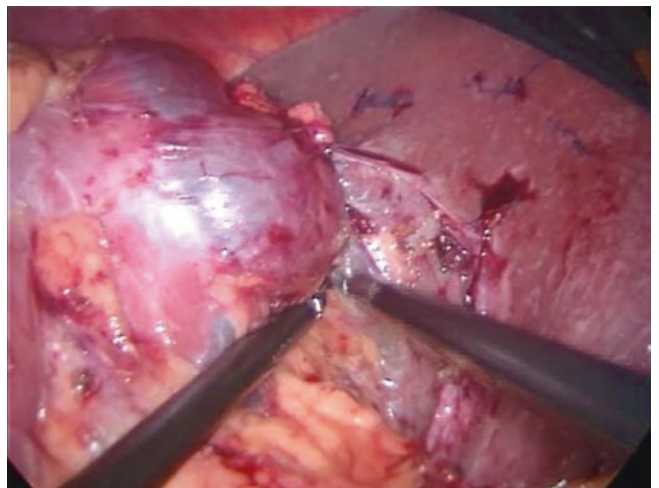


Fig 11.18 Upper polar cyst separated from the liver

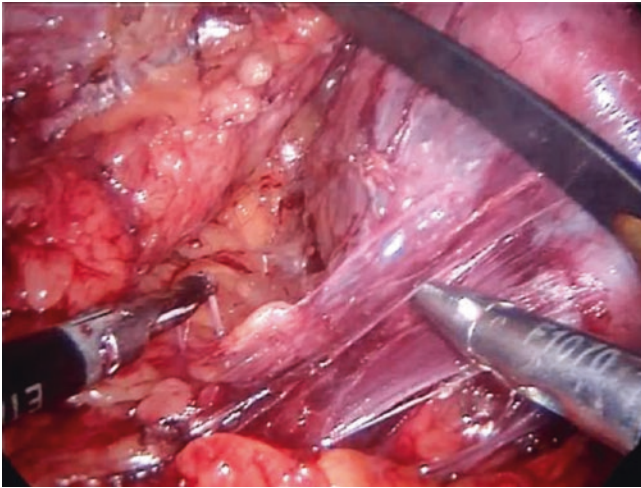


Fig 11.19 Kidney mobilised posteriorly

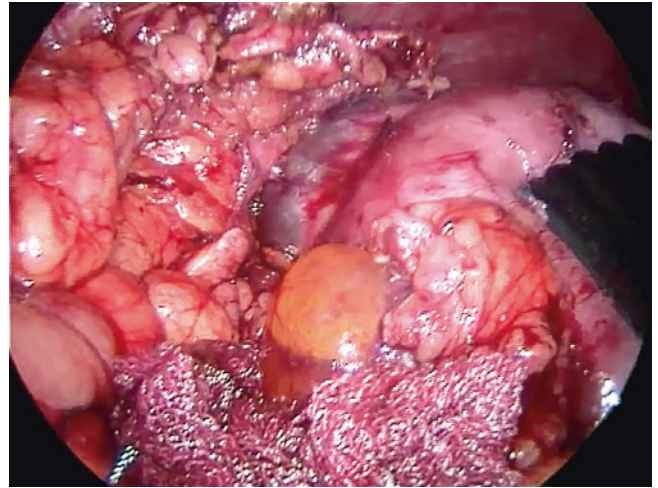


Fig 11.20 Upper pole mobilised completely

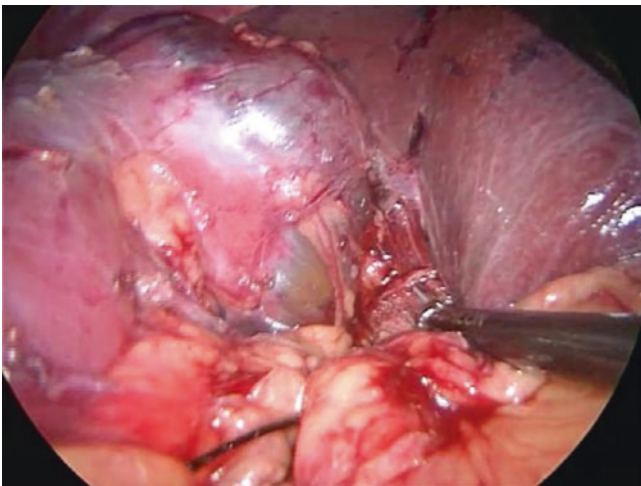


Fig 11.21 Cyst delineated anteriorly and medially

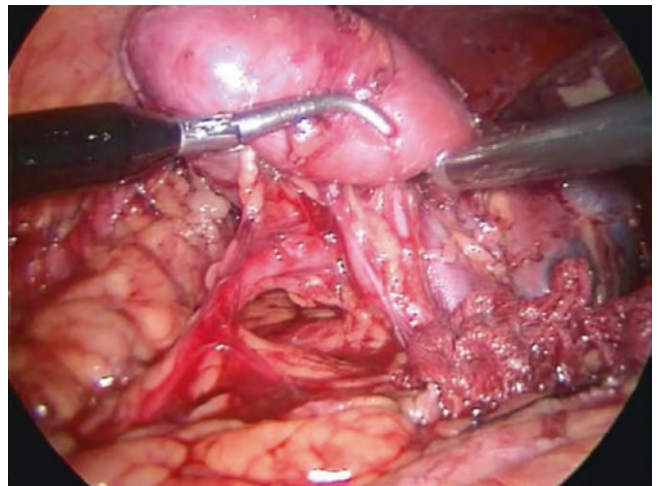


Fig 11.22 Hilar dissection in progress

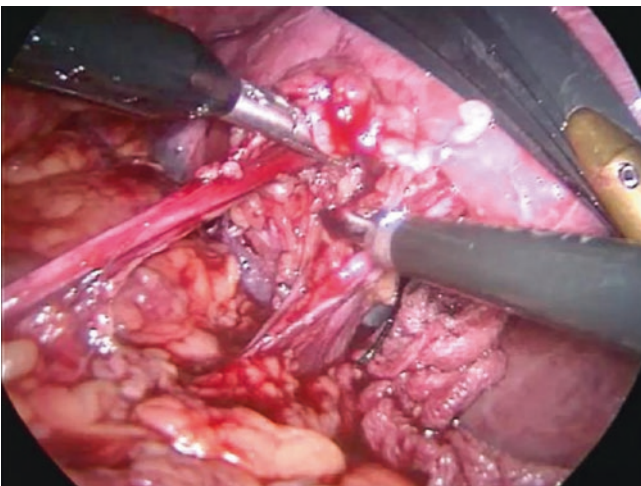


Fig 11.23 Ureter dissected and tented up

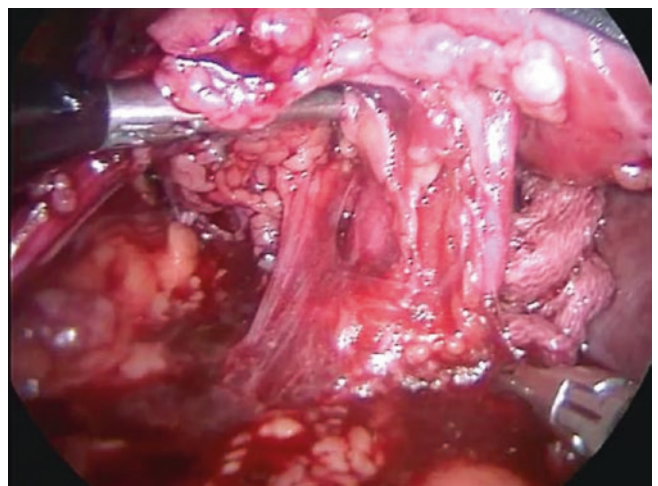


Fig 11.24 Completed hilar dissection

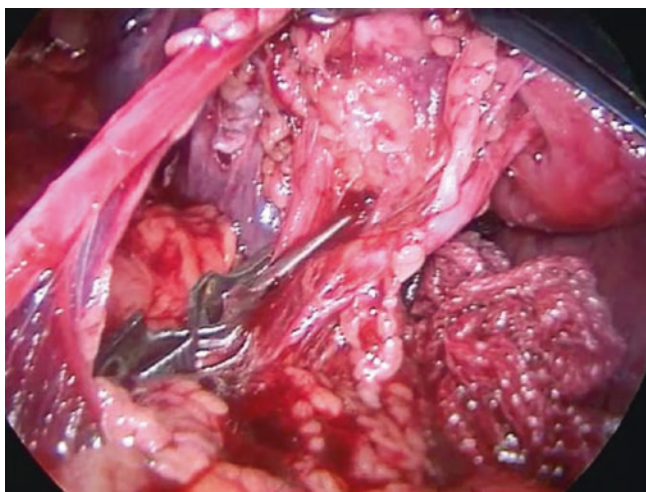


Fig 11.25 Selective clamping of upper polar segmental artery

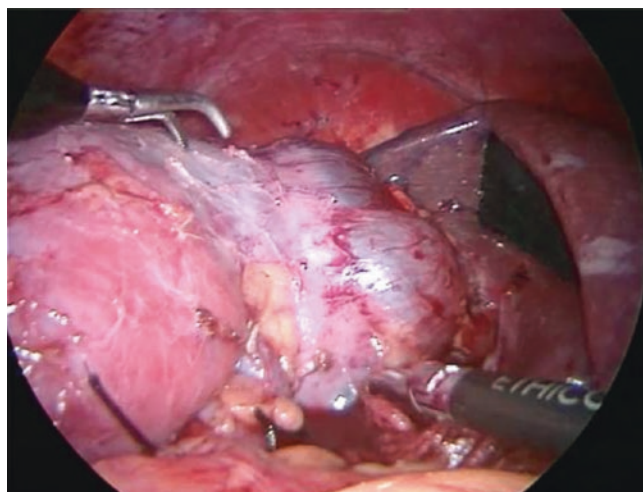


Fig 11.26 Pale upper polar parenchyma seen

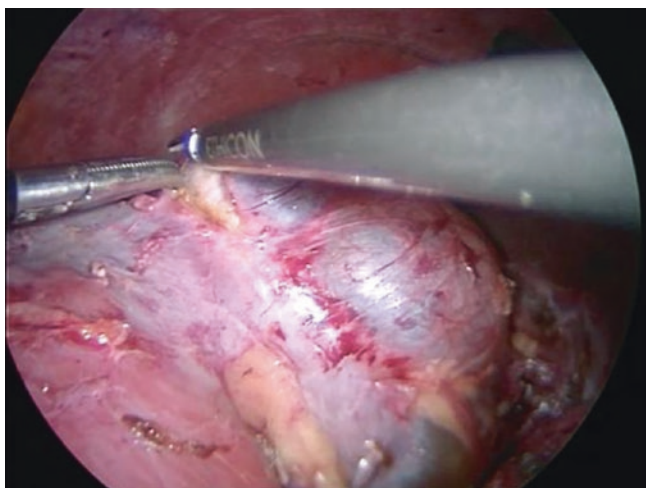


Fig 11.27 Parenchymal incision beyond cyst with ultrasonic shears

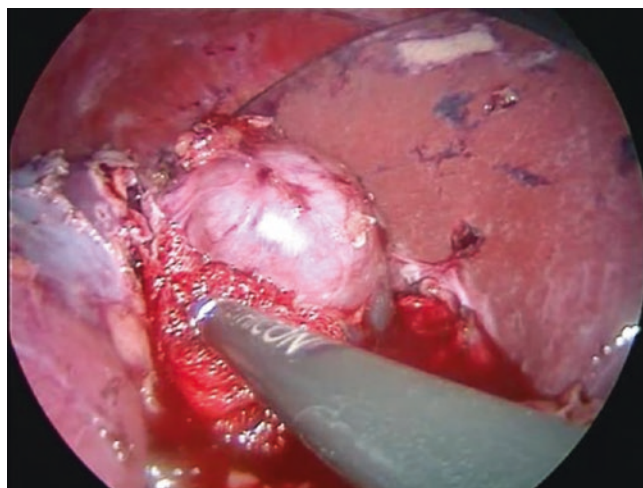


Fig 11.28 Cyst excision in progress

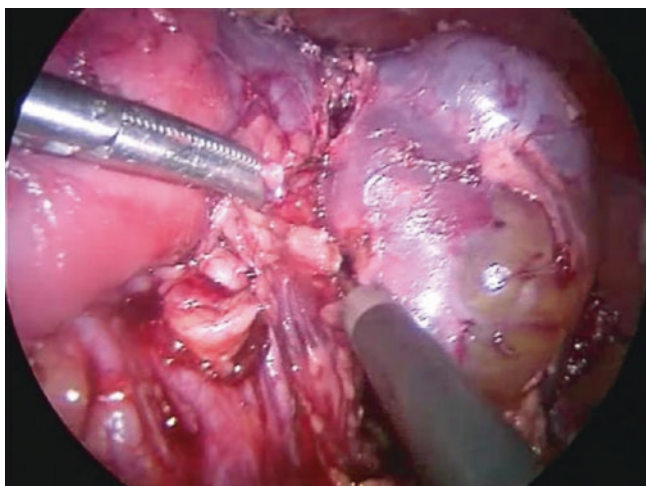


Fig 11.29 Cyst excision in progress

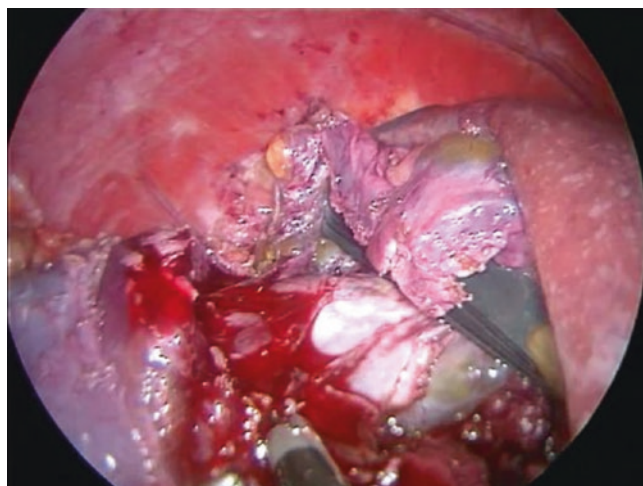


Fig 11.30 Cyst excision in progress

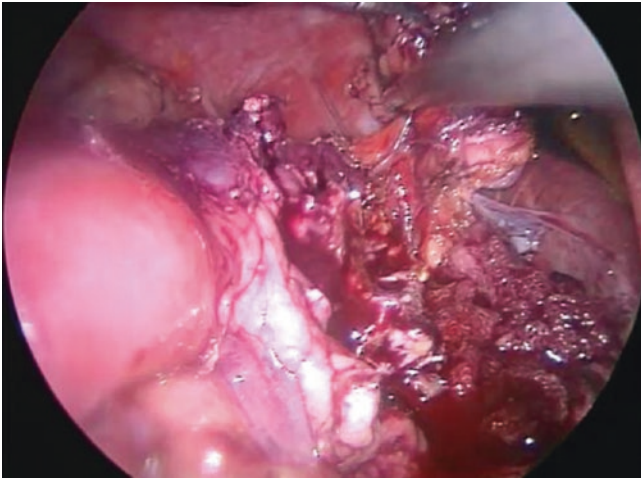


Fig 11.31 Excision almost completed

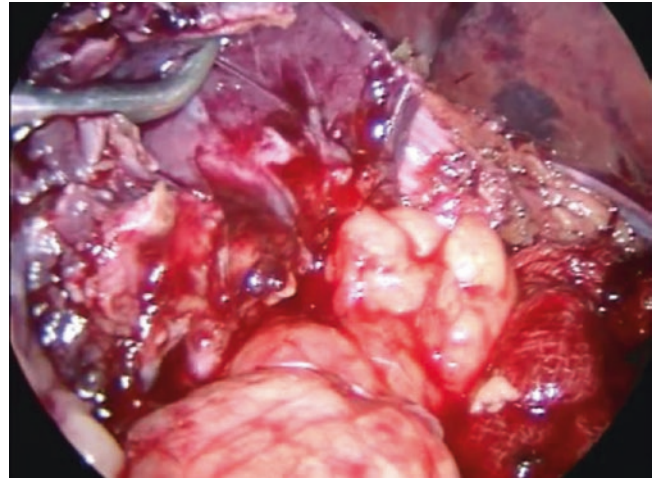


Fig 11.32 Parenchymal bed after cyst excision

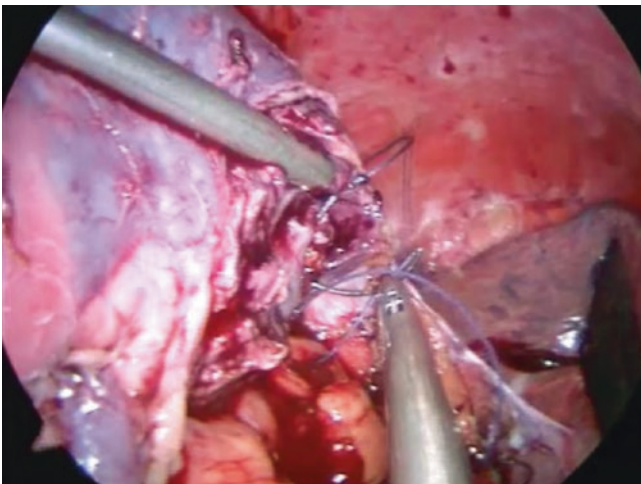


Fig 11.33 Parenchymal closure started

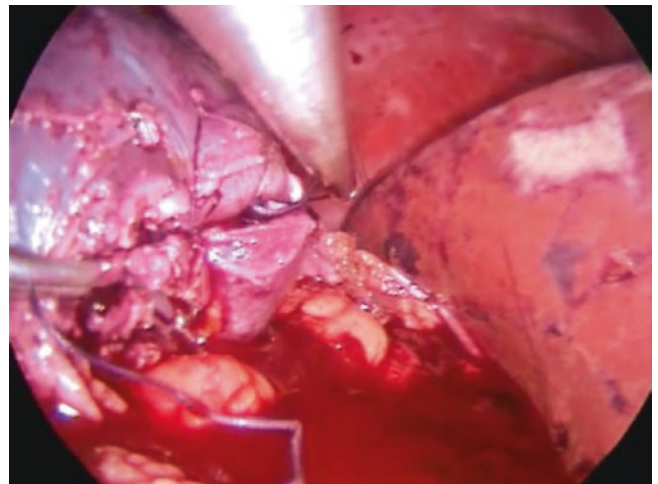


Fig 11.34 Parenchymal closure in progress

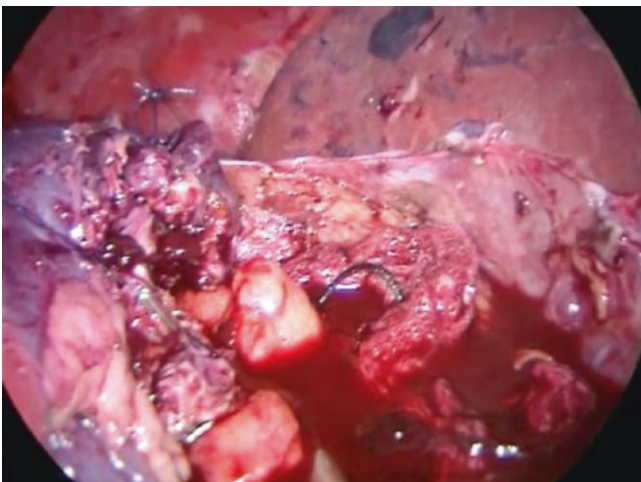


Fig 11.35 Parenchymal closure in progress

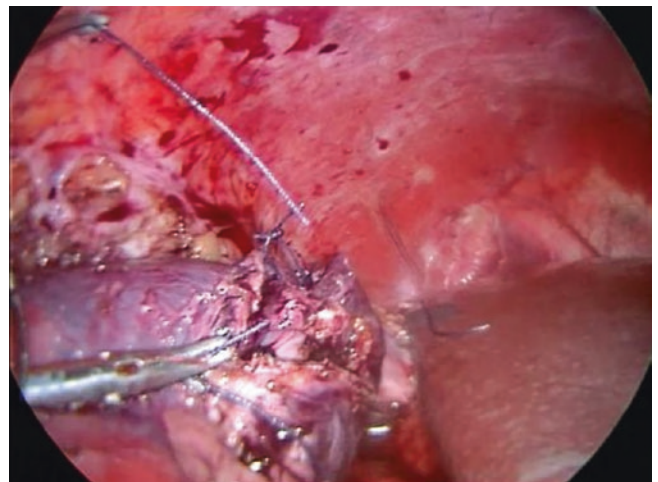


Fig 11.36 Parenchymal closure in progress

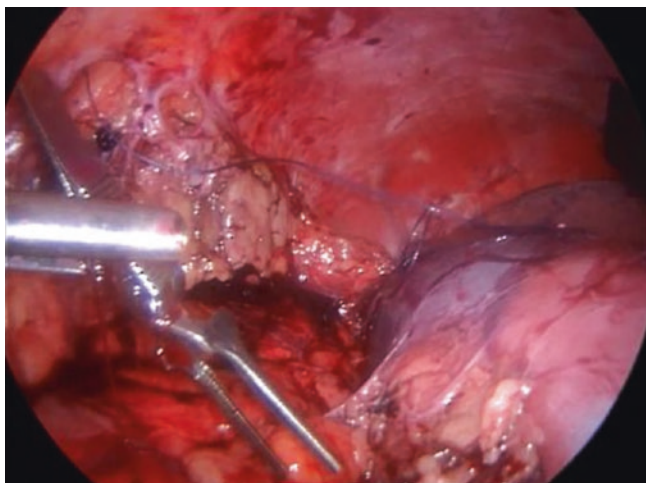


Fig 11.37 Clamp released

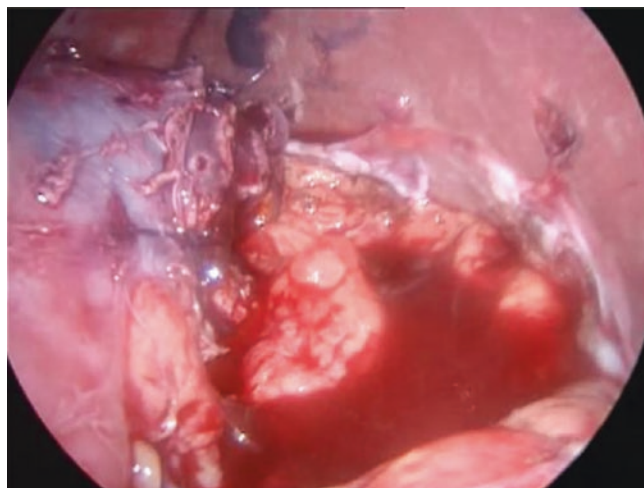


Fig 11.38 Cyst bed after clamp release

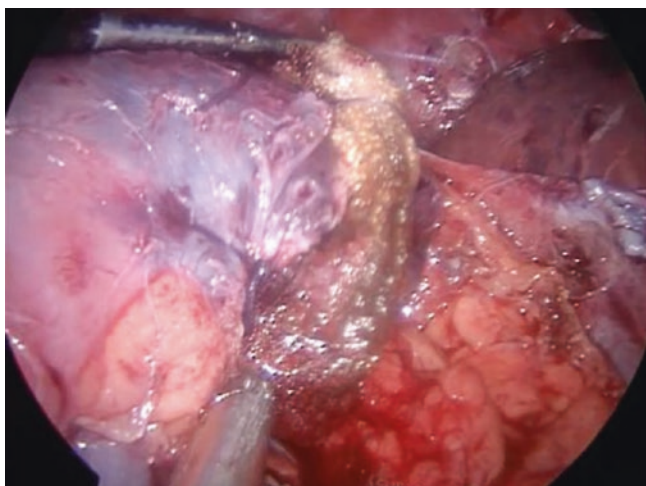


Fig 11.39 Hemostatic bolster application

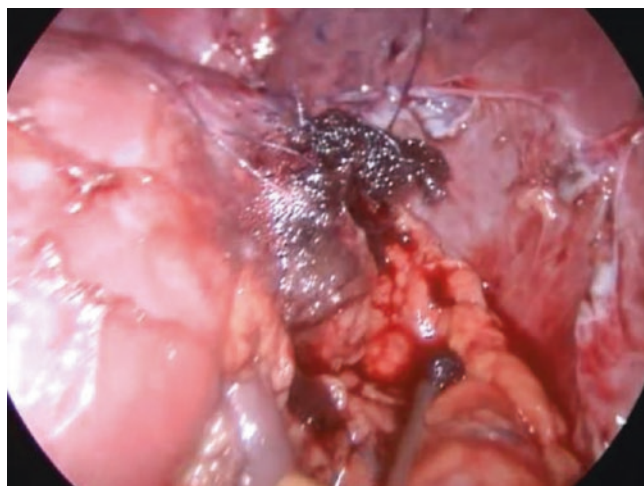

Fig 11.40 Final image after bolster application

References

1. Dunn MD, Clayman RV. Laparoscopic management of renal cystic disease. *World J Urol.* 2000;18:272–7.
2. Pearle MS, Traxer O, Cadeddu JA. Renal cystic disease: laparoscopic management. *Urol Clin North Am.* 2000;27:661–73.
3. Roberts WW, Bluebond-Langner R, Boyle KE, et al. Laparoscopic ablation of symptomatic parenchymal and peripelvic renal cyst. *Urology.* 2001;58:165–9.
4. Rubenstein SE, Hulbert JC, Pharand D, et al. Laparoscopic ablation of symptomatic renal cyst. *J Urol.* 1993;150:1303–6.

Kallappan Senthil, N. Sivasankaran, Anandan Murugesan,
Mizar G. Pai, and Manickam Ramalingam

12.1 Introduction

Generally, laparoscopy is offered to patients with renal pelvic stone in ectopic kidney and those who need adjunctive procedures like pyeloplasty [1]. Laparoscopy avoids nephron injury and is advantageous in children with large stone burden. PCNL may require more than one puncture in such situations [2].

A CT scan is a useful investigation to determine the exact relationship of the stone to the pelvis and calyces.

12.2 Technique

12.2.1 Retroperitoneoscopic Pyelolithotomy [1, 2]

Preliminary cystoscopy with retrograde pyelogram is done. A guide wire is placed in the pelvis and a stent may be placed just below the pelvis. Provision for C-arm screening will help in locating the position of the calculus intraoperatively.

The patient is then positioned in the true lateral (90° kidney) position and strapped. After creating the retroperitoneal space (technique described elsewhere), four ports are inserted. A 10 mm camera port is inserted below the tip of the 12th rib, two 5 mm ports are inserted for hand instruments, one in the anterior axillary line an inch above the iliac crest and the other below the costal margin.

An additional 10 mm port is inserted posterior to the telescope port for suction or retraction. The ureter is identified in the groove medial to the psoas by its characteristic peristalsis and arborisation of the vessels. It is then carefully traced up to the pelvis taking care not to injure any lower polar vessels. Inflammatory fat may be a hindrance to the dissection. The pelvis is carefully mobilized. C arm imaging may be useful at this juncture to decide the exact site of incision (pyelotomy). One of the instruments may be held at the presumed site of the stone and all other instruments are moved away prior to C-arm image intensifier screening. Pyelotomy is made using an endoknife or curved scissors. The stone is maneuvered out using a right-angled dissector and double J stent is advanced over the preplaced guide wire. The pyelotomy is then closed with interrupted 3-0 or 4-0 vicryl sutures. The vicryl stay sutures are used to close the muscle layers of the telescope port. A tube drain is left in place through the lower port.

12.2.2 Transperitoneal Pyelolithotomy

The preliminary steps are same as in laparoscopic pyeloplasty. Once the calculus is identified, pyelotomy is done and stone retrieved. Pyelotomy is closed with interrupted or continuous absorbable sutures and drain is placed.

12.2.2.1 Special Situations

- In cases where a stent was not preplaced, a guide wire with stent is passed through a Veress needle placed cranially in the hypochondrium such that it is directed towards the pyelotomy and ureter.

K. Senthil (✉)
Urology Clinic, Gowtham Annexe, Coimbatore, India
e-mail: senthilsatya@hotmail.com

N. Sivasankaran • M.G. Pai
Urology Clinic, 3/1054, Gowtham Annexe, Avinashi Road,
Coimbatore 641018, India
e-mail: sivasankaranpillai@gmail.com; mizargpai@yahoo.co.in

A. Murugesan
Department of Urology, PSG Institute of Medical Sciences
and Research, Peelamedu, Coimbatore, Tamil Nadu, India
e-mail: anandan79@gmail.com

M. Ramalingam
PSG Hospitals,
Coimbatore, India
e-mail: uroram@yahoo.com

- Ureteroscope through the cranially placed port also may be used to insert the stent.
- In intrarenal pelvis, dissection is continued into the pelvis by lifting the posterior lip and then through the pyelotomy, flexible cystoscope/nephroscope may be inserted to find the stone and basket it [3, 4].
- Flexible cystoscope/nephroscope may also be used to retrieve calculi that migrate from the pelvis to the calyces.
- C-arm imaging is used to verify the completeness of stone clearance.

12.3 Transperitoneal Pyelolithotomy

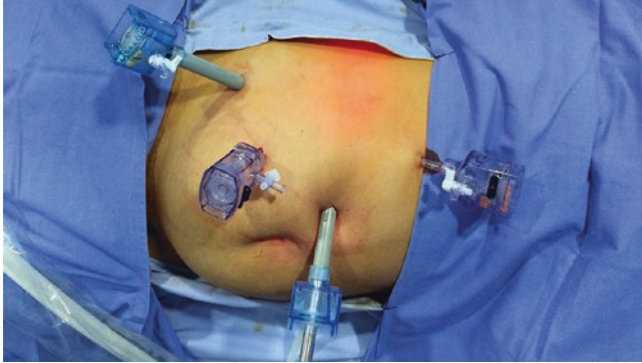

Fig. 12.1 Port position for right pyelolithotomy

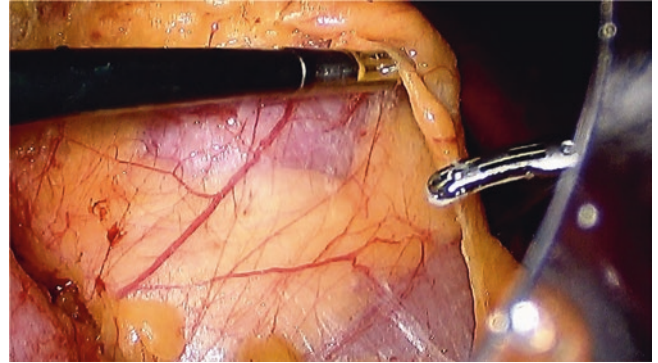


Fig. 12.2 Right colon being mobilised medially

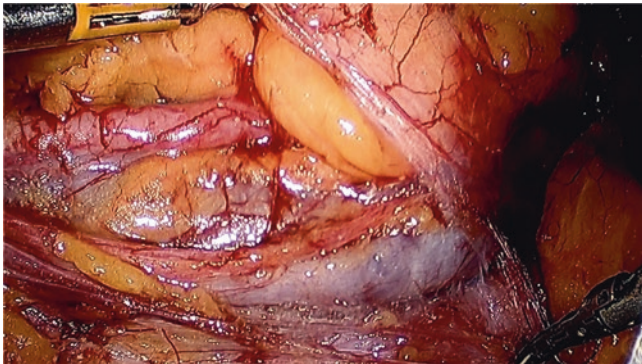


Fig. 12.3 Retroperitoneum dissected; ureter and IVC clearly made out

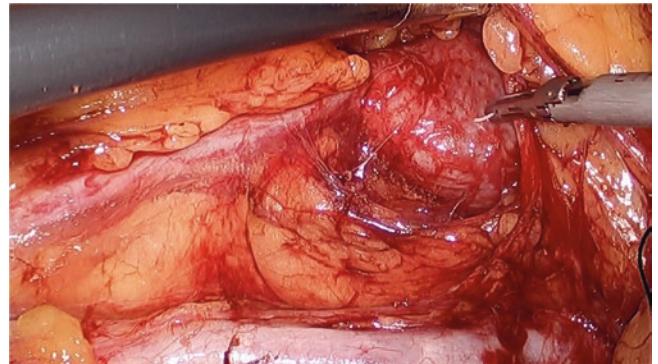


Fig. 12.4 Ureter traced till pelvis and pelvis dissected

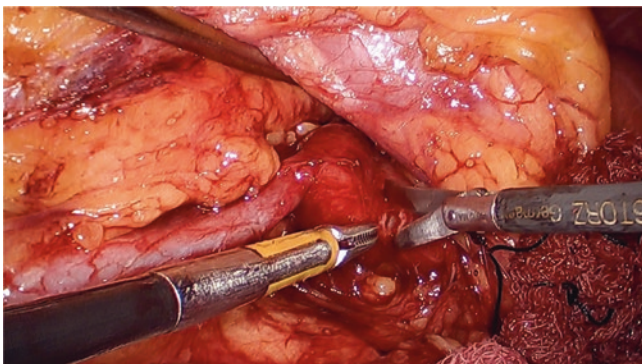


Fig. 12.5 Transverse pyelotomy started

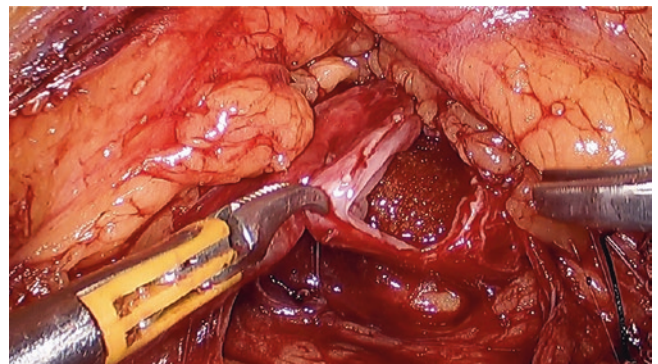


Fig. 12.6 Pyelotomy completed and stone visualised

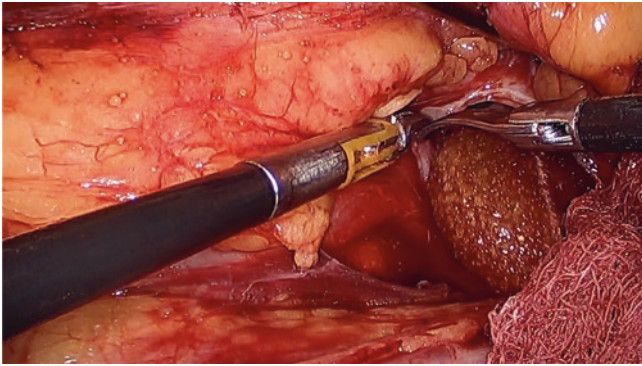


Fig. 12.7 Stone being extracted

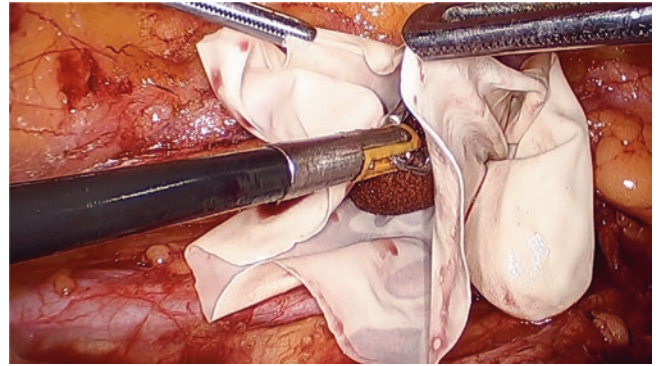


Fig. 12.8 Stone being placed in glove bag

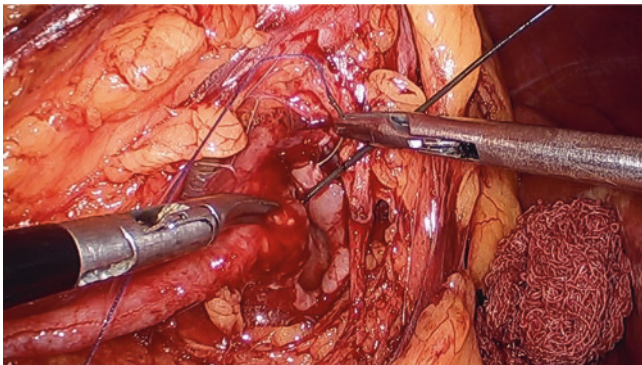


Fig. 12.9 Pyelotomy closure with 4-0 vicryl suture started

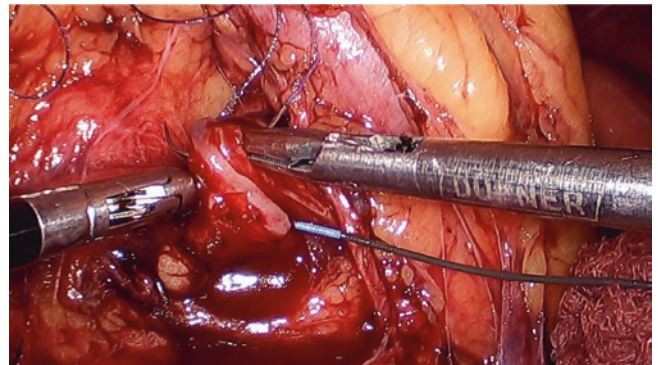


Fig. 12.10 Pyelotomy closure in progress

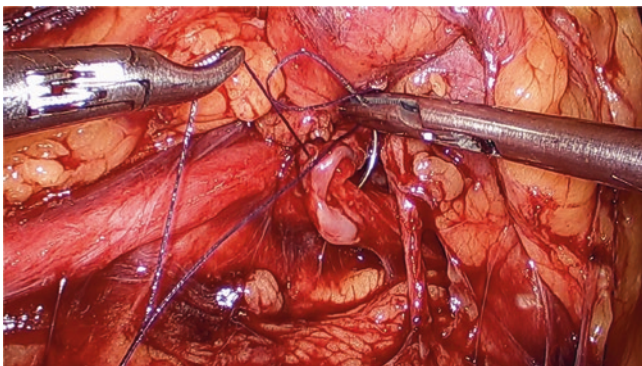


Fig. 12.11 Pyelotomy closure in progress

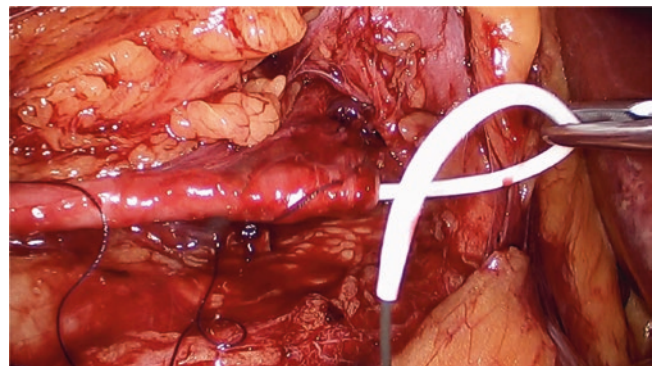


Fig. 12.12 Stent being inserted retrograde through preplaced guidewire

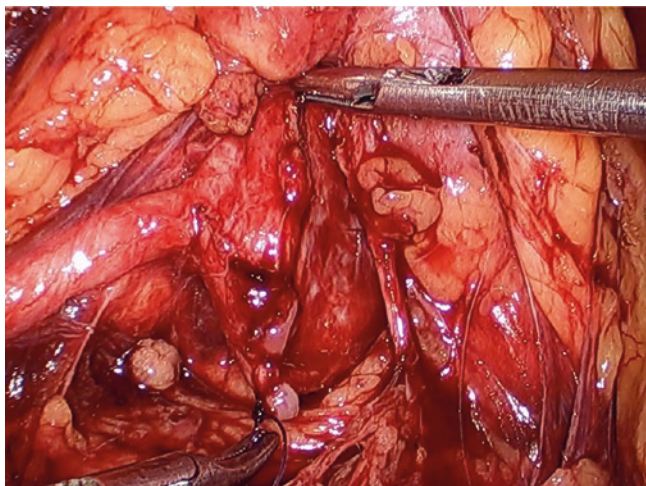


Fig. 12.13 Pyelotomy closure completed

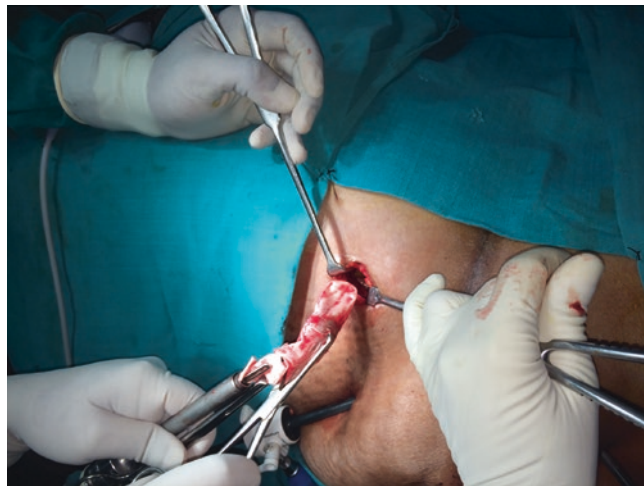

Fig. 12.14 Fingerstall of the glove with the stone, being extracted through one of the port sites

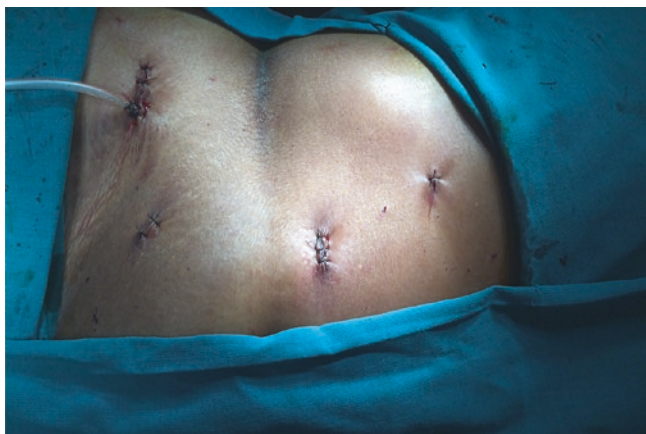

Fig. 12.15 Drain site

12.4 Retroperitoneoscopic Pyelolithotomy

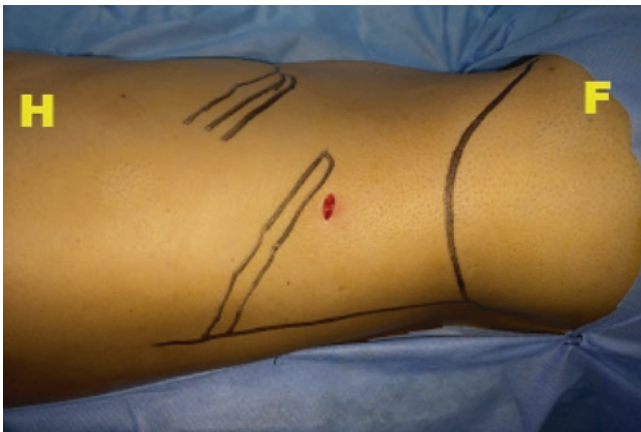

Fig. 12.16 Ports position for right pyelolithotomy

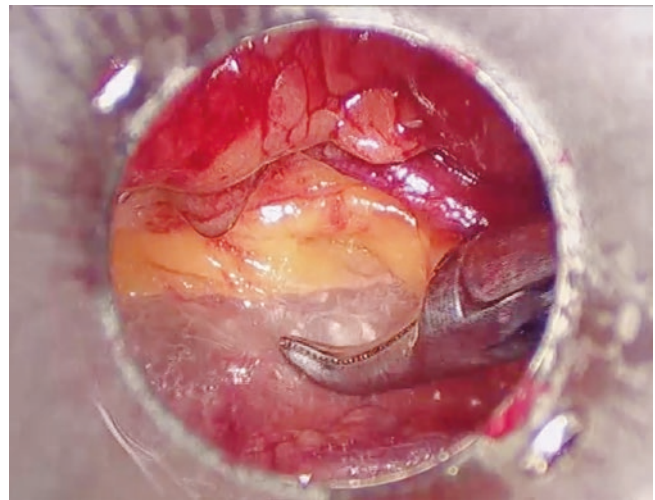


Fig. 12.17 Retroperitoneal space developed for right pyelolithotomy

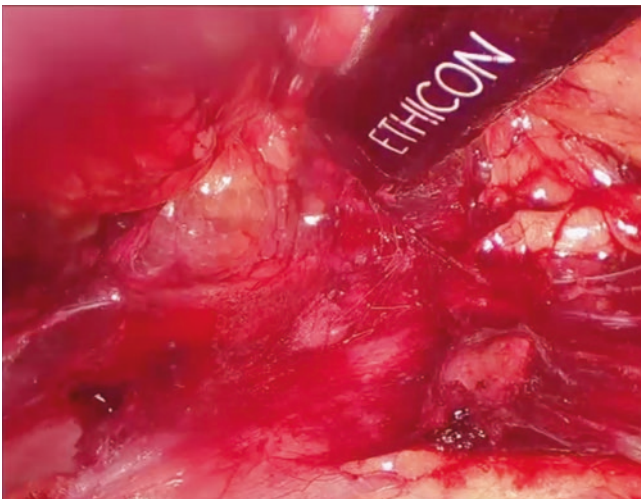


Fig. 12.18 Dissection along anteromedial aspect of psoas to identify ureter

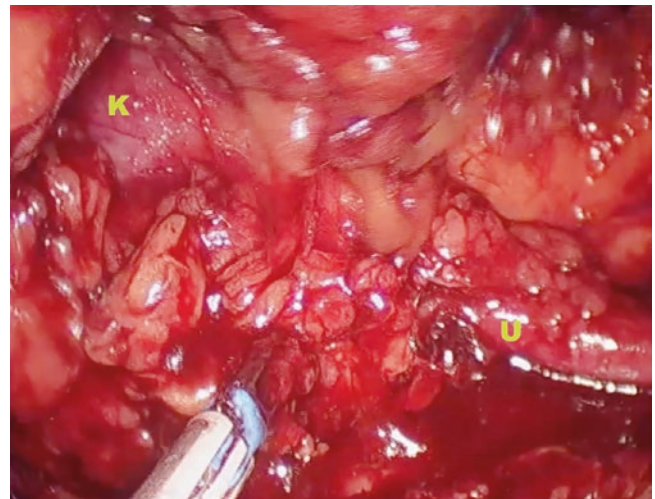


Fig. 12.19 Ureter dissected proximally towards pelvis

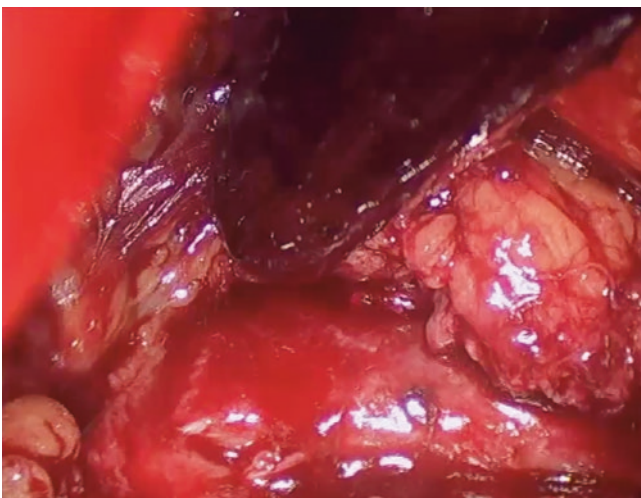


Fig. 12.20 Thick fat around pelvis dissected

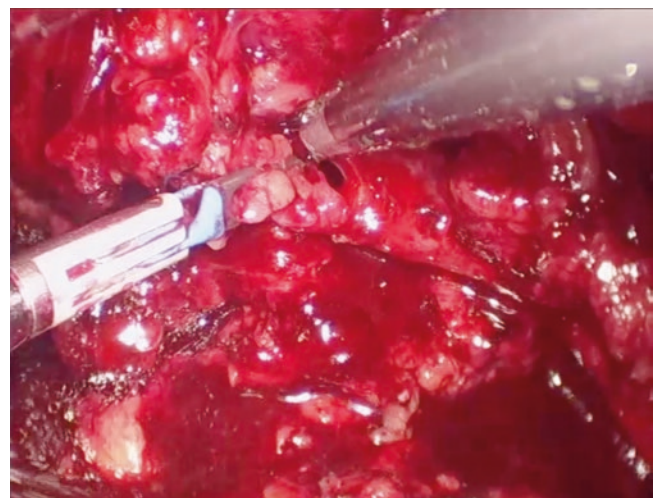


Fig. 12.21 Pyelotomy in progress

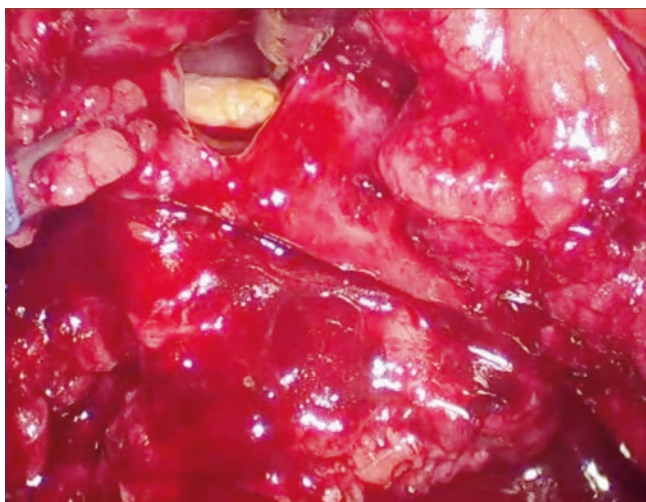


Fig. 12.22 Stone visualised through pyelotomy

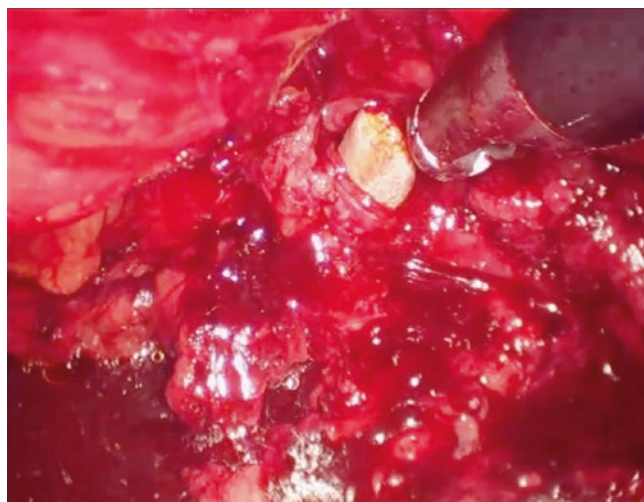


Fig. 12.23 Stone removed with grasper

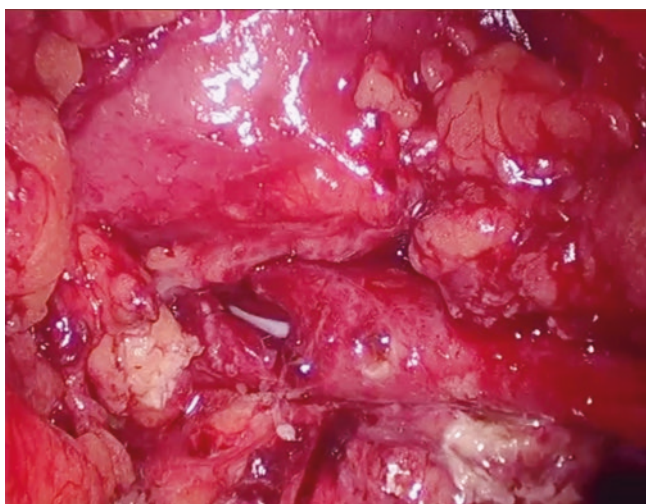


Fig. 12.24 Antegrade stenting done

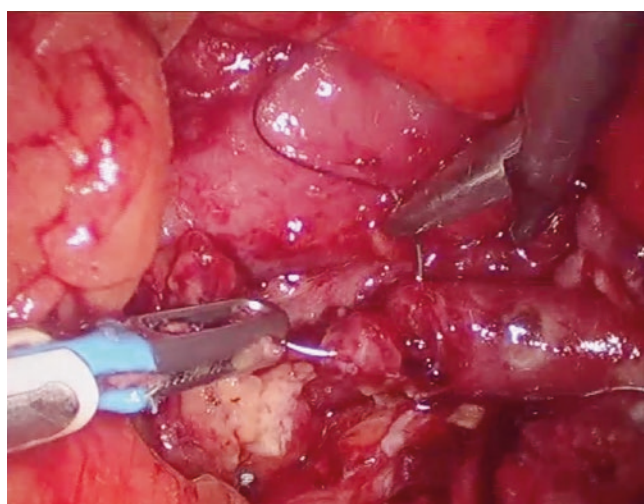


Fig. 12.25 Pyelotomy closure with 4-0 vicryl started

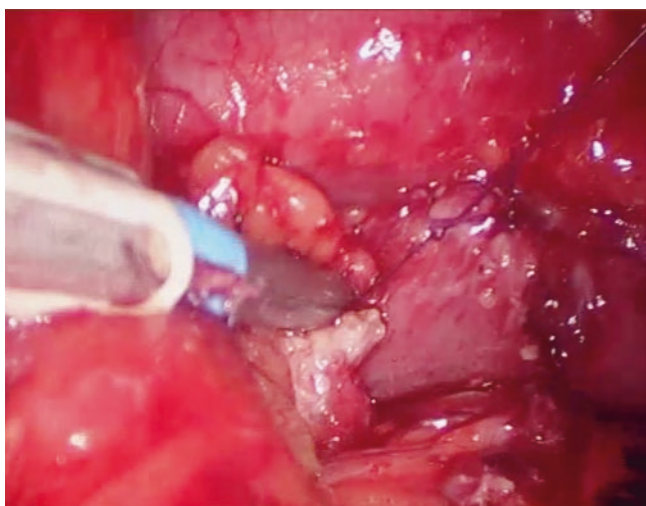


Fig. 12.26 Pyelotomy closure in progress

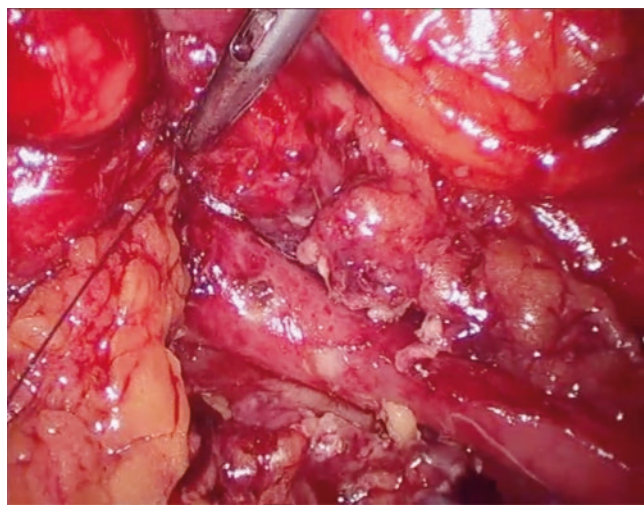


Fig. 12.27 Pyelotomy closure completed and perinephric fat tacking done

References

1. Kijvikai K. The role of laparoscopic surgery for renal calculi management. *Ther Adv Urol.* 2011;3(1):13–8.
2. Wang X, Li S, Liu T, Guo Y, Yang Z. Laparoscopic pyelolithotomy compared to percutaneous nephrolithotomy as surgical management for large renal pelvic calculi: a meta-analysis. *J Urol.* 2013;190(3):888–93.
3. Gaur DD, Trivedi S, Prabhudesai MR, Gopichand M. Retroperitoneal laparoscopic pyelolithotomy for staghorn stones. *J Laparoendosc Adv Surg Tech A.* 2002;12(4):299–303.
4. Ramalingam M, Senthil K, Selvarajan K, Pai MG. Laparoscopic pyelolithotomy in children (abstract). *J Endourol.* 2004;18:A228.

Nasser Simforoosh and Mohammad Hadi Radfar

13.1 Indication

Management of complete staghorn kidney stones is a urological challenge. Due to the high recurrence rates, complete stone clearance is of crucial importance in staghorn stones. Anatomic nephrolithotomy is an option in cases where, less invasive procedures such as percutaneous nephrolithotomy (PCNL) and extracorporeal shock wave lithotripsy (SWL) cannot achieve complete clearance in a reasonable number of sessions. Laparoscopy can duplicate the open technique, and provide the inherent advantages of minimally invasive procedure [1–3].

Deger et al. published the first case report of laparoscopic anatomic nephrolithotomy in 2004 [4]. We reported an initial series in 2008 and a complementary series of 24 patients who underwent the procedure in 2013 [5, 6].

13.2 Preliminary Evaluation

Patients should undergo routine laboratory evaluation, ultrasonography, and intravenous urography (IVU)/computed tomography (CT) scan.

13.3 Surgical Technique

The patient is placed in the lateral decubitus position with minimal flexion of the operating table and is supported by adequate padding. We use a four-port transperitoneal approach.

The white line of Toldt is incised, the colon (and duodenum on the right side) is mobilized medially, and the spleen/liver is retracted superiorly. Gerota's fascia is incised and the kidney is fully mobilized within this fascia. Both the renal artery and vein are completely dissected. Renal artery is clamped using one or two bulldog clamps. Renal parenchyma and the collecting system are sharply incised along Brodel's avascular plane. The stone is maneuvered and removed as completely as possible. The collecting system is irrigated with normal saline. Intraoperative endoprobe ultrasonography can be used to check for residual stone. Both the collecting system and renal cortex are repaired with one row of polyglactin 2/0 (31 mm needle) running sutures. We do not close the collecting system separately. Instead of tying knots, sutures are buttressed by applying Hem-o-lok® clips. Clips are placed after each throw of running suture. Then, the bulldog clamp/s is released. The nephrotomy site is examined carefully to ensure hemostasis. Using an endobag, the stone is extracted from the abdominal cavity. An external drain is placed. A double-J stent can be placed.

13.4 Conclusion

Laparoscopic anatomic nephrolithotomy (LAN) could be an acceptable alternative option in select patients having complete staghorn stones, with an acceptable stone-free rate and complications. In brief, patients with one-piece large staghorn stones, particularly when they are not appropriate candidates for PCNL, could be considered for LAN.

N. Simforoosh, MD (✉) • M.H. Radfar, MD
Department of Urology, Urology and Nephrology Research Center,
Shahid Labbafinejad Hospital, Shahid Beheshti University of
Medical Sciences, 9th Boostan, Pasdaran, Tehran 166666311, Iran
e-mail: simforoosh@iurtc.org.ir; mhadirad@yahoo.com

13.5 Laparoscopic Anatomic Nephrolithotomy

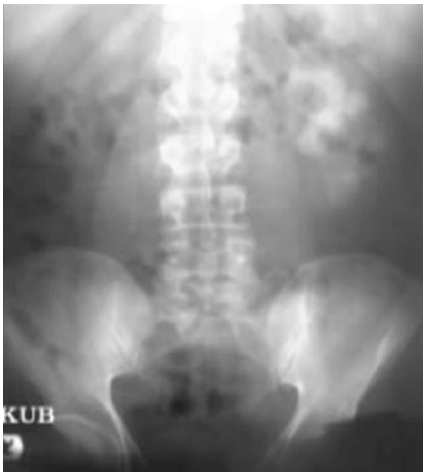

Fig. 13.1 CT image showing staghorn calculus

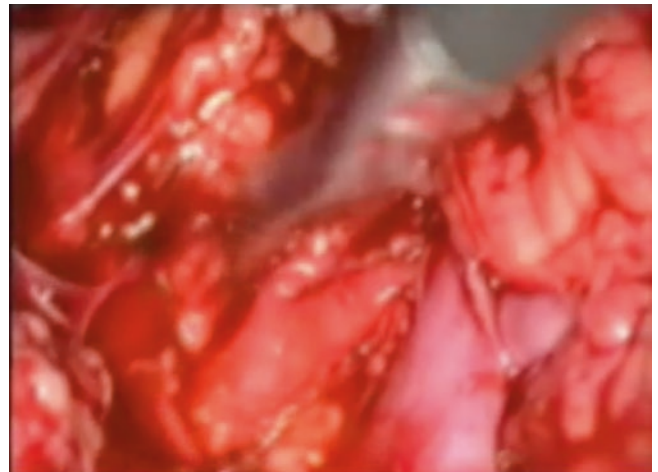


Fig. 13.2 Peritoneotomy over the kidney for bowel reflection

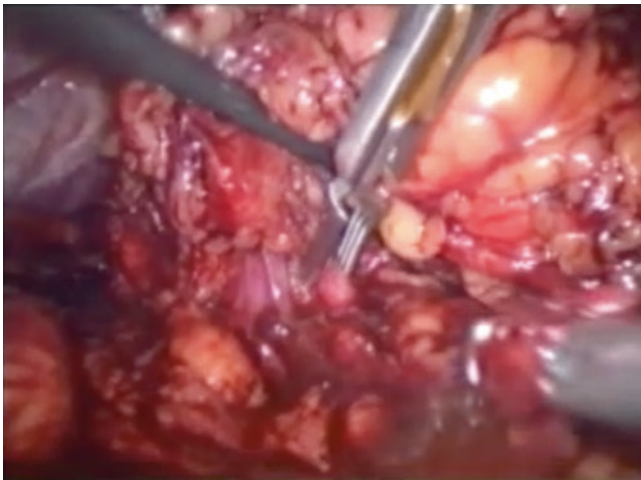


Fig. 13.3 Right colon reflection in progress

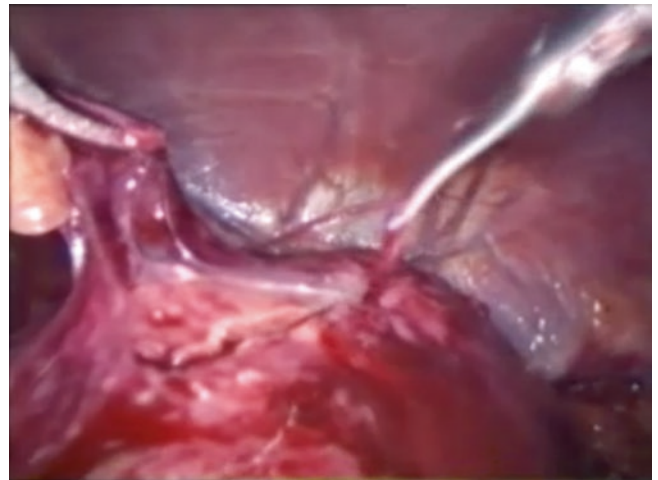


Fig. 13.4 Duodenum being kocherised

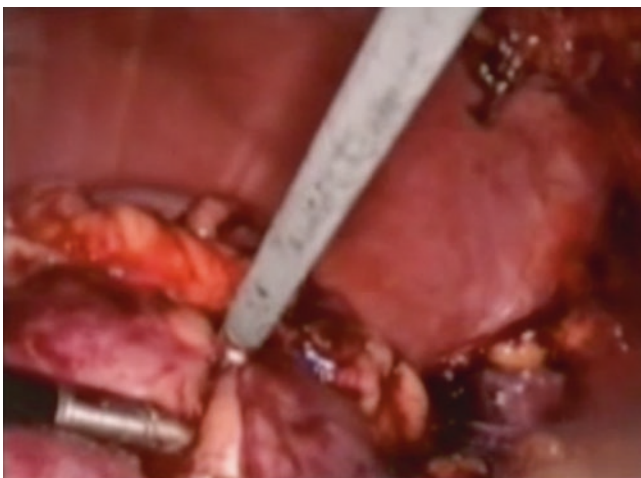


Fig. 13.5 Retroperitoneum dissected to identify the ureter

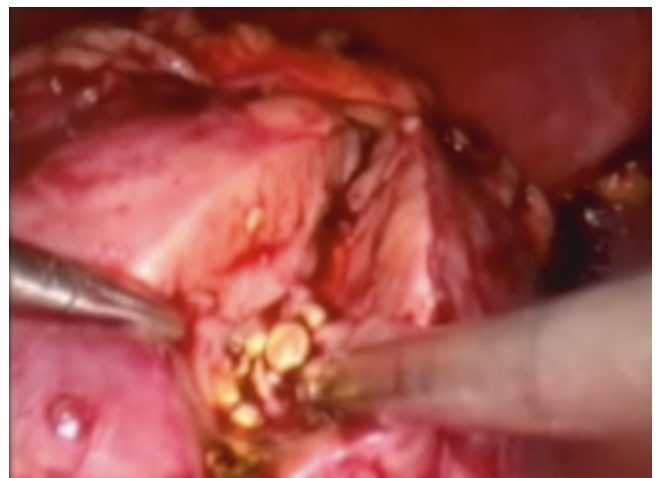


Fig. 13.6 Gerota's fascia being opened

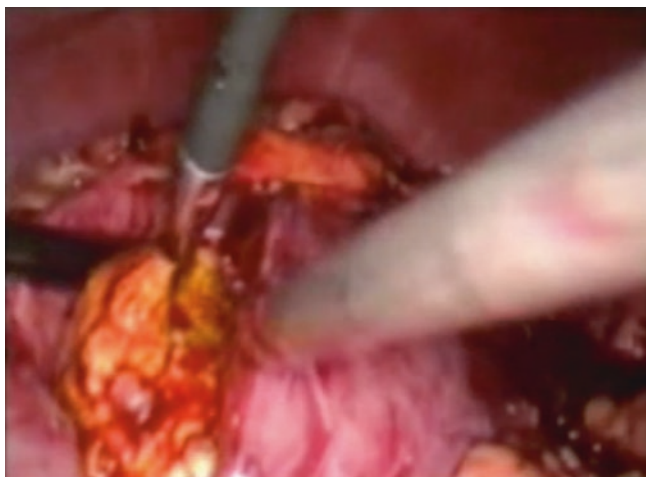


Fig. 13.7 Perinephric fat removed all around the kidney

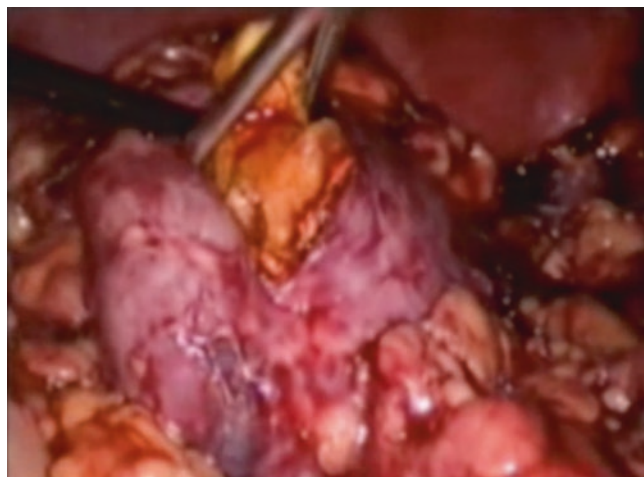


Fig. 13.8 Upper pole being released

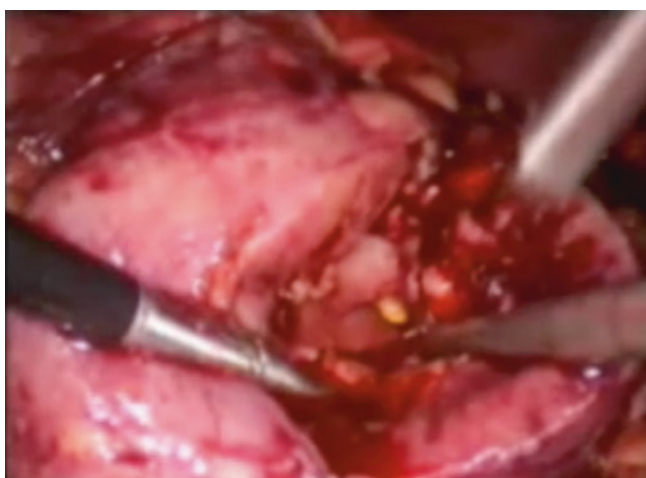


Fig. 13.9 Hilar dissection in progress

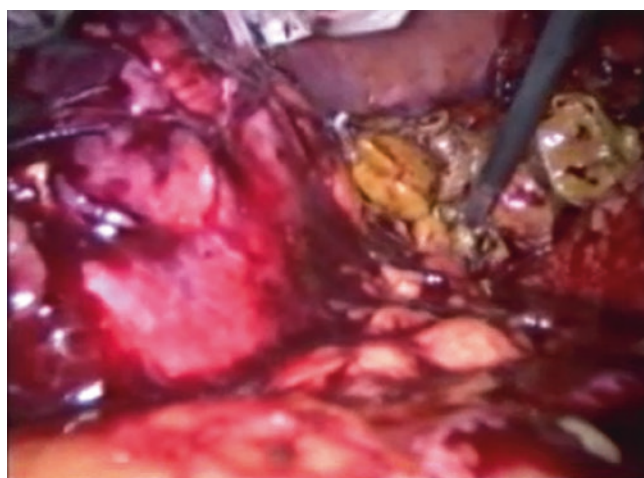


Fig. 13.10 Renal hilum dissected posteriorly to facilitate to facilitate clamping; renal pedicle dissected all around

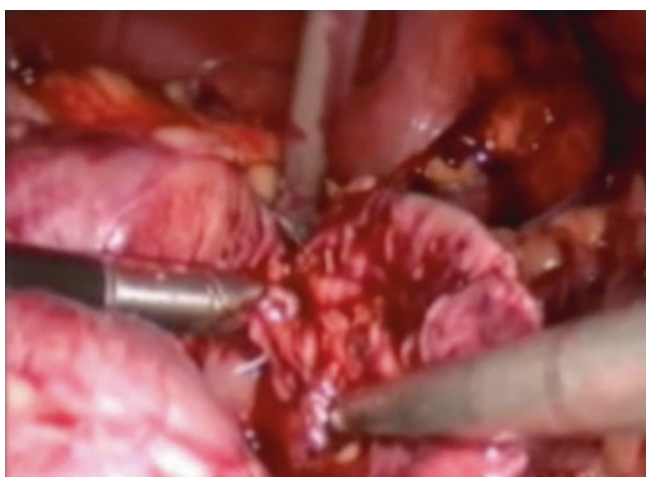


Fig. 13.11 Bulldog clamp applied around the hilum

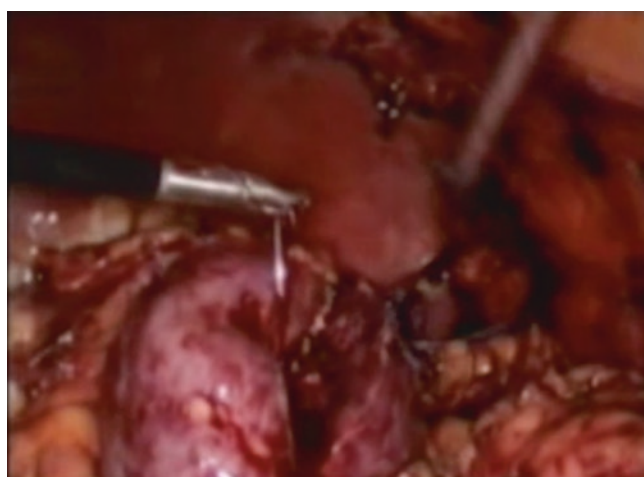


Fig. 13.12 Incision marked along the Brodel's line

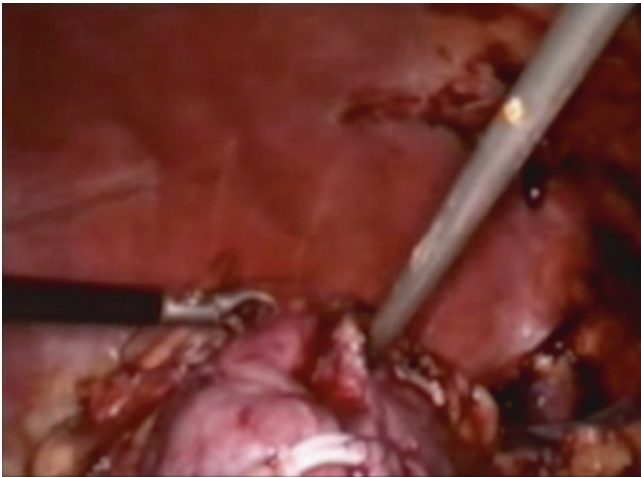


Fig. 13.13 Nephrotomy started

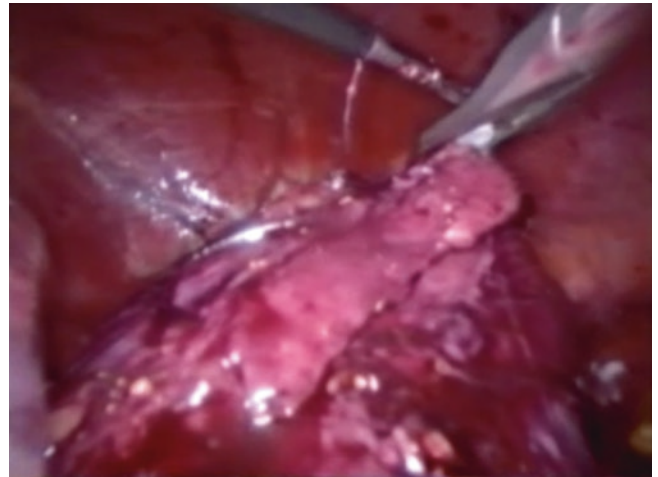


Fig. 13.14 Nephrotomy extended to the collecting system

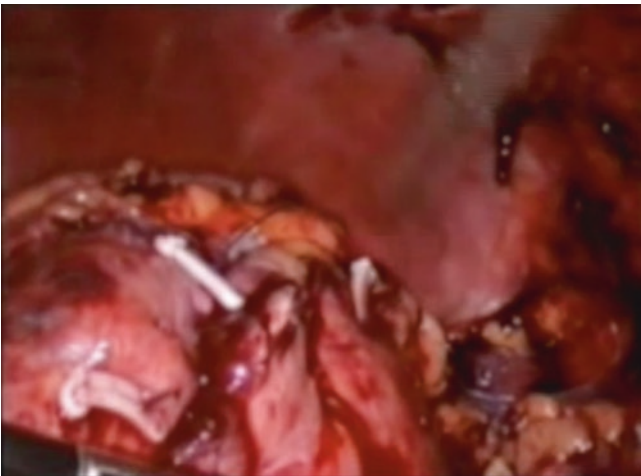


Fig. 13.15 Pyelocalyceal system opened and calculus seen

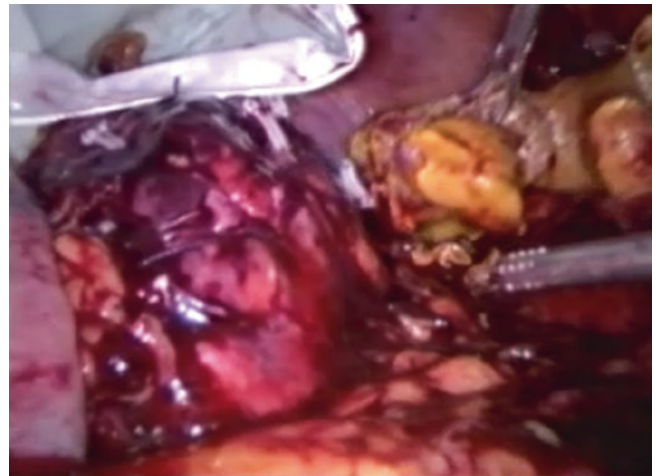


Fig. 13.16 Calculus being extracted

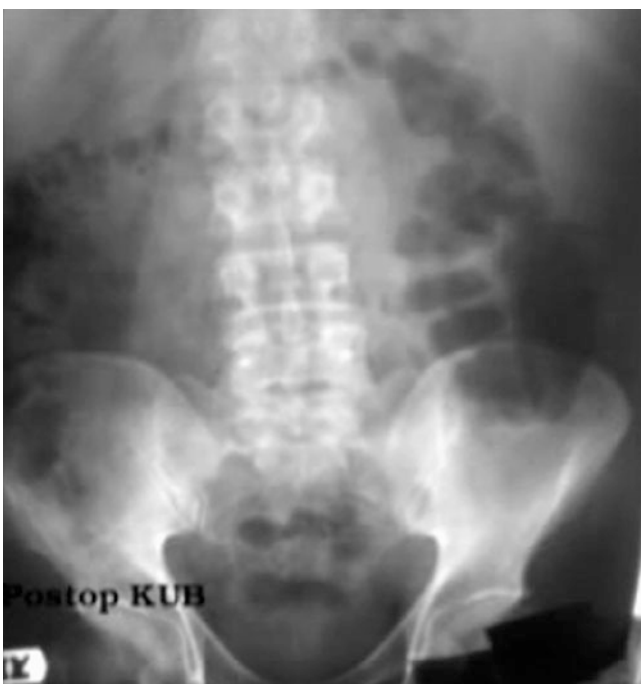

Fig. 13.17 Wash given to clear secondary stones if any

References

1. Miller SD, Ng CS, Streem SB, et al. Laparoscopic management of caliceal diverticular calculi. *J Urol*. 2002;167:1248–52.
2. Lopes Neto AC, Korkes F, Silva 2nd JL, et al. Prospective randomized study of treatment of large proximal ureteral stones: extracorporeal shock wave lithotripsy versus ureterolithotripsy versus laparoscopy. *J Urol*. 2012;187:164–8.
3. Nouralizadeh A, Simforoosh N, Soltani MH, et al. Laparoscopic transperitoneal pyelolithotomy for management of staghorn renal calculi. *J Laparoendosc Adv Surg Tech A*. 2012;22:61–5.
4. Deger S, Tuellmann M, Schoenberger B, Winkelmann B, Peters R, Loening SA. Laparoscopic anatomic nephrolithotomy. *Scand J Urol Nephrol*. 2004;38(3):263–5.
5. Simforoosh N, Aminsharifi A, Tabibi A, Noor-Alizadeh A, Zand S, Radfar MH, Javaherforooshzadeh A. Laparoscopic anatomic nephrolithotomy for managing large staghorn calculi. *BJU Int*. 2008;101(10):1293–6.
6. Simforoosh N, Radfar MH, Nouralizadeh A, Tabibi A, Basiri A, Mohsen Ziaee SA, Sarhangnejad R, Abedinzadeh M. Laparoscopic anatomic nephrolithotomy for management of staghorn renal calculi. *J Laparoendosc Adv Surg Tech A*. 2013;23(4):306–10.

Howard M.H. Lau, Peter Penkoff, Nian Zeng,
and Yinong Niu

14.1 Transperitoneal Approach

14.1.1 Background

Renal cell carcinoma (RCC) has historically been managed by radical nephrectomy (RN). The wide spread availability and use of imaging modalities such as computed tomography (CT) and magnetic resonance imaging (MRI) has lead to early diagnosis and stage migration of RCC. Currently most lesions are diagnosed as incidental small renal masses (SRM). SRMs are defined as solid renal tumors that enhance on CT and MRI and are suspected of being renal cell carcinomas. They are generally low-stage and relatively small ($d < 4$ cm or cT1a) at presentation [1].

In the last decade, nephron-sparing surgery (NSS) has been popularized and encouraged. The indications for NSS according to the European Association of Urology (EAU) guidelines are divided as follows: (1) absolute – anatomic or functional solitary kidney, (2) relative – functioning opposite kidney that is affected by a condition that might impair renal function in the future e.g. diabetes, hypertension; hereditary tumours also fall in this category, and (3) elective – localised unilateral RCC with a healthy contralateral kidney. Partial nephrectomy (PN) involves complete removal of tumour from the kidney while preserving as much renal parenchyma as possible. It can be performed as an open (OPN), laparoscopic (LPN) and more recently robotic (RPN). This chapter will describe the steps in

performing LPN. Currently PN is the gold standard for the treatment of T1a (< 4 cm) renal tumours [2, 3]. In carefully selected patients and in specialised centres where surgical expertise is available the indications for PN have expanded to include T1b tumours (4–7 cm) [4–7].

OPN has been the reference standard for nephron-sparing procedure due to larger numbers and longer follow up. At centres lacking advanced laparoscopic expertise, OPN is still the procedure of choice for NSS. However, where laparoscopic expertise is available, LPN is a routine procedure, with excellent outcomes similar to OPN [8–10]. LPN has been successfully performed in single kidneys [11] and is also feasible in central and hilar tumours in expert hands [12, 13]. Robotic surgery can reduce the technical difficulty in partial nephrectomy but will not be discussed in this chapter.

Advantages of PN include preservation of renal function, which decreases the risk of chronic kidney disease, and as shown in some studies improves overall survival compared to radical nephrectomy, predominantly in patients younger than 65 years of age [14, 15]. Factors influencing renal function in the post operative period are: preoperative renal function, volume of removed renal parenchyma and ischaemia time. Only the last factor is entirely dependent on surgery. In the long term other factors can contribute to worsening renal function e.g. diabetes, hypertension, medication etc.

Potential disadvantages of PN in comparison with RN can include higher incidence of postoperative haemorrhage, urine leak, positive surgical margin and local recurrence. There are several reports showing low recurrence rates after PN – 1–3 % for T1a tumours [17]. Large surgical margins have minimal clinical significance with margins of 1 mm being sufficient to prevent local recurrence and disease progression [15]. In the case of positive surgical margins these appear to have minimal impact on survival [18]. Rates of haemorrhage and urine leak during PN also appear to be low in the literature – 2.7 % and 1.9 % respectively [19]. When required these can be successfully managed with super-selective arterial embolization, stenting and percutaneous drainage.

H.M.H. Lau, MBBS (Syd), FRACS (Urol) (✉)
Western Sydney University, Sydney, NSW, Australia
Westmead Private Hospital, Sydney, NSW, Australia
e-mail: profhlau@gmail.com

P. Penkoff, MBBS, FRACS
Westmead Hospital, Sydney, NSW, Australia

N. Zeng • Y. Niu
Chayo Yang Hospital, Beijing, China

Renal hilar clamping provides bloodless field for surgical renorrhaphy but cold and warm ischaemia time (WIT) should be minimised to preserve renal function. The current mean WIT of <14 min is similar to OPN series [20], although the safe maximum of WIT is still debatable [21, 22]. With early unclamping, the author's mean WIT time at present is less than 12 min with more than 300 cases performed to date.

The only randomised control trial comparing PN and RN for tumours <5 cm in size could not definitely show oncologic equivalence or survival benefit between the two procedures [16]. Despite this is generally accepted that partial nephrectomy should be considered in patients with suitable tumours especially in patients younger than 65 year of age.

14.1.2 Technical Aspects of Laparoscopic Partial Nephrectomy

14.1.2.1 Preoperative Imaging

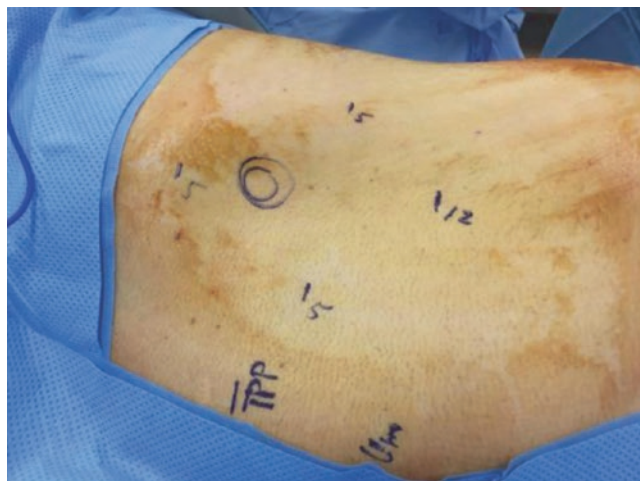
CT scan with IV contrast arterial and venous phase is preferred to image the renal vasculature. In cases where IVC thrombus is suspected MRI scan is the modality of choice. In cases of tumour with venous thrombus partial nephrectomy is not appropriate.

14.1.2.2 Nephrometry Scoring Systems

The PADUA classification [23] and the R.E.N.A.L. [24] score can be useful tools for comparison of surgical outcomes and have been also used to predict potential postoperative complications.

14.1.3 Patient Positioning


Patients are placed on the operating table in a lateral position and the table is flexed in order to increase the distance between the iliac crest and the rib cage. All pressure points are padded. Five millimetre camera port for a 30° laparoscope, 2 cm caudal to transpyloric plane and lateral to rectus abdominis muscle, 5 mm left hand and 10–12 mm right hand working ports are placed for left sided tumours and vice versa for right sided tumours; note the placement of additional 5 mm port between the two working ports which can be used for retraction as well as suction by the assistant.



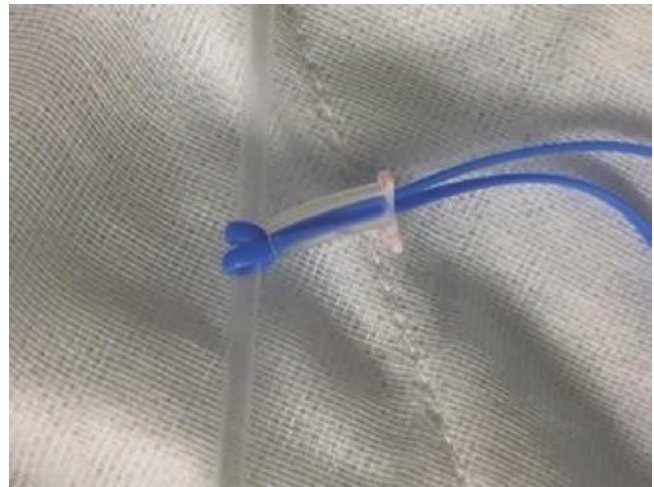Example of port site placement for left sided partial nephrectomy. Patient's head is to the left of the image. Transpyloric plane (TPP), umbilicus (Um) and approximate tumour position also marked on the skin.

14.1.3.1 Clamping of Vessels

Following mobilisation of colon and spleen or liver retraction the renal hilum is dissected to allow hilar clamping. The dissection is limited to the point where sufficient visualisation of the renal artery and vein is achieved to allow safe clamp application. The small amount of perivascular tissue may provide cushioning effect to the vessels and helps to minimise trauma. In the majority of cases arterial clamping alone is sufficient to achieve a bloodless surgical field. In cases with a smaller peripheral tumour selective clamping may be adequate. When clamping the renal artery and vein, it is important to ensure that all arterial branches are clamped as venous obstruction with continuous arterial inflow will lead to bleeding and poor vision. There are different clamping techniques available – laparoscopic “bulldog” clamps (most favoured by the authors), laparoscopic Satinsky clamp and vascular loops.



Laparoscopic Satinsky clamp



Example of using vascular loop to control hilum; the loop is snugged down onto the artery using a 1–2 cm short piece of drain tubing and clipped with Haem-o-lok clip on the other side.

14.1.3.2 Tumour Localisation

Preoperative imaging is used to guide surgical planning and initial dissection. Intracorporeal ultrasound probe is used for finer tumour localisation and identification of tumour margins and depth. Ultrasound scan can be especially useful in cases with dense perinephric fat that is adherent to the renal capsule.

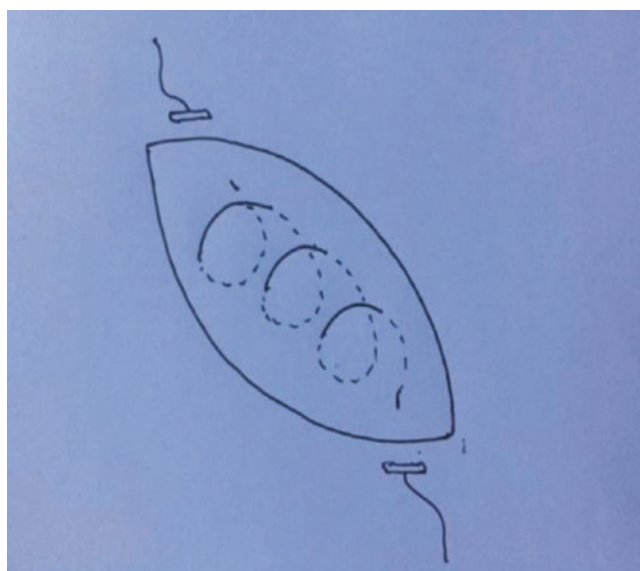
14.1.3.3 Tumour Dissection

A window is made in Gerota's fascia away from the tumour to avoid unexpected tumour spillage. Gerota's fascia is opened in line with the long axis of the kidney which allows subsequent closure over the renorrhaphy. The tumour is isolated circumferentially with the overlying tumour fat left intact. The line of resection is marked with diathermy a few millimetres from the tumour margin, Ultrasound scan is used to ensure accuracy. Cutting with cold scissors is used after clamping of the hilar vessels. This provides sufficient visibility and avoids thermal artefact which can obscure the plane between tumour and normal renal parenchyma. The assistant rests the sucker in the dissection field and uses it as a gentle retractor. This helps to maintain the surgical field blood free.

14.1.3.4 Renorrhaphy Repair

The sliding renorrhaphy technique is used for closure of the tumour defect. A continuous 3-0 PDS suture with Haem-o-lok clips at either end is applied as a first layer at the cortico-medullary junction. After tensioning the suture (sliding the Haem-o-lok clips and pulling on the suture at the same time) the hilar clamp can be released. The authors prefer 3-0 PDS with 26 mm/MH needle due to the ability to slide the clips on it, both from the starting and finishing points. This suture is usually sufficient to control the majority of the bleeding and thus allows early clamp release to minimise WIT. Individual interrupted 3-0 PDS sutures can be applied if required to control bleeding points. These bleeding points will not be visible if the vascular clamp is removed after the second layer is closed.

A second sliding renorrhaphy layer is applied with 3-0 V-loc 26 mm needle 30 cm. Haemostatic agents such as Floseal are used in the resection bed prior to fully tensioning that suture line. Finally, Gerota's fascia is closed over the renal defect to provide another layer for better haemostasis and to prevent renal torsion.



Sliding renorrhaphy stitch for internal layer. Suture should aim at the cortico-medullary junction where most intrarenal vessels travel.

14.1.4 Postoperative Management

Bed rest is recommended overnight, as well as mechanical deep vein thrombosis prophylaxis with TED stockings and calf compressor devices for 24 h. After this period low molecular weight heparin can be commenced. Patients are allowed a clear fluid diet immediately post surgery.

14.1.5 Case 1: Large Upper Pole/Hilar Tumour

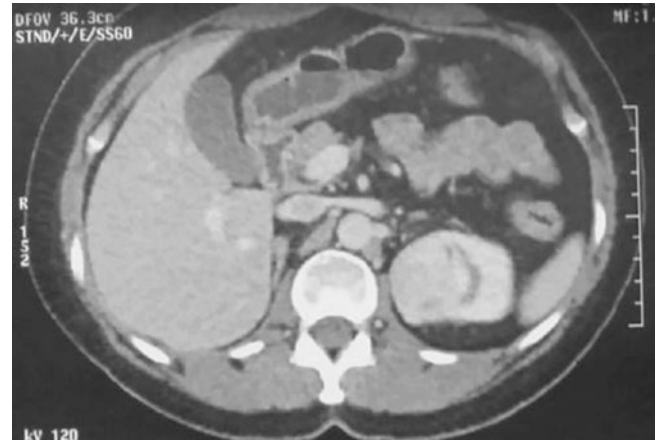


Fig. 14.1 CT scan of a left upper pole/hilar renal tumour

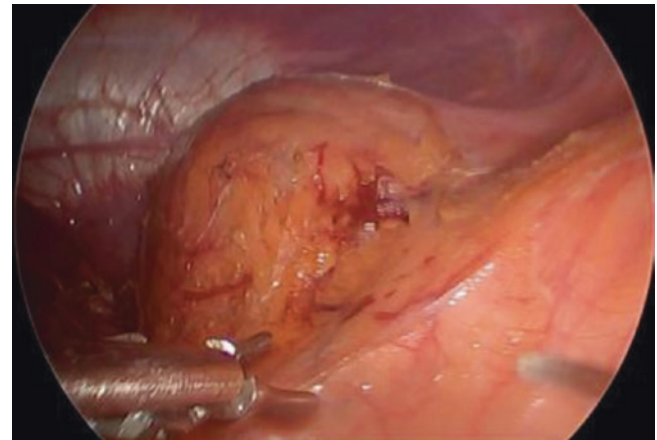


Fig. 14.2 Photo shows a large left upper pole tumor with border reaching renal hilum

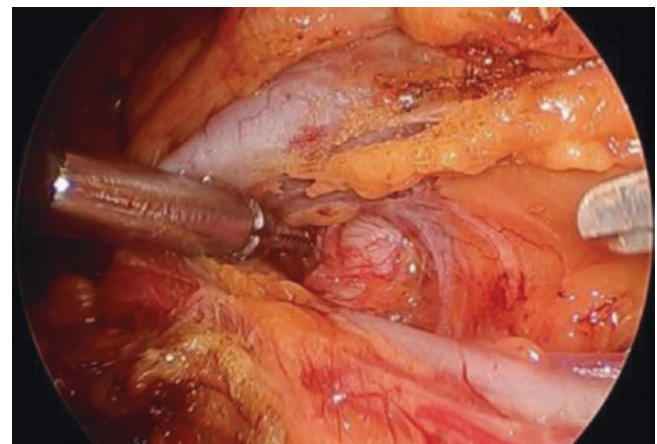


Fig. 14.3 Renal hilum is dissected enough to identify structures, vein anteriorly, artery posteriorly; note that full skeletonising of the vessels is not required as long as clamp can be applied safely

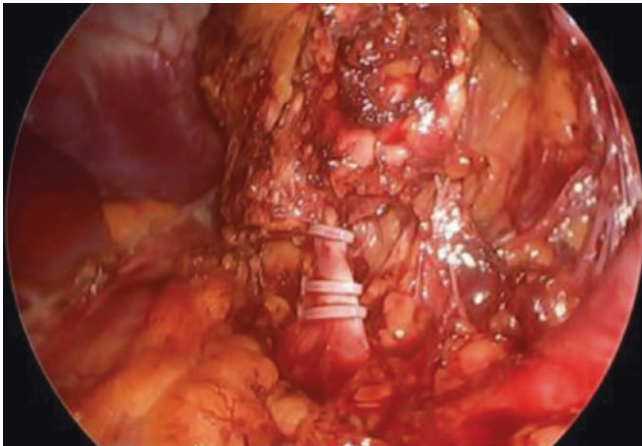


Fig. 14.4 In this case the adrenal gland was removed with the tumour (Photo shows the adrenal vein clipped with Haem-o-lok clips prior to division)

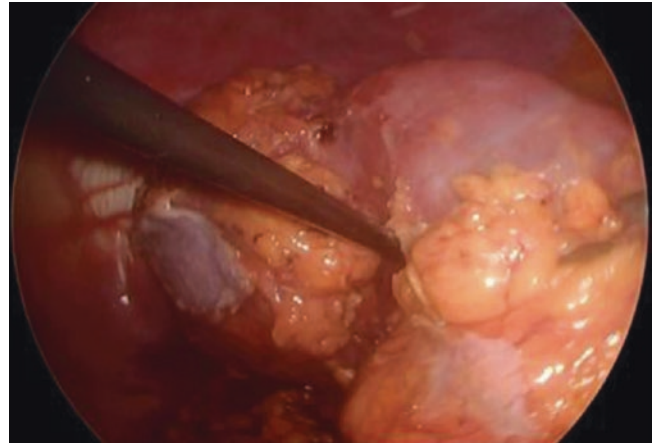


Fig. 14.5 Kidney is freed from all attachments to allow full mobility which is essential for unrestricted tumour excision and renorrhaphy. Perinephric fat and adrenal were left en-bloc with the tumour

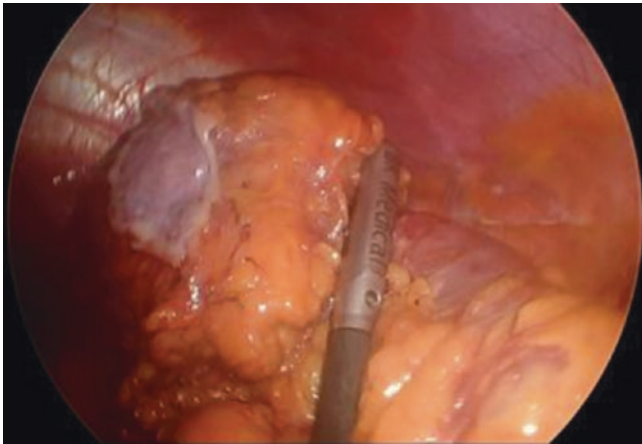


Fig. 14.6 Endoscopic ultrasound scan is used to identify tumour borders and depth and determine incision lines

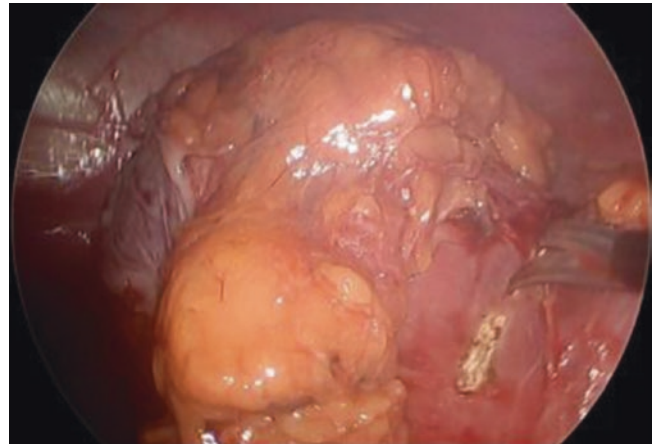


Fig. 14.7 Incision line is marked with diathermy circumferentially around tumour

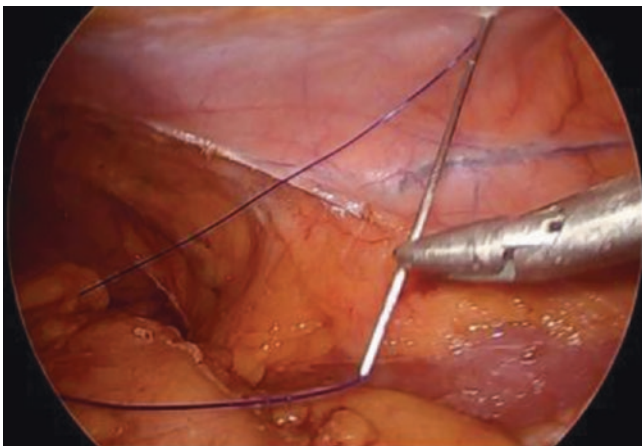


Fig. 14.8 When the kidney needs to maintain certain position to facilitate tumour excision and improve vision, a suture on a straight needle can be inserted through the abdominal wall, anchoring the kidney and exiting again through the abdominal wall. Desired tension on this suture is maintained by clipping it with artery forceps at the level of the skin

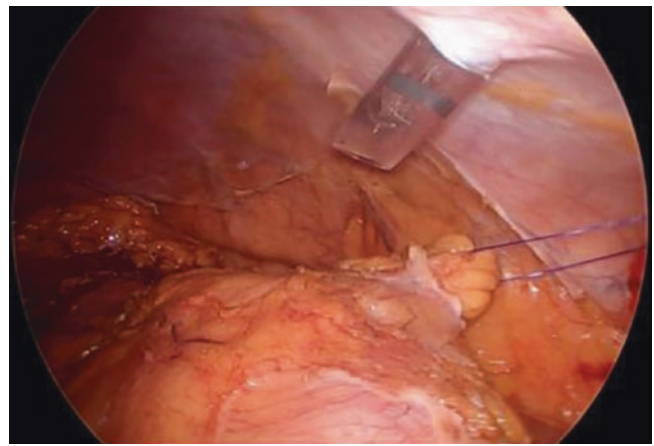


Fig. 14.9 Kidney secured in a desired position

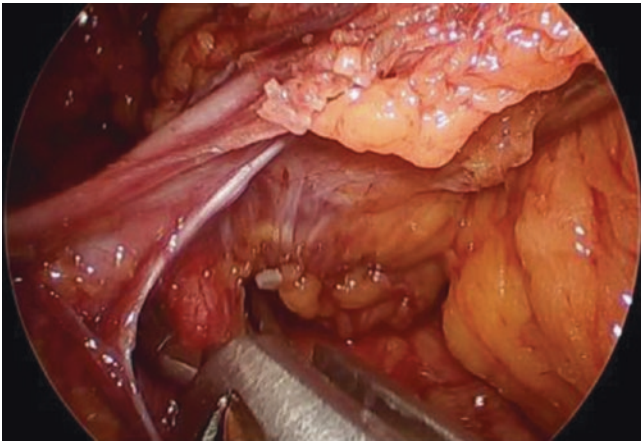


Fig. 14.10 Once the kidney is mobilised, tumour marked and all suture material prepared, the renal artery can be clamped. In this case laparoscopic “bulldog” clamp is used

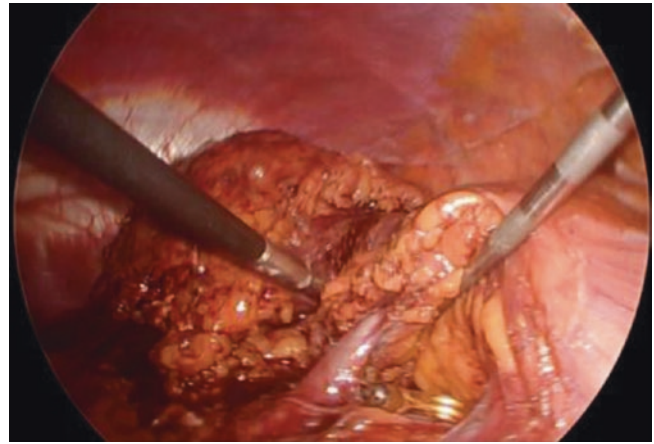


Fig. 14.11 Clamp deployed on the renal artery

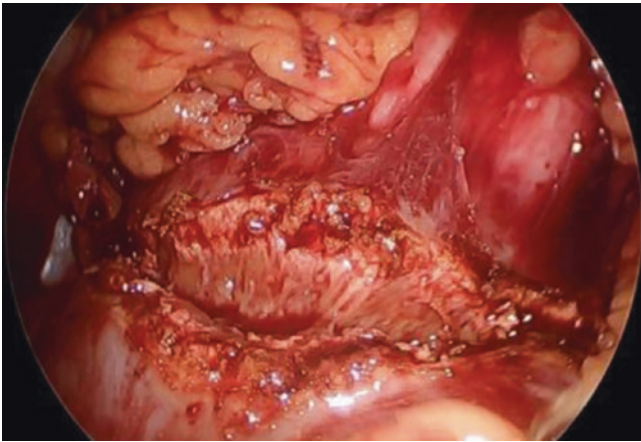


Fig. 14.12 Excision of tumour begins using cold scissors

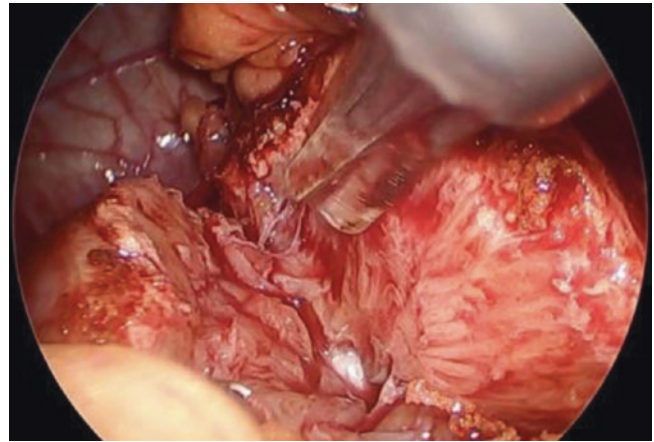


Fig. 14.13 Tumour dissection continues in a relatively bloodless field. Collecting system is visible at the deep end of the incision

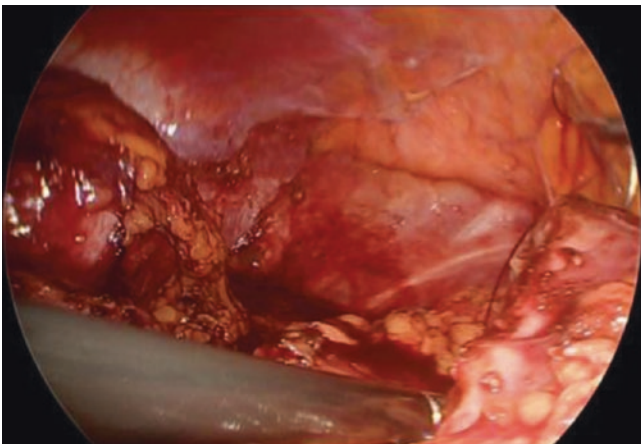


Fig. 14.14 Tumour is completely excised and placed aside. Renorrhaphy begins at the far end of the incision with 3-0 PDS (Haem-o-lok clip has already been attached to the suture end), suture is started outside and exits in the tumour bed

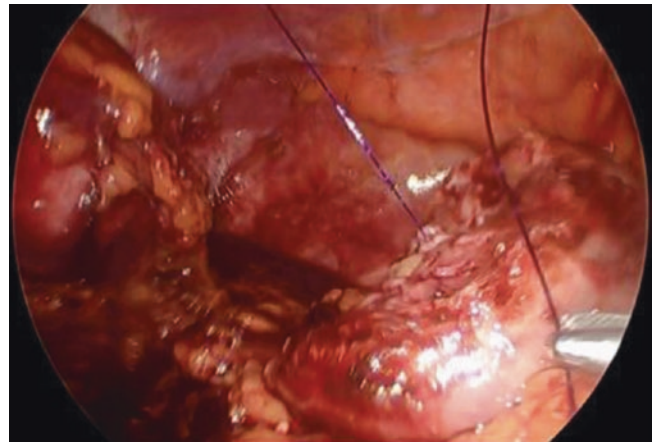


Fig. 14.15 Renorrhaphy continues with the same suture in the tumour bed at the corticomedullary junction; this suture is also used to close the collecting system

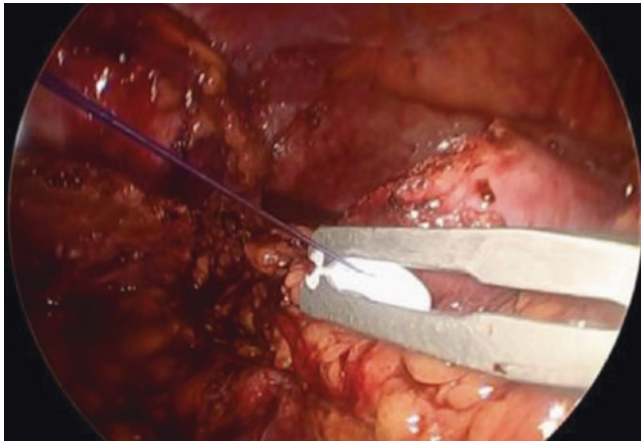


Fig. 14.16 The suture finishes as it exits through the renal capsule and another Haem-o-lok clip is applied to the near end to be able to create desired tension by sliding the clip on the thread in the direction of the kidney

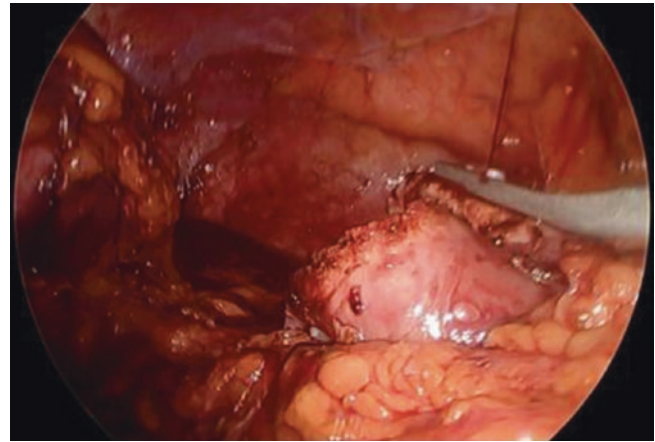


Fig. 14.17 The first Haem-o-lok clip at the far end is also tensioned in a similar fashion

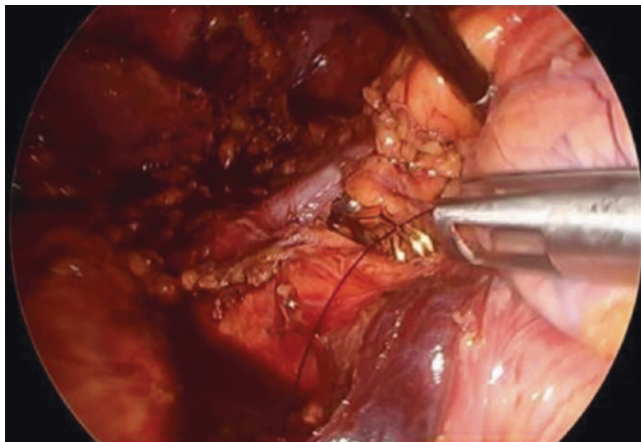


Fig. 14.18 Bulldog clamp is released after the deep (first) suture layer is applied. This allows for shortening the WIT and also identifies any deep bleeding vessels that can be sutured individually prior to commencing the second renorrhaphy layer

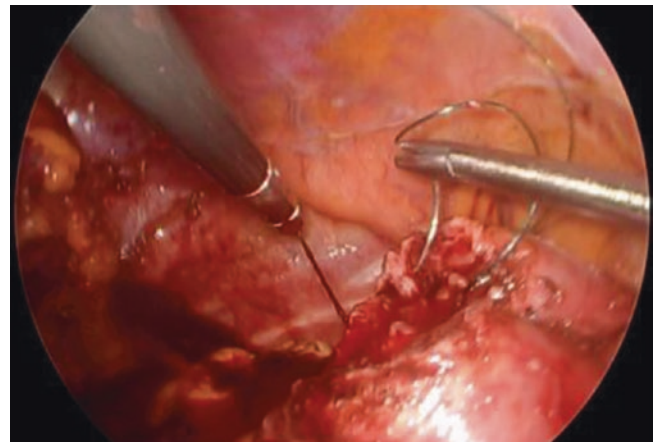


Fig. 14.19 Second suture layer is applied with 3-0 V-loc. This suture starts and exits at the renal cortex with each bite, again with Haem-o-lok clips on both ends

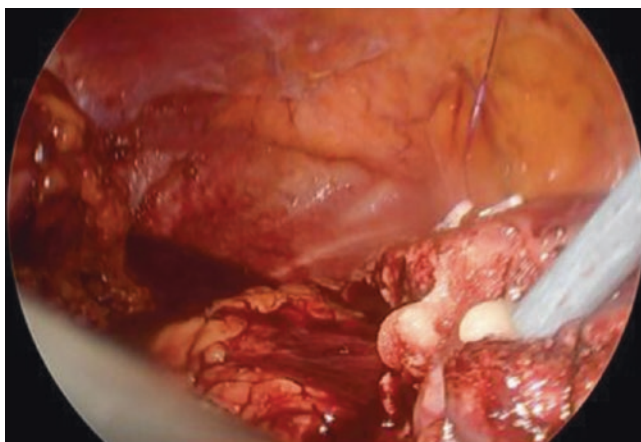


Fig. 14.20 Haemostatic agents, in this case Floseal, are applied in the renal defect prior to tensioning the second suture line

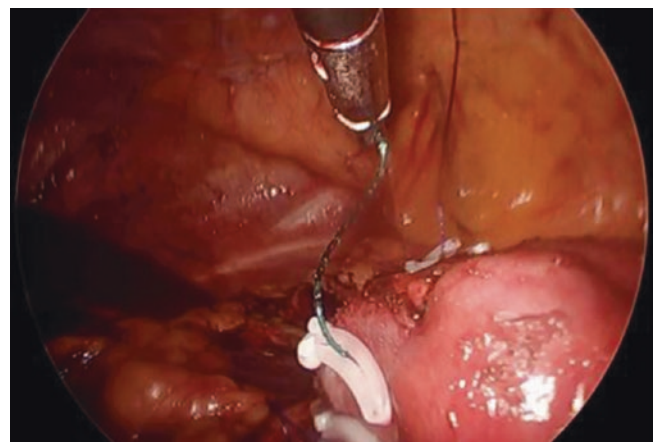


Fig. 14.21 Defect closed; two clips visible on either side of the suture line – one for the deep and one for superficial layer. *Blue* colour monofilament suture further tightening often required after closure of the second layer – PDS. *Green* colour, barbed suture – V-loc

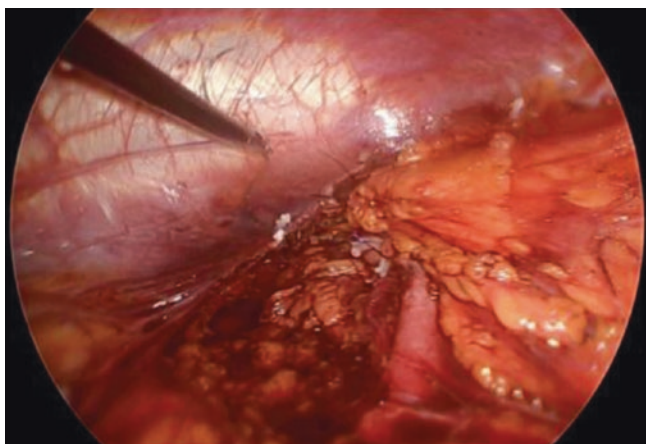


Fig. 14.22 Gerota's fascia closed over defect for extra haemostasis and also to prevent renal torsion

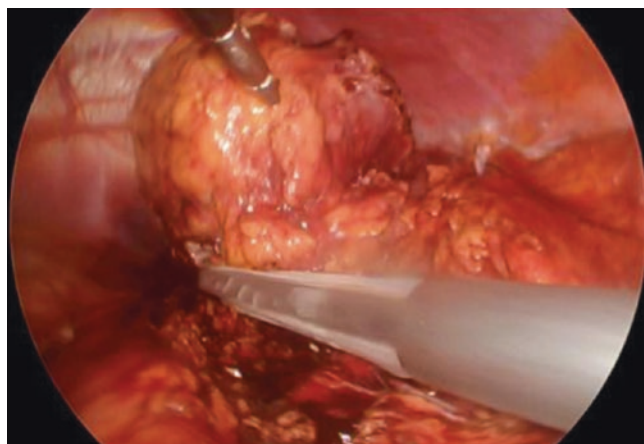


Fig. 14.23 Tumour placed in a laparoscopic bag and removed

14.1.6 Case 2: Interpolar Renal Mass

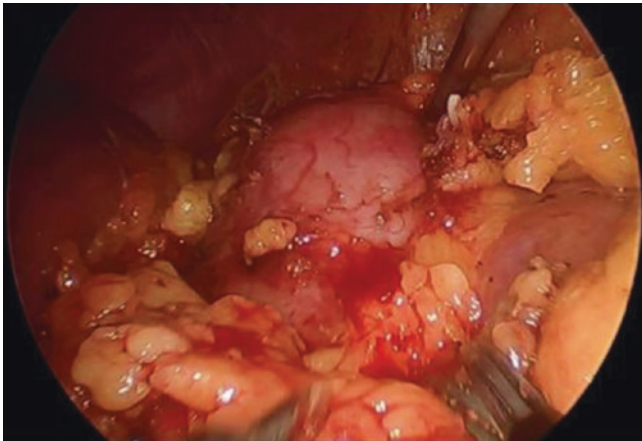


Fig. 14.24 Left interpolar tumour exposed following the initial steps of hilar dissection and kidney mobilisation (not shown)

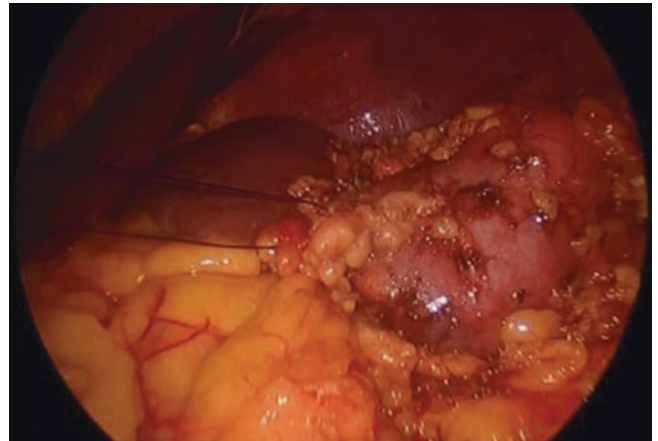


Fig. 14.25 Temporary nephropexy in a desired position

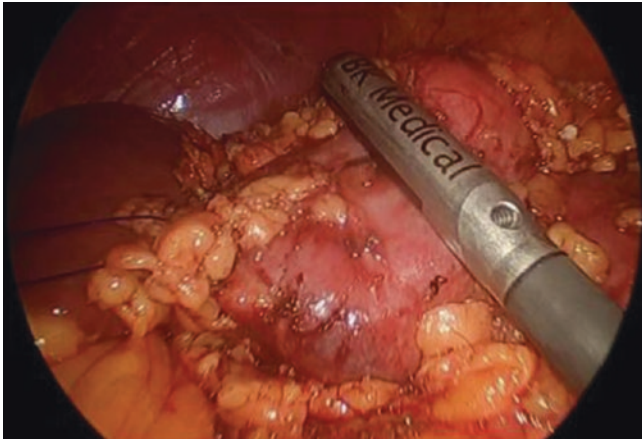


Fig. 14.26 Tumour borders identified with ultrasound scan

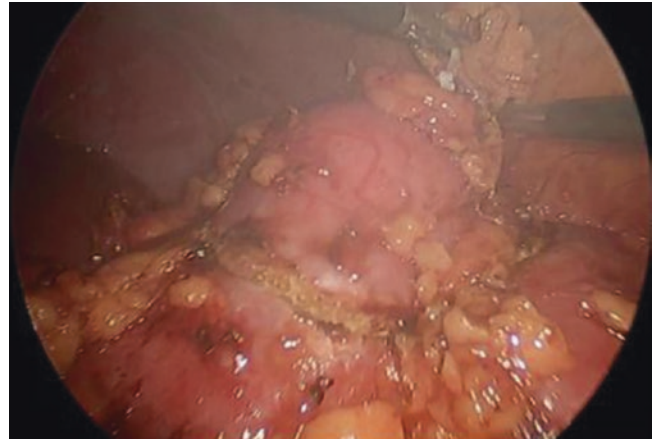


Fig. 14.27 Resection line marked with diathermy

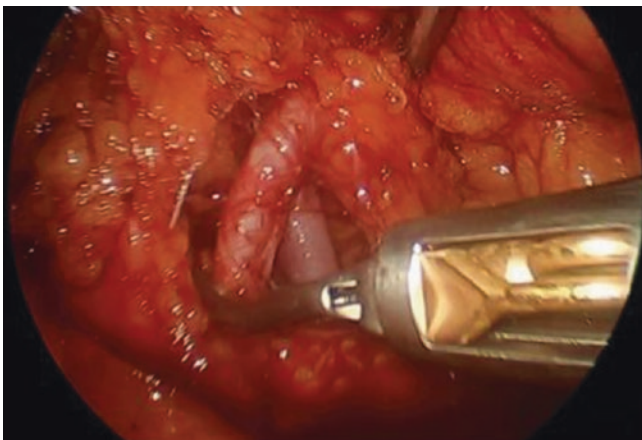


Fig. 14.28 Clamping of the renal artery. Please note the anatomical variant – in this case the renal artery was positioned anterior to the vein

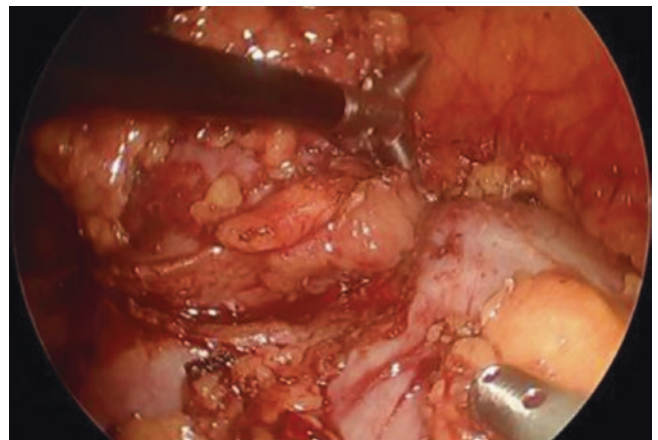


Fig. 14.29 Dissection of tumour using cold cut scissors

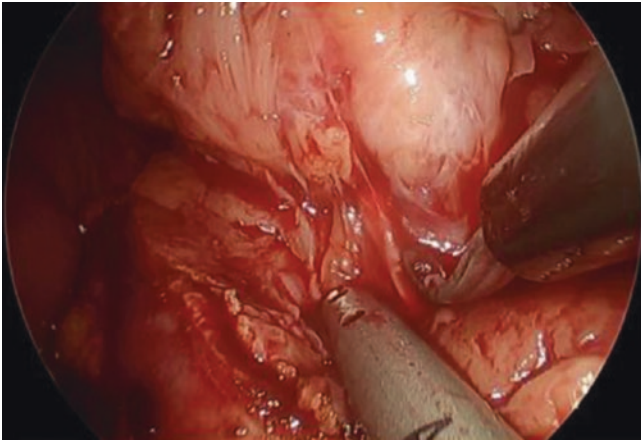


Fig. 14.30 Dissection of tumour with sucker providing counter traction and exposure

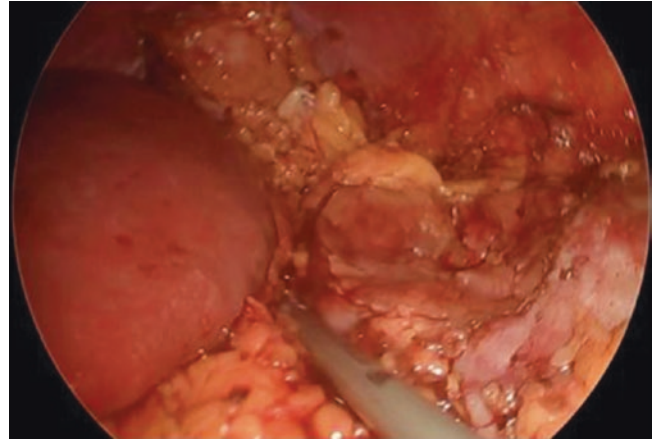


Fig. 14.31 Renal tumour bed with renal artery clamped, note almost bloodless surgical field

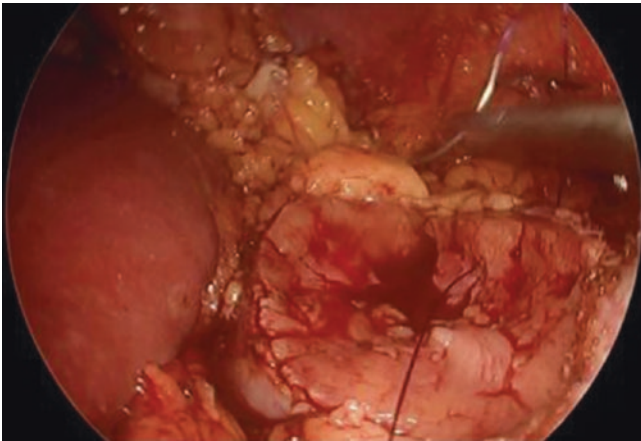


Fig. 14.32 First deep layer of renorrhaphy with 3-0 PDS

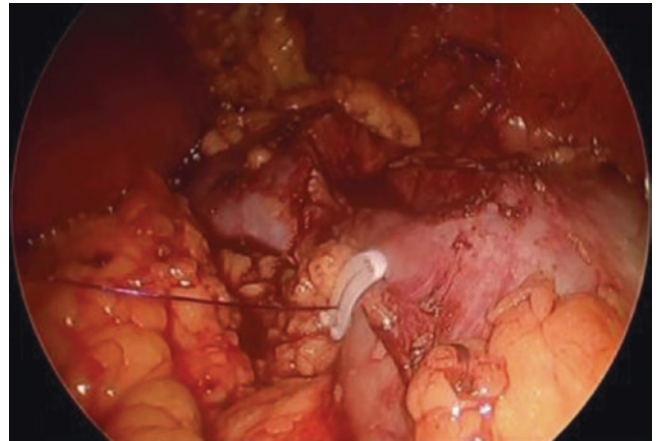


Fig. 14.33 First layer completed, sliding technique used to tighten suture line; defect appears much smaller in size

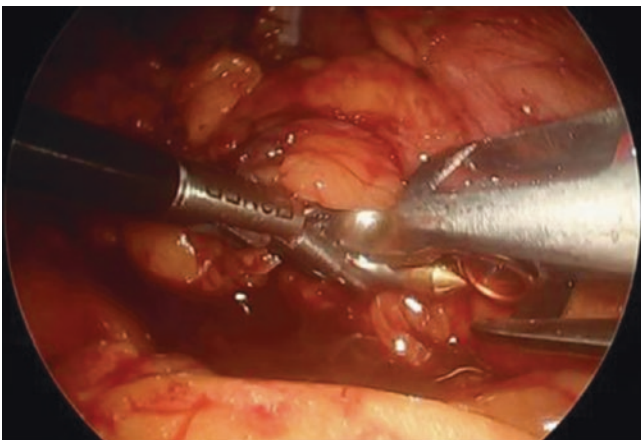


Fig. 14.34 Removal of renal hilar clamp

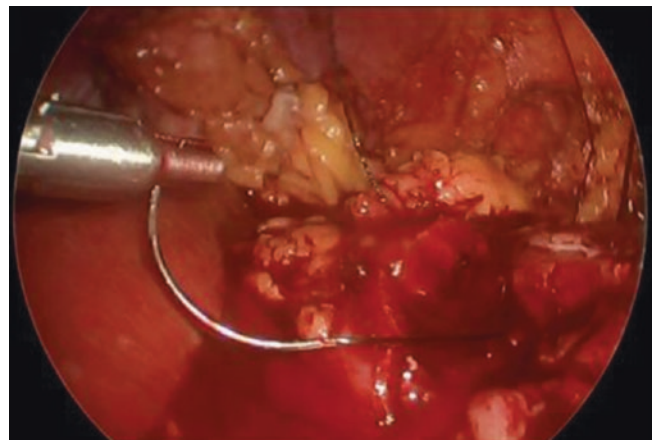


Fig. 14.35 Second layer completed (off clamp) with 3-0 V-loc

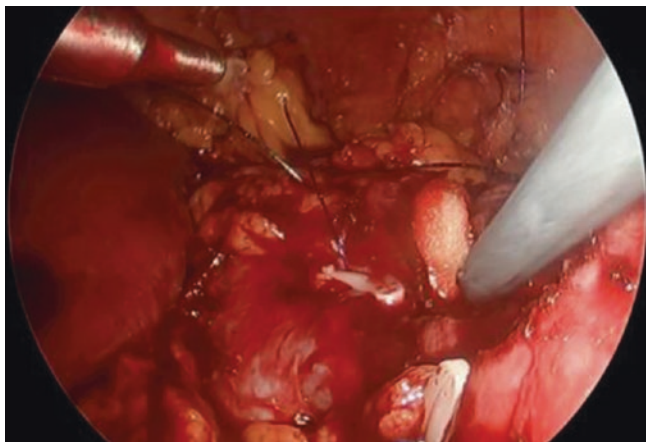


Fig. 14.36 Application of haemostatic agent Floseal in the renal bed prior to tensioning of the second layer

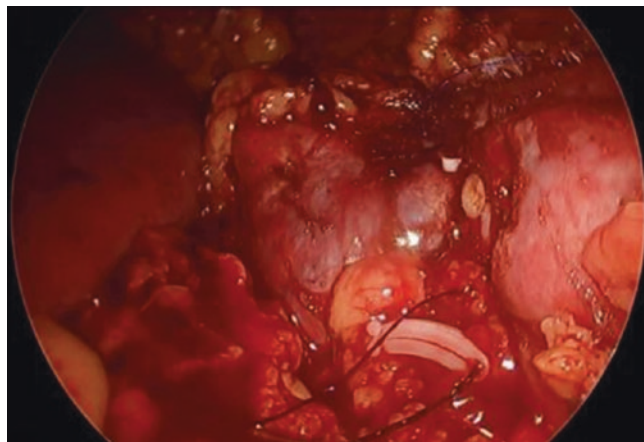


Fig. 14.37 Renal defect closed

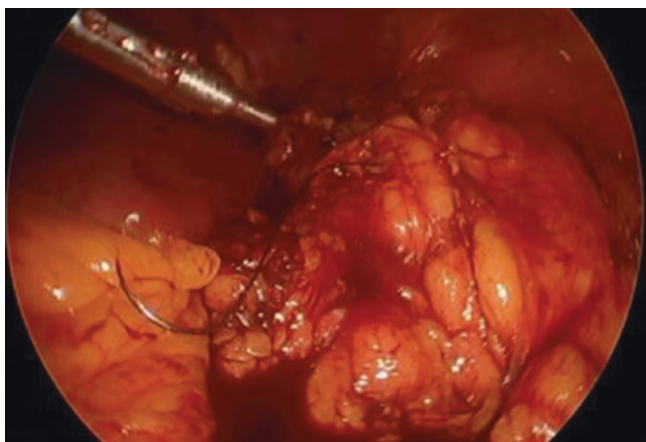


Fig. 14.38 Closure of Gerota's fascia over defect

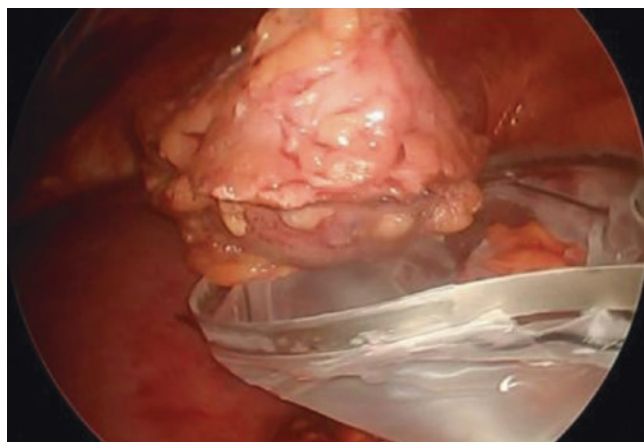

Fig. 14.39 Bagging of tumour and Retrieval

14.2 Retroperitoneoscopic Partial Nephrectomy

Nian Zeng and Yinong Niu

Partial nephrectomy is the treatment of choice for the small renal tumours and functionally or anatomically single kidneys with tumours [25, 28]. Minimally invasive approach is preferred for partial nephrectomy. Retroperitoneal laparoscopic approach was first described in 1994 [26]. This chapter describes the retroperitoneal laparoscopic approach for partial nephrectomy.

14.2.1 Indications

The indications for retroperitoneal partial nephrectomy is similar to open or transperitoneal approach [25] as described in the earlier chapter. Managing large tumours by retroperitoneal approach more than 6 cm may be difficult due to the small working space. Retroperitoneal approach may be specifically preferred in those with previous multiple laparotomies or laparoscopic surgeries resulting in extensive scarring and adhesions [27].

14.2.2 Technique

Under General anesthesia patient is placed in 90° lateral position. The port position is as described in Fig. 14.40. The 10 mm port is used for the camera. Pneumo retroperitoneum is created as in any other retroperitoneal approach. Initially, the ureter is dissected and identified. Renal hilum is then dissected and renal artery and vein isolated. Kidney is mobilised all around within the Gerota's fascia, preserving some perinephric fat around the tumour. Renal pedicle is clamped en bloc or individually and tumour excision started. Using scissors with diathermy, renal capsule around the tumour (with a margin) is incised and tumour separated from the renal parenchyma (with margin) by blunt and sharp dissection. The separated tumour is placed in an accessible site and the tumour bed is cauterized using bipolar diathermy or argon plasma coagulator. Using barbed sutures, the parenchyma is sutured in two layers – Inner parenchymal and collecting system sutures with 3-0 barbed suture for hemostasis and watertight calyceal closure. 2-0 barbed suture is used for outer parenchymal enmasse closure. Use of hemostatic agent is optional. Clamps are released and any undue bleeding is looked for. Tube drain is placed. Specimen is bagged and port sites are closed.

14.2.3 Conclusion

Retroperitoneal laparoscopic partial nephrectomy is a feasible and effective option in patients with small renal masses. This approach may be difficult in large tumours and scarred retroperitoneum, due to space constraints.

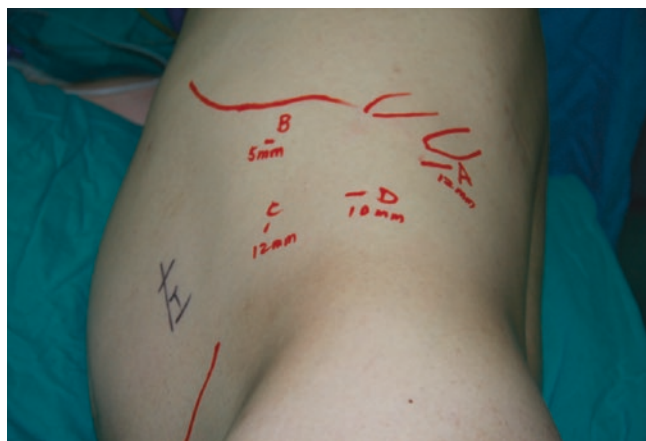

Fig. 14.40 Port position for left sided partial nephrectomy

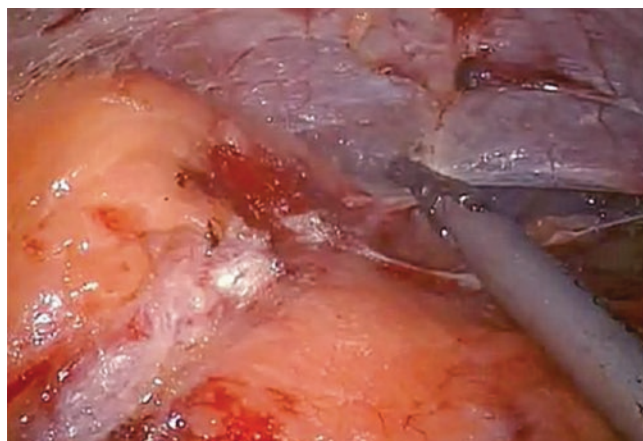


Fig. 14.41 Initial mobilisation of the kidney outside Gerota's fascia

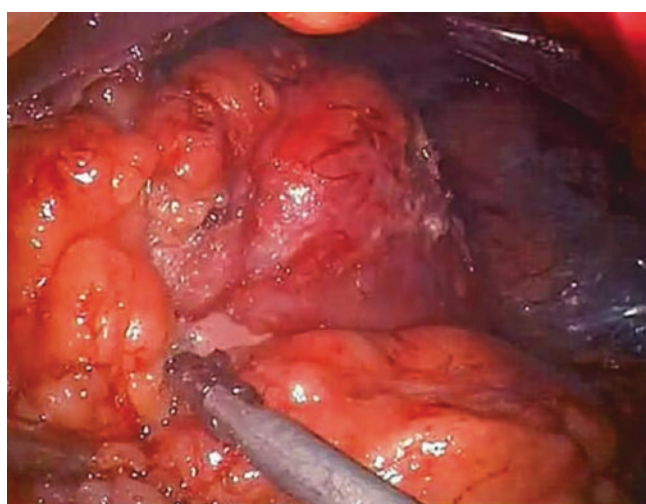


Fig. 14.42 Initial view of the tumour

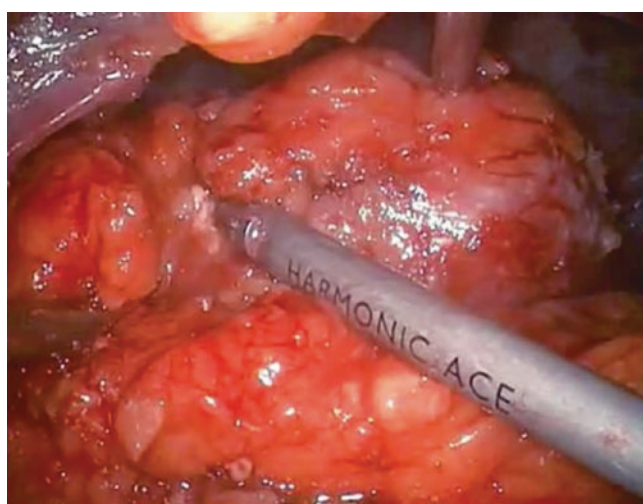


Fig. 14.43 Fat cleared from the kidney around the tumour

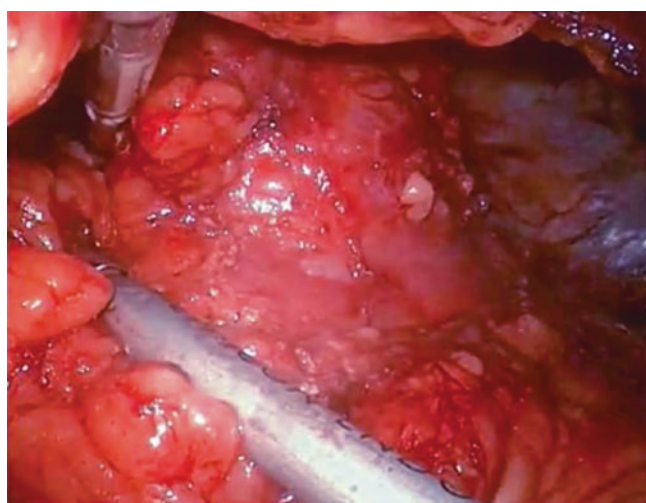


Fig. 14.44 Fat completely cleared all around from the tumour

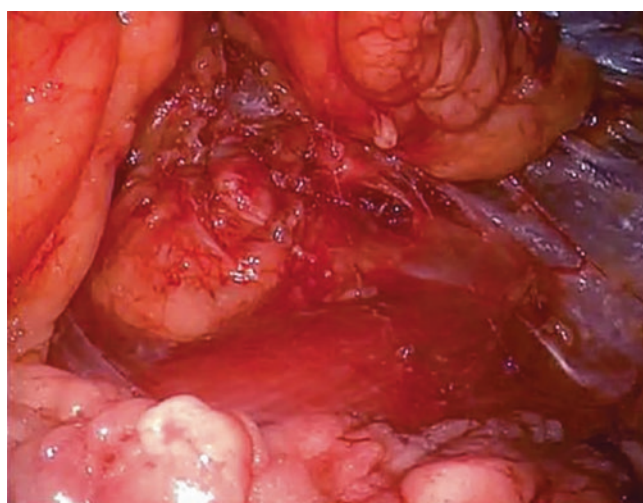


Fig. 14.45 Kidney completely lifted away from the Psoas

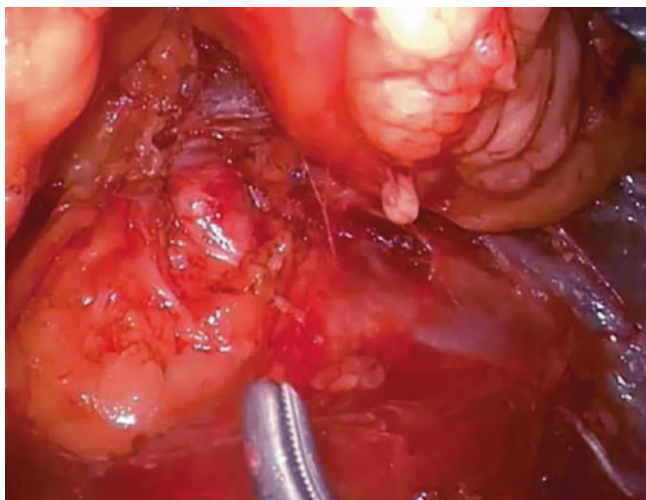


Fig. 14.46 Renal artery seen

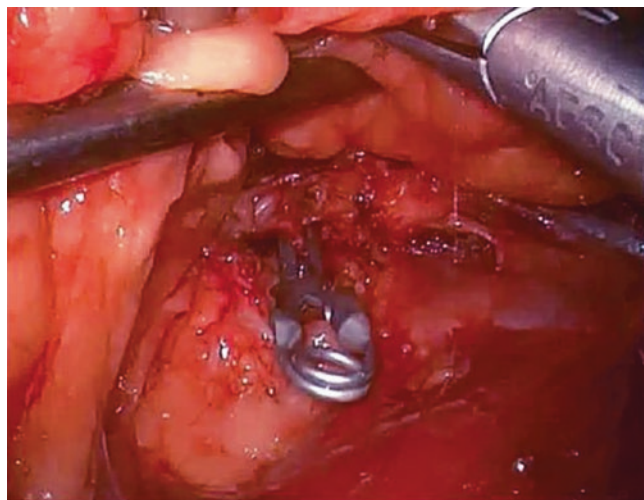


Fig. 14.47 Vascular clamp applied for renal artery

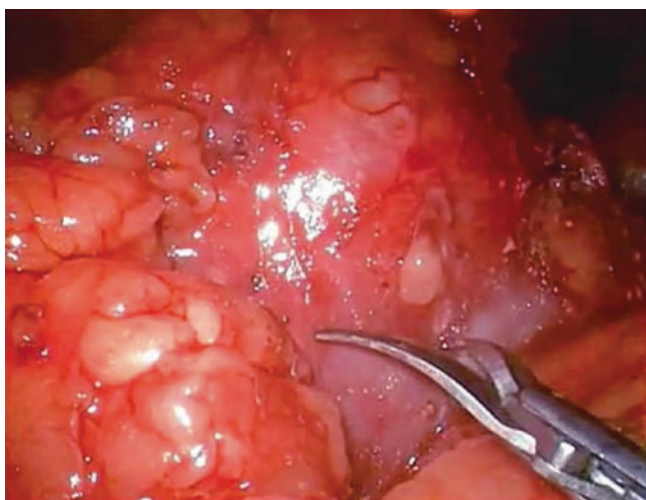


Fig. 14.48 Tumour excision started

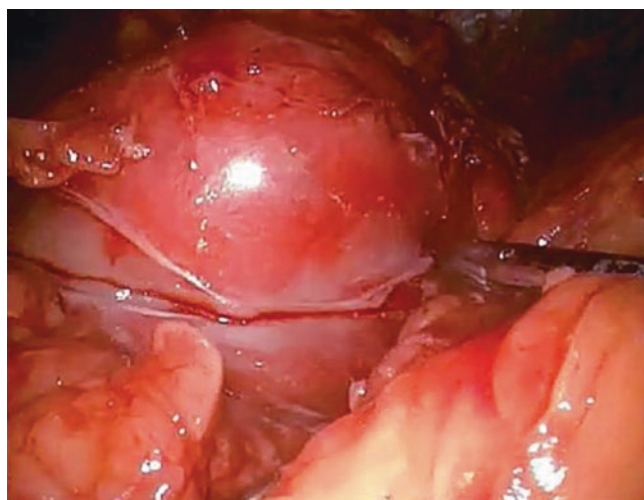


Fig. 14.49 Tumour excision in progress

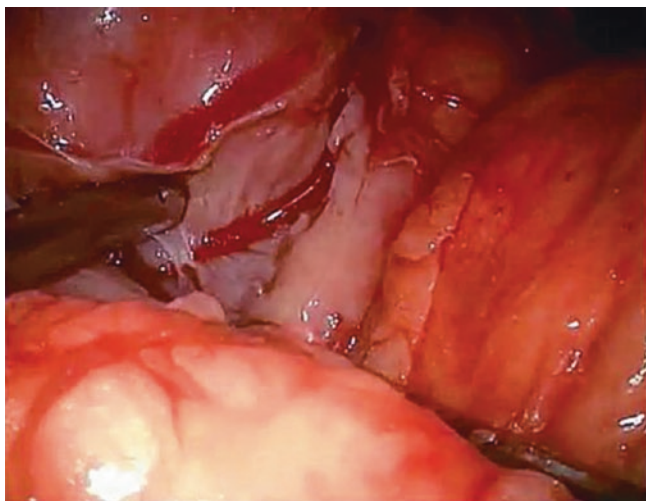


Fig. 14.50 Tumour excision by blunt dissection (Suction)

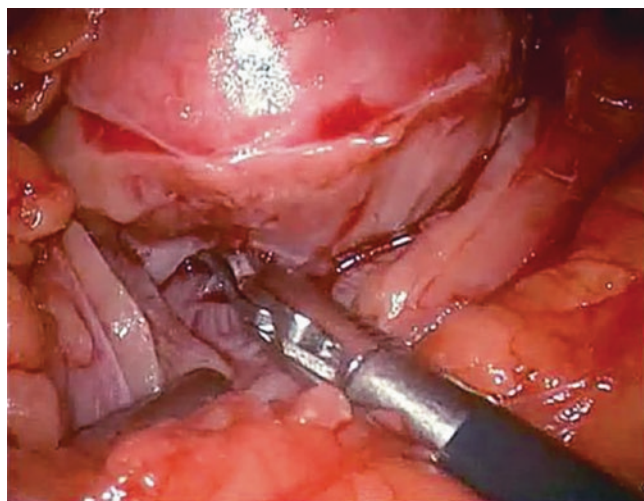


Fig. 14.51 Tumour excision by sharp dissection

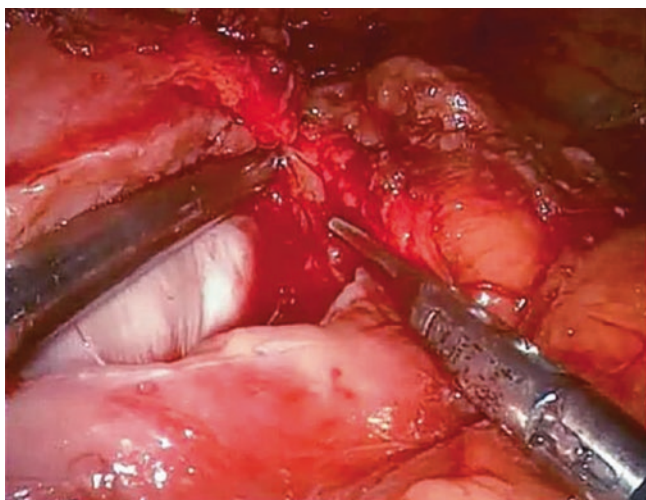


Fig. 14.52 Tumour capsule seen

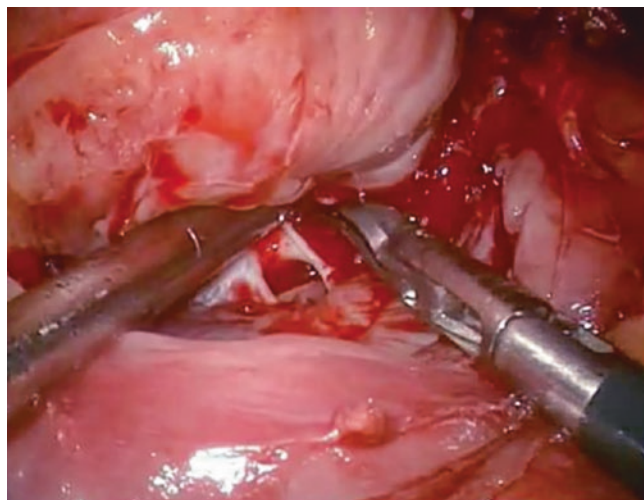


Fig. 14.53 Collecting system opened

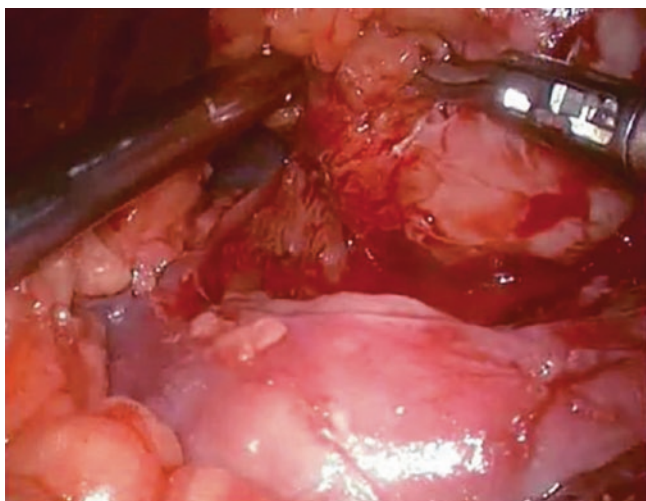


Fig. 14.54 Lateral kidney margin reached

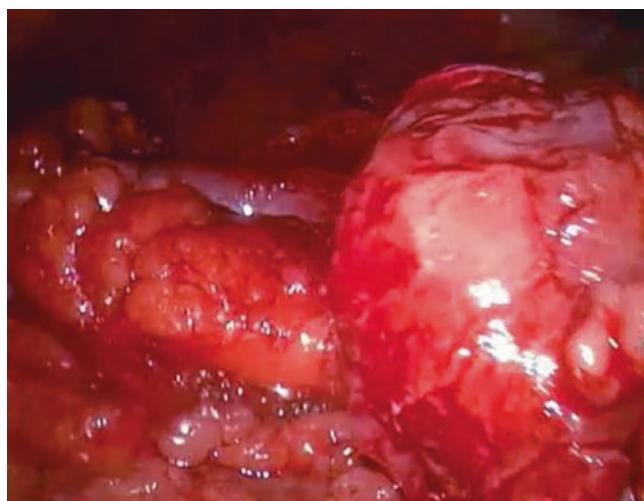


Fig. 14.55 Excision complete

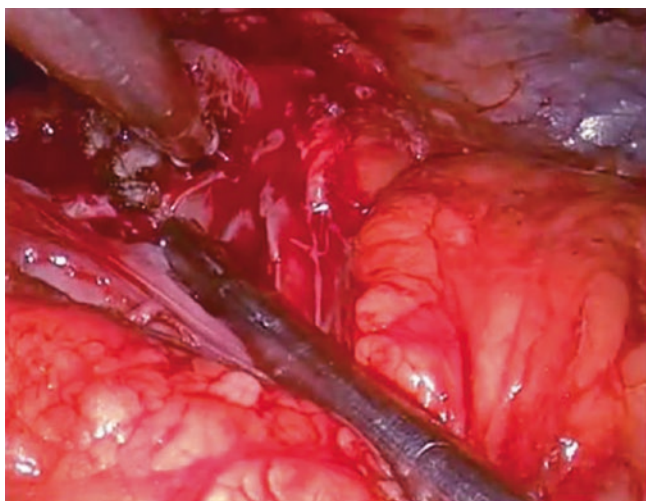


Fig. 14.56 Tumour bed bleeders fulgurated with bipolar forceps

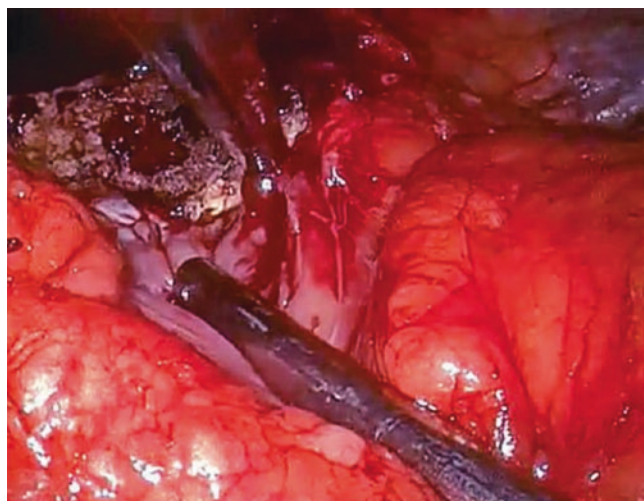


Fig. 14.57 Argon plasma coagulation of parenchyma

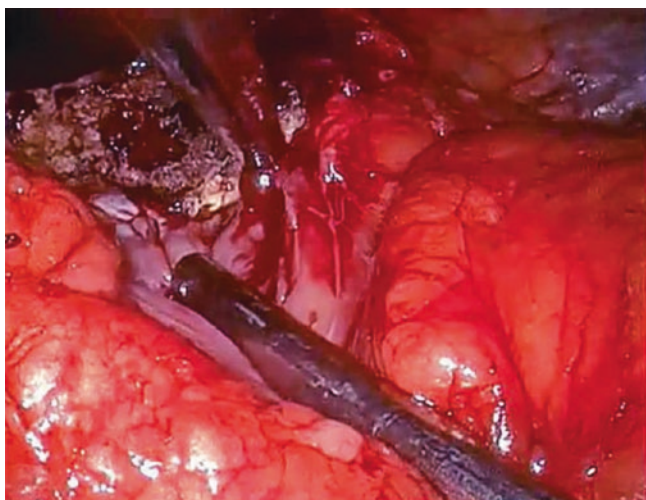


Fig. 14.58 Argon plasma coagulation of parenchyma

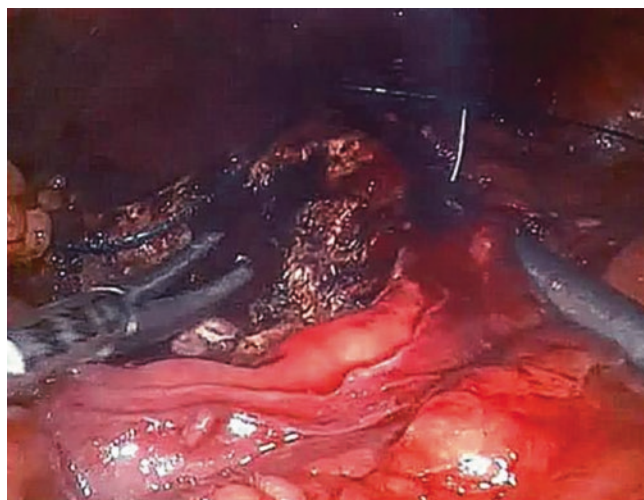

Fig. 14.59 Closure started with 1-0 V-Loc sutures

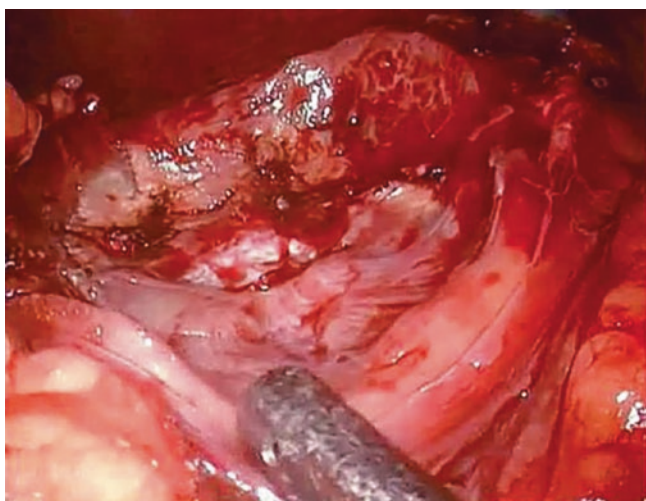


Fig. 14.60 Tumour bed after fulguration

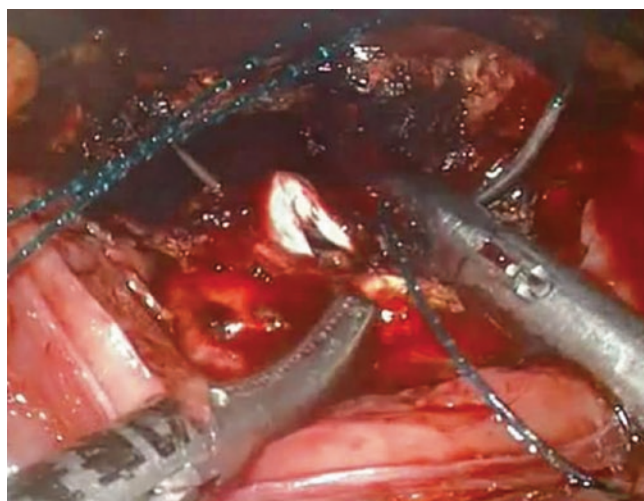


Fig. 14.61 Collecting system closure

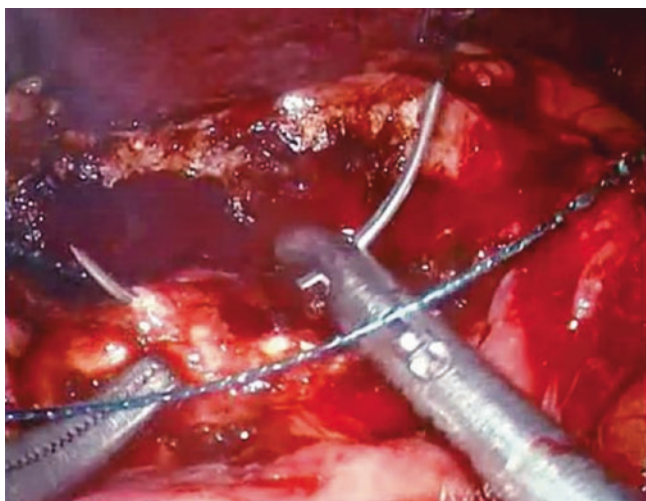


Fig. 14.62 Collecting system closure

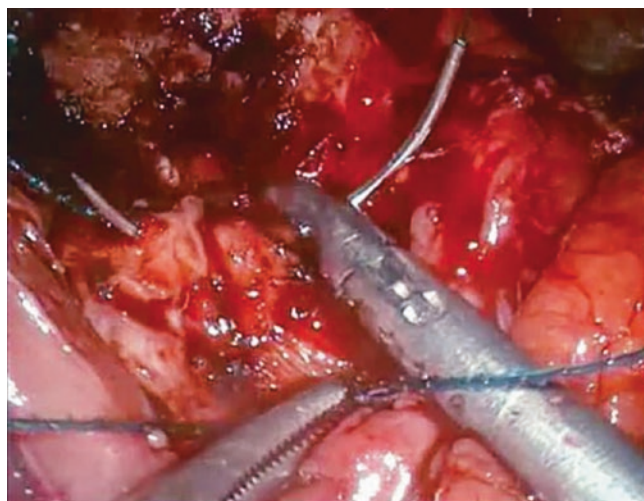


Fig. 14.63 Inner parenchymal suturing in progress

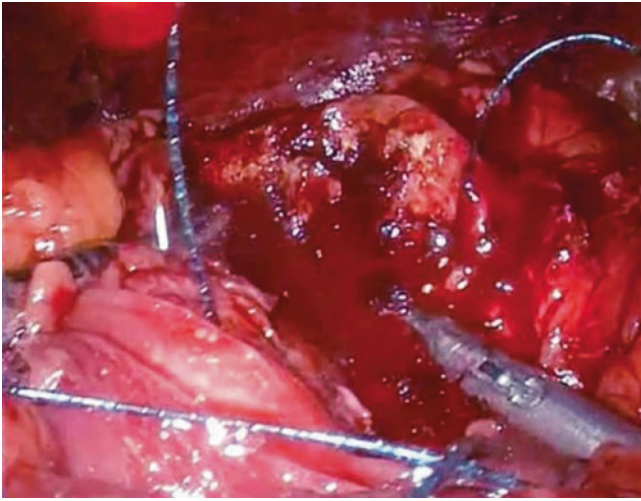


Fig. 14.64 Inner parenchymal suturing in progress

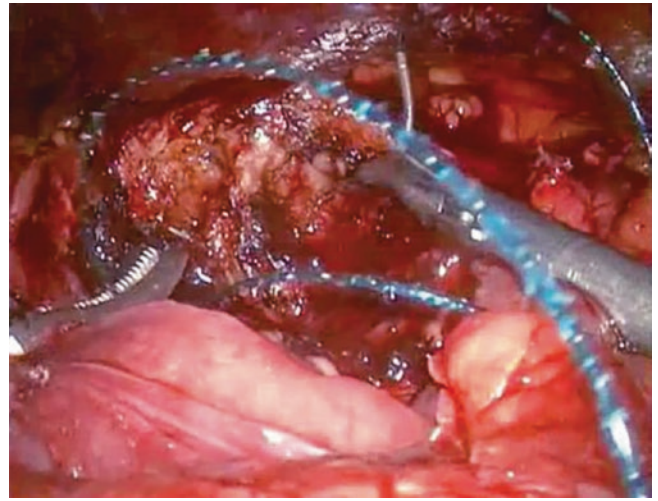


Fig. 14.65 Inner parenchymal suturing in progress

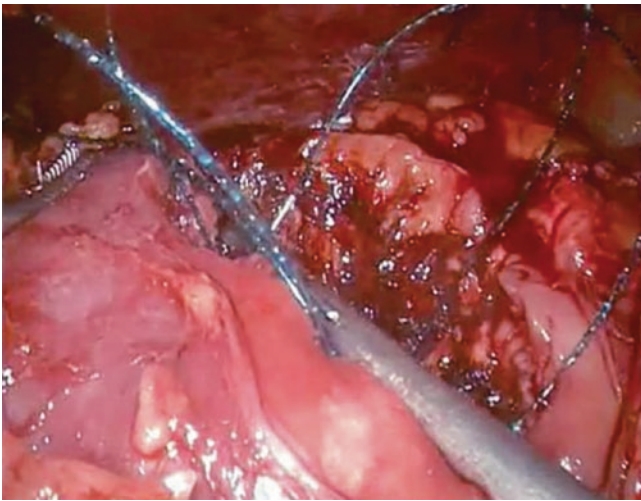


Fig. 14.66 Inner parenchymal suturing completed

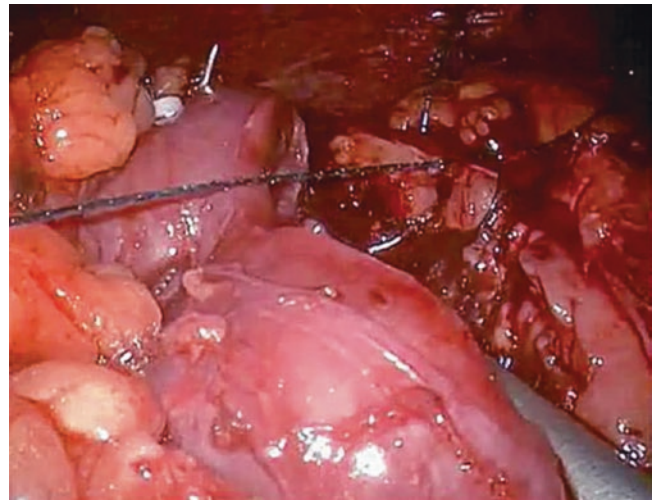


Fig. 14.67 Outer parenchymal suturing in progress

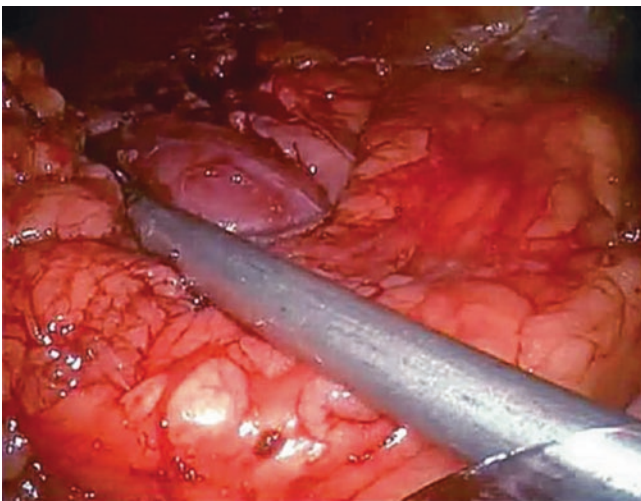


Fig. 14.68 Outer parenchymal suturing in progress

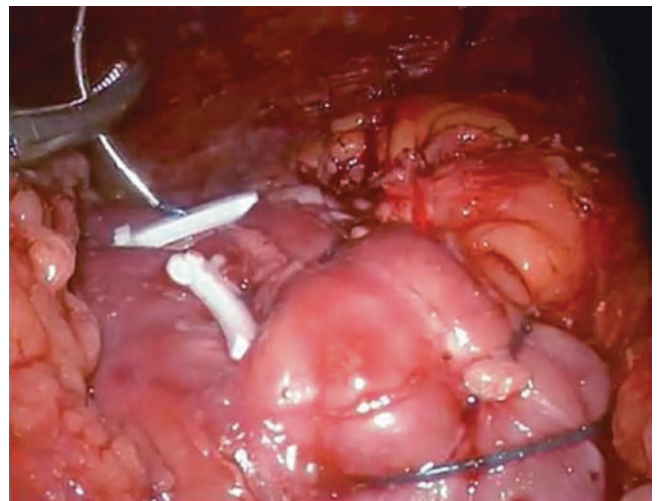


Fig. 14.69 Parenchymal closure completed

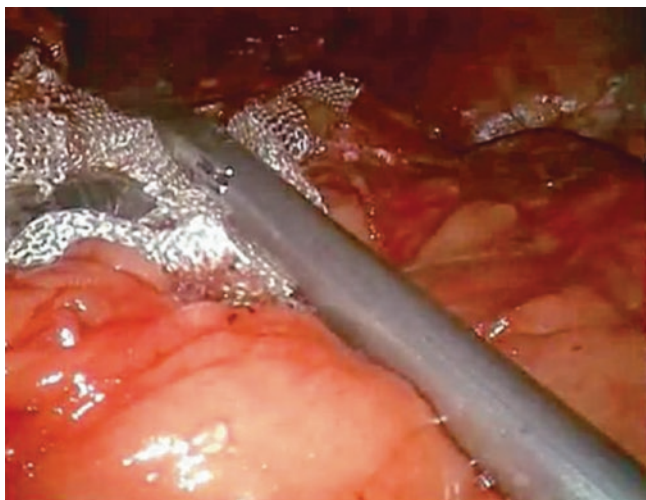


Fig. 14.70 Hemostatic agent placed

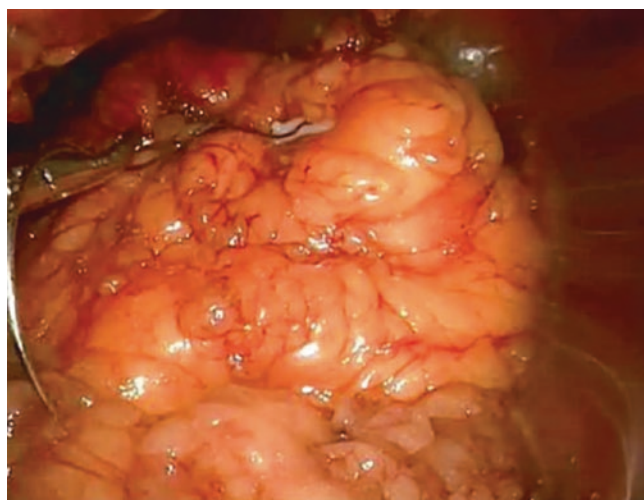


Fig. 14.71 Perinephric fat cover

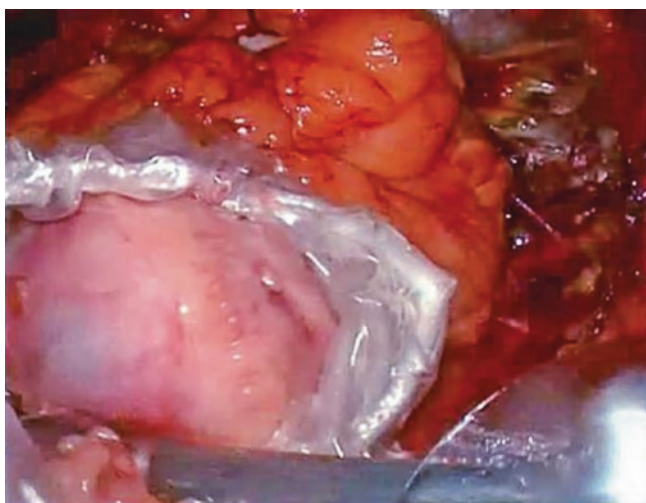


Fig. 14.72 Specimen bagged

References

1. Chow WH, Devesa SS. Contemporary epidemiology of renal cell cancer. *Cancer J*. 2008;14:288–301.
2. Lee CT, Katz J, Shi W, Thaler HT, Reuter VE, Russo P. Surgical management of renal tumors 4 cm. or less in a contemporary cohort. *J Urol*. 2000;163:730–6.
3. Hafez KS, Novick AC, Butler BP. Management of small solitary unilateral renal cell carcinomas: impact of central versus peripheral tumor location. *J Urol*. 1998;159:1156–60.
4. Leibovich BC, Blute ML, Cheville JC, Lohse CM, Weaver AL, Zincke H. Nephron sparing surgery for appropriately selected renal cell carcinoma between 4 and 7 cm results in outcome similar to radical nephrectomy. *J Urol*. 2004;171:1066–70.
5. Dash A, Vickers AJ, Schachter LR, Bach AM, Snyder ME, Russo P. Comparison of outcomes in elective partial vs radical nephrectomy for clear cell renal cell carcinoma of 4–7 cm. *BJU Int*. 2006;97:939–45.
6. Joniau S, Vander Eeck K, Srirangam SJ, Van Poppel H. Outcome of nephron-sparing surgery for T1b renal cell carcinoma. *BJU Int*. 2009;103:1344–8.
7. Antonelli A, Cozzoli A, Nicolai M, et al. Nephron-sparing surgery versus radical nephrectomy in the treatment of intracapsular renal cell carcinoma up to 7 cm. *Eur Urol*. 2008;53:803–9.
8. Gill IS, Kavoussi LR, Lane BR, et al. Comparison of 1,800 laparoscopic and open partial nephrectomies for single renal tumors. *J Urol*. 2007;178:41–6.
9. Lane BR, Gill IS. 5-year outcomes of laparoscopic partial nephrectomy. *J Urol*. 2007;177:70–4.
10. Permpongkosol S, Bagga HS, Romero FR, Sroka M, Jarrett TW, Kavoussi LR. Laparoscopic versus open partial nephrectomy for the treatment of pathological T1N0M0 renal cell carcinoma: a 5-year survival rate. *J Urol*. 2006;176:1984–9.
11. Gill IS, Colombo Jr JR, Moizadeh A, et al. Laparoscopic partial nephrectomy in solitary kidney. *J Urol*. 2006;175:454–8.
12. Frank I, Colombo Jr JR, Rubinstein M, Desai M, Kaouk J, Gill IS. Laparoscopic partial nephrectomy for centrally located renal tumors. *J Urol*. 2006;175:849–52.
13. Nadu A, Kleinmann N, Laufer M, Dotan Z, Winkler H, Ramon J. Laparoscopic partial nephrectomy for central tumors: analysis of perioperative outcomes and complications. *J Urol*. 2009;181:42–7.
14. Huang WC, Elkin EB, Levey AS, Jang TL, Russo P. Partial nephrectomy versus radical nephrectomy in patients with small renal tumors – is there a difference in mortality and cardiovascular outcomes? *J Urol*. 2009;181:55–61.
15. Thompson RH, Boorjian SA, Lohse CM, et al. Radical nephrectomy for pT1a renal masses may be associated with decreased overall survival compared with partial nephrectomy. *J Urol*. 2008;179:468–71.
16. Van Poppel H, Da Pozzo L, Albrecht W, et al. A prospective, randomised EORTC intergroup phase 3 study comparing the oncologic outcome of elective nephron-sparing surgery and radical nephrectomy for low-stage renal cell carcinoma. *Eur Urol*. 2011;59:543–52.
17. Van Poppel H, Joniau S. How important are surgical margins in nephron-sparing surgery. *Eur Urol Suppl*. 2007;6:533–9.
18. Bensalah K, Pantuck AJ, Rioux-Leclercq N, et al. Positive surgical margin appears to have negligible impact on survival of renal cell carcinomas treated by nephron-sparing surgery. *Eur Urol*. 2010;57:466–73.
19. Van Poppel H, Da Pozzo L, Albrecht W, et al. A prospective randomized EORTC intergroup phase 3 study comparing the complications of elective nephron-sparing surgery and radical nephrectomy for low-stage renal cell carcinoma. *Eur Urol*. 2007;51:1606–15.
20. Nguyen MM, Gill IS. Halving ischemia time during laparoscopic partial nephrectomy. *J Urol*. 2008;179:627–32.
21. Baumert H, Ballaro A, Shah N, et al. Reducing warm ischaemia time during laparoscopic partial nephrectomy: a prospective comparison of two renal closure techniques. *Eur Urol*. 2007;52:1164–9.
22. Janetschek G. Laparoscopic partial nephrectomy for RCC: how can we avoid ischemic damage of the renal parenchyma? *Eur Urol*. 2007;52:1303–5.
23. Ficarra V, Novara G, Secco S, et al. Preoperative aspects and dimensions used for an anatomical (PADUA) classification of renal tumours in patients who are candidates for nephron-sparing surgery. *Eur Urol*. 2009;56:786–93.
24. Kutikov A, Uzzo RG. The R.E.N.A.L. nephrometry score: a comprehensive standardized system for quantitating renal tumor size, location and depth. *J Urol*. 2009;182:844–53.
25. Ljungberg B, Bensalah K, Bex A, et al. Guidelines on renal cell carcinoma. In: European Association of Urology Web site, 2015.
26. Gill IS, Delworth MG, Munch LC. Laparoscopic retroperitoneal partial nephrectomy. *J Urol*. 1994;152:1539–42.
27. Xie M, Wang K, Men CP. Anatomic and programmed retroperitoneal laparoscopic partial nephrectomy (with 125 cases of reports). *Chin J Endourol Electron Version*. 2012;6:11–4.
28. Gill IS, Matin SF, Desai MM, Kaouk JH, Steinberg A, Mascha E, et al. Comparative analysis of laparoscopic versus open partial nephrectomy for renal tumors in 200 patients. *J Urol*. 2003;170:64–8.

Sam Bhayani

15.1 Technique

Robotic Partial Nephrectomy is a standardized robotic procedure, in which classically a small renal mass is excised or removed from the kidney. Although traditionally performed in masses less than 4 cm in size, currently these cases are also performed in solitary kidneys, large tumors, and patients with multiple tumors. The results of robotic partial nephrectomy have been similar, if not better, than open and laparoscopic surgery.

15.2 Trocar Placement

Trocar placement varies by robot type, tumor location, and size of patient. Most commonly a camera trocar is placed lateral to the umbilicus or more cephalad in the abdomen. One robotic arm is placed cephalad, and two robotic arms are placed caudal to the camera trocar. Generally speaking these three robotic trocars are also placed more lateral than the camera. Great versatility is present due to the length of the robotic instruments. Collisions, however, can be evident with smaller patients or very obese individuals, and sometimes this necessitates removal of one of the instrument arms. A 30 down lens is classically used to allow broad perspective on the operative field and allow angles of vision.

15.3 Reflection of the Colon

The colon is reflected near the white line of Toldt. Larger tumors require more colon mobilization than small tumors. Generally speaking wider mobilization allows better vision but also requires more dissection around other structures. After the colon is reflected, the perinephric fat should be visible.

15.4 Lateralization of the Kidney and Hilar Dissection

After the colon is reflected medially, the lower pole of the kidney and its surrounding fat should be visible. By lifting this fat with the ureter, the psoas muscle is identified and the kidney is lateralized. This places the hilum on stretch, and allows dissection of the fat between the psoas and the great vessels. The renal vein and artery should be encountered.

15.5 Removal of Peritumor Fat and Sonography

After the hilum is identified, the fat around the lesion is dissected with 1–2 cm of margin. This dissection may take longer with sticky fat or high body mass index patients. In some cases, it is not possible to remove this fat without capsulotomy. After the fat is removed, sonography can be used to identify the margins.

15.6 Excision of Tumor and Renorrhaphy

The hilum may be clamped and near infrared fluorescent imaging can be used to confirm ischemia. The tumor is excised and the kidney is then repaired. The deeper layer may be repaired with a variety of sutures to close the collecting system and any arterioles. The parenchymal layer is closed with a larger suture which is anchored by clips. These clips can be slid down the suture and backed up with another clip to prevent back slippage. The sliding clip renorrhaphy can be adjusted in tightness to promote sealing of the kidney. After this the kidney is unclamped.

S. Bhayani
Faculty Practice Plan, Washington University School of Medicine,
St. Louis, MO, USA
e-mail: bhayani@wustl.edu

15.7 Exiting the Abdomen

The tumor is placed into an entrapment bag and is removed from the body via extension of a trocar site. Postoperatively,

patients are extubated and sent to the recovery room. They may ambulate that evening or the next day depending on clinical conditions.

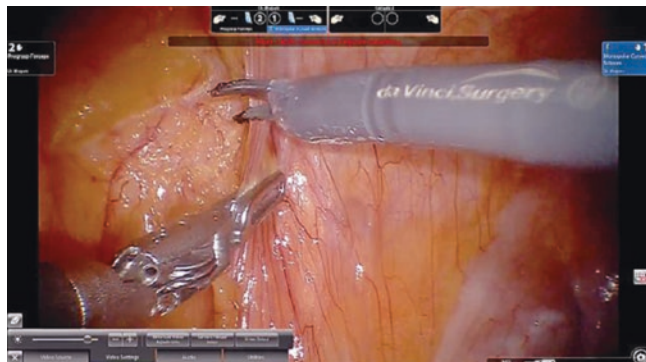


Fig. 15.1 Reflection of left colon along the line of Toldt

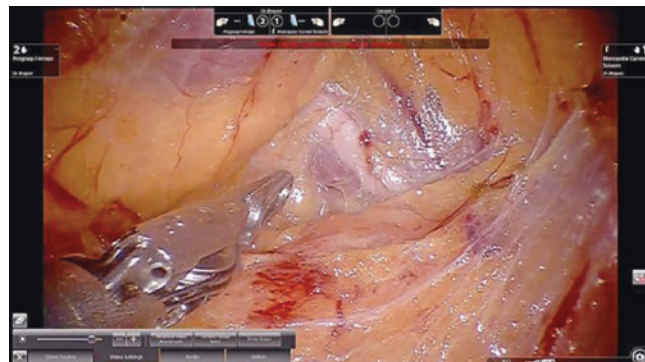


Fig. 15.2 Ureter identified in the retroperitoneum

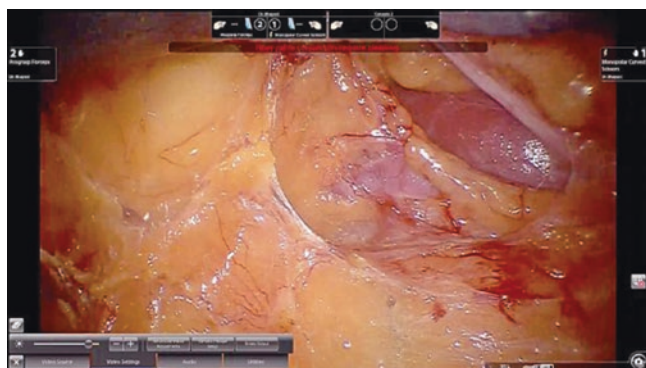


Fig. 15.3 Gonadal vein identified medial to the ureter

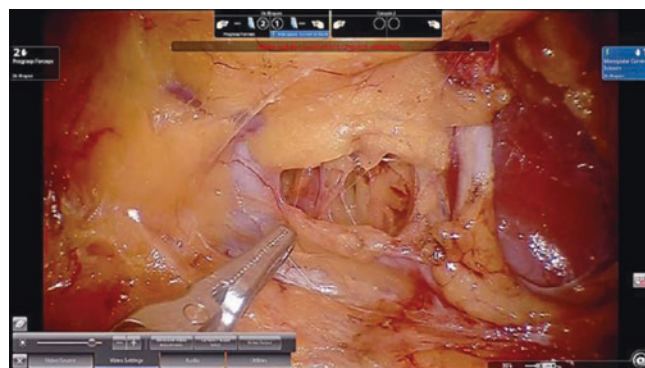


Fig. 15.4 Gonadal vein traced proximally till renal vein. Accessory renal artery dissected

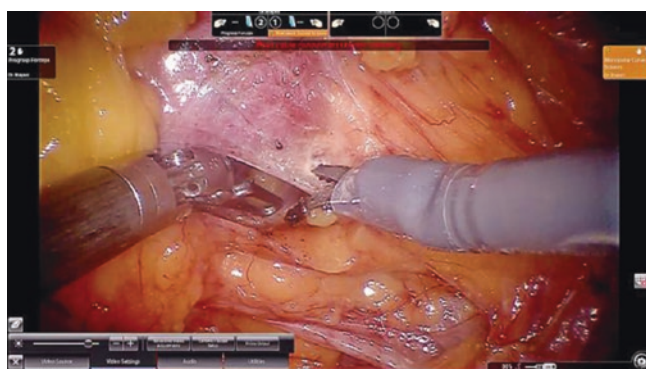


Fig. 15.5 Kidney mobilised all around – Dissection of the lower pole of the kidney – Ureter is identified and preserved

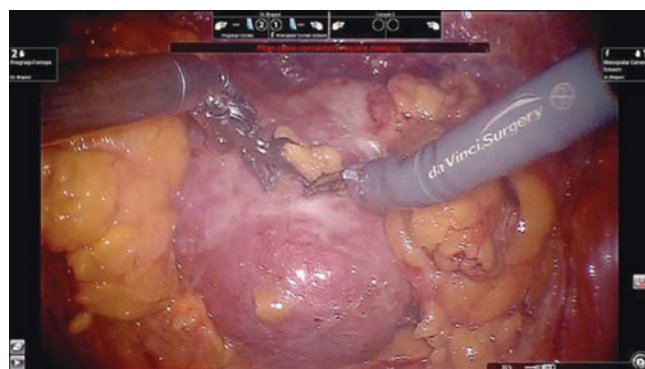


Fig. 15.6 Perinephric fat removed and kidney denuded

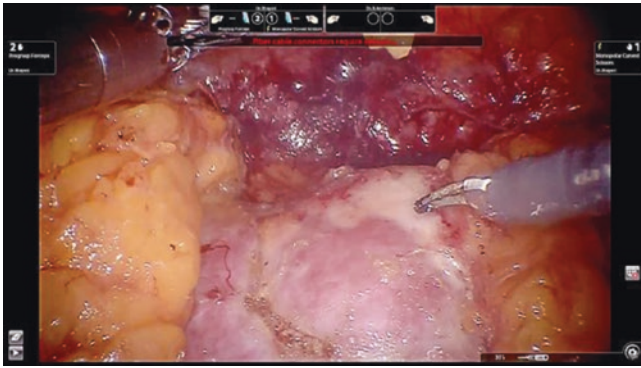


Fig. 15.7 Tumour seen after denuding the kidney

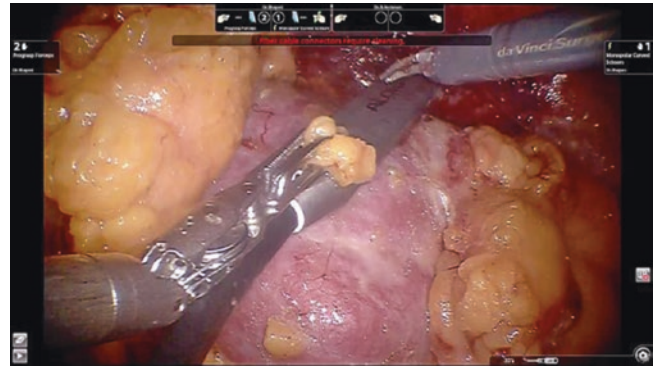


Fig. 15.8 Intra operative ultrasound to delineate the mass

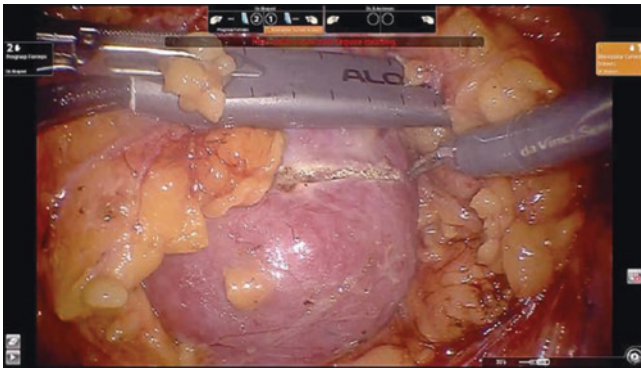


Fig. 15.9 Tumour margins marked with the help of ultrasound

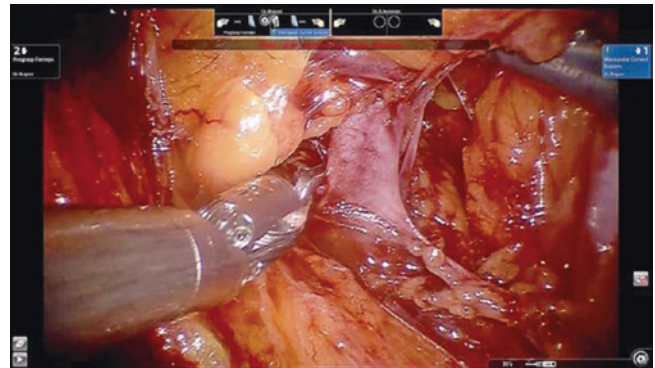


Fig. 15.10 Renal vein dissected

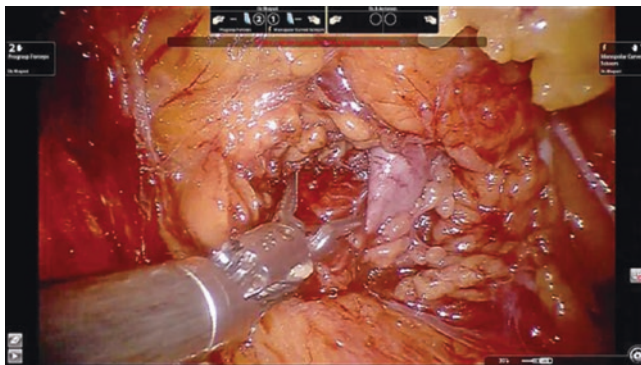


Fig. 15.11 One of the renal artery identified along the upper border of renal vein

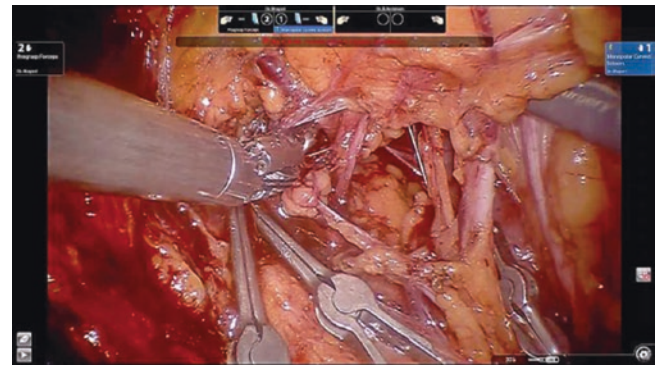


Fig. 15.12 Third renal artery seen posterior to renal vein

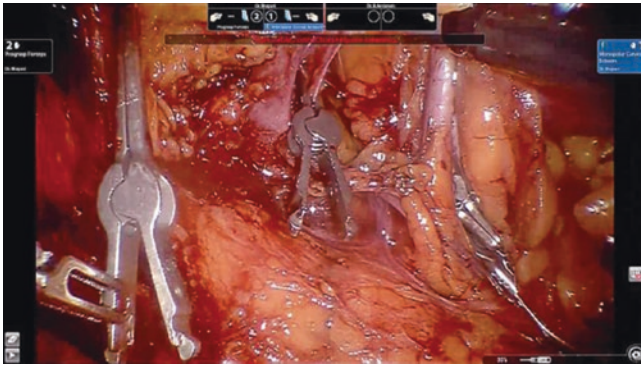


Fig. 15.13 Vascular clamp applied to renal artery branch

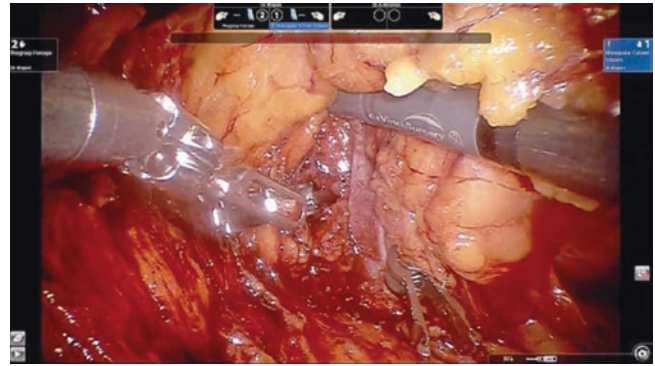


Fig. 15.14 Vascular clamp applied to the renal artery branch

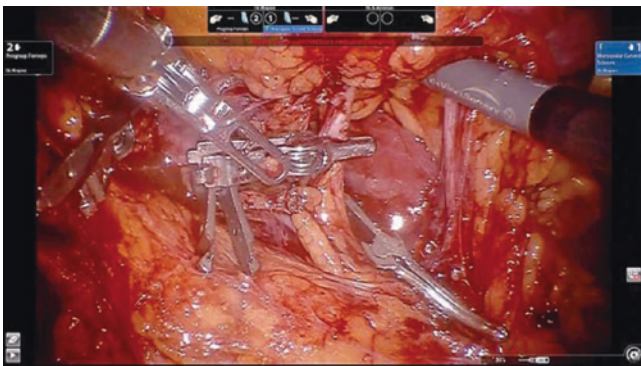


Fig. 15.15 Clamp applied to accessory renal artery

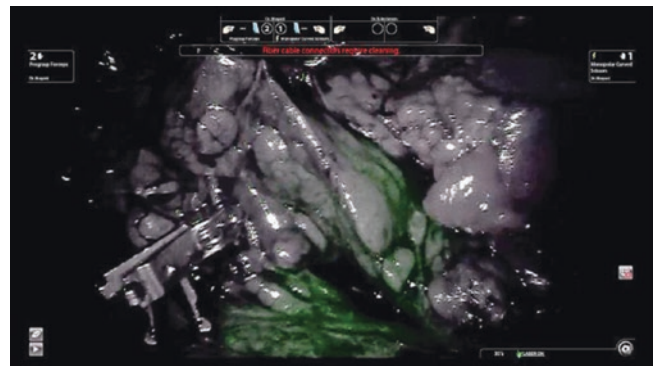


Fig. 15.16 Vascularity assessed using 'firefly'

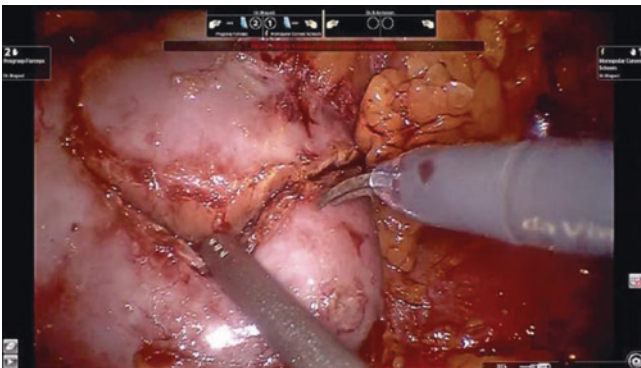


Fig. 15.17 Tumour resection started along the previous marking

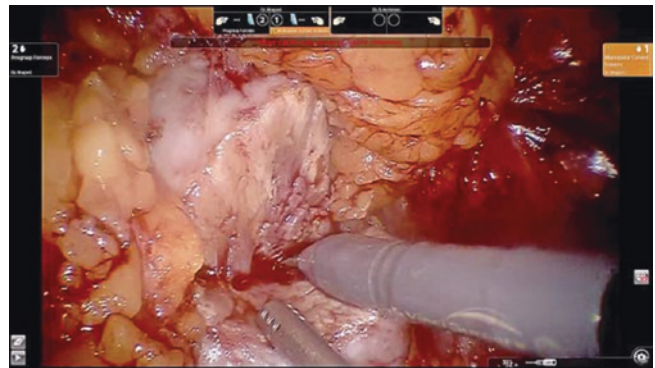


Fig. 15.18 Tumour resection in progress

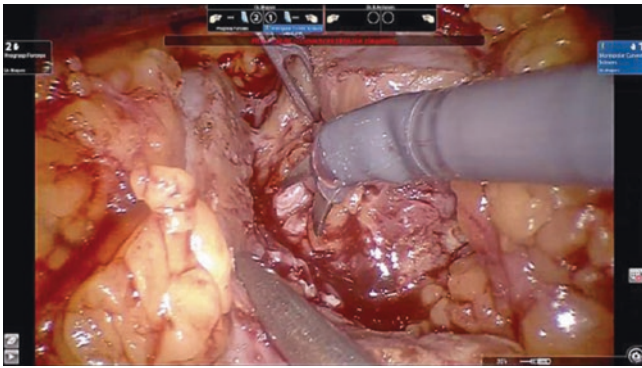


Fig. 15.19 Tumour resection in progress

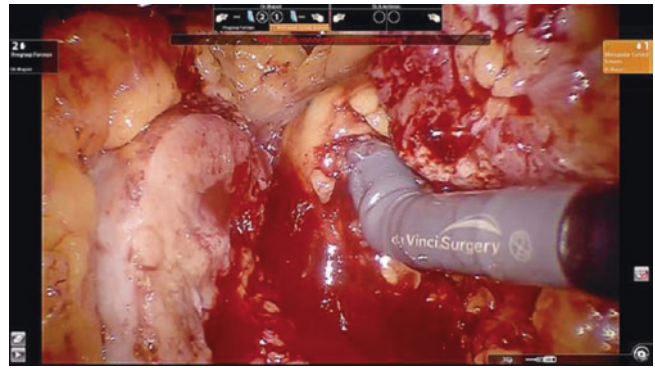


Fig. 15.20 Tumour resection complete

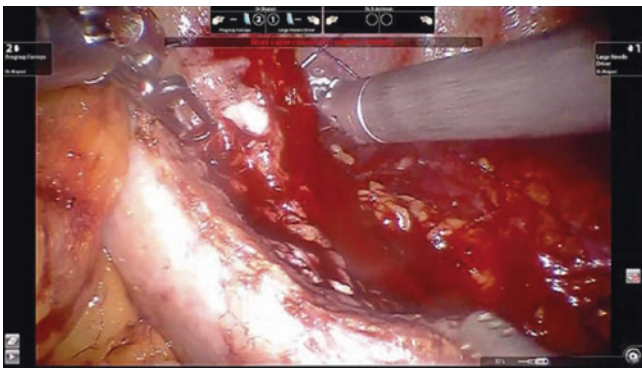


Fig. 15.21 Inner layer parenchymal suture with 3-0 barbed suture started

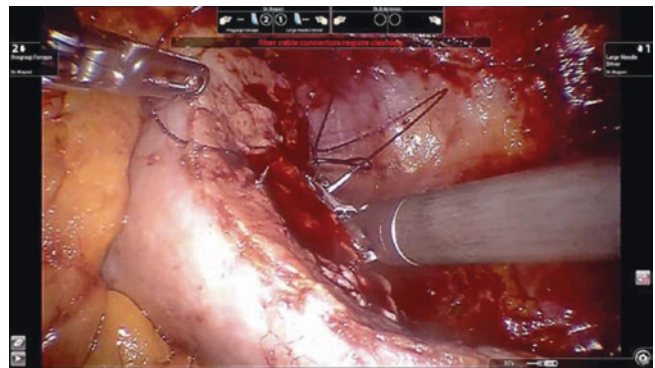


Fig. 15.22 Continuous suture of first layer in progress

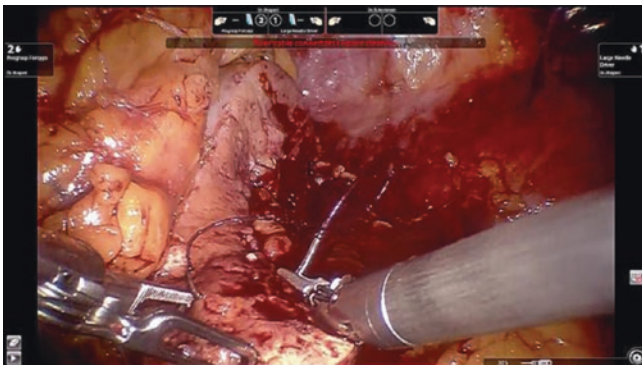


Fig. 15.23 Continuous suture in progress

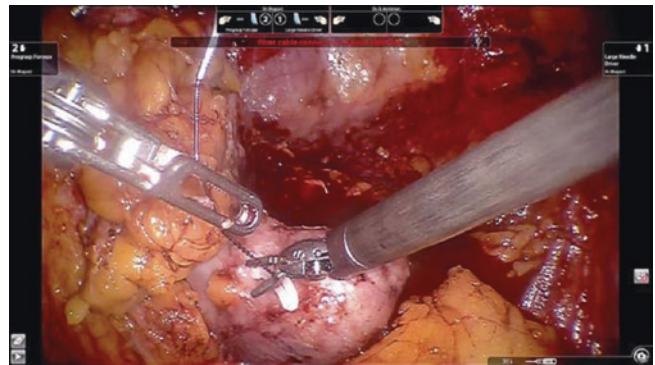


Fig. 15.24 Inner parenchymal suture – First layer completed with sliding clip

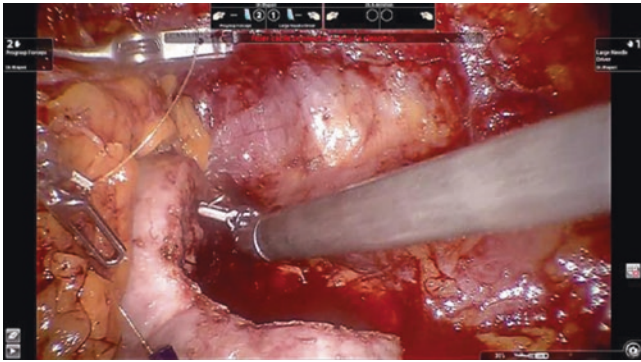


Fig. 15.25 Inner parenchymal suture – second layer started

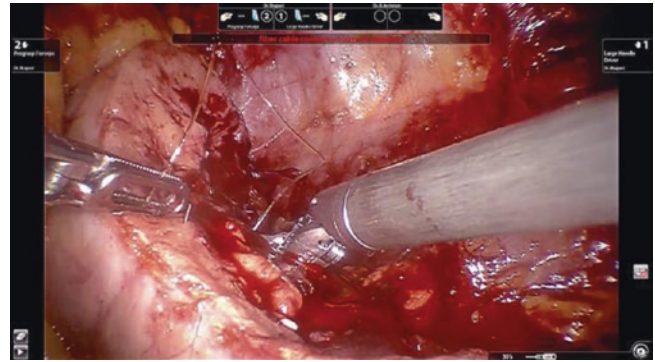


Fig. 15.26 Inner parenchymal suture – second layer in progress

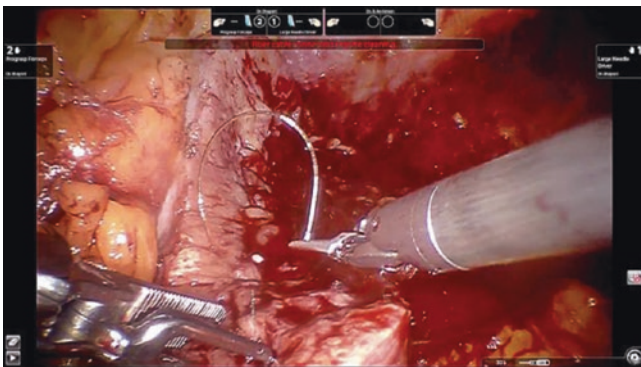


Fig. 15.27 Second layer continuous suture in progress

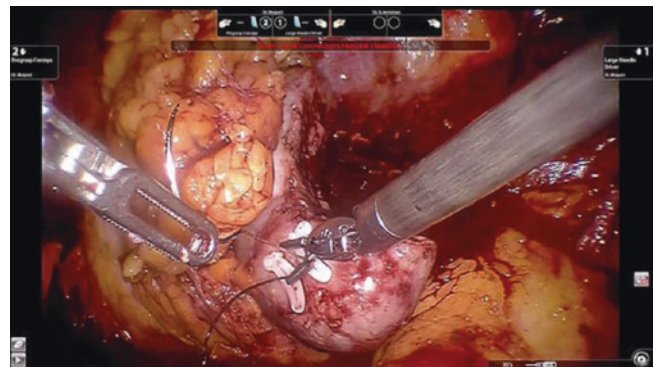


Fig. 15.28 Inner parenchymal suture – second layer completed

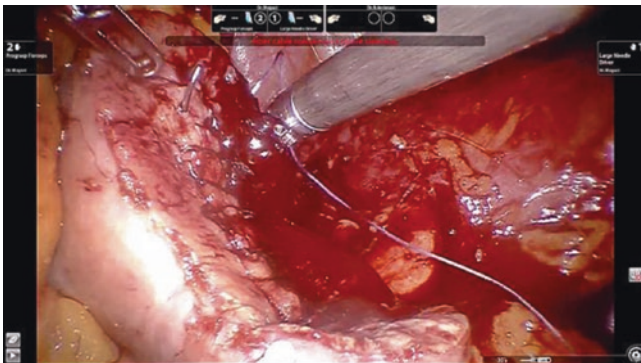


Fig. 15.29 Outer mass closure with 2-0 barbed suture started

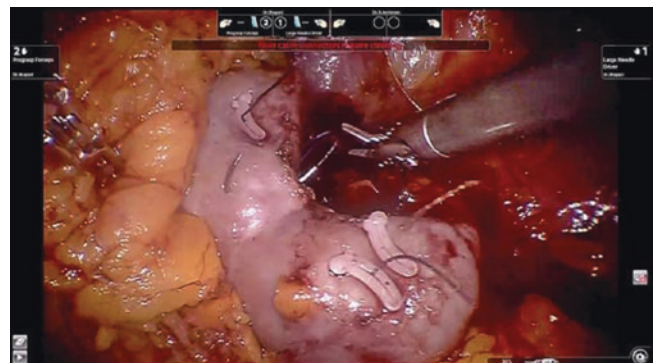


Fig. 15.30 Outer mass closure in progress

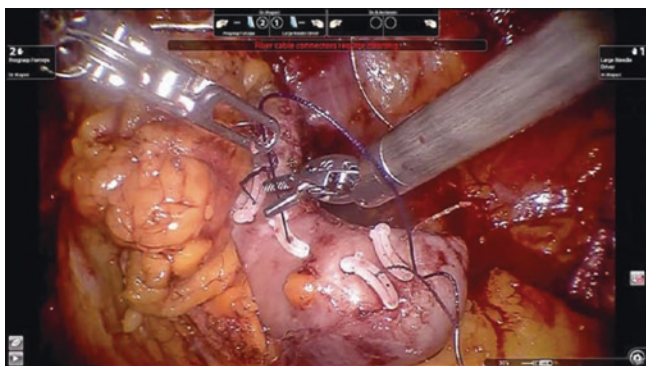


Fig. 15.31 Outer mass closure in progress

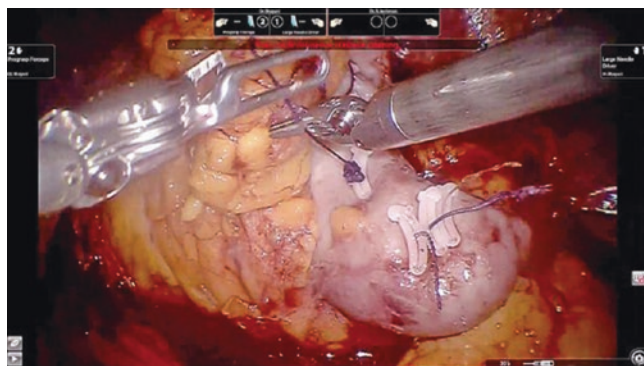


Fig. 15.32 Outer mass closure in progress

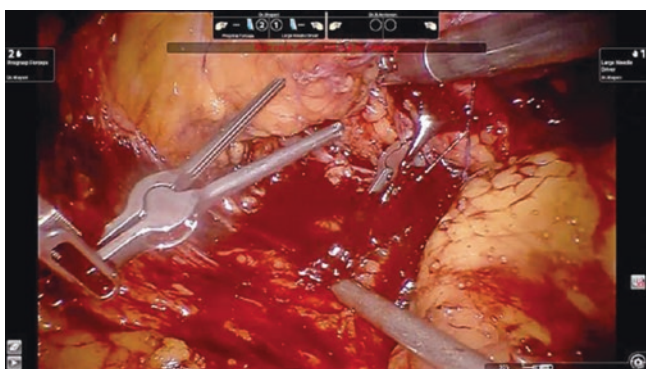


Fig. 15.33 Hilar clamps released

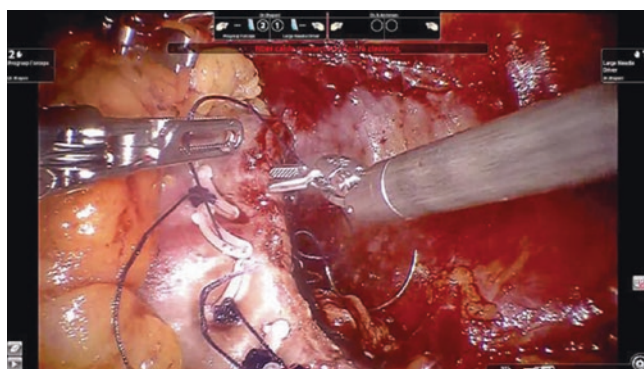


Fig. 15.34 If there is any bleeding sutures can be tightened further with Lapra-tie

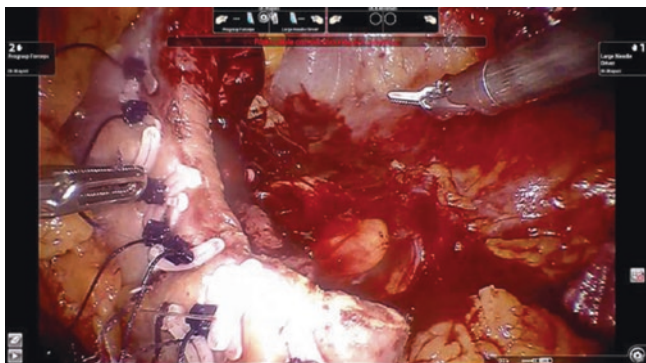


Fig. 15.35 Closure completed

Part III

Reconstructive Procedures of the Ureter

Manickam Ramalingam, Shailesh A. Shah,
Prashanth Kulkarni, Kallappan Senthil,
Anandan Murugesan, and Mizar G. Pai

16.1 Introduction

Uretero ureterostomy is performed for various pathologies like retrocaval ureter, stricture, malignant lesions etc. Though many reports on the laparoscopic management of retrocaval ureter are available, there are very few reports on ureteric stricture management by laparoscopic approach. According to Gill et al. who broadly classified laparoscopic reconstructive urology, ureteroureterostomy still falls under evolving procedure group. The technique varies slightly for various diseases [1–5].

Recently the concept of using buccal mucosa for reconstruction of diseased ureteral segment is coming up and its early results are excellent with no added morbidity.

Significant morbidities. There are only a few case reports available in the literature, wherein buccal mucosa was used for ureteral reconstruction. Few reports are available on open procedure for the management of long segment ureteral defect management. Buccal mucosa is used as either as a patch graft or a tubularised graft.

In this chapter, the following techniques are covered.

1. Ureteroureterostomy for retrocaval ureter – Trans peritoneal and retroperitoneal approach
2. Excision with Uretero ureterostomy for ureteric stricture.
3. Buccal mucosal graft ureteroplasty for ureteric stricture
4. Trans ureteroureterostomy

M. Ramalingam
PSG Hospitals,
Coimbatore, India
e-mail: uroram@yahoo.com

S.A. Shah (✉)
Department of Urology, Bodyline Hospitals,
Ahmedabad, Gujarat, India
e-mail: shaileshshahuro58@gmail.com

P. Kulkarni
Department of Urology, Narayana Health,
Bangalore, Karnataka, India
e-mail: uroprashant@gmail.com

K. Senthil
Urology clinic, Gowtham Annexe, Coimbatore, India
e-mail: senthilsatya@hotmail.com

A. Murugesan
Department of Urology, PSG Institute of Medical Sciences
and Research, Peelamedu, Coimbatore, Tamil Nadu, India
e-mail: anandan79@gmail.com

M.G. Pai
Urology Clinic, 3/1054, Gowtham Annexe, Avinashi Road,
Coimbatore 641018, India
e-mail: mizargpai@yahoo.co.in

16.2 Indications for Surgery

Patients with retrocaval ureter are usually asymptomatic and surgery is indicated only when the patient is symptomatic or develops back pressure changes in the kidney. Short strictures (post TB, ureterolithotomy, URS etc) are amenable for uretero ureterostomy. Long strictures in the mid ureter are better managed with buccal mucosal graft ureteroplasty or trans uretero ureterostomy. Trans ureteroureterostomy is also done along with ureterocystoplasty or cutaneous ureterostomy.

16.3 Evaluation

CT urograms is ideal to delineate the features of retrocaval ureter and also ureteric strictures. Intravenous Urogram may also be a useful investigation. Classical fish hook sign may be seen in intravenous Urogram and strictures can also be clearly delineated. RGP prior to surgery is essential in most cases, to plan the type of procedure required.

16.4 Technique

16.4.1 Trans Peritoneal Uretero Ureterostomy for Retrocaval Ureter

Retrograde pyelogram is done before laparoscopy to rule out associated distal obstruction.

The patient is placed in the right lateral position with a 70° tilt. Four ports (a 10 mm port 5 cm above and lateral to umbilicus for the telescope; a 5 mm port in the right subcostal region; a 5 mm port in the right iliac fossa, and a 5 mm port on the right flank for suction and irrigation) are inserted. The right colon is mobilized adequately to expose the ureter and inferior vena cava (IVC). The ureter is dissected from the IVC adequately and transected proximally at the lateral border of IVC, where it starts to wind around posteriorly. The circumcaval segment of the ureter is then transposed anteriorly. The stenotic ureter may be excised and the ends spatulated. Ureteroureterostomy suture starts in the posterior layer with interrupted 4-0 vicryl. Stent is inserted and anterior layer is completed. Omental wrapping or tacking is optional. A 14 Fr tube drain is placed through the flank port.

16.4.2 Retroperitoneal Uretero Ureterostomy for Retrocaval Ureter

Retrocaval ureter is usually approached transperitoneally. However a retroperitoneal approach is appropriate as both IVC and ureter are retroperitoneal organs. It has the definite advantage of retroperitoneoscopy.

16.4.3 Transperitoneal Approach for Ureteric Stricture Excision and Uretero Ureterostomy

With the patient under general anaesthesia and lateral decubitus with 75° tilt the ureter is approached transperitoneally. Pneumoinflation is done using veress needle. A 10 mm port is inserted at subumbilical area for the telescope. Under laparoscopic vision two working ports (5 mm suprapubic and 10 mm flank) are inserted. The ports are kept well away from any previous scar of ureterolithotomy. The right lateral peritoneal fold is identified and incised. After colonic mobilization, in retroperitoneal space the dilated proximal ureter is identified and dissected. The ureter is gently held with grasping forceps and further dissected in the pelvis. The ureter is traced upto the site of stricture. Sometimes the ureter may be adherent to the underlying vessel. If the strictured segment is densely adherent to the underlying artery with significant

scarring, we can choose not to excise. With sharp and blunt dissection lower ureter can be identified and is dissected sufficiently. Proximally dilated ureter is transected just above strictured segment and lower ureter is transected below the diseased segment of ureter. The lower end of ureter is spatulated. The anastomosis is performed using 4-0 polyglactin suture on 20 mm needle. First an apical suture is taken intracorporeally. A double J stent is placed with the help of a ureteroscope (9.5 Fr). Four posterior sutures followed by three anterior interrupted sutures are taken to complete the anastomosis. A penrose drain is kept adjacent to anastomosis. Pneumoperitoneum is desufflated and port sites are closed.

Urethral catheter is removed on the third post operative day followed by drain removal in the evening on the same day. Patient is discharged on the fourth postoperative day. Double J stent is removed after 3 weeks.

16.4.4 Trans Peritoneal Buccal Mucosal Graft Ureteroplasty

Three ports are used for the procedure; one 10 mm camera port and two 5 mm working ports. Colon is reflected medially, and the dilated pelvis and narrow segment of the ureter are identified. Extensive dissection is usually avoided but the dissection all around the abnormal ureter is a must for omental wrap in the end. The narrow segment of ureter is incised starting at the proximal dilated segment. Lower down healthy ureter is reached, which can be identified by an abnormal ureter diameter on visual impression, putting healthy mucosa in the normal ureter or by doing intra operative flexible ureteroscopy if the facility is available. After incising the ureter a strip of narrow ureter remains with stent in situ. From the ureteral margin biopsy can also be taken without compromising the width of the ureter.

Buccal mucosa is harvested depending on the length of defect and it is harvested from the non-dependent cheek. On either ends of the buccal mucosa, stay sutures are placed, which will help in handling the graft inside the body. Prepared buccal mucosa is placed in a small endobag and dropped in to the abdominal cavity via the 10 mm port. Buccal mucosa is placed as a dorsal onlay graft over the opened ureter. 4-0 polyglactin continuous or interrupted sutures can be used for suturing the graft with the ureterotomy. Omentum is mobilized and is placed as a wrap around the reconstructed site. The 5 mm iliac fossa port is used to place a drain tube.

Post operatively, urethral catheter is removed on the 5th post operative day and the drain is removed on the next day. DJ stent will be removed after 6 weeks and the follow up is similar to laparoscopic pyeloplasty.

16.4.5 Trans Uretero Ureterostomy

Patient is placed in supine position with Trendelenberg tilt. Four ports namely 10 mm camera port supraumbilical area, two 5 mm ports in the mid clavicular line at the level of umbilicus one on each side and another 5 mm port superomedial to the anterior superior iliac spine for suction and irrigation are placed. The diseased ureter is dissected from the bladder proximally till the normal ureter is seen (and felt). Ureter is divided at this level and the diseased segment is left in situ or excised, as the case may be. The ureter is tunneled beneath the sigmoid meso colon to reach the opposite iliac fossa. The dissection plane is superficial to the sacral promontory. This helps to tunnel the ureter just beneath the inferior mesenteric artery. The cut ureteric end is placed along the path of the normal contralateral ureter and the site of anastomosis selected, which provides tension free suturing. Once the site is selected, peritoneum over the normal contralateral ureter is incised. Extensive dissection of normal ureter is avoided to prevent devascularisation. Vertical incision is made over the contralateral normal ureter and the native ureteral (diseased) end is spatulated. Uretero ureterostomy is done with 4-0 polyglactin sutures in a continuous or interrupted fashion over a stent. Drain is placed and port sites closed.

16.5 Discussion

Many of the ureteral strictures are today managed by endourological techniques, including balloon dilatation and endoureterotomy. Patients with complete obliteration of ureter, as in our case, requires surgical excision and repair.

Iatrogenic ureteral strictures are commonly reported after gynecological surgeries. Tulikangas et al. [6] reported four

cases of laparoscopic ureteral repair in patients with pelvic ureter injury following laparoscopic gynecological surgery. The result was good except in one patient, in whom stricture developed at anastomotic site and this was managed conservatively. Nezhat et al. described end to end laparoscopic ureteroureterostomy in a patient with ureteral obstruction secondary to endometriosis. Among nine patients, one patient developed mild anastomotic stenosis managed conservatively with balloon dilatation and one patient developed recurrent endometriosis at anastomotic site. Similarly, Bhandarkar DS et al. has reported one case of laparoscopic resection and ureteroureterostomy for congenital mid ureteral stricture with successful outcome [6–9].

Buccal mucosal onlay patch graft can be safely performed by total laparoscopic approach without compromising on the outcome. This idea of making use of Laparoscopy in ureteral reconstruction was put forth by late Prof H S Bhat in one of his meetings (hence the name Prof H S Bhat procedure – patch onlay graft using buccal mucosa). Laparoscopic buccal mucosal graft ureteroplasty has the advantage of avoiding a major procedure like bowel interposition or auto transplantation, with good cosmesis. This procedure can be attempted by an uro-surgeon who has good laparoscopy skills with intracorporeal suturing techniques [14–18].

Trans uretero ureterostomy is useful in long mid and lower ureteric strictures with normal contralateral ureters, where bladder is diseased [9–14].

16.6 Conclusion

Ureteroureterostomy for various indications, by various methods can be completed laparoscopically with comparable results to open surgery.

16.7 Transureteroureterostomy for Retrocaval Ureter

16.7.1 Transperitoneal Approach

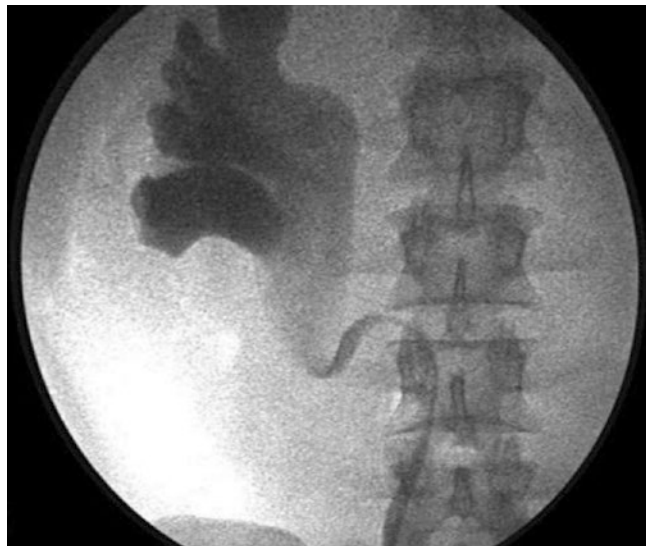

Fig. 16.1 RGP image showing the classical fish hook sign

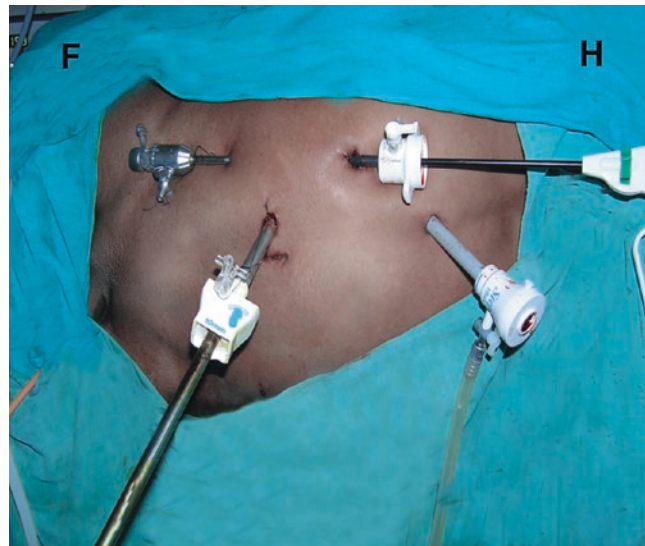


Fig. 16.2 Ports position

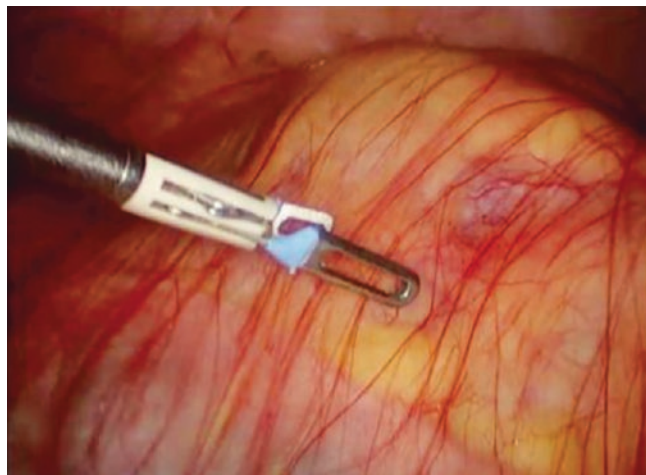


Fig. 16.3 Initial view of the right hydronephrotic kidney

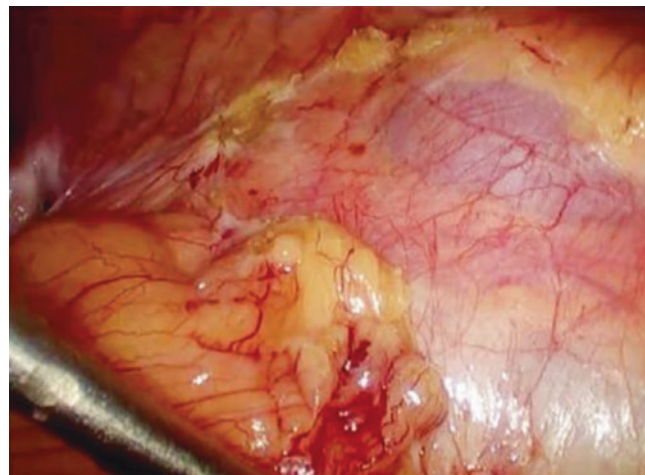


Fig. 16.4 Right colon being reflected

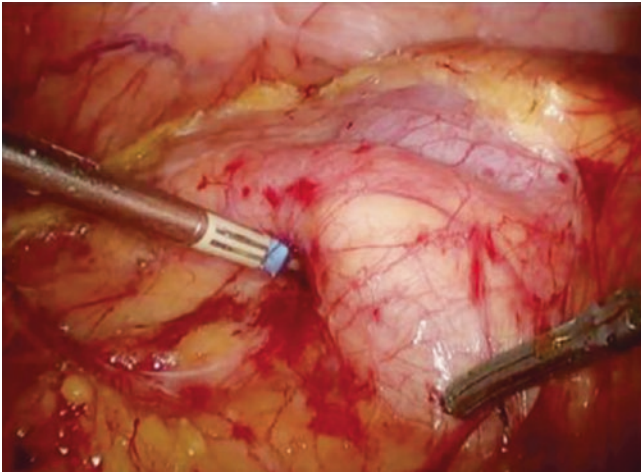


Fig. 16.5 Dilated pelvis and upper part of the ureter

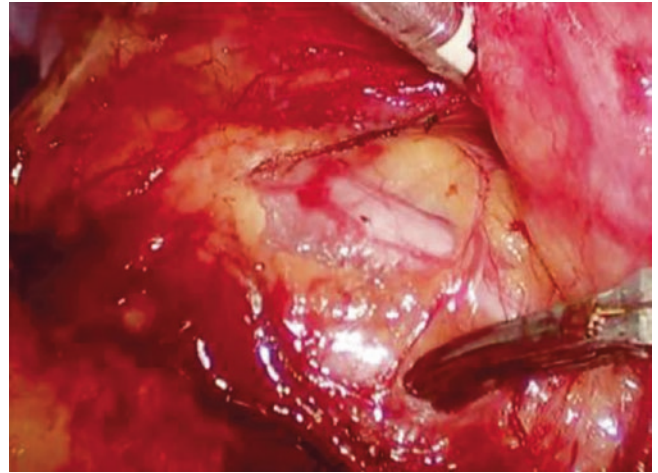


Fig. 16.6 Normal ureter caudal to retrocaval segment seen medial to IVC

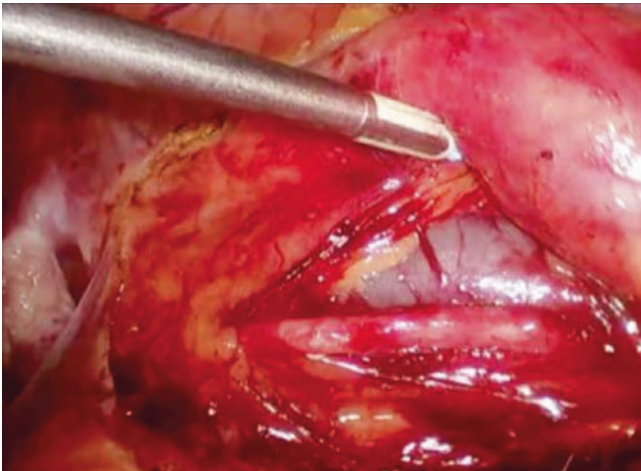


Fig. 16.7 IVC seen between dilated and undilated part of ureter

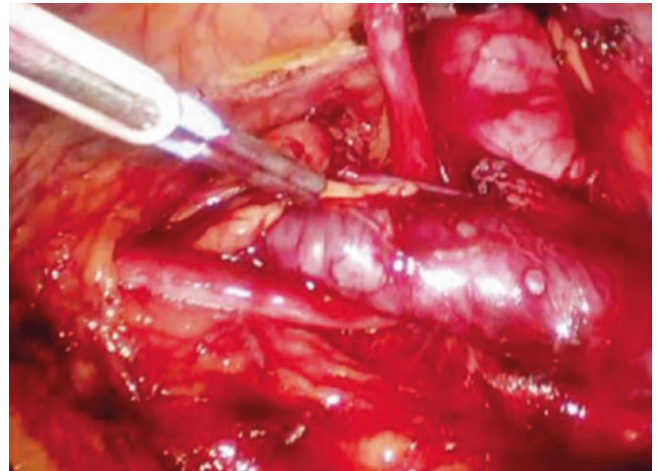


Fig. 16.8 Retrocaval part of ureter identified

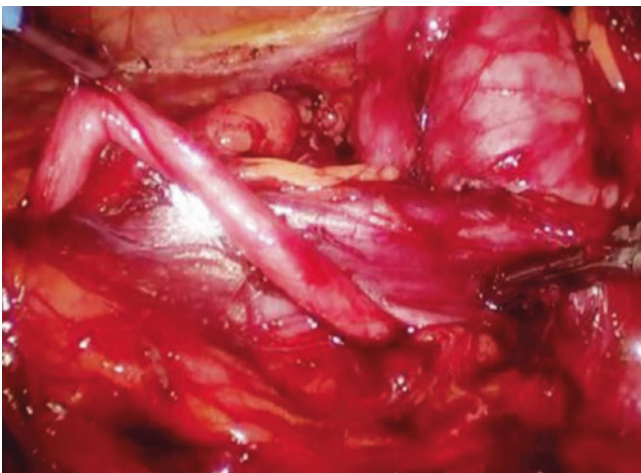


Fig. 16.9 Retrocaval segment completely dissected

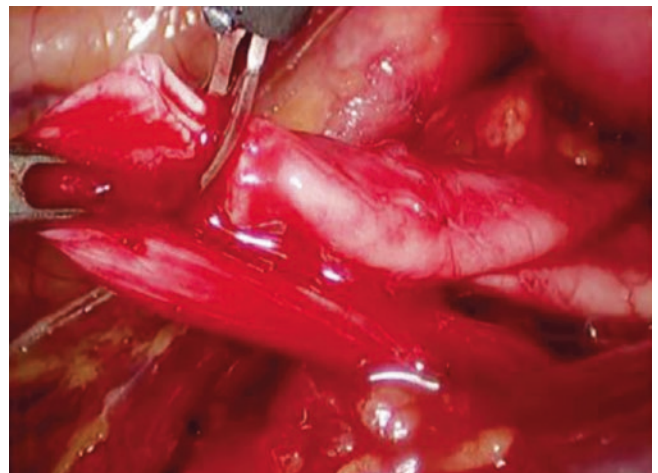


Fig. 16.10 Distal end of dilated ureteric segment being divided

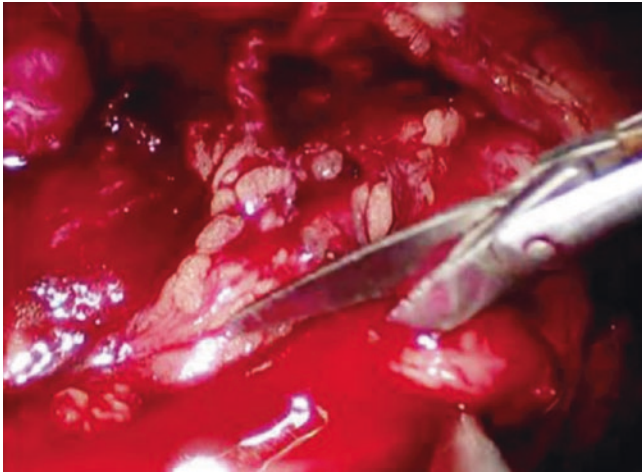


Fig. 16.11 Lower part of ureter spatulated

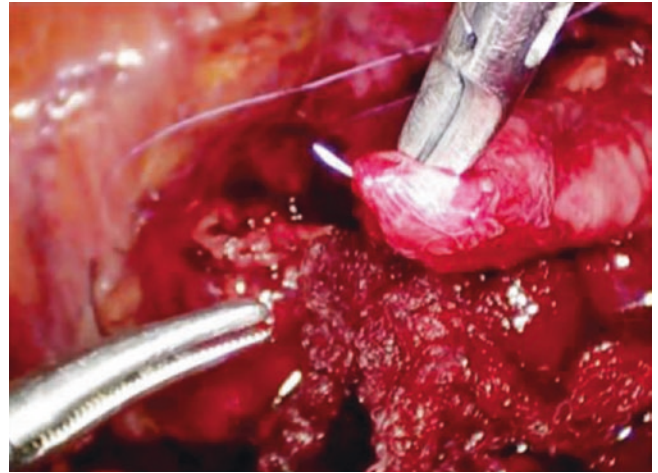


Fig. 16.12 Posterior layer suture with 4-0 vicryl started from the upper part of divided ureter

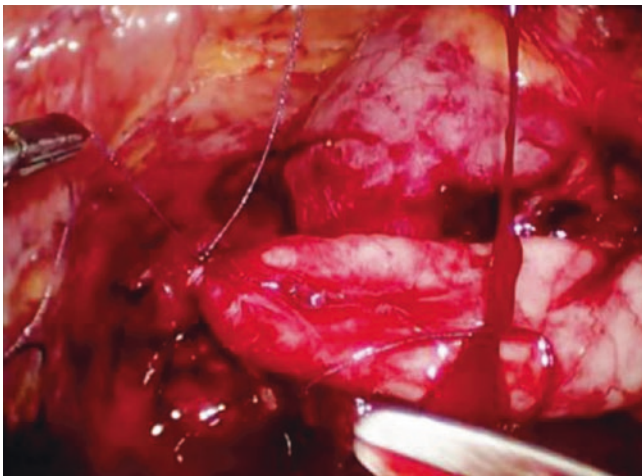


Fig. 16.13 Corresponding suture through the lower end ureter – apical suture in place

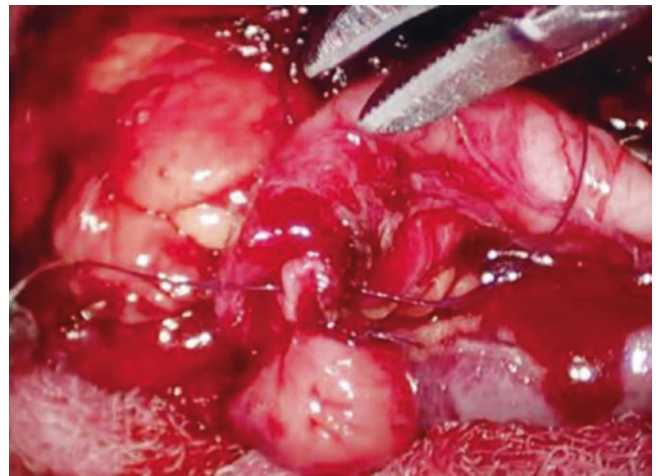


Fig. 16.14 Posterior layer suturing in continuous fashion

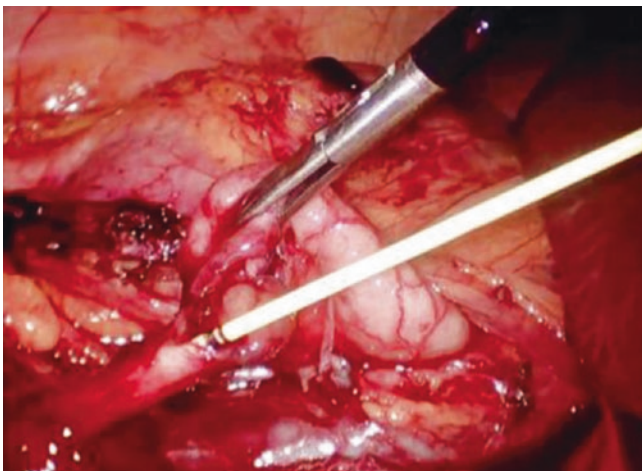


Fig. 16.15 Stent inserted antegrade after completion of posterior layer suture

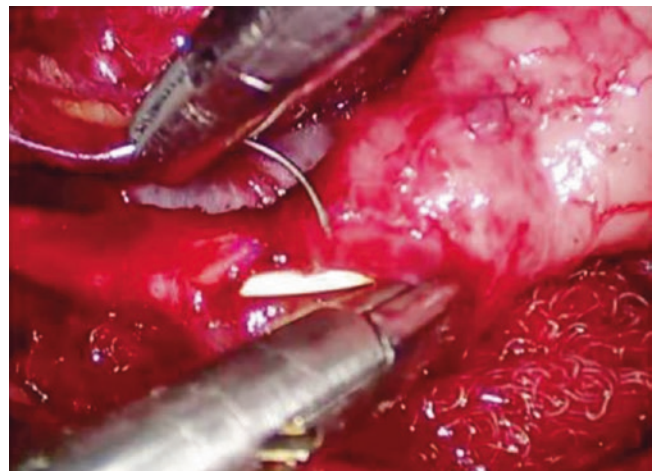


Fig. 16.16 Anterior layer suturing in progress

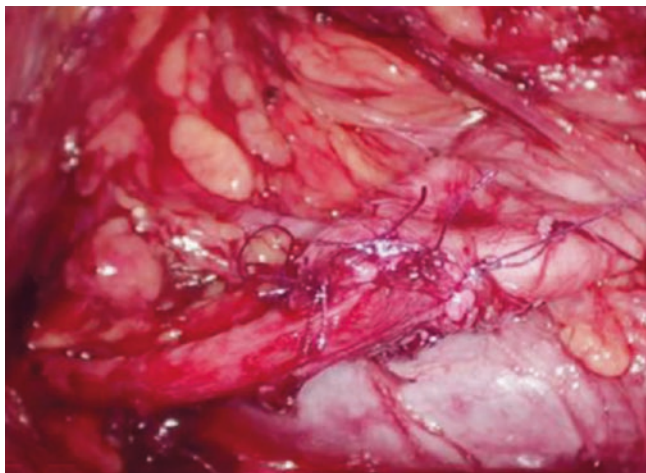


Fig. 16.17 Anterior layer suturing completed

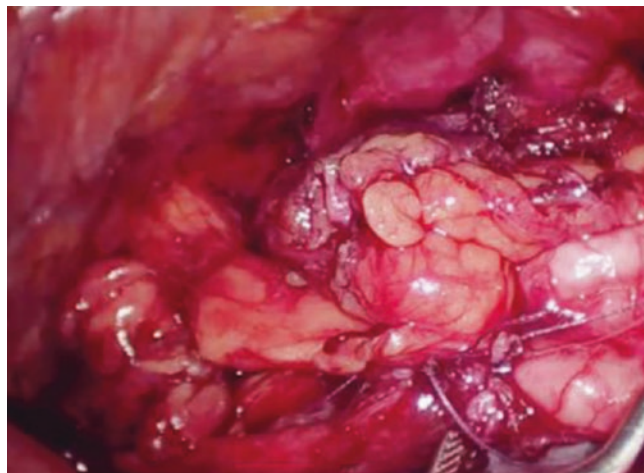


Fig. 16.18 Perinephric fat cover for anastomosis

16.7.2 Retroperitoneoscopic Ureteroureterostomy for Retrocaval Ureter

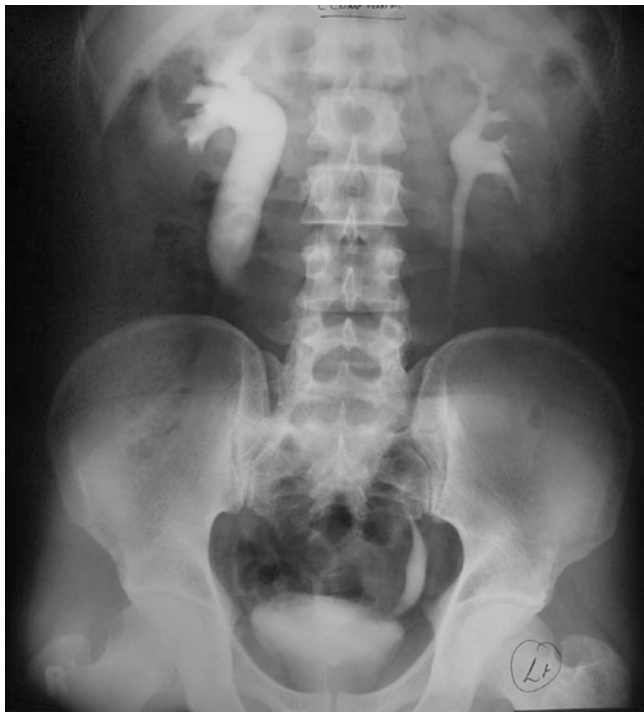

Fig. 16.19 IVU showing Seahorse sign suggestive of retrocaval ureter

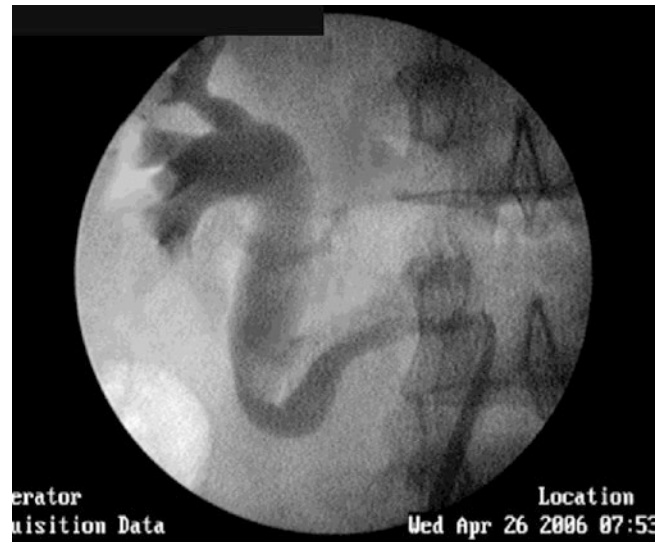

Fig. 16.20 RGP showing smooth upper ureteric narrowing and sinuous course suggestive of retrocaval ureter

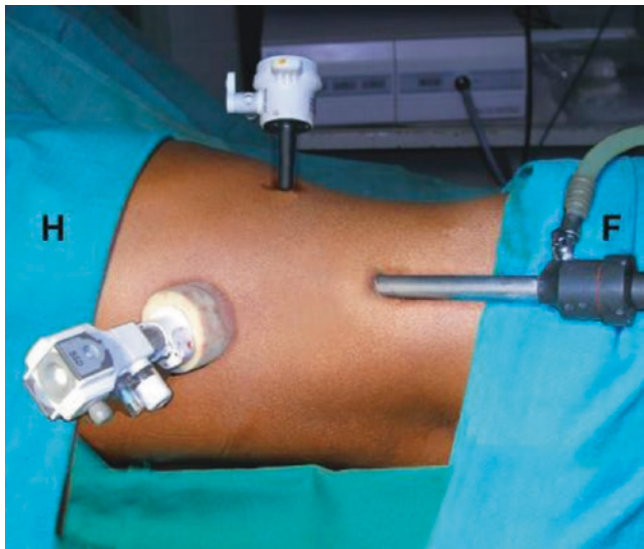


Fig. 16.21 External view of ports position

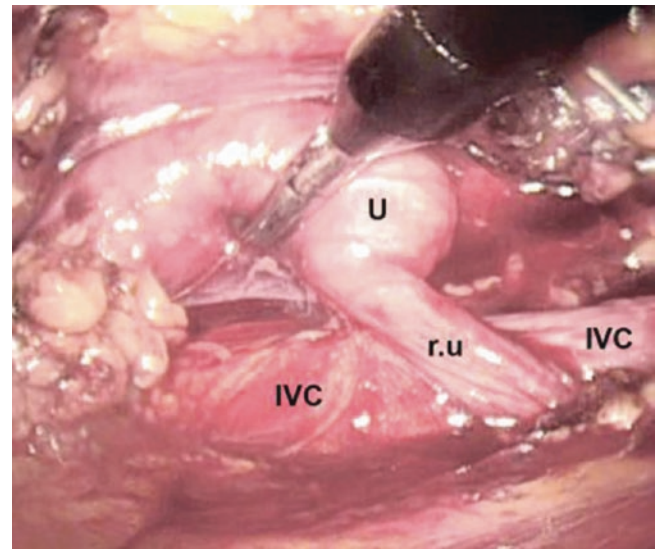


Fig. 16.22 Retroperitoneoscopic view of dilated upper ureter hooking IVC, *U* Dilated ureter, *r.u* Retrocaval segment of ureter

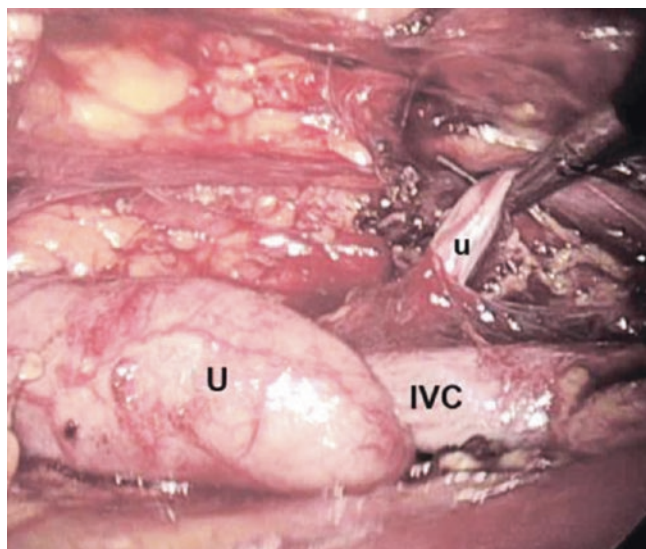


Fig. 16.23 Dissection on the medial aspect showing normal caliber ureter, *U* Dilated ureter

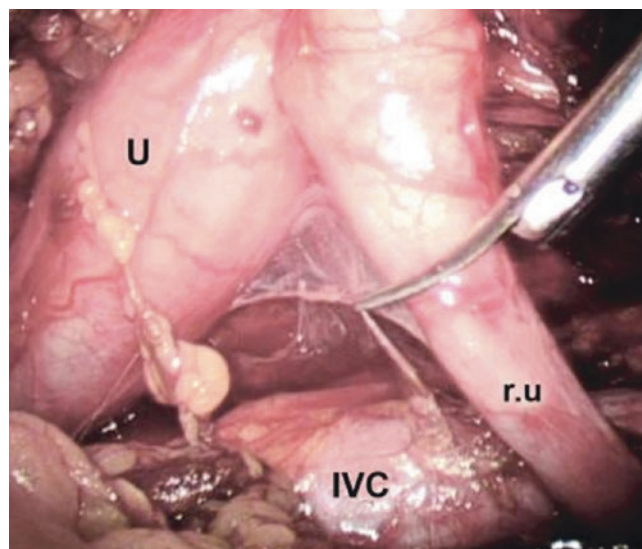


Fig. 16.24 Division of ureter on the transition zone, *U* Dilated ureter, *r.u* Retrocaval segment of ureter

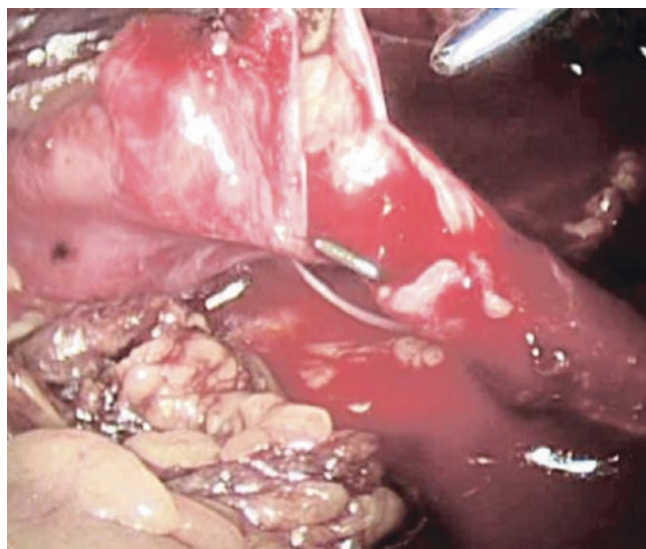


Fig. 16.25 Division of ureter on the transition zone

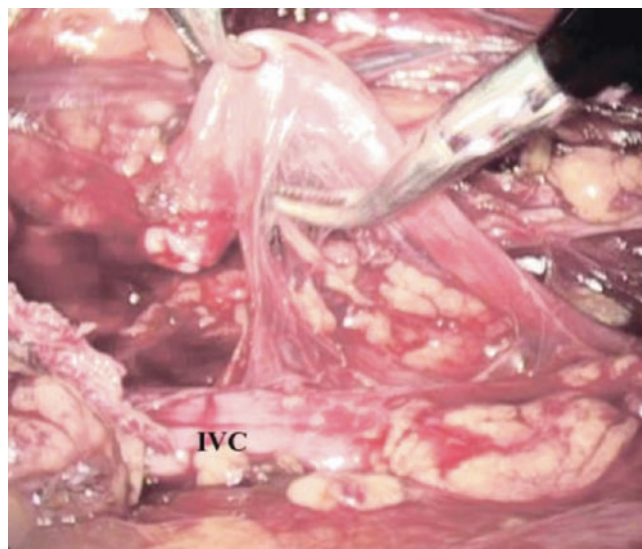


Fig. 16.26 Transposition of retrocaval segment by pulling medially (as it appears to be of normal caliber, it doesn't need excision)

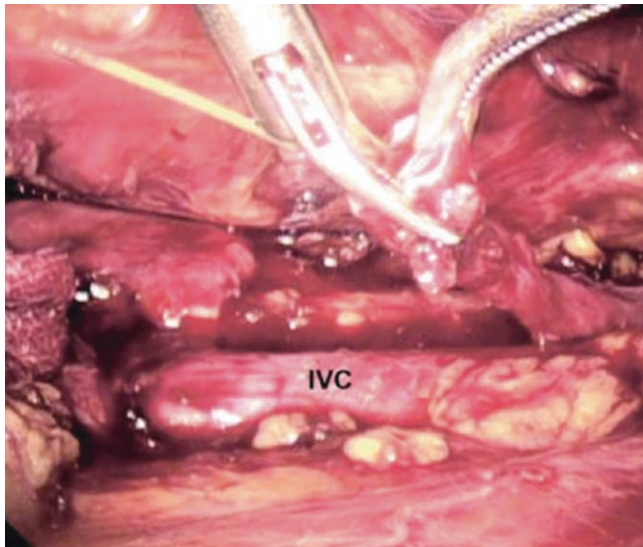


Fig. 16.27 Lateral spatulation of retrocaval segment of ureter (pre-placed guidewire comes into view)

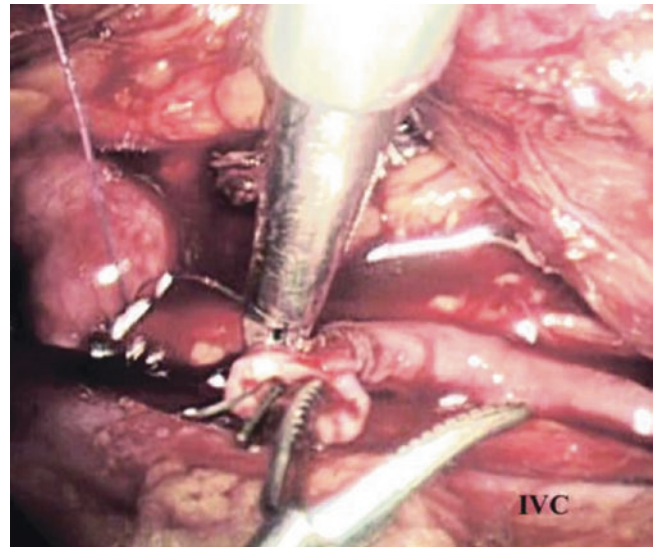


Fig. 16.28 Initial 4-0 vicryl suture taken outside in through the non-spatulated end of ureter

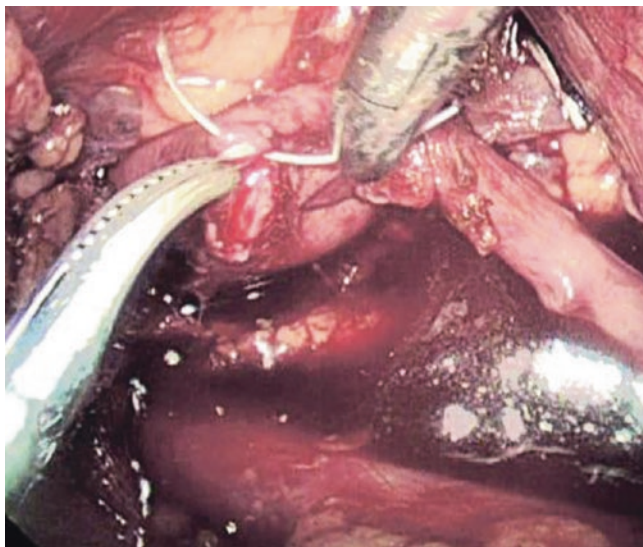


Fig. 16.29 Corresponding suture taken inside out through the medial aspect of the dilated ureter

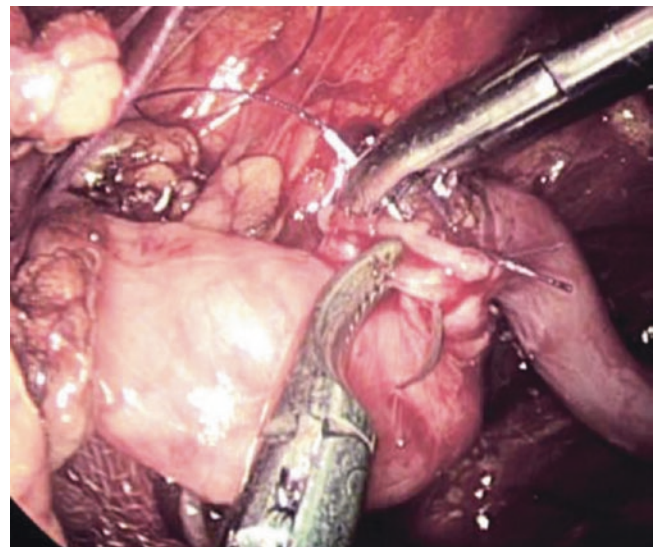


Fig. 16.30 Subsequent interrupted 4-0 vicryl suture

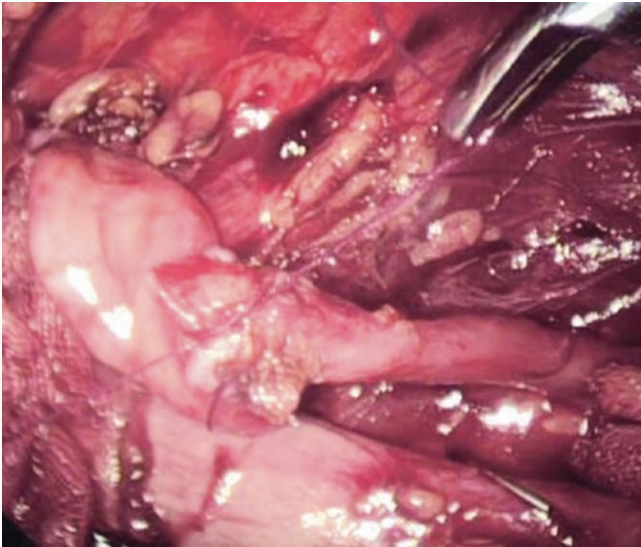


Fig. 16.31 Subsequent interrupted 4-0 vicryl sutures in progress

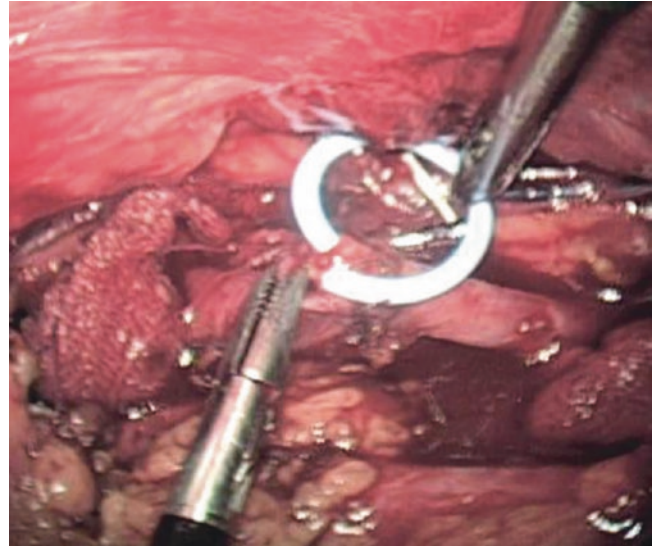


Fig. 16.32 After few interrupted sutures, stent is advanced retrograde

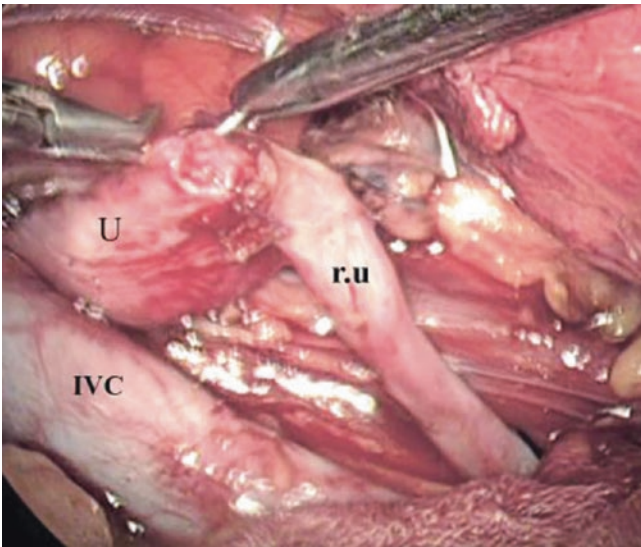


Fig. 16.33 With few more interrupted sutures (anterior layer) ureteroureterostomy is completed, *L* Lower pole kidney, *U* Dilated ureter, *r.u* Retrocaval segment of ureter

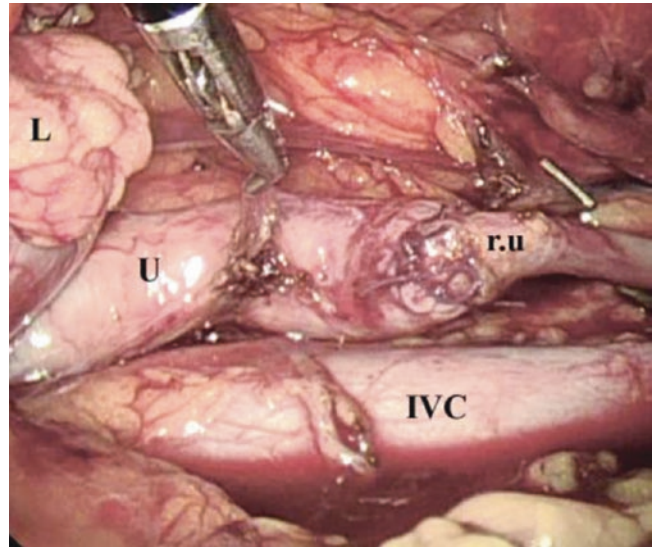


Fig. 16.34 Final view of completed ureteroureterostomy, *L* Lower pole kidney, *U* Dilated ureter, *r.u* previously retrocaval segment of ureter

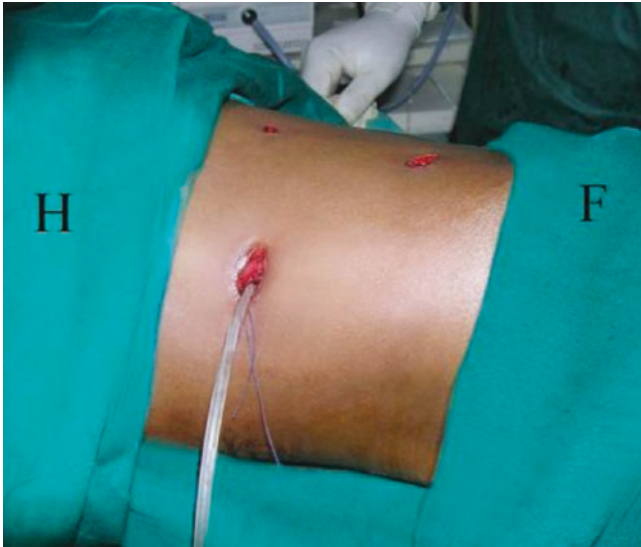


Fig. 16.35 Tube drain introduced through the primary port

16.7.3 Laparoscopic Ureteroureterostomy in Ureteral Stricture (Transperitoneal approach)

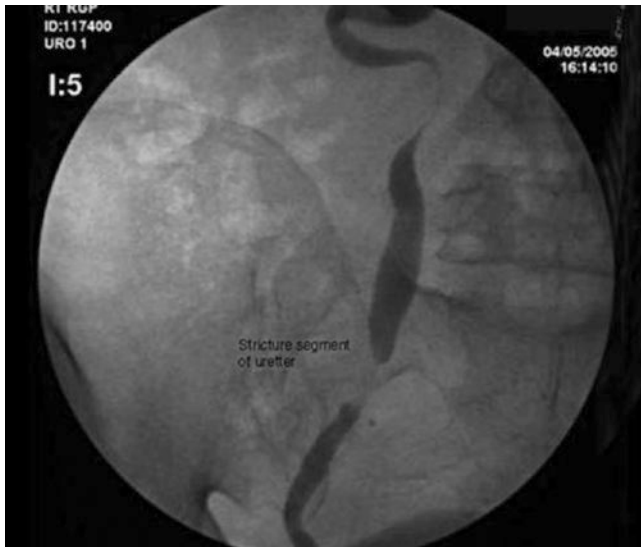

Fig. 16.36 Right RGP showing mid ureteric stricture

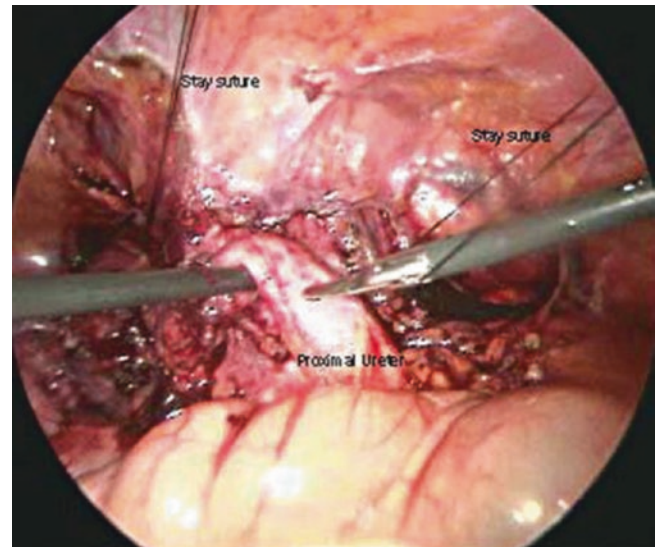


Fig. 16.37 Right colon mobilized. Midureter mobilized

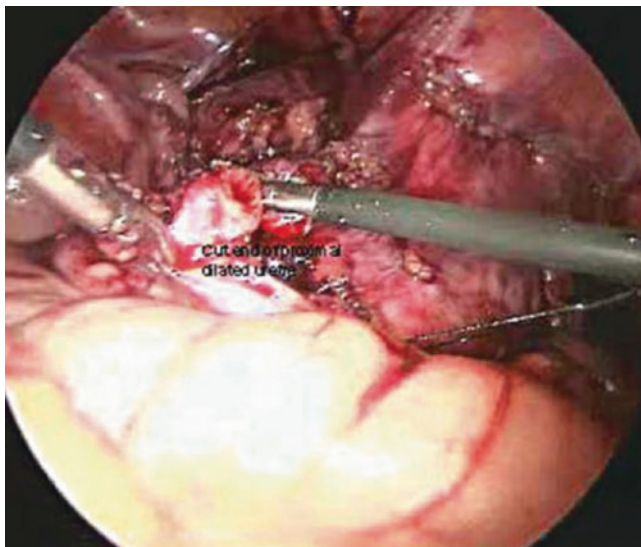


Fig. 16.38 Stricture segment excised

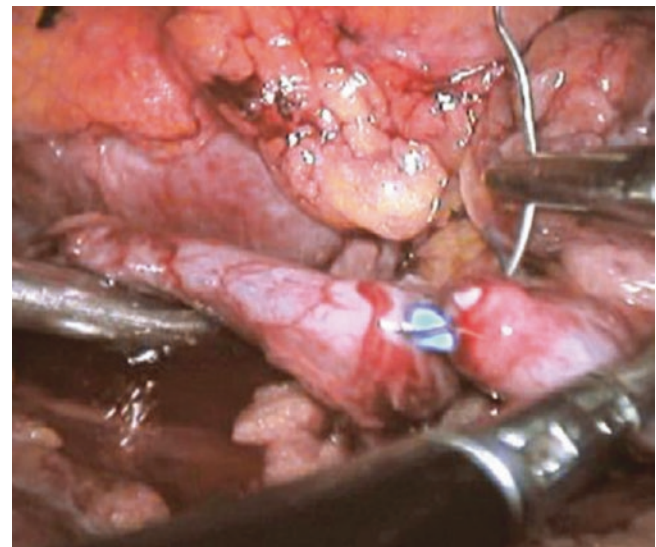


Fig. 16.39 Initial suture with 4-0 polyglactin passing through the dilated *upper* end of ureter and spatulated *lower* end

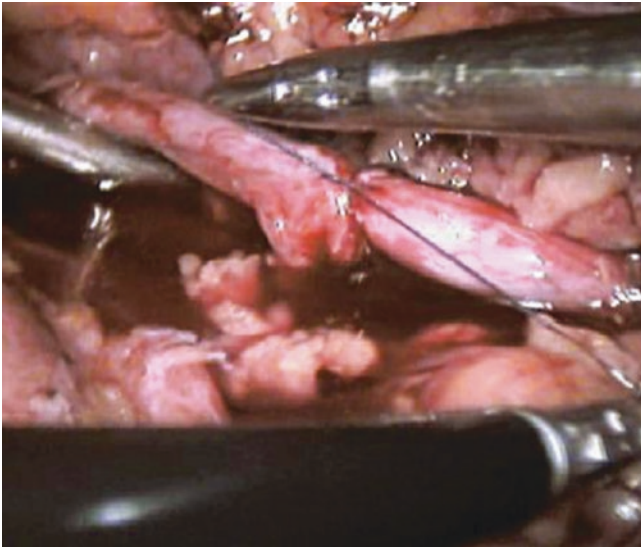


Fig. 16.40 Tension free approximation

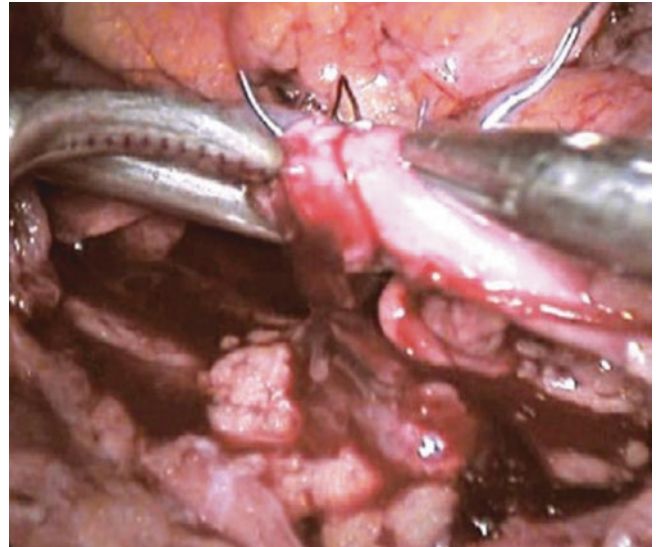


Fig. 16.41 Subsequent interrupted sutures

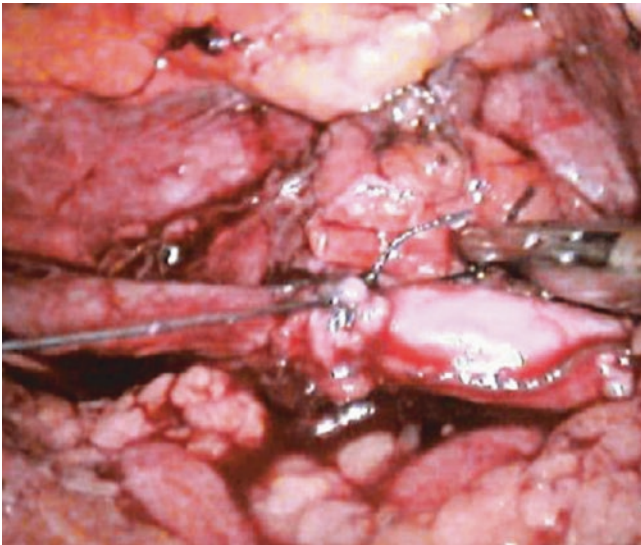


Fig. 16.42 Final view of ureteroureterostomy

16.7.4 Laparoscopic Buccal Mucosal Graft Ureteroplasty for Stricture Ureter

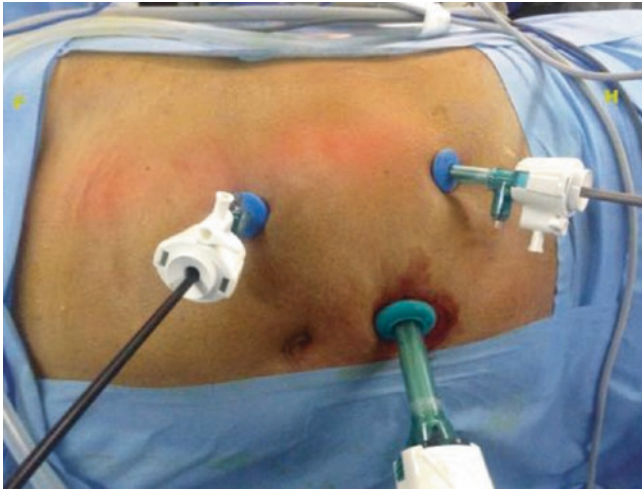

Fig. 16.43 Port position

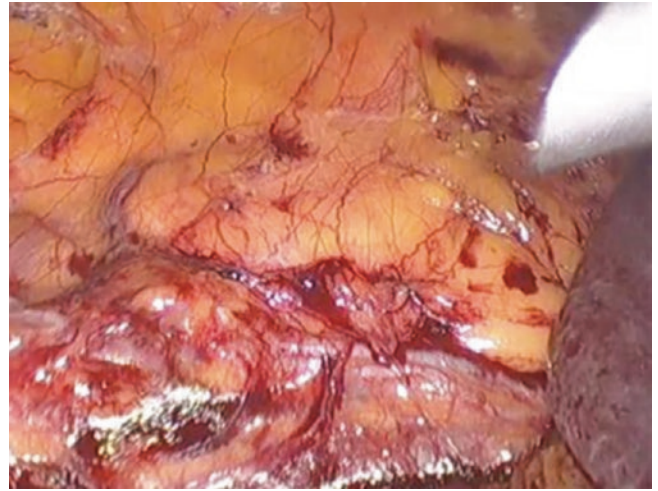


Fig. 16.44 Right colon mobilised

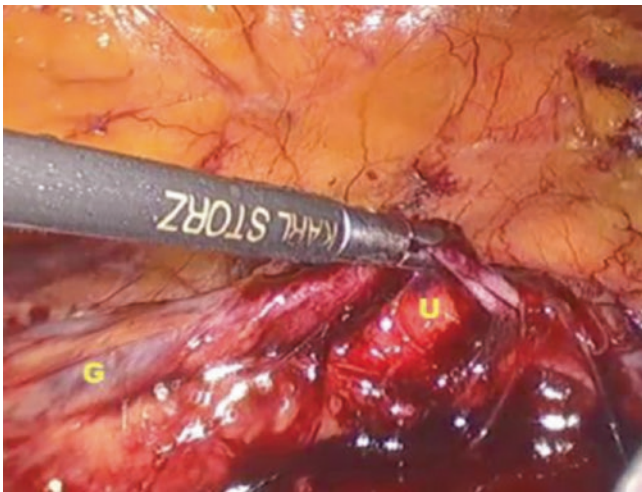


Fig. 16.45 Ureter being dissected off the adherant gonadal vein

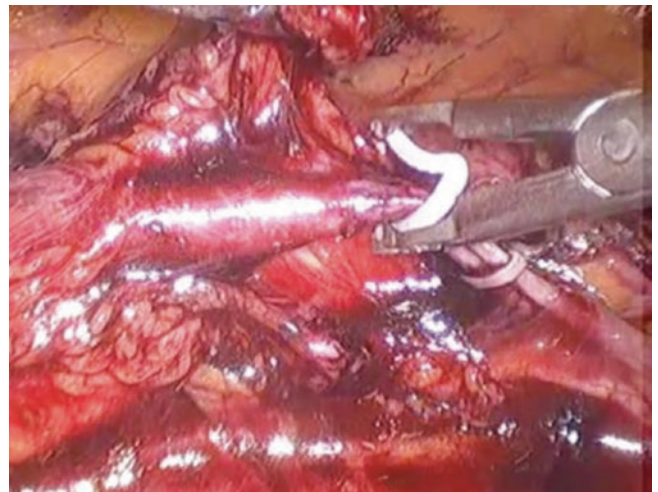


Fig. 16.46 Gonadal vein clipped

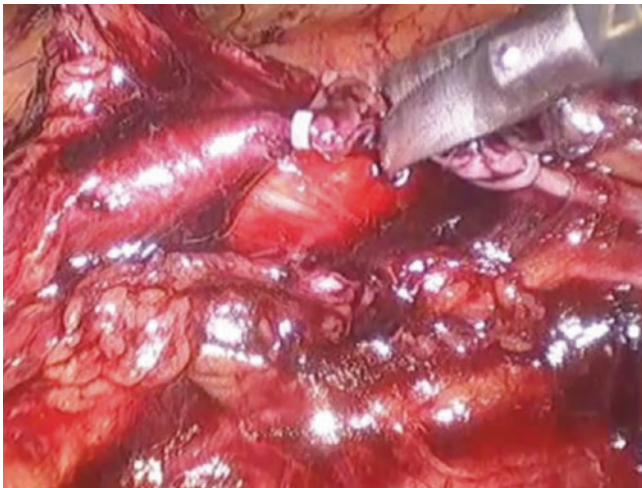


Fig. 16.47 Gonadal vein divided

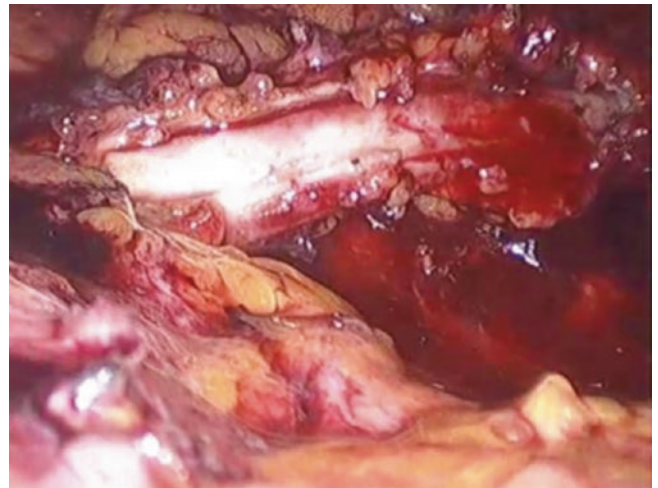


Fig. 16.48 Ureter visualised and mobilised

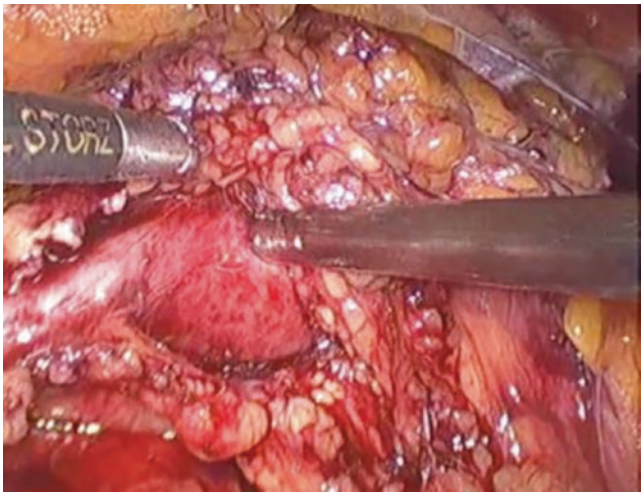


Fig. 16.49 Ureter dissected proximally till pelvis

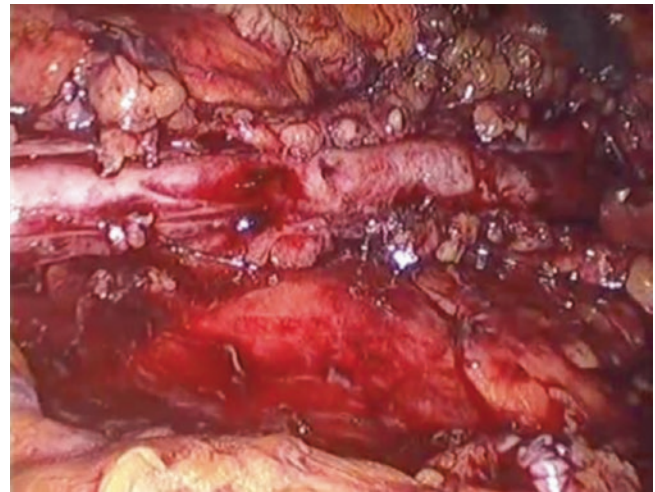


Fig. 16.50 Completely mobilised ureter and pelvis

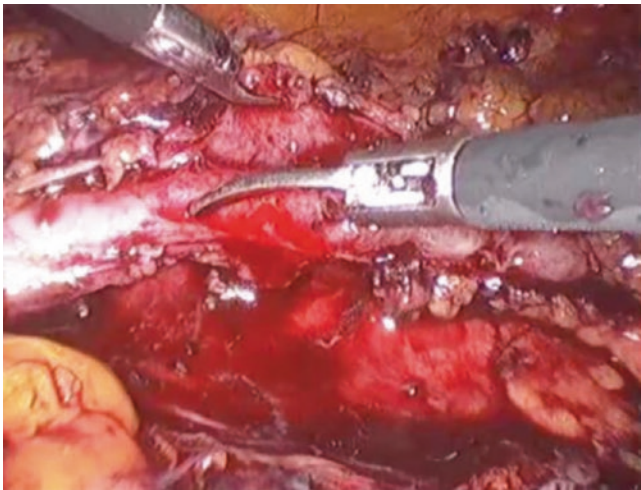


Fig. 16.51 Ureterotomy just above the level of stricture

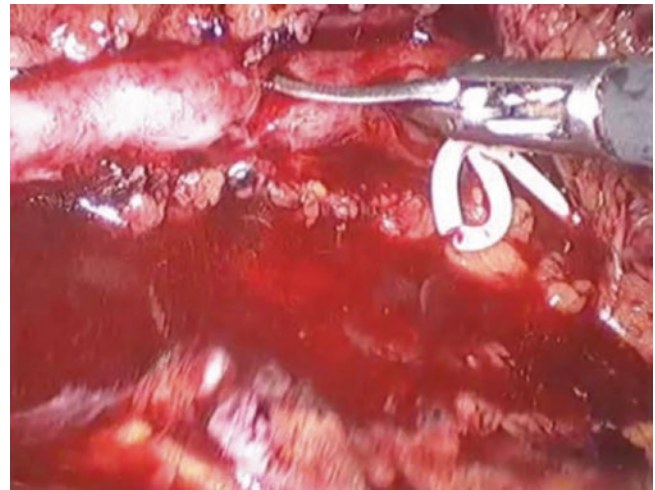


Fig. 16.52 Ureterotomy extended proximally and distally Preplaced stent seen

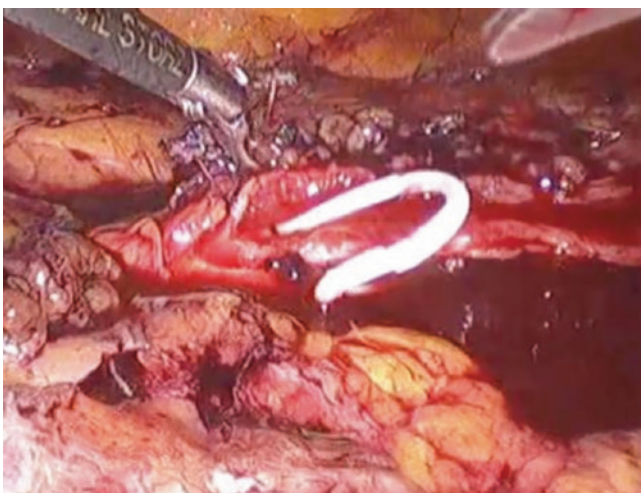


Fig. 16.53 Ureterotomy extended caudally till normal caliber ureter is seen

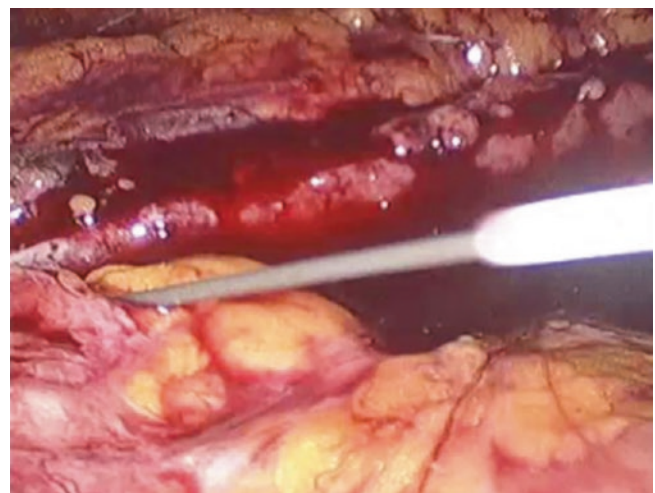


Fig. 16.54 New stent being inserted antegrade

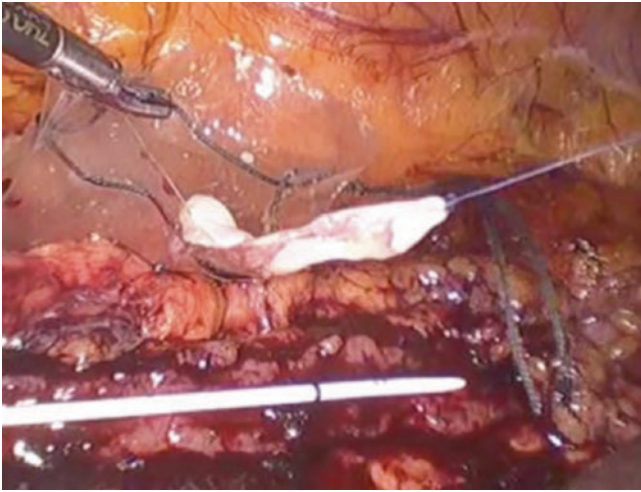


Fig. 16.55 Harvested buccal mucosa placed beside ureter

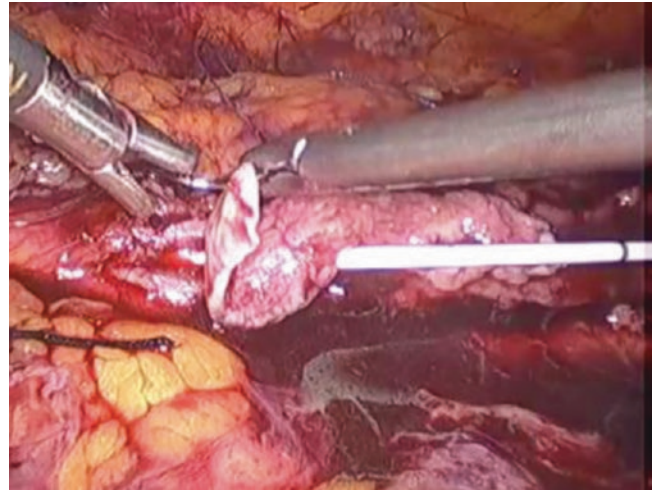


Fig. 16.56 Graft to ureter suturing done with 4-0 polyglactin sutures

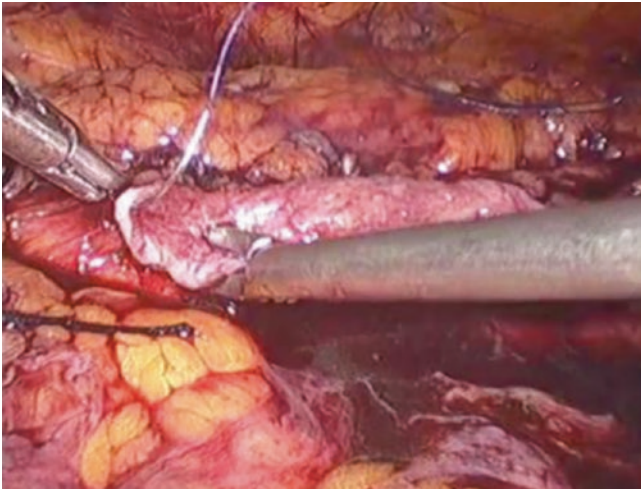


Fig. 16.57 Suturing started in the lower end

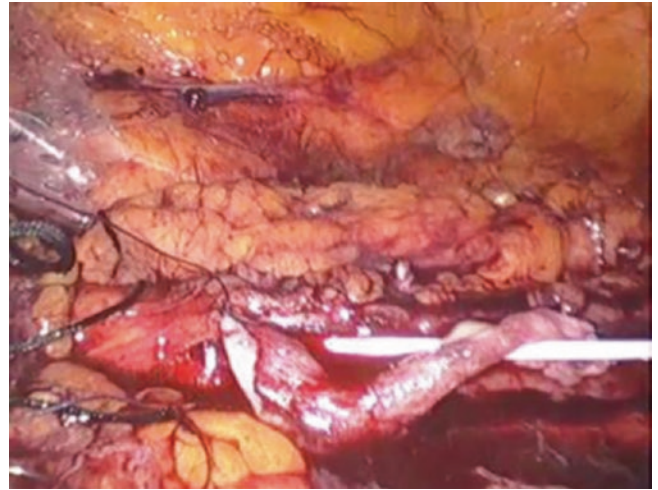


Fig. 16.58 Apical suture in place

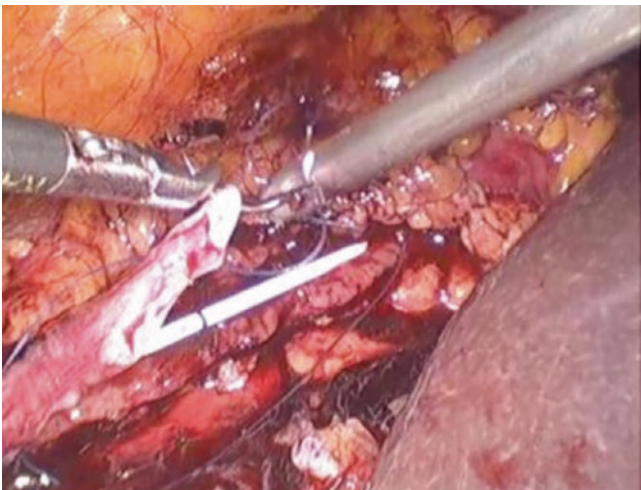


Fig. 16.59 Stay suture in the upper end

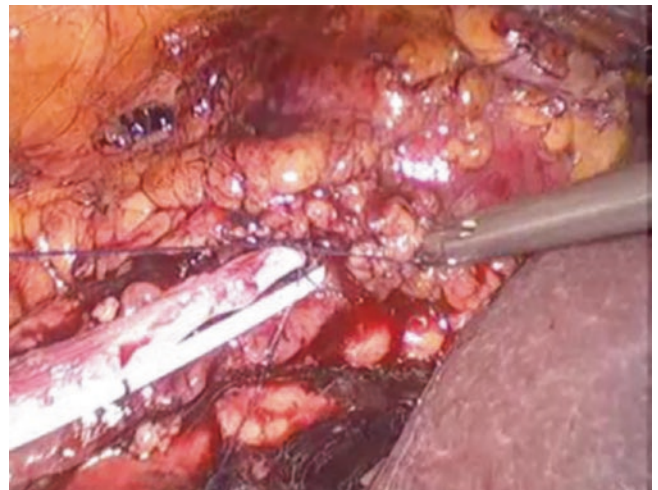


Fig. 16.60 Proximal end of graft sutured to cranial end of ureterotomy

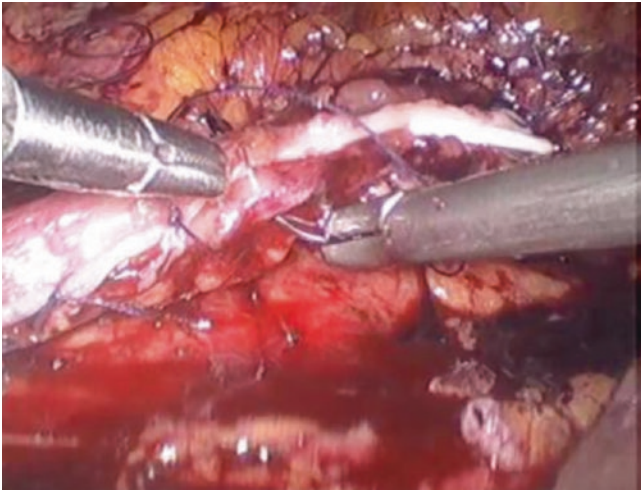


Fig. 16.61 Posterior layer of interrupted suturing in progress

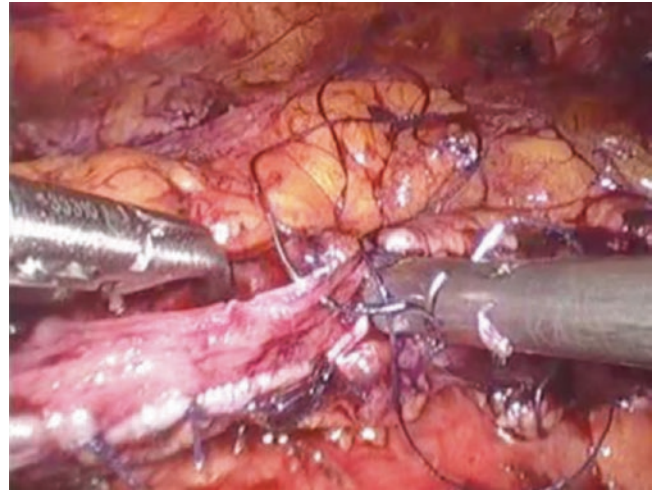


Fig. 16.62 Anterior layer interrupted suturing in progress

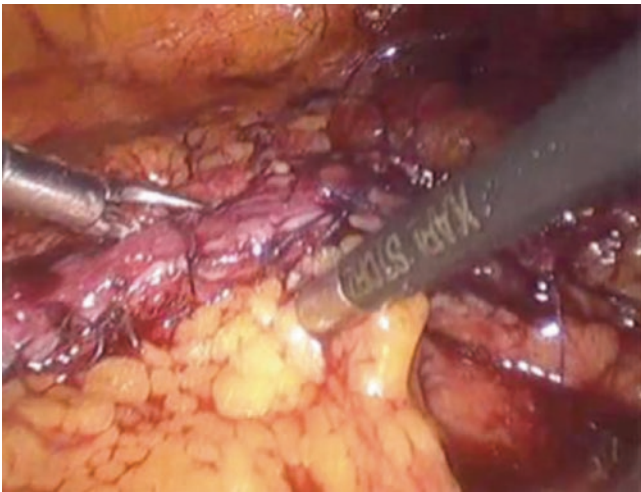


Fig. 16.63 Omental wrapping over the graft

16.7.5 Laparoscopic Trans Uretero Ureterostomy

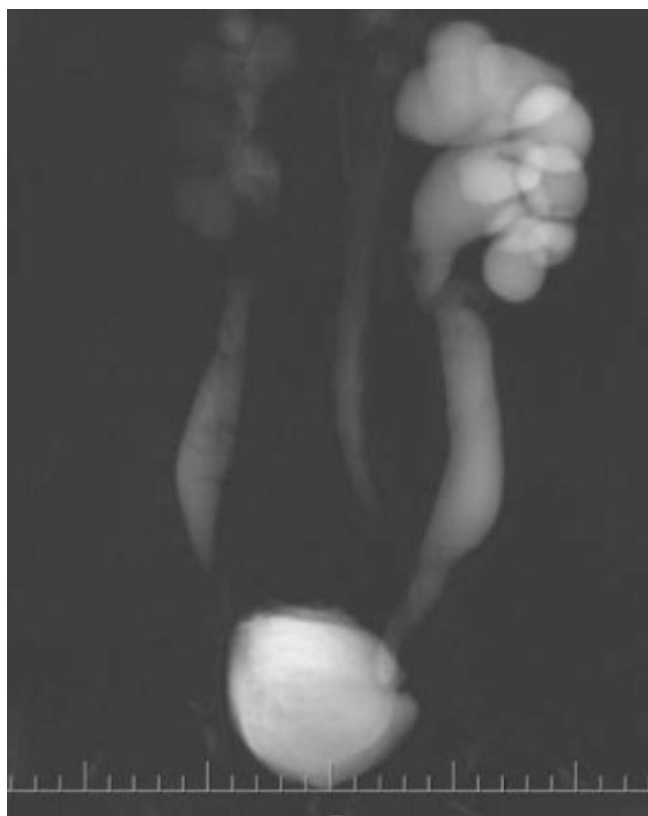

Fig. 16.64 MRI showing obstructed left ureter

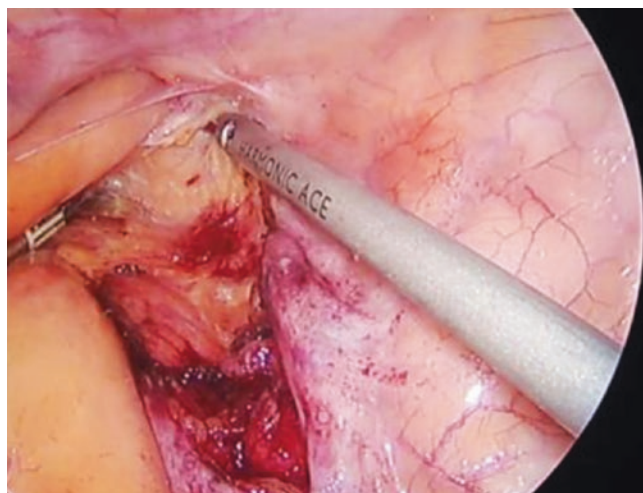


Fig. 16.65 Peritoneum being incised for native -right ureter dissection

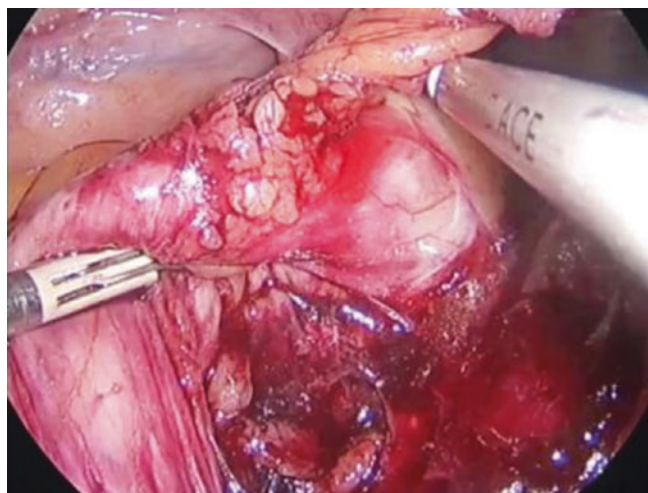


Fig. 16.66 Native right ureter being dissected

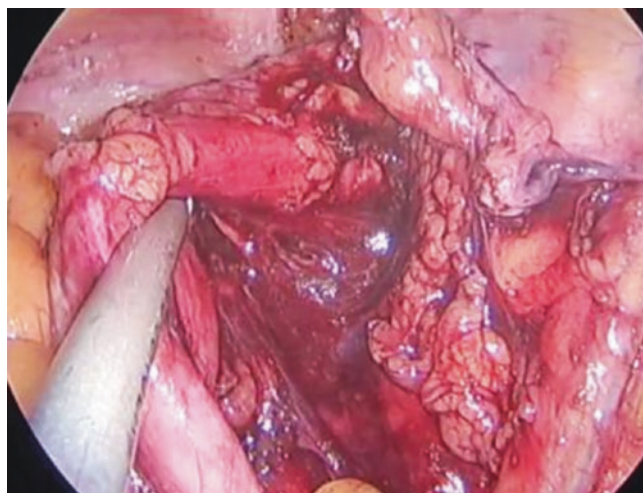


Fig. 16.67 Left ureter dissection in progress

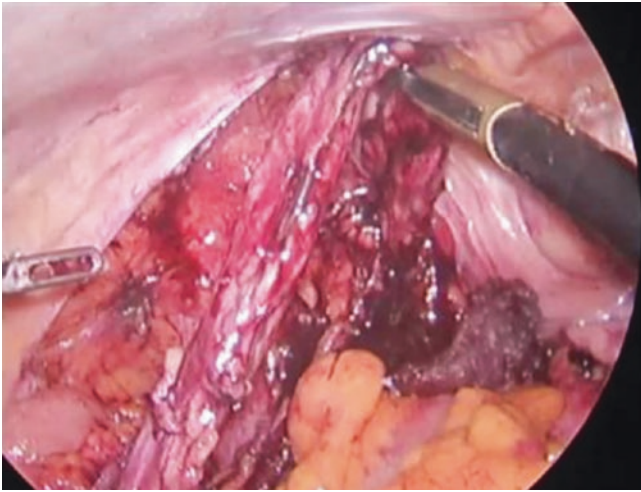


Fig. 16.68 Left ureter completely dissected from bladder (Distal extent) to above the pelvic brim (proximal extent)

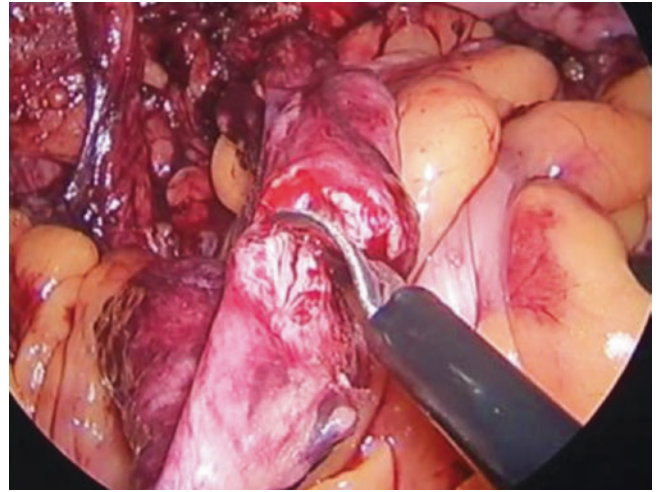


Fig. 16.69 Left ureter divided at about 6 cm from lower end

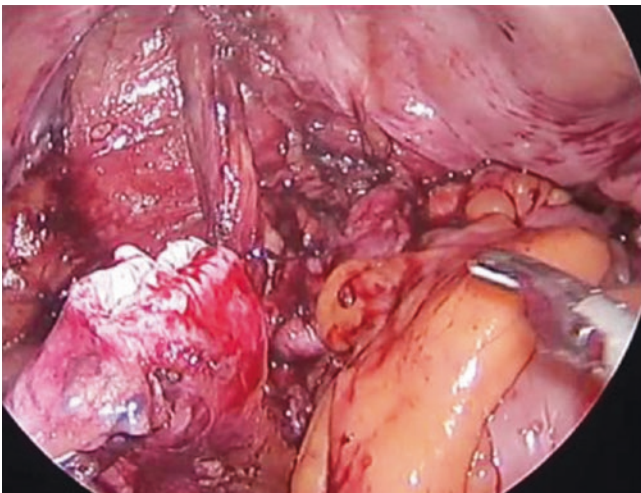


Fig. 16.70 Left ureter divided

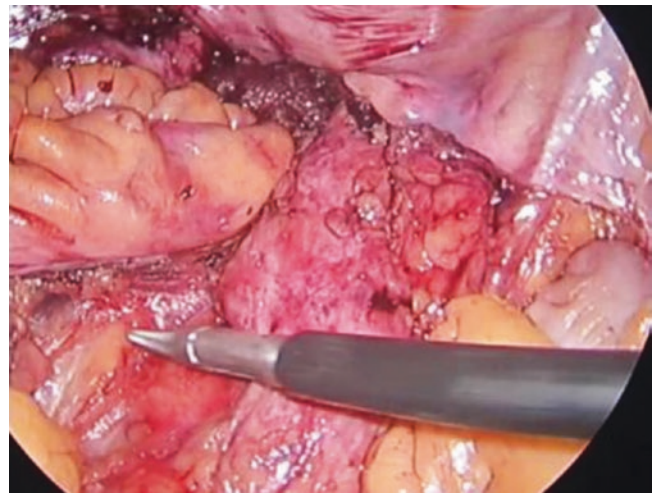


Fig. 16.71 Tunnel being developed beneath sigmoid mesocolon

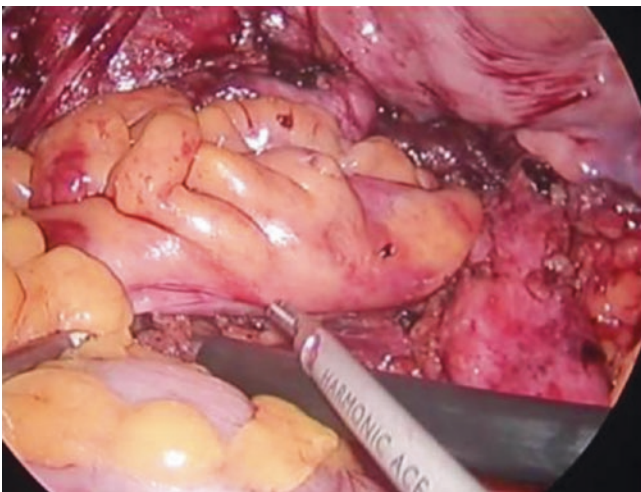


Fig. 16.72 Instrument being passed through tunnel from right to left

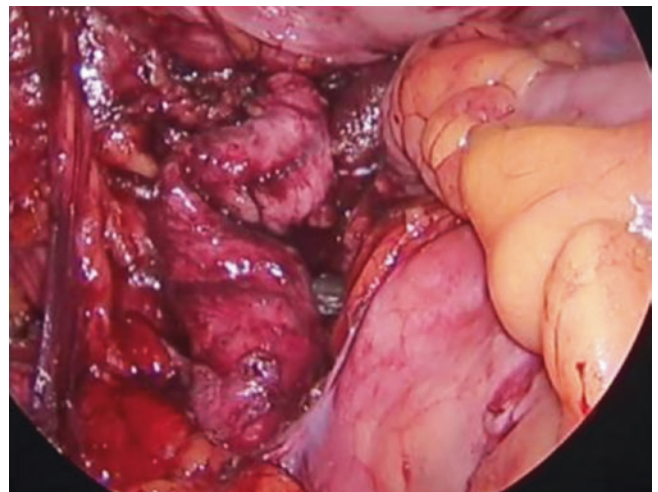


Fig. 16.73 Instrument passed to left from right side beneath the sigmoid mesocolon

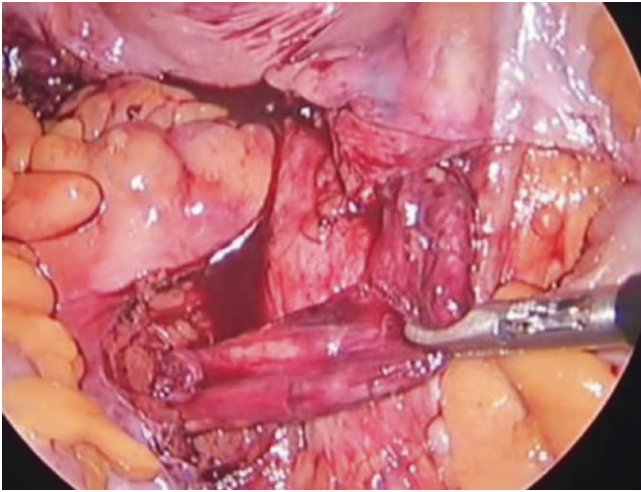


Fig. 16.74 Left ureter moved to the right through the tunnel

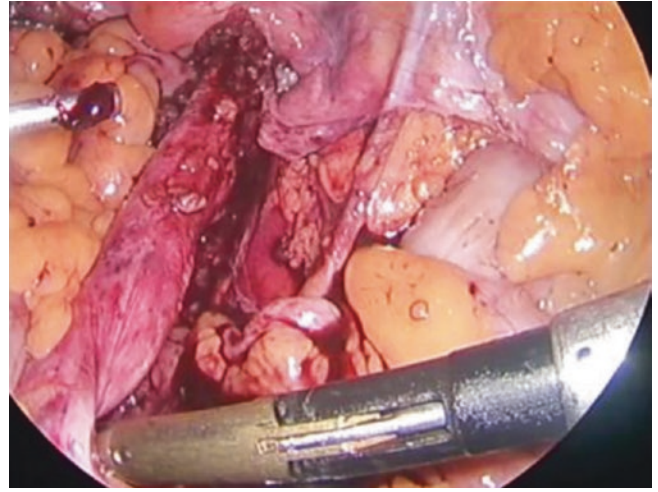


Fig. 16.75 Right ureter dissected fully

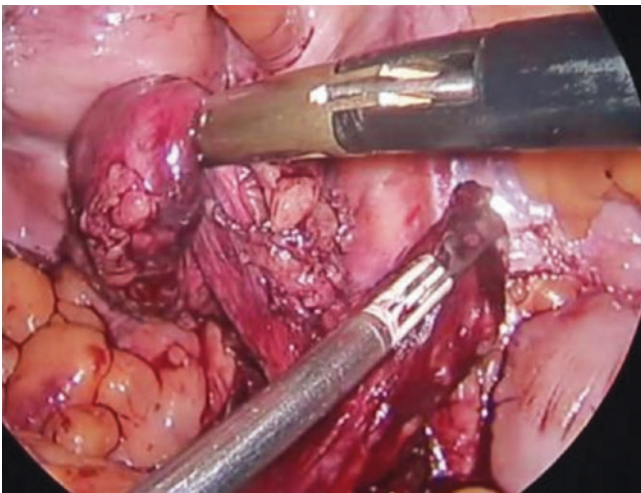


Fig. 16.76 Probability of tension free anastomosis assessed

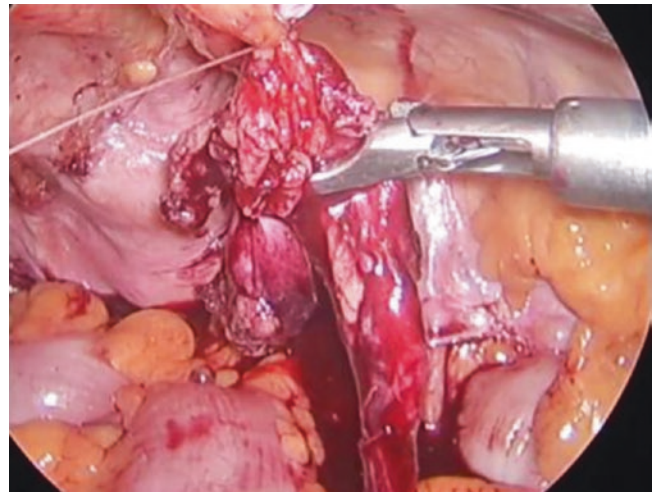


Fig. 16.77 Right ureter temporarily tacked to abdominal wall to facilitate anastomosis

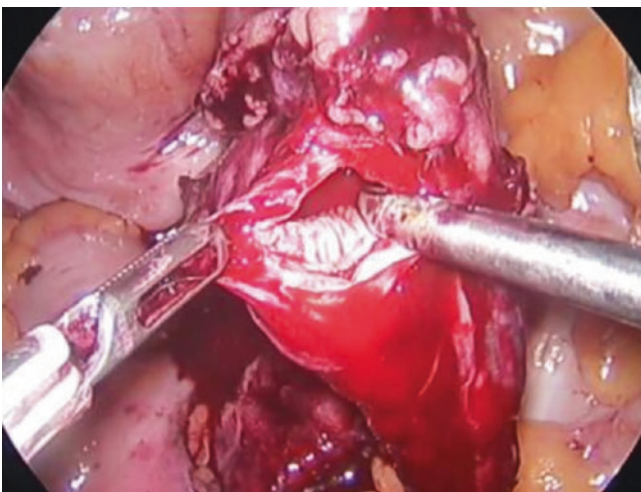


Fig. 16.78 vertical ureterotomy of right ureter

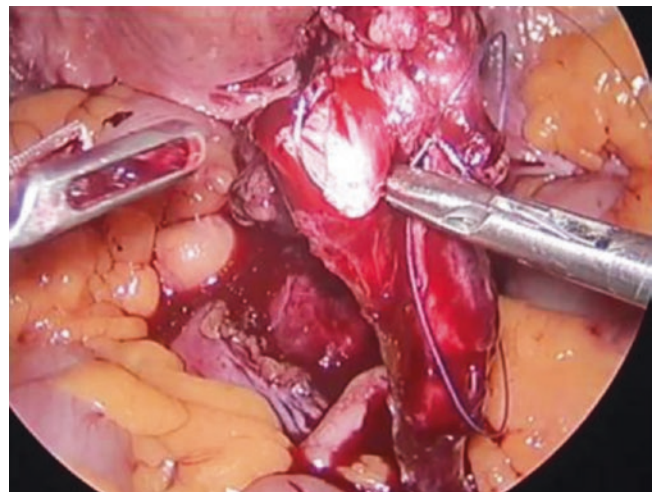


Fig. 16.79 Initial suture with 4-0 vicryl through the apex of ureterotomy of right ureter

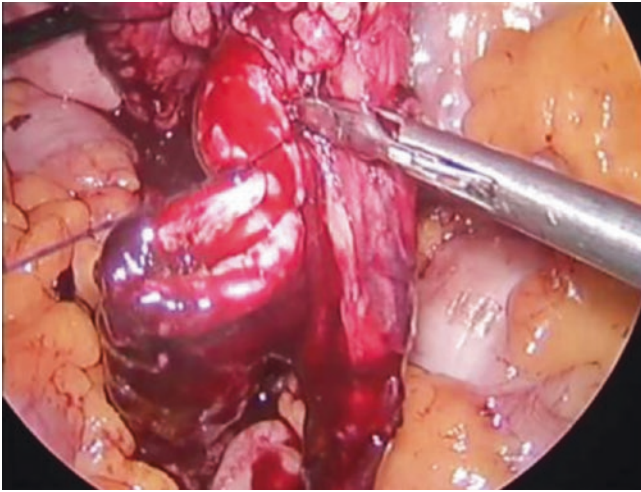


Fig. 16.80 Corresponding suture of cut end of left ureter

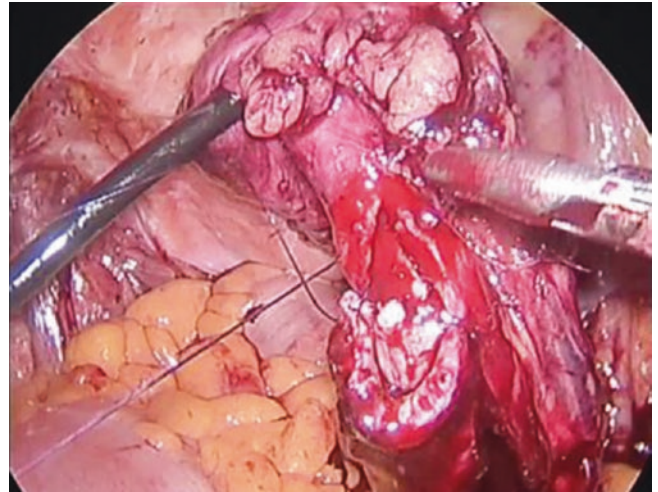


Fig. 16.81 Interrupted suturing of posterior layer in progress

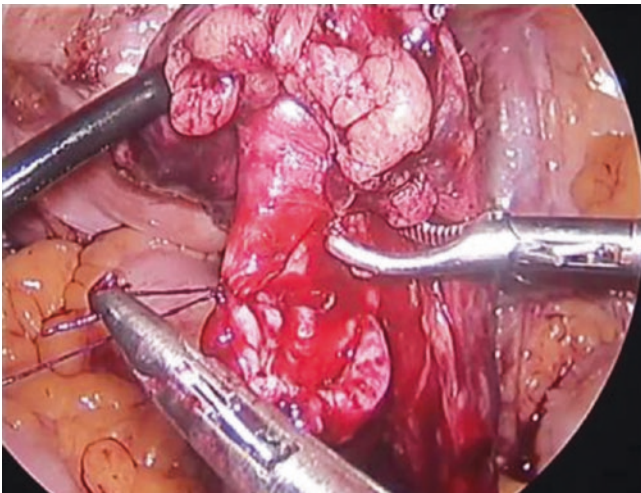


Fig. 16.82 Posterior layer completed

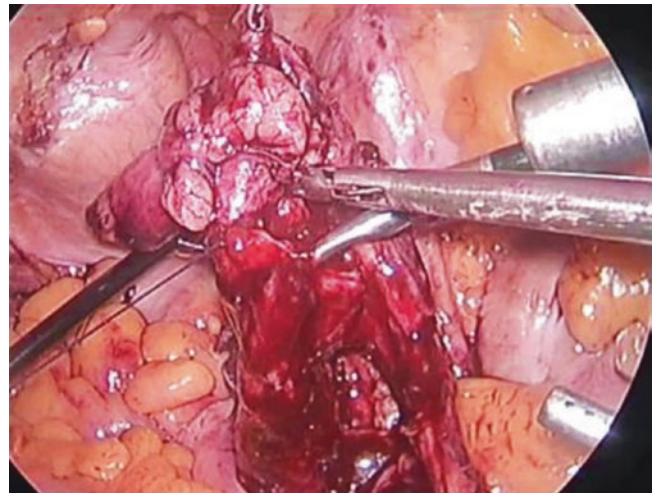


Fig. 16.83 Distal apical suture in place

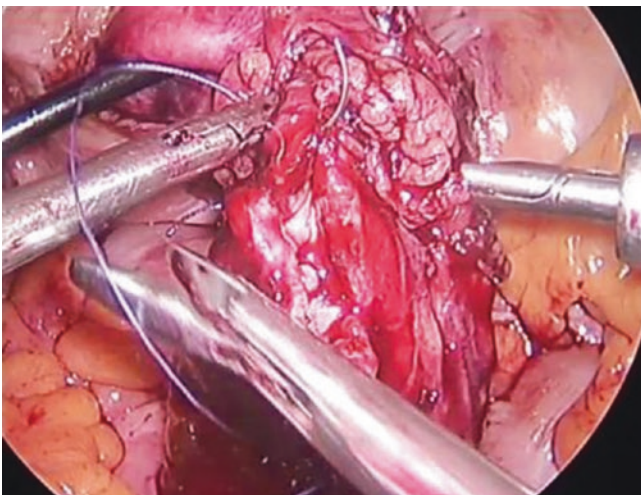


Fig. 16.84 Anterior layer suturing started

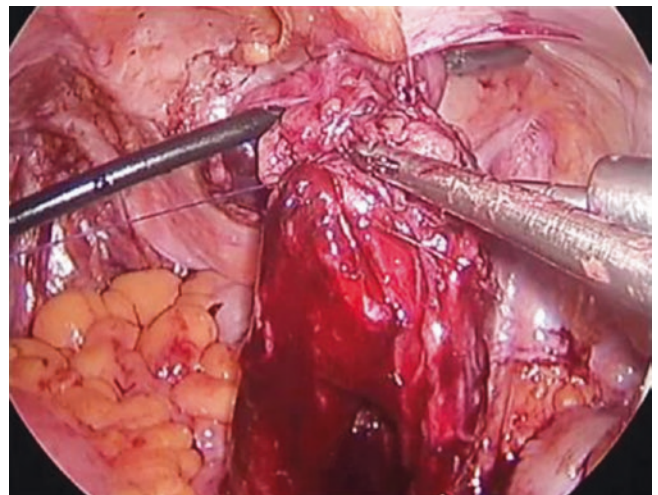


Fig. 16.85 Anterior layer first suture in place

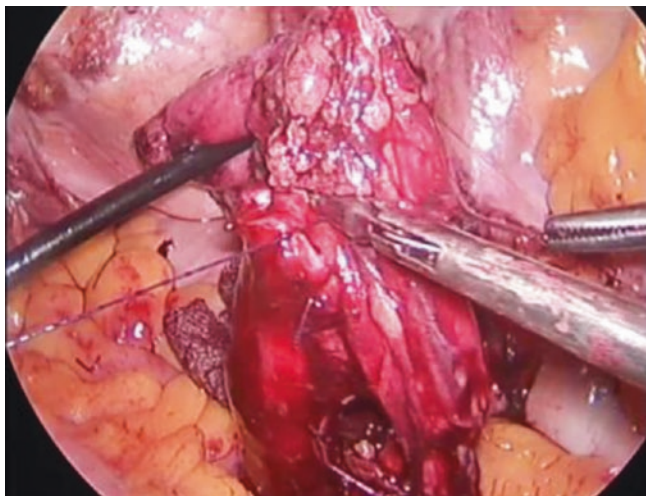


Fig. 16.86 Anterior layer suturing in progress

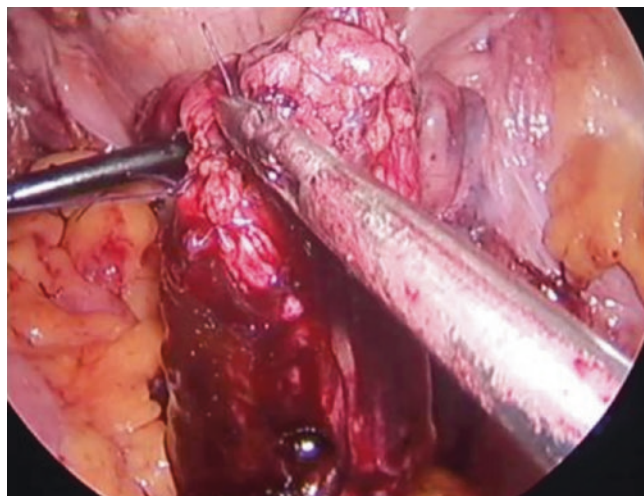


Fig. 16.87 Final suture in place

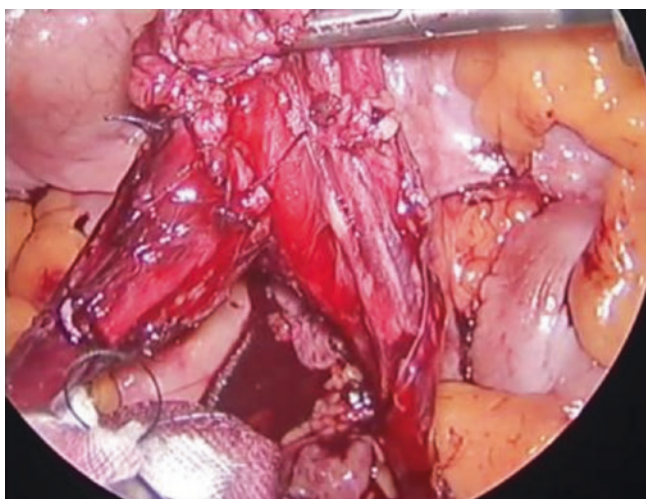


Fig. 16.88 Completed transureteroureterostomy anastomosis

References

1. Baba S, Oya M, Miyahara M, Deguchi N, Tazaki H. Laparoscopic correction of circumcaval ureter. *Urology*. 1994;44:122–6.
2. Gupta NP, Hemal AK, Singh I, Khaitan A. Retroperitoneoscopic ureterolysis and reconstruction of retrocaval ureter. *J Endourol*. 2001;15:291–3.
3. Hemal AK, Talwar M, Wadhwa SN, Gupta NP. Retroperitoneoscopic nephrectomy for benign disease of the kidney: postoperative nonrandomized comparison with open surgical nephrectomy. *J Endourol*. 1999;13:425–31.
4. Ishitoya S, Okubo K, Arai Y. Laparoscopic ureterolysis for retrocaval ureter. *Br J Urol*. 1996;77:155–68.
5. Matsuda T, Yasumota R, Tsujino T. Laparoscopic treatment of a retrocaval ureter. *Eur Urol*. 1996;29:115.
6. Polascik JT, Chen NR. Laparoscopic ureteroureterostomy for retrocaval ureter. *J Urol*. 1998;160:121–2.
7. Ramalingam M, Selvarajan K. Laparoscopic transperitoneal repair of retrocaval ureter: report of two cases. *J Endourol*. 2003;17:85–7.
8. Salomon L, Hoznek A, Balian C, Gasman D, Chopin DK, Abbou CC. Retroperitoneal laparoscope of a retrocaval ureter. *BJU Int*. 1999;84:181–2.
9. Bhandarkar DS, Lalimalani JG, Shah VJ. Laparoscopic resection and ureteroureterostomy for congenital mid ureteral stricture. *J Endourol*. 2005;19(2):140–2.
10. Gill IS, Ponsky LE, Desai M, Kay R, Ross JH. Laparoscopic cross trigonal Cohen ureteroneocystostomy: novel technique. *J Urol*. 2001;166:1811–4.
11. Nezhat CH, Nezhat F, Seidman D, Nezhat C. Laparoscopic ureteroureterostomy: a prospective follow up of 9 patients. *Prim Care Updat Obstet Gynecol*. 1998;5:200.
12. Ramalingam M, Senthil K, Pai MG. Laparoscopic transureteroureterostomy with ileal conduit in postradiation vesicovaginal fistula. *J Gynecol Surg*. 2010;26(4):263–5.
13. Piaggio LA, González R. Laparoscopic transureteroureterostomy: a novel approach. *J Urol*. 2007;177(6):2311–4.
14. Chung BI, Hamawy KJ, Zinman LN, Libertino JA. The use of bowel for ureteral replacement for complex ureteral reconstruction: long term results. *J Urol*. 2006;175(1):179–83.
15. Duckett JW, Coplen D, Baskin LS. Buccal mucosal urethral replacement. *J Urol*. 1995;153:1660–3.
16. Naude JH. Buccal mucosal graft in the treatment of ureteric lesions. *BJU Int*. 1999;83:751–8.
17. Shah SA, Ranka P, Visnagara M, Dodia S, Jain R. Use of buccal mucosa as onlay graft technique for benign ureteric strictures. *Indian J Urol*. 2003;20:28–32.
18. Sadhu S, Pandit K, Roy MK, Bajoria SK. Buccal mucosa ureteroplasty for the treatment of complex ureteric injury. *Indian J Urol*. 2011;73(1):71–2.

Prakash Johnson

17.1 Introduction

Ureteroureterostomy is the treatment of choice for symptomatic retrocaval ureter. Initially open approach and now laparoscopic uretero ureterostomy is the preferred approach [5]. With the wider availability of robots, robot assisted approach is preferred if available; the primary reason being the ease of suturing [1, 2, 4].

17.2 Indications and Evaluation

The indications and evaluation for robot assisted approach are similar to the classical laparoscopic approach, as described in the previous chapter.

17.3 Technique

RGP and prior placement of stent is preferred by few surgeons. The advantage is easier identification of ureter. With the patient under general anesthesia, in lateral kidney position, procedure is performed. The port position for is similar to that of pyeloplasty. The camera port is placed in the mid clavicular line. Two of the robotic ports each are placed in the midclavicular line, 10 cm away from the camera port. The fourth arm port is placed in the right iliac fossa in the anterior axillary line. Dissection starts with the mobilisation of colon. IVC and ureter are identified. Ureter is traced

completely from the pelvis to the pelvic brim level. The part of the ureter posterior to the IVC is also dissected and completely freed from the IVC. Minimal mobilisation of the IVC may be necessary in some cases. After the complete mobilisation, ureter is divided either lateral or medial to the IVC. The retrocaval part of the ureter may be excised if atretic, or preserved. Ureter is transposed anterior to IVC. Both the ends of the ureter are spatulated and end to end anastomosis is done with 4-0 PDS or vicryl sutures. Either interrupted or continuous sutures can be used. Stent is necessary and if not placed at the start of the procedure, is inserted after completion of the posterior layer of sutures. Drain is placed and abdomen exited.

17.4 Discussion

Hemal (2008) initially reported robot assisted approach for retrocaval ureter management. Since then few reports are available on this approach. Easy suturing is the only advantage, if any, for this approach compared to pure laparoscopic approach [3].

17.5 Conclusion

Robot assisted approach is useful for ureteroureterostomy in retrocaval ureter, especially in cases with difficult intracorporeal suturing.

P. Johnson
Sunderland Royal Hospital, Sunderland, UK
e-mail: prakashjohnson@aol.com

17.6 Robot Assisted Ureteroureterostomy for Retrocaval Ureter

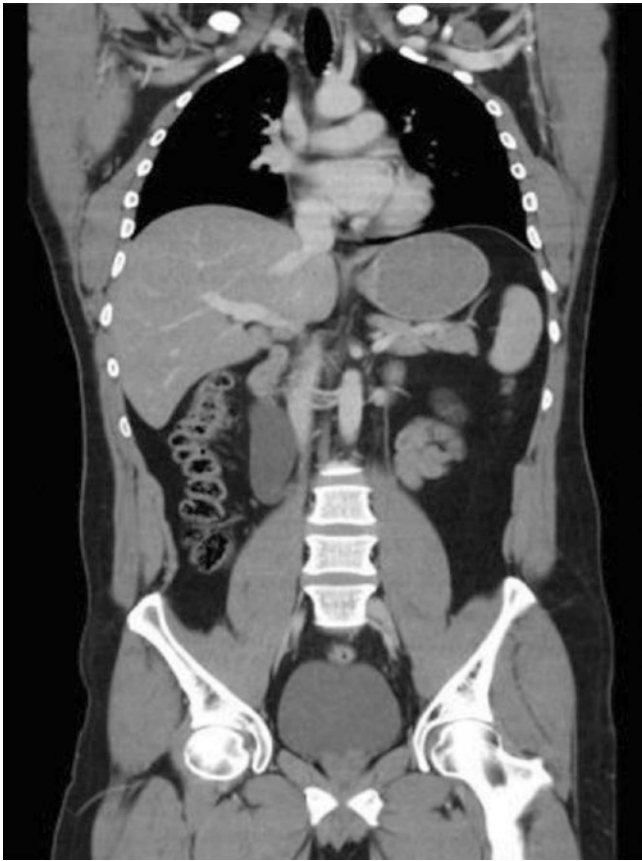

Fig. 17.1 CT scan showing hooking of IVC by ureter

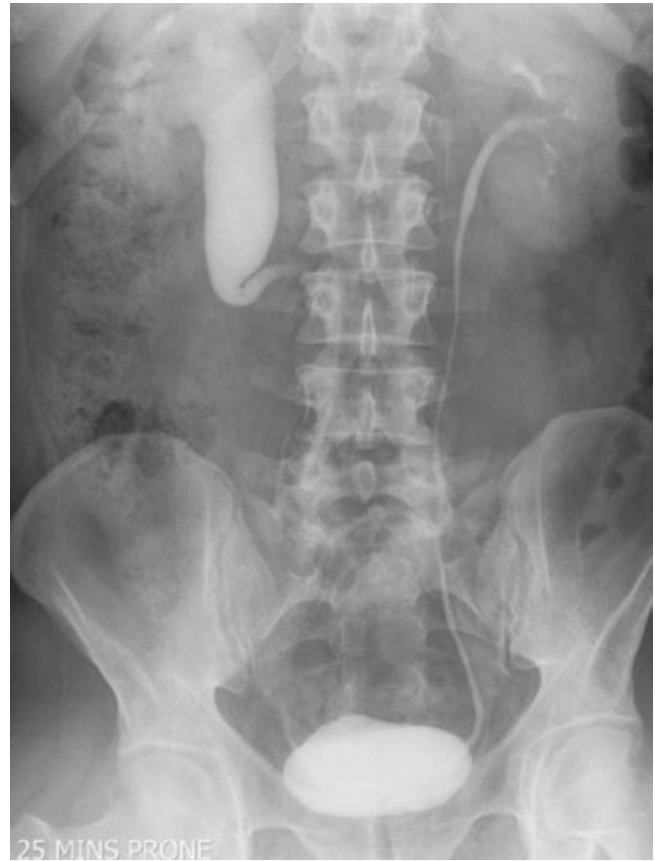

Fig. 17.2 IVU showing Sea horse sign of retrocaval ureter

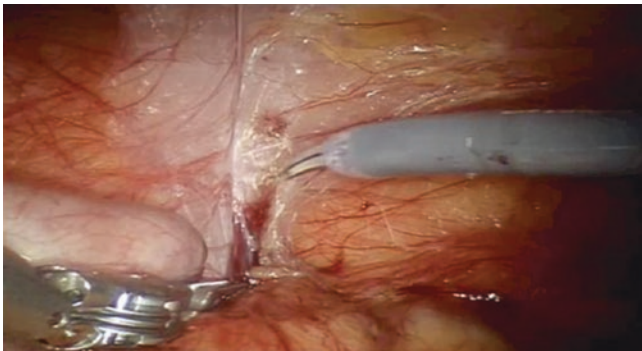


Fig. 17.3 Right colon being reflected medially

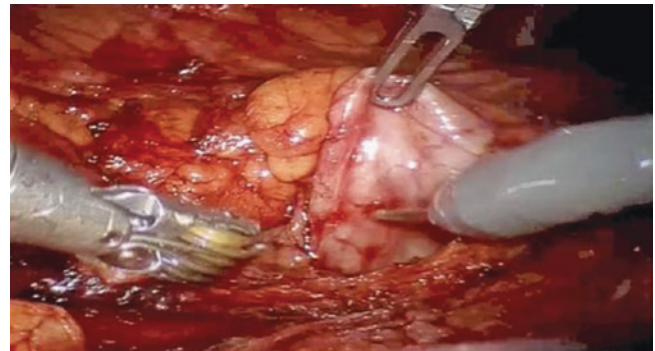


Fig. 17.4 Dilated upper part of ureter and pelvis seen

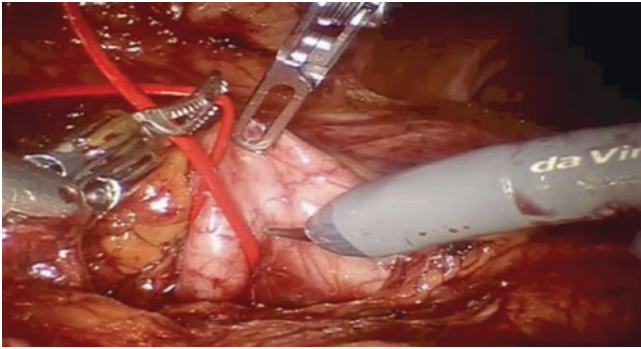


Fig. 17.5 Proximal segment of ureter looped

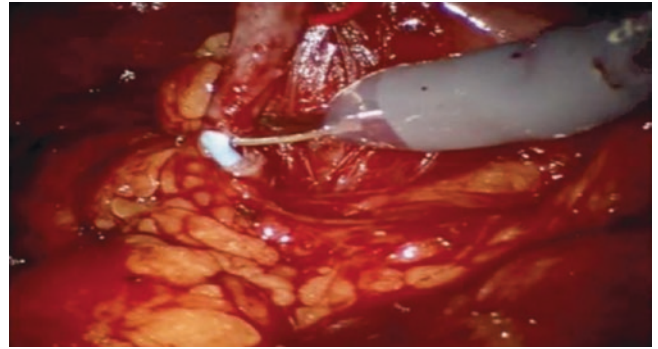


Fig. 17.6 Division of ureter just cranial to retrocaval segment. Preplaced stent seen

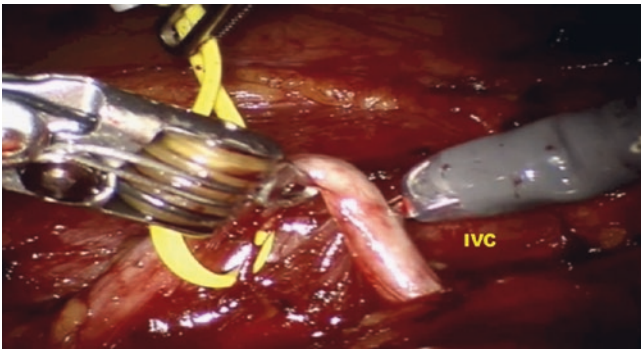


Fig. 17.7 Ureter below retrocaval segment looped with a differently coloured loop and dissected

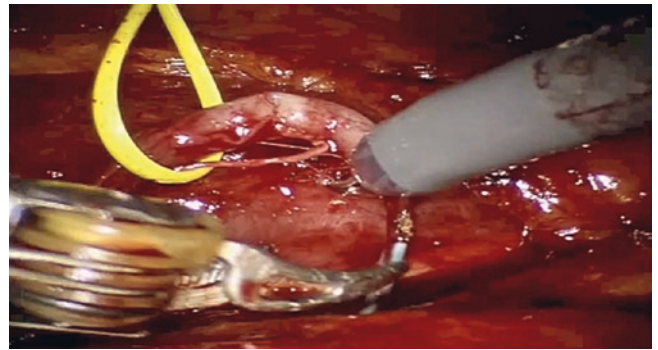


Fig. 17.8 Lower end of ureter divided

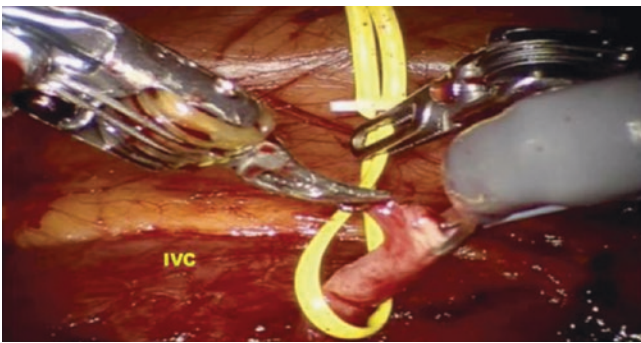


Fig. 17.9 Lower end being spatulated

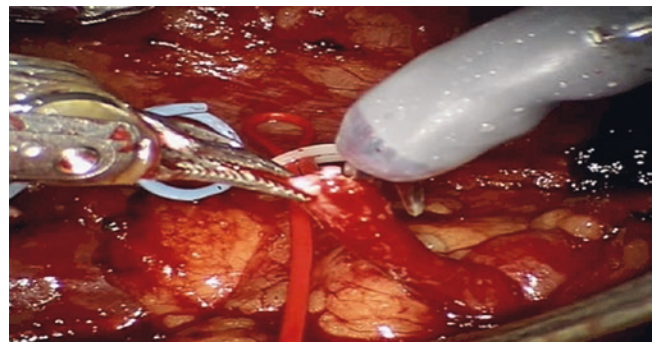


Fig. 17.10 Upper end being spatulated

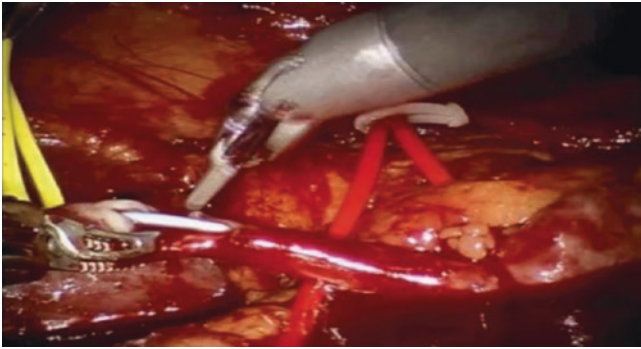


Fig. 17.11 Retrocaval segment transposed and proximal and distal ends of ureter approximated together

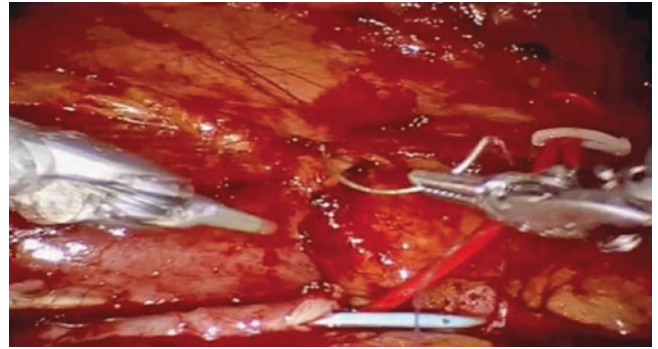


Fig. 17.12 Uretero ureterostomy started with 4-0 vicryl

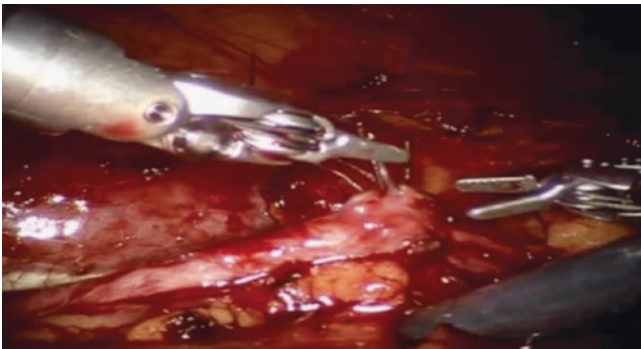


Fig. 17.13 Uretero ureterostomy with 4-0 vicryl suture in progress

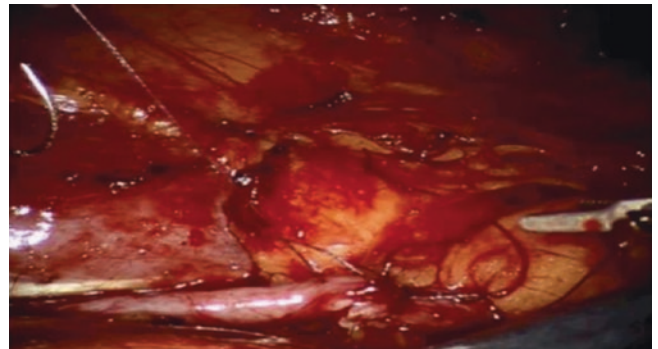


Fig. 17.14 Anastomosis completed

References

1. Hemal AK, Rao R, Sharma S, Clement RG. Pure robotic retrocaval ureter repair. *Int Braz J Urol.* 2008;34(6):734–8.
2. LeRoy TJ, Thiel DD, Igel TC. Robot-assisted laparoscopic reconstruction of retrocaval ureter: description and video of technique. *J Laparoendosc Adv Surg Tech A.* 2011;21(4):349–51.
3. Hemal AK, Nayyar R, Gupta NP, Dorairajan LN. Experience with robot assisted laparoscopic surgery for upper and lower benign and malignant ureteral pathologies. *Urology.* 2010;76(6):1387–93.
4. Smith KM, Shrivastava D, Ravish IR, Nerli RB, Shukla AR. Robot-assisted laparoscopic ureteroureterostomy for proximal ureteral obstructions in children. *J Pediatr Urol.* 2009;5(6):475–9.
5. Ramalingam M, Senthil K, Pai MG. Laparoscopic transureteroureterostomy with ileal conduit in postradiation vesicovaginal fistula. *J Gynecol Surg.* 2010;26(4):263–5.

Manickam Ramalingam, Kallappan Senthil,
K. Selvarajan, Shrenik Shah, Mohan K. Abraham,
and Anandan Murugesan

18.1 Introduction

Ureteric reimplantation in open surgery can be done extra-vesically or transvesically. Laparoscopic ureteric reimplantation by transvesical approach can be challenging because of the limited space and the risk of ports slipping out. It also involves considerable expertise in suturing. In extravesical reimplantation, suturing the bladder mucosa to the ureter and creating a submucosal tunnel, need dexterity [1–3].

18.2 Indications

- Congenital vesicoureteric reflux (VUR) that need surgical intervention.
- Primary obstructive mega ureter (POM)
- Ureterocele with back pressure changes.

M. Ramalingam (✉)
PSG Hospitals,
Coimbatore, India
e-mail: uroram@yahoo.com

K. Senthil
Urology clinic, Gowtham Annexe, Coimbatore, India
e-mail: senthilsatya@hotmail.com

K. Selvarajan, MCh
Paediatric Surgery, K.G. Hospital and Postgraduate Institute,
Coimbatore, India

S. Shah
Civil Hospital, Ahmedabad 380052, India
e-mail: urologysha@gmail.com

M.K. Abraham, MS, MCh, MBBS
Department Paediatric Surgery, School of Medicine,
Kochi, Kerala, India
e-mail: mohanabraham@aims.amrita.edu

A. Murugesan
Department of Urology, PSG Institute of Medical Sciences
and Research, Peelamedu, Coimbatore, Tamil Nadu, India
e-mail: anandan79@gmail.com

- Lower ureteric stricture.
- Lower ureteric injuries.
- Uretero Vaginal Fistula

The steps of ureteric reimplantation can be divided into

1. Dissection (and division) of ureter
2. Tailoring of ureter (Intra corporeal/Extracorporeal)
3. Preparation of bladder – Development of Retzius space and cystotomy (Developing submucosal plane)
4. Uretero vesical anastomosis

18.3 Surgical Techniques

Transvesical ureteric reimplantation - Cohen's Technique In VUR transvesical ureteric reimplantation is suitable if the ureter is not grossly dilated.

The difficulties encountered are:

- (a) Retaining trocars within bladder
- (b) Preventing gas leak after mobilising the ureter (as the hiatus will be open to extravesical space)
- (c) Suturing within the bladder.

Patient is placed in lithotomy position for a preliminary cystoscopy to assess the bladder neck and trigone, and to introduce a 5 Fr infant feeding tube into the ureter on the side to be reimplanted. The bladder is filled optimally for placement of camera port at the umbilical level. A 10 mm infra-umbilical midline incision is made and the linea alba is incised and a stay suture is taken through the dome of the bladder with 3–0 vicryl. This facilitates easy introduction of camera port under cystoscopic guidance, and prevents subsequent slippage of port. Now the cystoscope is removed and an optimum size foley catheter is introduced and clamped (to prevent gas leak). Insufflation of bladder is started, and the secondary ports are planned and inserted according to the

capacity of the bladder. The ports are fixed to the abdominal wall, to prevent slippage of trocars. A 5 Fr infant feeding tube of suitable length can also be dropped into the bladder through the 10 mm port, if not placed previously. The infant feeding tube is introduced into the ureter and transfixed with a 4-0 suture. Bladder mucosa over the ureteric orifice is circumcised with hook diathermy or cold scissors.

The ureter is held along with the stay suture with one of the hand instruments, and gentle traction is applied towards the opposite direction to facilitate mobilization using blunt and sharp dissection. The muscular or vascular attachments of the ureter are divided with hook diathermy. Optimum length of ureter is mobilised, depending on the caliber of the ureter. The mobilized ureter must be tension free. Subsequently submucosal tunnel is created by making a small button hole in the bladder mucosa cephalad to the opposite ureteric orifice. The ureteral end is trimmed and sutured to the bladder mucosa with 4-0 interrupted polyglactin suture.

Bilateral transvesical reimplantation may be a challenging procedure, as gas leaks at the hiatus. This results in perivesical emphysema leading to a collapsed bladder, which makes suturing difficult.

18.4 Transperitoneal Approach

Lich Gregoir's extravesical nontailored reimplantation (in moderately dilated ureter).

The patient is placed in a supine head low position with a sand bag below the ipsilateral hip. A preliminary cystoscopy is done to inspect the bladder interior and assess the capacity. Indwelling urethral catheter is placed with a provision for filling the bladder intraoperatively. The access to the catheter is kept sterile. Umbilical 10 mm port for the telescope and the two working ports are used; (one 5 mm port lateral to contralateral rectus and another 5 mm port in the anterior axillary line on the side of lesion, midway between the costal margin and iliac crest). In addition, a suprapubic 5 mm port is inserted for stabilizing the ureter and to help introducing the stent.

The lower ureter is adequately mobilized. This may be easier in megaureter but difficult in stricture due to inflammation and scarring. Colon may need to be reflected occasionally. The ureter is dissected adequately just above the pathological area and transected as distal as possible, taking care to retain some periadventitial tissue with the ureter. Bladder is minimally mobilized and detrusor muscle incised using hook scissors at the selected site of reimplantation.

Submucosal plane is developed to facilitate tunneling. Cystotomy done and a 5 Fr double pigtail stent is passed proximally into the ureter and distally into the bladder. Ureter is anastomosed to the bladder mucosa using 5-0 polyglactin interrupted sutures using the Lich Gregoir's extravesical reimplantation technique. The incised detrusor is buttressed over the ureter to form a submucosal tunnel using 3-0 interrupted sutures. The anterolateral wall of the bladder is sutured to the psoas muscle (Psoas hitch). Hitch is done as high as possible using absorbable sutures (1-0 polyglactin). Omental wrapping over the anastomotic site is preferable.

Lich Gregoir's extravesical tailored reimplantation (Grossly dilated ureter in primary obstructive megaureter).

Whenever the distal ureter of primary obstructive megaureter is grossly dilated and tortuous, it needs to be tailored. The redundant segment of ureter is excised and distal cut end is tailored (smoothly tapered) using continuous 3-0 or 4-0 vicryl depending upon the width of the ureteral wall. Rest of the technique of reimplantation is similar to what has been described already.

18.5 Nipple Valve Reimplantation

Nipple valve reimplantation is preferred in grossly dilated ureters with thick walled bladder. The nipple valve on its own acts as an anti reflux mechanism without tunneling. In the conditions mentioned above, creating tunnel as anti reflux mechanism would be difficult. Ureter is tailored as far as necessary. The distal end is incised and everted upon itself so that, only peristalsis of ureter opens the lumen. This is similar to the everting sutures taken while creating 'rose bud' conduit stoma.

18.6 Psoas Hitch

Whenever there is tension at the anastomotic area, it is advisable to suture the bladder wall just above the reimplanted area to the psoas with two or three interrupted 2-0 vicryl sutures to relieve the tension at the anastomotic site.

18.7 Comments

In transvesical approach slippage of the trocars results in quick perivesical emphysema making reintroduction of trocar extremely difficult.

18.8 Trans Vesicoscopic Cohen Reimplantation

18.8.1 Ureterocele

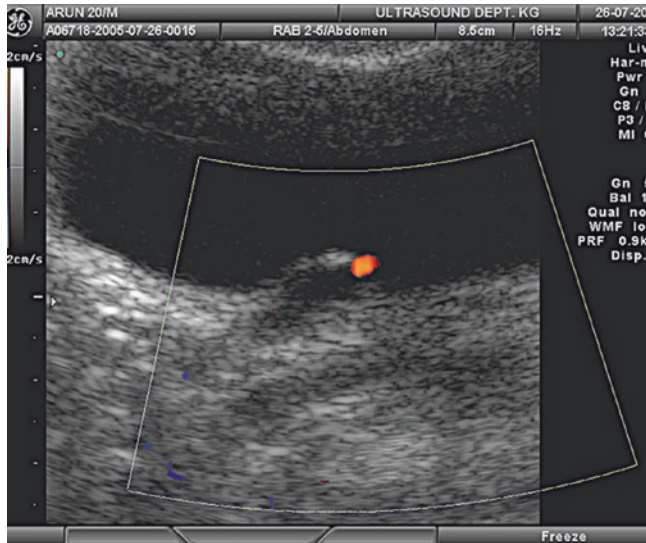


Fig. 18.1 Ultrasound scan showing right ureterocele. Ureteric jet shows the location of orifice

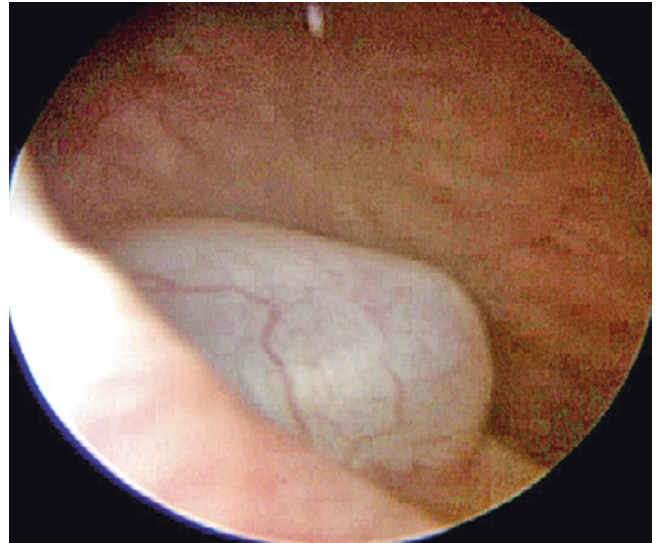


Fig. 18.2 Cystoscopic view of right ureterocele

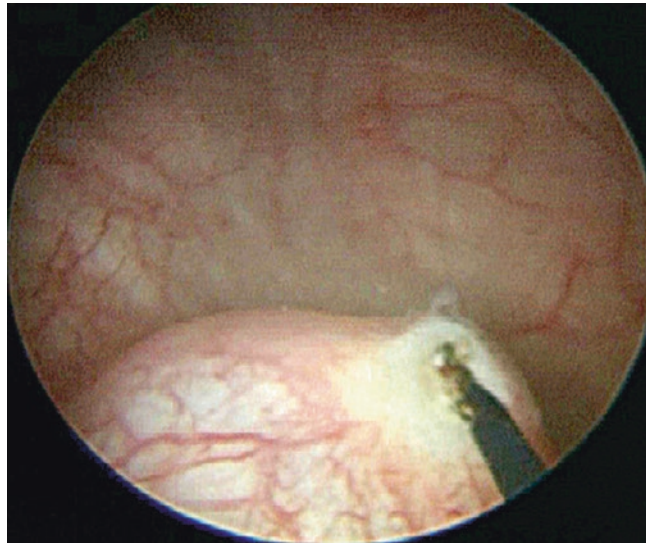


Fig. 18.3 Cystoscopic deroofing of ureterocele to advance ureteric stent

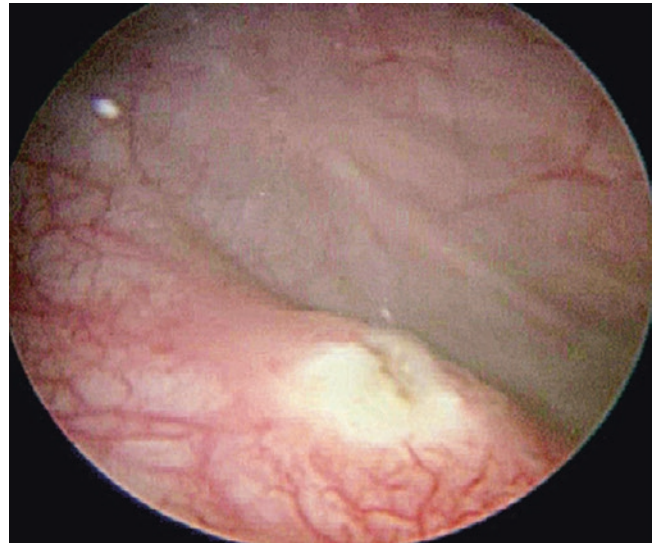


Fig. 18.4 View after deroofing ureterocele

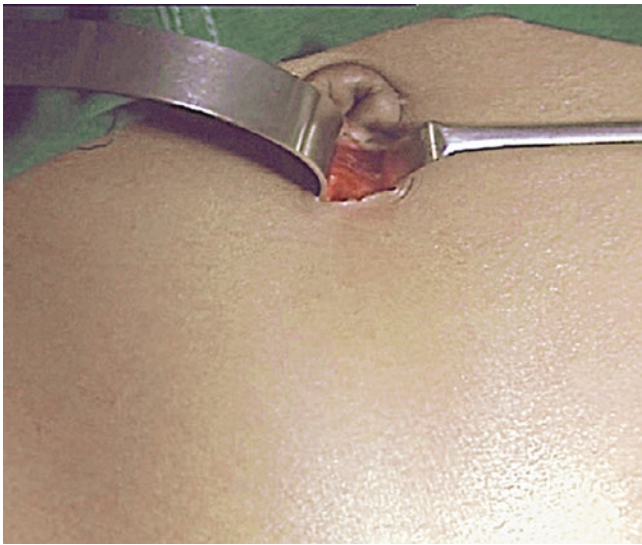

Fig. 18.5 Subumbilical camera port site

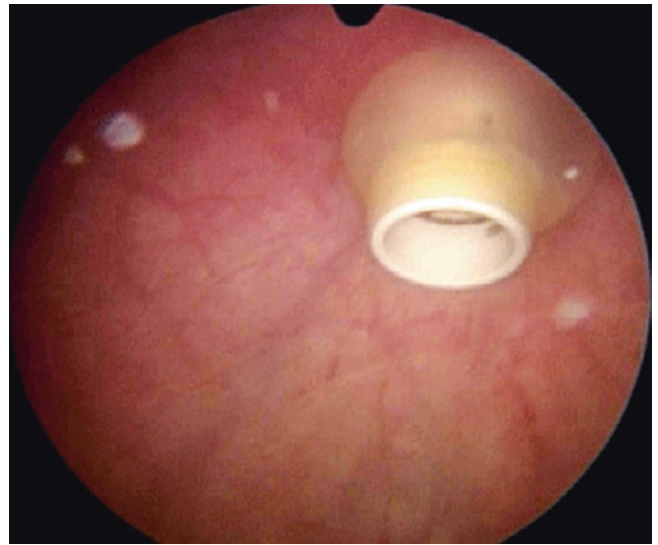


Fig. 18.6 Balloon trocar inserted as subumbilical camera port

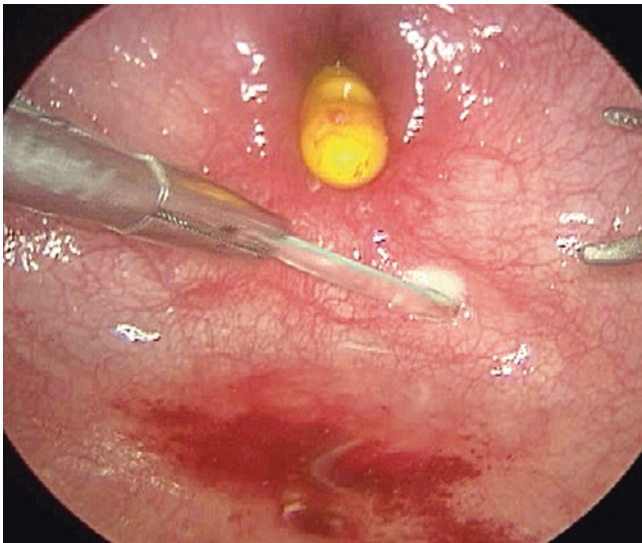


Fig. 18.7 Transvesical laparoscopic view after deroofing. Infant feeding tube is advanced into the ureter

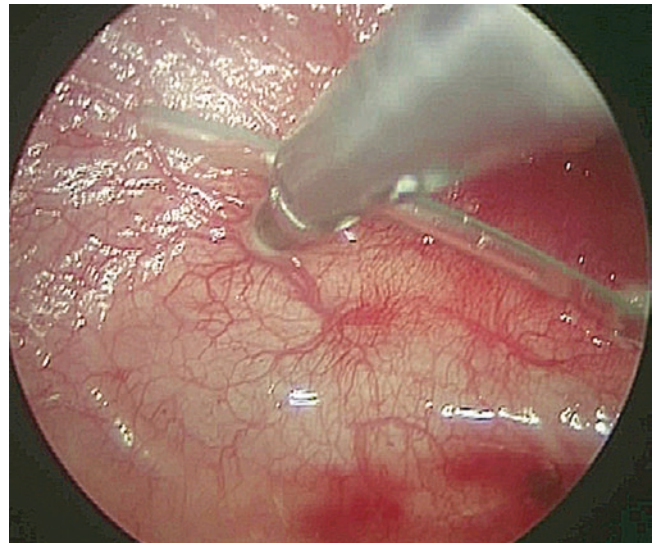


Fig. 18.8 Locating left ureteric orifice to plan direction of submucosal tunneling

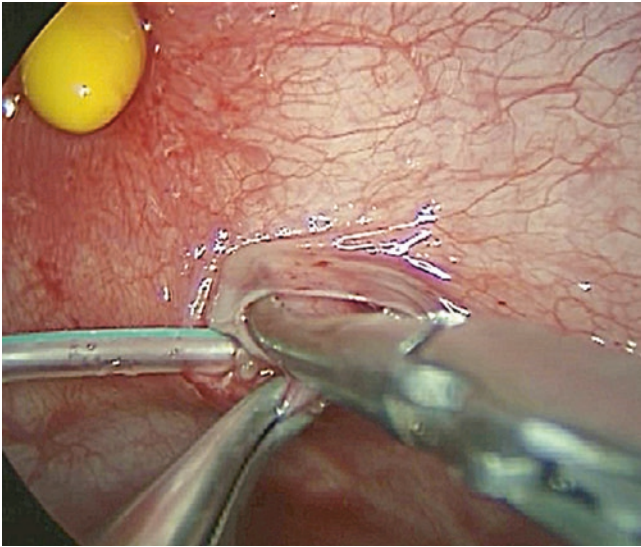


Fig. 18.9 Ureter is being carefully mobilised (after circumferential incision of bladder mucosa)

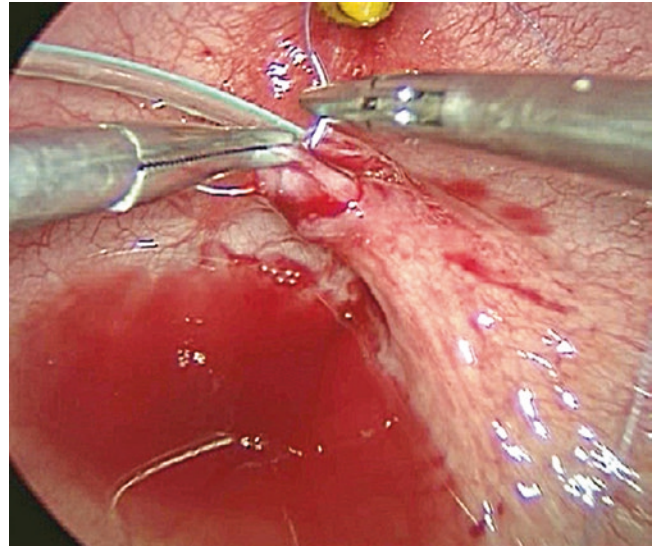


Fig. 18.10 Ureteric stent is being transfixed to Ureter

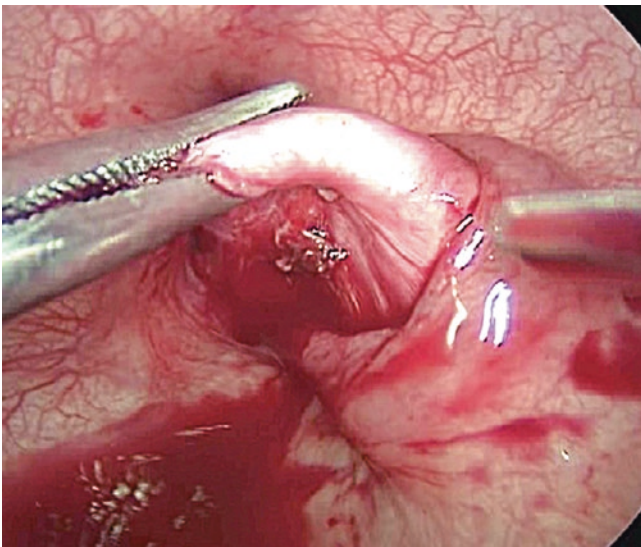


Fig. 18.11 Ureter is held with dissector and dissected all around

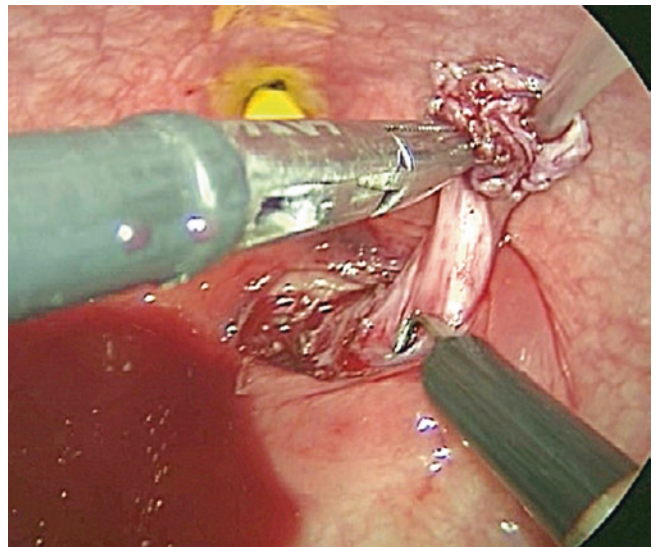


Fig. 18.12 All bladder muscle fibre attachments to the ureter are divided using hook dissector with electrocautery

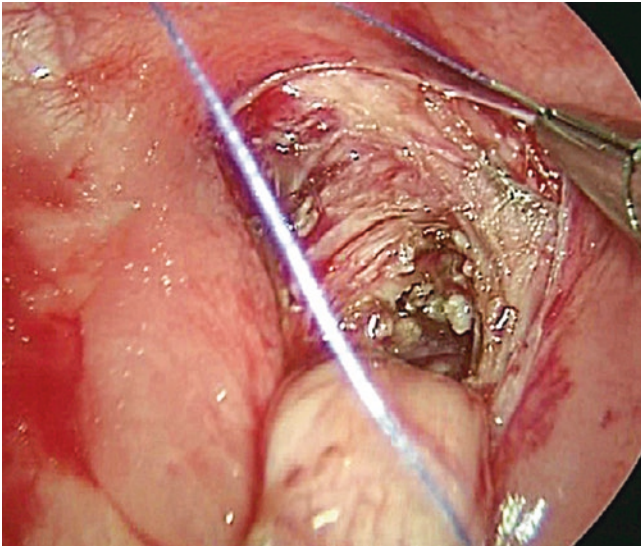


Fig. 18.13 Ureter is mobilised till perivesical fat is seen

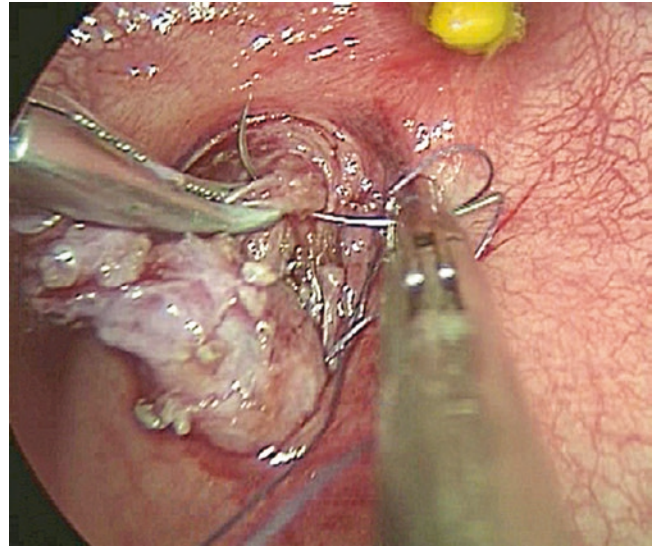


Fig. 18.14 Hiatus has to be narrowed using 2-0 vicryl suture to prevent air leak

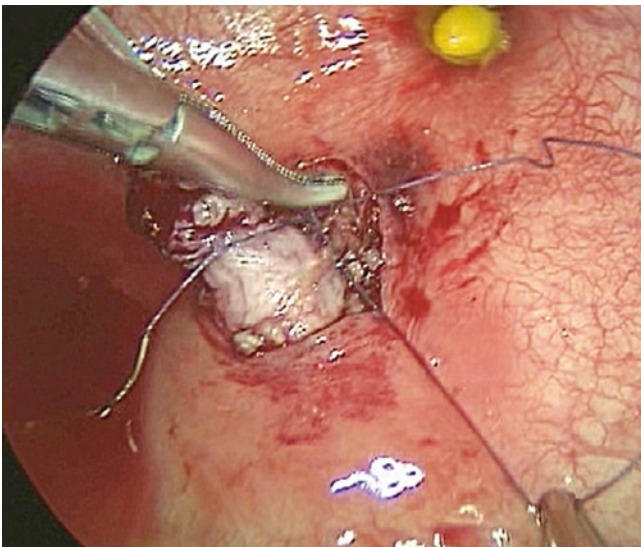


Fig. 18.15 Hiatus narrowed adequately

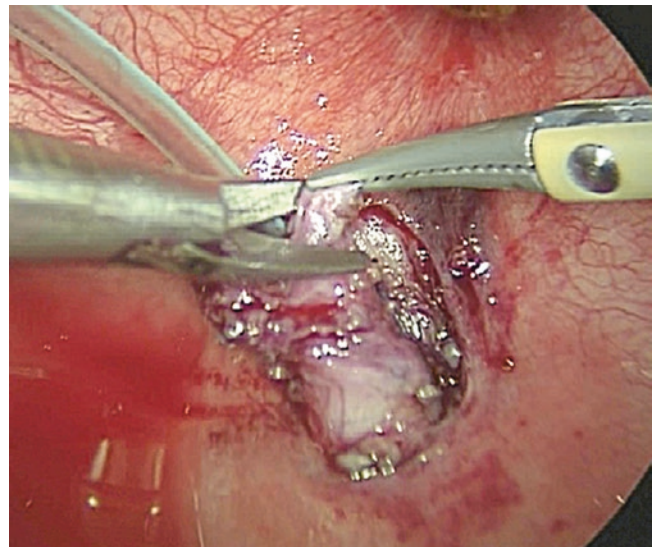


Fig. 18.16 Ureter margins being freshened is being excised with scissors

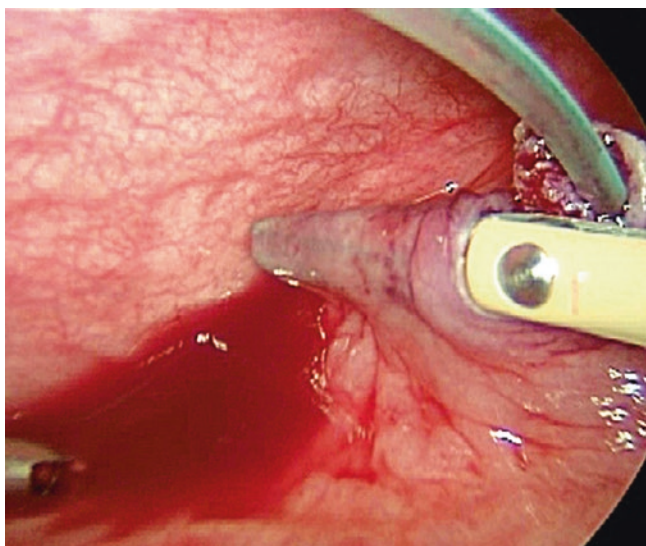


Fig. 18.17 Submucosal tunnel is being created with a dissector

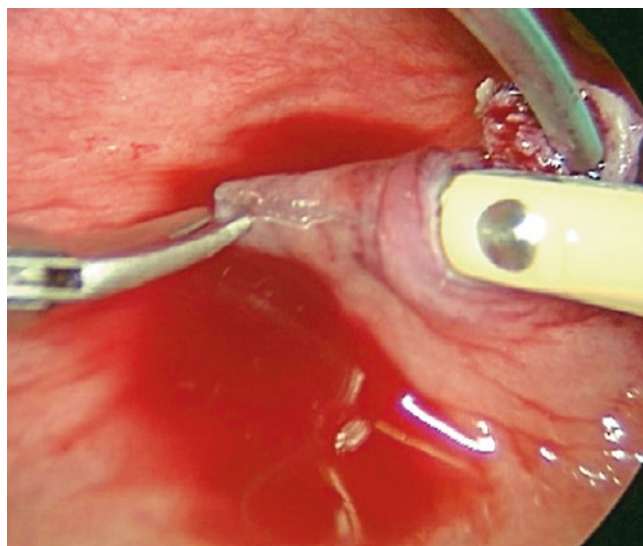


Fig. 18.18 Once adequate length of submucosal tunnel is achieved, sufficient bladder mucosal incision is made for neoureteric orifice

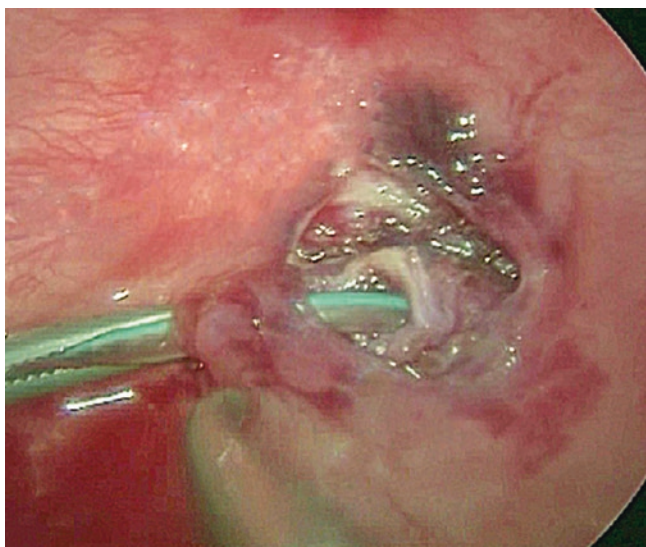


Fig. 18.19 The ureteric stent with ureter is grasped with a dissector and routed through the submucosal tunnel

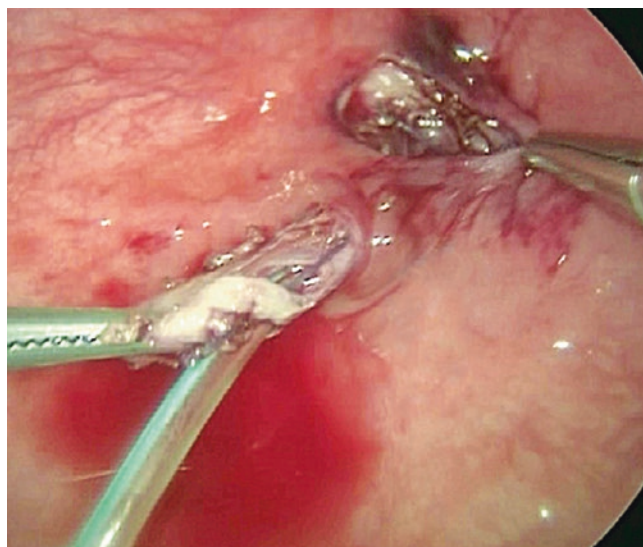


Fig. 18.20 Ureter is seen exiting through the new tunnel

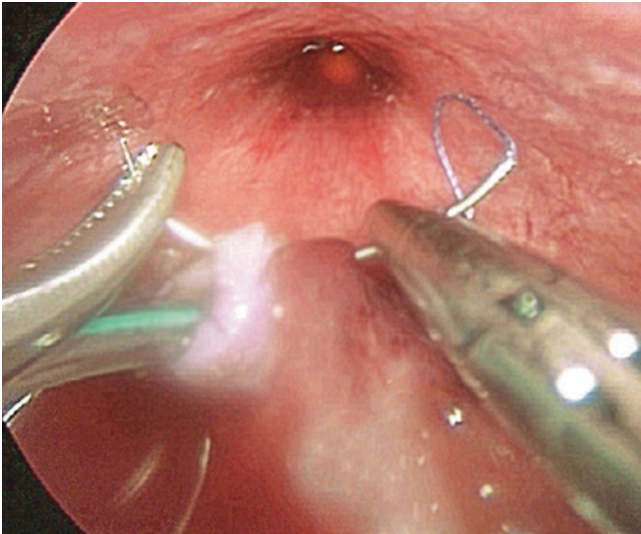


Fig. 18.21 Ureteric end is sutured to mucosal edge using interrupted 4-0 vicryl suture

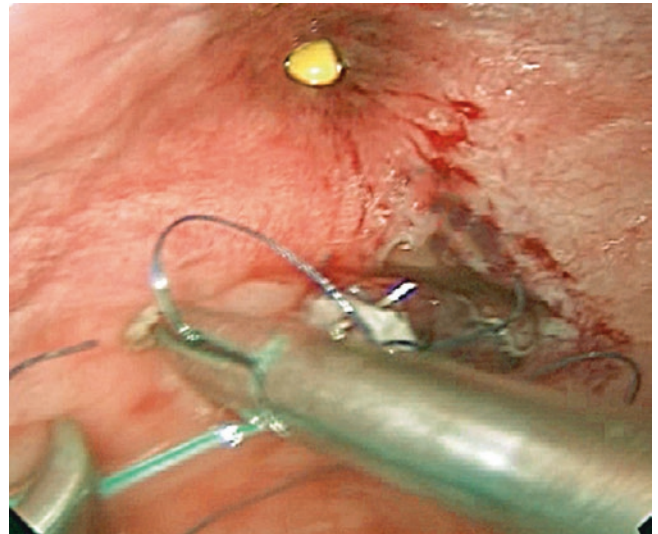


Fig. 18.22 Few more vicryl sutures are placed to fix the ureter

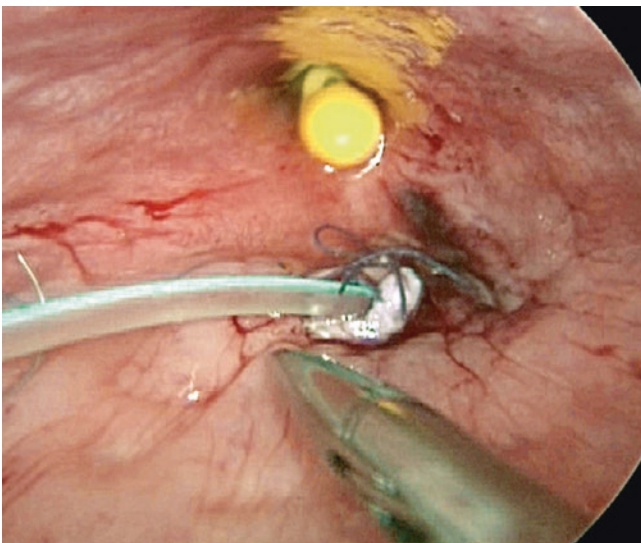


Fig. 18.23 View after reimplantation

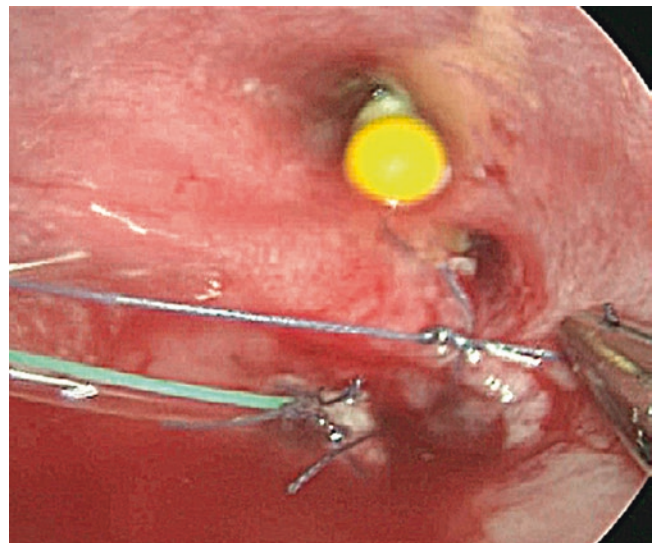


Fig. 18.24 Mucosal defect at hiatus is closed

18.8.1.1 Problems in Transvesical Laparoscopic Surgeries

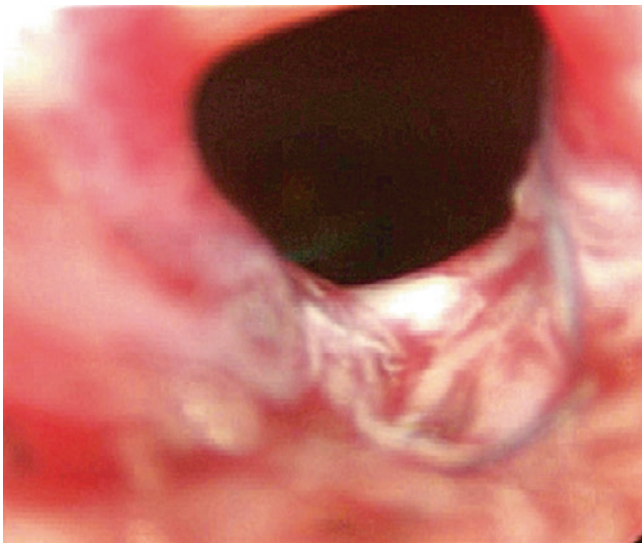


Fig. 18.25 Camera port slipped out of the bladder

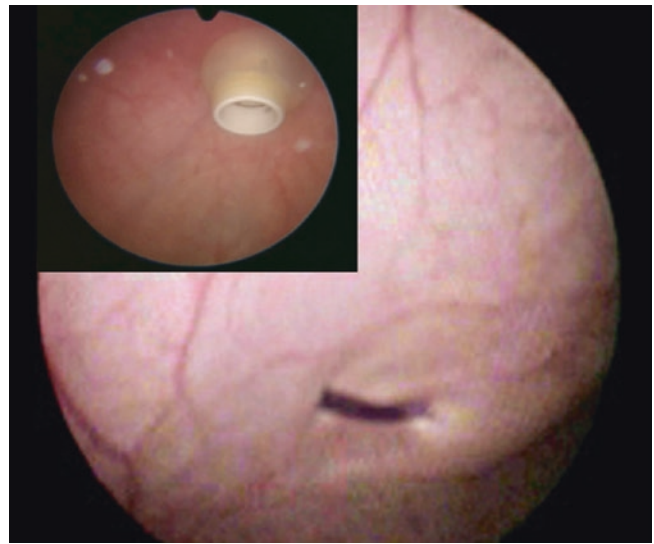


Fig. 18.26 This can be prevented by a stay suture taken through the dome of the bladder or by using a balloon tip trocar (as shown in the inset)

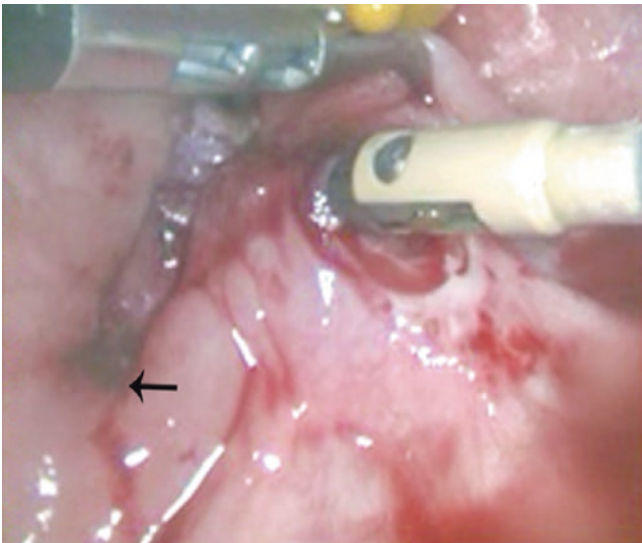


Fig. 18.27 When the dissector is not in a desired direction while creating a submucosal tunnel, rotulating dissector is helpful

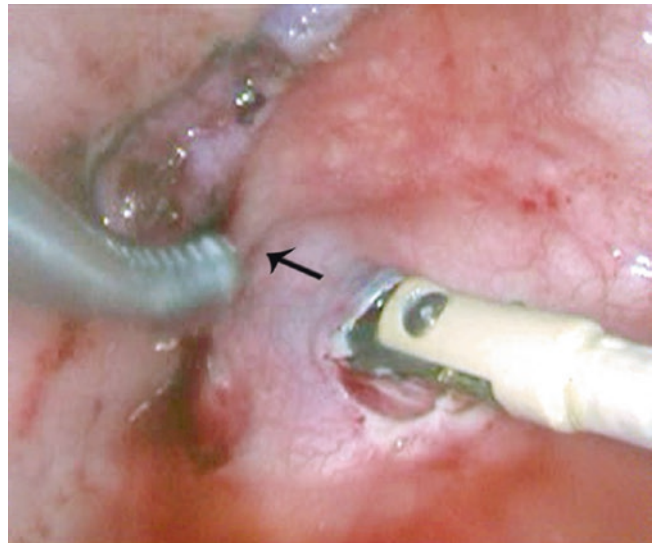


Fig. 18.28 When the dissector is not in a desired direction while creating a submucosal tunnel, rotulating dissector can be favourably rotated and tunnel can be made in the desired direction

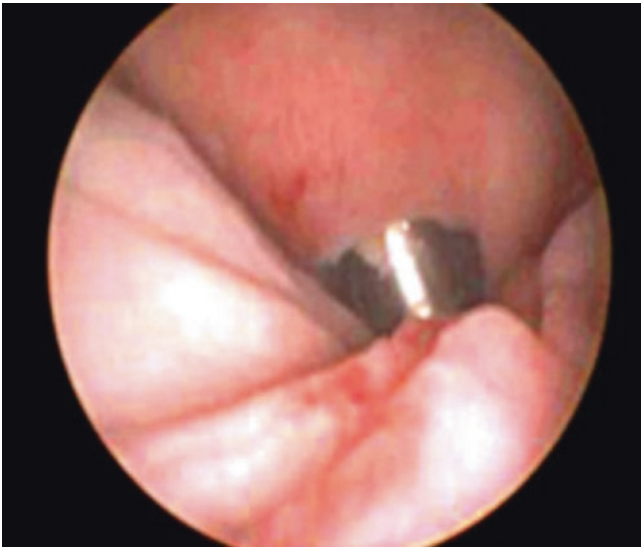

Fig. 18.29 Collapse of the bladder (due to escape of air) may result in slippage of trocar

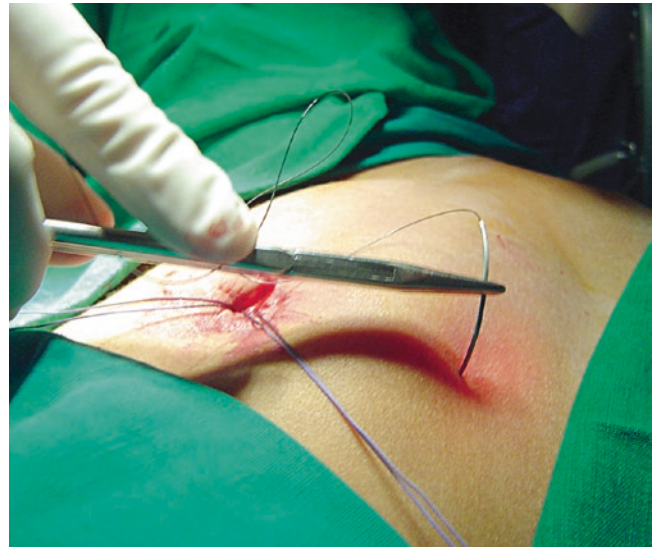

Fig. 18.30 Prevention of collapse of bladder with a stay (1 ethilon) taken through the dome and anterolateral wall of the bladder

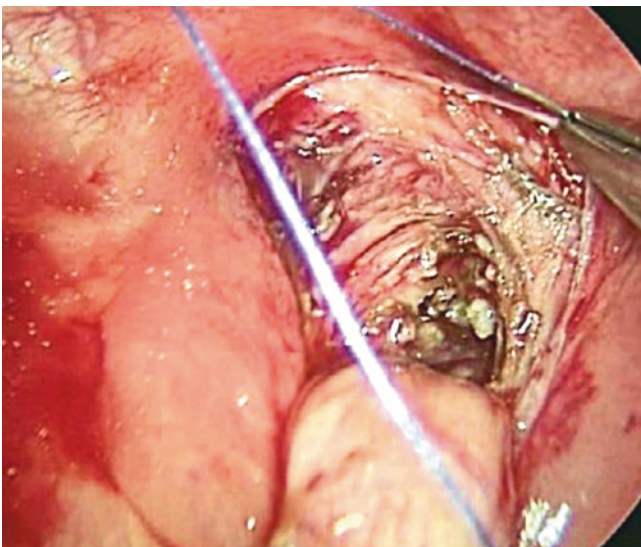


Fig. 18.31 Gas leak through hiatus (which can result in perivesical emphysema and collapsing of bladder)

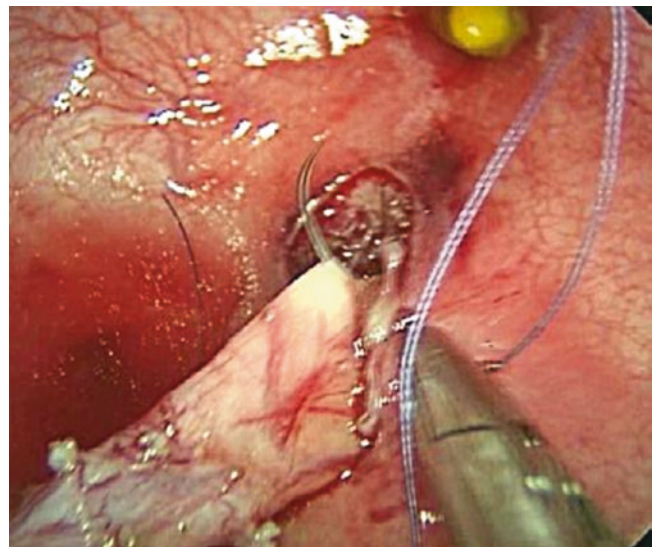


Fig. 18.32 Adequate closure of the hiatus prevents this leak

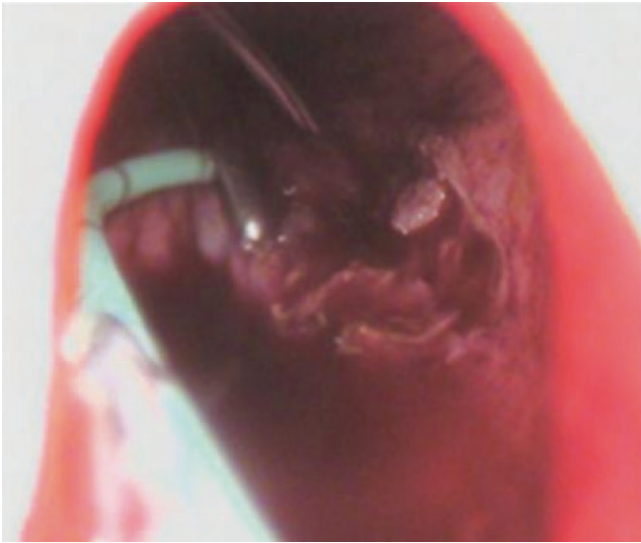


Fig. 18.33 Accumulation of blood stained urine preventing progress of surgery (as seen by Cystoscopy)

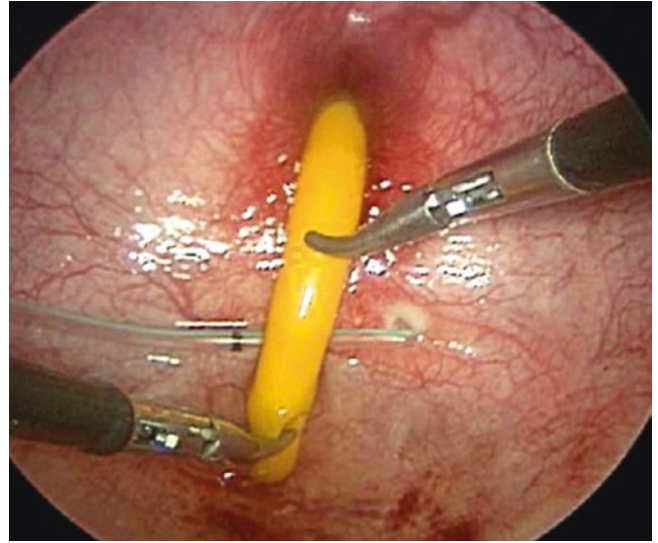


Fig. 18.34 Accumulated urine sucked out through foley catheter placed perurethrally

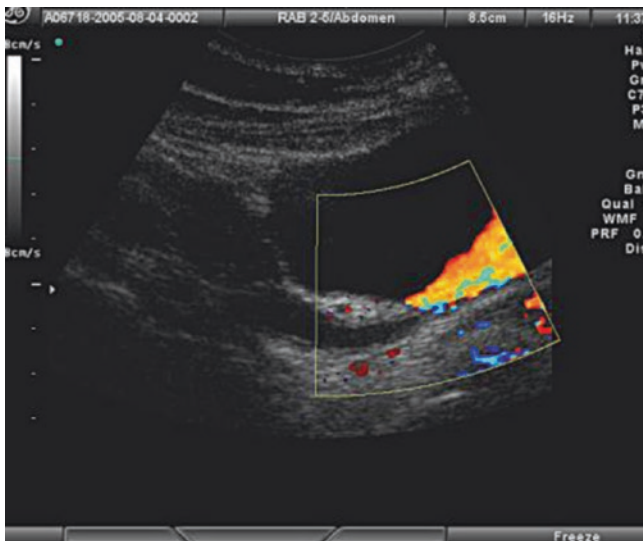


Fig. 18.35 Ultrasound scan done 3 months later shows good efflux from reimplanted ureter

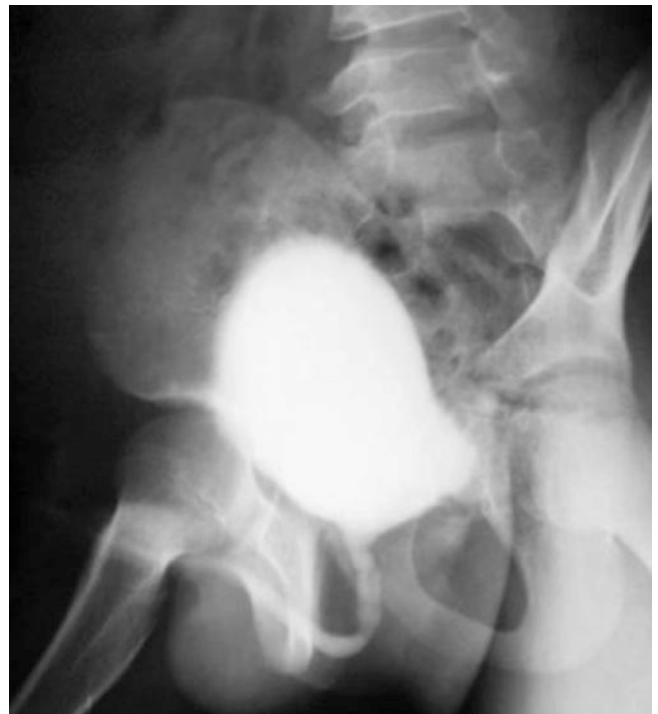

Fig. 18.36 Postoperative MCU done 3 months later shows no reflux

18.9 Transvesical Reimplantation in VUR

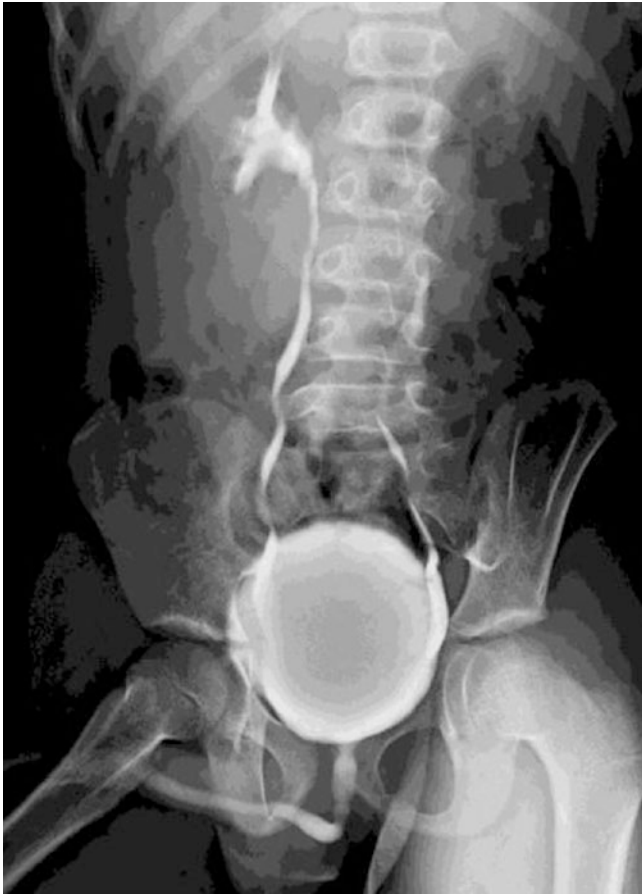

Fig. 18.37 Gross right VUR

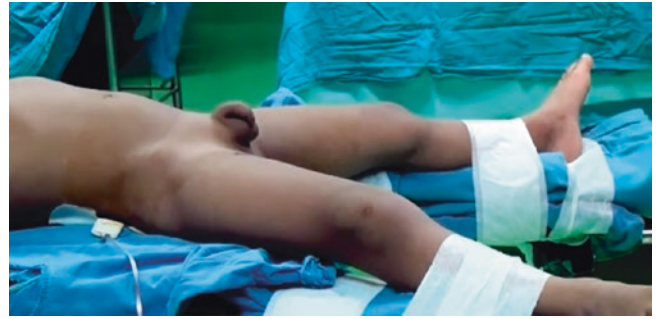

Fig. 18.38 Patient position for tranvesicoscopic ureteric reimplantation

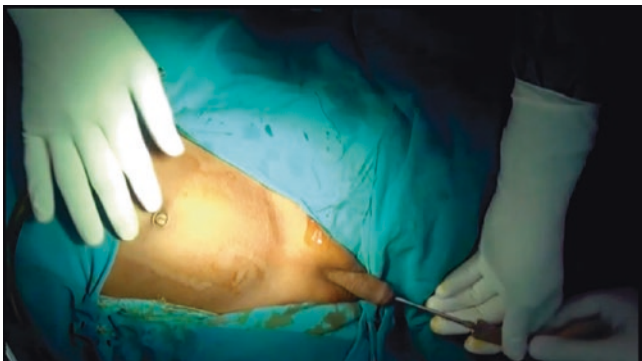


Fig. 18.39 Retrograde placement of urethral dilator to guide camera port placement

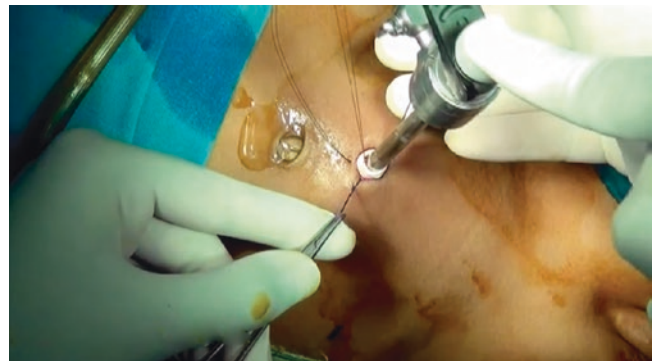


Fig. 18.40 Trocar railroaded over the dilator

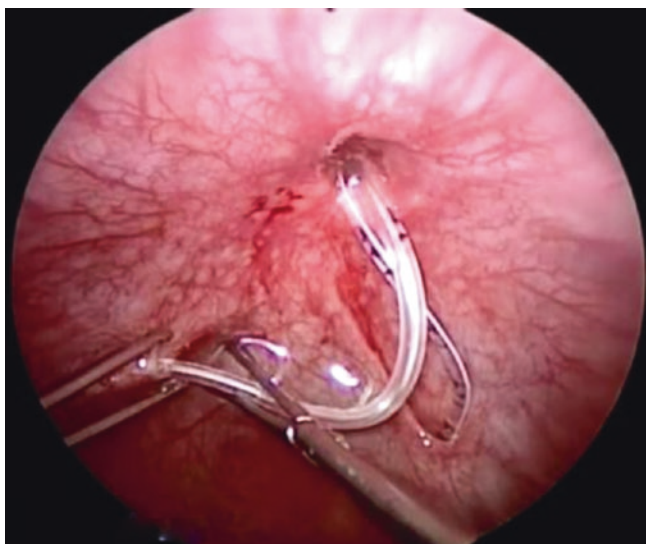


Fig. 18.41 Both ureters stented

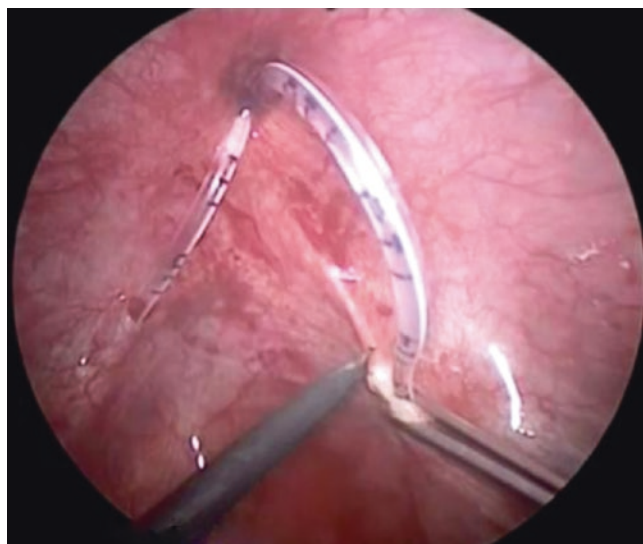

Fig. 18.42 Bladder mucosa around ureteric orifice incised

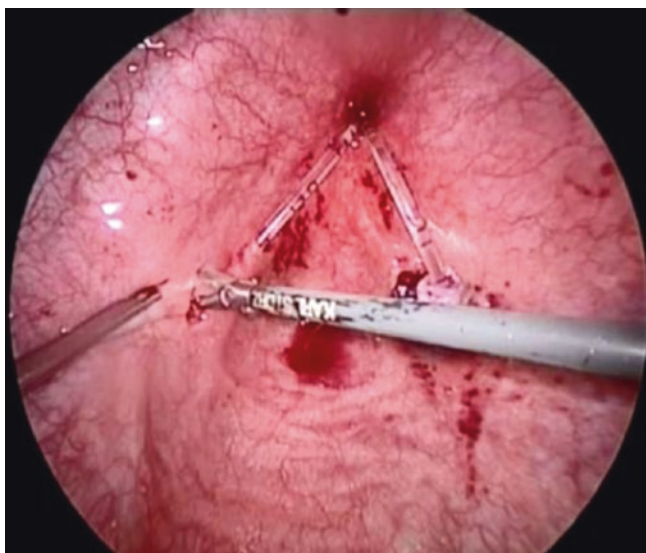


Fig. 18.43 Neo meatus for right ureter made above the left ureteric orifice

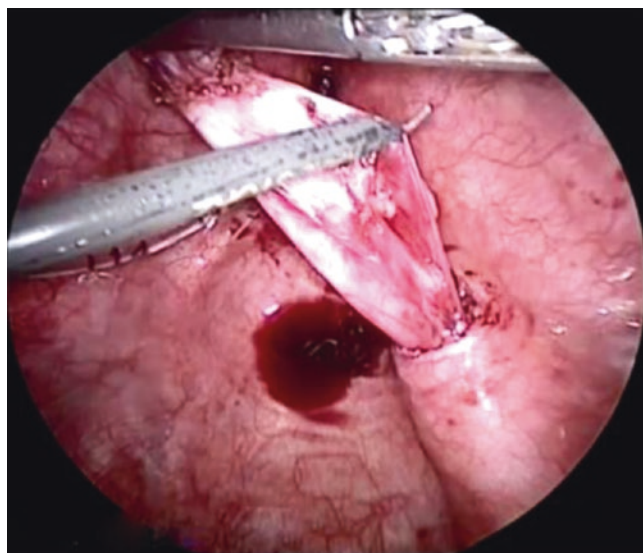


Fig. 18.44 Right ureter being mobilised

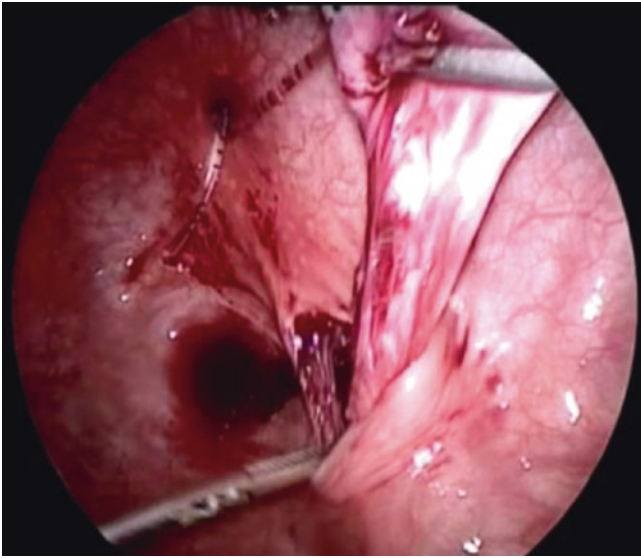


Fig. 18.45 Right ureter mobilised

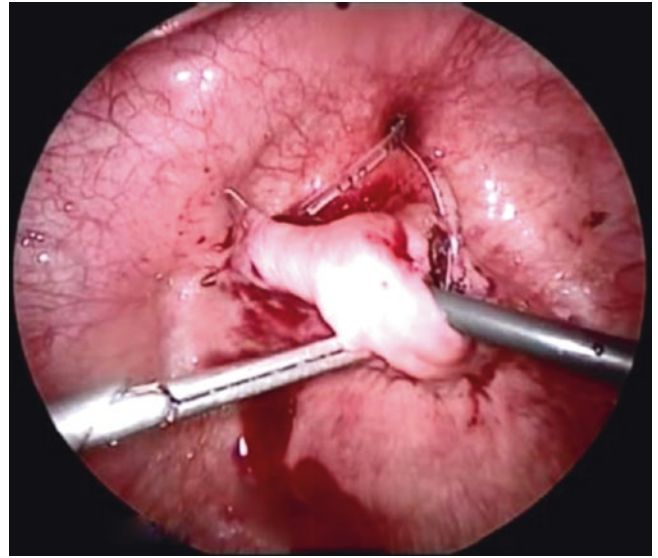


Fig. 18.46 Tunnel created for right ureter

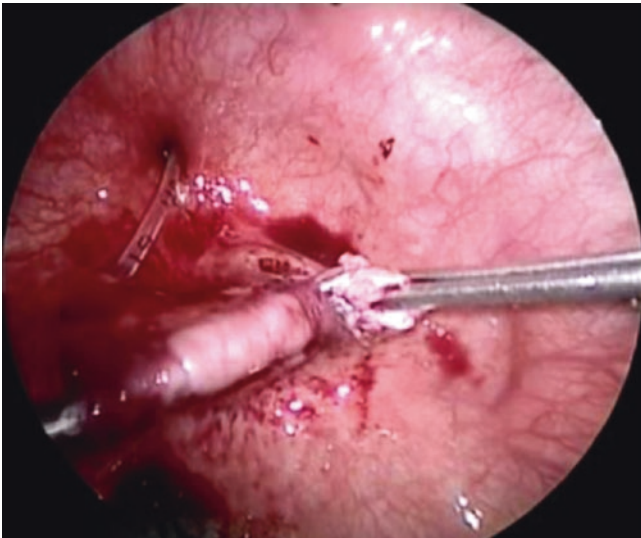


Fig. 18.47 Right ureter grasped for tunneling

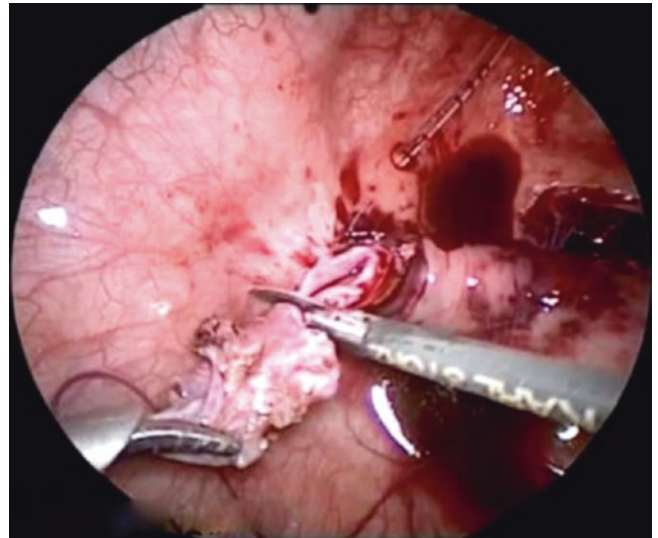


Fig. 18.48 Right distal ureter trimmed

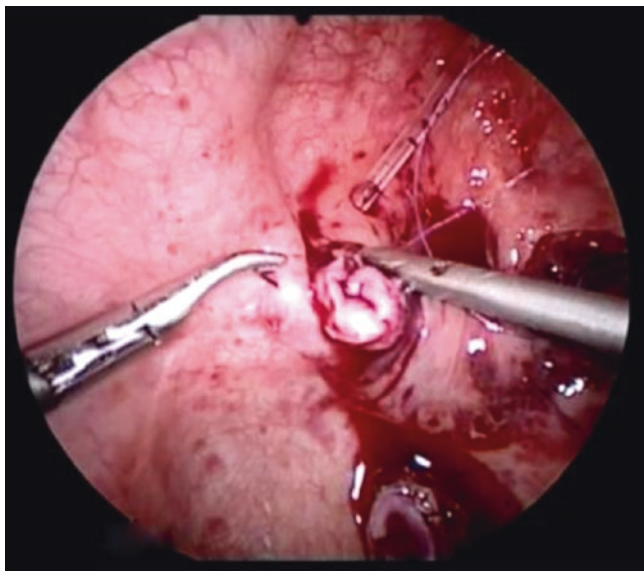


Fig. 18.49 Neo ureteric orifice of right ureter reconstructed using 4-0 PDS

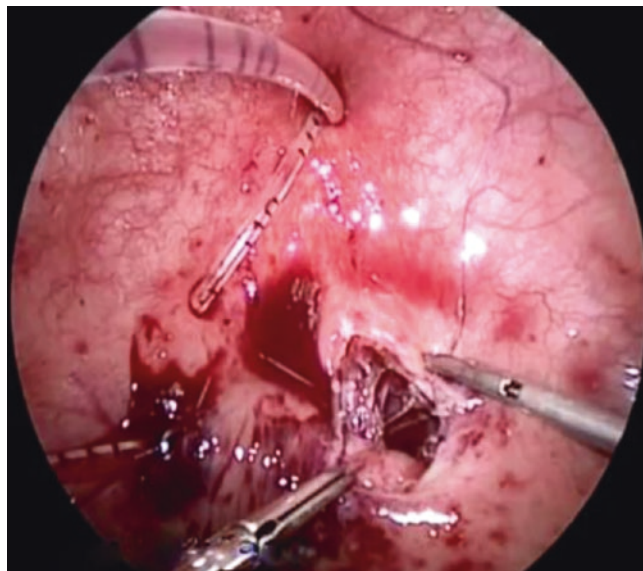


Fig. 18.50 Hiatal defect being closed

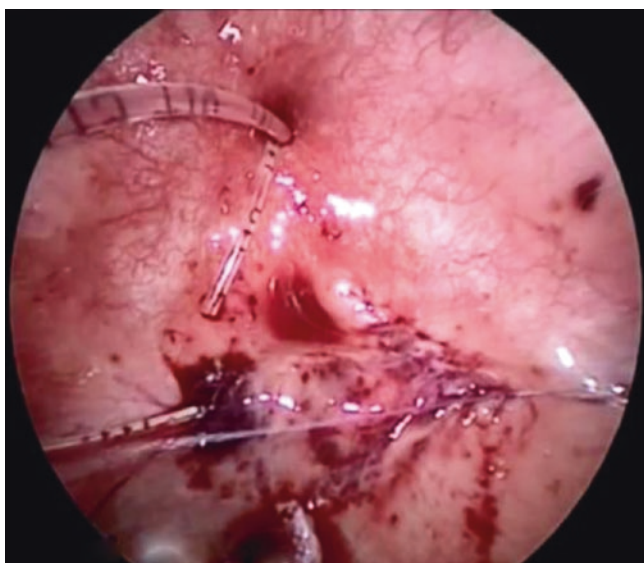


Fig. 18.51 Hiatal defect closed

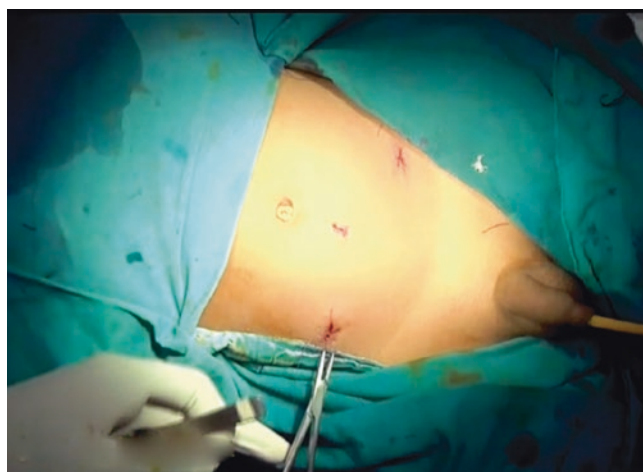

Fig. 18.52 Ports closed

18.10 Extravesical Reimplant (Tailored)

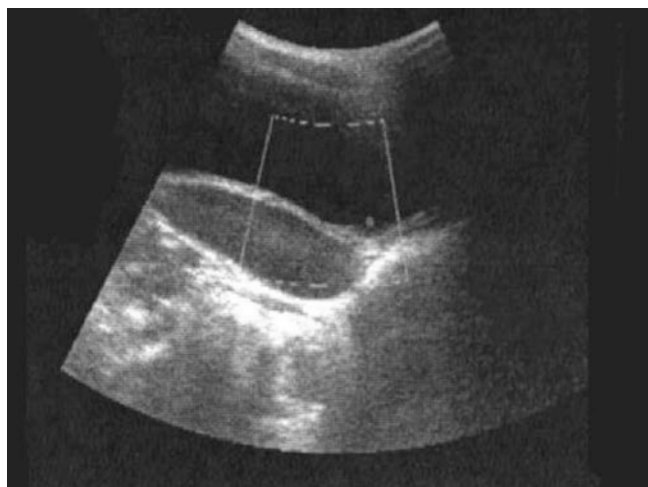


Fig. 18.53 USG showing obstruction at VUJ

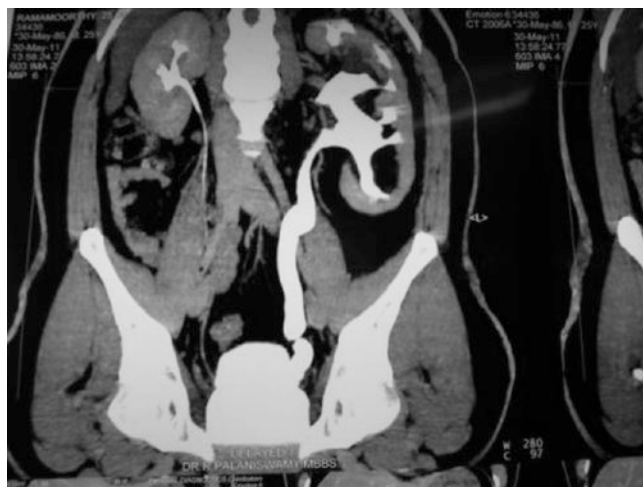

Fig. 18.54 CT image showing ureteric obstruction

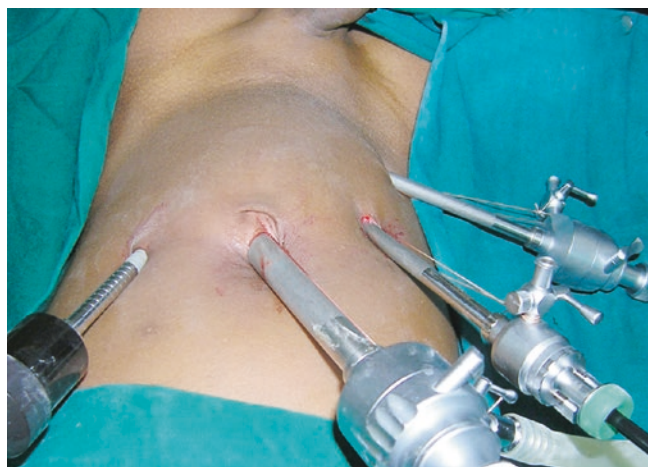


Fig. 18.55 Ports position

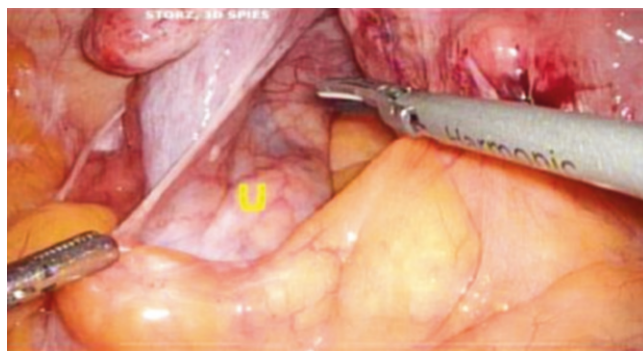


Fig. 18.56 Initial view of left lower ureter

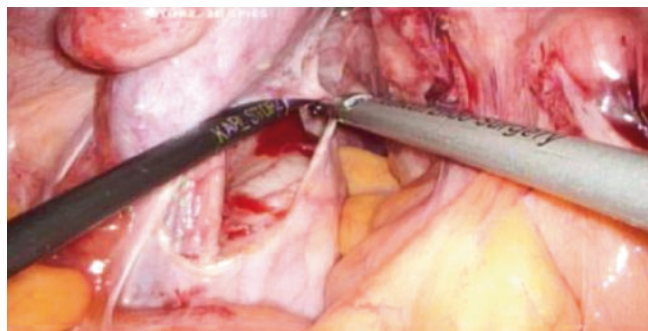


Fig. 18.57 Peritoneal incision exposing ureter

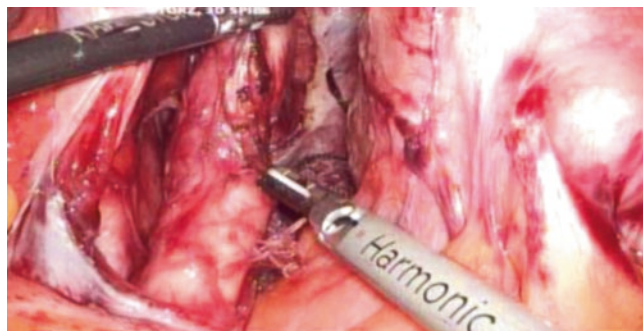


Fig. 18.58 Ureter being dissected at the level of vessel crossing

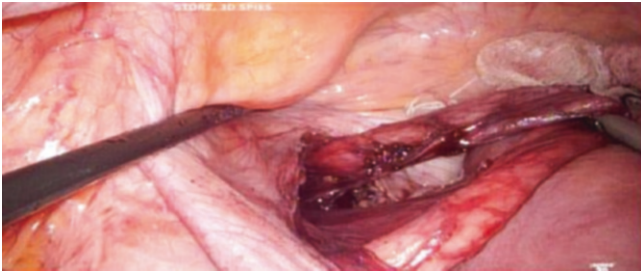


Fig. 18.59 Ureter dissection proceeds distally

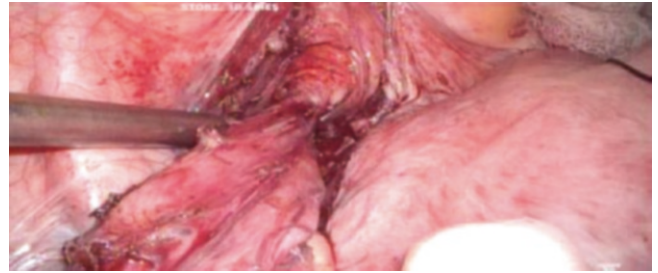


Fig. 18.60 Dissection till narrowing at the level of vesico ureteric junction

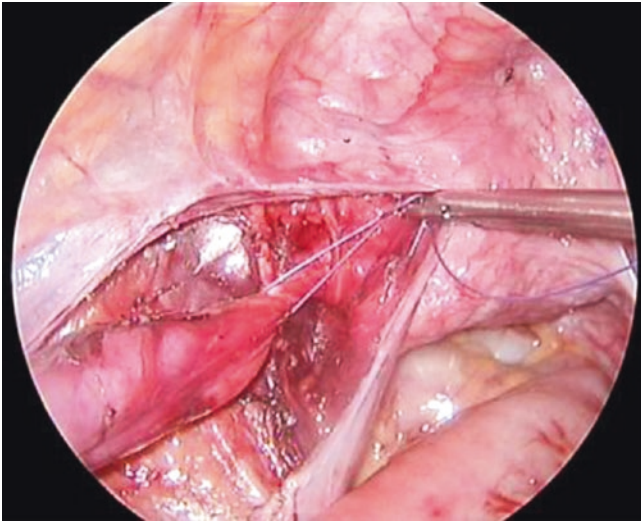


Fig. 18.61 Ureter ligated at hiatus

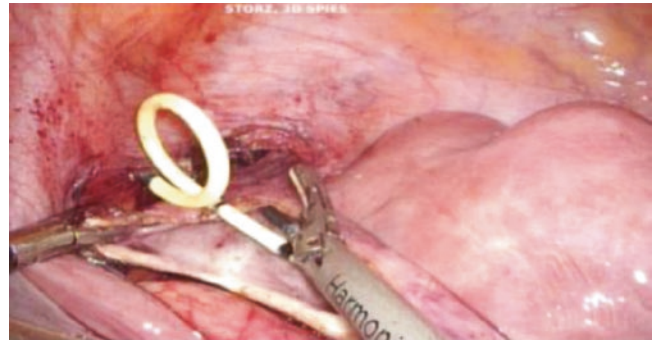


Fig. 18.62 Ureter incised and excess ureter being trimmed (note pre-placed stent)

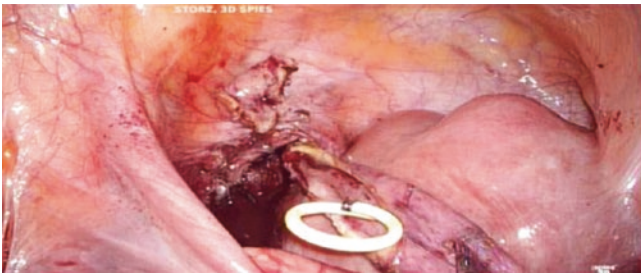


Fig. 18.63 Ureter trimming complete

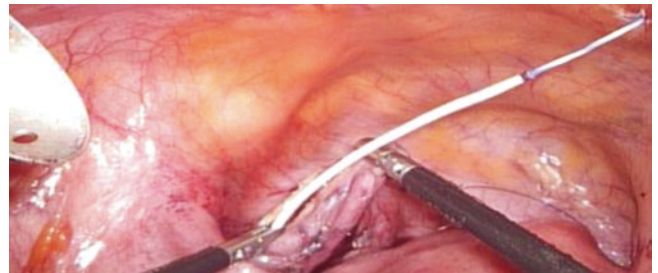


Fig. 18.64 (New) stent being inserted retrograde

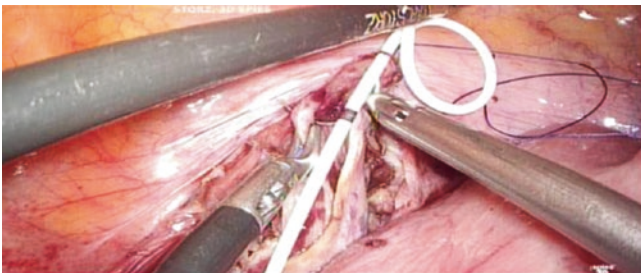


Fig. 18.65 Tailoring started at the distal end using 4-0 PDS

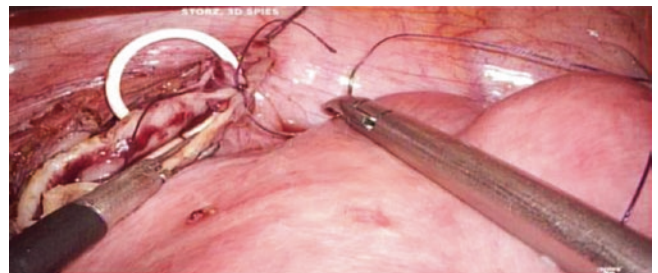


Fig. 18.66 First tailoring suture in place

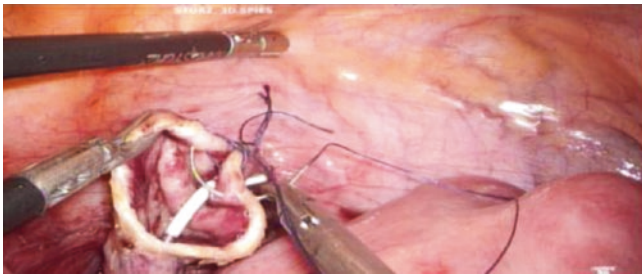


Fig. 18.67 Tailoring with continuous suture in progress

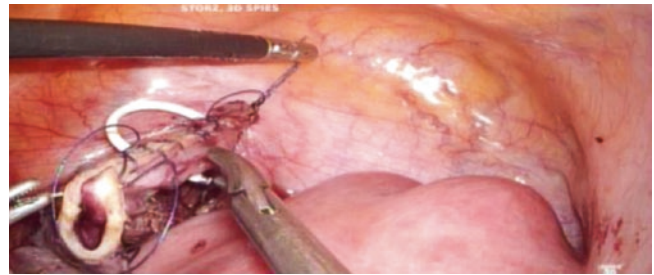


Fig. 18.68 Tailoring in progress

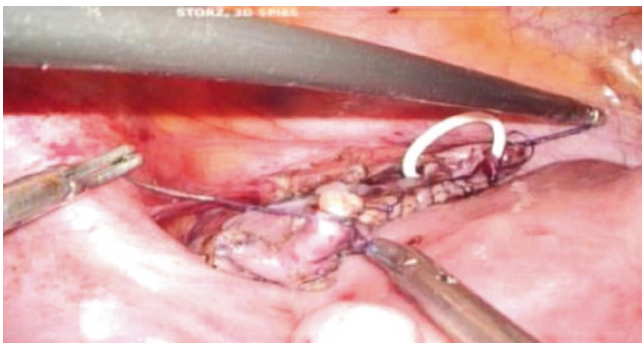

Fig. 18.69 Tailoring completed

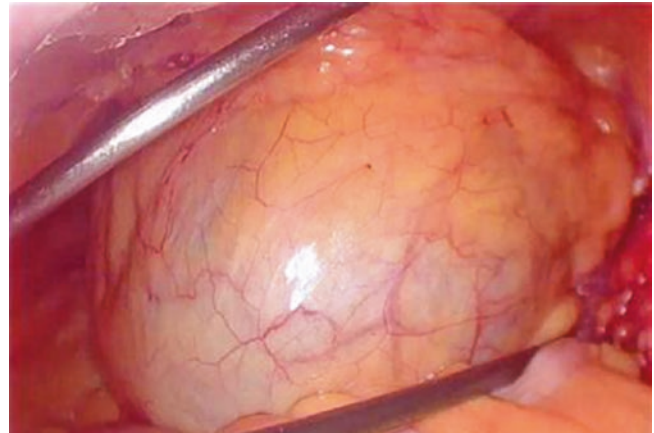


Fig. 18.70 Bladder distended

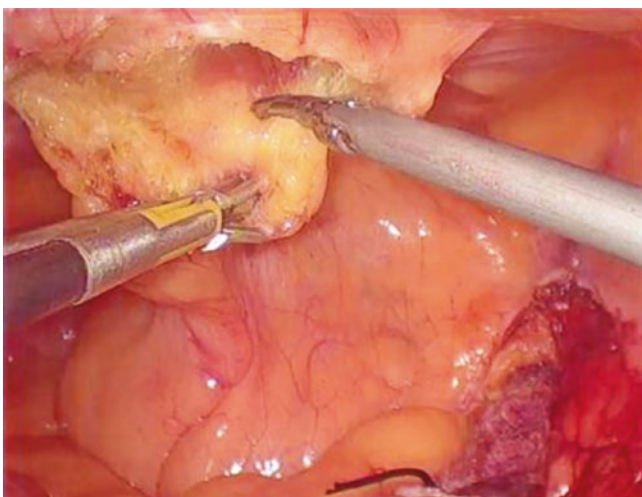


Fig. 18.71 Bladder being dropped down from abdominal wall

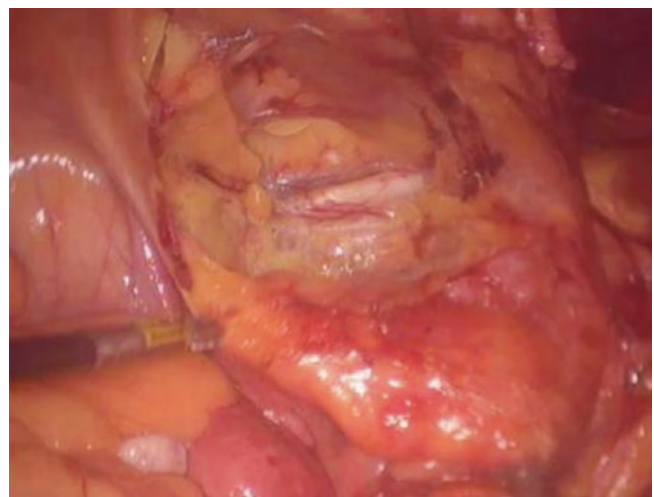

Fig. 18.72 Incision of perivesical fat after distending the bladder

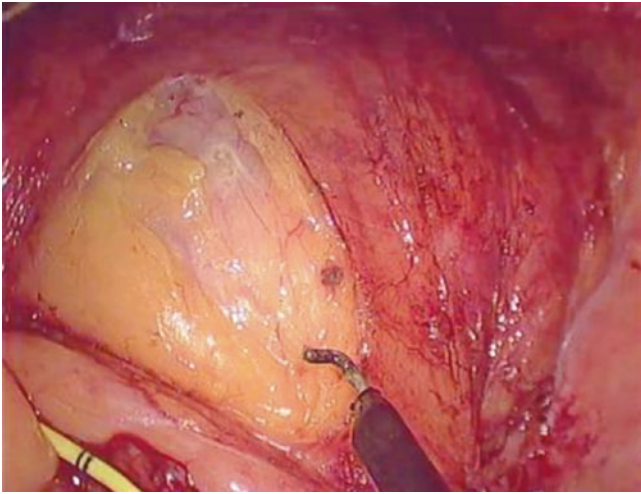


Fig. 18.73 Retzius space developed as distal as necessary depending on the area of reimplantation

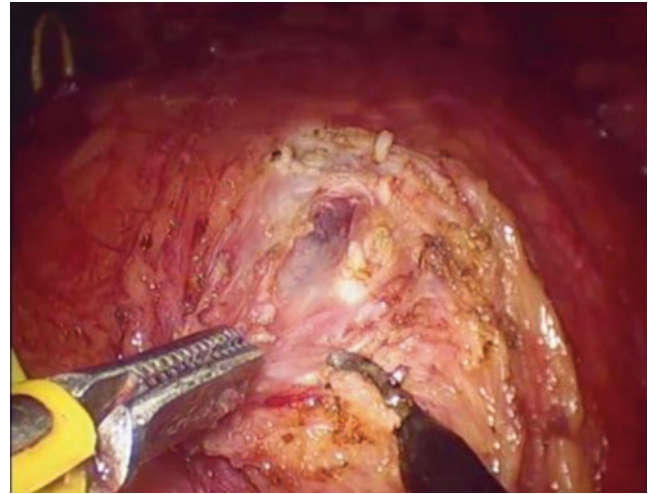


Fig. 18.74 Incision and separation of detrusor muscle to develop submucosal plane

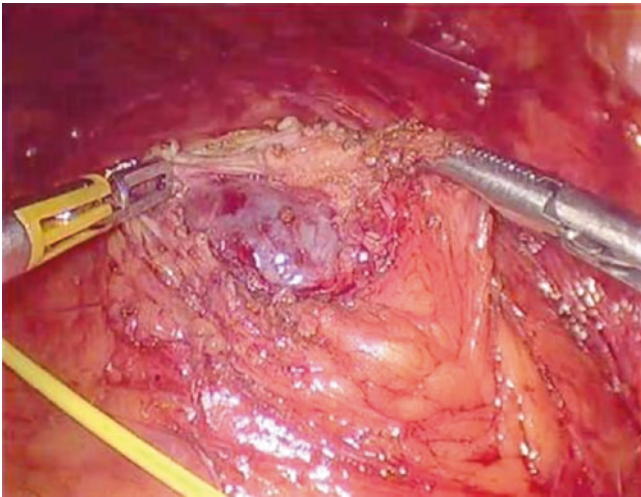


Fig. 18.75 Submucosal plane fully developed

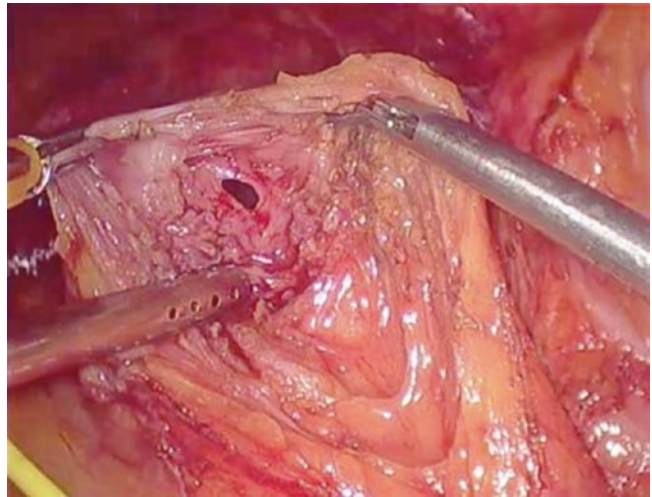


Fig. 18.76 Mucosa incised at the distal end

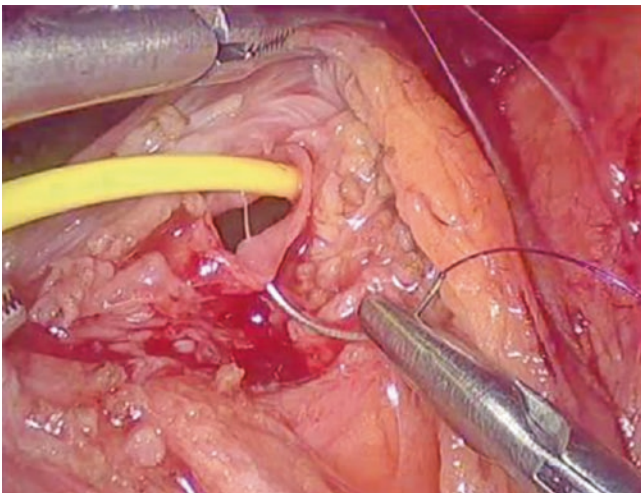


Fig. 18.77 First suture with 4-0 PDS outside-in through the bladder mucosa

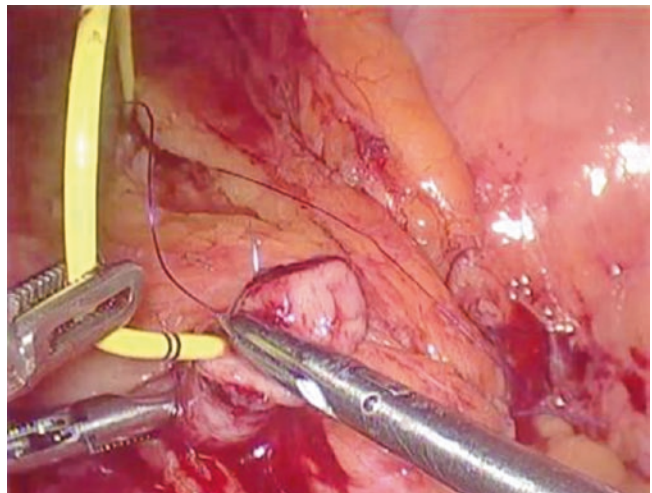


Fig. 18.78 Apical suture inside-out through the spatulated end of ureter

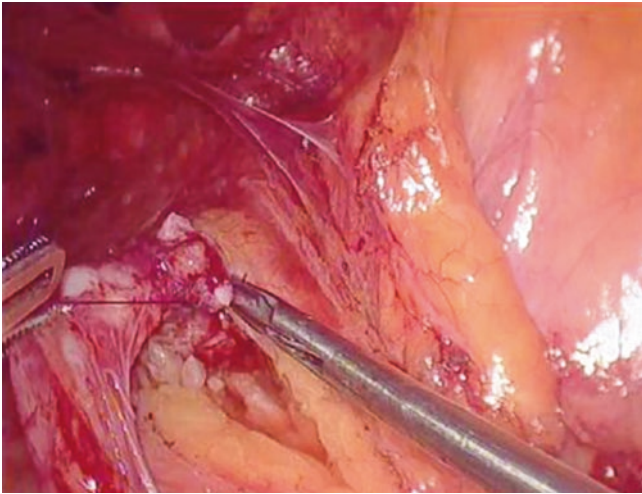


Fig. 18.79 First suture with Polydioxanone in place

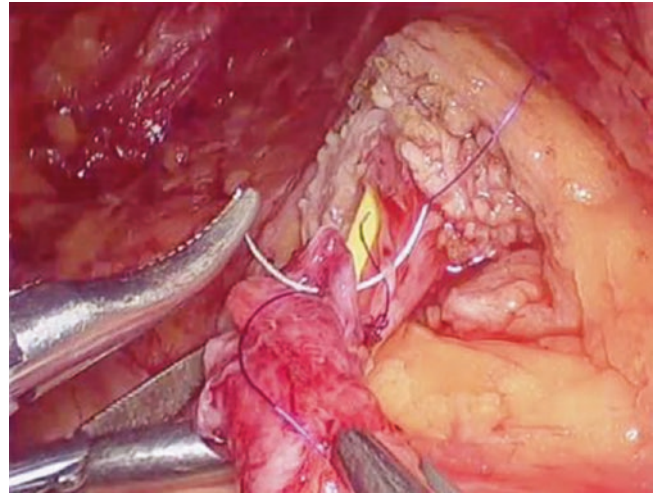


Fig. 18.80 Medial aspect suturing in progress

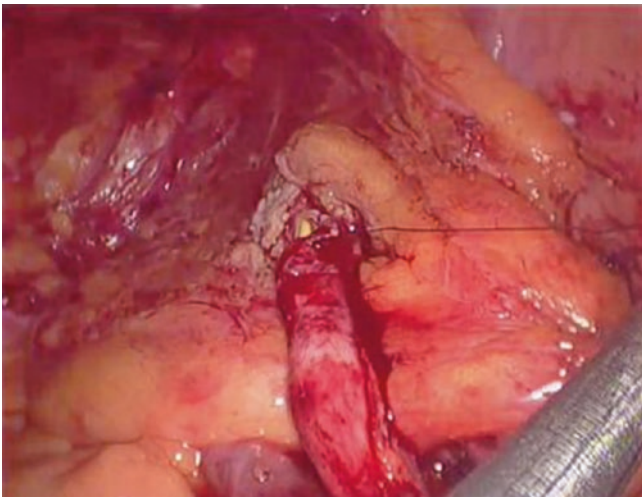


Fig. 18.81 Continuous suture on medial aspect complete

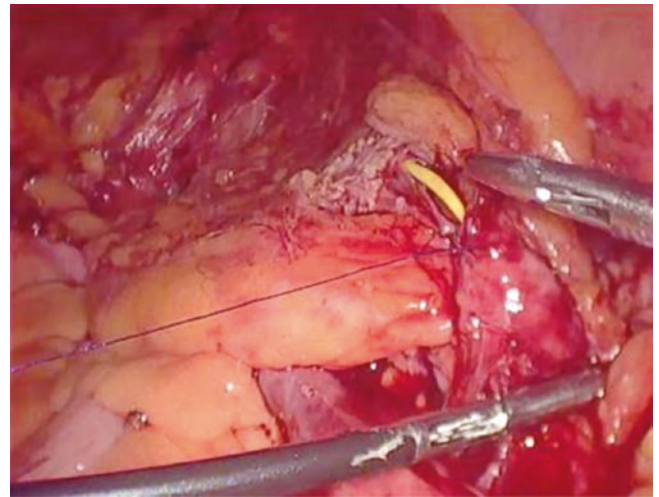


Fig. 18.82 Lateral aspect suture started

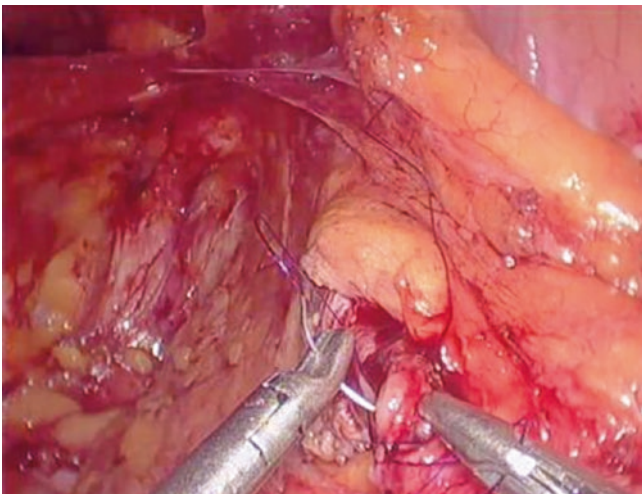


Fig. 18.83 Lateral aspect suturing in progress

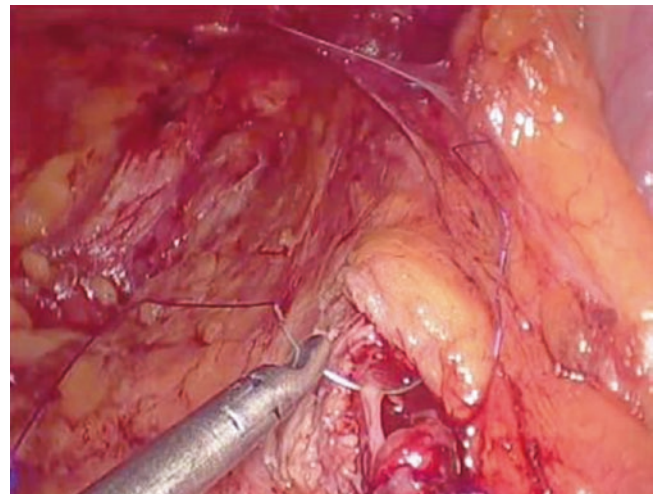


Fig. 18.84 Continuous suturing in progress

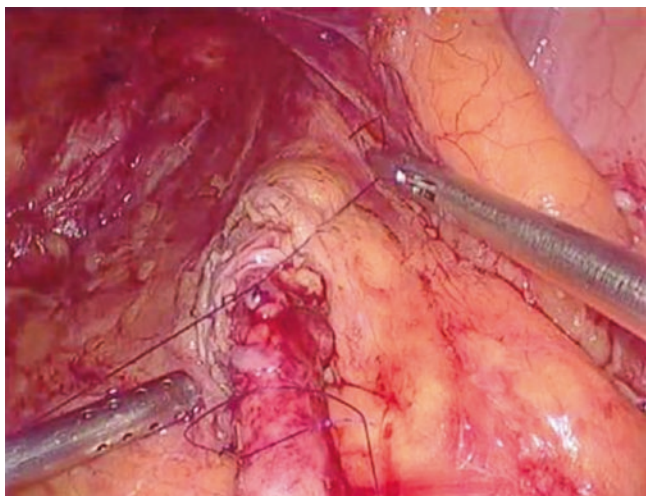


Fig. 18.85 Final suture in place

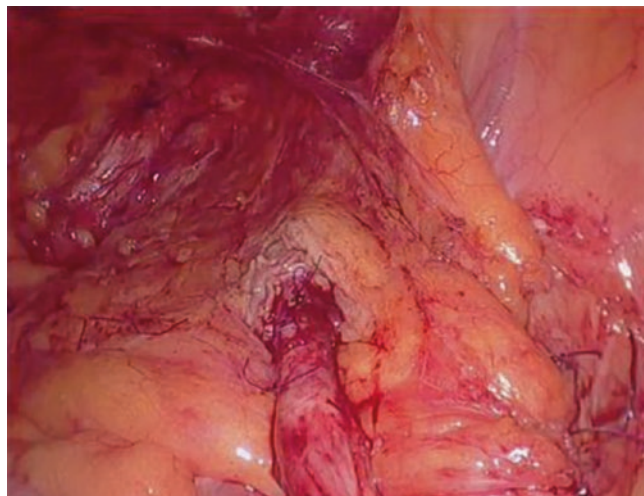


Fig. 18.86 Completed anastomosis

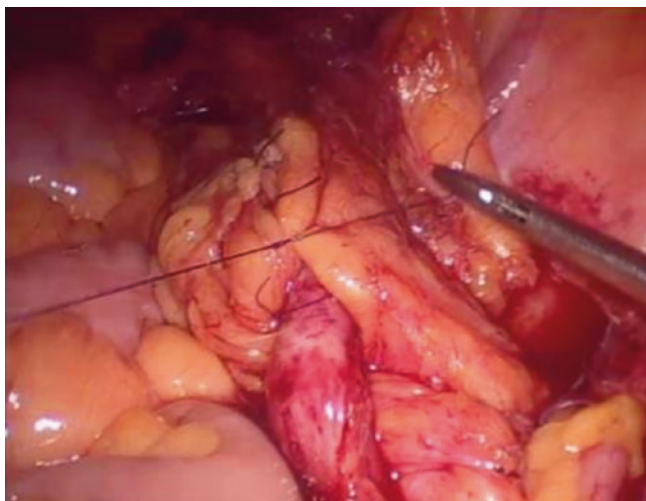


Fig. 18.87 Second layer suturing with 3-0 vicryl (Detrusorrhaphy) completed

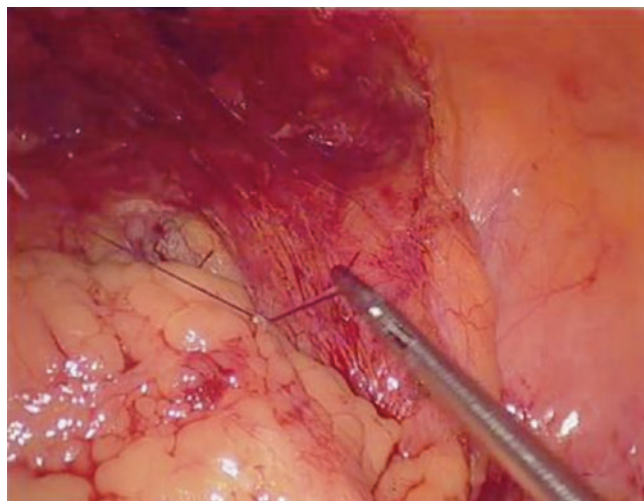


Fig. 18.88 Final image after omental buttressing

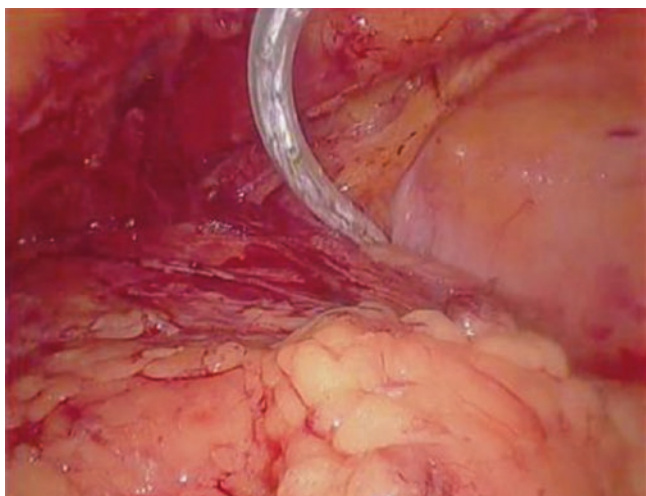


Fig. 18.89 Drain placement

18.11 Psoas Hitch Ureteric Reimplantation for Ureterovaginal Fistula

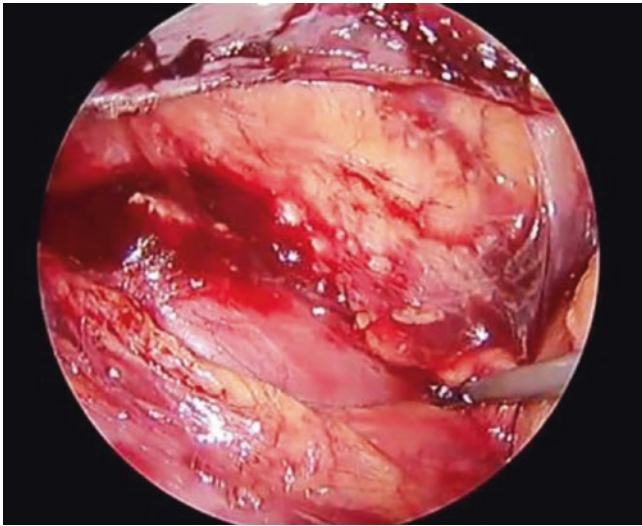


Fig. 18.90 Psoas exposed

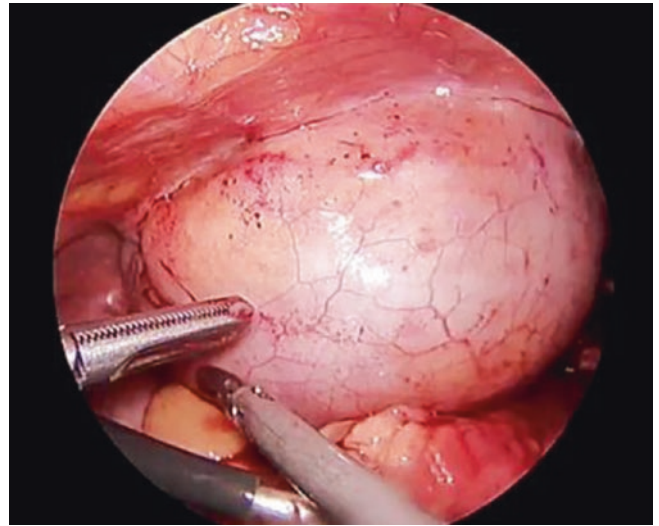


Fig. 18.91 Bladder distended

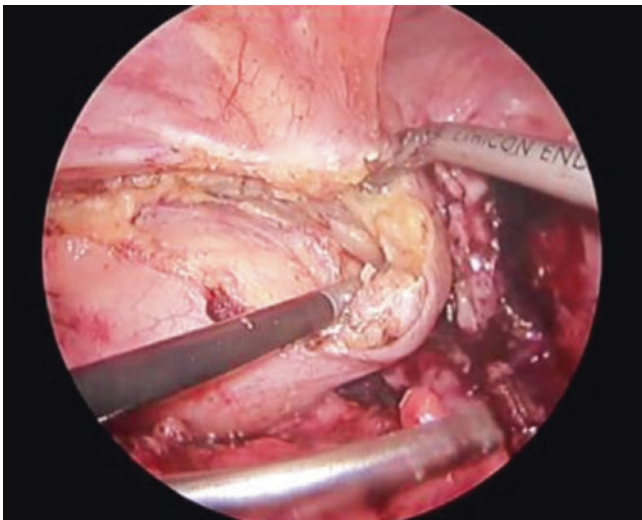


Fig. 18.92 Bladder dropped down from the anterior abdominal wall

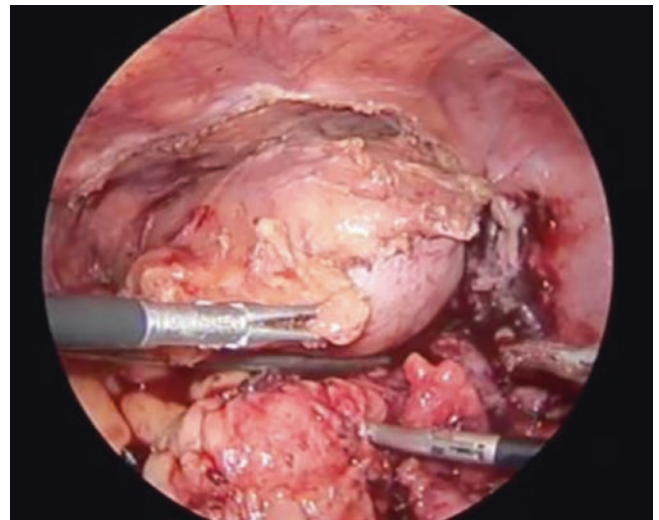


Fig. 18.93 Retzius space developed with complete severing of attachments on the side opposite to planned psoas hitch

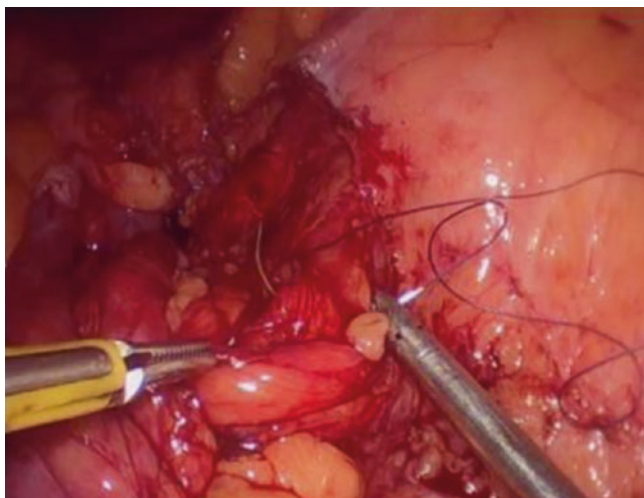


Fig. 18.94 Suture taken through psoas muscle with 2-0 polyglactin suture – good bulk of muscle necessary for better hold

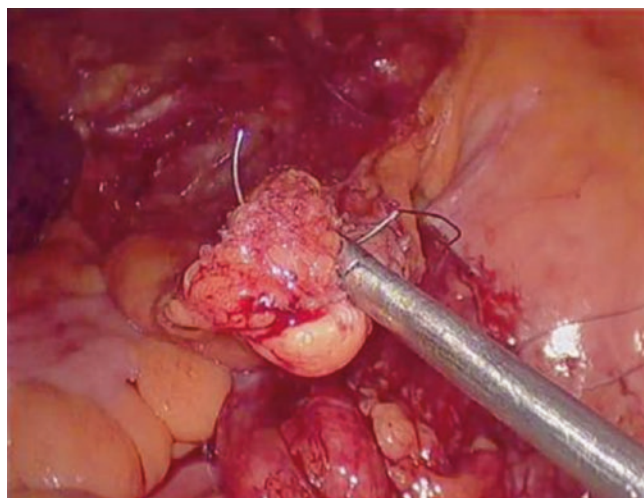


Fig. 18.95 Suture through the bladder

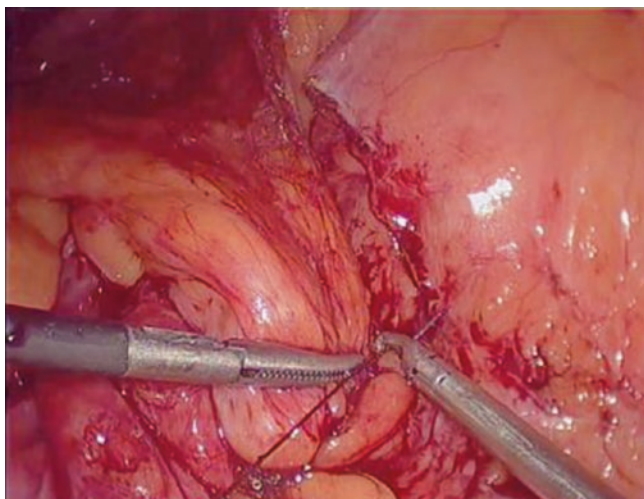


Fig. 18.96 Psoas hitch suture in place

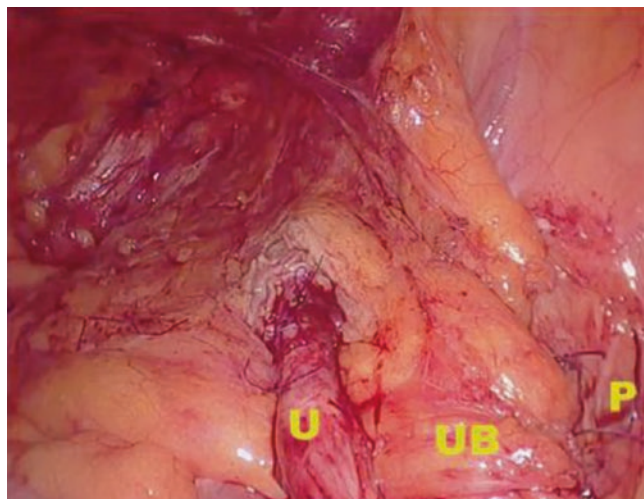


Fig. 18.97 Ureter reimplanted after psoas hitch

18.12 Boari Flap Reimplantation

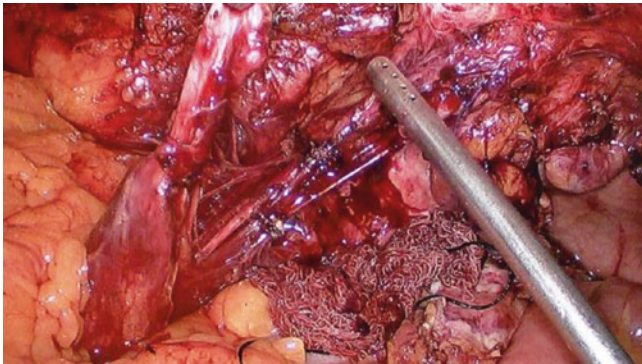


Fig. 18.98 Junction of dilated left ureter and strictured ureter seen (a case of long segment stricture left lower ureter)

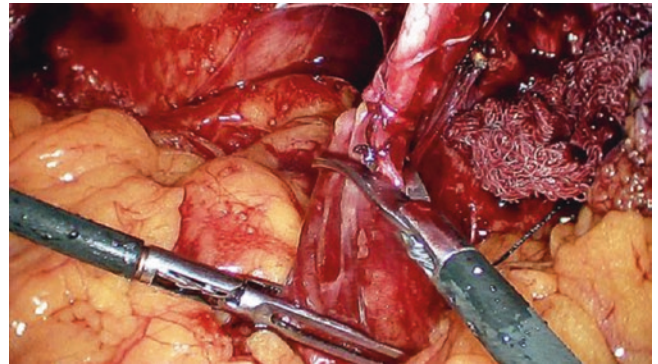


Fig. 18.99 Ureter being divided proximal to narrow segment at pelvic brim level

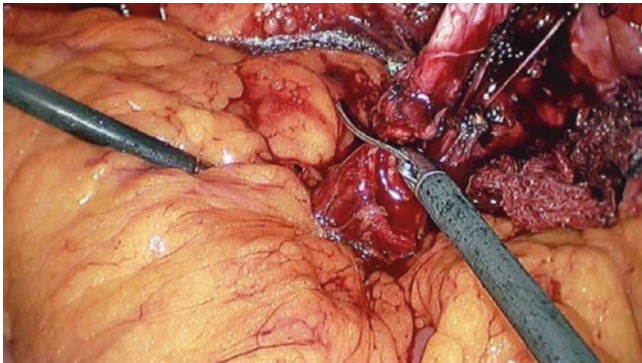


Fig 18.100 Ureter division complete

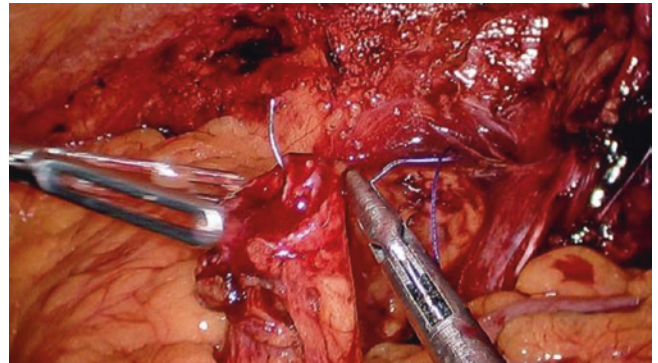


Fig 18.101 Initial bite outside – in through the dilated ureter

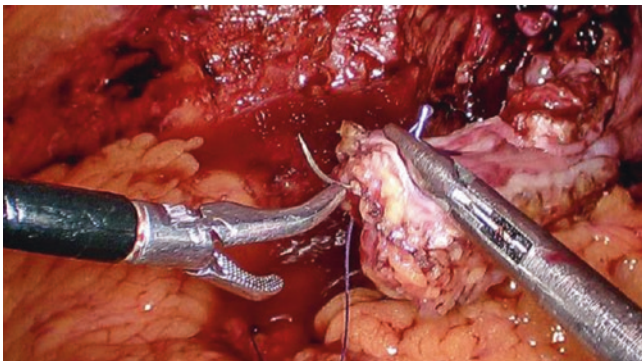


Fig 18.102 Initial bite inside- out through the apex of the boari flap

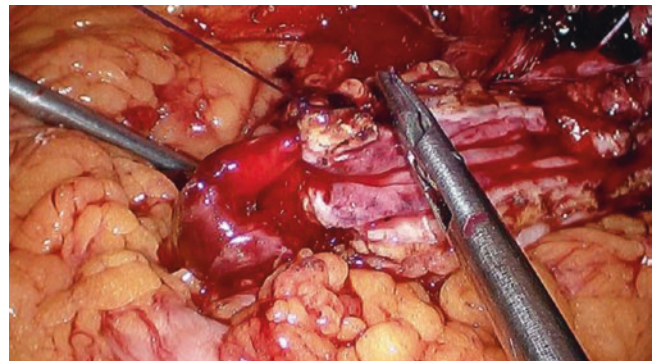


Fig 18.103 Apical suture in place

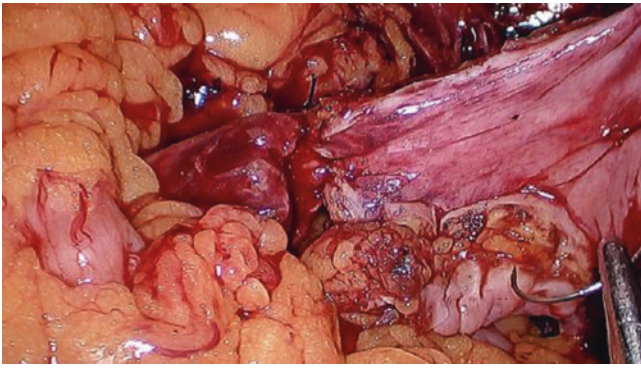


Fig 18.104 Posterior layer interrupted suturing of flap and ureter in progress

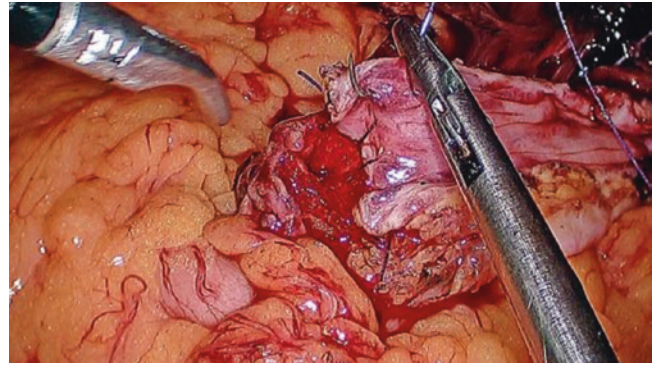


Fig 18.105 Posterior layer suturing in progress

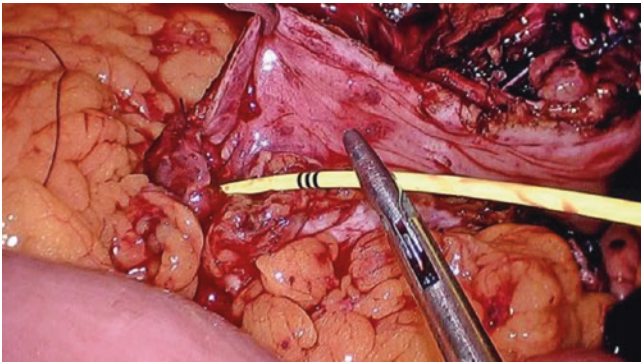


Fig 18.106 Stent being inserted retrograde

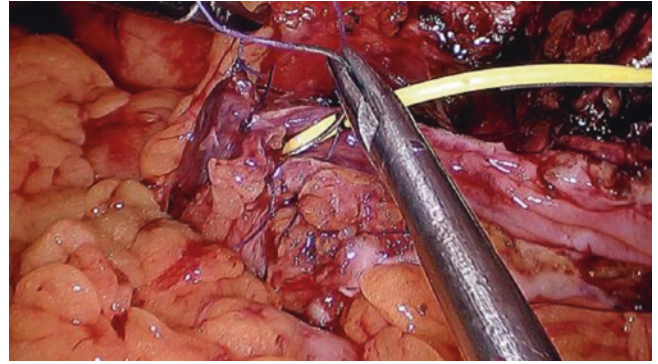


Fig 18.107 Anterior layer suturing in progress

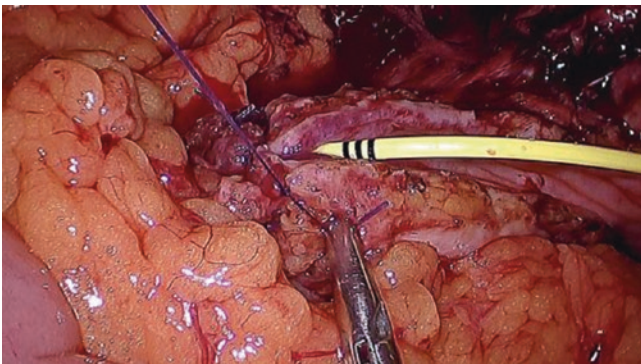


Fig 18.108 Anterior layer suturing complete

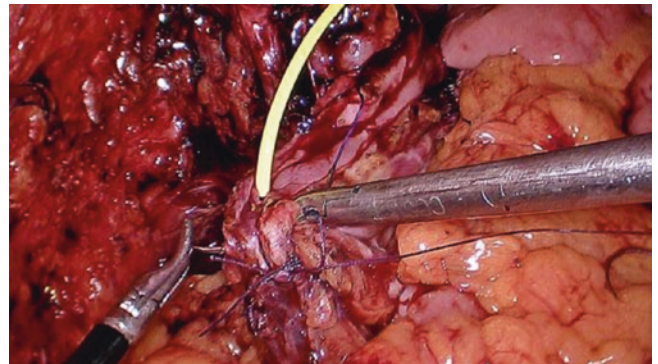


Fig 18.109 Flap tubularisation started with 3-0 vicryl

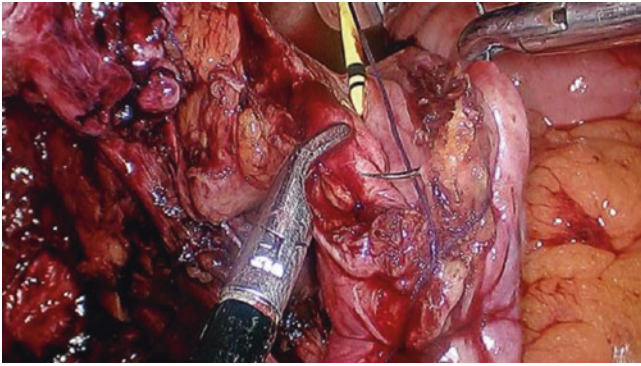


Fig 18.110 Flap tubularisation in progress

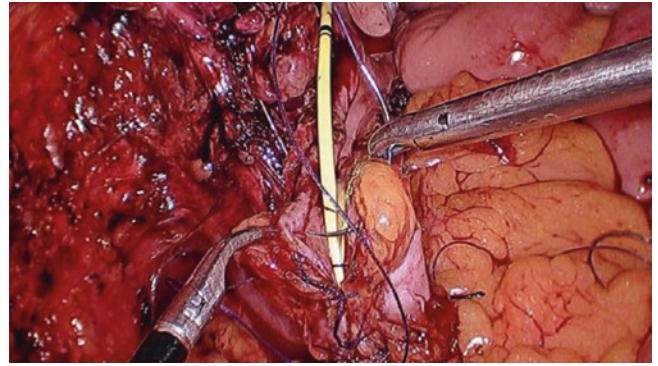


Fig 18.111 Flap tubularisation in progress

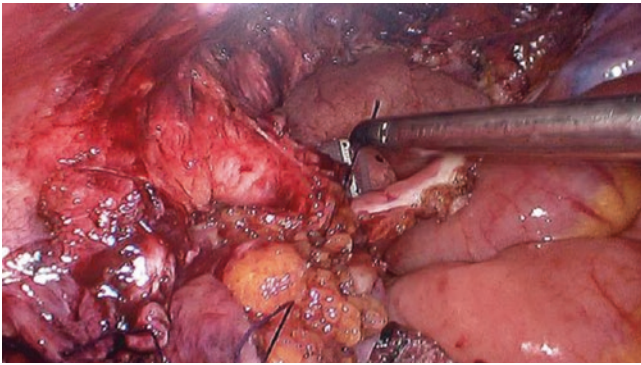


Fig 18.112 Flap tubularisation completed

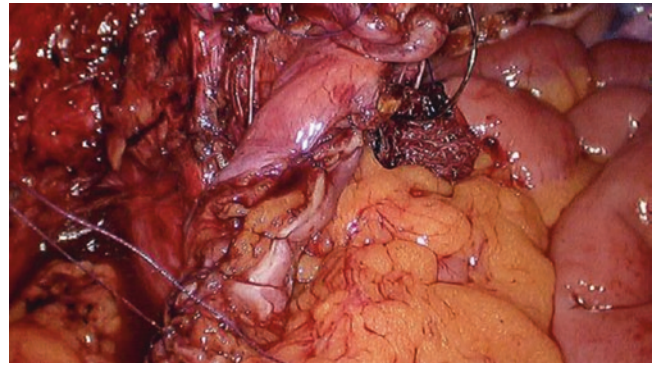


Fig 18.113 Flap tubularisation and bladder closure completed

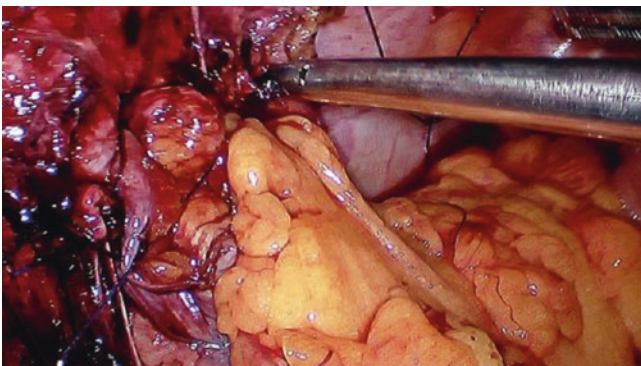


Fig 18.114 Omental wrapping

18.13 Nipple Valve Ureteric Reimplantation

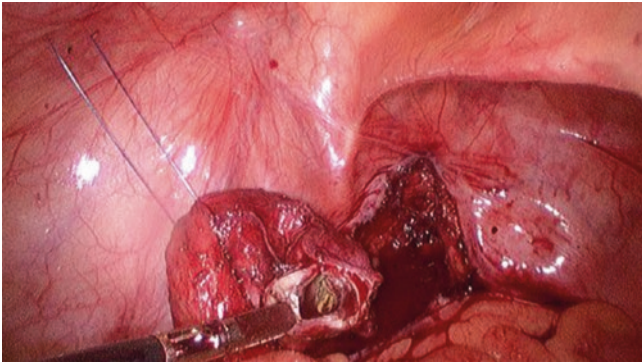


Fig. 18.115 Grossly dilated distal end of ureter (POM divided at hiatus and spatulated)

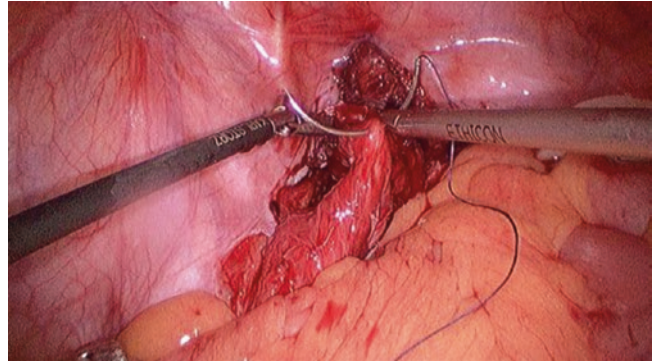


Fig. 18.116 Initial serosal bite 2 cm from cut end using 3-0 vicryl (for eversion)

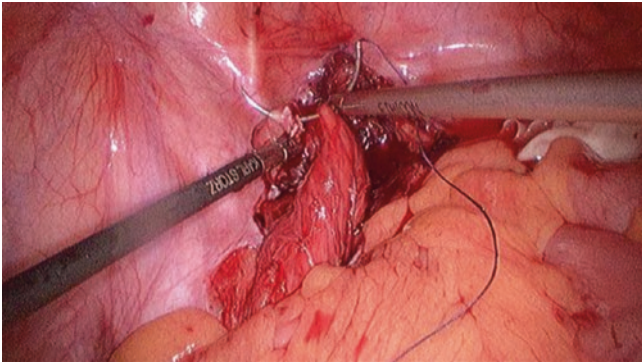


Fig. 18.117 Bite through mucosa for eversion

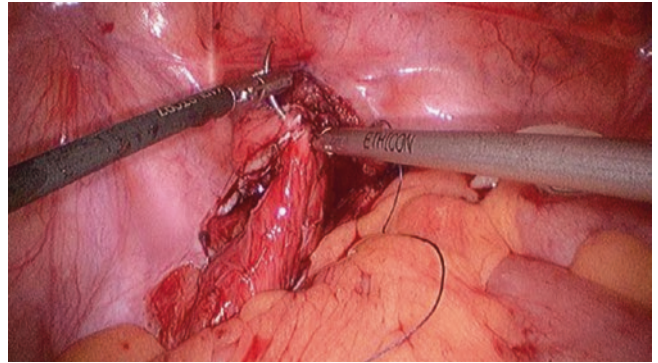


Fig. 18.118 Eversion in progress

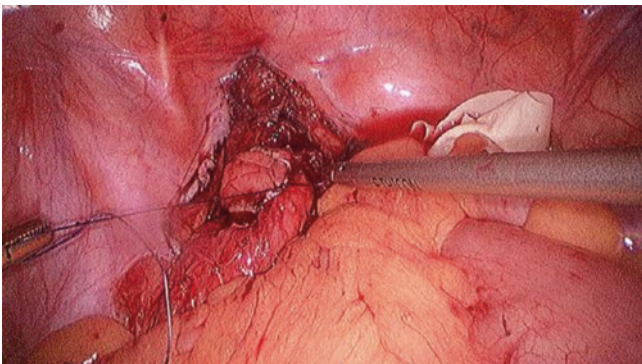


Fig. 18.119 First eversion suture in place

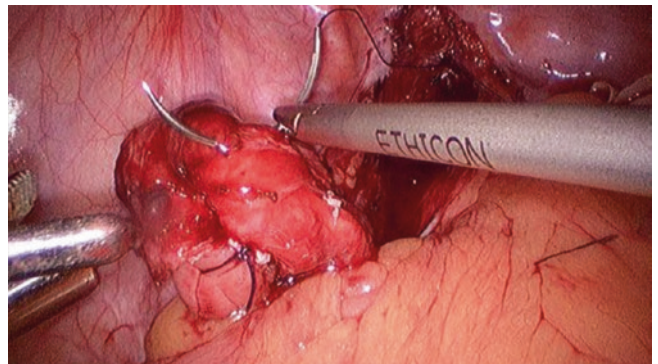


Fig. 18.120 Second eversion suture in progress

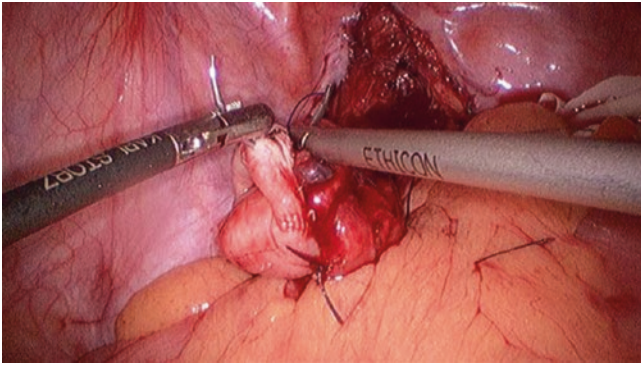


Fig. 18.121 Second eversion suture in progress

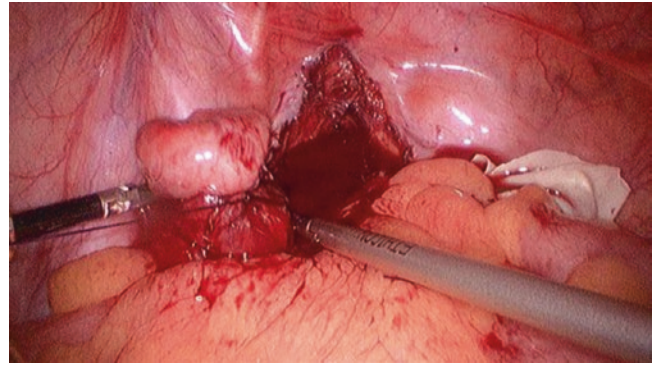


Fig. 18.122 Second eversion suture complete

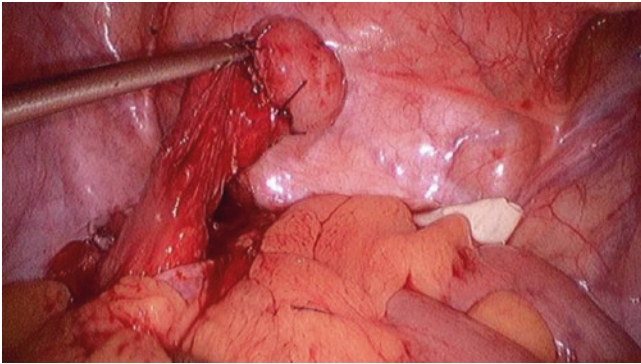


Fig. 18.123 Completed nipple

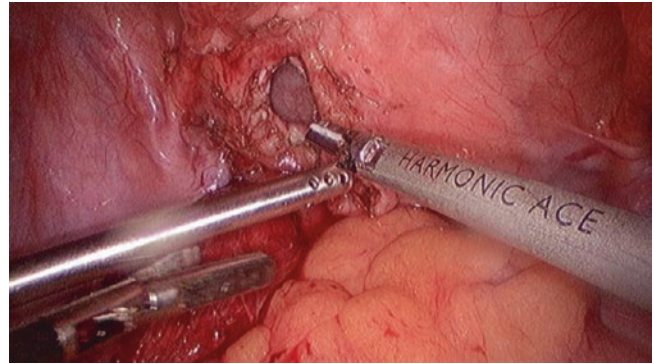


Fig. 18.124 Cystotomy over the anterolateral wall for reimplantation

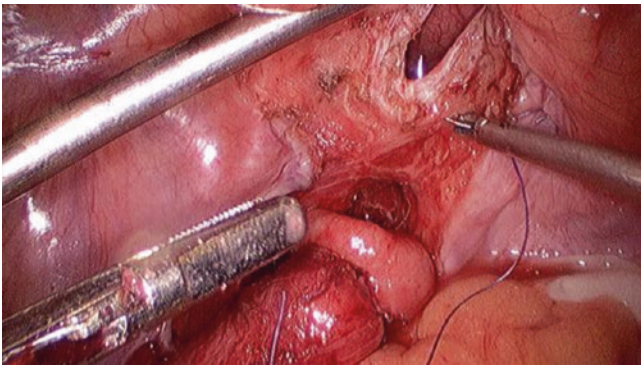


Fig. 18.125 First bite outside-in through bladder using 3-0 vicryl

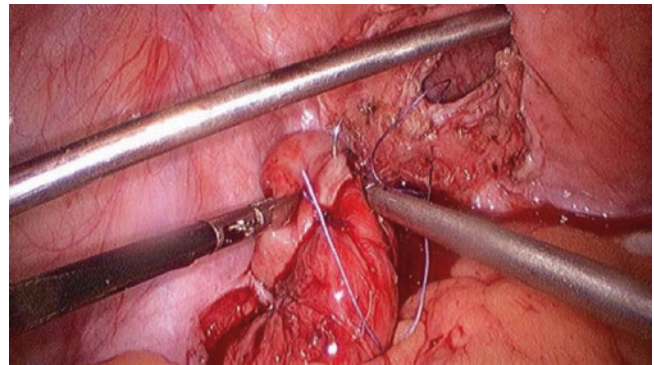


Fig. 18.126 Corresponding suture through reconstructed nipple valve ureter

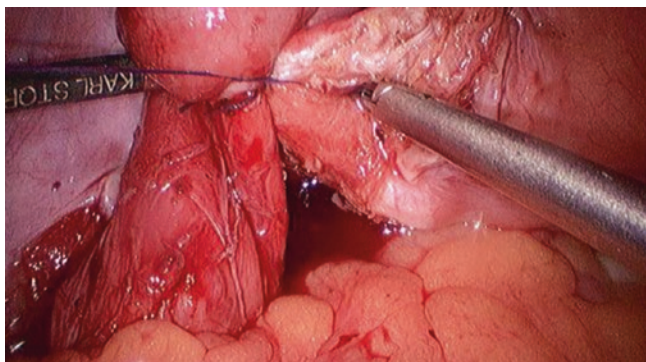


Fig. 18.127 First reimplantation suture complete

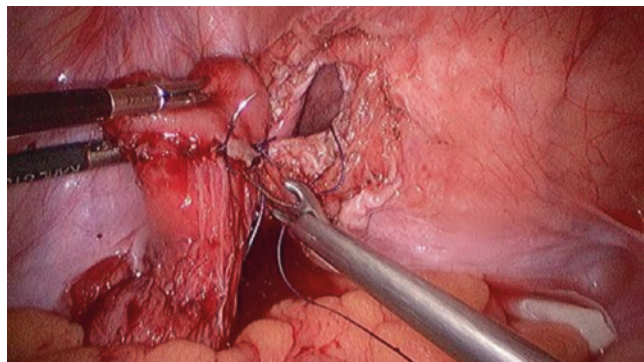


Fig. 18.128 Reimplantation in progress with similar interrupted sutures

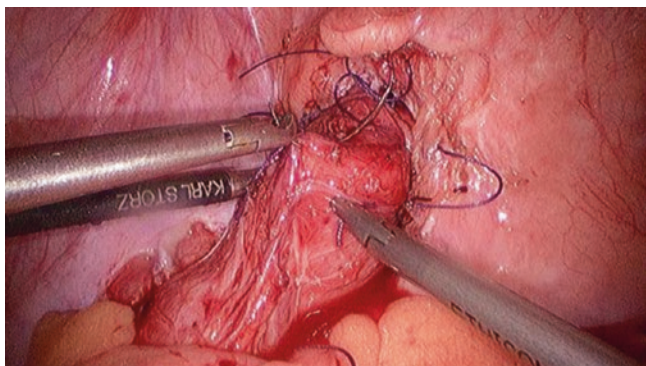


Fig. 18.129 Reimplantation in progress

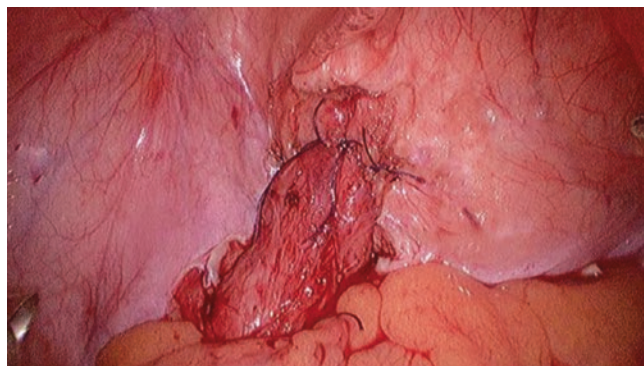


Fig. 18.130 Nipple completely withdrawn into the bladder. Completed reimplantation

18.14 Ureteric Reimplantation in Ectopic Ureter

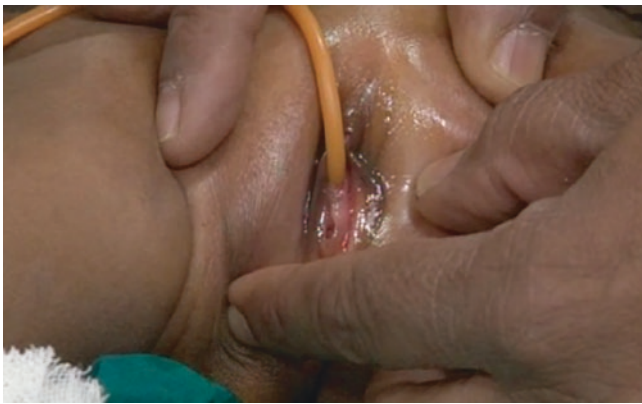

Fig. 18.131 Ectopic opening in Vagina in a child with continuous dribbling

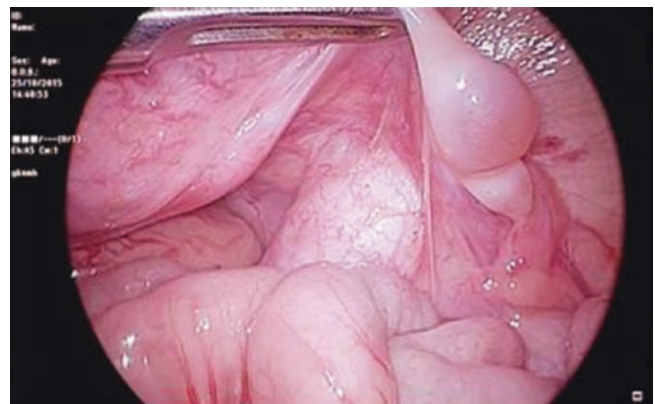


Fig. 18.132 Laparoscopic view showing dilated right ureter

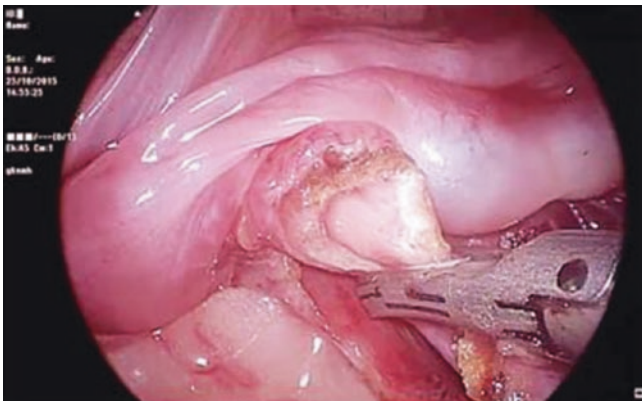

Fig 18.133 Ureter being divided

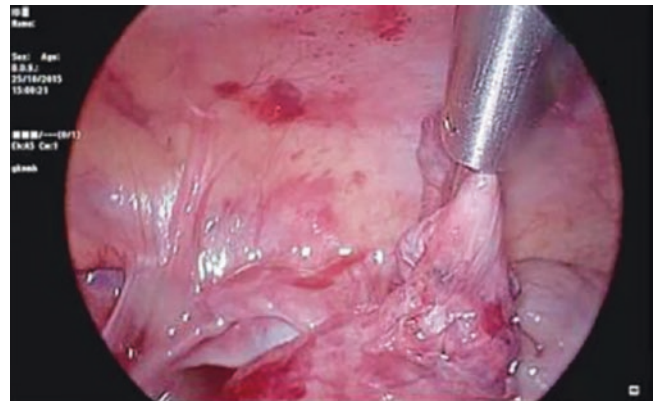


Fig 18.134 Ureter being brought out through port

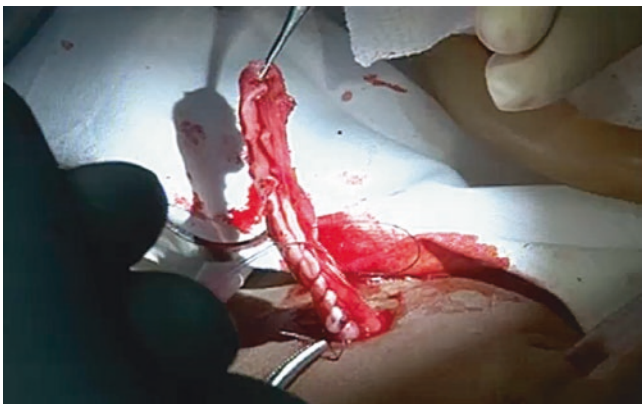


Fig 18.135 Extracorporeal ureteric tailoring in progress

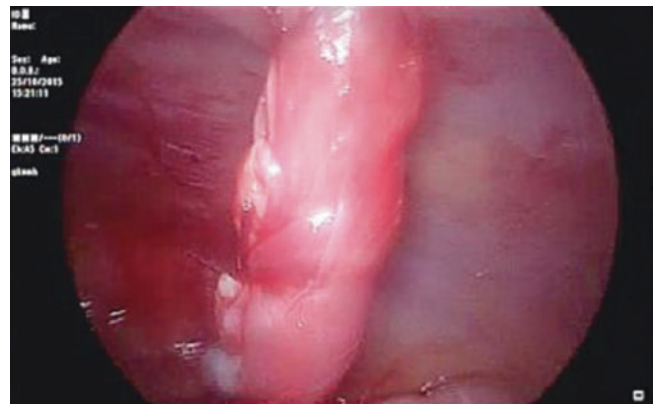

Fig 18.136 Tailored ureter being pushed back

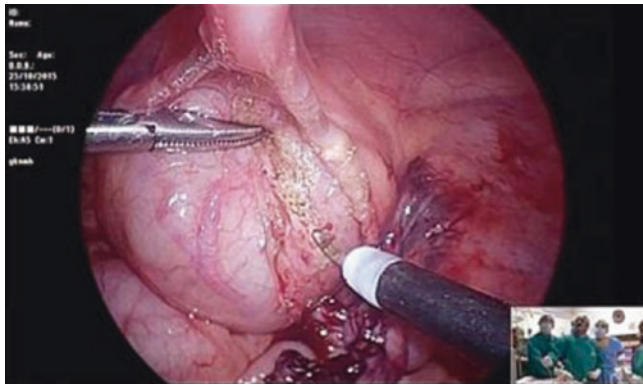


Fig. 18.137 Oblique cystotomy over anterior wall

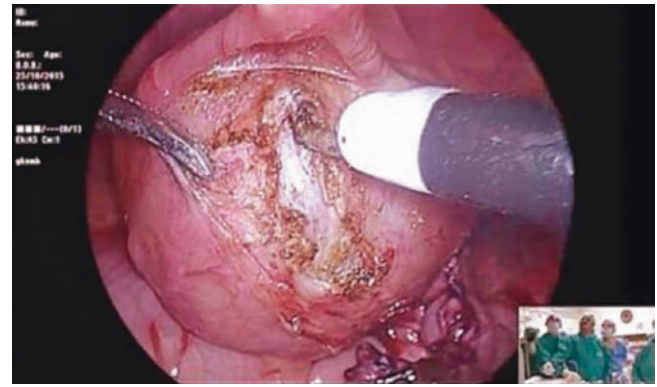


Fig. 18.138 Detrusorotomy for submucosal plane being developed

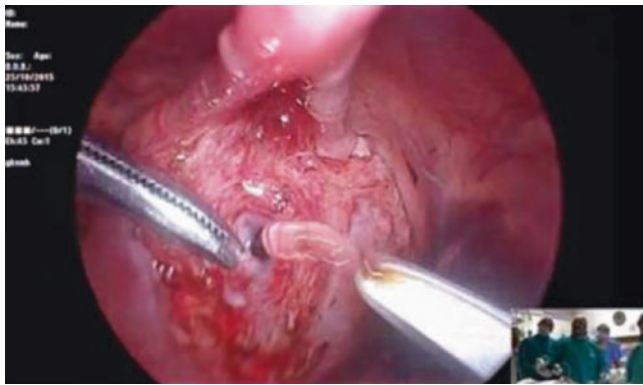

Fig. 18.139 Mucosa incised distally

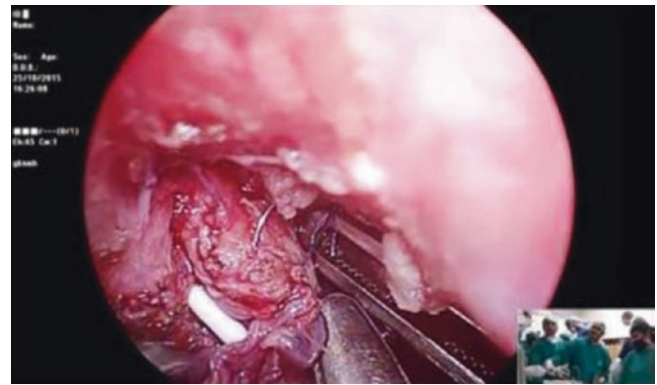


Fig. 18.140 Extravesical reimplantation with 4-0 vicryl

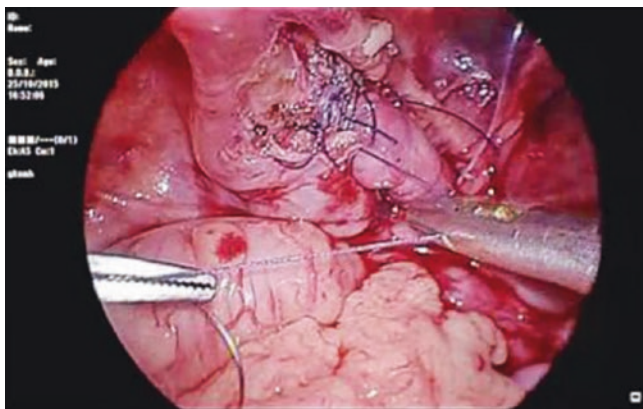


Fig. 18.141 Second layer suturing with 3-0 vicryl in progress

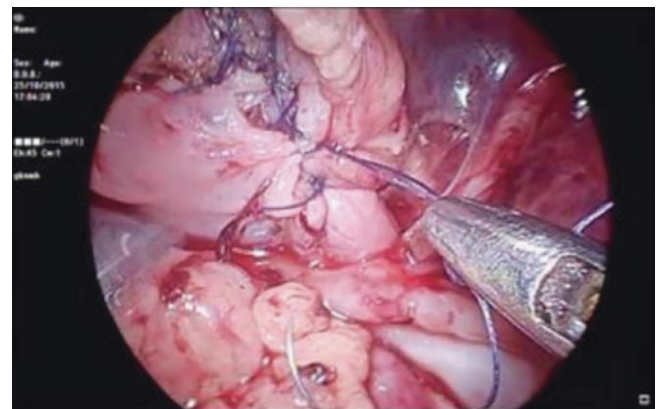


Fig. 18.142 Completed Lich-Gregoir's extravesical reimplantation

18.15 Tips: Special Situation

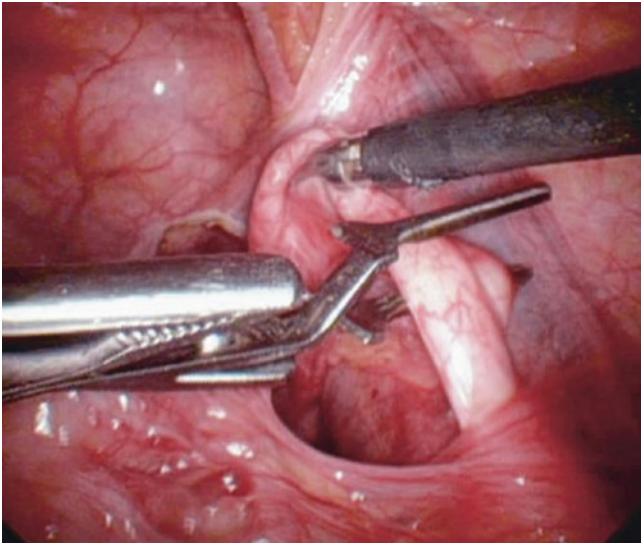


Fig. 18.143 Clamping of ureter for intra operative urodynamics in a case with poor compliance bladder with Gr.4 VUR

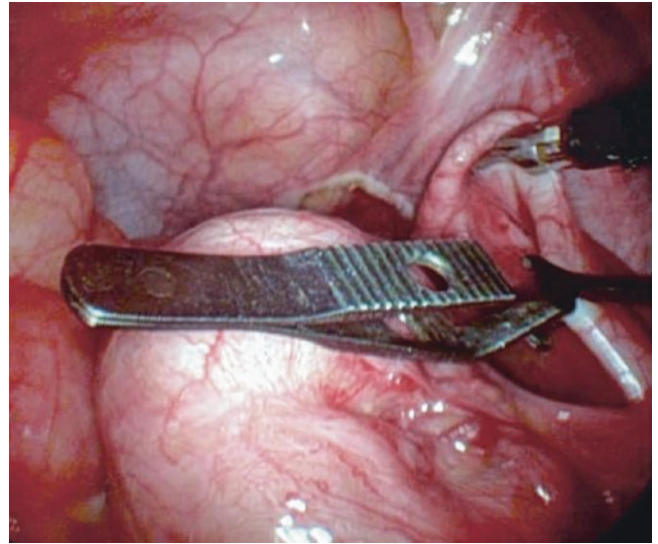


Fig. 18.144 Clamping (Bulldog) of ureter for intra operative urodynamics

References

1. Lakshmanan Y, Fung LC. Laparoscopic extravesicular ureteral reimplantation for vesicoureteral reflux: recent technical advances. *J Endourol*. 2000;14:589–93.
2. Olsen LH, Deding D, Yeung CK, Jorgensen TM. Computer assisted laparoscopic pneumovesical ureter reimplantation (am). Cohen: initial experience in a pig model. *APMIS Suppl*. 2003;109: 23–5.
3. Ramalingam M, Senthil K, Venkatesh V. Laparoscopic repair of ureterovaginal fistula: successful outcome by laparoscopic ureteral reimplantation. *J Endourol*. 2005;19:1174–6.

19.1 Introduction

Since the introduction of da Vinci robotic system (Intuitive Surgicals, Sunnyvale, CA, United States) in 1998, robot assisted laparoscopic surgery (RALS) has expanded its application in Urological practice with promising results. The technical advantages of RALS over pure laparoscopy are magnified (up to ten times) 3D vision, wristed instruments (robotic arms provide 7 degrees of movement as compared to 4 degrees of movement with laparoscopic instruments), tremor filtration and an ergonomic operation set-up which ultimately transform into safer operative procedure and so better patient outcomes.

Though RALS has proved its role in prostate and upper urinary tract surgery, (more than 80 % of radical prostatectomies and more than 40–50 % of partial nephrectomies are being done with RALS in the United States), its use in distal ureteric pathologies is gradually expanding. Open reconstructive techniques are considered the ‘gold standard’ for distal ureter due to limited literature on RALS for such procedures. However, few case reports and case series are available since 2008 on RALS. In this chapter we will describe the RALS techniques for distal ureter for various pathology. The aim is to describe technical points pertaining to RALS.

19.2 Indications

- **In paediatrics,**
 - Symptomatic, high grade vesico-ureteric reflux (VUR)
 - Congenital ureteric anomalies
- **In adults,**
 - Primary obstructive mega ureter.
 - Lower ureteric stricture of various etiologies
 - Lower ureteric injuries
 - Lower ureteric malignancy

19.3 Technique

- **PRE-OPERATIVE PREPARATION:**
Standard preanesthetic work up is done in all patients, according to the institution protocol. The urological imaging work up includes ultrasonography, Computed tomography, dynamic renal scan, micturating cysto-urethrogram (MCUG), Intravenous pyelogram, retrograde pyelogram etc, depending on the pathology. The study of these imaging should fetch the length, exact location and etiology, to select the appropriate procedure. Sterile urine culture is desirable. For adults, liquid diet and a proctoclysis enema on the previous night prior to surgery is the norm at our institute.
- **PATIENT POSITION AND PORT PLACEMENT:**
Position: For adults, steep Trendelenburg tilt with low lithotomy position on Allen stirrups with adequate padding of all pressure points and adequate fixation of the patient with operative table with straps is the standard. The steep trendelenburg position along with a relevant port placement (depending on the site of the pathology) will give us an opportunity to expose, dissect and reconstruct the extent of the ureter from 2–3 cm proximal to vessel crossing till vesico-ureteric junction. For children, legs can be kept apart and straight on the table with head to be turned on the side to avoid robotic arm hitting the endotracheal tube. Standard DVT prophylaxis is followed for adults by using sequential

R. Patel • A. Sivaraman (✉)
Apollo Hospitals, Chennai, India
e-mail: ananthsiv@gmail.com

compression device and body warmers used for both paediatric and adult patients to prevent hypothermia.

Endoscopy: Rigid/Flexible cystoscopy with guide-wire/ ureteric catheter placement is an optional step prior to the definitive procedure. The rationale is to assess the lower urinary tract and better identification of diseased ureter during dissection. Use of endoscopy is also suggested to decide the site of re-implantation.

19.3.1 Port Placement

Pneumoperitoneum is created with veress needle and Peritoneum is insufflated with CO₂ at 12–15 mmHg. In general, a standard robotic prostatectomy template with a slightly cephalad port placement is used. The cephalad port placement provides enough working space to complete the reconstructive part whatsoever require (It may include proximal/cranial mobilisation of the ureter, psoas hitch and boari flap reconstruction depending on the pathology). Standard ports are used (12 mm for camera and 8 mm robotic trocars for operative arm), though smaller ports (8 mm camera and 5 mm operative arm trocars available for da Vinci robotic Xi system) are an option for younger children, particularly for intravesical re-implantation. The camera port is placed above umbilicus in midline with two robotic operative arm ports are placed approximately 3–4 cm caudal and 8–9 cm lateral to camera port. Utilisation of third operative arm port is optional and to be placed on ipsilateral side of the pathology. For unilateral procedure, ipsilateral operative arm port is placed slightly cranial to the opposite side port to maintain triangulation. Two assistant ports each of 12 mm and 5 mm are used. Standard re-usable robotic instruments are used.

19.3.2 Surgical Technique

Procedure starts with incision of the peritoneum over iliac vessels and dissection around the common iliac vessel bifurcation. Ureter is identified and traced distally till the stricture/injury. Ureter is dissected, preserving the adventitial vascular plexus, which is clearly visible with the magnified 3D vision provided by the robot. Ureter is mobilized proximally if necessary for a tension free anastomosis. The fourth arm can be used for retraction of the bowel and peritoneum. Ureter is divided proximal to the stricture and spatulated on posterior aspect.

Retzius space is developed and bladder dropping done. Normal bladder, after mobilisation usually reaches proximal to vessel crossing which helps in tension free anastomosis and eases any additional procedure like psoas hitch and boari flap, in case the need arises. Bladder is filled with saline or air and opened near the dome obliquely.

We prefer refluxing anastomosis for (modified Lich-Gregoir) adults. Initial suture is taken at the apex of ureteric Spatulation and corresponding suture is taken in the bladder. 4-0 monocryl or PDS suture can be used. Both continuous and interrupted suturing can be used, depending on the surgeon's preference. We prefer continuous sutures. After placing the medial layer sutures, stent is placed and then the lateral layer sutures are continued. Anastomosis is checked for leaks after completion. Perivesical fat or a tag of omentum may be wrapped around to secure the anastomosis. Drain is placed. Supra pubic catheter is not essential.

19.3.3 Post-Operative Care

Drain is usually removed on second day if there is no leak and urethral catheter is removed by seventh to tenth day. Stent is removed by 4–6 weeks. Functional study is done at 3 months.

19.4 Outcomes

Kasturi et al. [1] has published their data on 150 patients who underwent extravesical robotic-assisted laparoscopic ureteral reimplantation (RALUR) (nerve-sparing) for primary VUR. The operative success rate was 99.3 % as evident by MCUG performed at 3 months. They concluded that bilateral nerve-sparing robotic-assisted extravesical reimplantation has the same success rate as the traditional open approaches, with minimal morbidity and no voiding complications. The robotic technology as compared to pure laparoscopy provides excellent visualization of nerves of pelvic plexus and helps its preservation which decreases post-operative voiding dysfunction. Akhavan et al. [2] has also demonstrated comparable success rate (92.3 %) for extravesical RALUR done for 78 ureters with primary VUR.

Isac et al. [3] published their retrospective study, comparing open and robotic assisted ureteroneocystostomy (RUNC). Twenty-five patients underwent RUNC with 41 patients who underwent open procedure. Their results showed shorter hospital stay, less narcotic use and less blood loss for robotic group as compared to open group. Median operative time was shorter in open group (200 vs 279 min) with no difference in reoperation rates. Recently, Fifer et al. [4] studied the data of 55 patients who underwent robotic ureteral reconstructive procedures and concluded that robotic platform is feasible, safe, effective and able to replicate techniques of open surgery with equivalent outcomes.

Gellhause et al. [5] published their retrospective multi-institutional data of patients who has undergone robotic assisted reconstructive procedures for lower urinary tract after iatrogenic injury during gynecological procedure. Total

49 procedures were done in 43 patients out of which majority were uretero-ureterostomy and UNC. They demonstrated a success rate of 95.9% for robotic assisted reconstructive procedure with complication rate of 6.1%. At our institution, we have a similar outcomes for gynecological injuries. We prefer early repair for ureteric injuries though complex genitor-urinary fistula repair will typically undergo surgery after 8–12 weeks. Apart from Gynecological injuries, majority of our adult cases comprise of distal ureteric strictures,

megaureters, ureteric obstruction due to cystitis cystica involving ureteric orifices etc.

19.5 Conclusion

Robot assisted laparoscopic ureteric reimplantation is almost equally effective as open approach with the added benefits of minimal access surgery.

Fig. 19.1 Patient and ports position

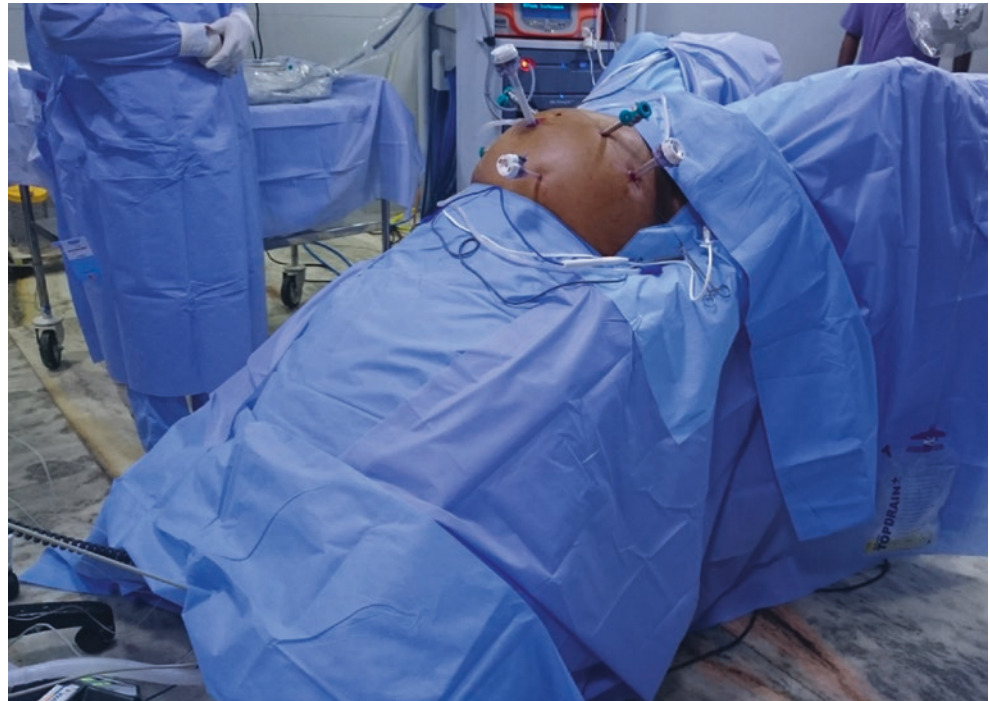
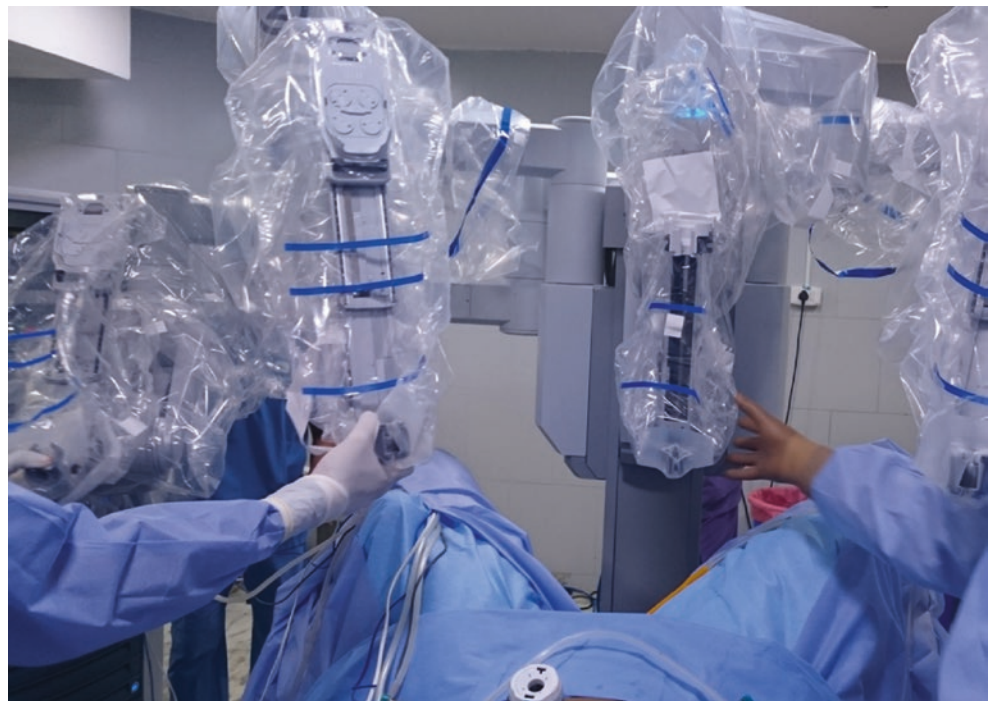
Fig. 19.2 Robot position between the thighs



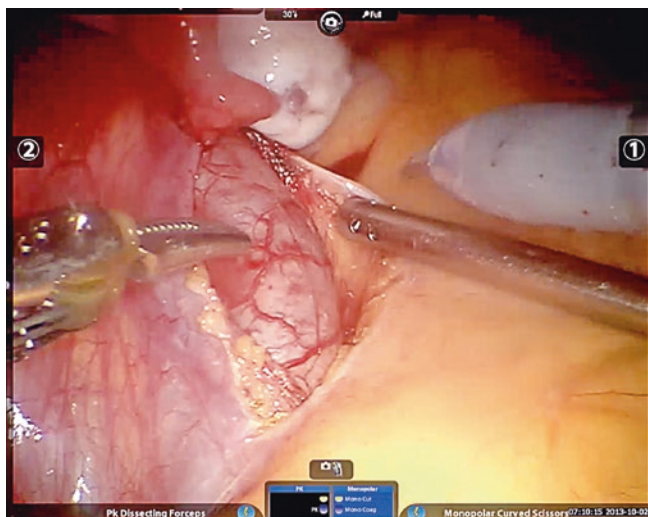


Fig. 19.3 Peritoneotomy done and ureter dissection started

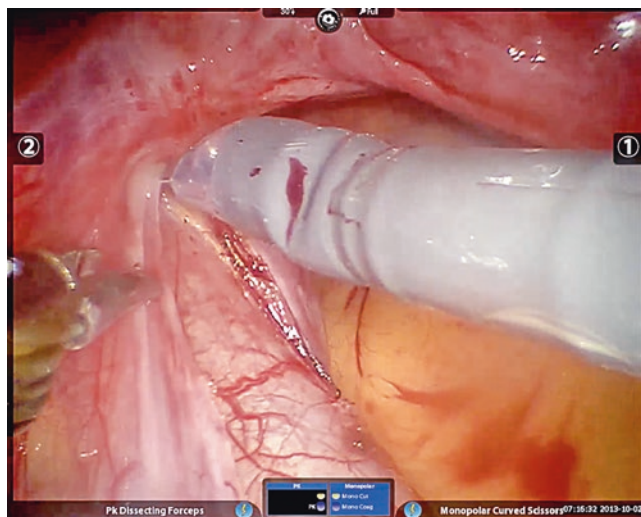


Fig. 19.4 Left Ureter dissection in progress

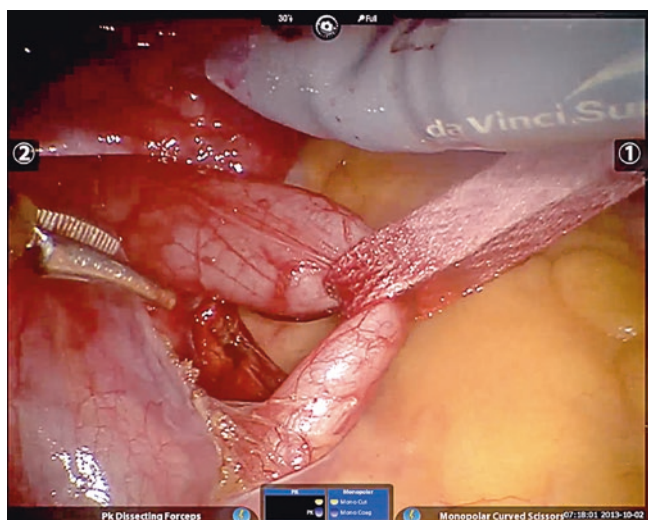


Fig. 19.5 Ureter looped

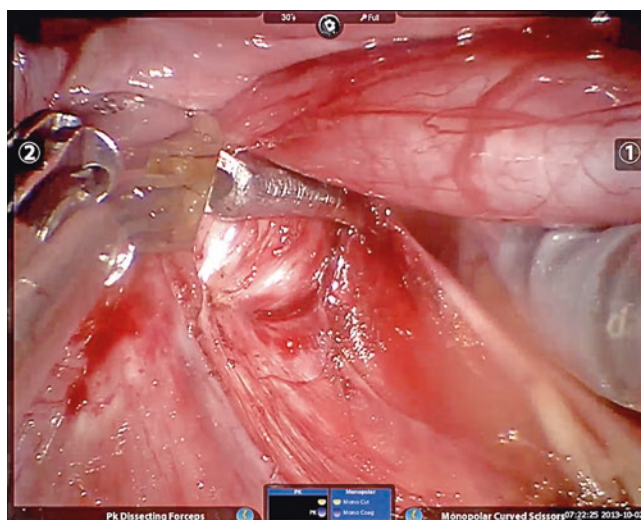


Fig. 19.6 Ureteric obstruction seen at the level of pelvic brim

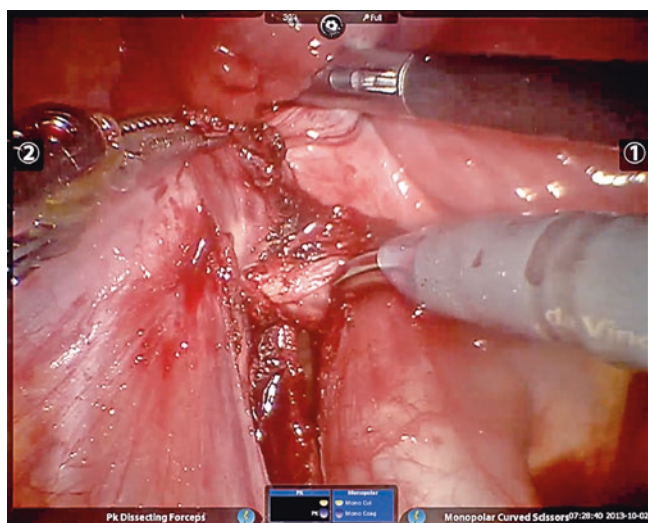


Fig. 19.7 Obstructed area of ureter being dissected

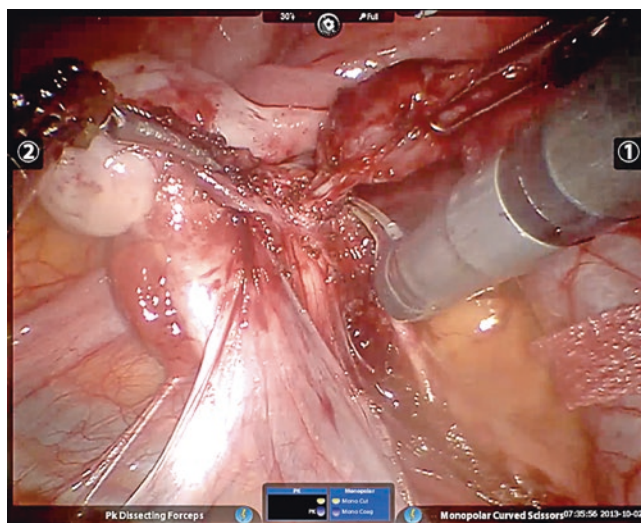


Fig. 19.8 Ureter divided proximal to obstruction

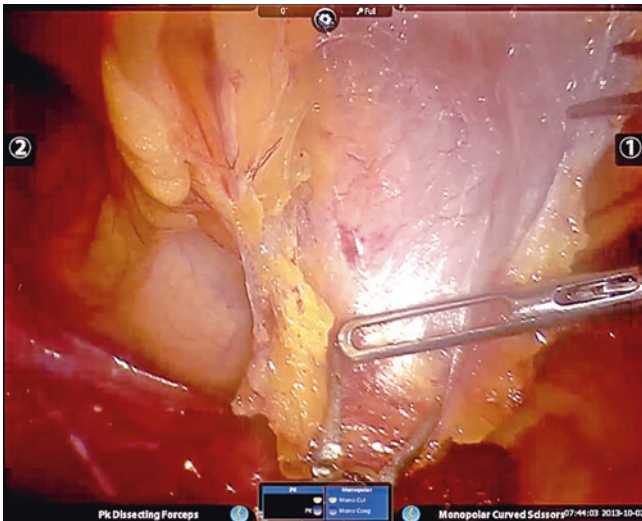


Fig. 19.9 Retzius space being developed

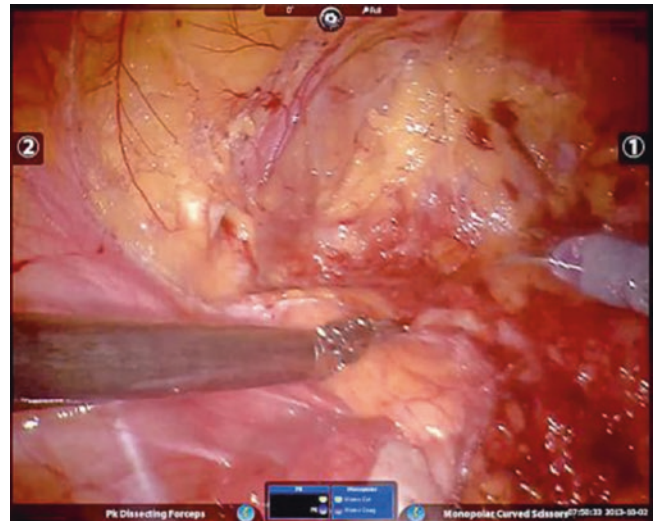


Fig. 19.10 Bladder completely dropped down

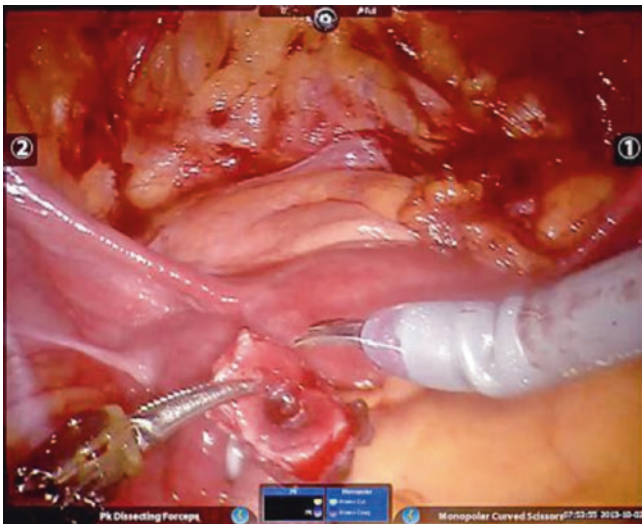


Fig. 19.11 Ureter spatulated

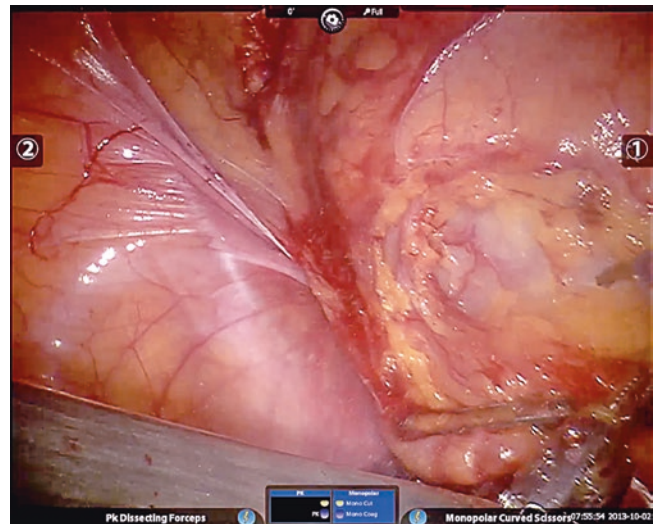


Fig. 19.12 Perivesical fat excised at the site of reimplantation

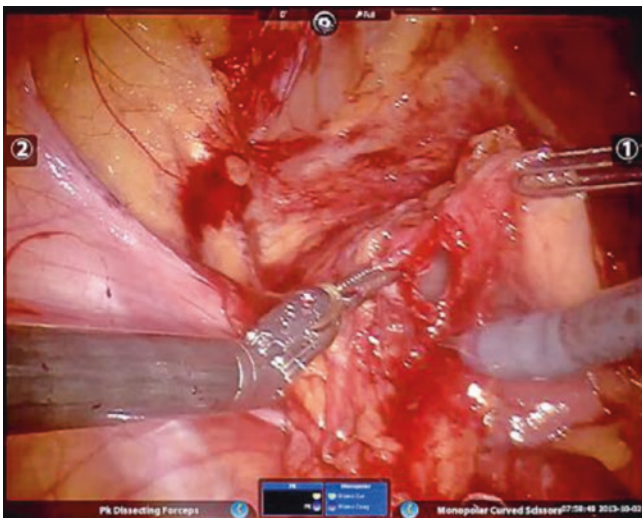


Fig. 19.13 Vesicotomy for reimplantation

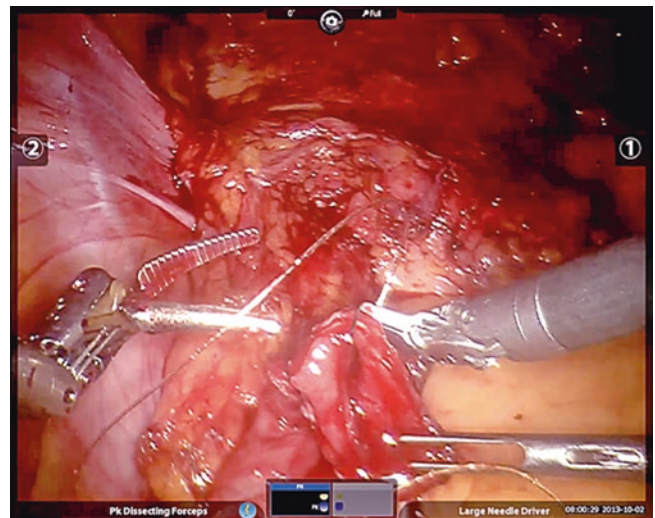


Fig. 19.14 Reimplantation started with initial bite through the spatulated end of ureter

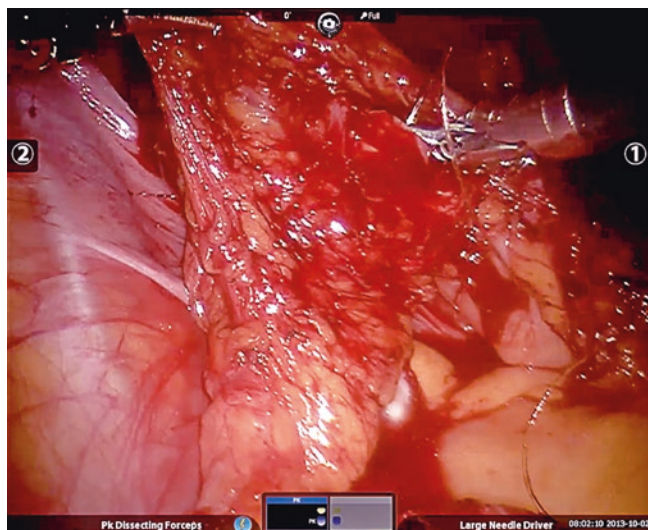


Fig. 19.15 Corresponding suture through bladder

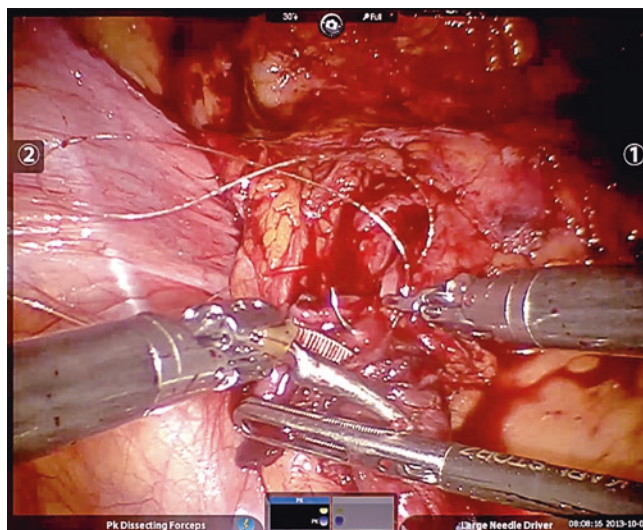


Fig. 19.16 Continuous suturing with 4-0 Monocryl in progress

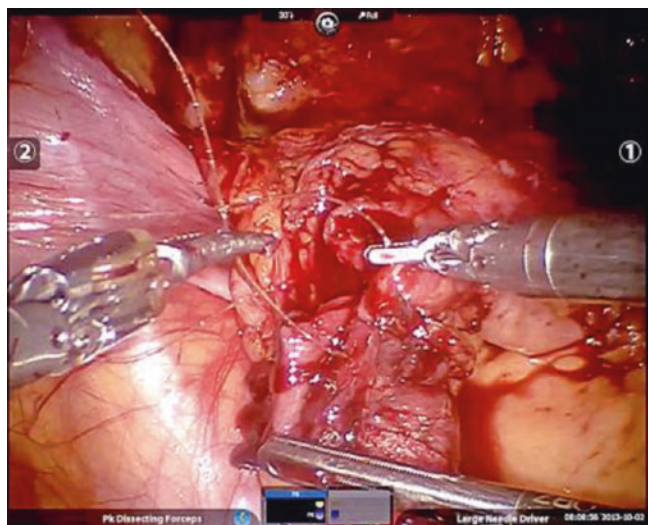


Fig. 19.17 Medial layer suturing in progress

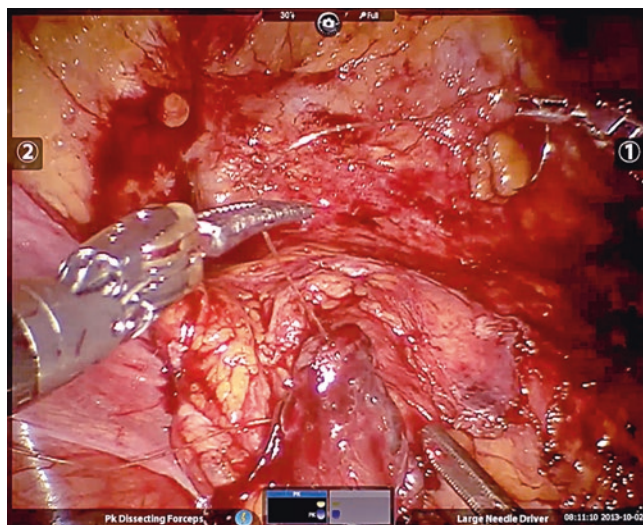


Fig. 19.18 Medial layer completed

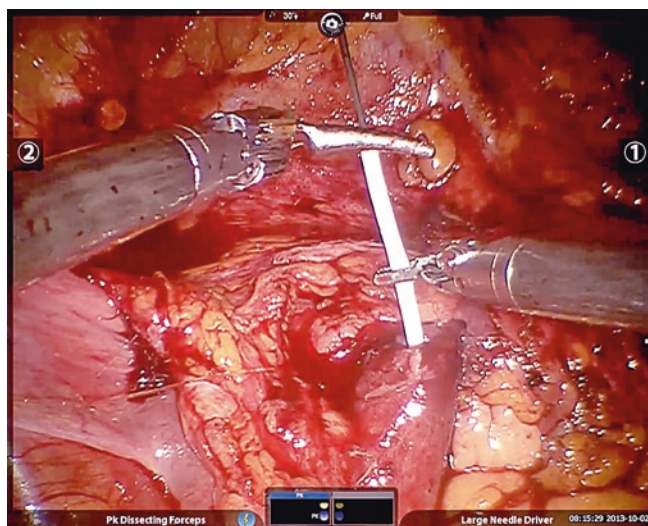


Fig. 19.19 Stent being inserted retrograde

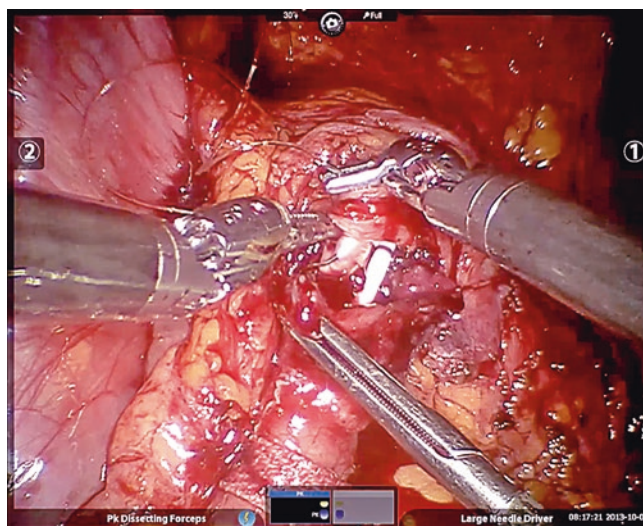


Fig. 19.20 Lateral layer suturing started

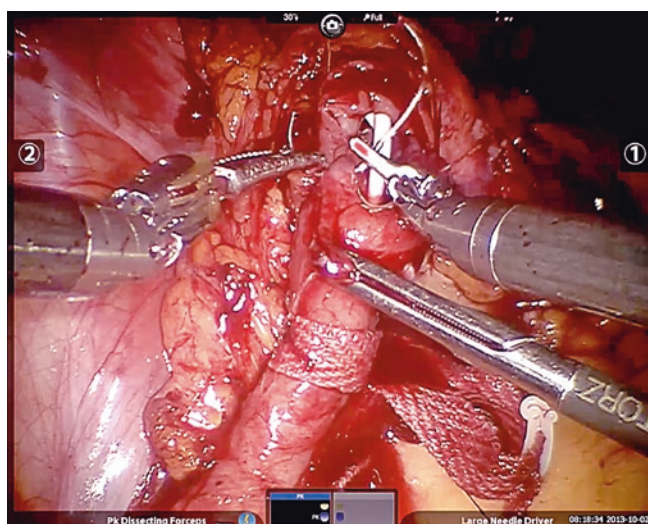


Fig. 19.21 Lateral layer suturing in progress

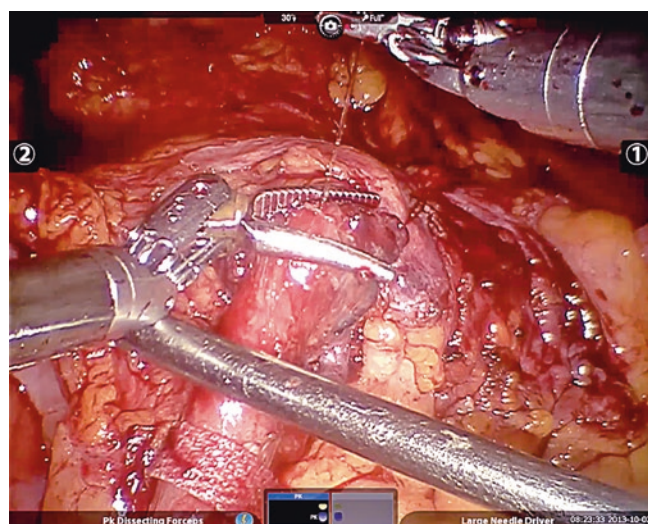


Fig. 19.22 Sutures completed

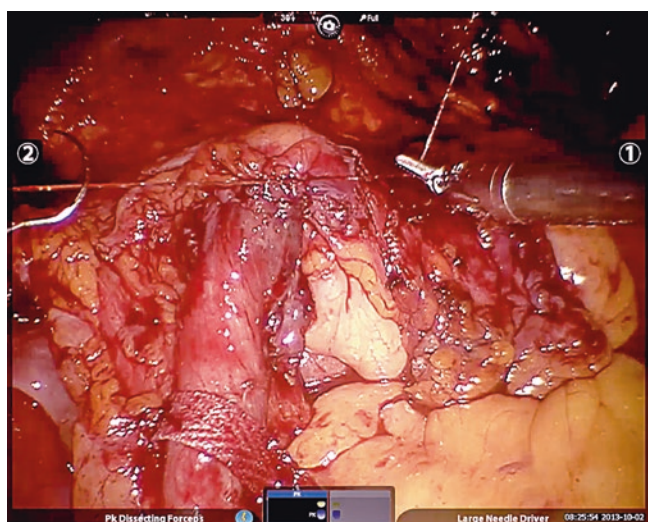


Fig. 19.23 Detrusorrhaphy completed with 2-0 monocryl suture

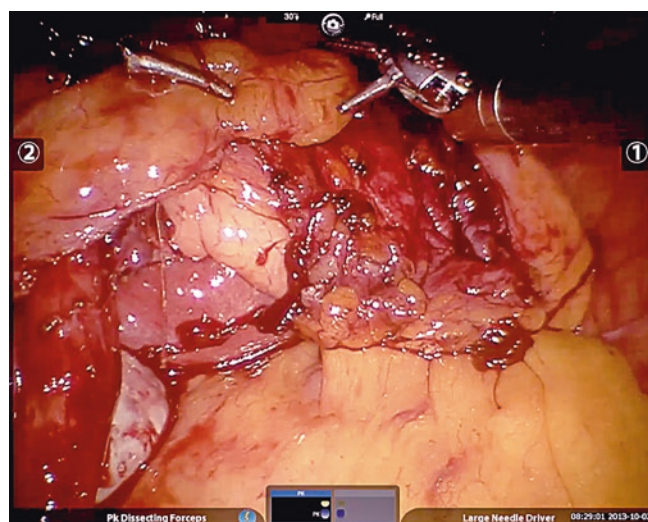


Fig. 19.24 Omental wrapping over anastomosis

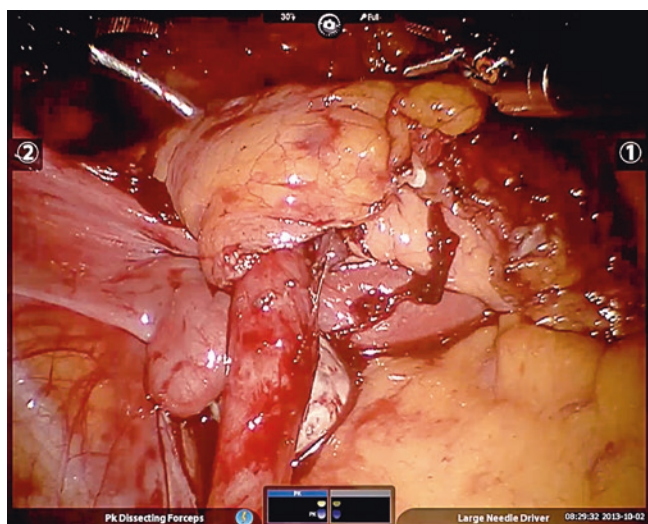


Fig. 19.25 Completed reimplantation

19.6 Robotic Psoas Hitch Uteric Reimplantation

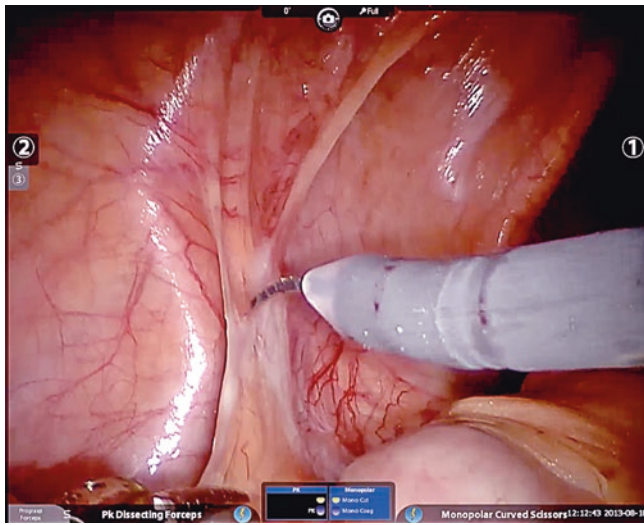


Fig. 19.26 Medialisation of sigmoid to enter retroperitoneum

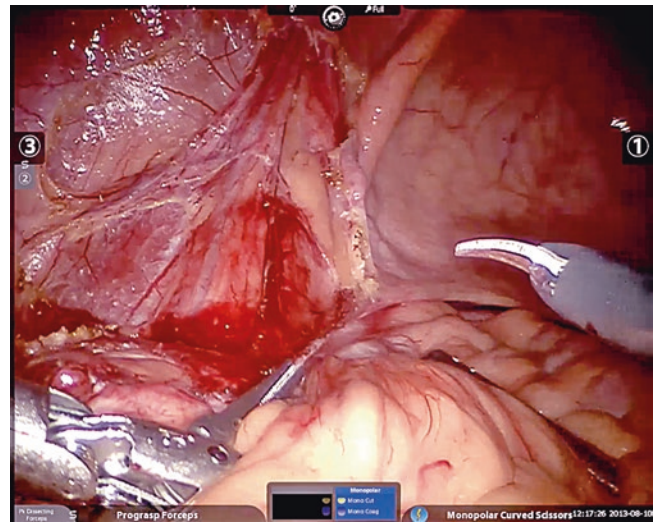


Fig. 19.27 Retroperitoneal dissection over the iliac vessels to identify ureter

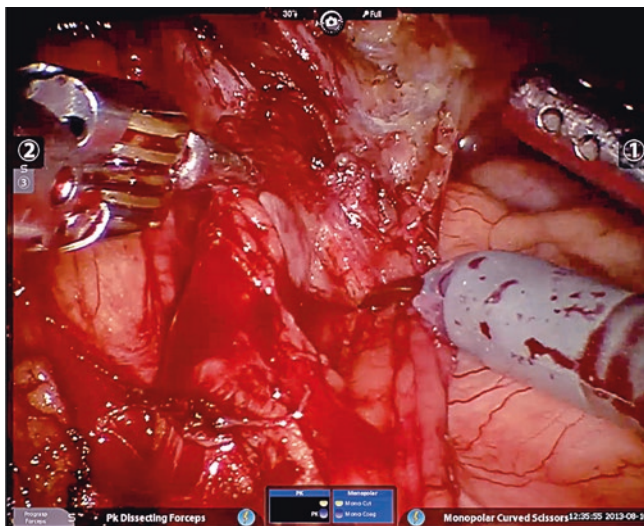


Fig. 19.28 Ureteric dissection in progress

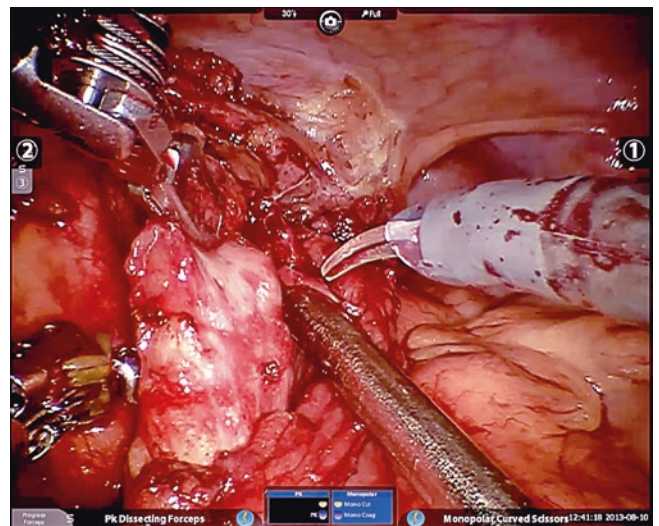


Fig. 19.29 Ureter being dissected from surrounding adhesions

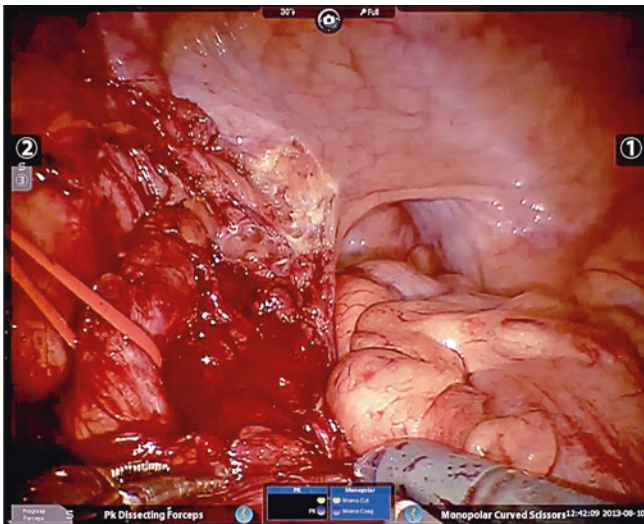


Fig. 19.30 Ureter looped

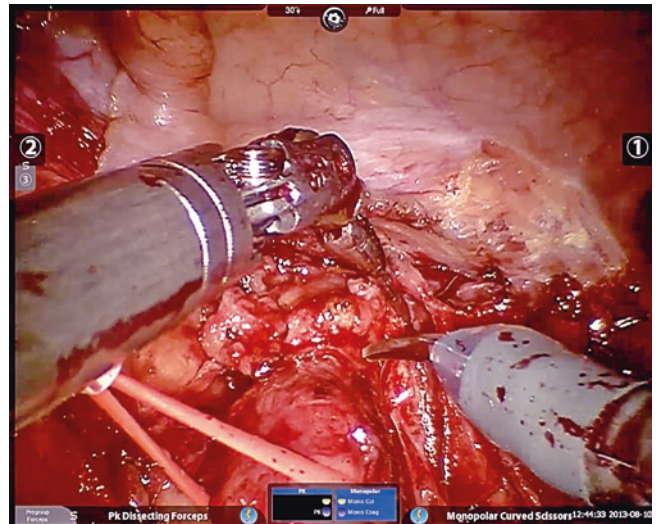


Fig. 19.31 Ureter being dissected distally, close to bladder

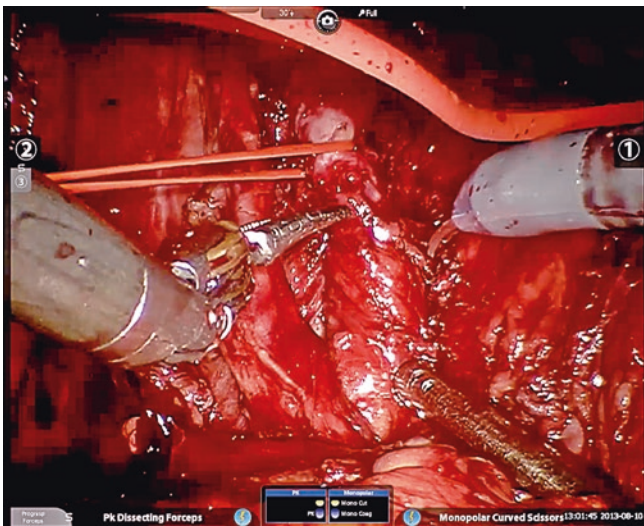


Fig. 19.32 Ureter being dissected proximally

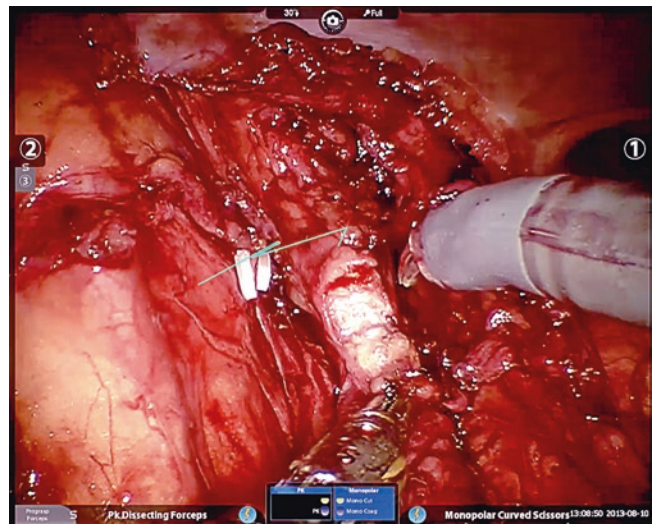


Fig. 19.33 Ureter being divided

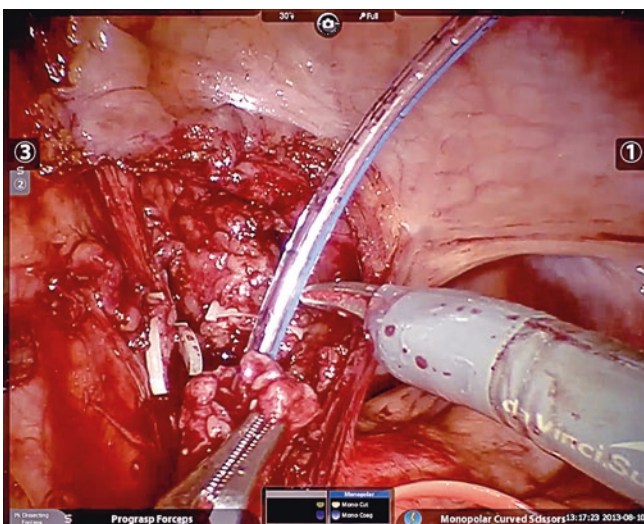


Fig. 19.34 Ureter completely divided and stent placed

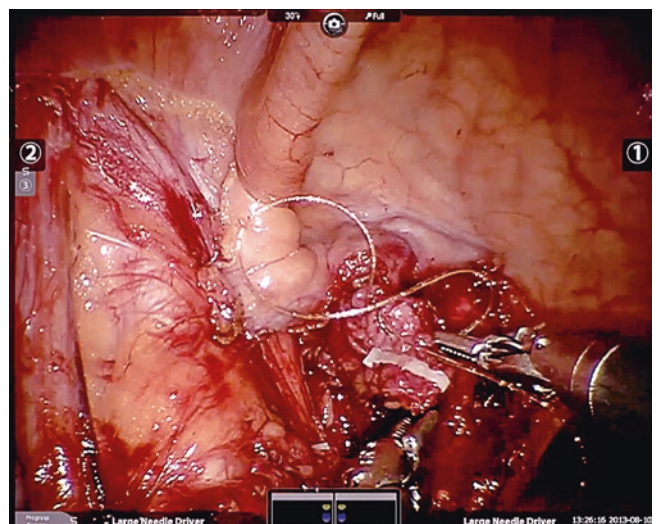


Fig. 19.35 Lower end of ureter being clipped and transfixed

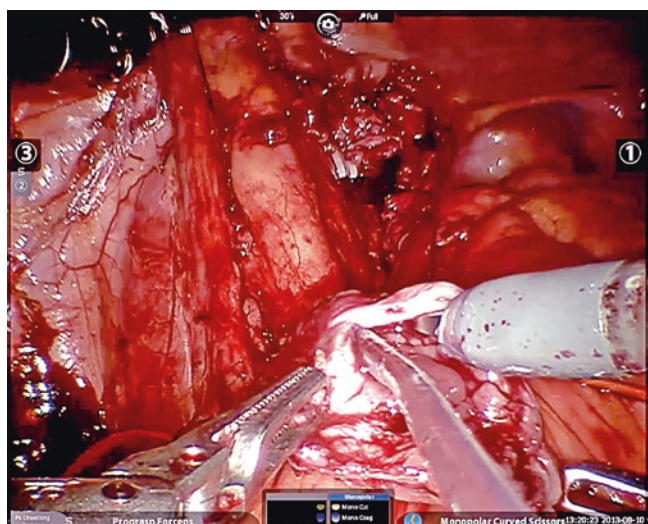


Fig. 19.36 Ureter spatulated

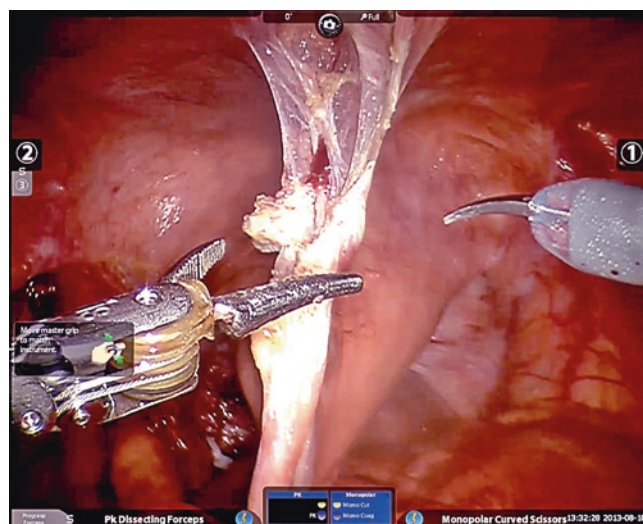


Fig. 19.37 Bladder dropped down

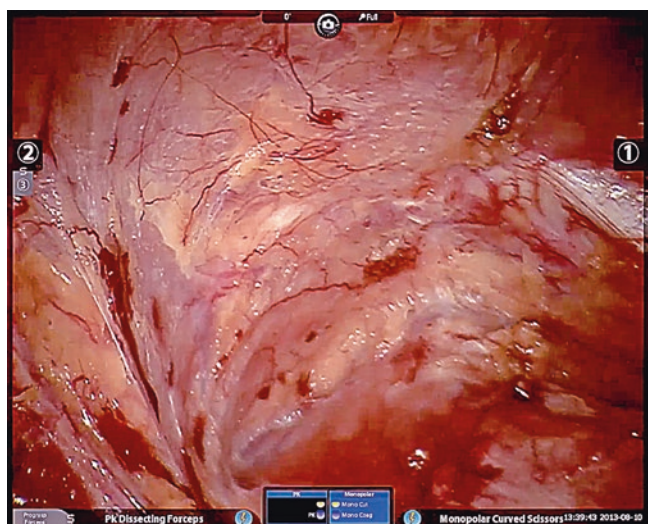


Fig. 19.38 Retzius space fully developed

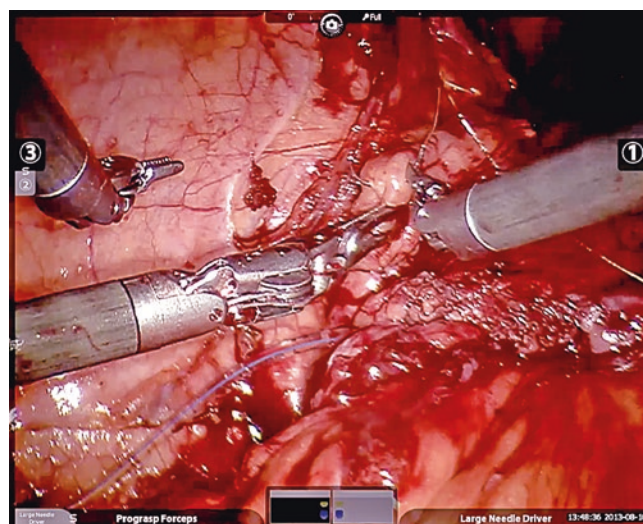


Fig. 19.39 Bladder bite for psoas hitch

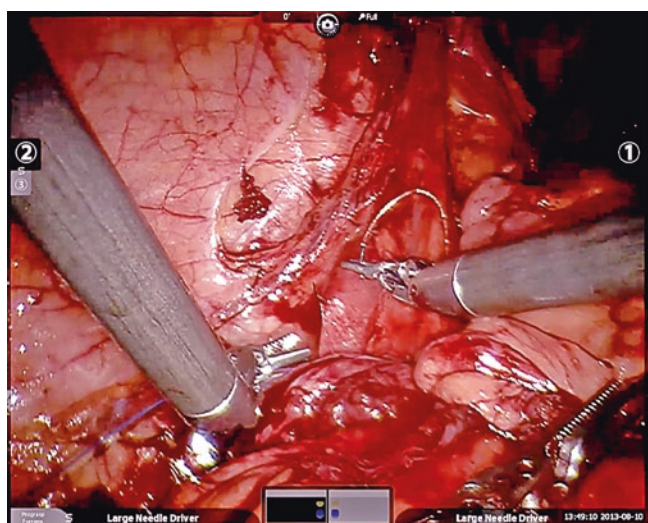


Fig. 19.40 Bite through psoas

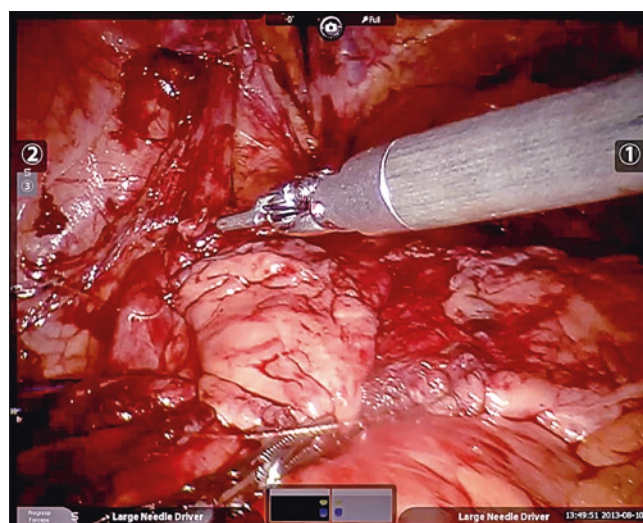


Fig. 19.41 Psoas hitch with 3-0 vicryl in progress

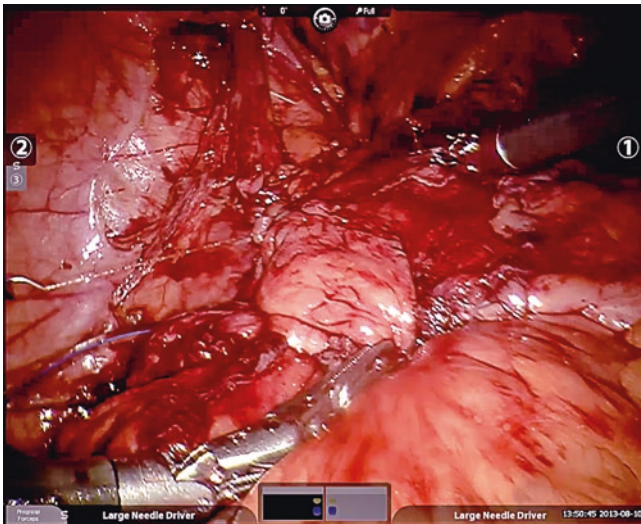


Fig. 19.42 Psoas hitch in place

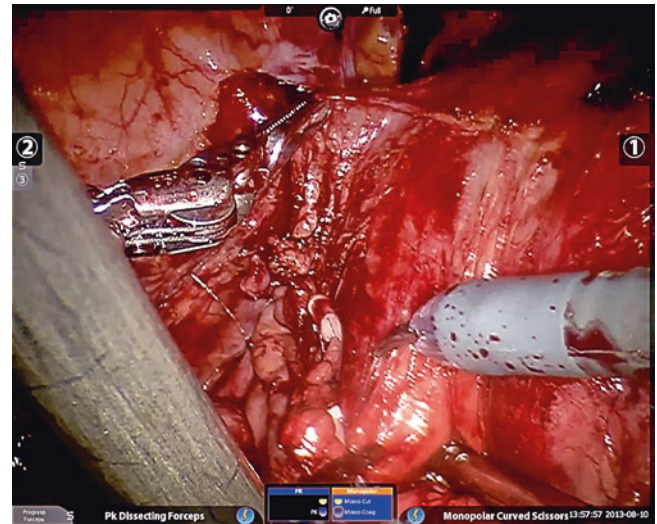


Fig. 19.43 Perivesical fat cleared

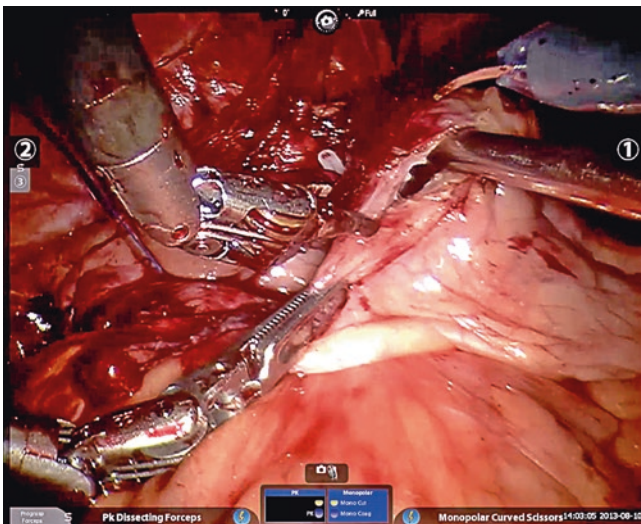


Fig. 19.44 Vesicotomy being done

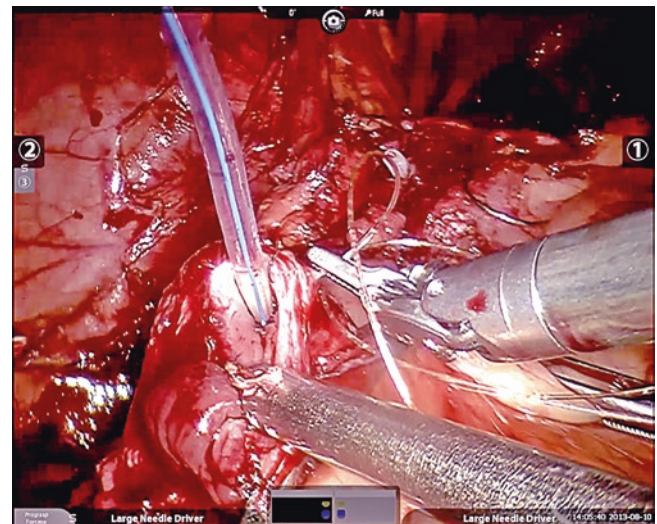


Fig. 19.45 Reimplantation started with initial bite through the ureter using double armed PDS suture

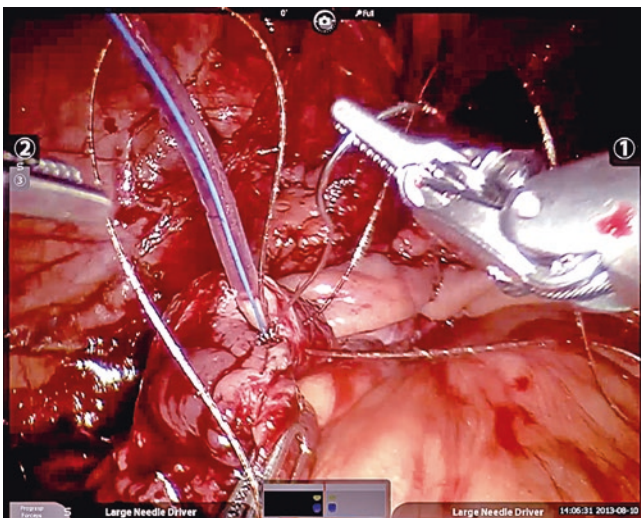


Fig. 19.46 Second needle passed through the ureter

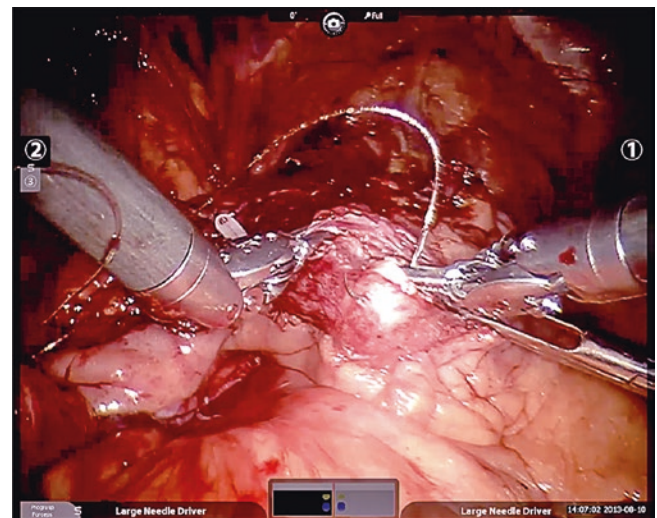


Fig. 19.47 Initial bite through the bladder

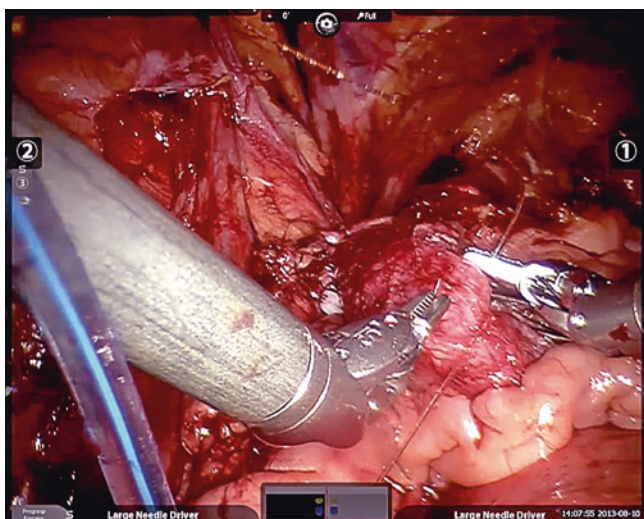


Fig. 19.48 Lateral layer suturing in progress

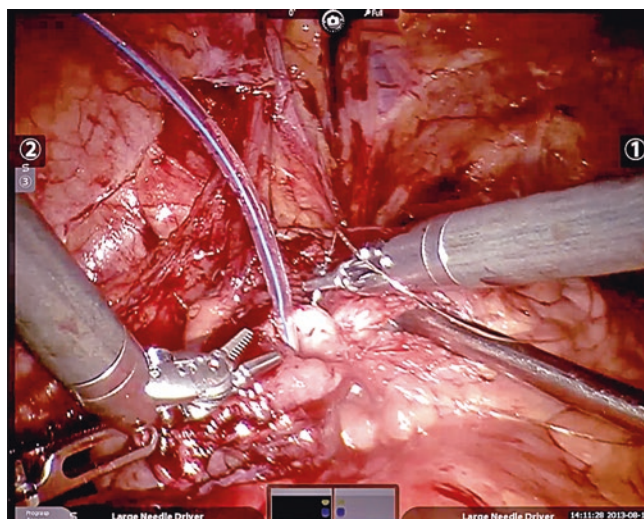


Fig. 19.49 Lateral layer suturing in progress

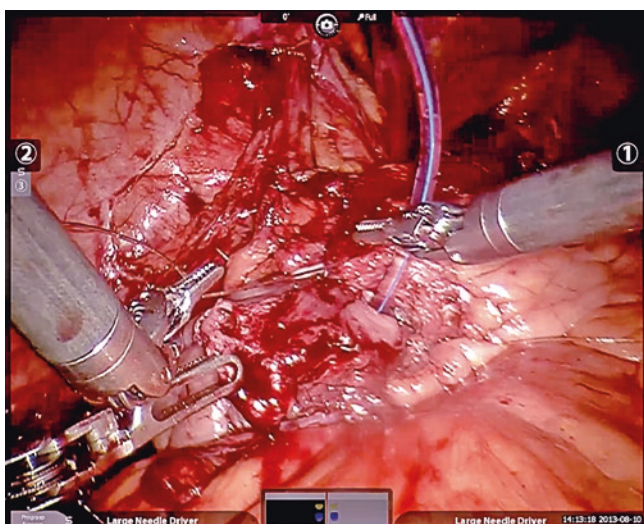


Fig. 19.50 Lateral layer suturing completed

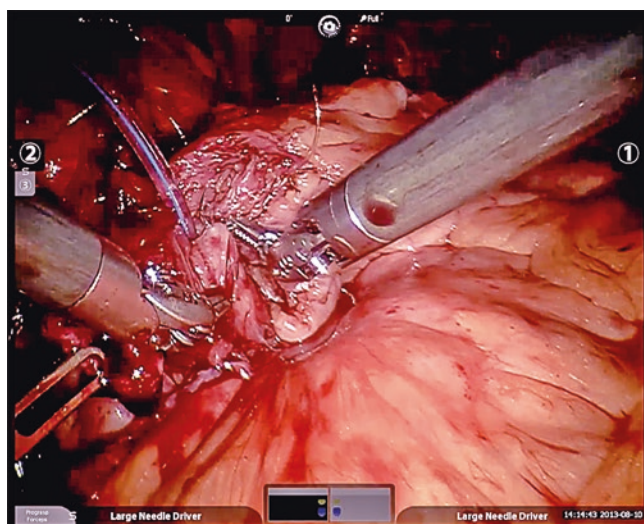


Fig. 19.51 Medial layer suturing started

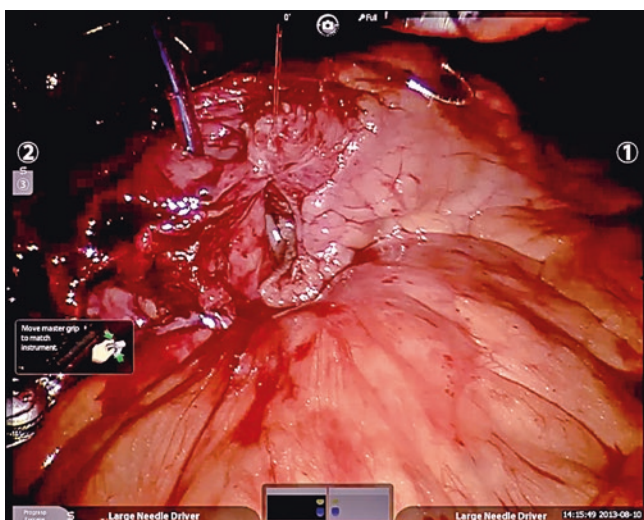

Fig. 19.52 Medial layer suturing in progress

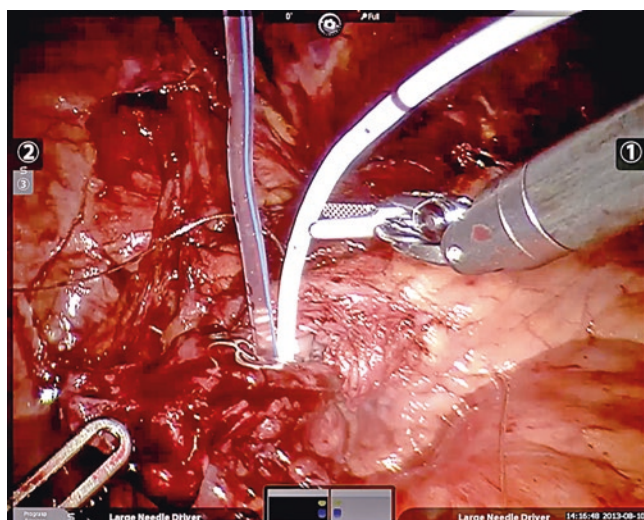


Fig. 19.53 Stent insertion in progress

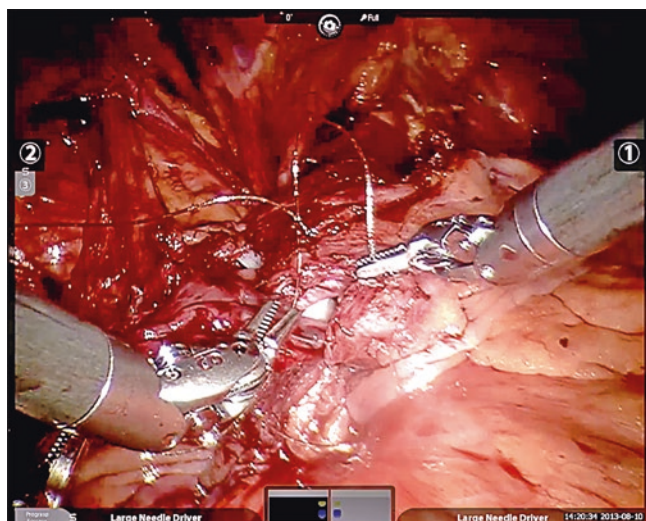


Fig. 19.54 Medial layer suturing continued

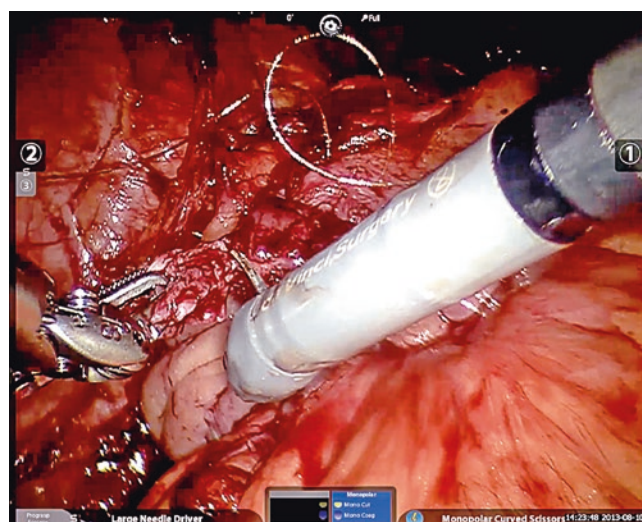


Fig. 19.55 Redundant uterine margin excised

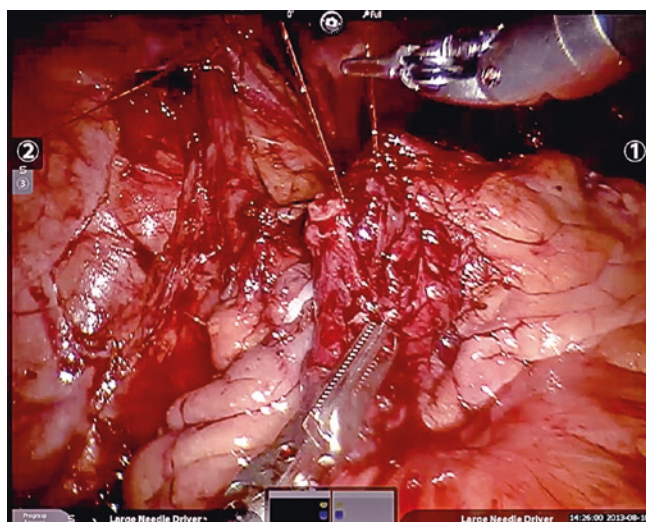


Fig. 19.56 Medial and lateral sutures completed

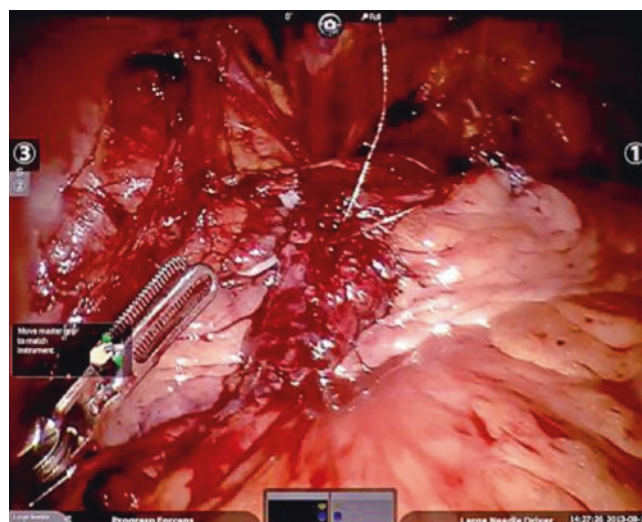


Fig. 19.57 Reimplantation completed

References

1. Kasturi S, Sehgal SS, Christman MS, et al. Prospective long-term analysis of nerve-sparing extravesical robotic-assisted laparoscopic ureteral reimplantation. *Urology*. 2012;79:680–3.
2. Akhavan A, Avery D, Lendvay TS. Robot-assisted extravesical ureteral reimplantation: outcomes and conclusions from 78 ureters. *J Pediatr Urol*. 2014;10:864.
3. Isac W, Kaouk J, Altunrende F, et al. Robot-assisted ureteroneocystostomy: technique and comparative outcomes. *J Endourol*. 2013;27(3):318–23.
4. Fifer GL, Raynor MC, Selph P, et al. Robotic ureteral reconstruction distal to the ureteropelvic junction: a large single institution clinical series with short-term follow up. *J Endourol*. 2014;28(12):1424–8.
5. Gellhaus PT, Bhandari A, Monn MF, et al. Robotic management of genitourinary injuries from obstetric and gynaecological operations: a multi-institutional report of outcomes. *BJU Int*. 2015;115:430–6.

Manickam Ramalingam, Kallappan Senthil,
and Anandan Murugesan

20.1 Introduction and Indication

Boari flap is an useful option for the management of long lower ureteric strictures [1–4, 6, 7]. Success of the procedure depends on the construction of a well vascularised bladder flap with a length to width ratio [5] of 4:3. All the steps of open surgery can be replicated by laparoscopy. Preliminary IVU or CT urogram and cystoscopy are essential to rule out any intravesical pathology.

20.2 Surgical Techniques

Cystoscopy and retrograde pyelogram helps in assessing bladder capacity and the length of the stricture respectively. This helps in deciding the flap. Optimum sized foley catheter is introduced and kept sterile in an accessible area for distending the bladder whenever needed.

Patient is positioned supine with the side of lesion elevated up by 45° so that the bowel falls away from the dissection area. Camera port (10 mm) is placed in the supraumbilical region. Three additional 5 mm ports (lateral to rectus muscle on each side and one in suprapubic area) are inserted for hand instruments.

The narrowed segment of distal ureter is mobilised, excised and sent for biopsy. Feasibility of direct reimplantation of

ureter (using psoas hitch) is always considered before deciding on a Boari flap. The length of the defect is assessed using ureteric catheter and the required length of Boari flap (width of 6 cm at the base and 4 cm at the tip and length as needed for the ureter), is marked on the bladder using diathermy. Subsequently the flap can be raised using electrocautery or preferably ultracision. The end of the flap is anastomosed to the spatulated ureter using interrupted 4-0 vicryl sutures. Then a 6 Fr double pigtail stent is passed through the suprapubic port into the ureter and its lower end is placed in the bladder. The flap can be tubularised and sutured in two layers, with continuous 4-0 vicryl for the inner layer, (mucosa and a part of the detrusor) and interrupted 3-0 vicryl sutures for the outer layer. The bladder defect should be closed from lateral to medial in two layers as above or with single layer using 3-0 barbed suture. Omental wrapping can be done over the flap. Tube drain is placed through the pararectus port.

20.3 Comment

As we gain confidence in intracorporeal laparoscopic suturing, such reconstructive procedures are feasible. Even though it is time consuming, morbidity is low. Laparoscopic surgery is now evolving into a preferred approach for such advanced reconstructive urological surgeries.

M. Ramalingam
PSG Hospitals,
Coimbatore, India
e-mail: uroram@yahoo.com

K. Senthil (✉)
Urology Clinic, Gowtham annexe, Coimbatore, India
e-mail: senthilsatya@hotmail.com

M. Anandan
Department of Urology, PSG Institute of Medical Sciences
and Research, Peelamedu, Coimbatore, Tamil Nadu, India
e-mail: anandan79@gmail.com

20.4 Laparoscopic Boari Flap Ureteric Reimplantation

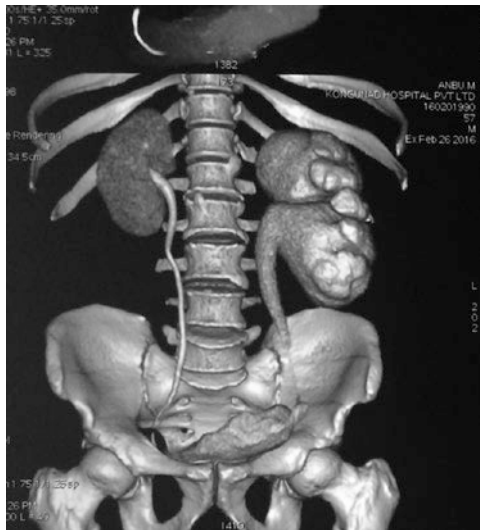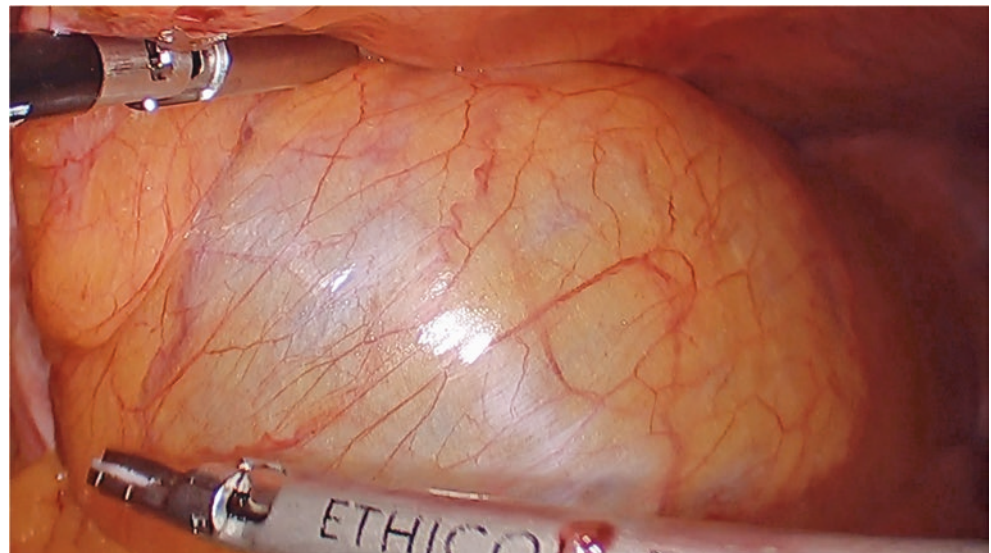


Fig. 20.1 CT cystogram showing long segment ureteric narrowing on left side

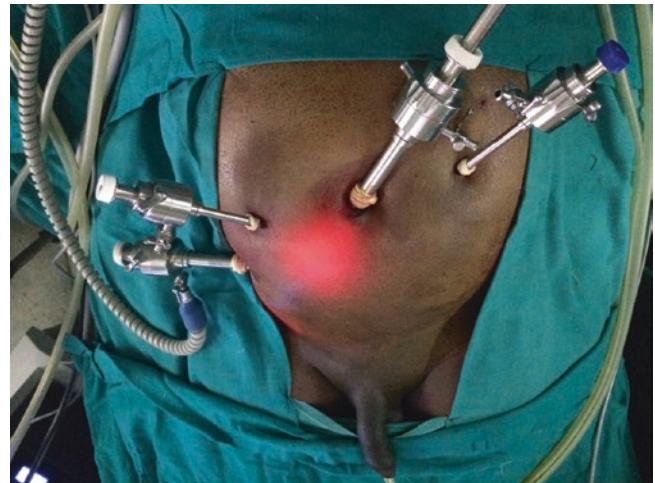

Fig. 20.2 Ports position (note the port on the left side is more cranial)

Fig. 20.3 Initial view of distended bladder



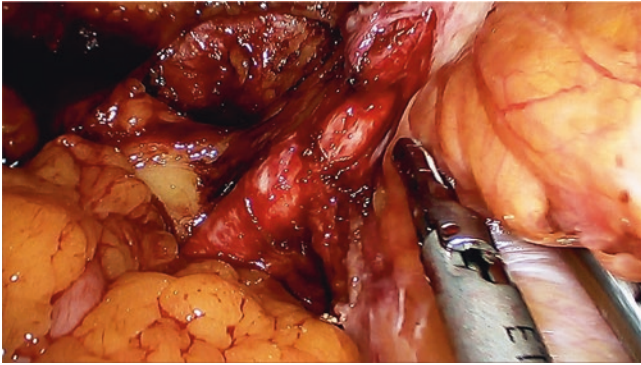


Fig. 20.4 Ureter seen lateral to bladder

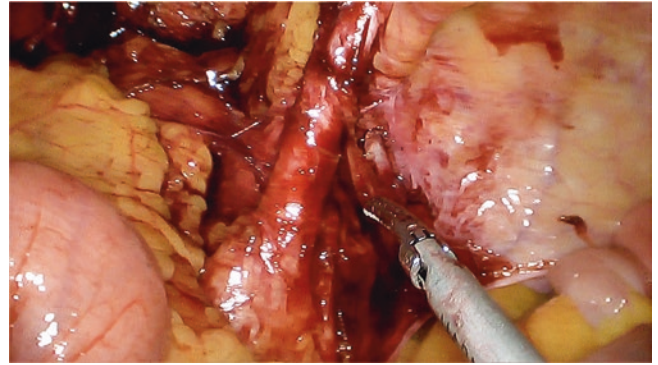


Fig. 20.5 Dilated ureter and strictured narrow ureter seen

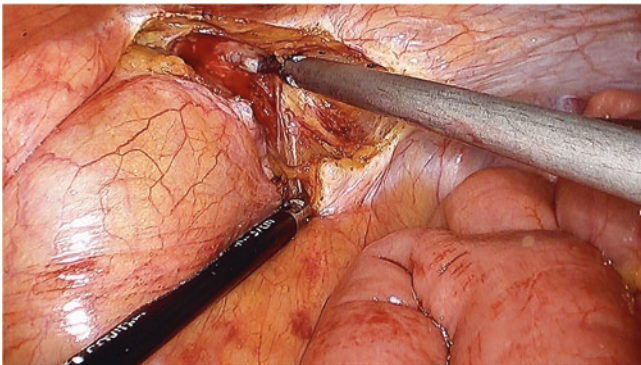


Fig. 20.6 Bladder being dropped down

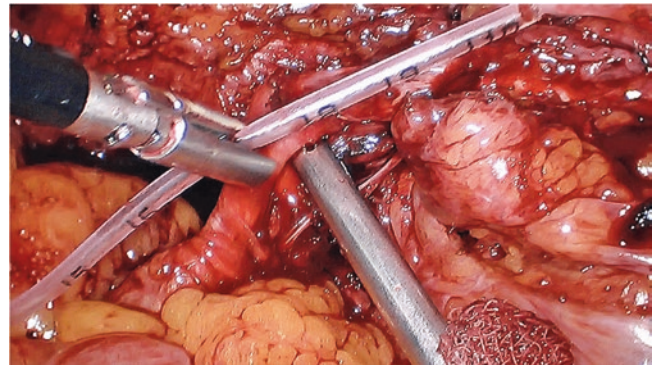


Fig. 20.7 Measurement of ureteric defect with infant feeding tube

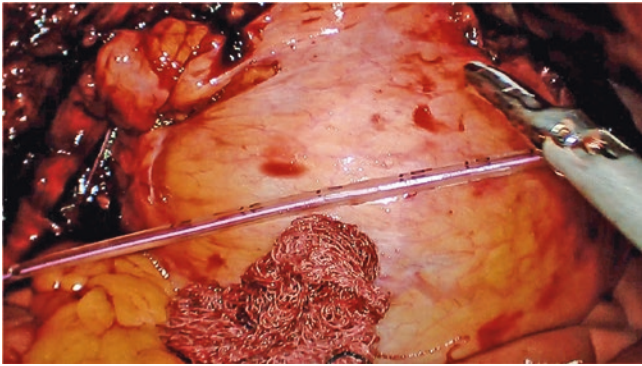


Fig. 20.8 Corresponding length of flap measured over the bladder

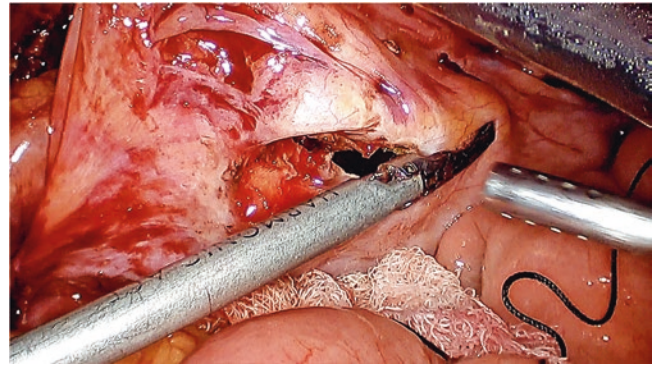


Fig. 20.9 Flap creation in progress

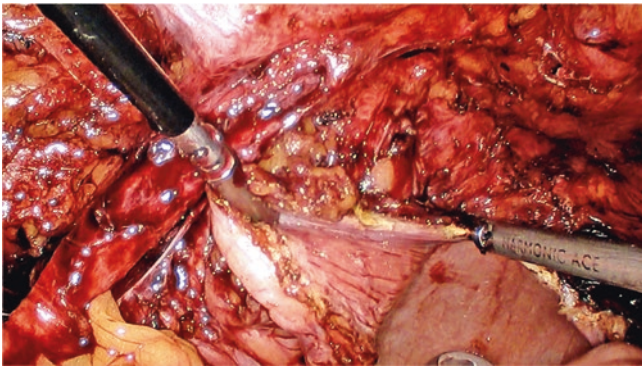


Fig. 20.10 Flap creation in progress

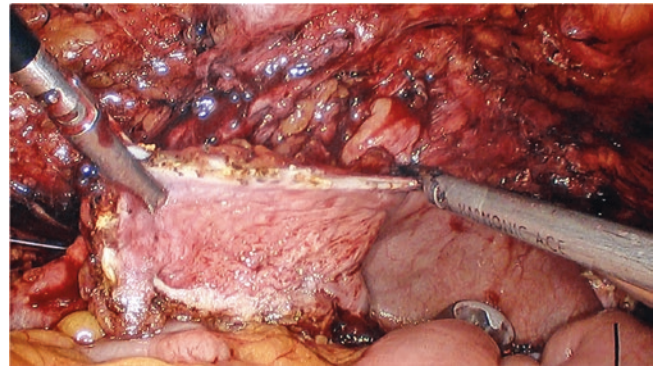


Fig. 20.11 Flap creation almost complete

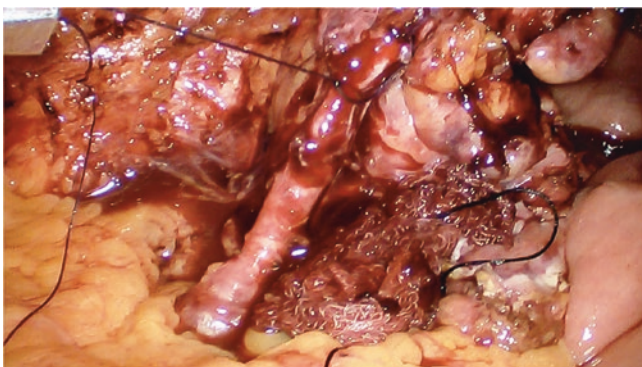


Fig. 20.12 Ureter ligated close to bladder

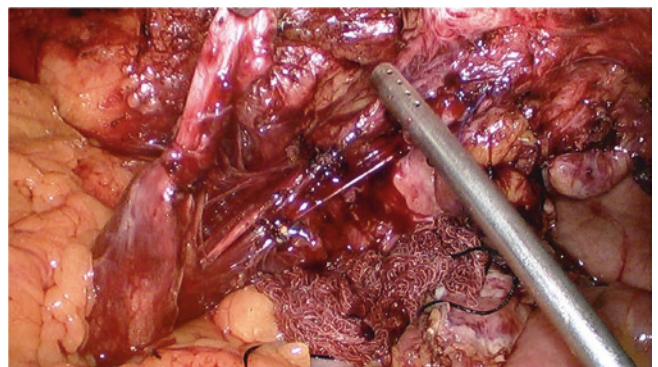


Fig. 20.13 Junction of dilated ureter and strictured ureter seen

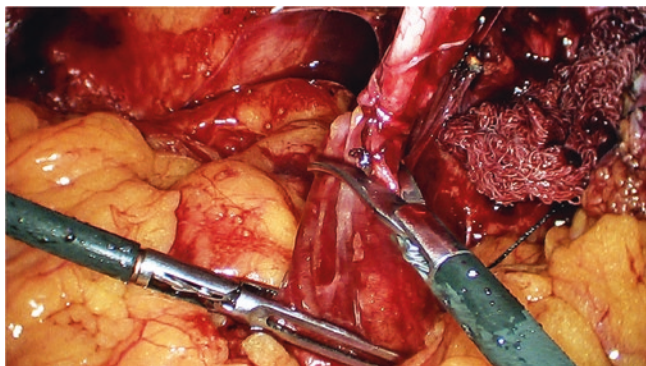


Fig. 20.14 Ureter being divided proximal to narrow segment

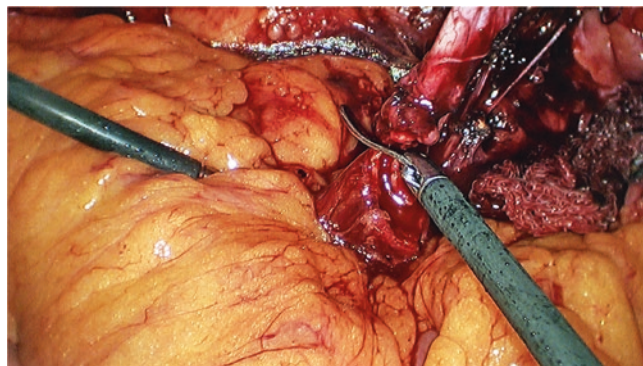


Fig. 20.15 Ureter division complete

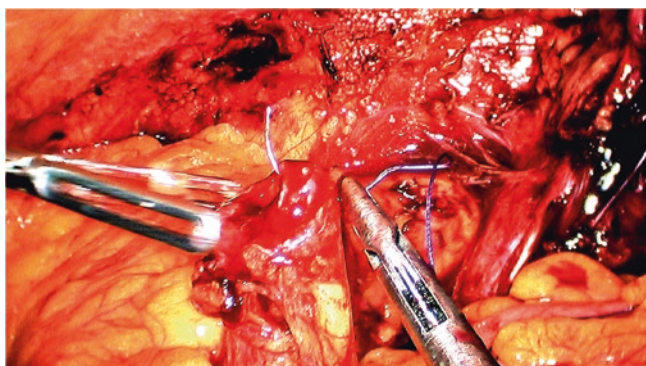


Fig. 20.16 Initial suture outside – in with 3-0 vicryl through the dilated ureter

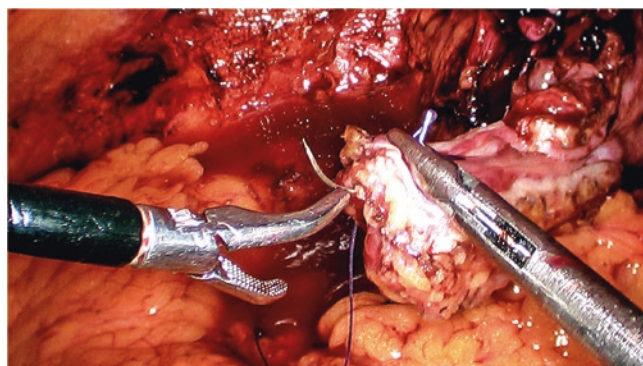


Fig. 20.17 Corresponding suture inside- out through the apex of the boari flap

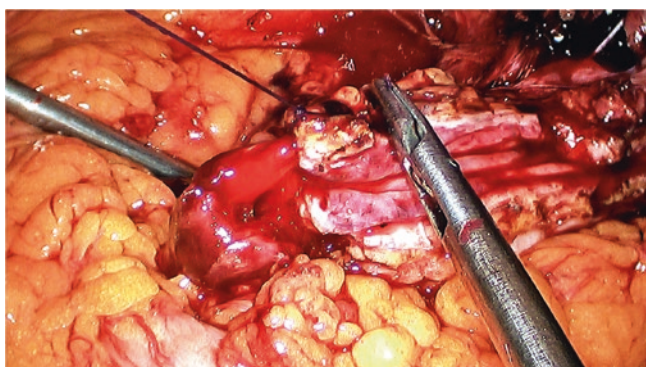


Fig. 20.18 Apical suture in place

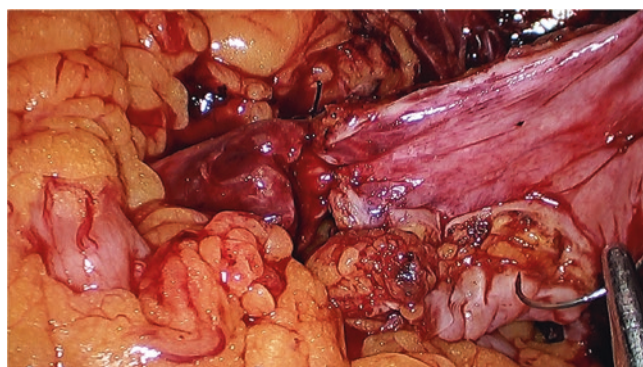


Fig. 20.19 Posterior layer interrupted suturing of flap and ureter in progress

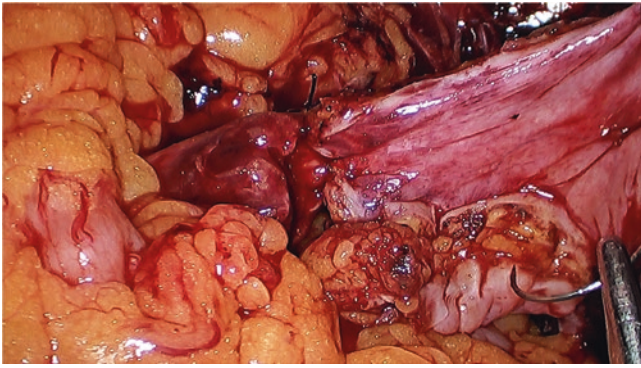


Fig. 20.20 Posterior layer suture completed

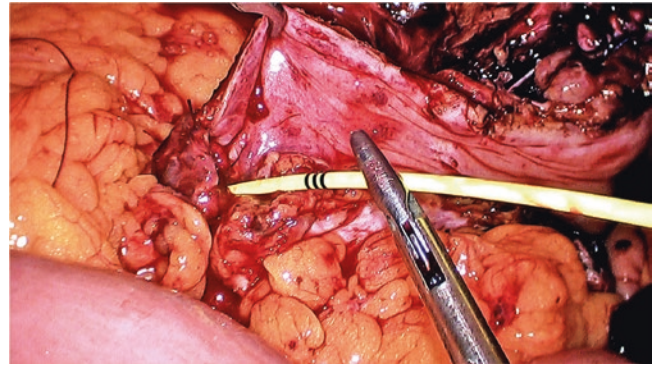


Fig. 20.21 Stent being inserted retrograde

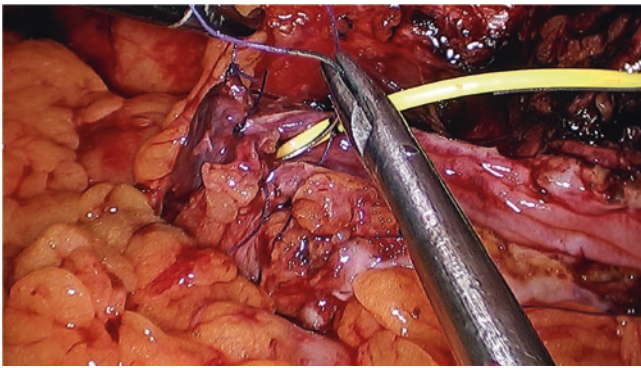


Fig. 20.22 Anterior layer suturing in progress

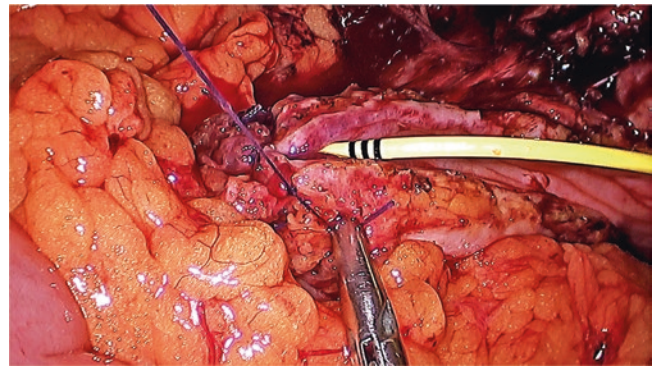


Fig. 20.23 Anterior layer suturing complete

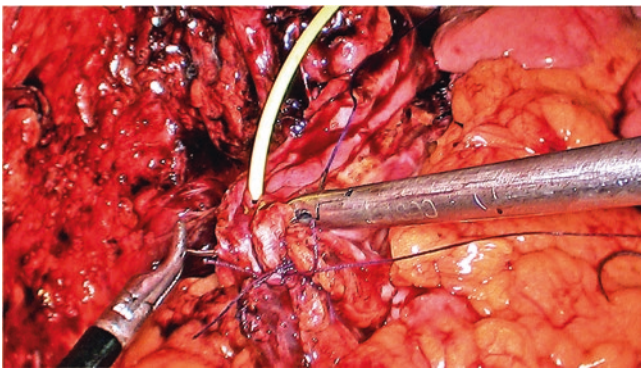


Fig. 20.24 Flap tubularisation with 2-0 vicryl started

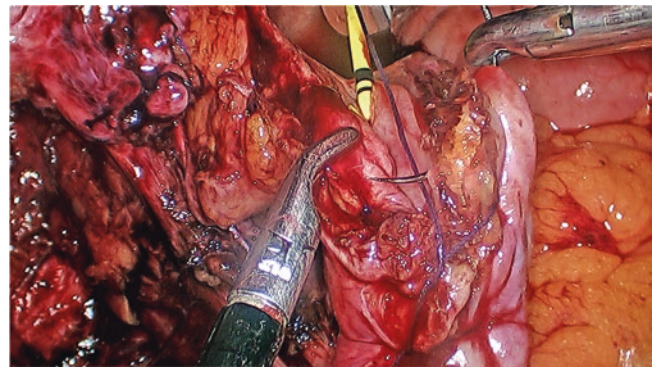


Fig. 20.25 Flap tubularisation as continuous suture in progress

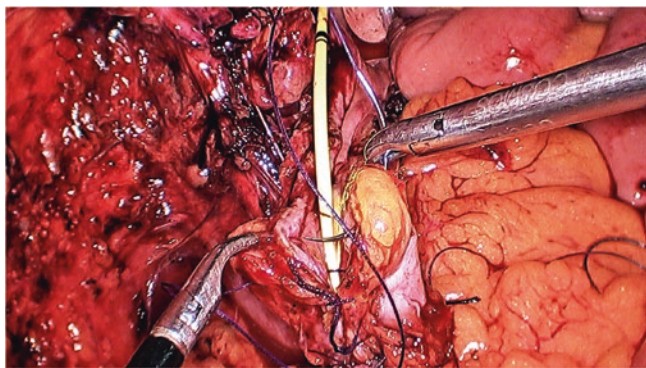


Fig. 20.26 Flap tubularisation in progress

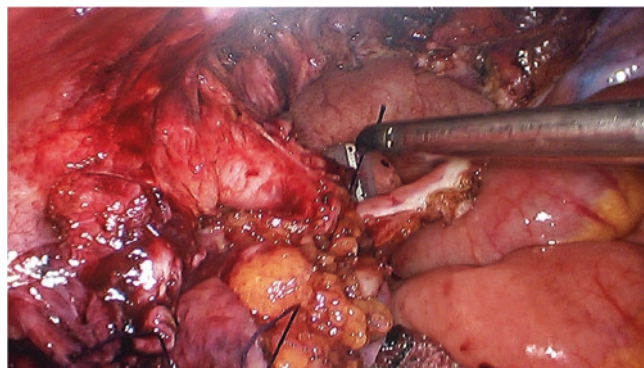


Fig. 20.27 Flap tubularisation completed and bladder defect being closed

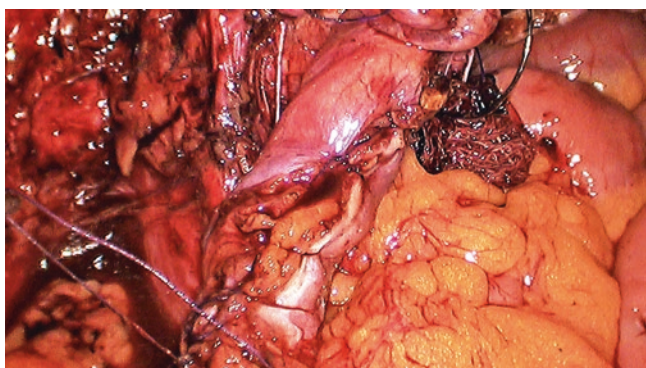


Fig. 20.28 Bladder closure completed

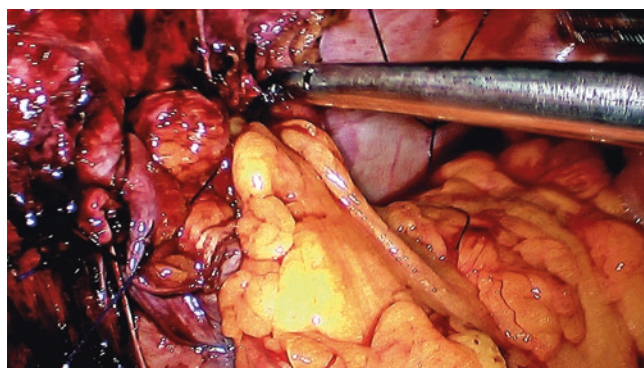


Fig. 20.29 Omental wrapping done

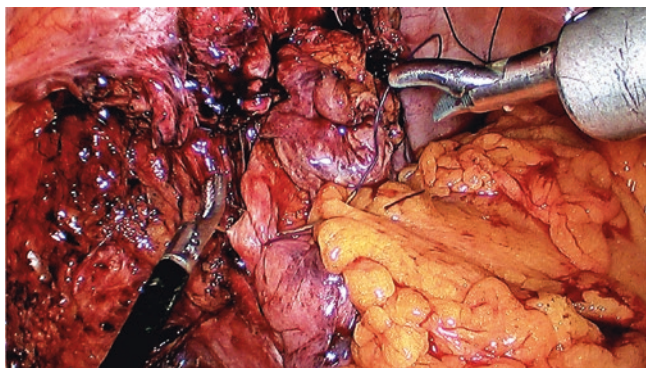


Fig. 20.30 Omentum tacked onto sutural line

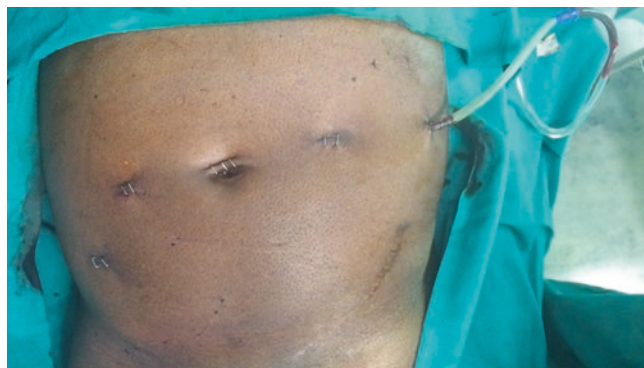

Fig. 20.31 Drain placed

References

1. Boari A. Chirurgia dell ureter, con pretazienze de Dott: I. Albarran, 1, 900 contribute sperementale alla aplastica delle uretere. Atti Accad Med Ferrara. 1894;14:444.
2. Fergany A, Gill IS, Abdel-Samee A, Kaouk J, Meraney A, Sung G. Laparoscopic bladder flap ureteral reimplantation: survival porcine study. J Urol. 2001;166(5):1920.
3. Fugita OE, Dinlenc C, Kavoussi L. The laparoscopic Boari flap. J Urol. 2001;166(1):51–3.
4. Kaouk JH, Gill IS. Laparoscopic reconstructive urology. J Urol. 2003;170:1070–8.
5. Pai MG, Kaseroro EM, Phillip PJ. Use of bladder flap in reconstruction of lower third of ureter: East African. Med J. 1976;53–6: 314–9.
6. Ramalingam M, Senthil K, et al. Laparoscopic Boari flap reimplantation (Abstract). J Endourol. 2004;18:A195.
7. Ramalingam M, Selvarajan K, Senthil K, Pai MG. Laparoscopic Boari flap repair – report of 3 cases. J Laparoendosc Adv Surg Tech published. 2008;18(2):271–5.

Anandan Murugesan and Rajiv Yadav

21.1 Introduction

Boari's bladder flap reconstruction is one of the management options for lower ureteric stricture. It is the preferred treatment option in situation where the stricture segment is either proximal or is longer in length, thus precluding tension free reimplantation with direct vesico ureteric anastomosis with or without psoas hitch. Other than open surgery, Boari's flap can also be performed by minimally invasive surgical approach with laparoscopy. Extensive suturing involved in laparoscopy, increases the operative duration and also increases the surgeon fatigue. Robot assisted approach is helpful in such cases, mainly because of the ease of the suturing and the preservation of vascularity due to minimal and delicate handling of tissues.

21.2 Indications

Lower and mid ureteric strictures (especially in cases with suspicion of lower ureteric ischemia). Adequate bladder capacity (>300 ml) is a prerequisite for fashioning a Boari's flap.

21.3 Procedure

Patients are initially evaluated with CT urography to delineate the ureteric anatomy and assess the location and length of the stricture. If the bladder is not adequately filled during the urography, 'Cystogram' is done to assess the bladder capacity.

Under general anaesthesia, retrograde pyelogram is done for exact delineation of the length of stricture segment. Intra operative identification of the stricture segment is facilitated by placing a 'Ureteric balloon' at the level of the distal end of stricture.

Patient is placed in a low lithotomy position with a steep 30° Trendelenburg tilt. Six ports are placed as shown in the picture. Robot is docked from between the legs. Peritoneum is incised just medial to the iliac vessels and the ureter is seen coursing in the retroperitoneum. If the ureter is seen through the peritoneum, incision of the peritoneum directly over the ureters suffices. Preserving the vascularity of the ureter, it is mobilized outside the adventitial layers and looped. Distally the ureter is dissected till the bladder and proximally, it is mobilized till the dilated normal portion of ureter is seen (facilitated by observing the tip of the preplaced ureteric balloon). Ureter is dissected few centimetres further proximal to the stricture level.

Bladder is mobilized from its peritoneal attachments. Bladder is filled with approximately 200 ml saline and the flap is planned. Similar to the open approach a superior vesical artery based flap is fashioned. The length of the required flap is measured using a ureteric catheter and corresponding length of the flap is marked obliquely across the anterior bladder wall. In case a non-refluxing anastomosis is planned, approximately 3–4 cm of flap length in addition to the estimated ureteral defect is created. Base of the flap is kept sufficiently wide to avoid flap ischemia. Suggested ratio of flap length to base width is 3:1 or less, to avoid flap ischemia. Bladder is

A. Murugesan, MBBS, MS, MCh
Department of Urology, PSG Institute of Medical Sciences
and Research, Peelamedu, Coimbatore, Tamil Nadu, India
e-mail: anandan79@gmail.com

R. Yadav (✉)
Medanta- The Medicity Hospital,
Sector 38, Gurgaon (Delhi, NCR), Haryana, India, 122001
e-mail: drrajivyadav@gmail.com

incised along the marked line and the posterolateral flap is created. The flap is then fixed by a superficial absorbable suture to the psoas muscle, keeping the alignment in line with ureter. The ureter is delivered through a small opening created in the posterior flap, approximately 2–3 cm proximal to the tip. A 3–4 cm submucosal tunnel is then created, to allow a non-refluxing anastomosis. Bladder mucosa is incised and the ureter is pulled into the flap through the tunnel. Spatulated ureteric end is anastomosed to the bladder mucosa using interrupted 4-0 PDS sutures. Few retention sutures are placed between the detrusor and the ureteric adventitia to prevent prolapse of the ureter.

Bladder flap is tubularised in two layers (inner mucosal layer with 4-0 PDS, outer muscular layer with 3-0 vicryl continuous sutures). Bladder integrity is confirmed by saline instillation. Penrose drain is placed and robot undocked.

21.4 Benefits

In comparison to conventional laparoscopy, robot assisted approach is beneficial, primarily in the ease of suturing. The dissection of the ureter avoiding excessive rough handling and better preservation of vascularity is achieved with robot assisted approach.

21.5 Conclusion

Robot assisted approach is preferable for Boari flap ureteric reconstruction, if facilities are available. It is helpful in suturing and better handling of tissues and reducing the time of surgery, which might have a bearing in the long term outcome (Figs. [21.1](#), [21.2](#), [21.3](#), [21.4](#), [21.5](#), [21.6](#), [21.7](#), [21.8](#), [21.9](#), [21.10](#), [21.11](#), [21.12](#), [21.13](#), [21.14](#), [21.15](#), [21.16](#), [21.17](#), [21.18](#), [21.19](#), [21.20](#), [21.21](#), [21.22](#), [21.23](#), [21.24](#), [21.25](#), and [21.26](#)).

21.6 Robot Assisted Boari Flap Ureteric Reimplantation

Fig. 21.1 Port position

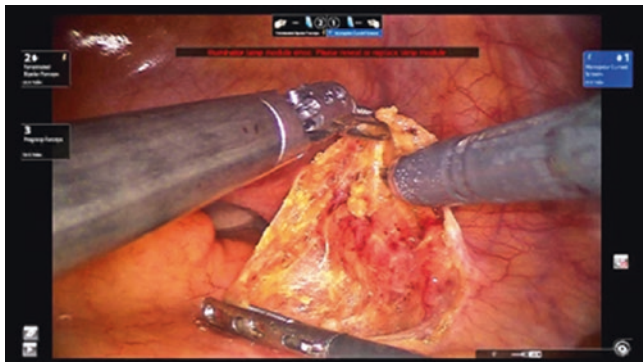
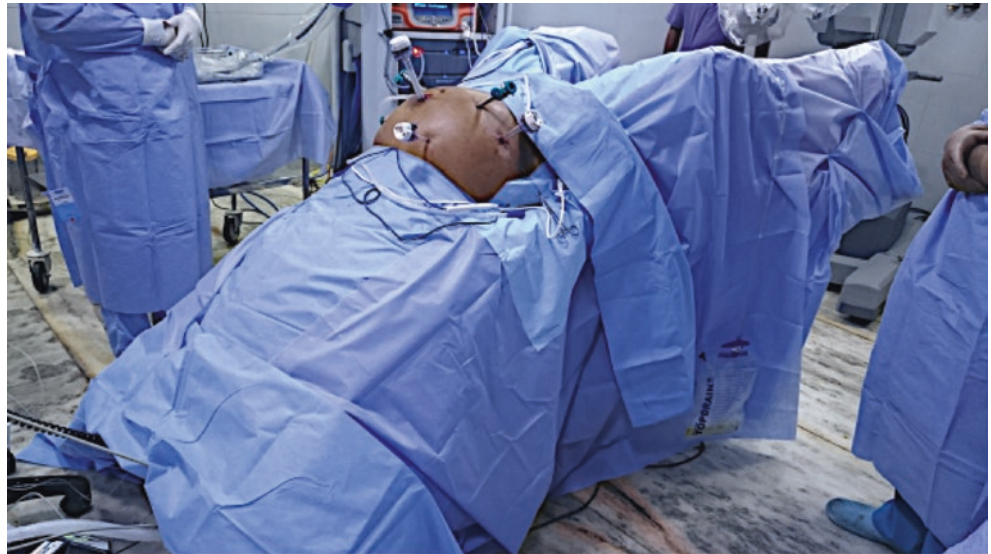

Fig. 21.2 Peritoneal incision over right ureter

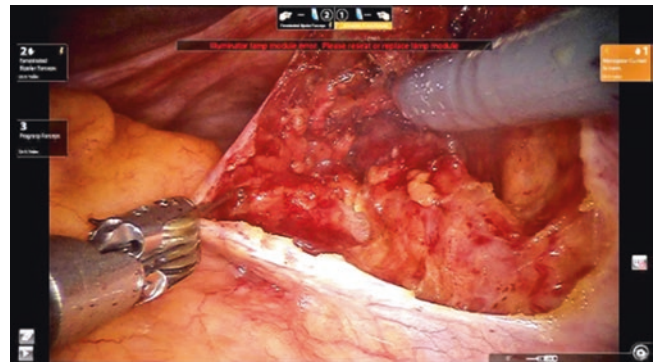


Fig. 21.3 Ureter being dissected

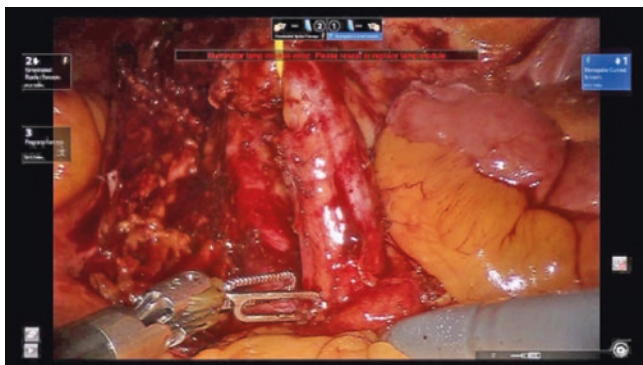


Fig. 21.4 Ureter mobilised and looped

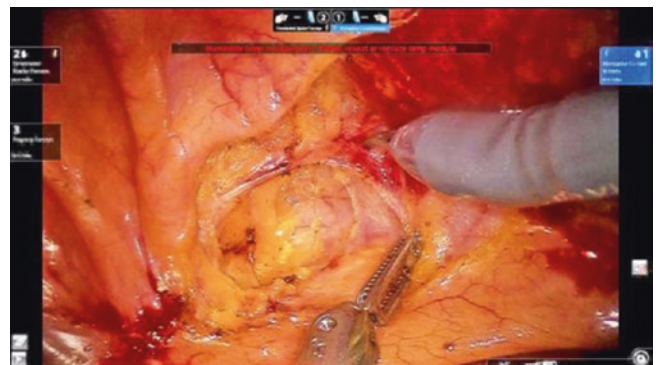

Fig. 21.5 Retzius space being developed

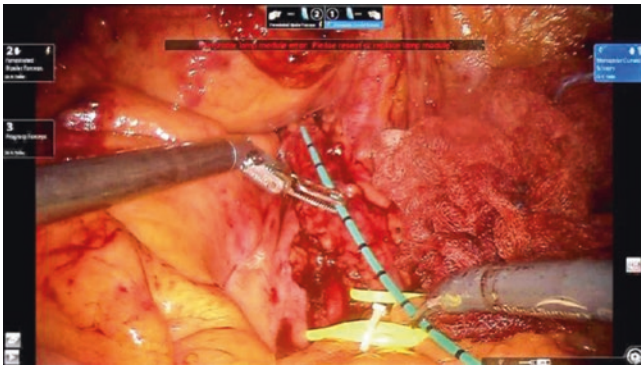


Fig. 21.6 Length of ureteric defect being measured

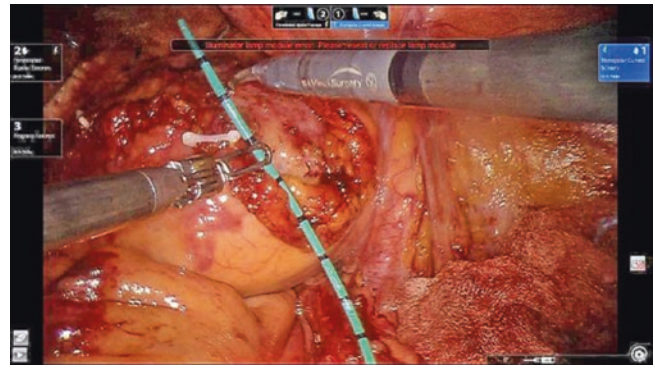


Fig. 21.7 Corresponding length of bladder flap measured

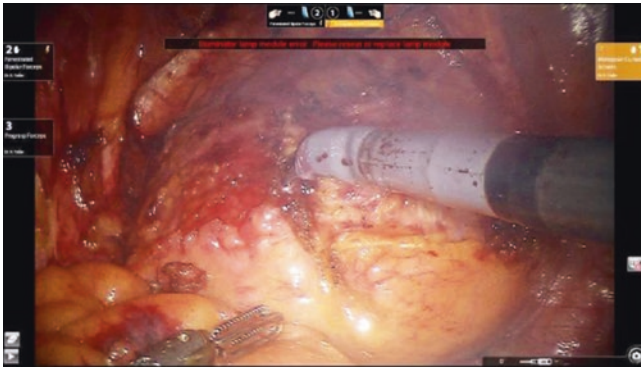


Fig. 21.8 Boari flap being marked

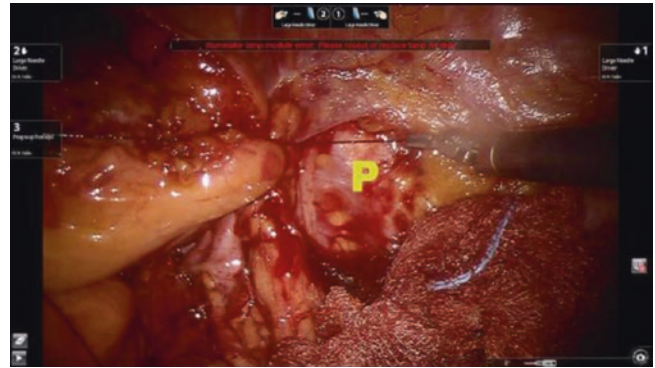


Fig. 21.9 Bladder hitched to psoas

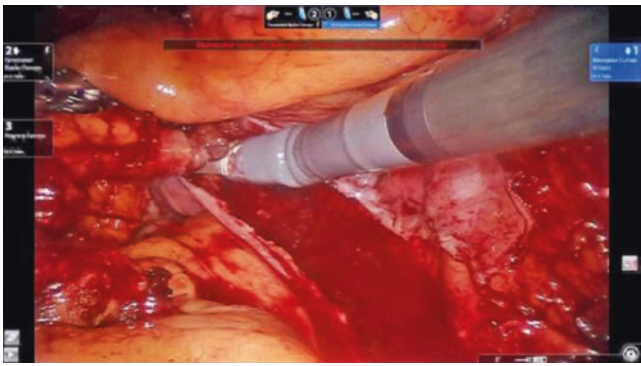


Fig. 21.10 Distal end of ureter clipped and divided

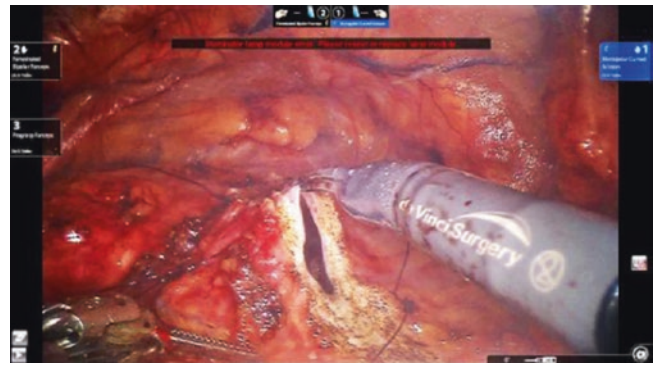


Fig. 21.11 BoariFlap being developed

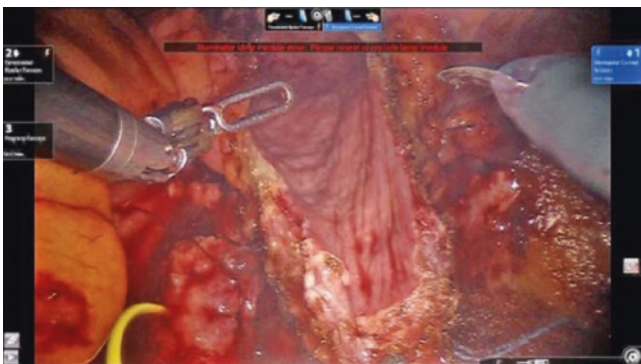


Fig. 21.12 Boari flap completed

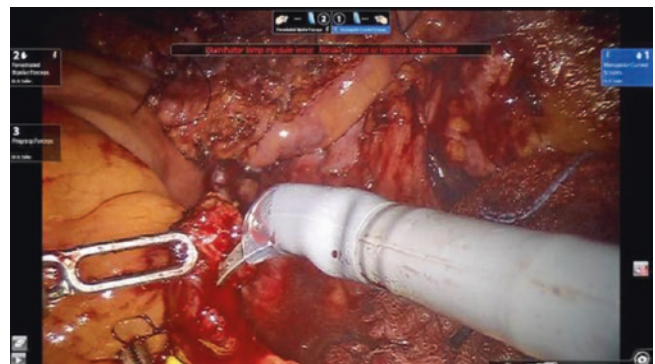


Fig. 21.13 Ureter spatulated

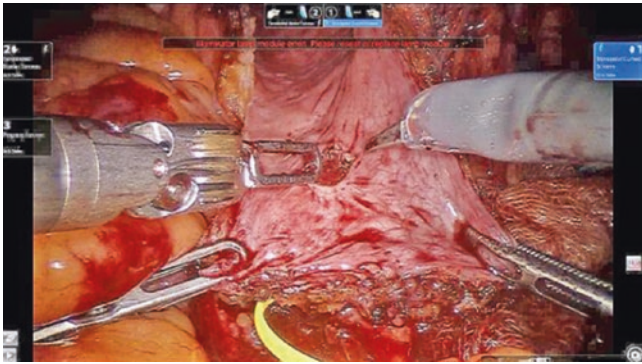


Fig. 21.14 Mucosa of flap incised for delivering the ureter

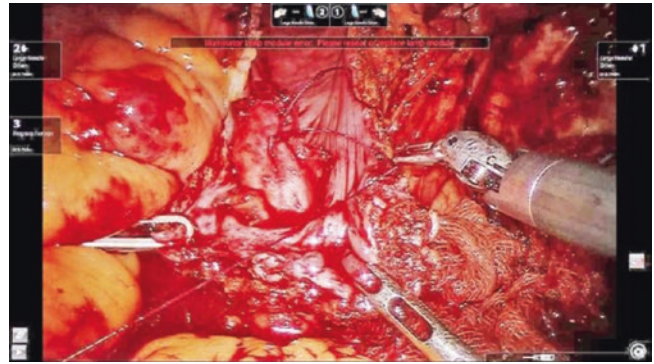


Fig. 21.15 Ureter delivered through the flap

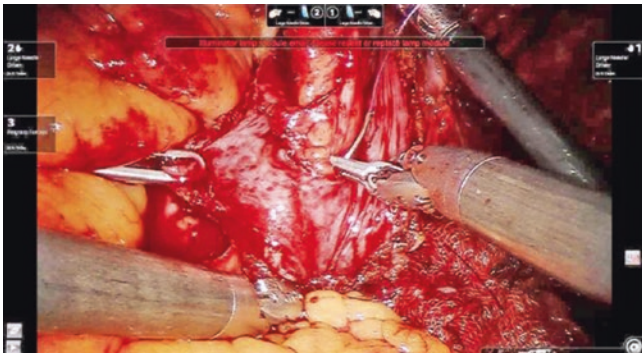


Fig. 21.16 Ureter adventitia fixed with flap

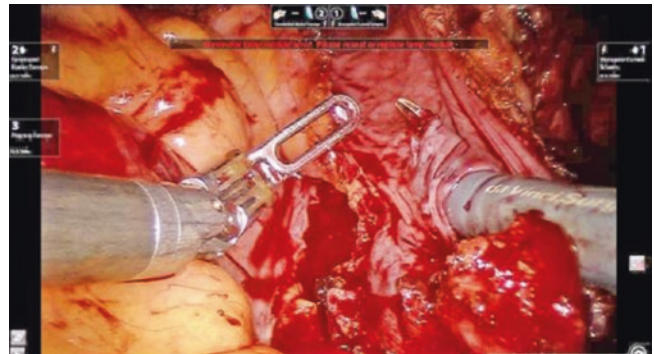


Fig. 21.17 Submucosal tunnel developed distally for ureter

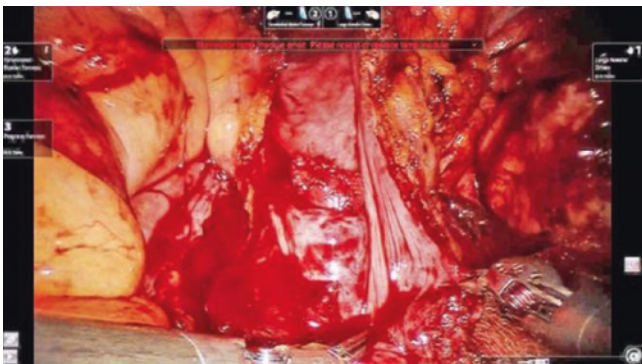


Fig. 21.18 Ureter brought through sub mucosal tunnel

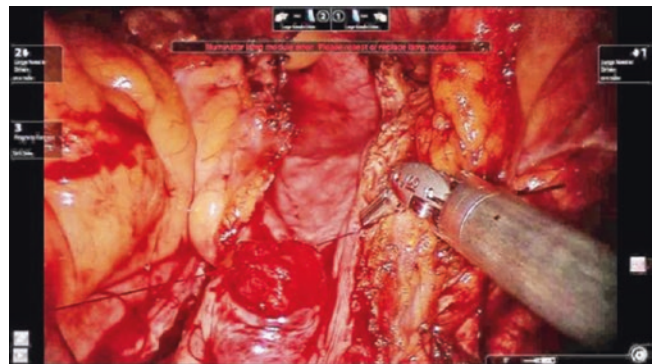


Fig. 21.19 Ureteric anastomosis with mucosa of Boari flap in progress

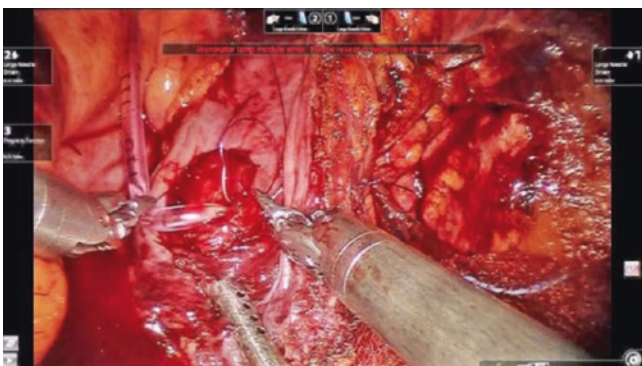


Fig. 21.20 Ureteric anastomosis with 4-0 Vicryl in progress

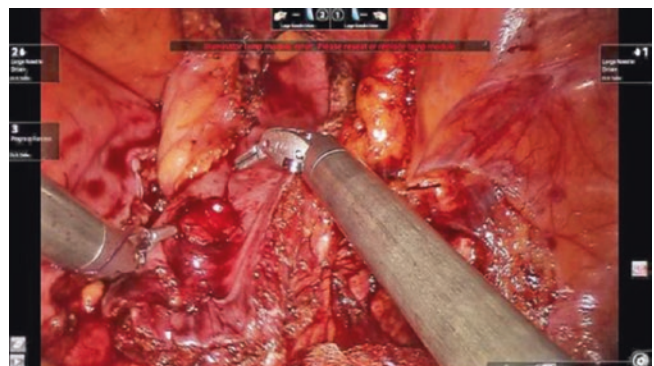


Fig. 21.21 Uretero vesical anastomosis complete

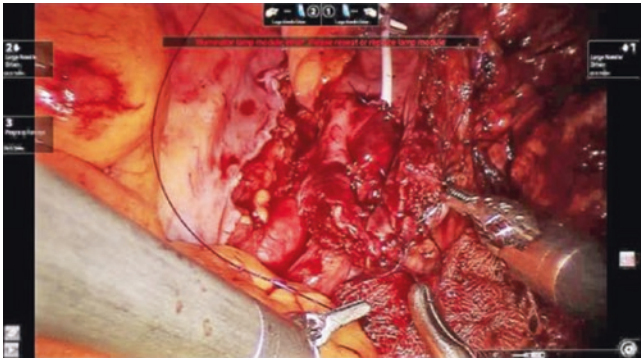


Fig. 21.22 Flap tubularisation started after stent insertion

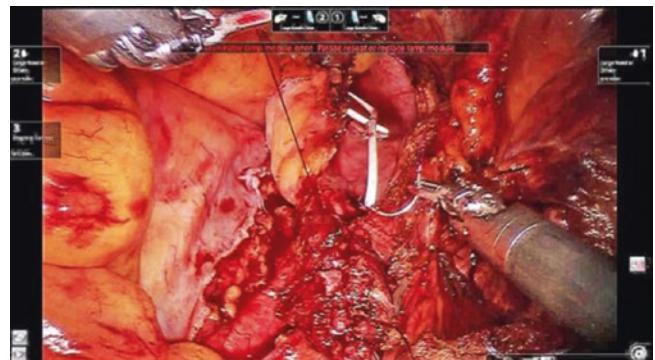


Fig. 21.23 Flap tubularisation in progress

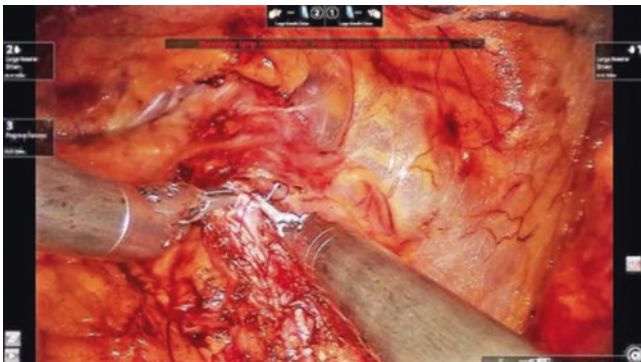


Fig. 21.24 Flap suture extended to cystotomy closure

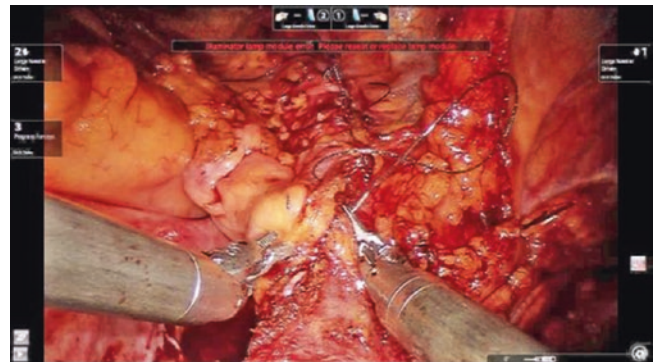


Fig. 21.25 Bladder second layer closure with 2-0 V lock suture in progress

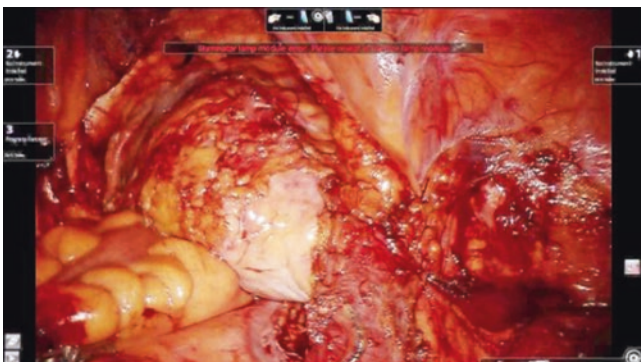


Fig. 21.26 Boari flap completed. Bladder distended to check for leak

22.1 Introduction

Retroperitoneoscopic ureterolithotomy is one of the accepted procedures [1–3] in the management of large ureteric calculi.

22.2 Indication

Retroperitoneoscopic ureterolithotomy is indicated for large ureteric stones where multiple sittings of ESWL fail to fragment it or there is technical difficulty during ureteroscopy.

22.3 Technique

With the patient in the lithotomy position, cystoscopy and RGP is performed. A 6 F open-tip ureteral catheter is introduced and positioned in contact with the lower margin of the stone under fluoroscopic control. If the stone is impacted, we do not attempt to push the catheter or the guidewire past it. The distal end of ureteric catheter with guidewire is kept sterile so that it is accessible for subsequent stent advancement. The patient is placed in 90° lateral position with ipsilateral flank up. Pneumoretroperitoneum is created and ports are placed. Ten millimeter camera port at tip of 12th rib, 10 mm port, one fingerbreadth above the iliac crest in the midaxillary line and a 5 mm port in the anterior axillary line midway between the first and second ports are inserted. An optional fourth 10 mm trocar is inserted in the anterior axillary line just below the rib margin. This port is helpful in allowing the introduction of a fan retractor to retract the kidney in obese patients.

K. Senthil, MCh (Urol FRCS) (✉)
Urology Clinic, Gowtham annexe, Coimbatore, India
e-mail: senthilsatya@hotmail.com

P. Rajendran, MCh (Uro)
Madhava Hospital, Nellithope, Pondicherry, India

The ureter is identified, dissected, and traced to the stone, which is identified by a bulge. In thin patients, this is an easy task and in obese patients, it is difficult. In these cases, guidewire can be introduced into the ureteral catheter and moved gently back and forth to look for transmitted movement. The ureter is opened longitudinally over the stone using an endoknife.

The stone is extracted and placed on the psoas for later removal using a bag. A guide wire is introduced through the previously inserted open-tip ureteral catheter and passed into the renal pelvis under vision. This guidewire is used to place a double-J stent into the kidney at the end of the procedure. The ureterotomy is sutured with interrupted 3-0 vicryl. A retroperitoneal drain is placed and the trocar port sites are closed.

22.4 Comments

Measures to prevent upward migration of the calculus are as follows –

- (a) The patient may be placed in a head up position
- (b) Dissector or a sling is placed above the stone level.

One must be prepared with a flexible nephroscope and ureteroscope to retrieve migrated calculus. C arm with image intensifier is very useful to locate the calculus especially when migration occurs.

22.5 Conclusions

Retroperitoneoscopic or transperitoneal ureterolithotomy is preferable to open ureterolithotomy whenever indicated. Retroperitoneoscopic ureterolithotomy is less invasive and more appropriate (Figs. 22.1, 22.2, 22.3, 22.4, 22.5, 22.6, 22.7, 22.8, 22.9, and 22.10).

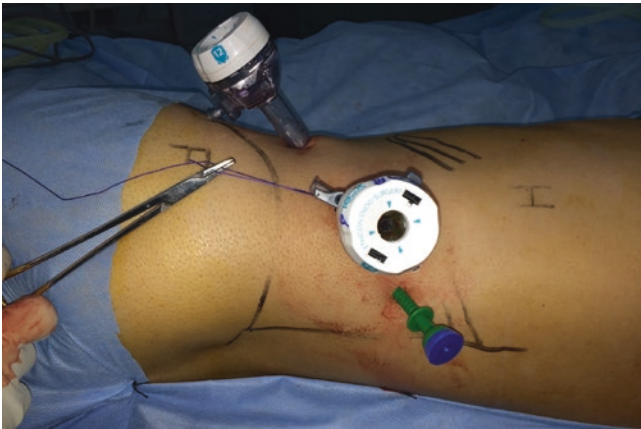

Fig. 22.1 Ports position for left retroperitoneoscopic ureterolithotomy

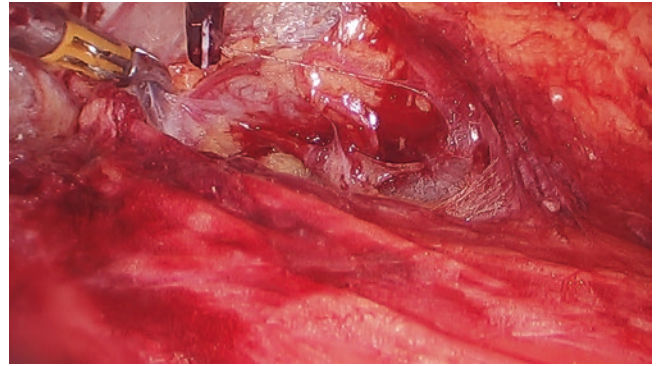


Fig. 22.2 Dissection medial to psoas shows ureter

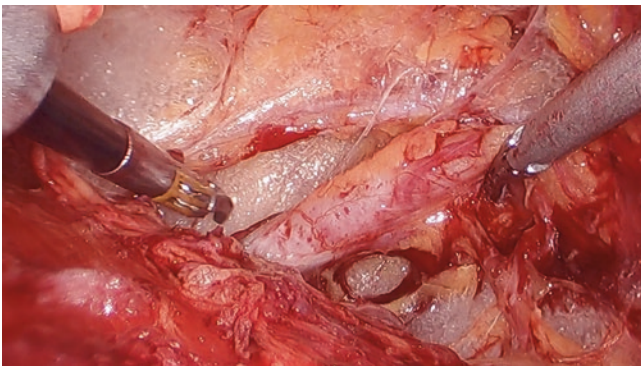


Fig. 22.3 Ureter dissected and bulge due to stone seen

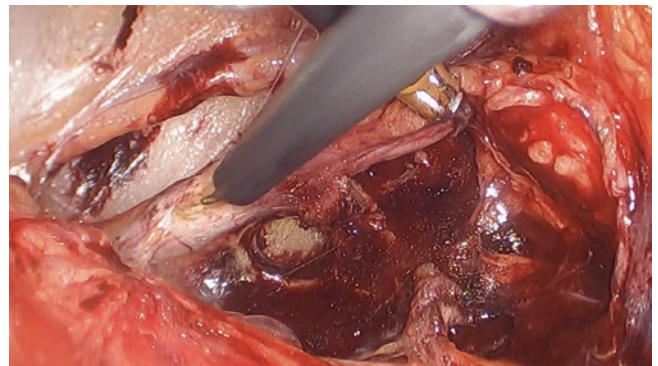


Fig. 22.4 Ureterotomy being done with hook

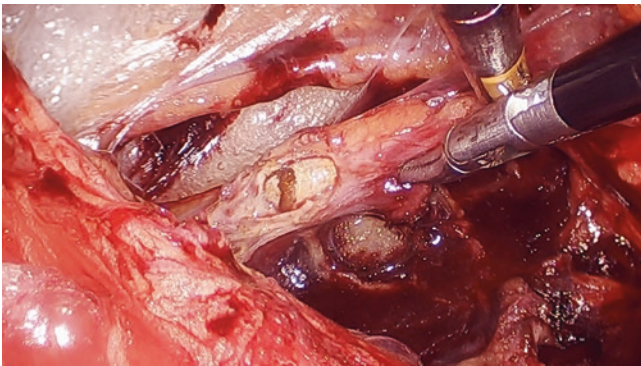


Fig. 22.5 Calculus seen through ureterotomy

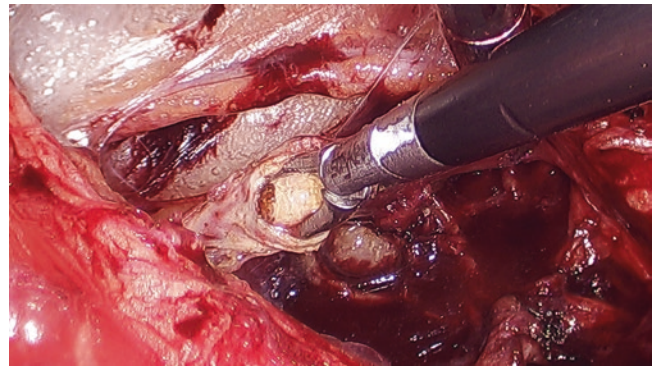


Fig. 22.6 Stone being retrieved

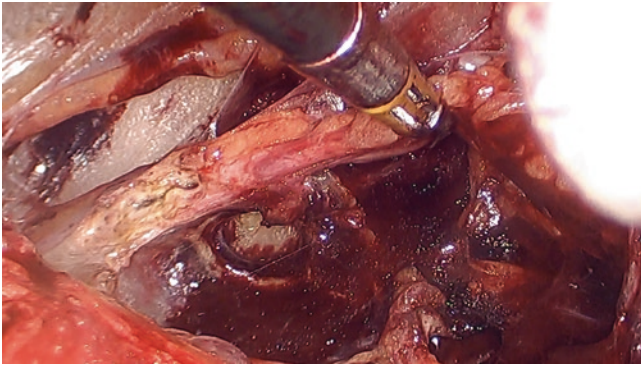


Fig. 22.7 Ureterotomy after removal of stone

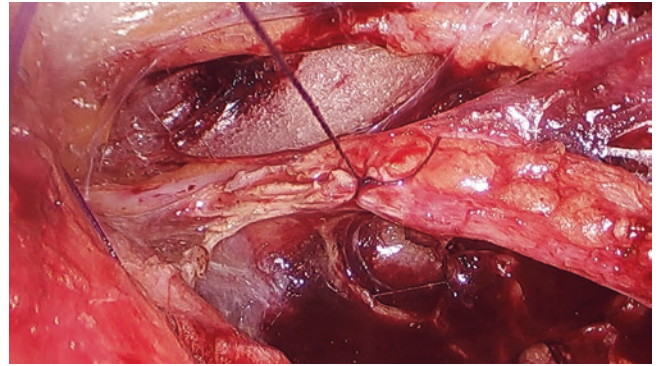


Fig. 22.8 Ureterotomy closure with 4-0 vicryl started

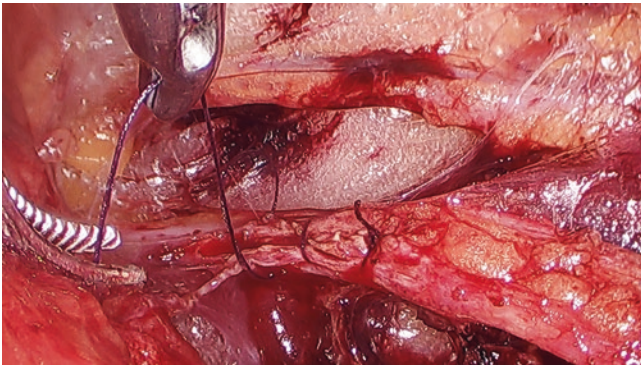


Fig. 22.9 Closure of ureterotomy in interrupted fashion

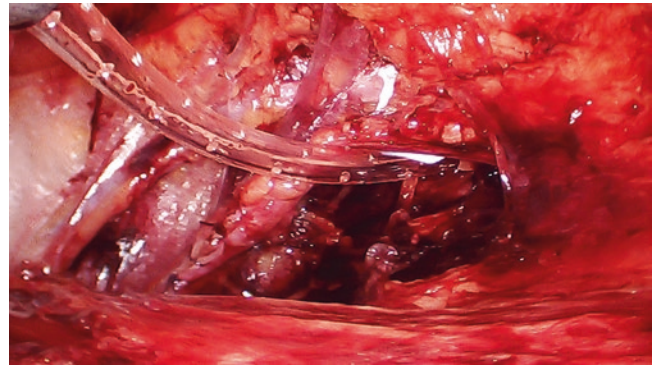


Fig. 22.10 Drain placed

References

1. Gaur DD. Laparoscopic operative retroperitoneoscopy: use of a new device. *J Urol.* 1992;148:1137.
2. Gaur DD, Agarwal DK, Purohit KC, et al. Retroperitoneal laparoscopic pyelolithotomy. *J Urol.* 1994;151:927.
3. Gaur DD, Trivedi S, Pradhudesai MR. Laparoscopic ureterolithotomy: technical considerations and long-term follow-up. *BJU Int.* 2002;89:339.

Sanjay B. Kulkarni

23.1 Introduction

Primary or secondary nonmalignant extrinsic ureteral obstruction can be managed by open or laparoscopic ureterolysis [1–3].

23.2 Indication

Ureterolysis is warranted whenever there is significant back-pressure changes in the upper tract.

23.3 Surgical Technique

Preoperative ureteric stenting improves renal function. The stent also guides the surgeon intraoperatively. The patient is placed in 70° lateral position. By transperitoneal

approach, using a para umbilical camera port, two secondary ports in midclavicular line and a fourth port in the corresponding iliac fossa, the obstructed ureter is approached. By mobilising the colon ureter is identified and released. Incisional biopsy is done from the fibrous plaque. Ureter can be lateralised and intraperitonealised. Omental wrapping has to be done to place the ureter away from fibrous plaque. Omentum also provides better vascularity and helps in healing.

23.4 Conclusion

Laparoscopic ureterolysis is a less morbid procedure compared to open ureterolysis, with similar results.

S.B. Kulkarni, FRCS
Kulkarni Endosurgery Institute and Reconstructive
Urology Centre, Pune, India
e-mail: sanjaybkulkarni@gmail.com

23.5 Laparoscopic Ureterolysis

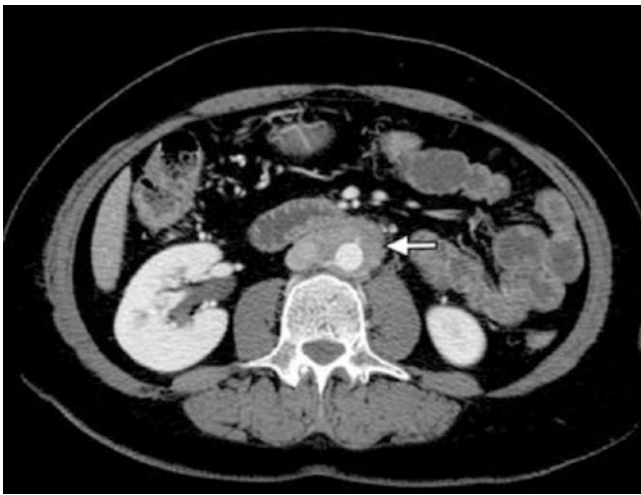

Fig. 23.1 CT image showing retroperitoneal fibrosis

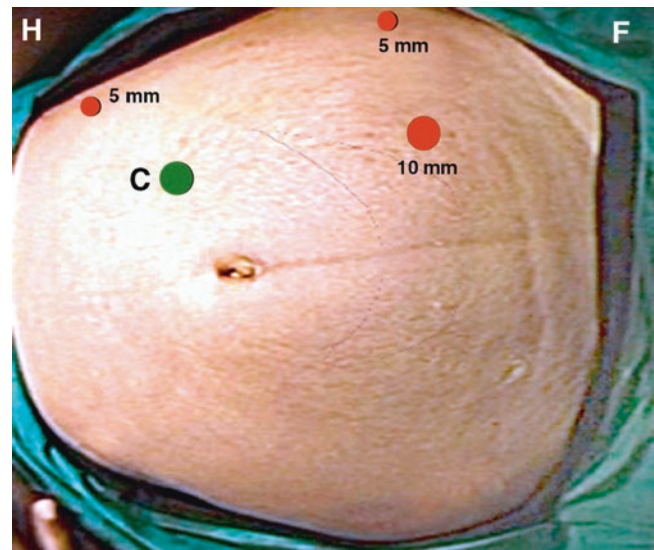


Fig. 23.2 Port position for left side ureterolysis

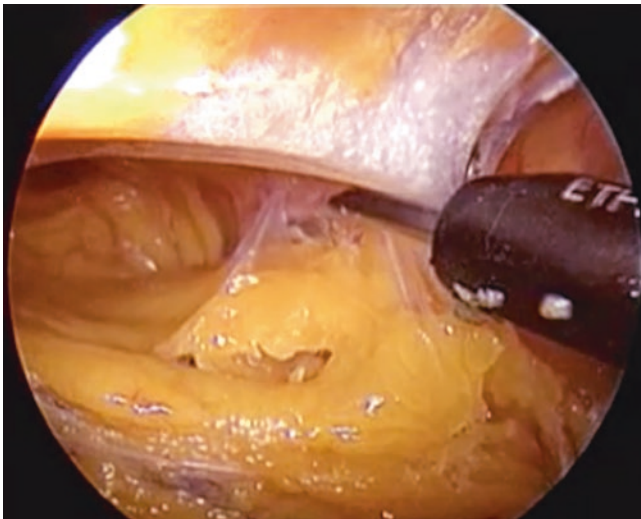


Fig. 23.3 Omental adhesions being released

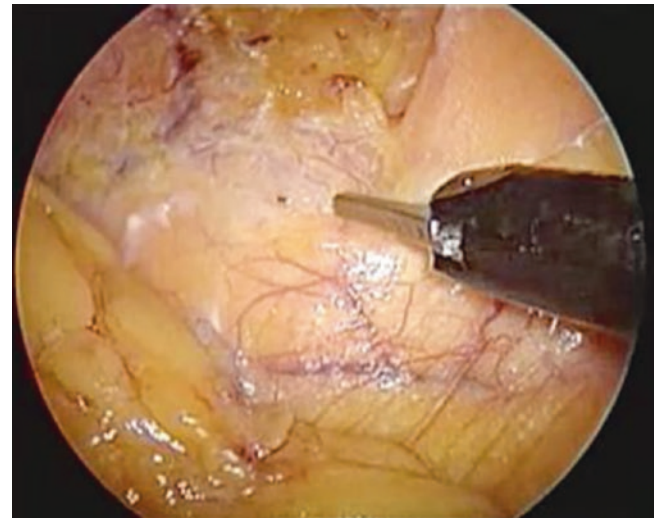


Fig. 23.4 Left colon being reflected medially

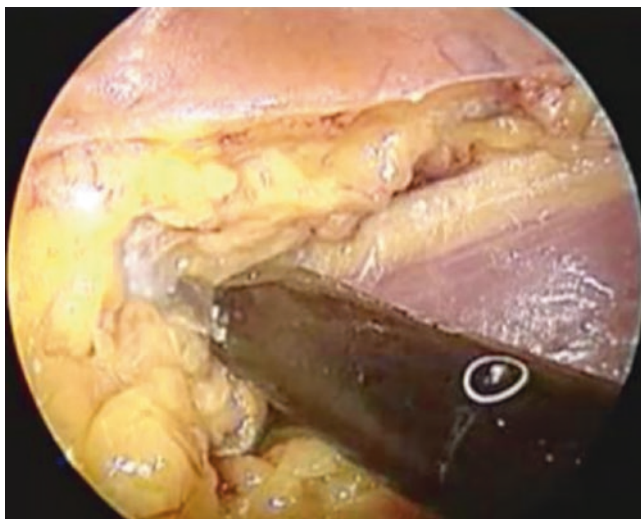


Fig. 23.5 Retroperitoneal dissection anterior to psoas

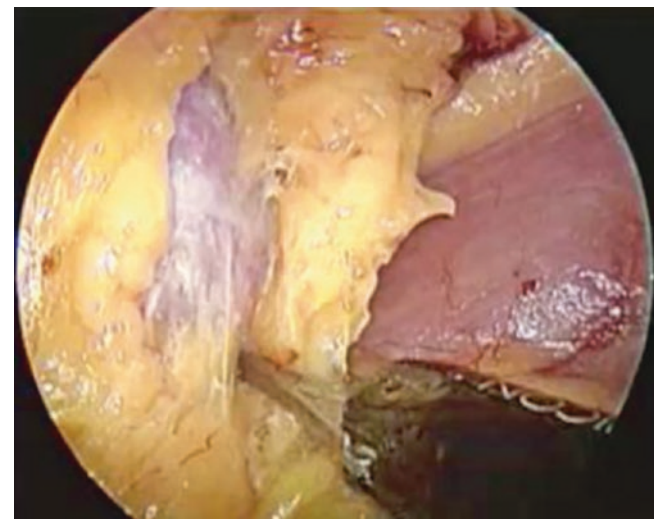


Fig. 23.6 Lower pole of kidney seen

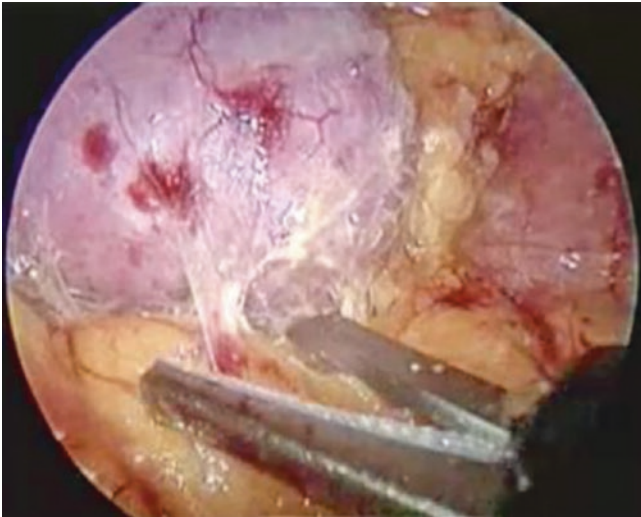


Fig. 23.7 Lower pole of kidney dissected to delineate the ureter medially

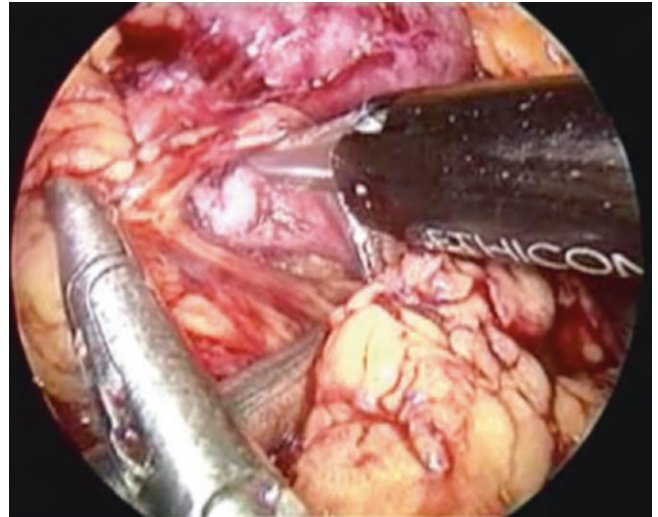


Fig. 23.8 Blunt dissection with peanut pusher to prevent injury to iliac vessels

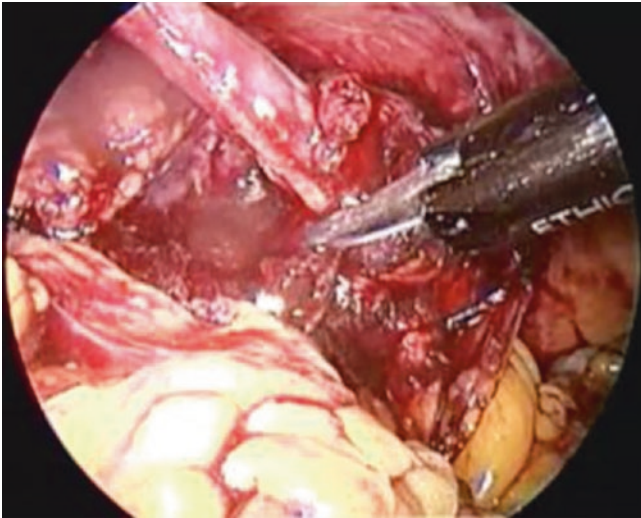


Fig. 23.9 Ureter identified and dissected

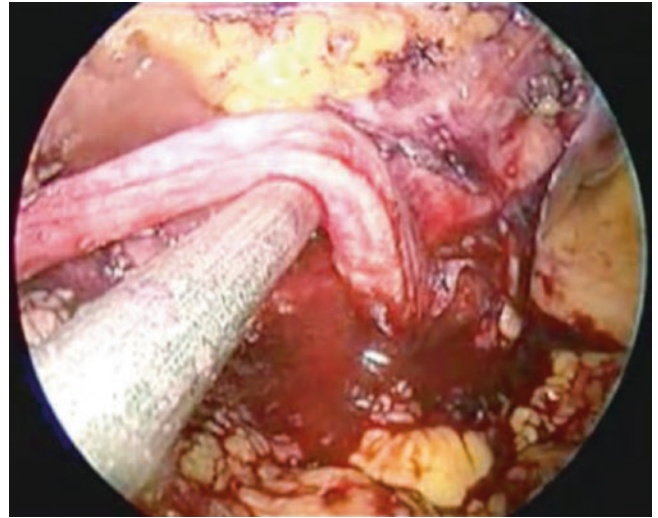


Fig. 23.10 Ureter released from surrounding fibrotic adhesions and dissection proceeds distally

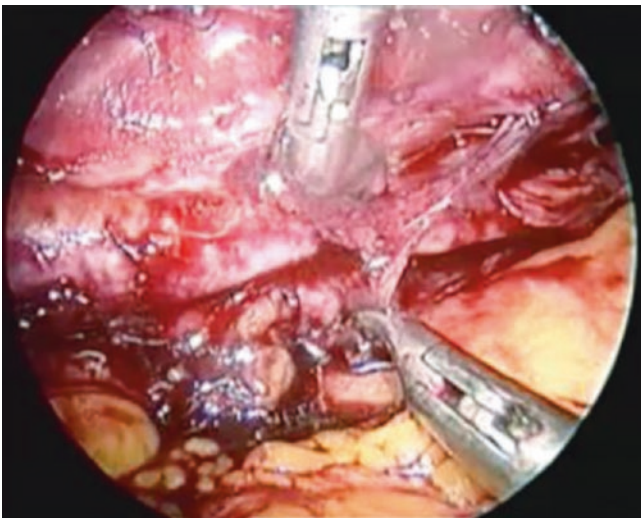


Fig. 23.11 Ureteral dissection in progress close to pelvic brim

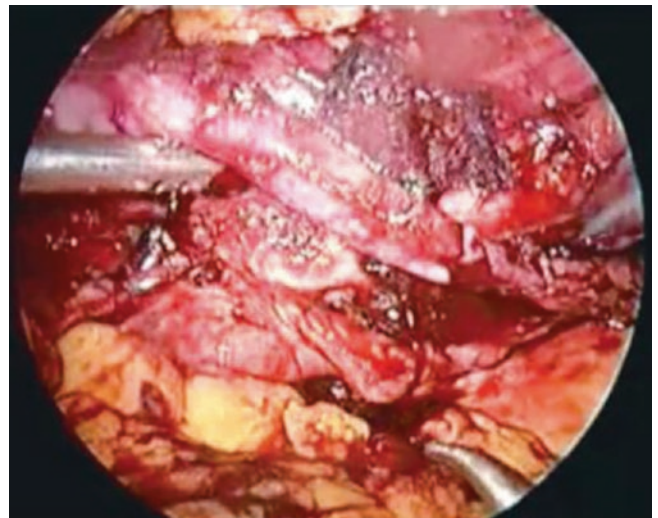


Fig. 23.12 Ureter dissected beyond vessel crossing

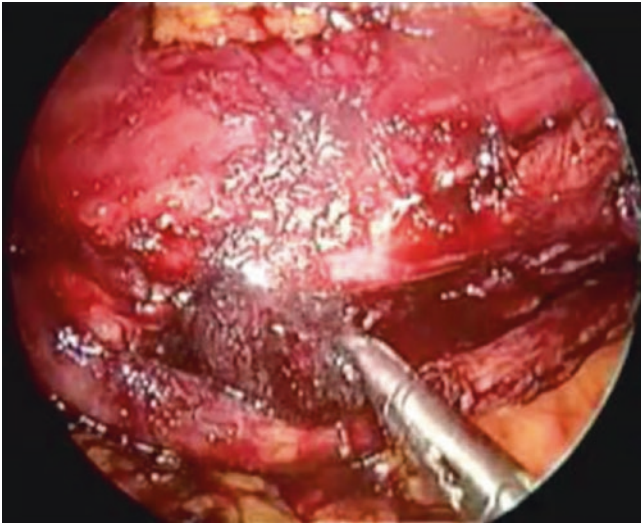


Fig. 23.13 Ureter completely dissected free

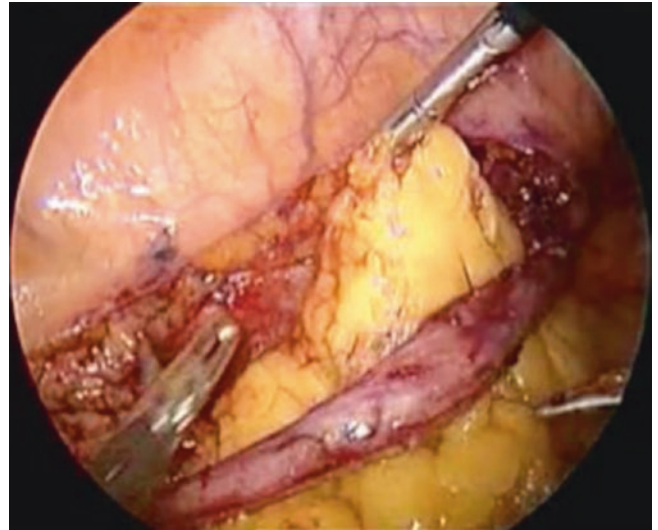


Fig. 23.14 Omentum being wrapped around the ureter

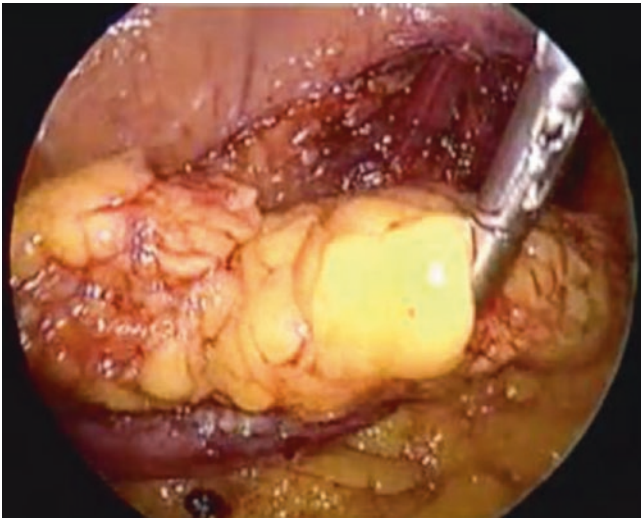


Fig. 23.15 Changing to right loin position similar dissection and omental wrapping of right ureter done

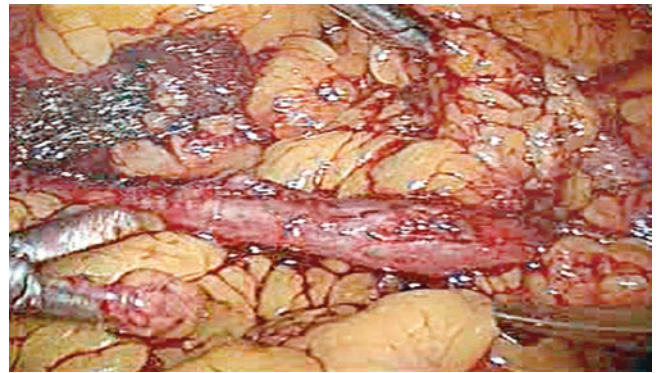


Fig. 23.16 Omentum brought posterior to ureter

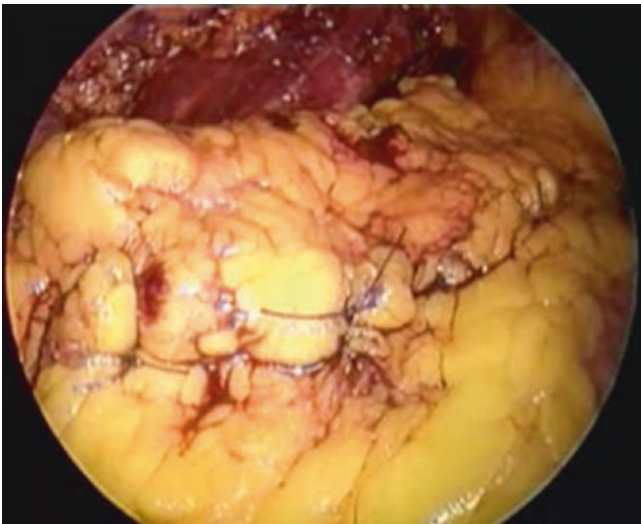


Fig. 23.17 Ureter completely wrapped with omentum

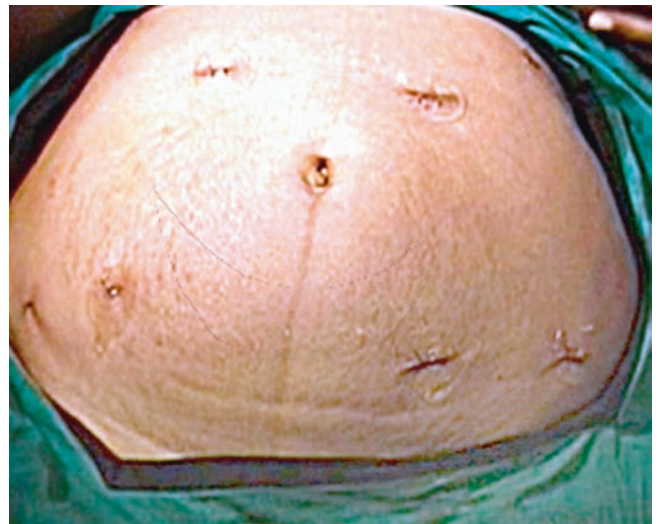


Fig. 23.18 Final view of the port marks

References

1. Ishitoya S, Okubo K, Arai Y. Laparoscopic ureterolysis for retrocaval ureter. *Br J Urol*. 1996;77:155–68.
2. Kavoussi LR, Clayman RV, Brunt LM, Soper NJ. Laparoscopic ureterolysis. *J Urol*. 1992;147(2):426–9.
3. Mattelaer P, Boeckmann W, Brauers A, Wolff JM, Jakes G. Laparoscopic ureterolysis in retroperitoneal fibrosis. *Acta Urol Belg*. 1996;64(4):15–8.

24.1 Introduction

Substitution of ureter using ileum is suitable in cases with long or multiple ureteric strictures. The usage of ileum as a replacement of ureter was first done by Shoemaker in 1906 and subsequently popularized by Goodwin in 1959 [1]. Historically, ileal ureter replacement is done for ureteric strictures secondary to tuberculosis. However, its usage has increased with increased incidence of ureteric strictures secondary to endoscopic procedures as well as radiation strictures. Ileum is a suitable substitute of ureter due to its rich blood supply and mobility. The risk of uraemia and acidosis is low if the selected patients have good renal functions pre-operatively [2].

The first case of laparoscopic ileal ureter replacement was reported in 2000 [3] and the same group has also shown clear benefits of laparoscopic over open surgery in terms of post-operative recovery [4]. Since then, there are various reports of ileal ureter using laparoendoscopic single site as well as robotic approach.

24.2 Indications

- Long segment or multiple ureteric strictures
- Retroperitoneal fibrosis (RPF)

Contraindications

- Previous abdominal surgeries
- Impaired renal function
- Previous pelvic irradiation

24.3 Surgical Techniques

A conventional laparoscopy set and 30° telescope is used. The patient is placed in a lateral position. A transperitoneal approach is used in all of our patients. Ports were positioned as follows: 10 mm port at the level of the umbilicus for camera, two additional 12 mm ports 5 cm above and below the umbilicus, and one 5 mm port 1 cm below the xiphoid for liver retraction for right-sided surgery. All the ports are placed in the midline. An additional 12 mm port is placed in either right or left iliac fossa to facilitate the application of Endo-GIA stapler (Fig. 24.1).

The colon is medialised to expose the renal pelvis (Fig. 24.2). A careful dissection of renal pelvis was performed. After the ureter is identified, the ureter is transected and the double J stent is removed if it was inserted previously. Extensive mobilization of the renal pelvis is then performed and stay suture using a straight needle is used to suspend the renal pelvis. A loop of terminal ileum 20 cm away from ileocaecal valve is identified and suspended to the abdominal wall using straight needle. The distal end of terminal ileum is transected using endo-GIA stapler. A bipolar cautery is used for haemostasis of the cut mesentery if bleeding occurs. The transected end of ileum is brought up to the renal pelvis and temporarily fixed in that position using vicryl 3/0 sutures. The proximal end of ileum is brought down to pelvis to ensure adequate length for the distal anastomosis and it is transected at this point using the Endo-GIA. Care is taken to ensure that it is an isoperistaltic segment. The bowel continuity is re-established by

A. Sim (✉)
Department of Urology, Singapore General Hospital,
Outram Road, Singapore, Singapore
e-mail: Allen.sim.s.p@singhealth.com.sg

C. Schwentner
Department of Urology, Eberhard-Karls University,
Tuebingen, Germany

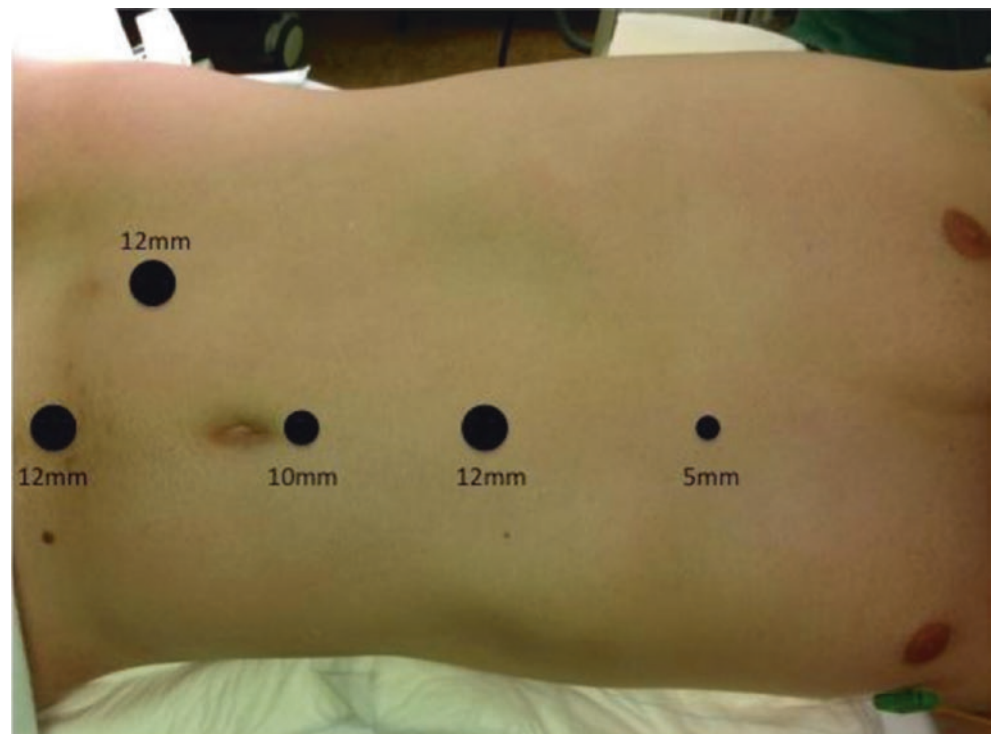
performing functional end-to-end anastomosis using Endo-GIA stapler. The pyeloileal anastomosis can be performed using barbed sutures such as V-lock or Stratafix suture. A 9 fr double J stent was inserted before completion of the anastomosis. After completion of pyeloileal anastomosis, the bladder is mobilized and a cystostomy is performed at the dome. The ileovesical anastomosis is performed in a similar fashion using barbed suture. A surgical drain is placed.

24.4 Tips and Tricks

Previous study has shown that laparoscopic ileal ureter is superior to open surgery in terms of shorter time to convalescence and shorter hospital stay [4]. A recent study has also demonstrated feasibility of completely intracorporeal ileal ureter using robotic technique. However, the operative time

was 7 h and this is partly attributed by the docking and undocking of the robot during different parts of surgery according to the author. We think that laparoscopic approach is clearly advantageous in terms of operative time as the position of the patients can be adjusted whenever necessary without having to undock the robot, thus shortening the operative time. The additional 12 mm port inserted to right or left iliac fossa provides a better angle for manipulation of Endo-GIA to aid in the bowel resection and reconstruction. The use of a stay suture can be helpful for the pyeloileal anastomosis to suspend the renal pelvis thus allowing a clearer view during the anastomosis. The pyeloileal and ileovesical anastomosis can be performed efficiently with the aid of barbed suture such as stratafix or V-Lock. Newer surgical equipment such as Endo Stitch (Covidien) can be useful especially for laparoscopic surgeon with inadequate experience in intracorporeal stitching and knot-tying.

Fig. 24.1 Picture showing port placement for laparoscopic right ileal ureter: 10 mm port above umbilicus for camera; 12 mm port $\times 2$ 5 cm above and below the umbilicus, 5 mm port 1 cm below the xiphoid for liver retraction and additional 12 mm port in right iliac fossa for Endo-GIA stapler



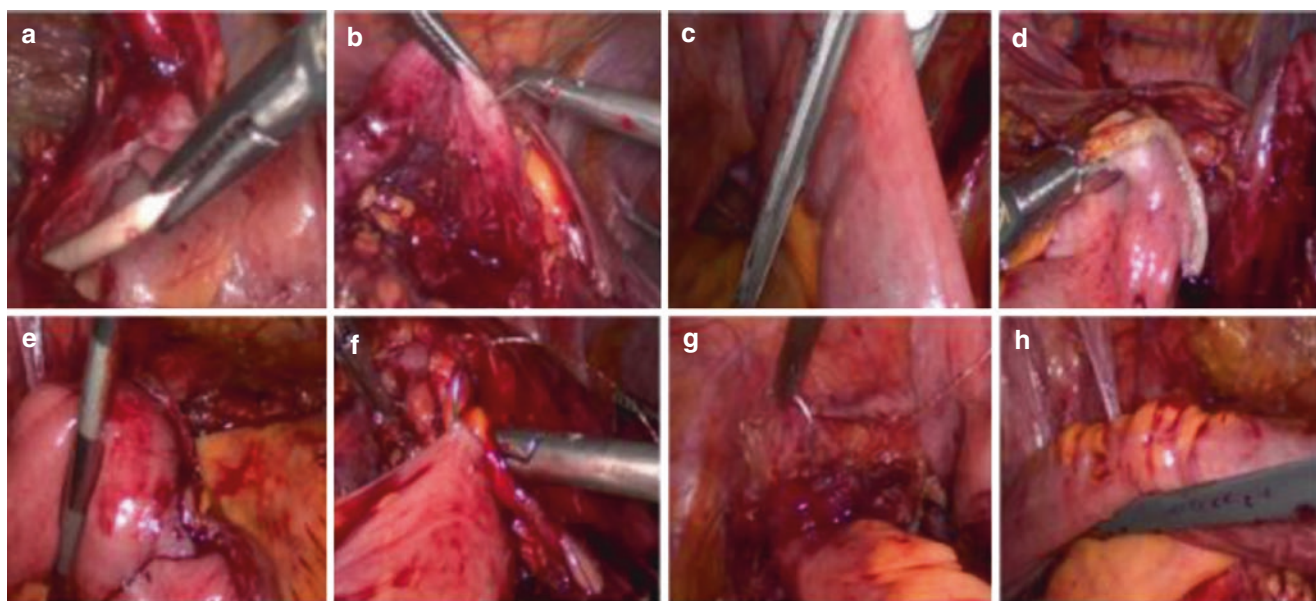


Fig. 24.2 (a) Ureter identification and removal of Double J stent; (b) renal pelvis mobilization and suspension; (c) Bowel transection using Endo_GIA stapler; (d) transected bowel temporarily fixed to

renal pelvis; (e) end-to-end anastomosis after distal transection; (f) pyeloileal anastomosis; (g) ileovesical anastomosis; (h) completed isoperistaltic ileal ureter

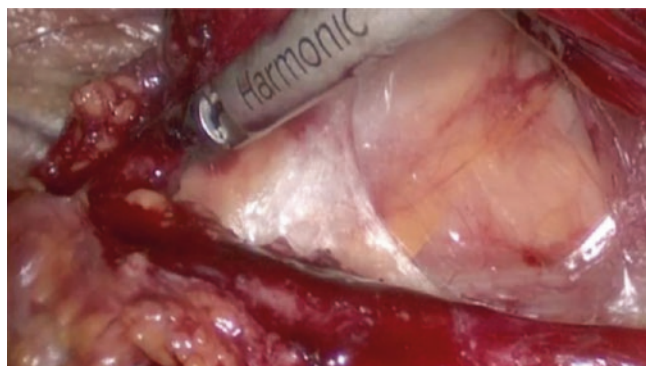


Fig. 24.3 Right colon reflected

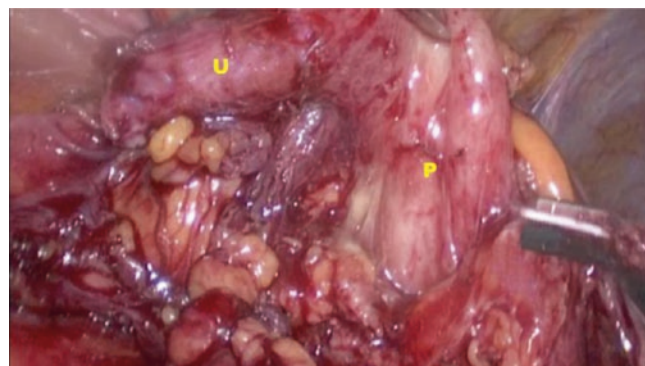


Fig. 24.4 Ureter traced proximally and pelvis dissected

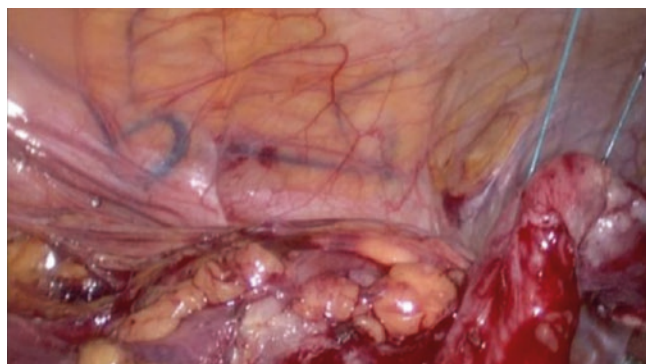

Fig. 24.5 Stay suture taken in pelvis

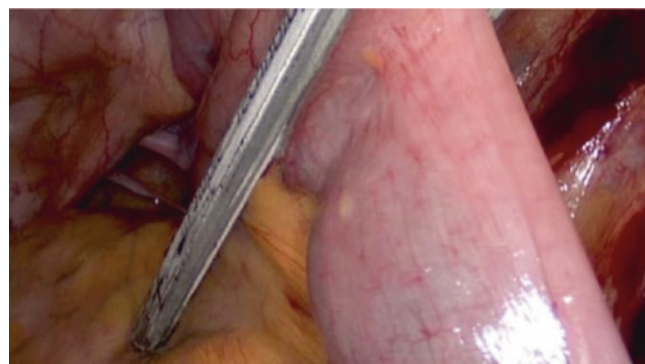

Fig. 24.6 Bowel isolation using stapler

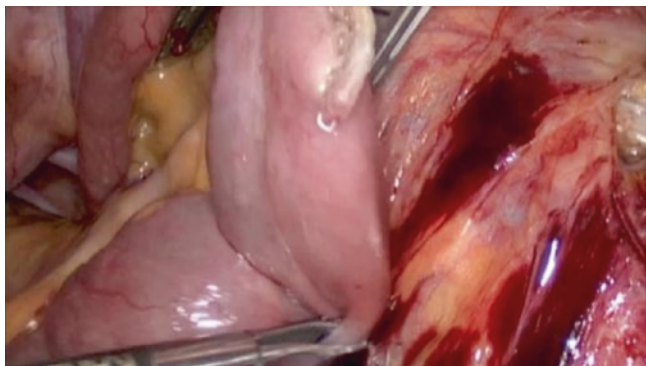


Fig. 24.7 Proximal end of bowel divided

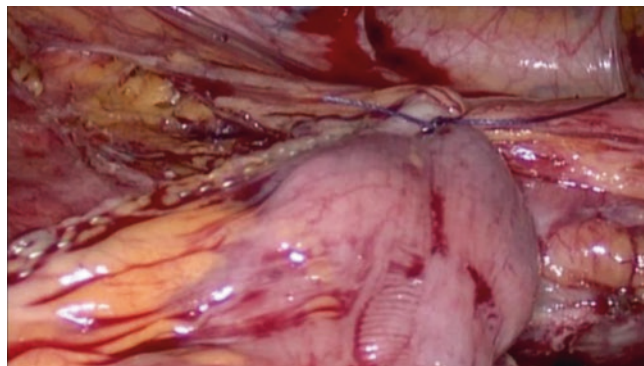

Fig. 24.8 Proximal end of segment fixed with stay

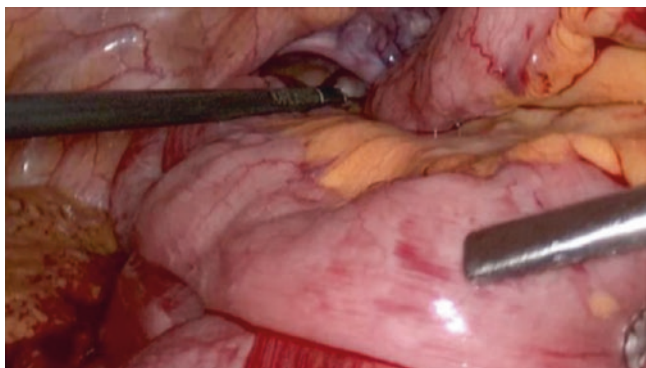


Fig. 24.9 Required bowel length being assessed

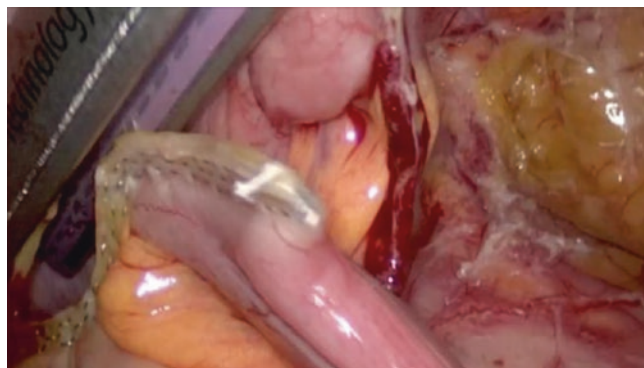


Fig. 24.10 Distal end of bowel divided

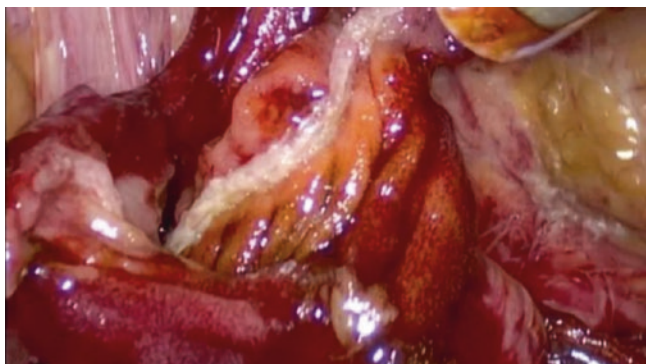


Fig. 24.11 Bowel continuity restored by stapler, bowel mucosa seen

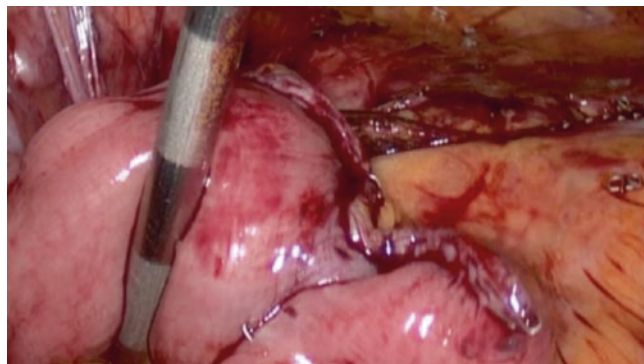


Fig. 24.12 Ileoileal anastomosis completed

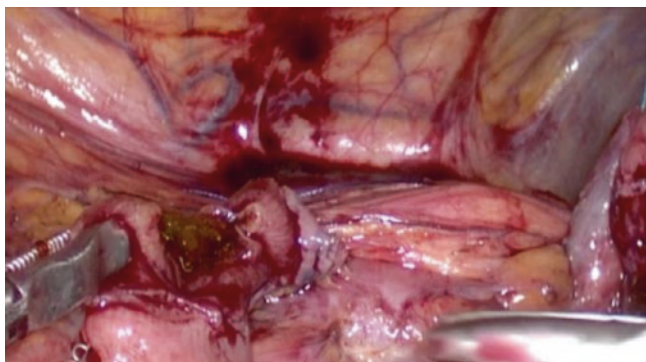


Fig. 24.13 End of ileal segment opened for anastomosis

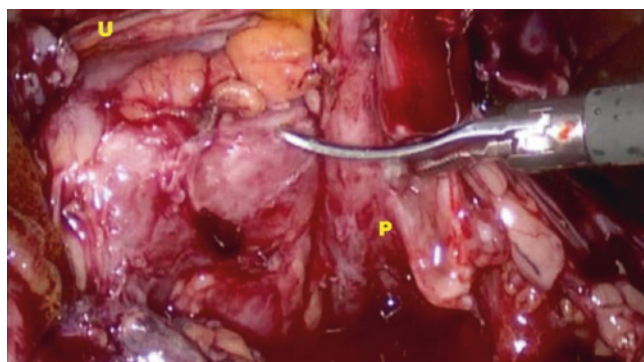


Fig. 24.14 Pyelotomy in progress

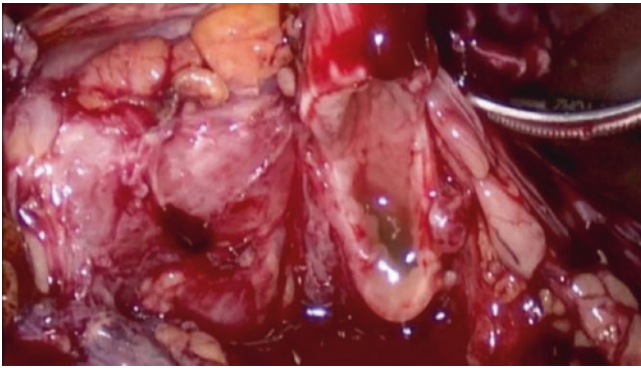


Fig. 24.15 Pyelotomy completed

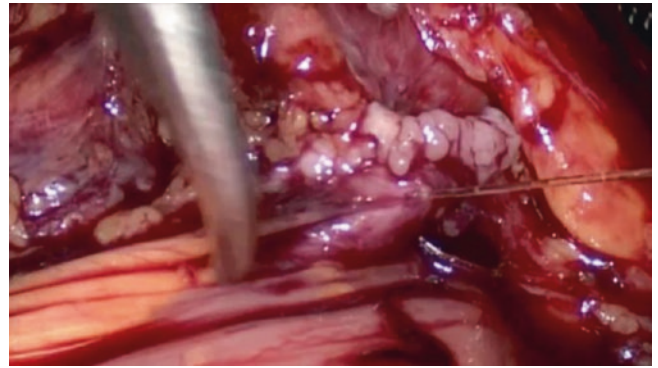


Fig. 24.16 Pyelo ileal anastomosis with 2-0 Vicryl suture in progress

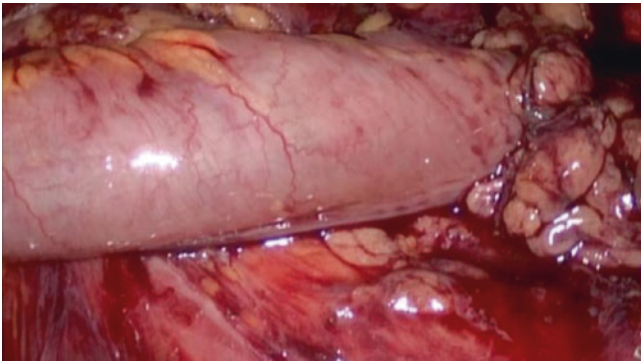


Fig. 24.17 Completed pyeloileal anastomosis

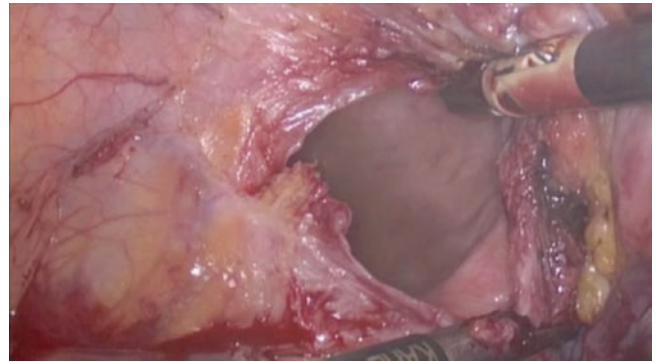


Fig. 24.18 Cystotomy done near the dome

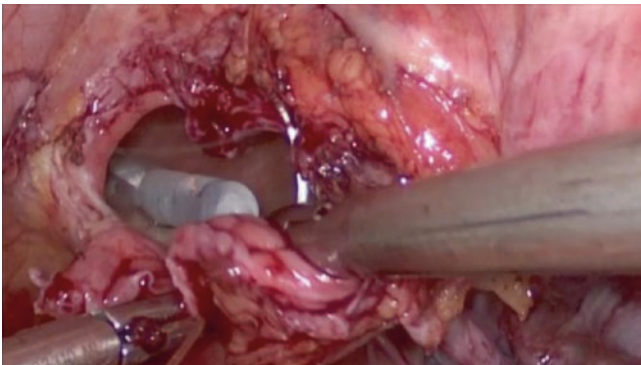


Fig. 24.19 Vesico ileal anastomosis started with 2-0 suture

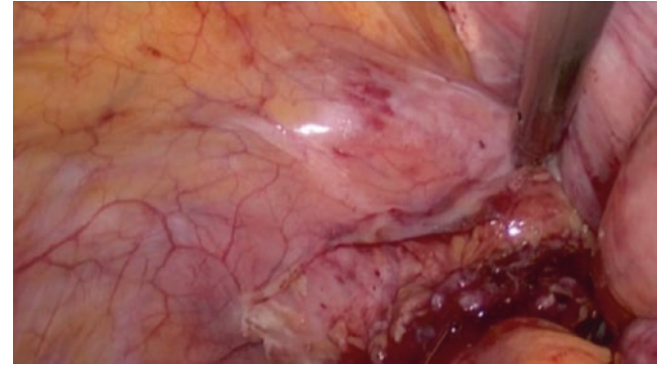


Fig. 24.20 Vesico ileal anastomosis in progress

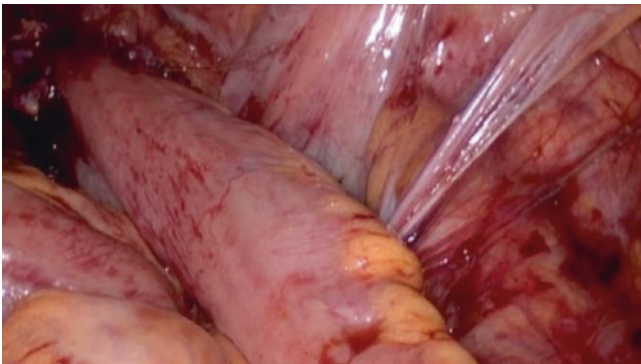

Fig. 24.21 Completed vesico ileal anastomosis

References

1. Abrams HJ, Buchbinder MI, et al. Experience with ileal ureters. *Bull N Y Acad Med.* 1977;53(4):329–37.
2. Armatys SA, Mellon MJ, Bihle R, et al. Use of ileum as ureteral replacement in urological reconstruction. *J Urol.* 2009;181(1):177–81.
3. Gill IS, Savage SJ, Sung GT, et al. Laparoscopic ileal ureter. *J Urol.* 2000;163:1199–202.
4. Stein RJ, Gill IS, Desai MM, et al. Laparoscopic assisted ileal ureter: technique, outcomes and comparism to open procedure. *J Urol.* 2009;182:1032–9.

Manickam Ramalingam, Kallappan Senthil,
Nagesh Kamat, and P. Khanderwal

25.1 Introduction

In extensive disease or injury to the ureter, the options are autotransplantation or ileal ureteral substitution [1]. The metabolic and physiological effects of ileal ureter must be kept in mind prior to embarking on the procedure. The general contra indications are renal impairment when the serum creatinine is greater than 2 mg/dl, bladder dysfunction, bladder outlet obstruction, inflammatory bowel disease or radiation enteritis.

25.2 Surgical Technique

Intraoperative RGP will give an idea about the length of stricture. With patient in 70 loin position by a transperitoneal approach using four ports, the colon is mobilised. The ureter is dissected and traced up to the renal pelvis. The feasibility of using the pelvis for anastomosis is ascertained. A suitable segment of the ileum is selected and brought out through a 5 cm incision in midline or extension of one of the ports for

extracorporeal bowel isolation [2]. The mesentery is divided more extensively than for an ileal conduit to allow mobility. Ileoileal continuity is completed and the isolated ileal segment is thoroughly washed before putting it back inside the abdomen. The wound is closed to prevent air leakage. The loop is oriented in an isoperistaltic fashion. It is preferable to bring the isolated ileum retroperitoneally. Proximal end is anastomosed to the renal pelvis with 3–0 vicryl sutures starting with the posterior layer first. The distal end of the loop is anastomosed to the bladder with 2–0 vicryl sutures. A drain is placed through the flank port. A Cystogram is done on the 14th day to confirm absence of extravasation and the urethral catheter is removed. In case of totally intracorporeal technique, bowel segment isolation is done using staplers. Rest of the technique is the same as laparoscopy assisted technique.

25.3 Special Situations

If the pelvis is intrarenal or scarred then a ileocalycostomy may be performed.

M. Ramalingam
PSG Hospitals,
Coimbatore, India
e-mail: uroram@yahoo.com

K. Senthil (✉)
Urology Clinic, Gowtham Annexe, Coimbatore, India
e-mail: senthilsatya@hotmail.com

N. Kamat
Kamats Kidney Hospital, Baroda, Gujarat, India

P. Khanderwal
Kamat Hospital, Baroda, India

25.4 Laparoscopy Assisted Ileal Ureter

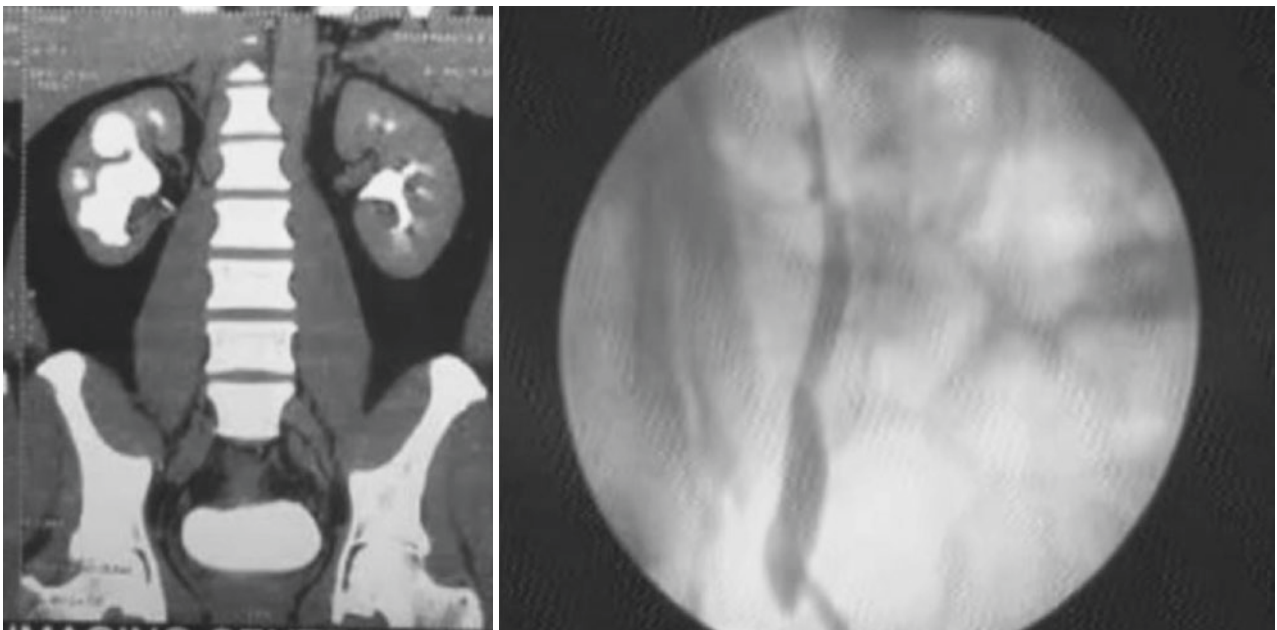


Fig. 25.1 CT showing UPJ obstruction with intra renal pelvis. RGP shows long segment upper ureteric narrowing

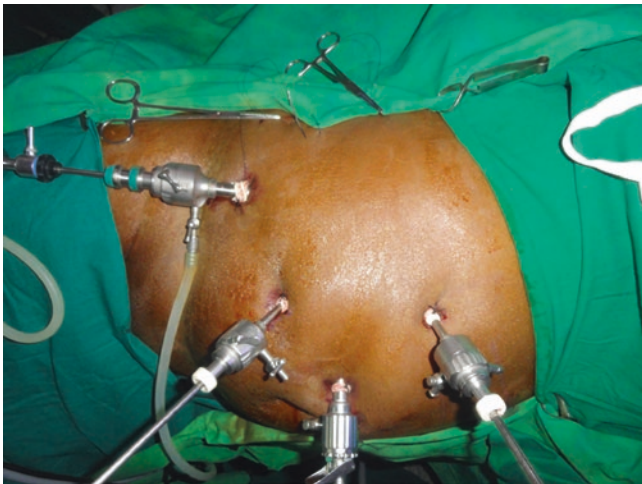


Fig. 25.2 Ports position

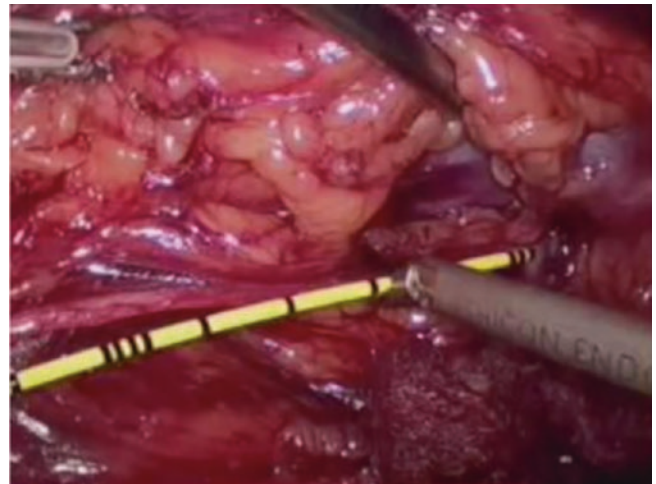


Fig. 25.3 Ureteric catheter used to measure the length of stricture i.e. about 6 cm

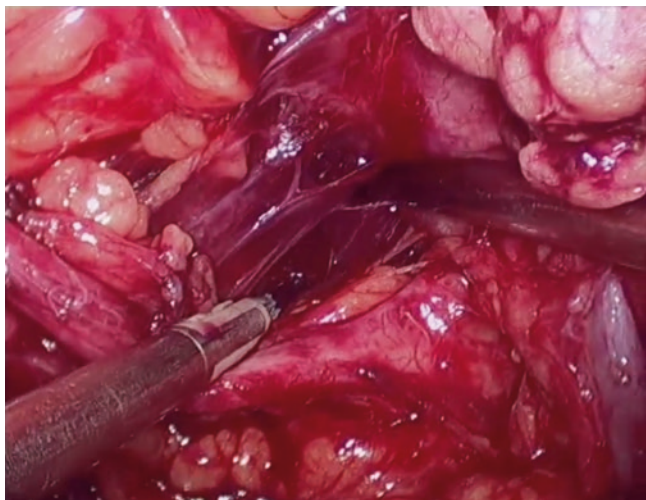


Fig. 25.4 Ureter traced proximally till pelvis

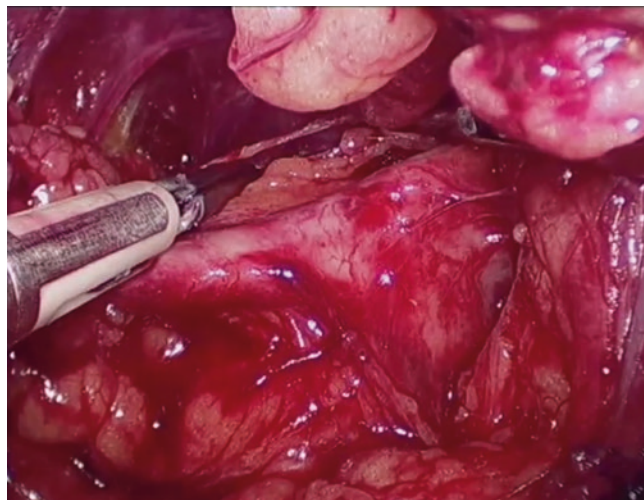


Fig. 25.5 Pelvis dissected and found to be not large enough to reconstruct a long flap pyeloplasty

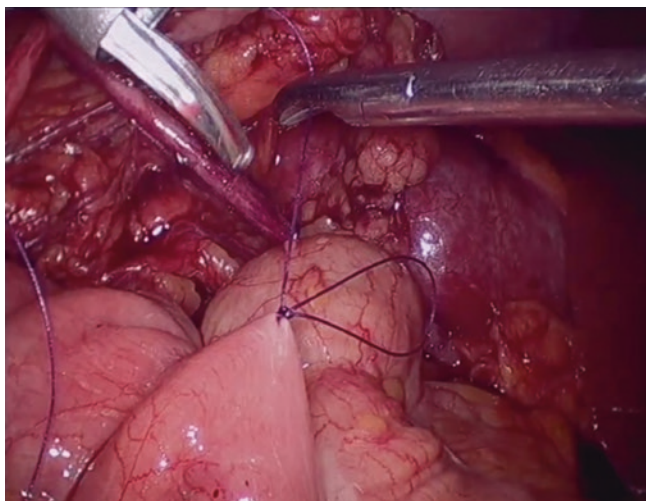


Fig. 25.6 Ileal segment selected and proximal and distal ends marked

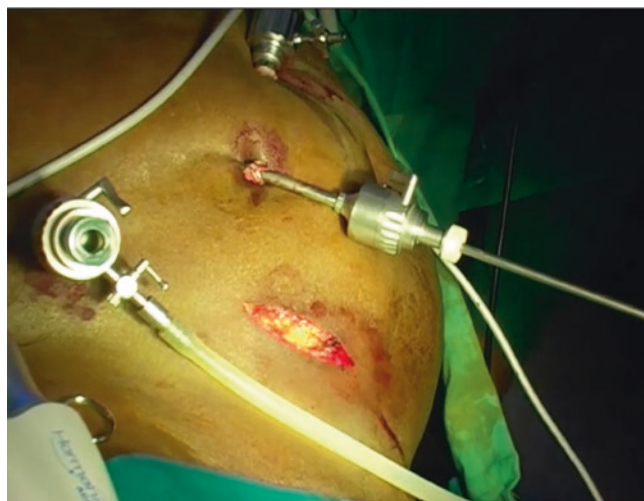

Fig. 25.7 Five cm incision was made in right iliac fossa for isolation of selected ileal segment extracorporeally

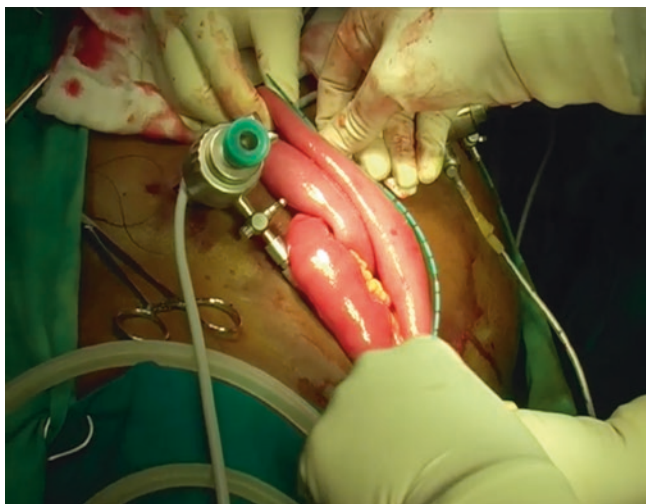


Fig. 25.8 Bowel segment brought out extracorporeally and length marked

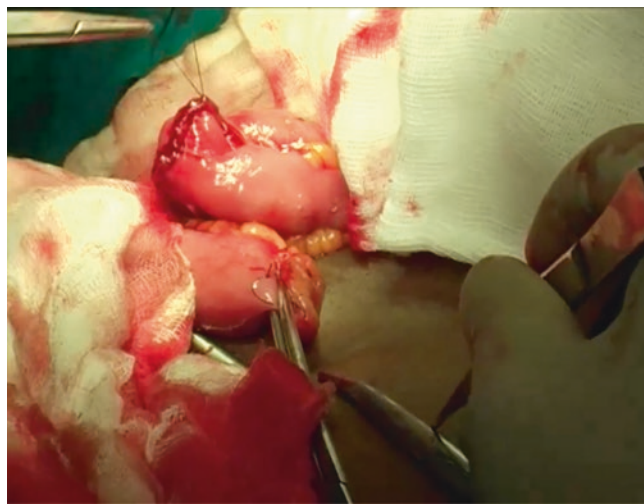


Fig. 25.9 Bowel segment isolated

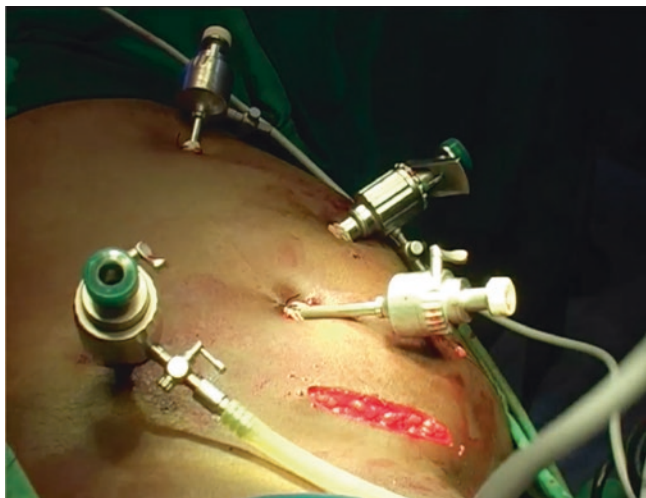


Fig. 25.10 Abdomen closed after intraperitonealising the bowel

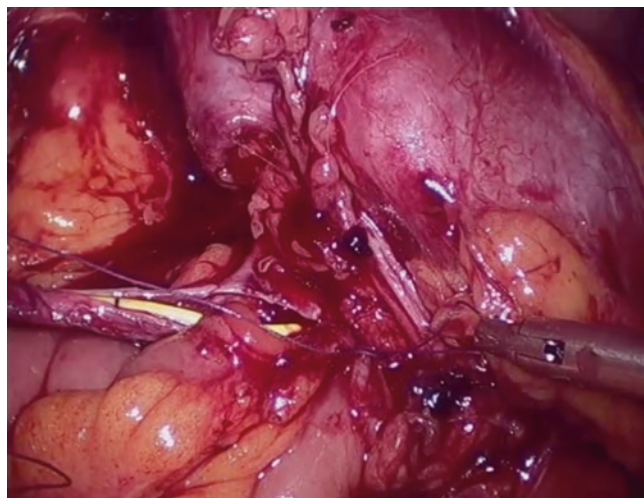


Fig. 25.11 Linear pyelotomy made and pyelo ileal anastomosis started with interrupted 2-0 Vicryl sutures

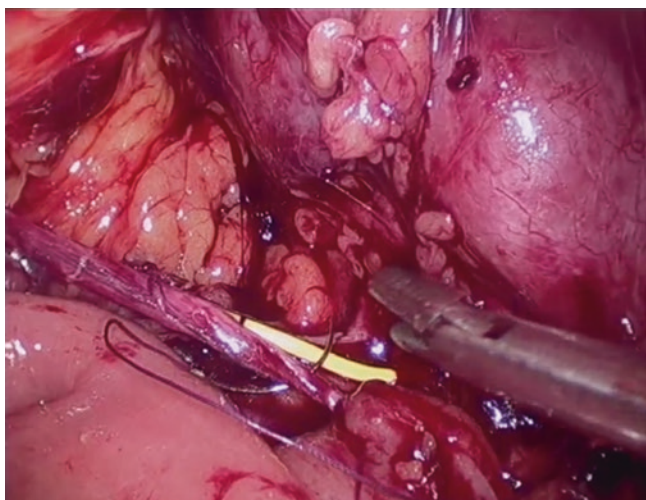


Fig. 25.12 Medial wall suturing in progress

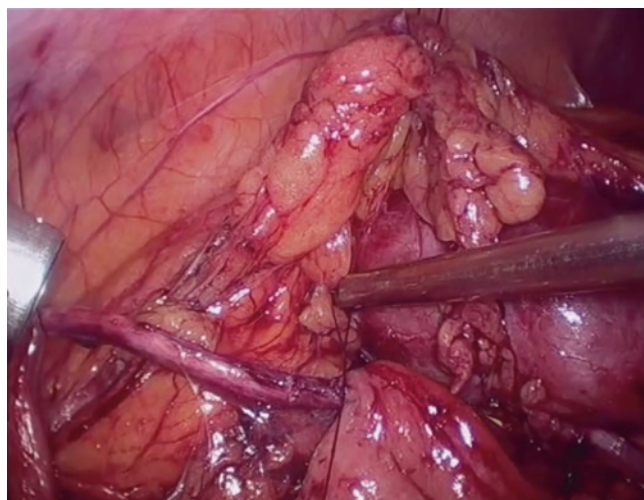


Fig. 25.13 Medial wall suturing complete

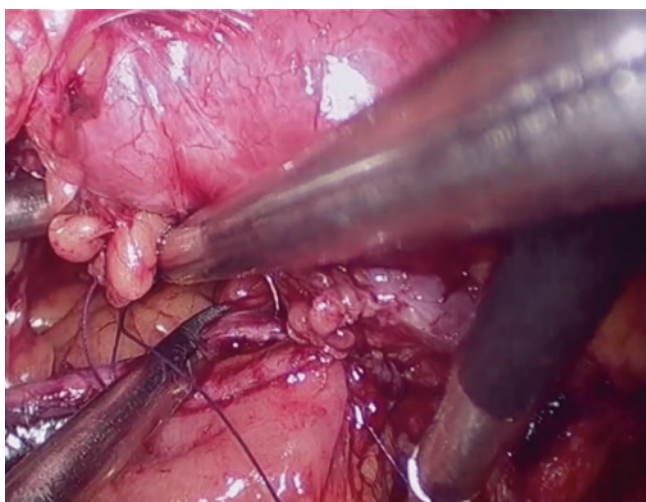


Fig. 25.14 Lateral wall suturing in progress

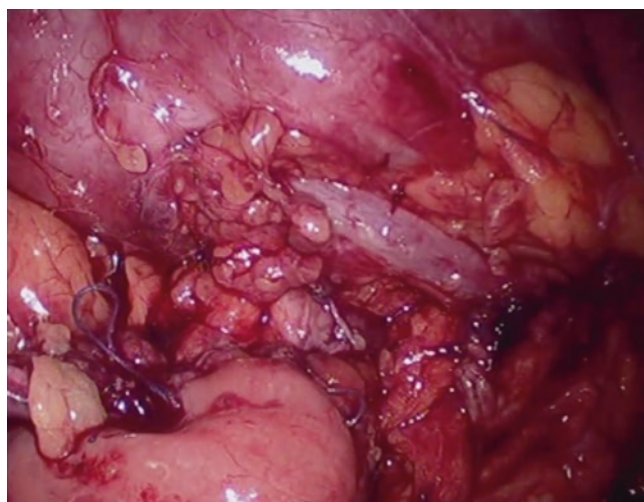


Fig. 25.15 Pyeloileal anastomosis completed

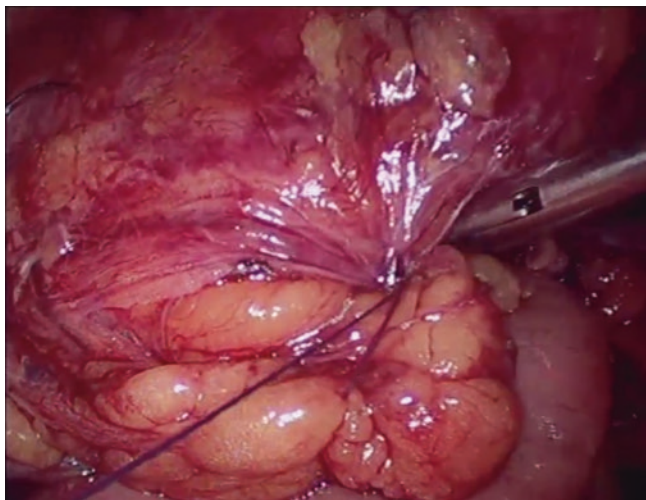


Fig. 25.16 Perinephric fat cover of sutureline

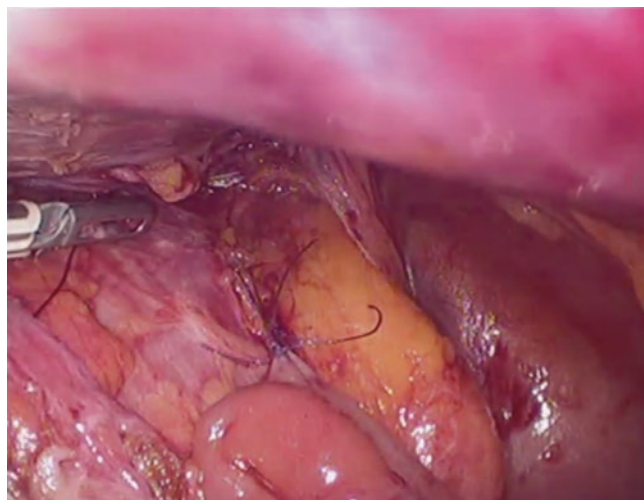


Fig. 25.17 Lower end of isolated ileum tacked to bladder to facilitate anastomosis

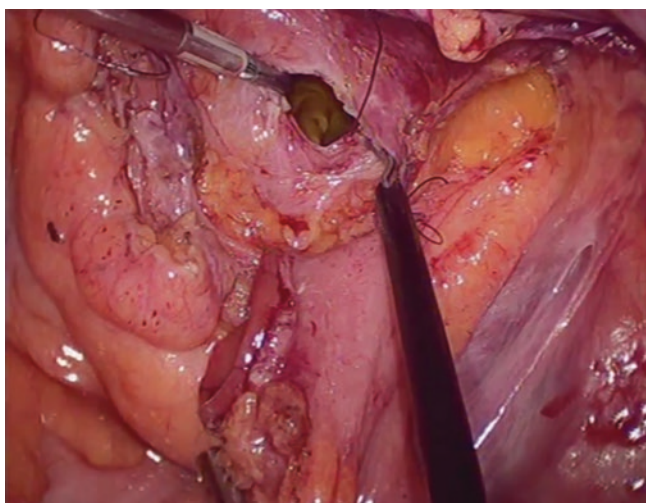


Fig. 25.18 3 cm cystotomy made in the anterior wall for ileal anastomosis

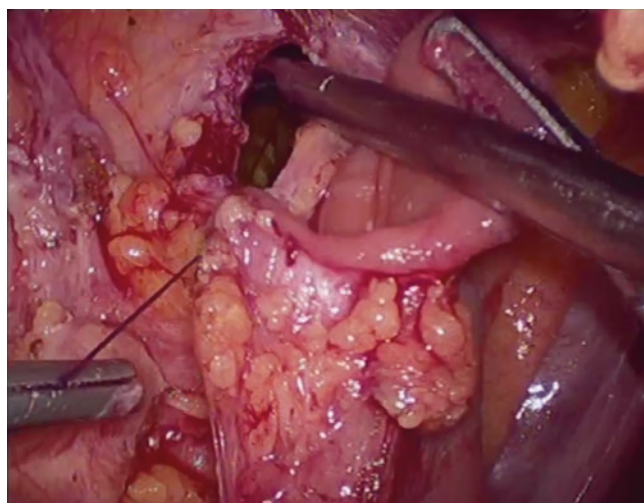


Fig. 25.19 Vesico ileal anastomosis started with interrupted sutures using 2-0 Vicryl

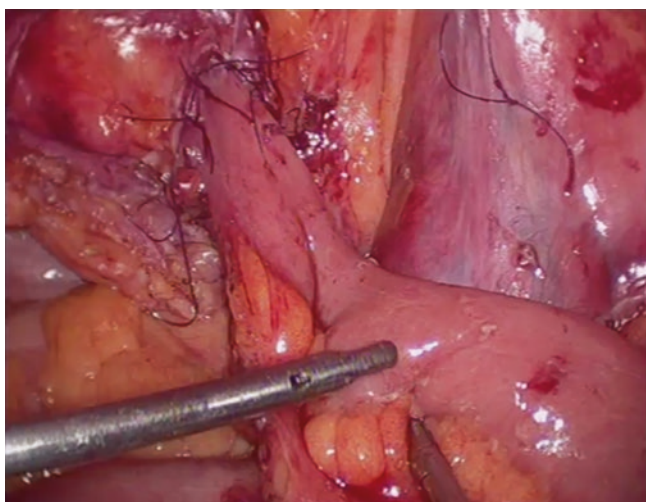


Fig. 25.20 Vesico ileal anastomosis in progress

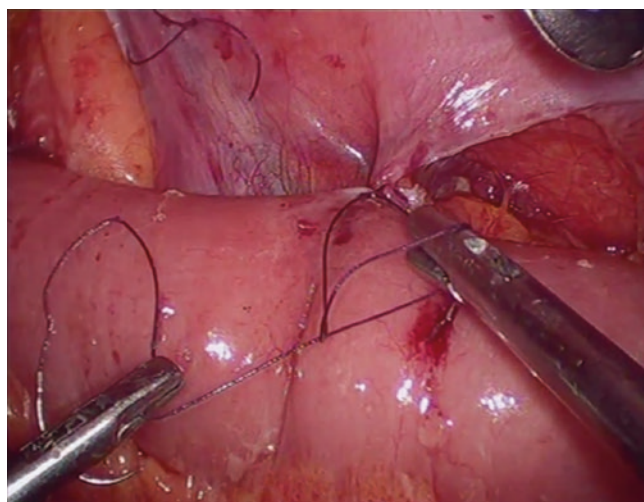


Fig. 25.21 Ileal segment fixed to lateral abdominal wall

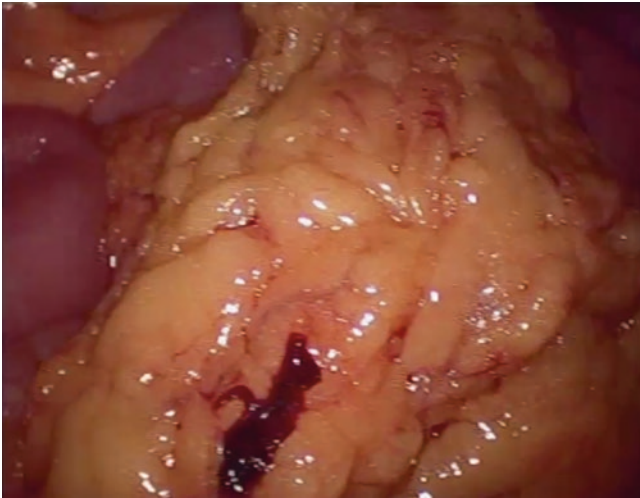


Fig. 25.22 Omental wrapping of anastomosis

References

1. Gill IS, Savage SJ, Sednagore AJ, Sung GT. Laparoscopic ileal ureter. *J Urol.* 2002;163(4):1199–202.
2. Ramalingam M, Senthil K, Pai MG. Modified technique of laparoscopy-assisted surgeries (transportal). *J Endourol.* 2008; 22(12):2681–5. doi:[10.1089/end.2008.0209](https://doi.org/10.1089/end.2008.0209).

Part IV

Reconstructive Procedures of the Urinary Bladder

Manickam Ramalingam, V. Venkatesh,
and Amudha Giridhar

26.1 Introduction

Bladder injuries needing repair can be managed by laparoscopic approach [1–5]. A CT abdomen and cystogram will give an idea of the extent of injury.

26.2 Indications

Isolated bladder ruptures (traumatic or iatrogenic) can be dealt with laparoscopy, if the patient is hemodynamically stable.

26.3 Contraindication

Laparoscopy may be contraindicated when bladder injury is a component of multi-organ injuries or if the patient is unstable.

26.4 Surgical Technique

Urethral catheterisation is done and the Foley's catheter is kept sterile for filling the bladder subsequently. The ports are; 10 mm subumbilical camera port, and two 5 mm working ports in both the iliac fossae. The cranial margin of the bladder laceration is picked up with a dissector and the interior of the bladder is visualized with the laparoscope to rule out any other tear. Edges of the bladder wall needs trimming. Free hand suturing is done with 2–0 polyglactin running suture. Then the bladder is distended gently with 150 ml saline to visualize any leak that can be oversewn. A tube drain is introduced through one of the secondary ports. An indwelling catheter is left for 10 days.

26.5 Conclusion

Whenever the patient's condition allows, laparoscopic cystorrhaphy is preferable as it is a fairly simple and less morbid procedure.

M. Ramalingam (✉)
PSG Hospitals,
Coimbatore, India
e-mail: uroram@yahoo.com

V. Venkatesh
V G Hospital, Coimbatore, India
e-mail: vghospital@eth.net

A. Giridhar
GKNM Hospital,
Papa Nayaken Palayam, Coimbatore 641037, India

26.6 Laparoscopic Repair of Bladder Injuries

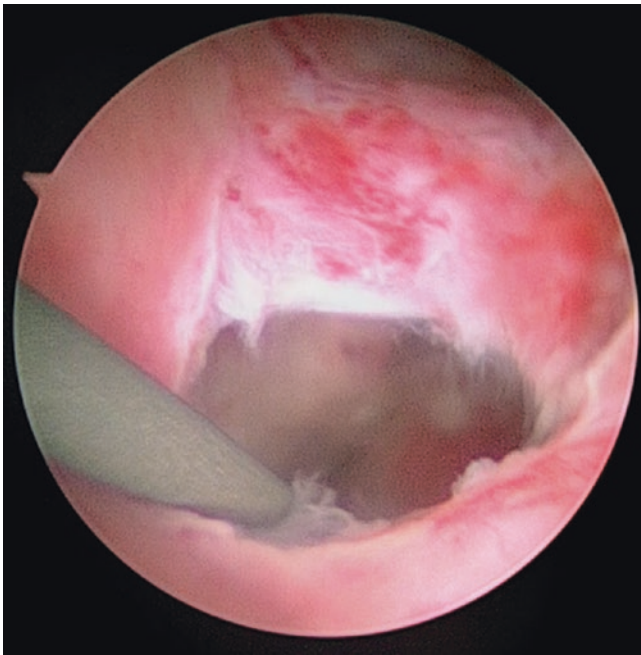


Fig. 26.1 Cystoscopic view of bladder injury (1 week post Lap Hysterectomy). Ureters stented

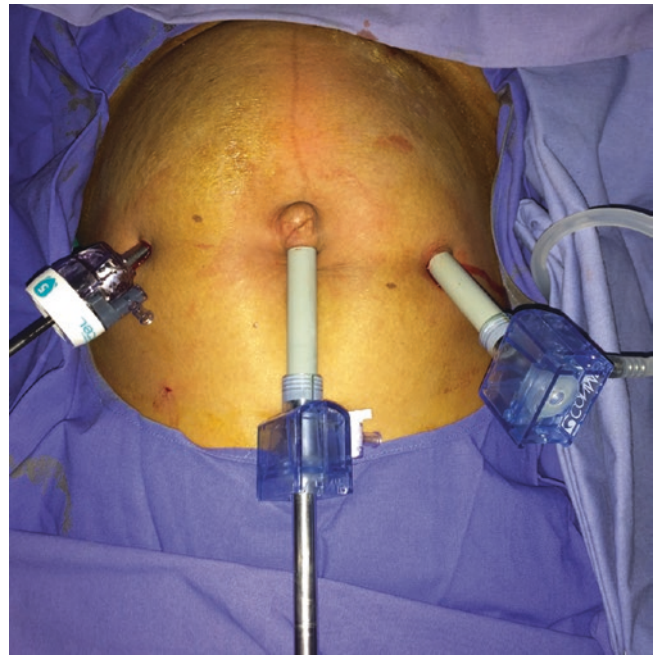

Fig. 26.2 Ports position

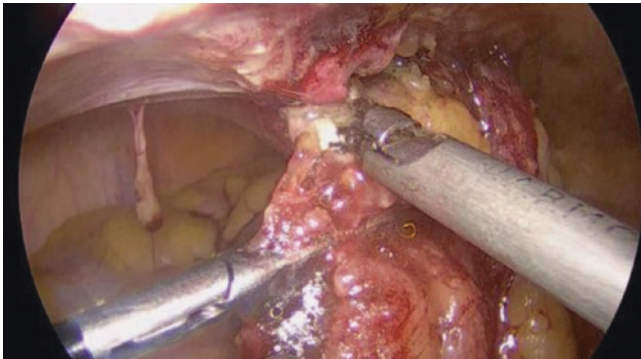


Fig. 26.3 Initial view and adhesiolysis

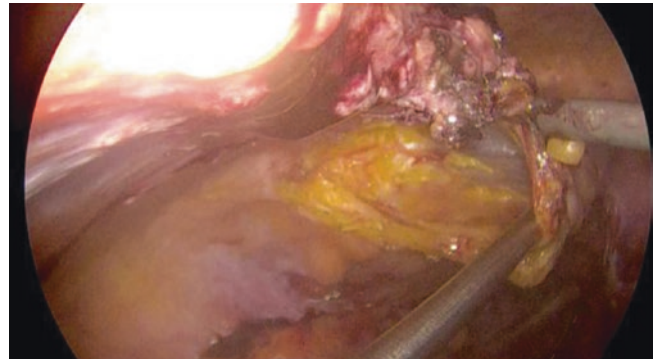


Fig. 26.4 Bladder mobilisation

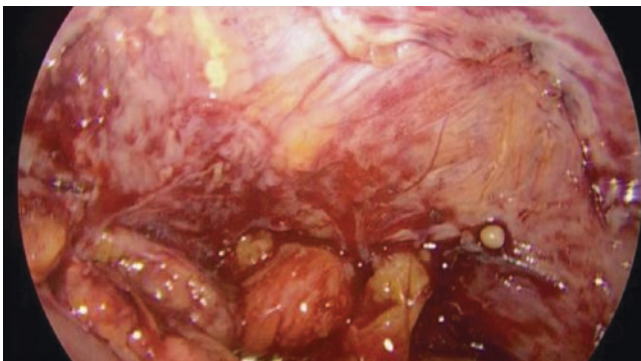


Fig. 26.5 Omentum adherent to bladder at the injury site

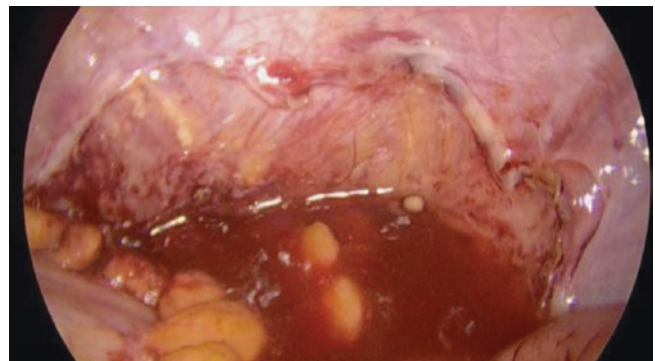


Fig. 26.6 Urine leak on separating omentum

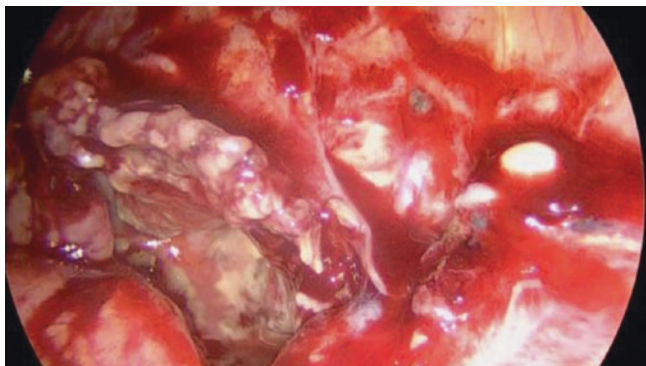


Fig. 26.7 Bladder rent with slough

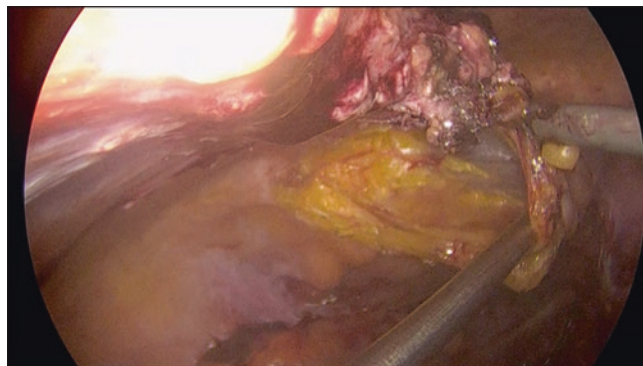


Fig. 26.8 Bladder further mobilised

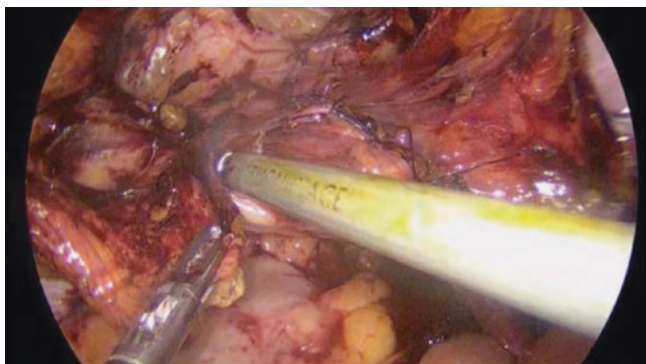


Fig. 26.9 Bladder bivalving started

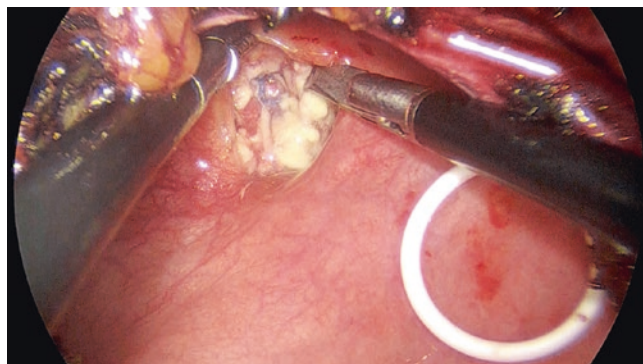


Fig. 26.10 Rent seen from interior of bladder

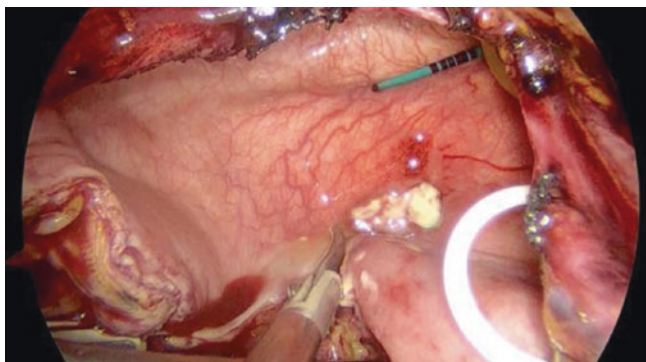


Fig. 26.11 Bladder bivalved till rent

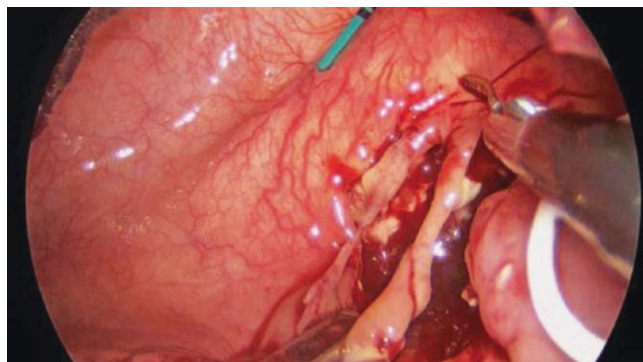


Fig. 26.12 Rent margins freshened

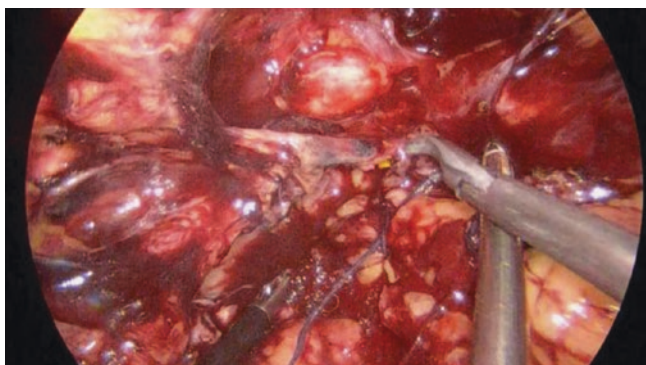

Fig. 26.13 Omentum fixed posterior to bladder

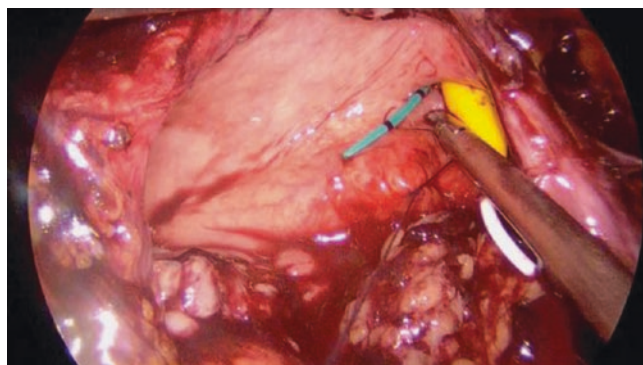


Fig. 26.14 Bladder closure started with 2-0 vicryl suture from posterior end. Stent placed to safeguard ureter

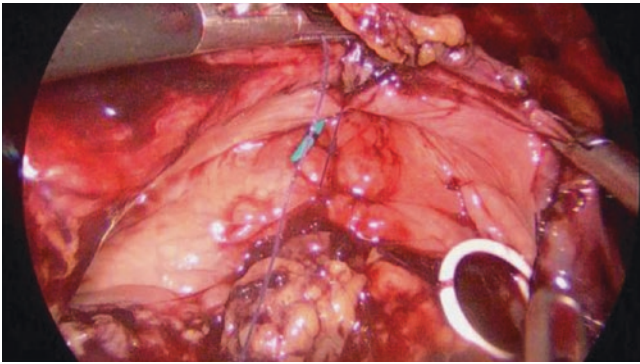


Fig. 26.15 Continuous suture of bladder rent in posterior wall

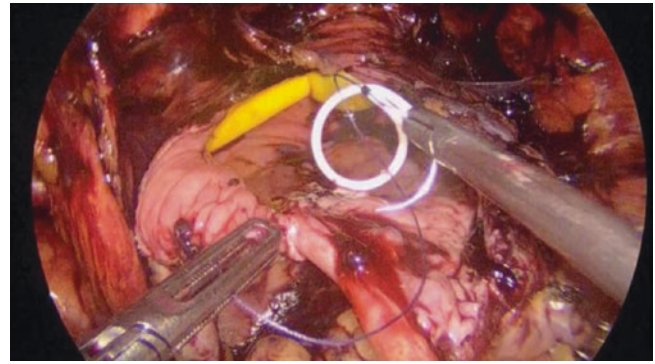


Fig. 26.16 Bladder closure in progress – posterior wall complete

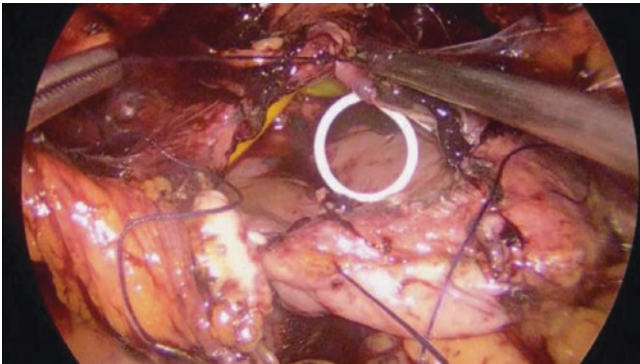

Fig. 26.17 Anterior wall closure started

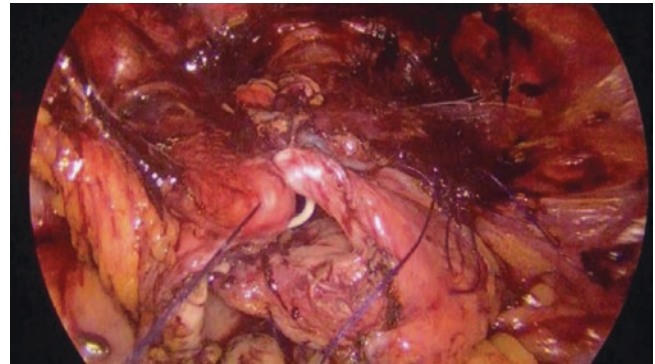


Fig. 26.18 Anterior layer closure in progress

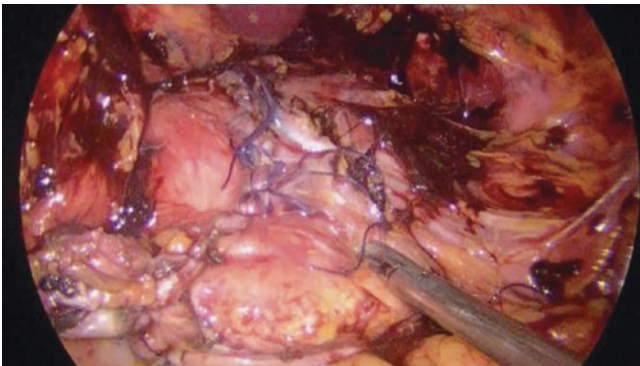


Fig. 26.19 Bladder repair complete

References

1. Appeltans BM, Schapmans S, Willemsen PJ, Verbruggen PJ, Denis LJ. Urinary bladder rupture: laparoscopic repair. *Br J Urol*. 1998;81(5):764–5.
2. Iselin CE, Rohner S, Tuchschnid Y, Schmidlin F, Graber P. Laparoscopic repair of traumatic intraperitoneal bladder rupture. *Urol Int*. 1996;57(2):119–21.
3. Parra RO. Laparoscopic repair of intraperitoneal bladder perforation. *J Urol*. 1994;151:1003–5.
4. Poffenberger RJ. Laparoscopic repair of intraperitoneal bladder injury: a simple new technique. *Urology*. 1996;47:248–9.
5. Reich H, McGlynn F. Laparoscopic repair of bladder injury. *Obstet Gynecol*. 1990;76:909–10.

Manickam Ramalingam, Kallappan Senthil,
and Mizar G. Pai

Laparoscopic bladder diverticulectomy is a challenging procedure [1–4]. Large primary bladder diverticulum with narrow neck is prone for complications like calculi, UTI and malignancy.

27.1 Indication

- (a) Large diverticulum with narrow neck.
- (b) Urachal diverticulum (as it is prone for complications frequently)

27.2 The Diverticulum Is Approched with Caution in the Following Conditions

- (a) Diverticulum adjacent to ureteric orifice.
- (b) Diverticulum lodging tumor.
- (c) In diverticulum secondary to bladder outlet obstruction needing correction of bladder outlet.

27.3 Surgical Technique

Preliminary cystogram and cystoscopy will give a baseline idea about the size and location of the diverticulum and its relation to the ureteric orifice. If the neck of the diverticulum

is close to the ureteric orifice, a ureteric stent is inserted to protect the ureter. The patient is placed in the lithotomy position. A 14 F three way Foley catheter is introduced to distend or empty the bladder as and when needed. Using an umbilical camera port and two ports in the midclavicular line one on each side 5 cm below and lateral to umbilicus, the bladder diverticulum is approached transperitoneally. Identification of the diverticulum is made easier by distending the bladder.

An incision is made in the peritoneum over the diverticulum, and the diverticulum is exposed. The dome of the diverticulum is pulled using a grasper, and a circumferential dissection of its neck is performed. The diverticulum is divided at the level of neck using electrocautery or ultracision. The specimen can be left in the rectovesical or rectovaginal pouch to be retrieved at the end. The bladder defect is then repaired with continuous 3-0 barbed suture. The bladder is then filled with saline to confirm a water-tight closure, and a drain is placed under direct vision. The excised diverticulum is removed through the 10 mm port.

27.4 Postoperative Followup

Cystogram is done on the tenth post operative day to check for any extravasation. Urethral foley catheter can be removed if there is no extravasation.

M. Ramalingam (✉)
PSG Hospitals,
Coimbatore, India
e-mail: uroram@yahoo.com

K. Senthil
Urology Clinic, Gowtham Annexe, Coimbatore, India
e-mail: senthilsatya@hotmail.com

M.G. Pai
Urology Clinic, 3/1054, Gowtham Annexe, Avinashi Road,
Coimbatore 641018, India
e-mail: mizargpai@yahoo.co.in

27.5 Laparoscopic Bladder Diverticulectomy

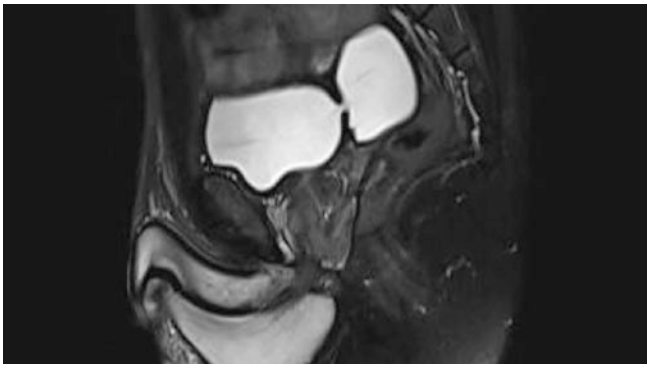


Fig. 27.1 CT scan showing bladder diverticulum

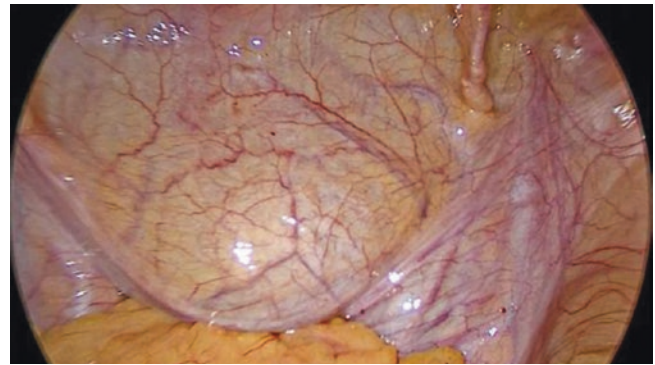


Fig. 27.2 Initial view of bladder

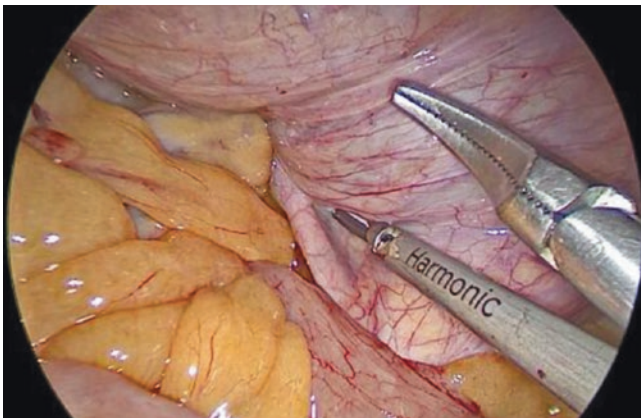


Fig. 27.3 Ureter seen posterior to diverticulum – close to the neck of the diverticulum

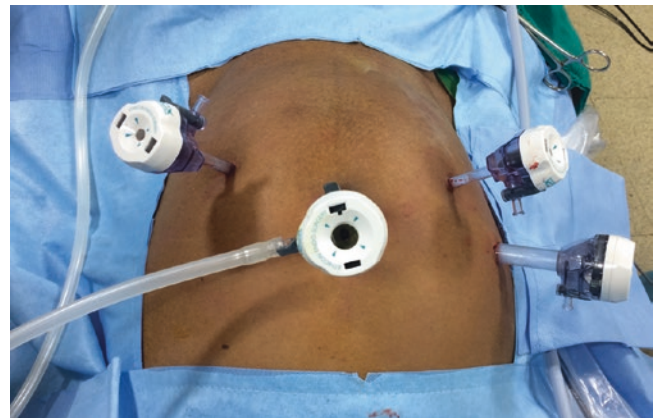


Fig. 27.4 Ports position

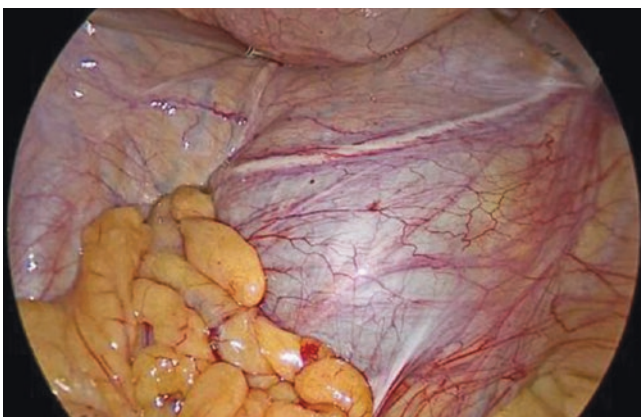

Fig. 27.5 Diverticulum seen posterolateral (*right*) to bladder – vas crossing over it

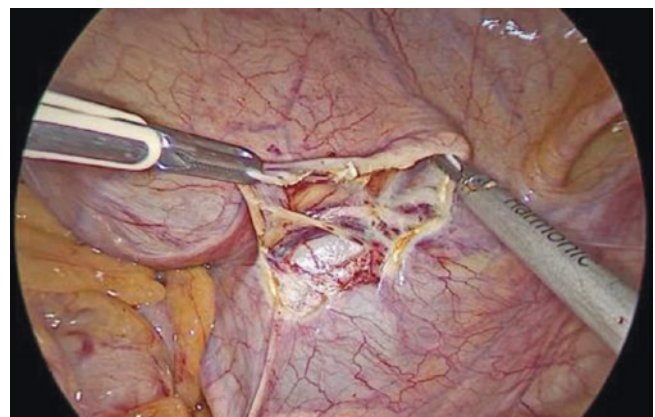


Fig. 27.6 Peritoneum over the diverticulum being incised

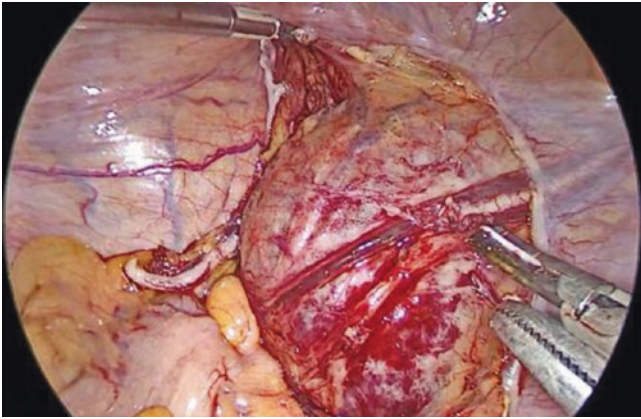


Fig. 27.7 Diverticulum dissection in progress – superior surface

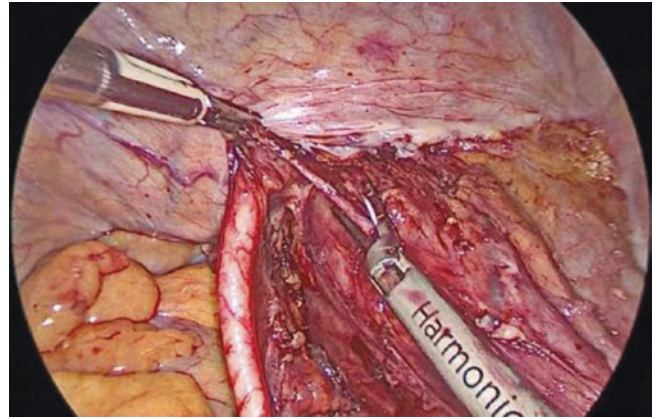


Fig. 27.8 Diverticular dissection in progress – medial surface

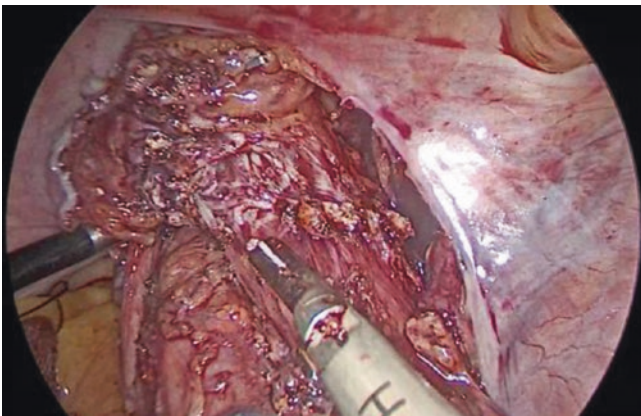


Fig. 27.9 Diverticulum neck defined

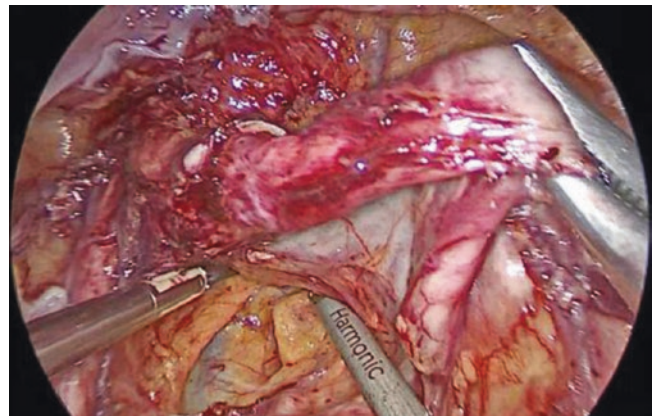


Fig. 27.10 Diverticulum dissection in progress – posterior surface

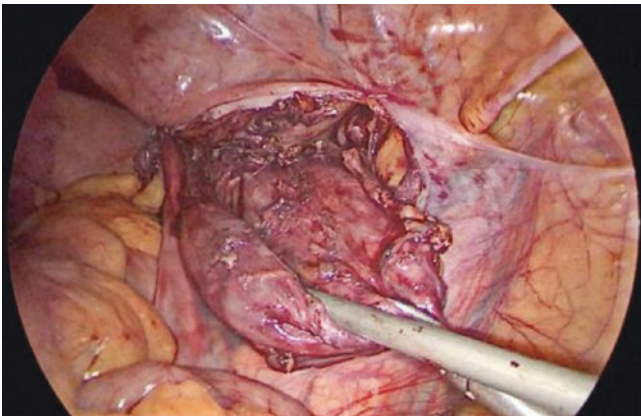


Fig. 27.11 Diverticulum dissection almost complete

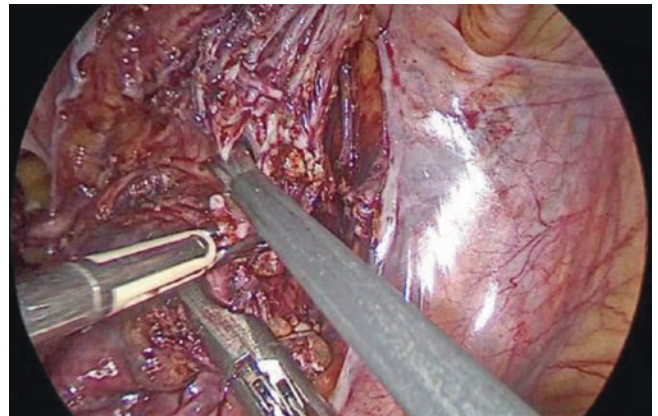


Fig. 27.12 Diverticulum neck being opened

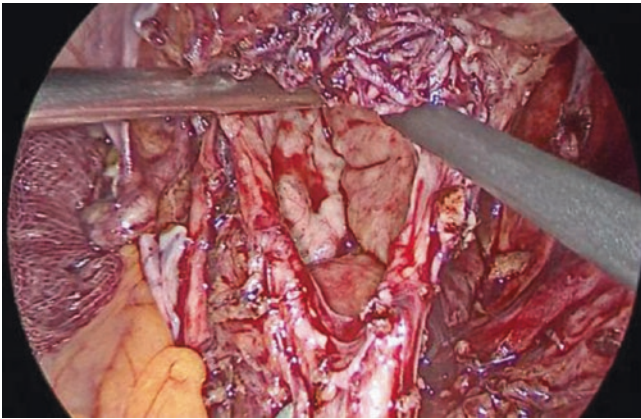


Fig. 27.13 Diverticulum neck opened

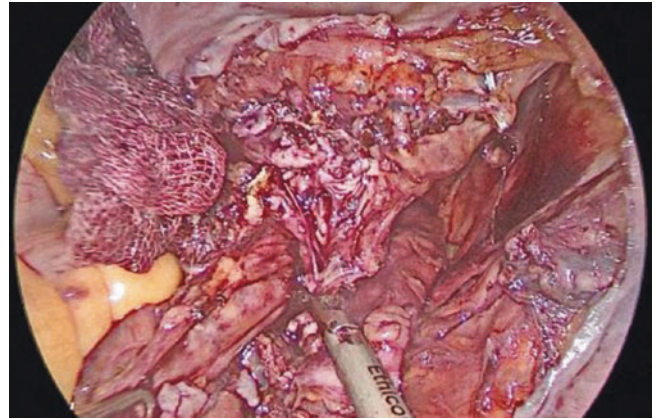


Fig. 27.14 Diverticulum excision in progress

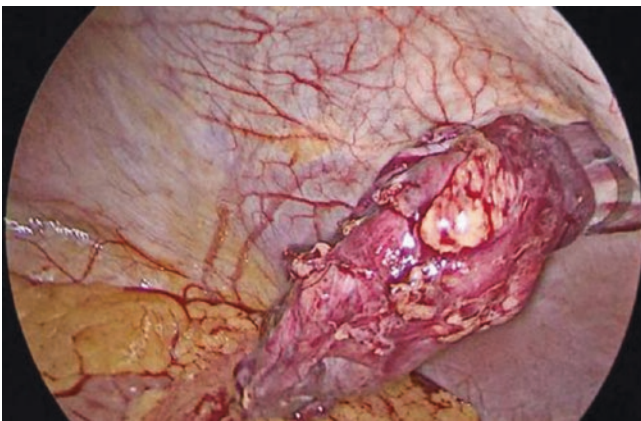

Fig. 27.15 Diverticulum being retrieved through 12 mm port

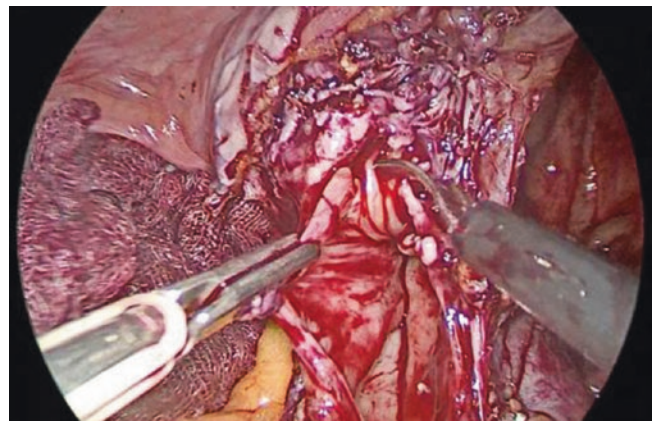


Fig. 27.16 Diverticulum excision in progress

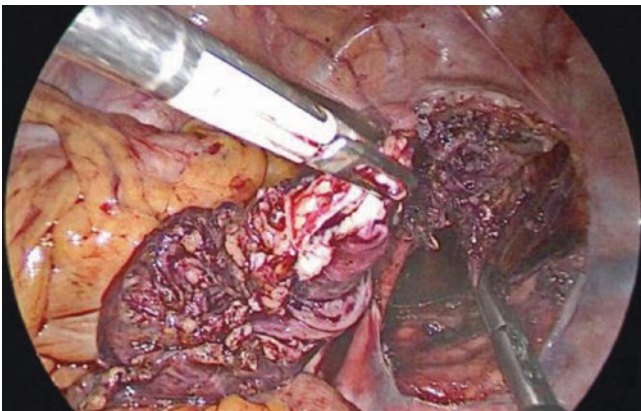

Fig. 27.17 Diverticulum excised

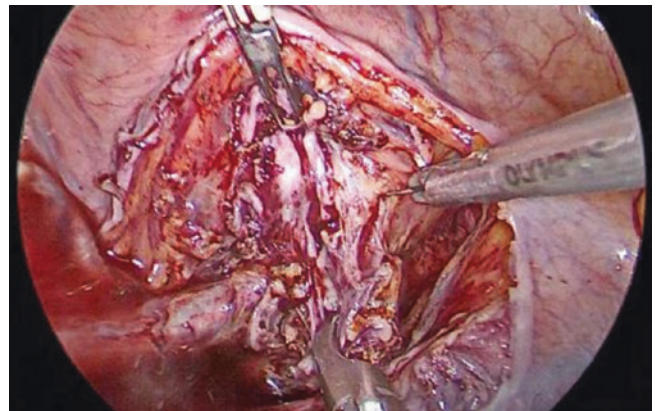


Fig. 27.18 Bladder rent closed with 3-0 v loc sutures

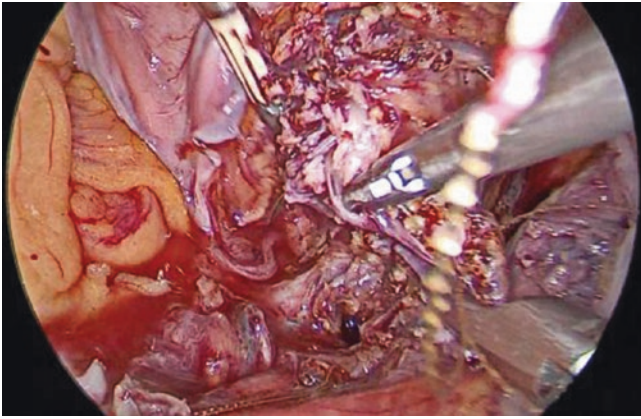


Fig. 27.19 Rent closure in progress

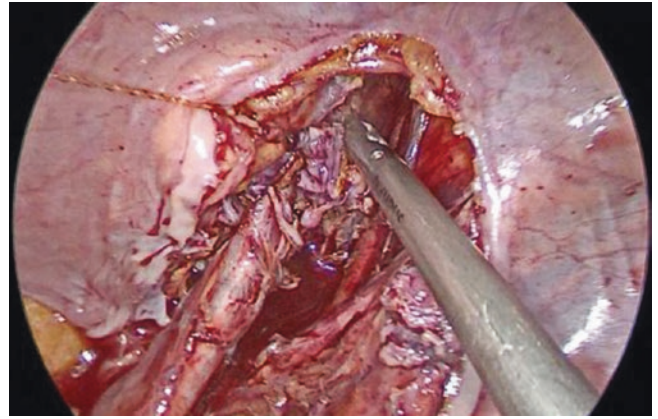


Fig. 27.20 Rent closure complete

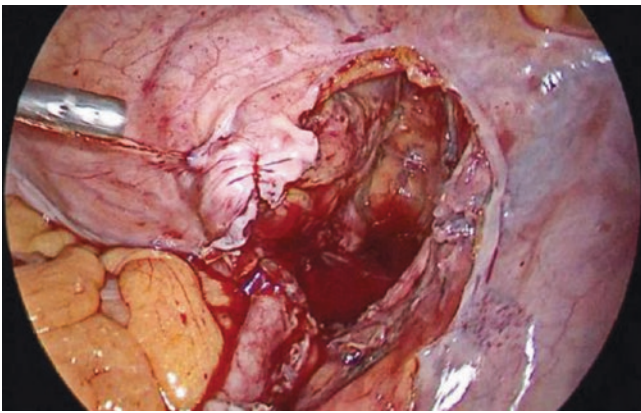


Fig. 27.21 Second layer closure in progress

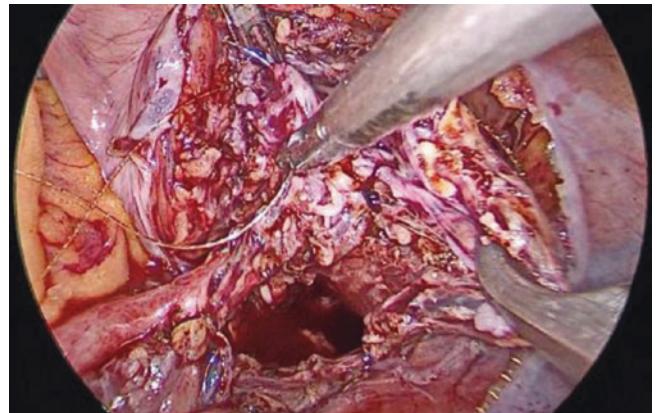


Fig. 27.22 Rent closure in progress

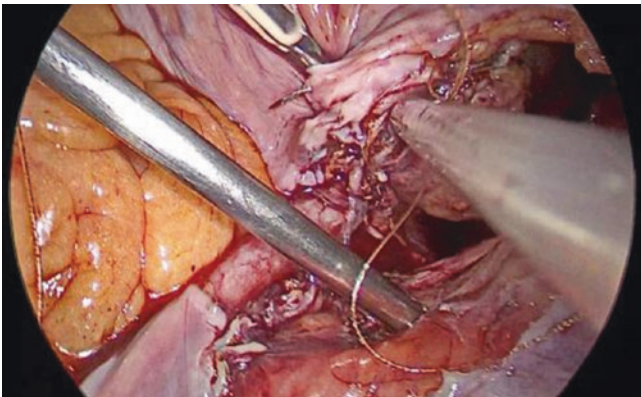


Fig. 27.23 Second layer closure in progress

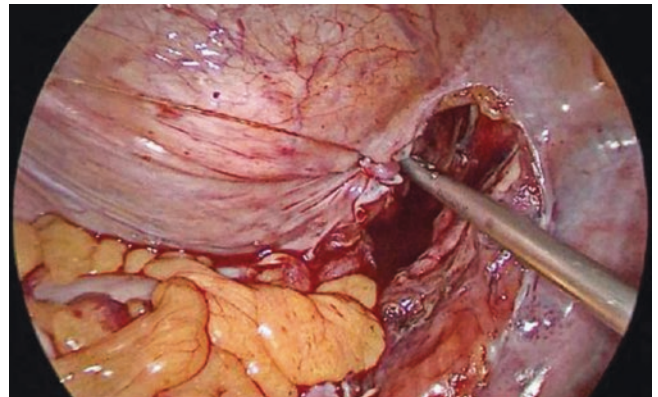


Fig. 27.24 Closure completed

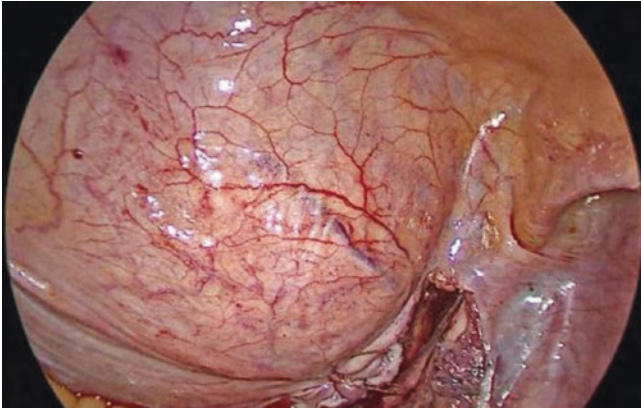


Fig. 27.25 Integrity of closure checked with bladder fill

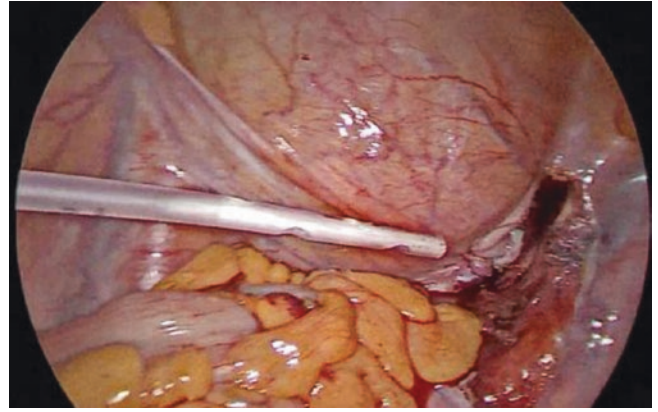


Fig. 27.26 Drain placed

References

1. Champault G, Riskalia H, Rizk N, et al. Laparoscopic resection of a bladder diverticulum. *Prog Urol*. 1997;7:643.
2. Das S. Laparoscopic removal of bladder diverticulum. *J Urol*. 1992;148:1837.
3. Foncillas J, Sacristan J, Blasco FJ, et al. Laparoscopic bladder diverticulectomy. *Actas Urol Esp*. 1993;7(3):10.
4. Rozenberg H, Abdelkader T, Hussein AA. Laparoscopic excision of a voluminous bladder diverticulum. *Prog Urol*. 1994;4:91.

Vipul R. Patel and Hariharan Palayapalayam Ganapathi

28.1 Introduction

Diverticulum is usually congenital, or associated with bladder outlet obstruction. Laparoscopic diverticulectomy is an established procedure for bladder diverticulum. Better vision, precise dissection and easier suturing with robot assisted approach will make the procedure 'easier' for the surgeons.

28.2 Indications and Evaluation

The indication and evaluation is similar to the laparoscopic approach.

28.3 Technique

Patient is placed in low lithotomy position with steep Trendelenberg tilt. Port position is similar to that of radical prostatectomy, except the absence of 5 mm assistant port in the hypochondrium. Side docking of the robot (as in gynecological procedures) is preferred. This helps in performing per operative cystoscopic illumination of the bladder during dissection. In most cases, ureter is entering close to the neck of the diverticulum. Hence the ureter is initially dissected and traced till the diverticulum neck. The diverticulum is identified by bladder filling and it is dissected all around. The diverticulum neck is identified by the narrowing of diverticu-

lum close to the neck, aided by cystoscopic bladder illumination. Diverticulum neck is incised and diverticulum completely disconnected from the bladder 'under vision', taking care to preserve the ureteric orifice close to the neck. Neck is closed in two layers and the diverticulum is excised. Drain is placed. Urethral catheter is retained for 7–10 days and removed.

28.4 Discussion

The first published report of robot assisted bladder diverticulectomy [1]. The ease of water tight suturing with the robot is the benefit proposed, in lieu of classical laparoscopic approach [2]. The cystoscope illumination assisted robotic diverticulectomy [3]. This approach helps in easier identification of diverticulum neck and also helps continuous monitoring of the dissection close to ureteric orifice. Diverticulectomy can very well be combined with TURP or photo vapourisation of prostate [4]. Daviduik et al. have reported no Clavein Grade 3 or 4 complications in their series of patients undergoing robot assisted bladder diverticulectomy [5]. This confirms the feasibility of this approach with results comparable to open surgery.

Conclusion

Robot assisted bladder diverticulectomy provides a success rate similar to open approach with minimally invasive benefit to patients and ergonomic benefit to surgeons.

V.R. Patel (✉) • H.P. Ganapathi
University of Central Florida College of Medicine,
Global Robotics Institute, Florida Hospital Celebration Health,
410 Celebration Place, Orlando, FL 34747, USA
e-mail: Vipul.Patel.MD@fhosp.org

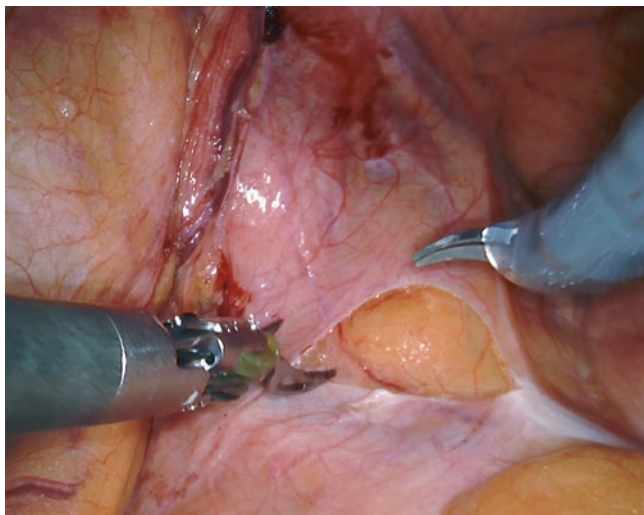


Fig. 28.1 Peritoneal incision over the diverticulum

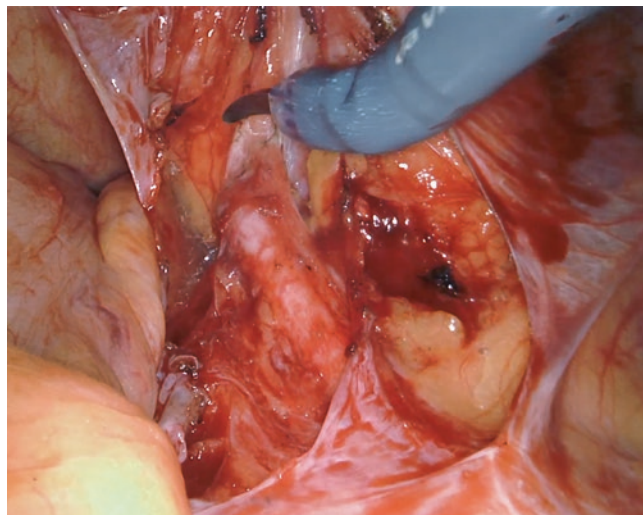


Fig. 28.2 Ureter identified close to diverticulum

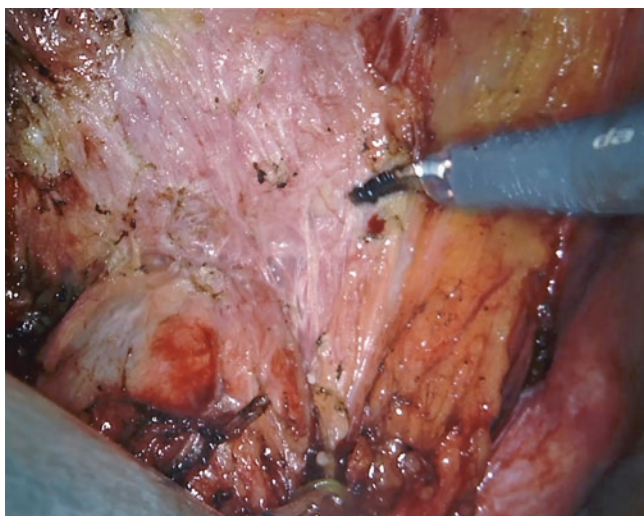


Fig. 28.3 Dissection of diverticulum in progress

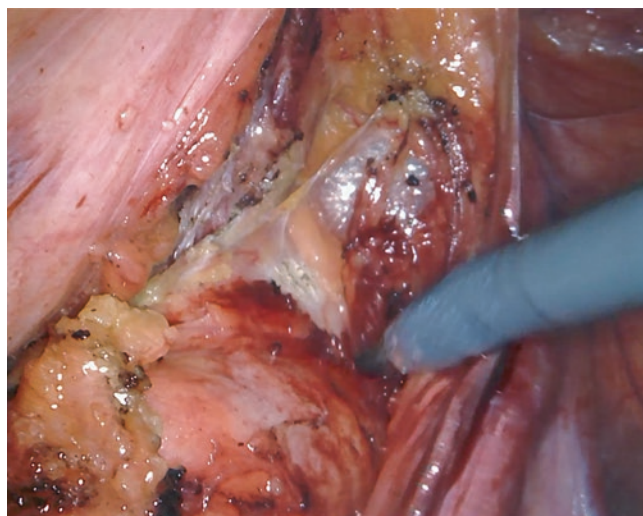


Fig. 28.4 Dissection of diverticulum in the anterolateral aspect

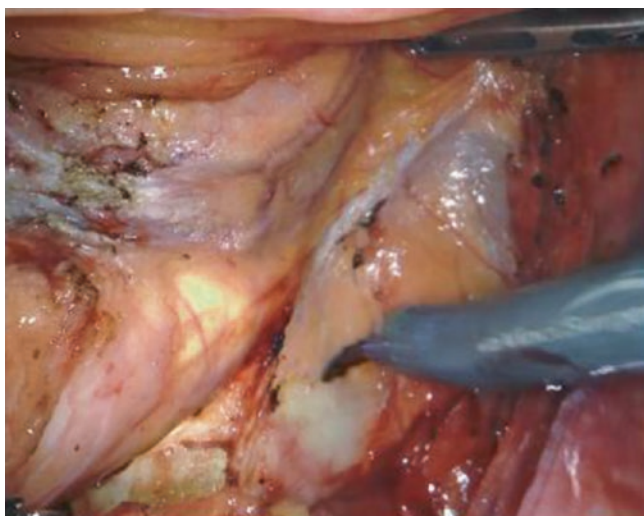


Fig. 28.5 Dissection of diverticulum in progress – cystoscopic illumination of diverticulum made out

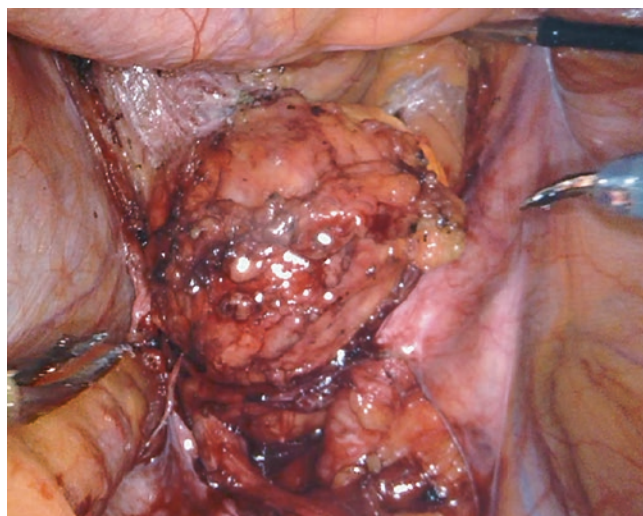


Fig. 28.6 Peripheral dissection of diverticulum complete

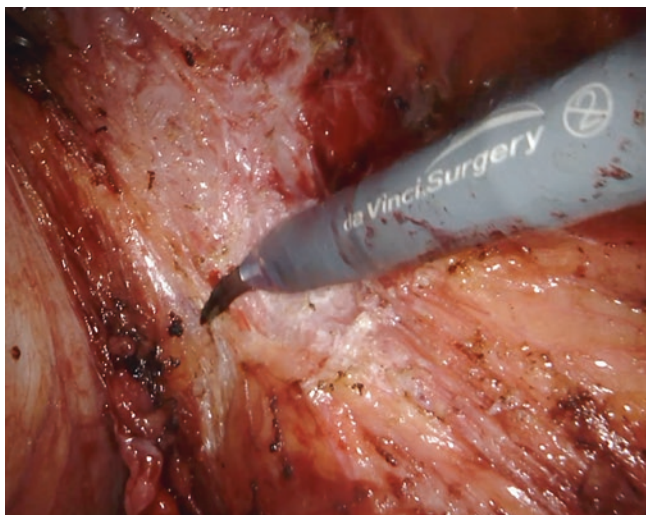


Fig. 28.7 Dissection close to neck of diverticulum

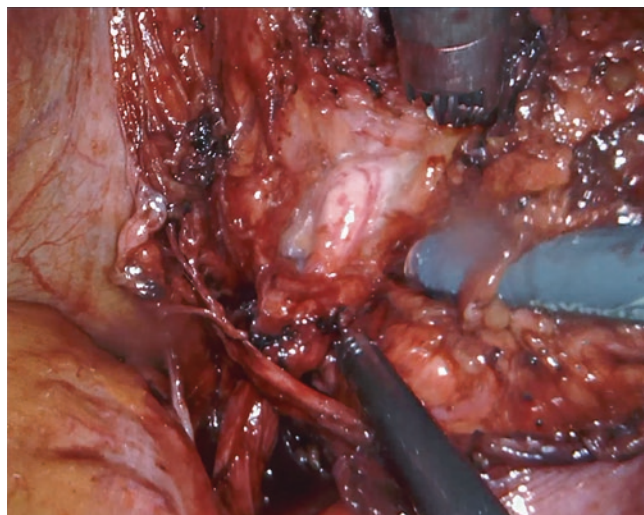


Fig. 28.8 Ureter seen entering close to diverticulum neck

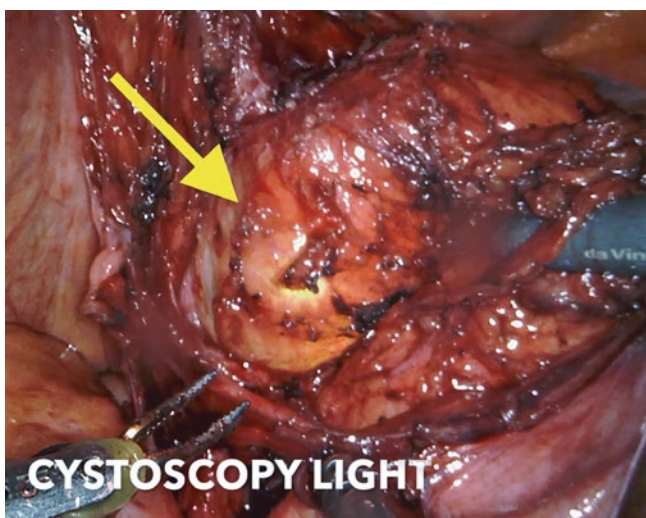


Fig. 28.9 Cystoscopy light seen through diverticulum

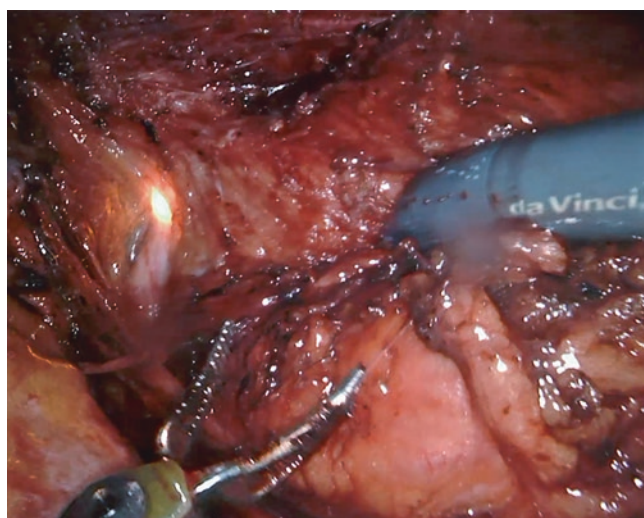


Fig. 28.10 Neck of the diverticulum identified

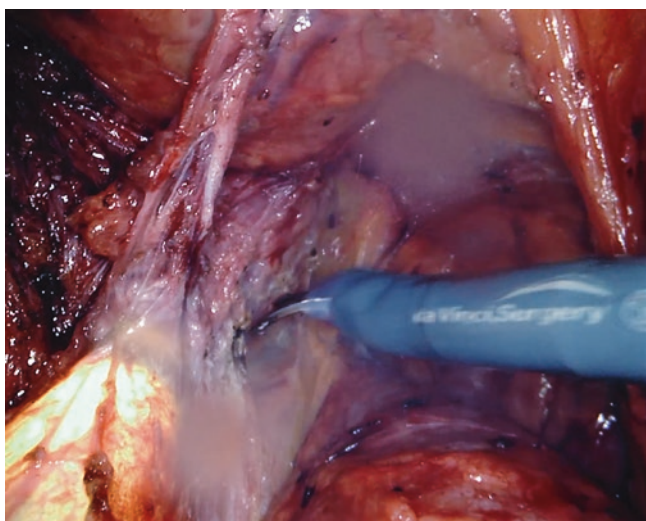


Fig. 28.11 Dissection of the posterior aspect of neck of diverticulum

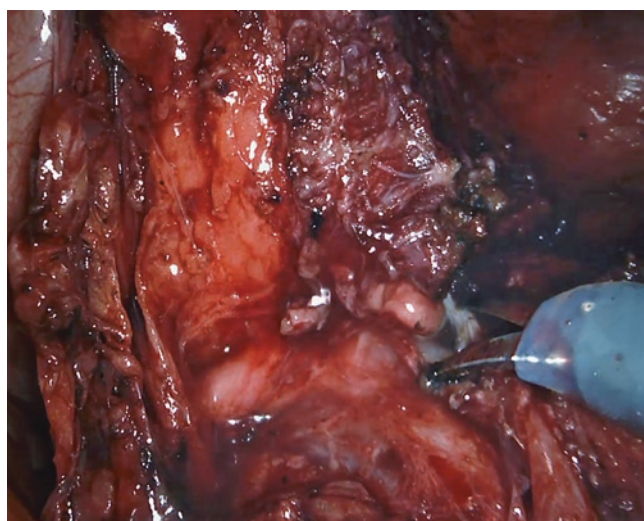


Fig. 28.12 Diverticulum neck being divided

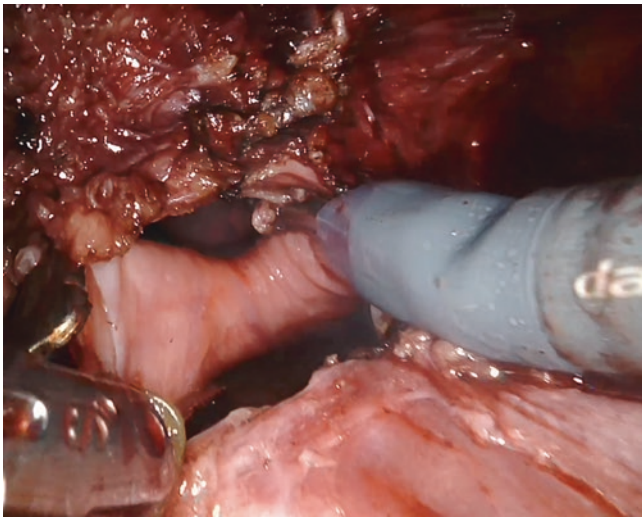


Fig. 28.13 Diverticulum excision in progress

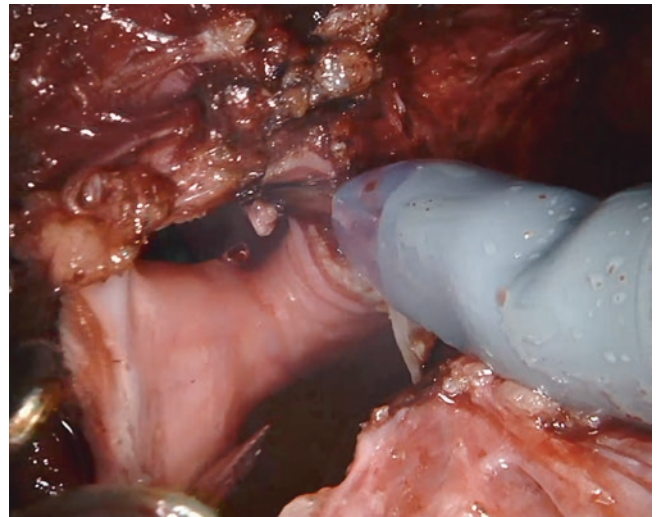


Fig. 28.14 Ureteric orifice with urine jet seen at the neck of the diverticulum

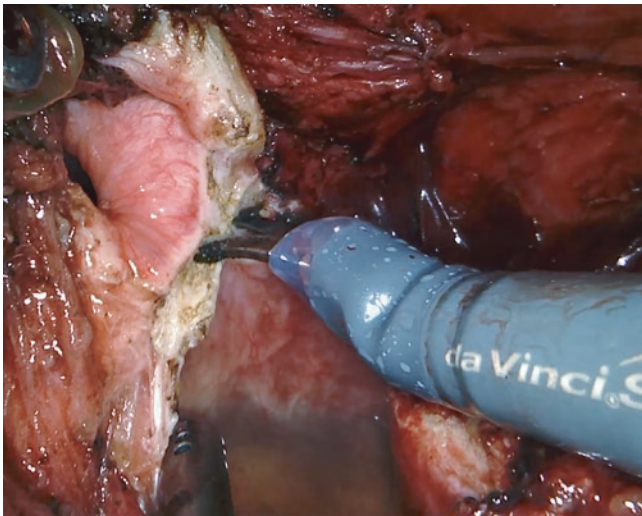


Fig. 28.15 Diverticulum excision in progress

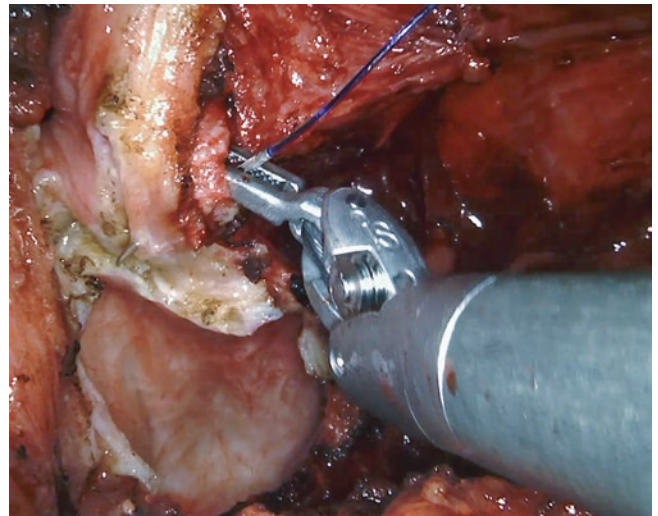


Fig. 28.16 Closure of bladder rent with 3-0 PDS started

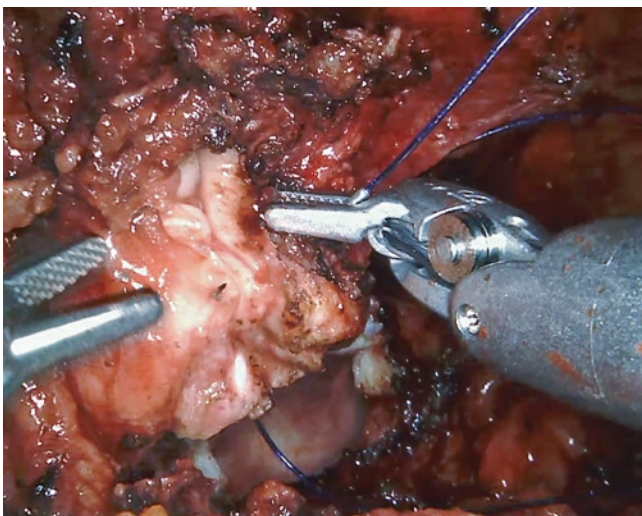


Fig. 28.17 Closure in progress

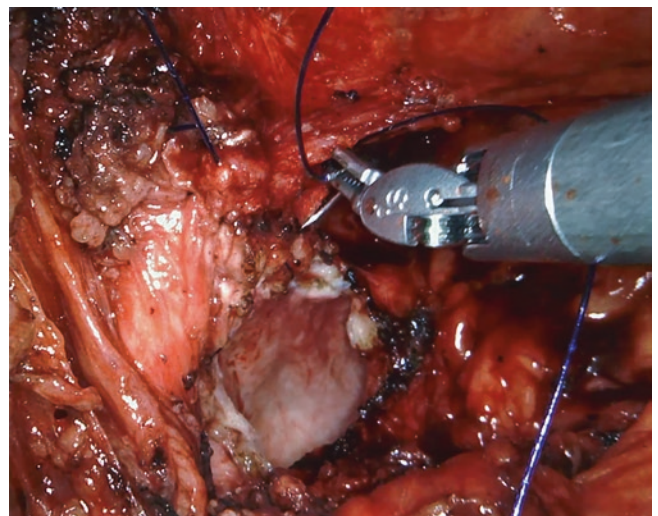


Fig. 28.18 Closure in progress

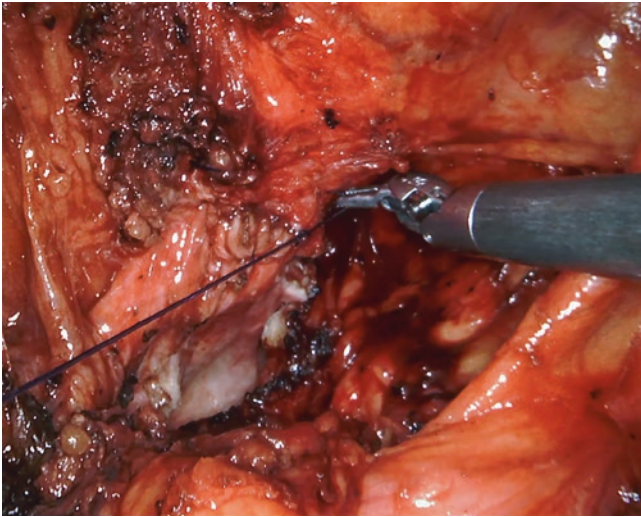


Fig. 28.19 Closure complete

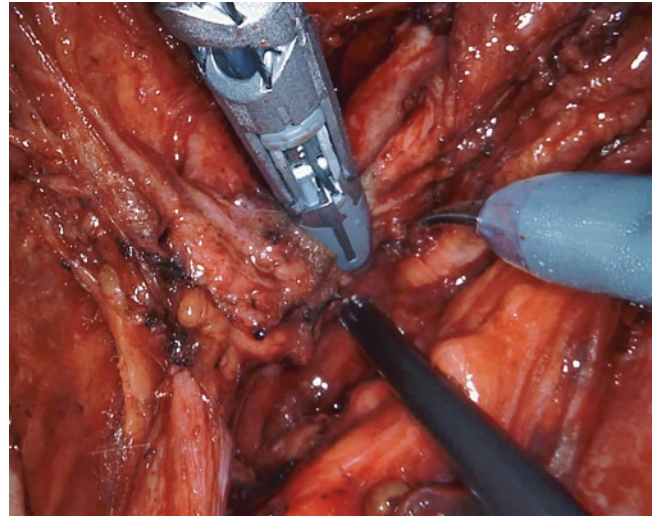


Fig. 28.20 Diverticulum being excised

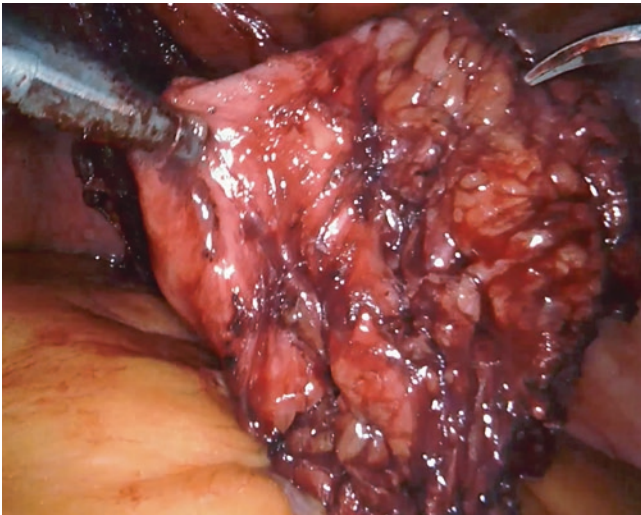


Fig. 28.21 Excised diverticulum

References

1. Rao R, Nayyar R, Panda S, Hemal AK. Surgical techniques: robotic bladder diverticulectomy with the da Vinci-S surgical system. *J Robot Surg.* 2007;1(3):217–22.
2. Moreno Sierra J, Galante-Romo I, Ortiz-Oshiro E, Castillon-Vela IT, Fernandez-Perez C, Silmi-Moyano A. Bladder diverticulum robotic surgery: systematic review of case reports. *Urol Int.* 2010; 85(4):381–5.
3. Macejko AM, Viprakasit DP, Nadler RB. Cystoscope- and robot-assisted bladder diverticulectomy. *J Endourol.* 2008;22(10):2389–91.
4. Kural AR, Atug F, Akpınar H, Tufek I. Robot-assisted laparoscopic bladder diverticulectomy combined with photoselective vaporization of prostate: a case report and review of literature. *J Endourol.* 2009;23(8):1281–5.
5. Davidiuk AJ, Meschia C, Young PR, Thiel DD. Robotic-assisted bladder diverticulectomy: assessment of outcomes and modifications of technique. *Urology.* 2015;85(6):1347–51.

Manickam Ramalingam, C. Mallikarjuna,
and Suma Natarajan

29.1 Introduction

Open transabdominal and transvaginal approaches for repair of vesicovaginal fistula (VVF) are well described [1, 2]. Currently laparoscopic approach is widely practised in the repair of vesicovaginal fistula [5–9]. Transvesical transurethral repair has been described by Mc Kay et al. [3, 4], wherein he used a transurethral port for suturing. The repair continues to be a challenge even by open technique as recurrence results in about 5–10%. VVF due to obstetric causes are repaired 3 months after the onset of vaginal urinary leak. However iatrogenic VVF following pelvic surgery can be managed earlier as there is no ischemia to tissues.

29.2 Surgical Technique

Preliminary evaluation includes IVU/CT urogram and cystoscopy to know the location and relation of VVF to the ureteric orifice and to rule out an associated ureterovaginal fistula.

29.2.1 Transperitoneal Approach (O'Connor's Technique)

Cystoscopy and ureteric stenting is done for protection of ureteric orifice and ureters. Patient is placed in lithotomy position.

M. Ramalingam
PSG Hospitals,
Coimbatore, India
e-mail: uroram@yahoo.com

C. Mallikarjuna (✉)
Asian Institute of Nephrology and Urology,
Hyderabad, Telangana, India
e-mail: mallikuro7@gmail.com

S. Natarajan
Department of Obstetrics and Gynecology, Ganga Women and
Child Centre, Coimbatore, India

Optimum sized three way urethral catheter is left in and kept sterile and accessible for subsequent bladder filling. Four ports (a 10 mm supra umbilical camera port, two 5 mm ports in each midclavicular line for hand instruments and one 5 mm suprapubic port for suction and irrigation) are used. Cystotomy is done in the midline using electrocautery or ultracision till the edge of the fistula. Subsequently adequate mobilization of bladder wall from vaginal wall is done. The fistula is excised with cold scissors. The bladder defect and vaginal defect are trimmed. Initially the vaginal defect is closed horizontally using interrupted 3–0 absorbable monofilament sutures. Whenever possible omentum is mobilized and sutured over the anterior wall of vagina below the sutureline. Then the bladder defect is closed in two layers (inner layer with 3–0 continuous vicryl sutures and outer layer with 2–0 interrupted vicryl sutures) bringing in trimmed, healthy bladder wall over the previously fistulous area. 14 size transabdominal drain is left through one of the pararectus ports.

29.2.2 Transvesical Approach (Cystorrhaphy)

After preliminary cystoscopy and colposcopy to assess the defect, vagina is packed with large pad to prevent leak of water or air. Using cystoscopic view and irrigation, two 5 mm transvesical suprapubic ports are inserted for hand instruments. Usually some of the irrigating fluid escapes and the transvesical ports tend to slip out of the bladder. It is also important to keep the bladder distended to have some working space. Hence a trocar with self retaining mechanism needs to be used. Subsequently the pneumovesico insufflation is done. Urethra can be used as a third port for transurethral suturing. The edges of the fistula are trimmed (any suture material of previous surgery that is seen can be removed). Transurethral suturing of vesical defect is carried out using 3–0 interrupted vicryl.

If the vaginal defect is small it can be left alone. Otherwise the vaginal defect can be closed with continuous 2–0 vicryl suture by vaginal route as in open surgery. Urethral foley catheter is left in for about 10 days.

29.3 Follow-Up

The tube drain can be removed on the eighth postoperative day if there is less drainage. The urethral foley catheter can be removed on the tenth postoperative day following a cystogram.

29.4 Comment

Laparoscopic repair of vesicovaginal fistula is feasible by minimally invasive technique. This is certainly more acceptable for the distressed patient than open repair. Transvesical cystorrhaphy appears to be the least morbid procedure.

29.5 Laparoscopic VVF Repair (O' Connor's Technique)

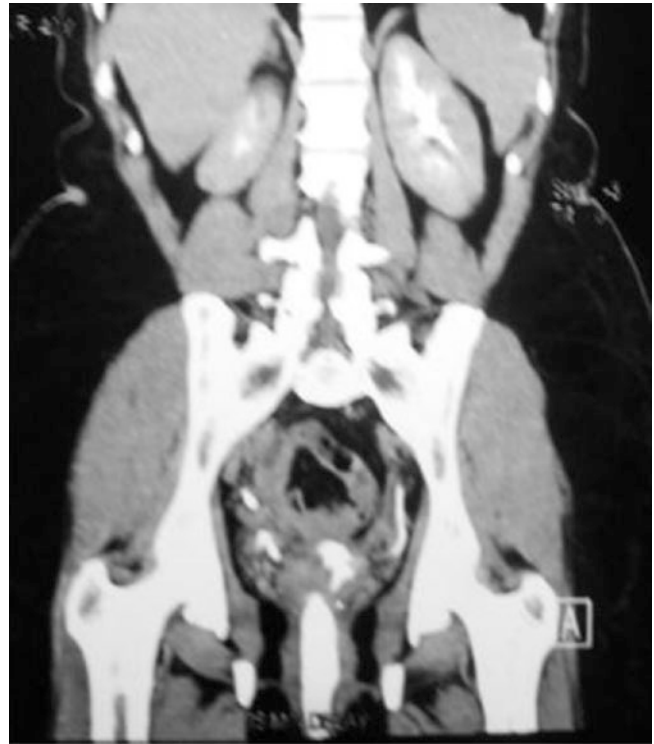

Fig. 29.1 CT image showing vesico vaginal fistula

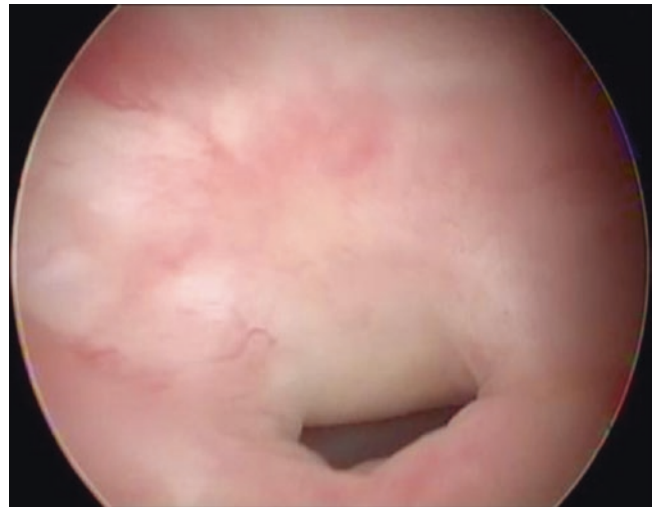


Fig. 29.2 Cystoscopic view showing a supra trigonal VVF

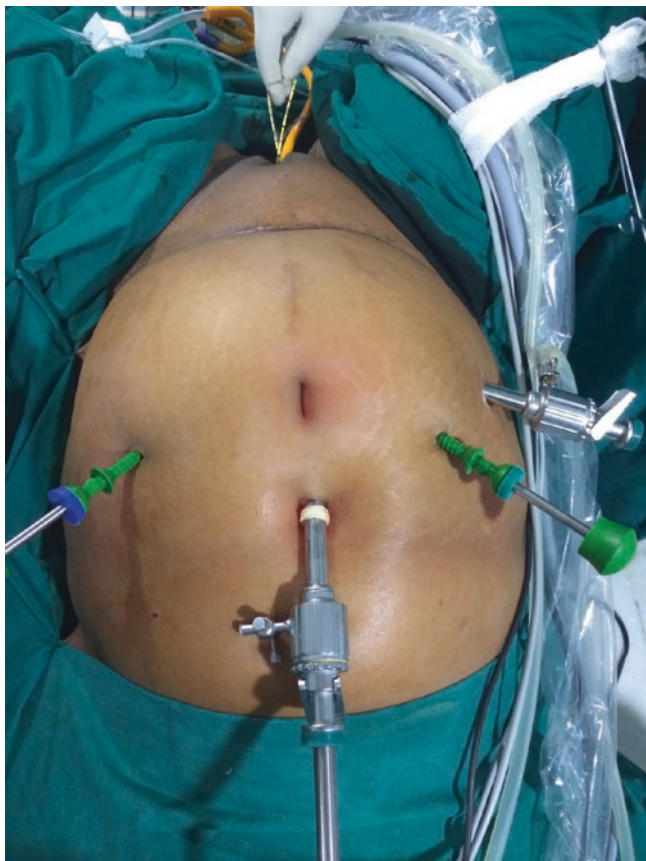

Fig. 29.3 Port position

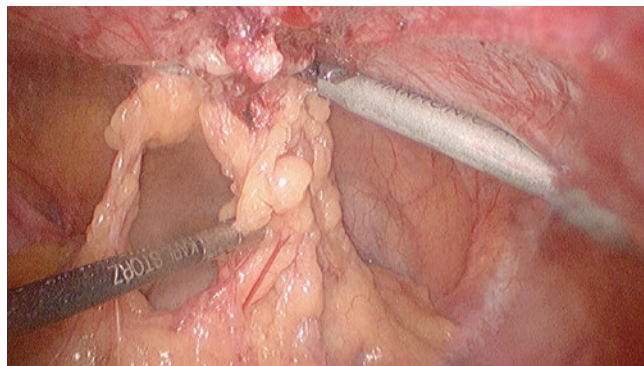


Fig. 29.4 Adhesiolysis in progress

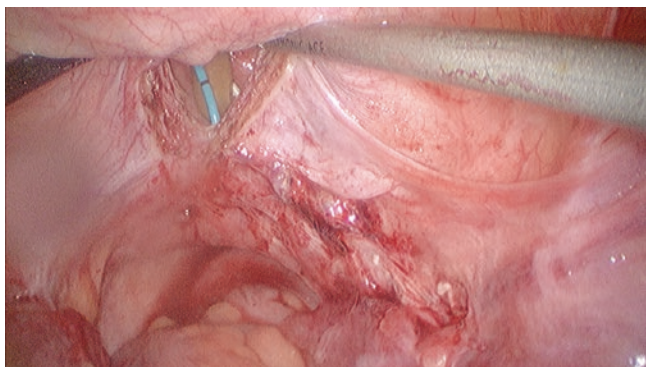


Fig. 29.5 Vertical cystotomy being done

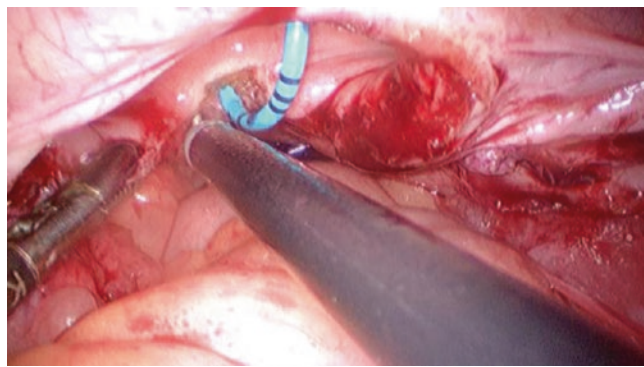


Fig. 29.6 Cystotomy extended around fistula (Note preplaced ureteric catheter in fistula)

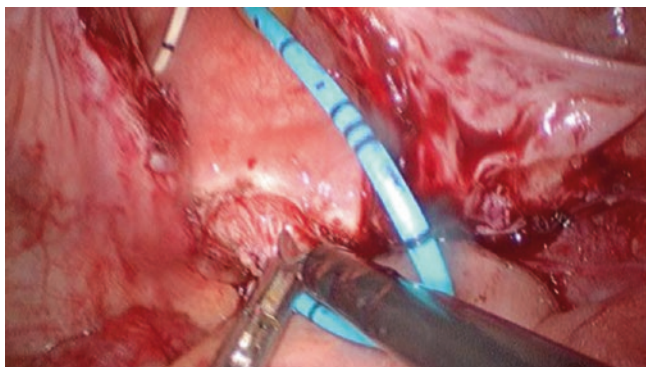


Fig. 29.7 Bladder mucosal incision around fistula

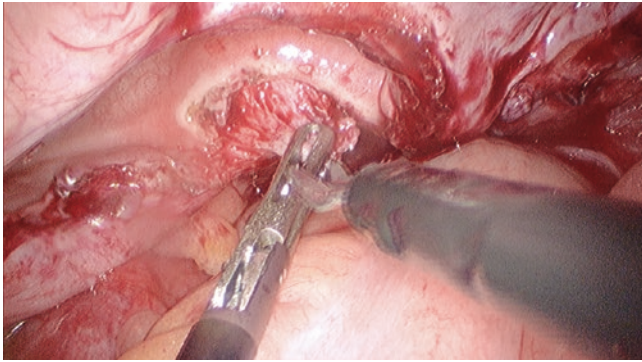


Fig. 29.8 Plane developed between posterior wall of bladder and anterior vaginal wall

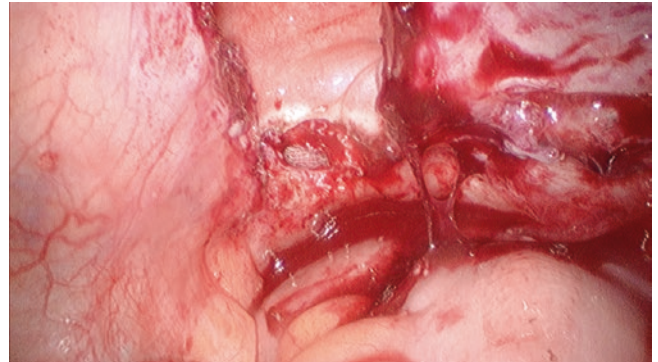


Fig. 29.9 Fistula completely excised

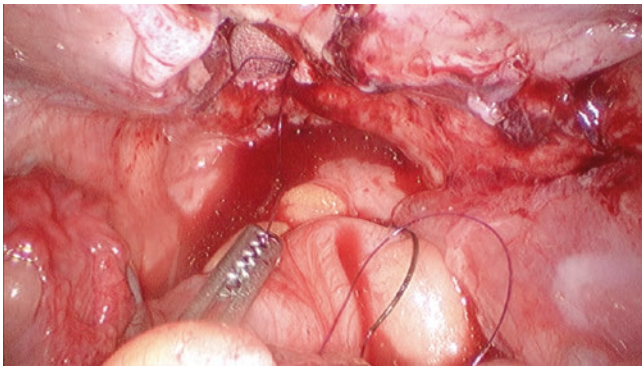


Fig. 29.10 Vaginal rent closure with 3-0 PDS suture in progress

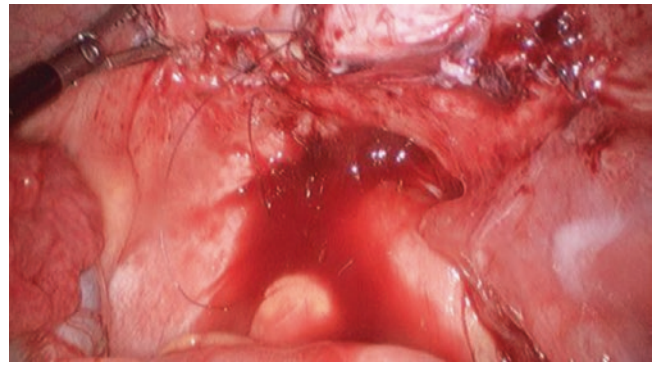


Fig. 29.11 Vaginal closure in progress

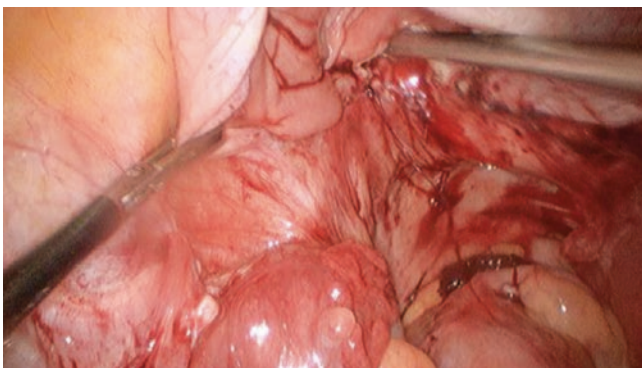


Fig. 29.12 Vaginal closure completed

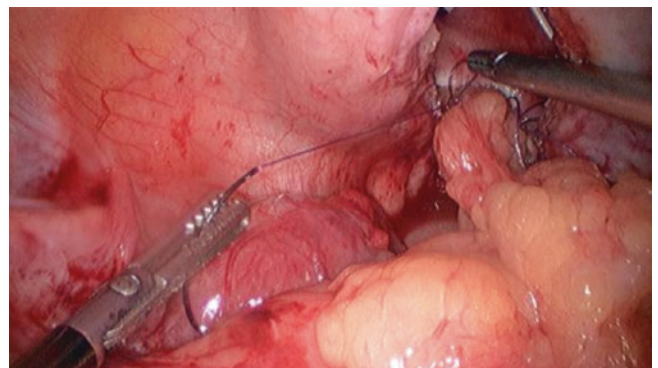


Fig. 29.13 Omental interposition anterior to vagina

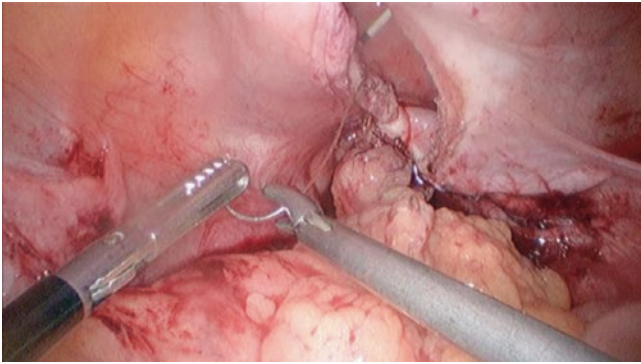


Fig. 29.14 Bladder closure started

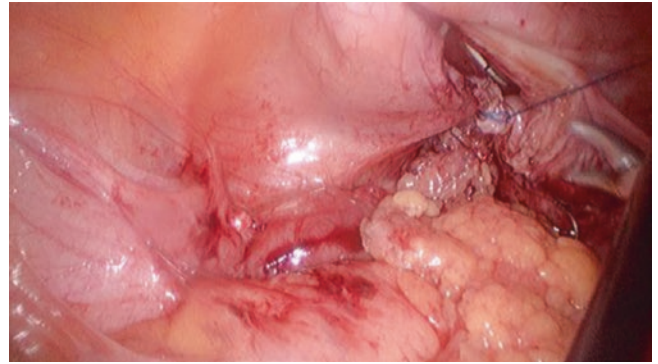


Fig. 29.15 Bladder closure with 3-0 V Lock suture in continuous fashion

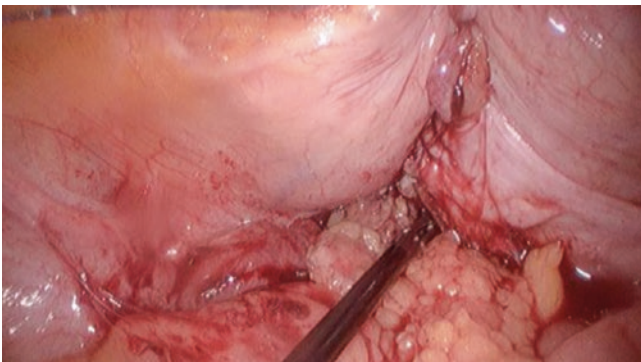


Fig. 29.16 Bladder closure in progress

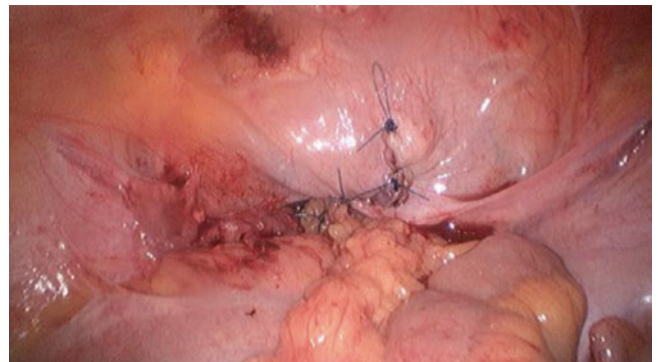

Fig. 29.17 Bladder distended to look for any leak

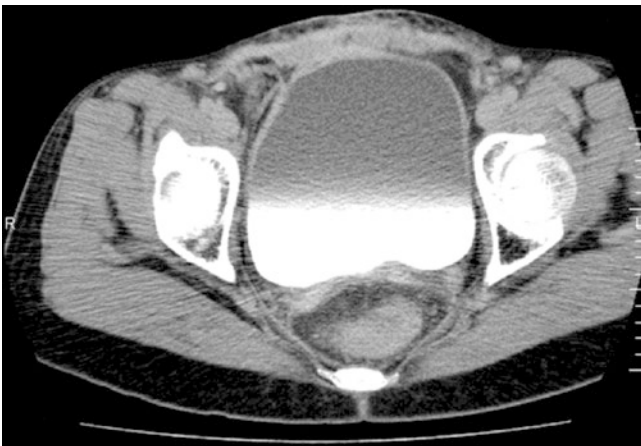

Fig. 29.18 CT cystogram done 3 months later does not show any leak

29.6 Modification;1. Cystorrhaphy

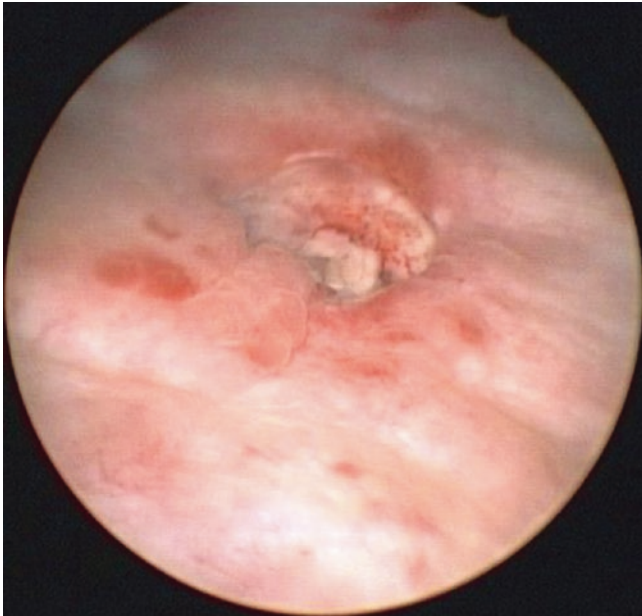

Fig. 29.19 Cystoscopy showing the VVF in supratrigonal area following hysterectomy 1 week back

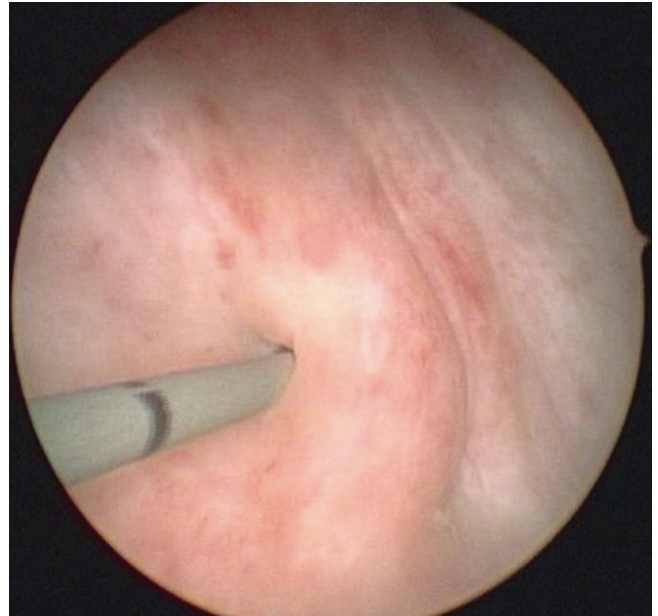


Fig. 29.20 Left ureteric catheterisation done to safeguard left ureter as it is close to VVF

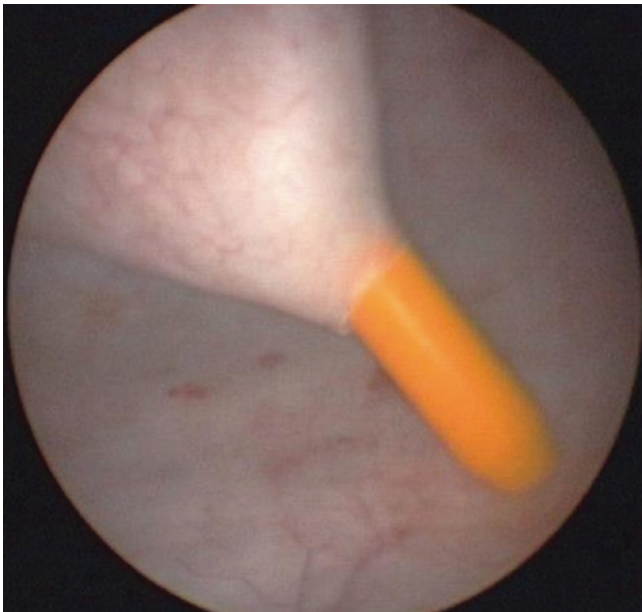


Fig. 29.21 Transvesical port insertion under cystoscopic guidance

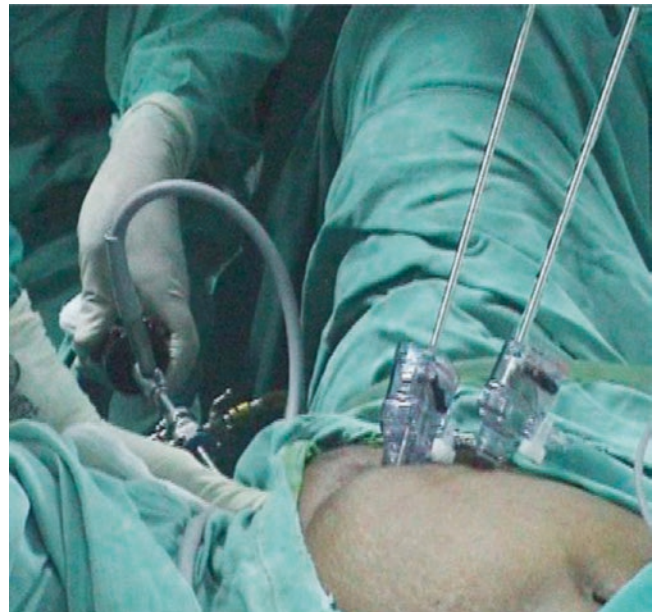

Fig. 29.22 External view of ports position for transvesical approach. Note cystoscope through urethra as camera port

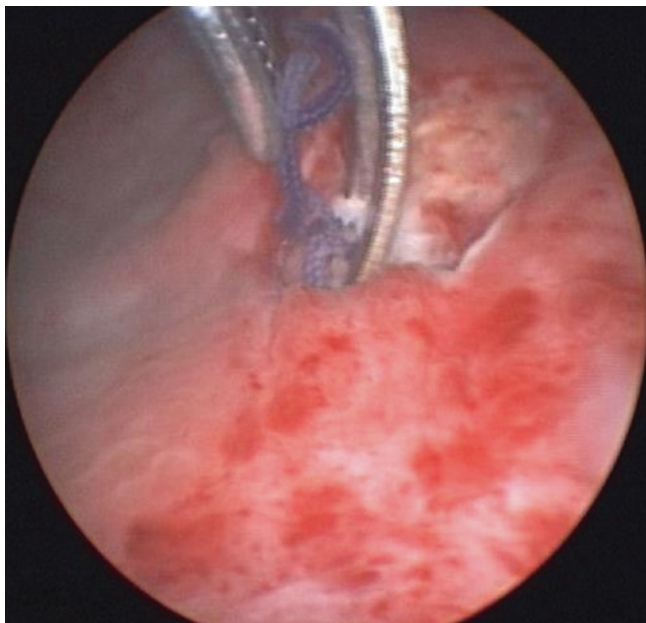


Fig. 29.23 Trimming the edges of the bladder defect

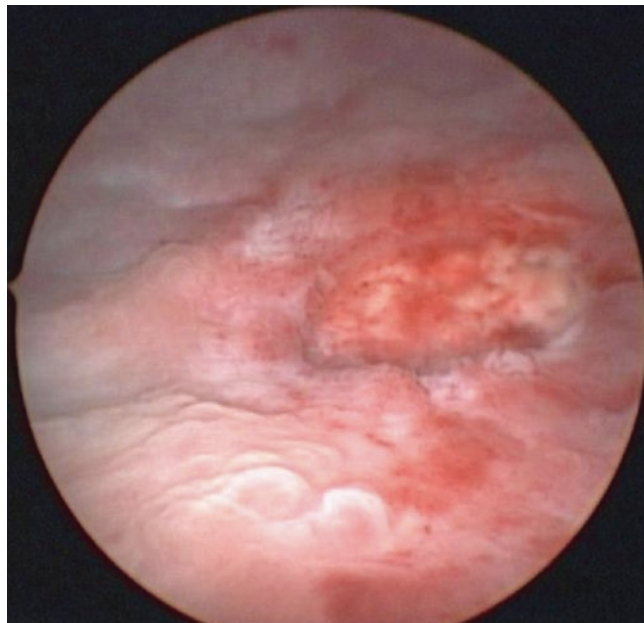


Fig. 29.24 View after trimming the edges

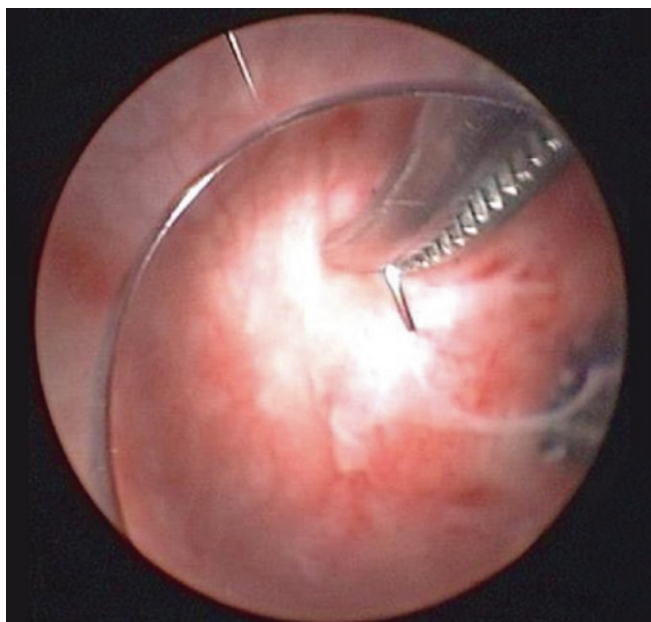


Fig. 29.25 Common difficulty in transvesical approach is escape of air through VVF preventing bladder distention

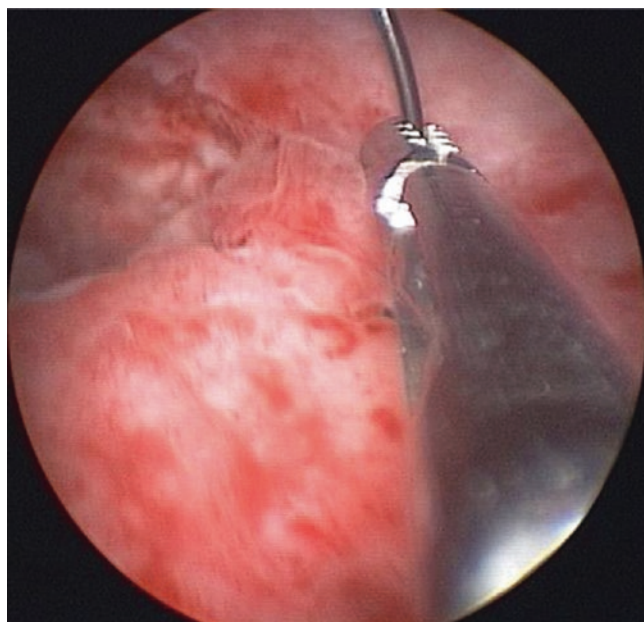


Fig. 29.26 Closing the bladder defect transvesically using 3-0 interrupted vicryl sutures

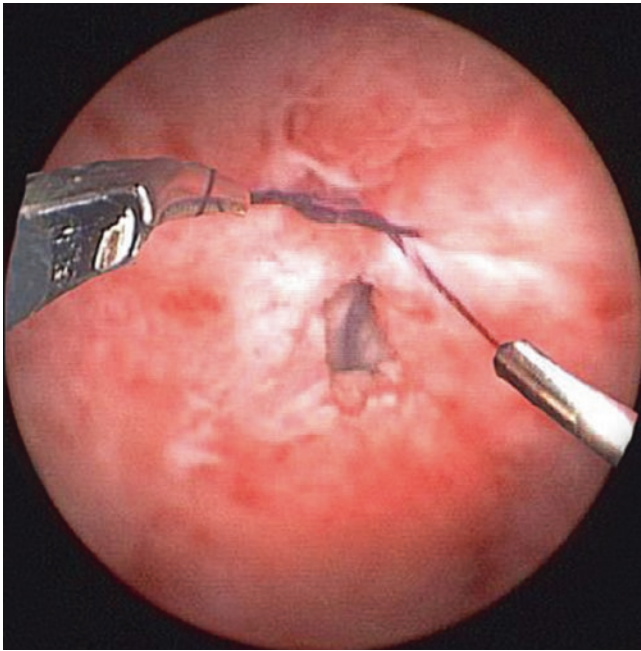


Fig. 29.27 Closure of the defect in progress

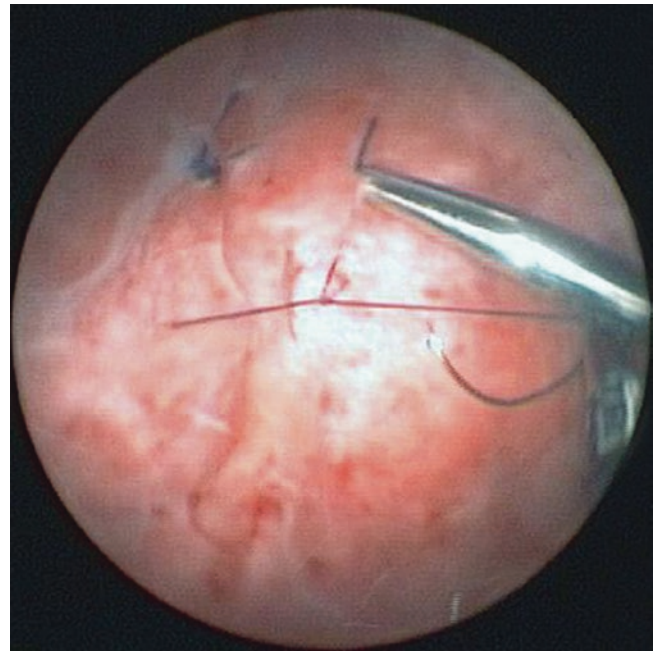


Fig. 29.28 Defect nearly closed

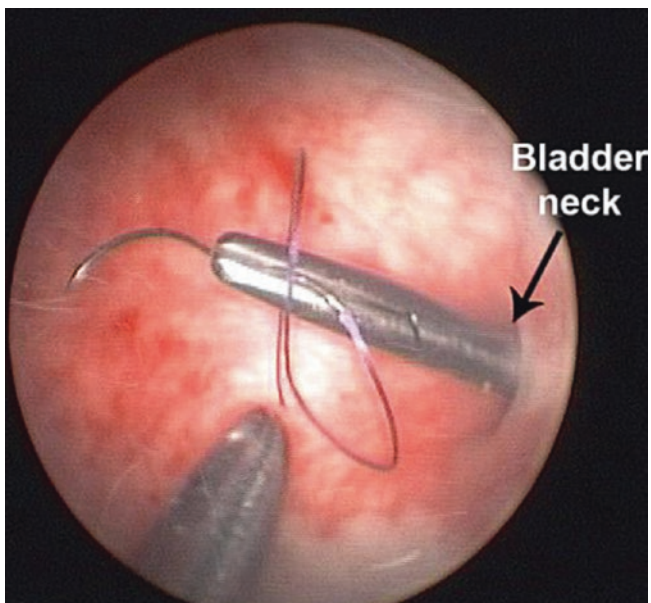


Fig. 29.29 If closure of defect is difficult urethra can be used as a port for the needle holder (as seen by transvesical 5 mm camera port)

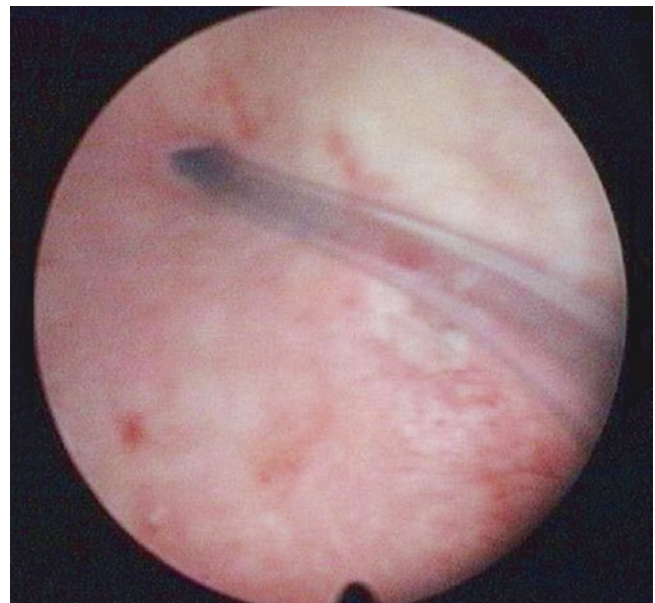


Fig. 29.30 Tube drain (a suprapubic catheter) introduced through transvesical port

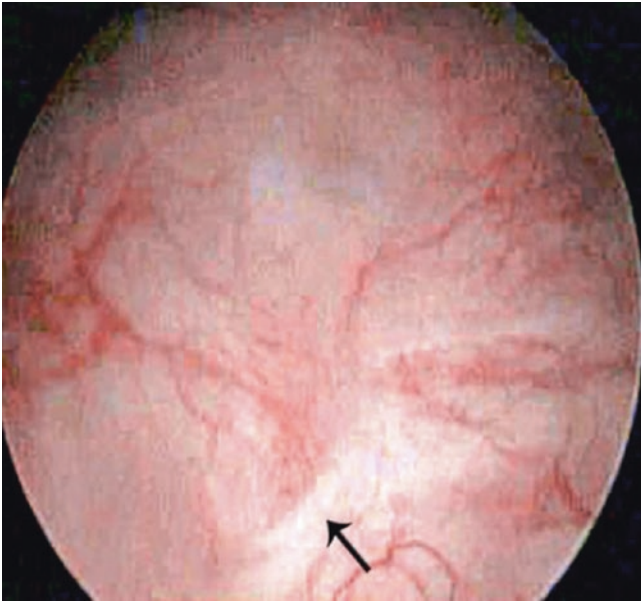


Fig. 29.31 Cystoscopic view 3 months later shows well healed scar (at the previous site of fistula)

29.7 Technical Modification 2. Transverse Cystotomy Approach

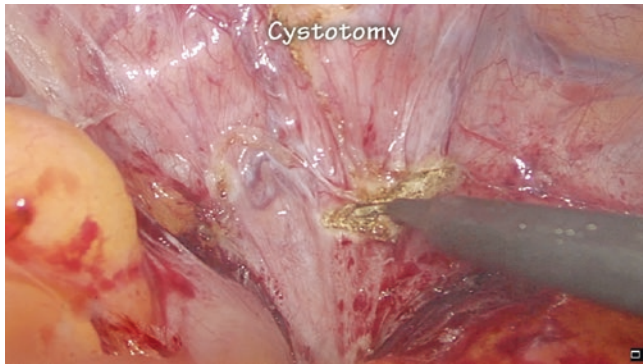


Fig. 29.32 Transverse cystotomy started

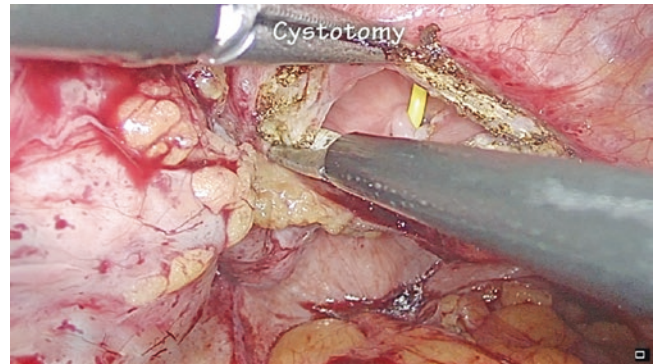


Fig. 29.33 Transverse cystotomy in progress – yellow ureteric catheter seen in the fistula

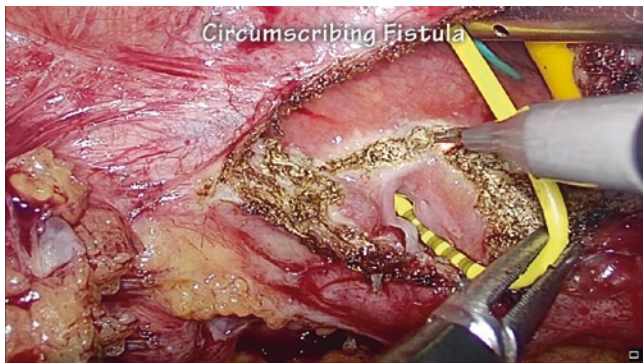


Fig. 29.34 Cystotomy extended to encircle the fistula

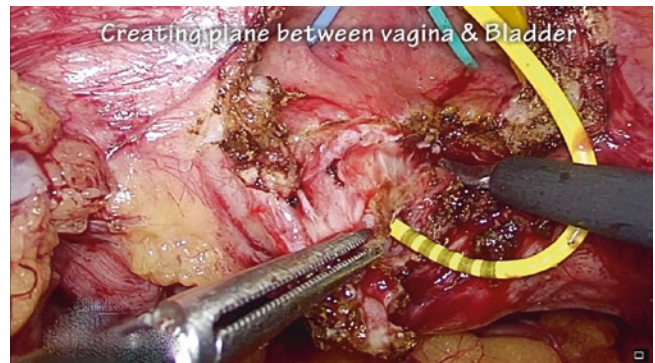


Fig. 29.35 Plane created between the bladder and vagina

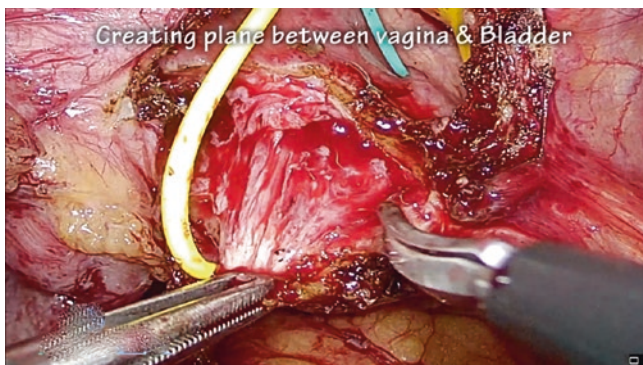


Fig. 29.36 Plane between bladder and vagina created

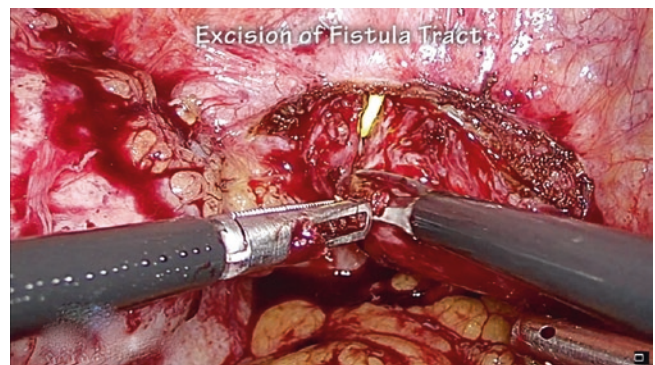


Fig. 29.37 Fistula margin excised

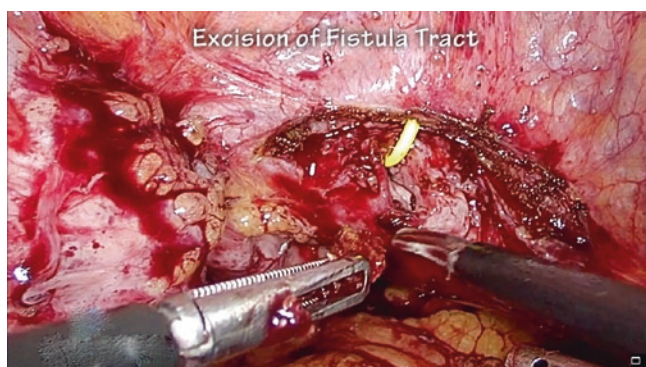


Fig. 29.38 Freshened fistula margin

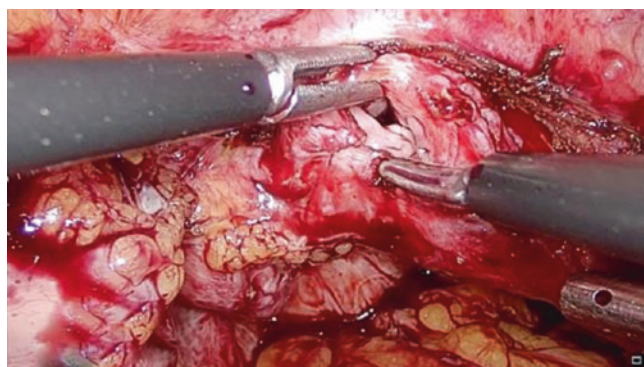


Fig. 29.39 Vaginal opening of the fistula

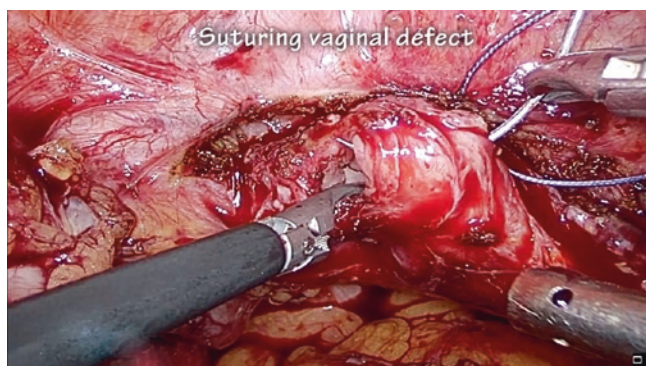

Fig. 29.40 Vaginal closure started

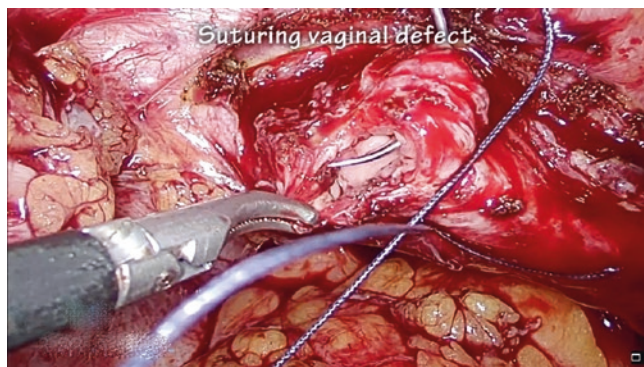


Fig. 29.41 Vagina transversely closed

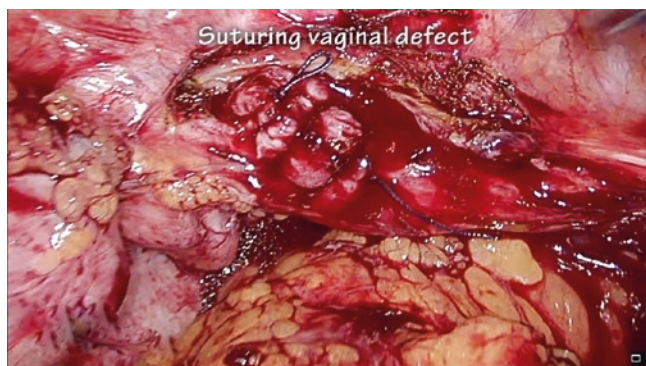


Fig. 29.42 Vaginal closure complete

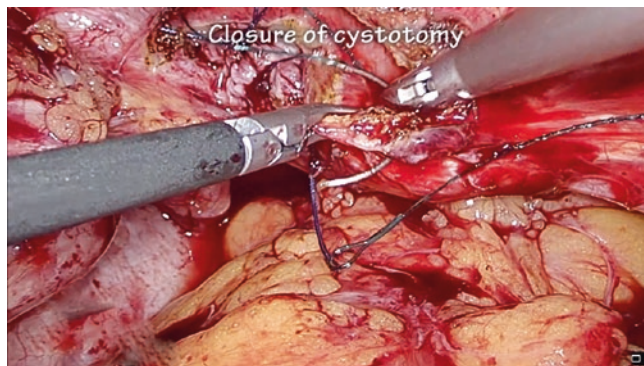


Fig. 29.43 Bladder closure started with barbed sutures

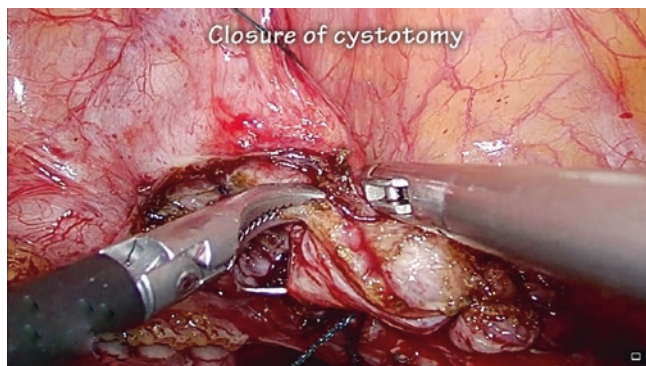


Fig. 29.44 Bladder closure in progress with 3-0 V loc suture

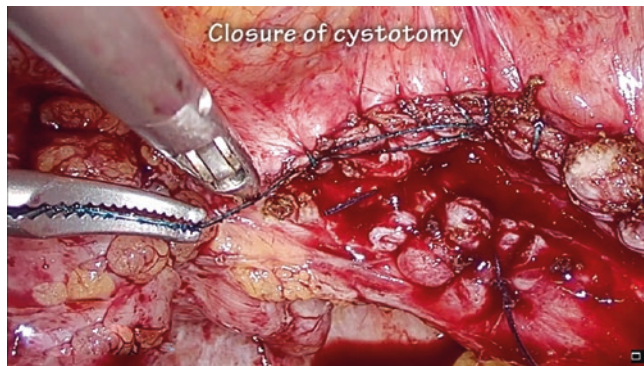


Fig. 29.45 Bladder closure complete

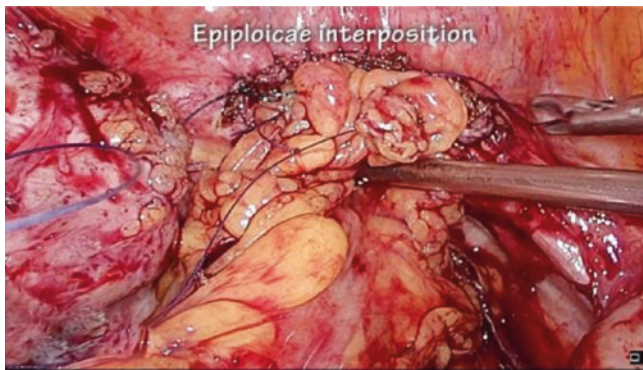


Fig. 29.46 Omental or colonic epiploica interposition

References

1. Gerber GS, Schoenberg HW. Female urinary fistulas. *J Urol.* 1993;149:229–36.
2. Goodwin WE, Scardino PT. Vesicovaginal fistulas: a summary of 25 years of experience. *J Urol.* 1980;123:370–4.
3. Mc Kay HA. Transurethral suture cystorrhaphy for repair of vesicovaginal fistulas: evolution of a technique. *Int Urogynaecol J Pelvic Floor Dysfunct.* 2001;12(4):282–7.
4. Mc Kay HA. Vesicovaginal fistula repair: transurethral suture cystorrhaphy as a minimally invasive alternative. *J Endourol.* 2004;18(5):487–90.
5. Miklos JR, Sobolewski C, Lucente V. Laparoscopic management of recurrent vesicovaginal fistula. *Int Urogynaecol J Pelvic Floor Dysfunction.* 1999;10(2):116–7.
6. Nabi G, Hemal AK. Laparoscopic repair of vesicovaginal fistula and right nephrectomy for nonfunctioning kidney in a single session. *J Endourol.* 2001;15(8):801–3.
7. Nezhat CH, Nezhat F, Nezhat C, Rottenberg H. Laparoscopic repair of a vesicovaginal fistula: a case report. *Obstet Gynecol.* 1994;83(5.2):899–901.
8. Ou CS, Huang UC, Tsuang M, Rowbotham R. Laparoscopic repair of vesicovaginal fistula. *J Laparoendosc Adv Surg Tech A.* 2004;14(1):17–21.
9. Ramalingam M, Senthil K, Selvarajan K, Pai MG. Laparoscopic repair of vesicovaginal fistula our experience (Abstract). *J Endourol.* 2004;18:A192.

Jayapriya Jayakumaran, Hariharan Palayapalayam Ganapathi,
Ravimohan Mavaduru, and Sejal D. Patel

Over the past 20 years, vesicovaginal fistula (VVF) repair has evolved from strictly transabdominal/transvaginal approach to minimally invasive approach. Robotic assistance has overcome some of the technical difficulties of the laparoscopic approach in VVF dissection and intracorporeal suturing by its technical advantages like EndoWrist™ instruments with 7 degrees of freedom, 3-D vision with improved depth perception, motion scaling, tremor filtration, higher magnification, and improved surgeon's ergonomics. Robotic-assisted VVF repair was first reported in 2005 [1].

Robot assisted VVF repair can be done with either transvesical (O'Connor) or extravesical approach. The extravesical technique is performed by focusing on a site-specific dissection and repair without cystotomy or bivalving of the bladder. The cure rates are similar in both approaches (95.9 % vs 98.04 %) [2]. Single site surgery has also been utilized with reasonable success. Whatever the surgical technique the basic surgical principles of fistula reconstruction remain same.

- Wide exposure of the fistula track and surrounding tissue with circumferential excision of fibrous and scar tissue from the fistula edges, saving both ureteric orifices.
- Tension-free repair of freshened fistula edges in the vagina with absorbable suture material.
- Watertight closure of bladder with non-overlapping suture lines with or without tissue interposition
- Un-interrupted postoperative bladder drainage for adequate healing.

The proper timing of corrective surgery (early vs delayed repair) has been debated. Uncomplicated post gynecological urinary fistulae may be repaired as soon as they are identified and confirmed [3, 4]. Though very rare nowadays, obstetric fistula following obstructed labor may require 3–6 months waiting period for tissue healing to allow appropriate repair.

Preliminary evaluation includes a physical examination, office flexible cystoscopy (to assess fistula site, size and relationship with ureteric orifice). Retrograde cystourethrography / excretory urography is performed to confirm VVF and exclude concurrent ureteric injury [5].

Surgical Steps:

1. After appropriate antibiotic prophylaxis and general anesthesia is achieved, the patient is prepped and draped in the low lithotomy position and stabilized with all pressure points protected.
2. Cystoscopy is performed at the beginning to confirm the fistula site (Fig. 30.1). In smaller fistula, a ureteric catheter of different color is pushed through the fistula into the vagina, taking it out through the introitus (Fig. 30.2). This helps to identify fistulous orifice intra-operatively. Alternatively a Foley catheter can be placed transvaginally in case of large VVF. Ureteric catheters may be placed to protect the ureteric orifices if close to fistula site. Clamping the vaginally placed Foley catheter and packing the vagina with a wet sponge can prevent loss of

J. Jayakumaran (✉) • S.D. Patel
Center for Reproductive Medicine,
Pinehurst Street, Orlando, FL, USA

Florida Hospital, Orlando, FL, USA
e-mail: drjphari@gmail.com

H.P. Ganapathi
University of Central Florida College of Medicine, Global
Robotics Institute, Florida Hospital Celebration Health,
410 Celebration Place, Orlando, FL 34747, USA

Florida Hospital, Orlando, FL, USA
e-mail: hari.uro@gmail.com

R. Mavaduru
Post Graduate Institute of Medical Education and Research
(PGIMER), Chandigarh, India

pneumoperitoneum. Urethral Foley catheter is placed for subsequent bladder filling and drainage.

3. Insufflation is achieved with a Veress needle. A supra-umbilical camera port, three 8 mm robotic ports (two on left side and one on right side) and two 5 mm assistant ports on right side are placed (Fig. 30.3). Patient is placed in steep Trendelenburg position and robot is docked from the side. Side docking allows intraoperative access to catheters and cystoscopy if required. In iatrogenic fistula, the extent of postoperative adhesions may vary requiring meticulous adhesiolysis (Fig. 30.4a, b). If required, bladder is filled with saline for better anatomical delineation. A vertical midline cystotomy is made in direct proximity of VVF using monopolar robotic scissors (Fig. 30.5). Bedside assistant may gently manipulate the ureteric catheter to locate the site of fistula. The cystotomy incision is continued vertically on the posterior bladder wall connecting it to the fistulous orifice (Fig. 30.6a). Complete bivalving of the bladder may be required in case of complicated trigonal fistula (Fig. 30.6b)
4. Margins of fistulous tract are marked and resected in the form of a 'tennis racket' with the monopolar robotic scissors (Fig. 30.7a). The borders of the fistulous tract are freshened for closure. The bladder wall is fully mobilized off the anterior aspect of the vagina using robotic scissors and gentle counter traction with the robotic Maryland grasper to allow tension free closure (Fig. 30.7b). It is preferable to do a slow and careful sharp dissection of the fistulous edges, taking care not to injure trigone or ureteric orifices.
5. The vagina is closed horizontally using running, locking 3-0 monofilament synthetic absorbable suture (Fig. 30.8a, b). Removal of the vaginal pack without loss of pneumoperitoneum confirms successful closure. Omentum can be mobilized and sutured over the anterior wall of vagina. If omentum cannot be adequately mobilized, the epiploic appendices of the sigmoid colon or a peritoneal flap is used as tissue for interposition.

Miklos et al did not find any difference in cure rates for VVF repairs between groups with and without omental interposition grafts [2]. To minimize the contact surface of suture lines, bladder is closed vertically (Fig. 30.9a, b) in single layer, running continuous fashion with a 3-0 monofilament, absorbable suture. Closure is initiated at the apex of the incision at the most distal part of cystotomy near to the ureteric orifices. Water-tightness of bladder closure is confirmed by filling the bladder with saline through an indwelling Foley catheter. Additional interrupted sutures are applied if minor leak is detected. A systematic review reported that VVF repairs with bladder fill test had higher success rate compared with those without a bladder fill test [2].

Ureteric orifice involvement may necessitate re-implantation (uretero-neocystostomy). Rarely, significantly decreased bladder capacity may warrant augmentation cystoplasty. A suprapubic cystostomy tube is placed in complex VVF repairs. A Jackson-Pratt drain is introduced in the rectovaginal pouch, through one of the side ports and secured to the skin with 1-0 silk suture. The trocars are removed under optical guidance after reducing the pressure of pneumoperitoneum below 10 mmHg. At the end, the fascia of 12 mm trocar is closed with monofilament non-absorbable suture. The skin is closed by absorbable suture.

30.1 Post-operative Management

Ureteric catheters can be removed immediately after the procedure or on post-operative day 1. Usually pelvic drain is removed on postoperative day 1 or 2. Urethral catheter can be removed in 1–2 weeks depending on the complexity of reconstruction. Cystogram is performed before removing urethral Foley catheter in case of complicated fistula repair to ensure optimal healing. Patient is advised to avoid intercourse for 2 months postoperatively.

30.2 Conclusion

A systematic review reported the overall success rate of robotic assisted laparoscopic VVF repair as 80–100 % with a follow-up period of up to 74 months [2]. The most important aspect of the VVF repair remains adequate dissection, a

watertight seal, and good postoperative bladder decompression to allow for tissue healing. The optimal approach for VVF repair is still debated, but minimally invasive robotic technology has enabled reconstructive surgeons the advantages of a transabdominal approach with the decrease in morbidity associated with open surgery.

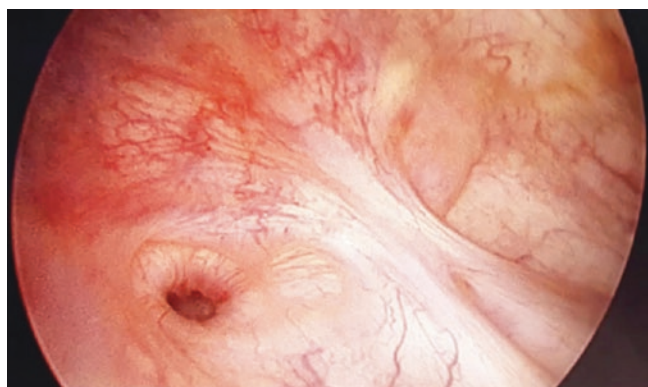


Fig. 30.1 Supra-trigonal vesico-vaginal fistula showing well epithelialized fistulous tract

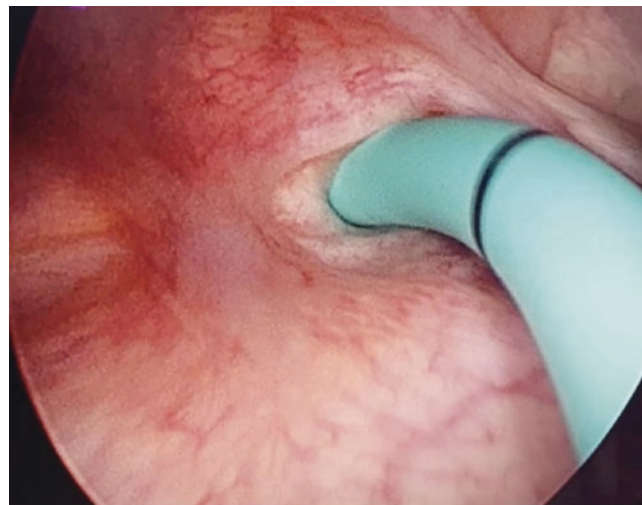


Fig 30.2 Cytoscopic placement of ureteric catheter through fistulous tract for easy identification

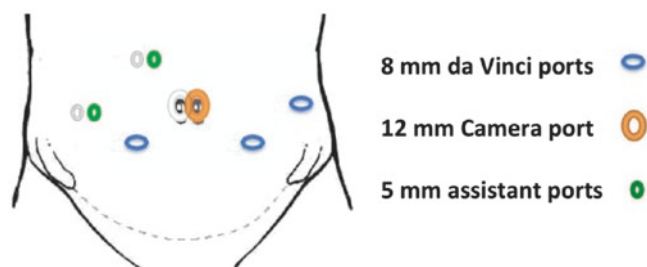


Fig. 30.3 Port position for robotic-assisted vesico-vaginal fistula repair

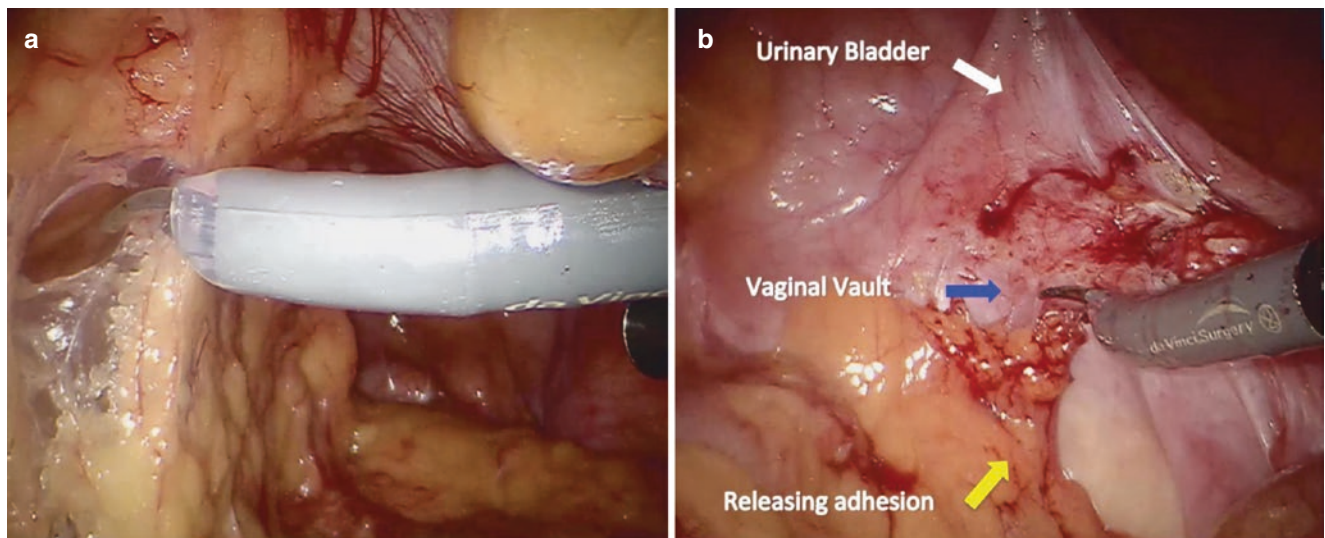


Fig. 30.4 (a) Releasing omentum adherent to abdominal wall in a case of post-hysterectomy vesico-vaginal fistula repair. (b) Releasing adhesions from vaginal vault in a case of post-hysterectomy vesico-vaginal fistula repair

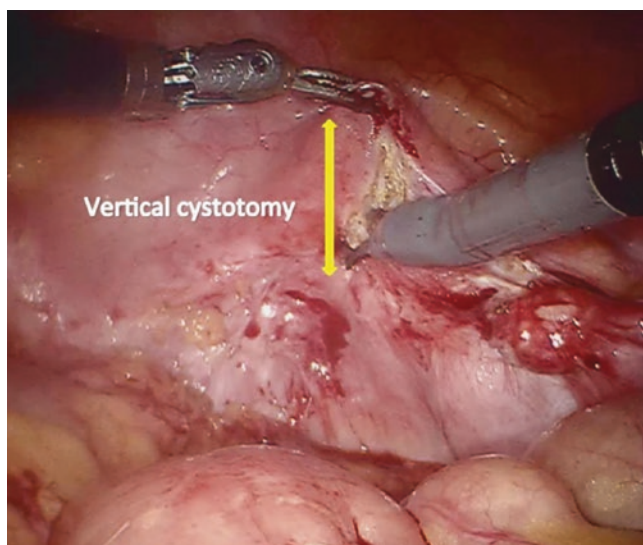


Fig. 30.5 Vertical cystotomy incision to access the fistulous tract in a case of post hysterectomy supra trigonal VVF

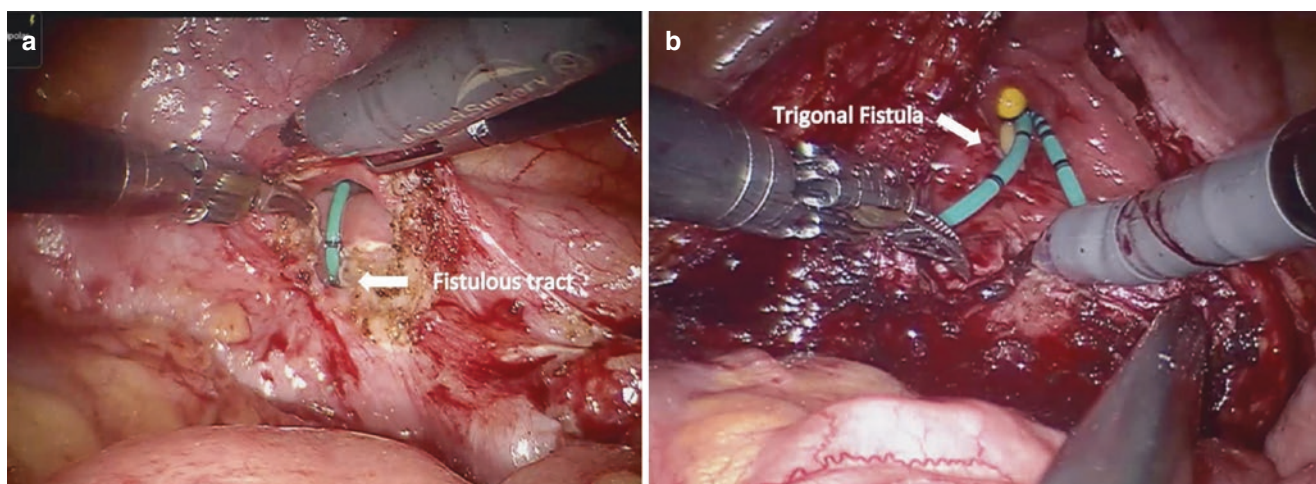


Fig. 30.6 (a) Identification of small supra-trigonal vesico-vaginal fistula with the help of pre-placed ureteric catheter. (b) Bivalving the bladder to reach the fistulous tract in a case of complicated trigonal fistula

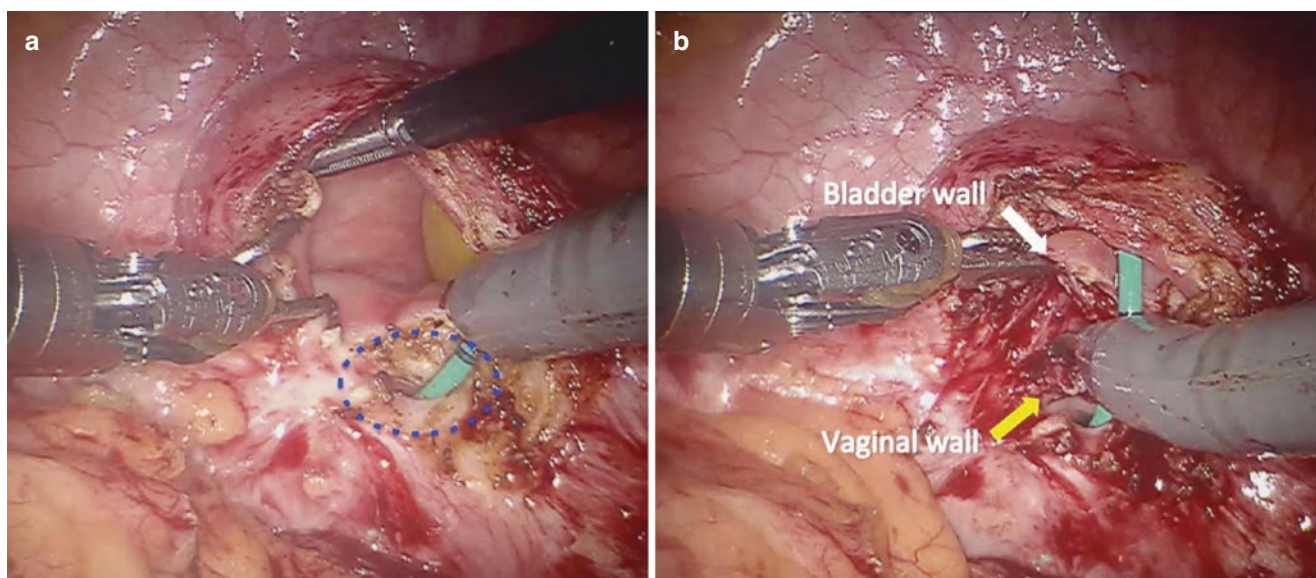


Fig. 30.7 (a) Fistulous tract circumscribed to freshen the margins. (b) Developing between bladder and vaginal wall for adequate closure

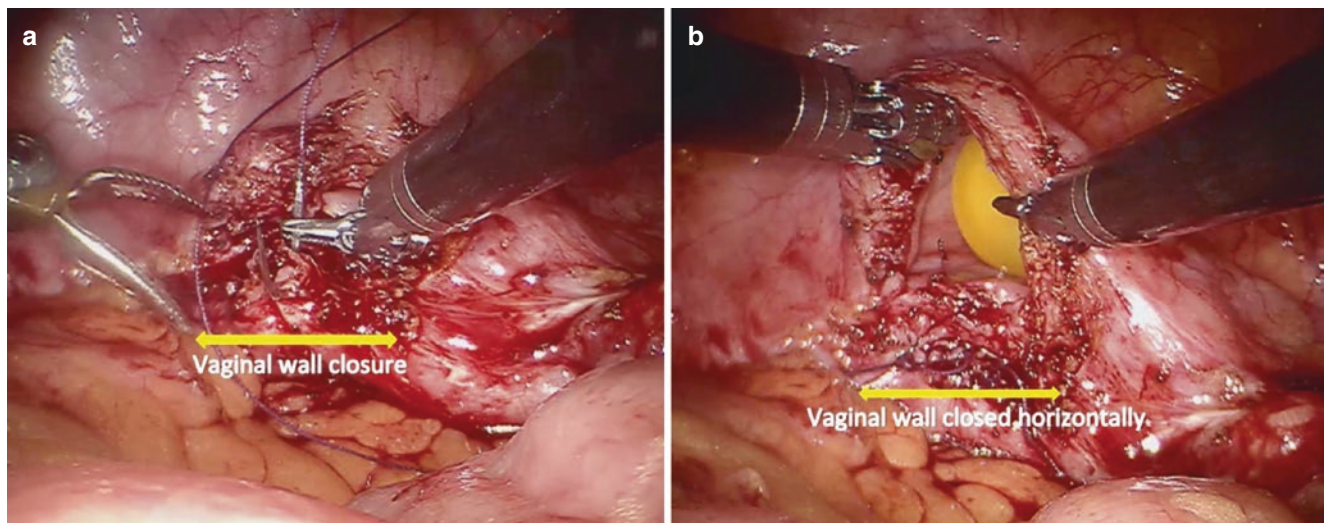


Fig. 30.8 (a) Horizontal closure of vaginal wall with absorbable suture. (b) Water tight closure of vaginal wall horizontally

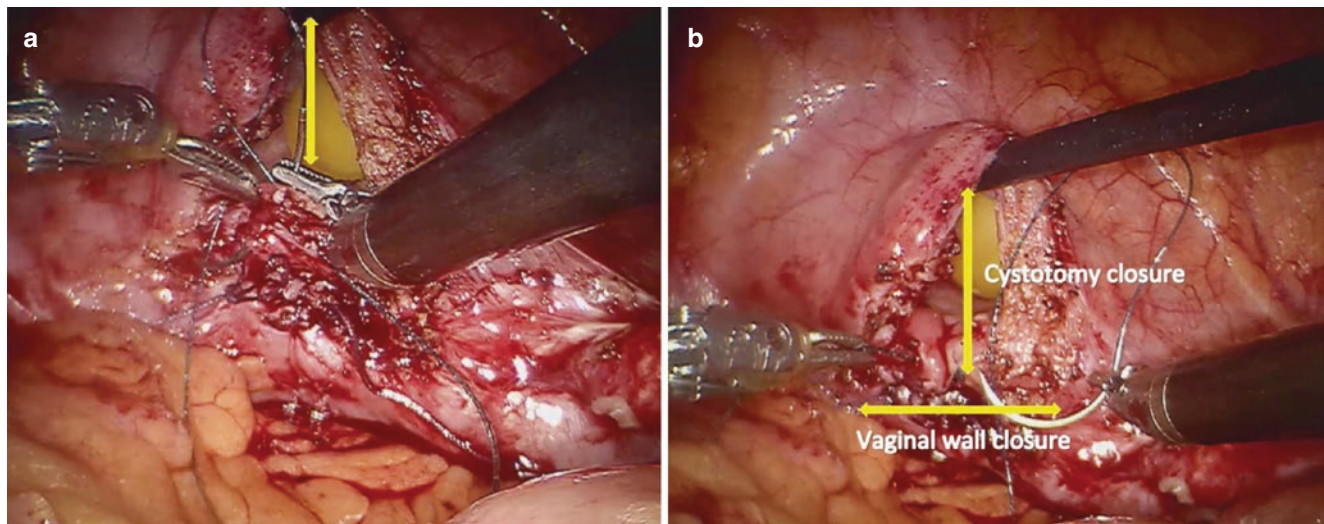


Fig. 30.9 (a) Placing apical suture for vertical cystotomy closure. (b) Non-overlapping suture lines: water tight closure of bladder vertically using absorbable suture

References

1. Melamud O, Eichel L, Turbow B, Shanberg A. Laparoscopic vesicovaginal fistula repair with robotic reconstruction. *Urology*. 2005;65:163–5.
2. Miklos JR, Moore RD, Chinthakanan O. Laparoscopic and robotic-assisted vesicovaginal fistula repair: a systematic review of the literature. *J Minim Invasive Gynecol*. 2015;22(5):727–36.
3. Wein AJ, Malloy TR, Carpiello VL, et al. Repair of vesicovaginal fistula by a suprapubic transvesical approach. *Surg Gynecol Obstet*. 1980;150(1):57–60.
4. Collins CG, Collins JH, Harrison BR, et al. Early repair of vesicovaginal fistula. *Am J Obstet Gynecol*. 1971;111(4):524–8.
5. Romics I, Kelemen Z, Fazakas Z. The diagnosis and management of vesicovaginal fistulae. *BJU Int*. 2002;89:764–6.

Manickam Ramalingam, Kallappan Senthil,
R. Renukadevi, and Vijayanthi Raja

31.1 Introduction

Vesicouterine fistula is a rare complication after lower segment caesarean section. Patients usually present with cyclical hematuria. The preferred management is disconnection by abdominal route. Laparoscopic approach has been described [1, 2].

31.2 Surgical Technique

Preliminary cystoscopy and CT Cystogram give an idea of the fistula. Patient is placed in lithotomy position. This helps in intraoperative cystoscopy to maneuver uterus; and to instill methylene blue into the uterus for confirming the fistulous connection to the bladder.

Four ports (Umbilical camera port, two ports in the mid-clavicular line 5 cm below and lateral to umbilicus and one right flank port for hand instruments) are used. Fistula is disconnected from uterus using ultracision or bipolar scissors. Cystotomy is made encircling the fistula. Uterine rent is closed with interrupted 2-0 vicryl. Omentum is tacked onto the anterior wall of cervix. Bladder rent is closed in two layers using 3-0 vicryl sutures. Tube drain is left in for about 5 days. Bladder is drained by foley catheter for 7 days.

31.3 Follow Up

A cystogram is done on day 10 to rule out urinary extravasation and the Foley catheter is removed.

M. Ramalingam (✉)
PSG Hospitals,
Coimbatore, India
e-mail: uroram@yahoo.com

K. Senthil, MCh (Urol., FRCS)
Urology clinic, Gowtham annexe, Coimbatore, India
e-mail: senthilsatya@hotmail.com

R. Renukadevi
Urology Clinic, 3/1054, Gowtham Annexe, Avinashi Road,
Coimbatore 641018, India
e-mail: renuram_d@yahoo.co.in

V. Raja, MBBS, MD
Balaji Nursing Home, #48, Cowley Brown Road, R S Puram,
Landmark: Adjacent To Central Library, Coimbatore, India

Conclusion

With increasing laparoscopic suturing skill, it can also be managed laparoscopically.

Figures 31.1, 31.2, 31.3, 31.4, 31.5, 31.6, 31.7, 31.8, 31.9, 31.10, 31.11, 31.12, 31.13, 31.14, 31.15, 31.16, 31.17, 31.18, 31.19, 31.20, 31.21, 31.22, 31.23, 31.24, 31.25, 31.26, and 31.27.

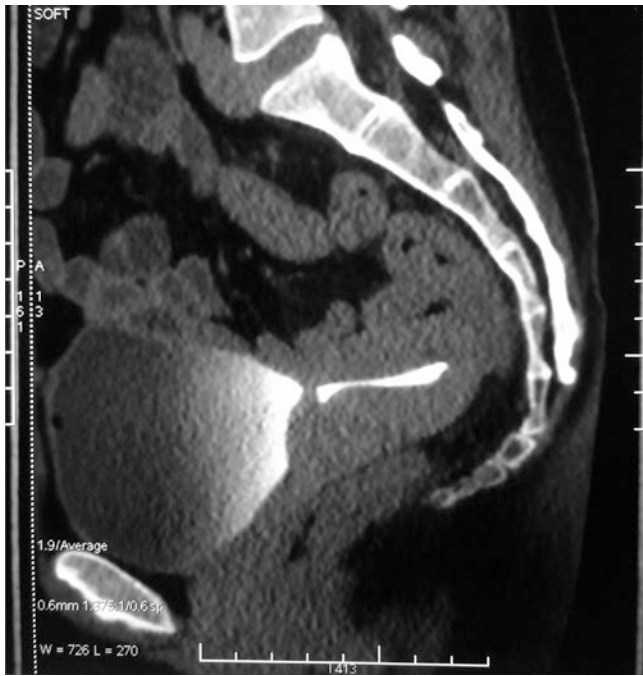

Fig. 31.1 CT scan showing fistulous connection between posterior wall of bladder and uterus

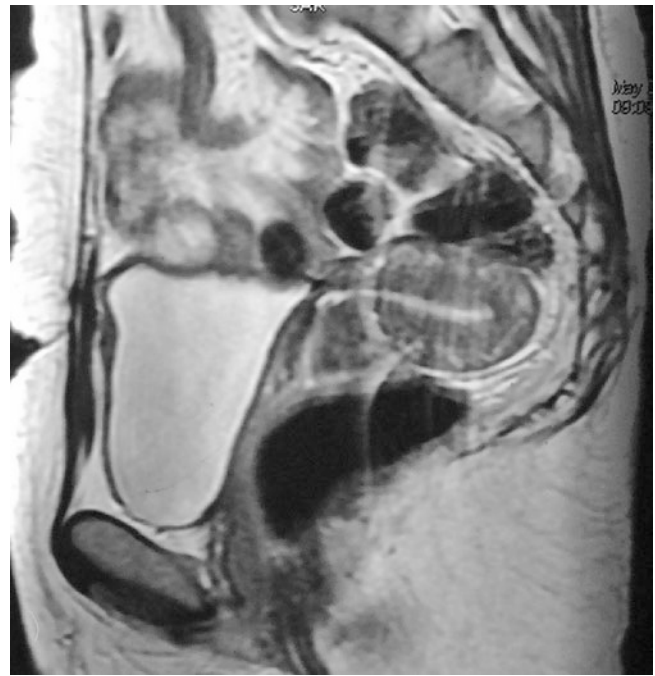

Fig. 31.2 MRI showing fistulous connection between posterior wall of bladder and uterus

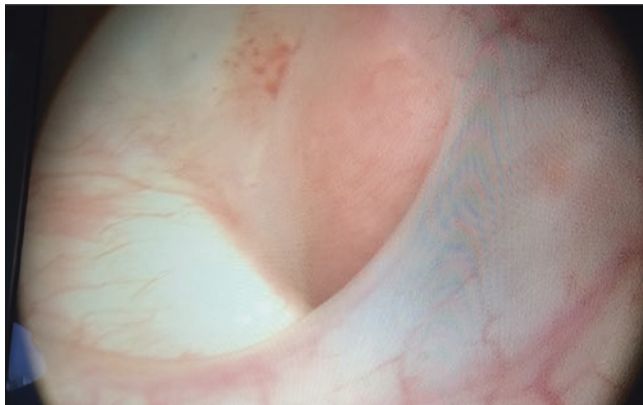


Fig. 31.3 Cystoscopy showing fistula in the posterior wall of bladder

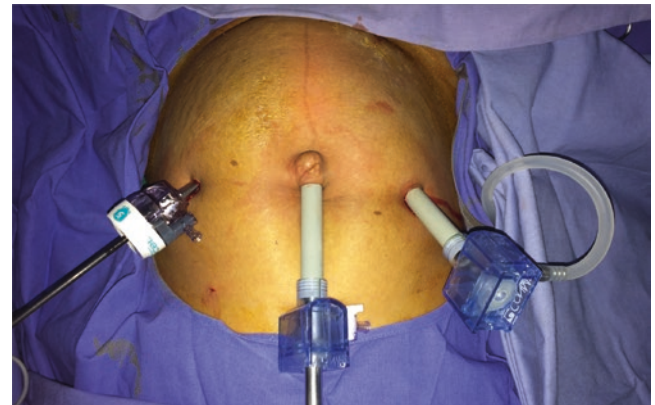


Fig. 31.4 Ports position as seen from head end

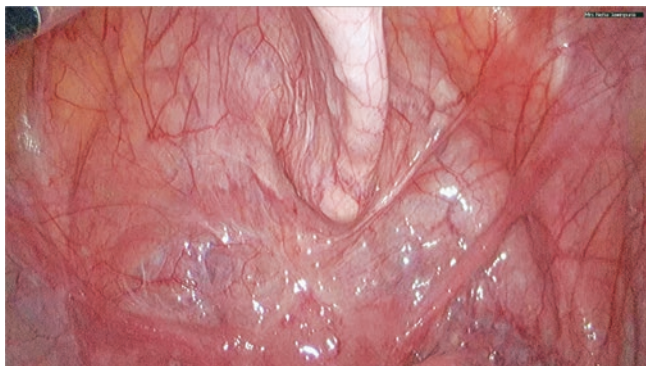


Fig. 31.5 Initial view of the bladder and the uterus

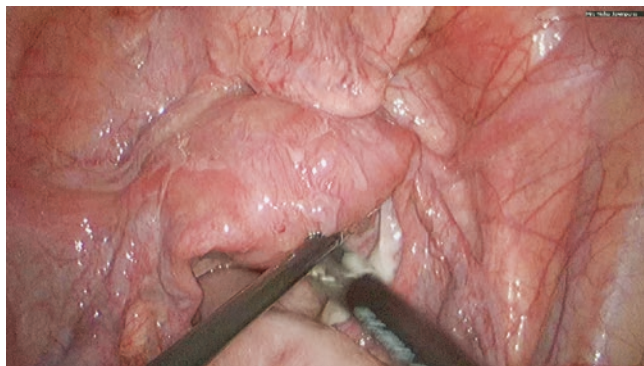

Fig. 31.6 Retroverted uterus

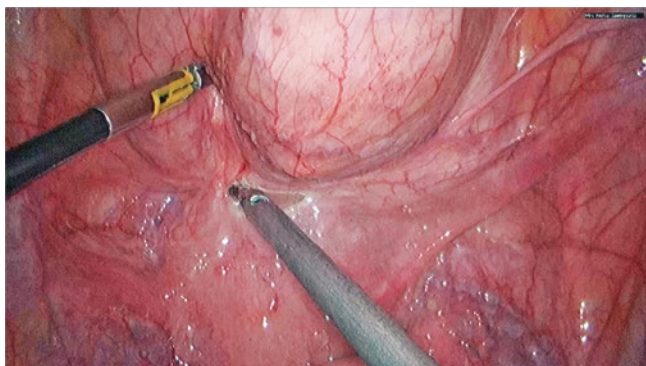


Fig. 31.7 Dissection started at the uterovesical space

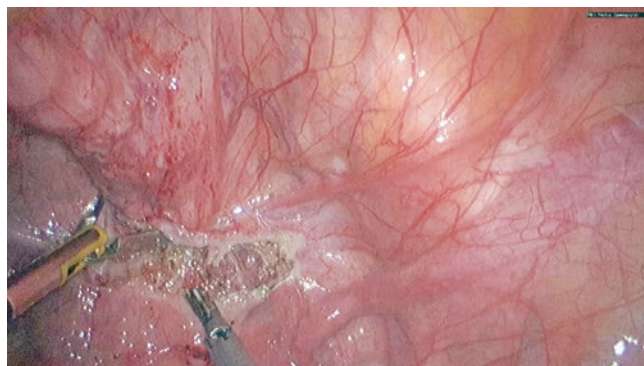


Fig. 31.8 Dissection in progress between the bladder and the uterus

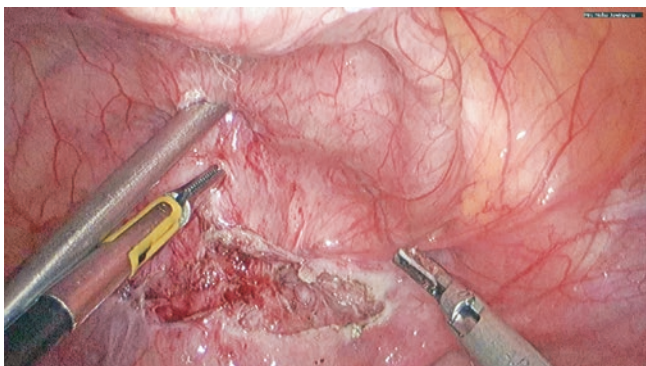


Fig. 31.9 Densely adherent bladder and uterus at the area of fistula

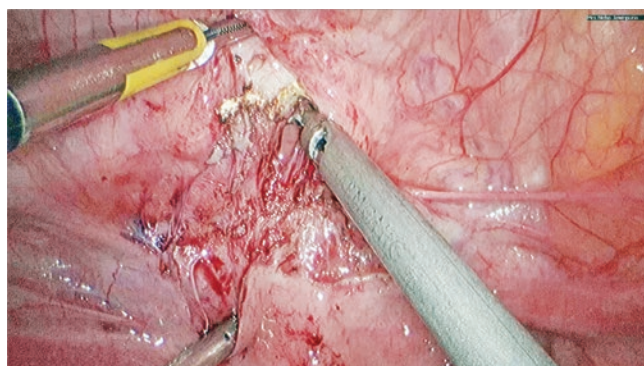


Fig. 31.10 Vertical cystotomy done at the level of fistula

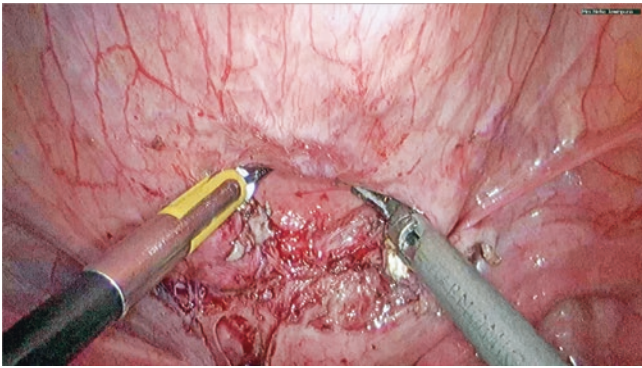


Fig. 31.11 Cystotomy extended

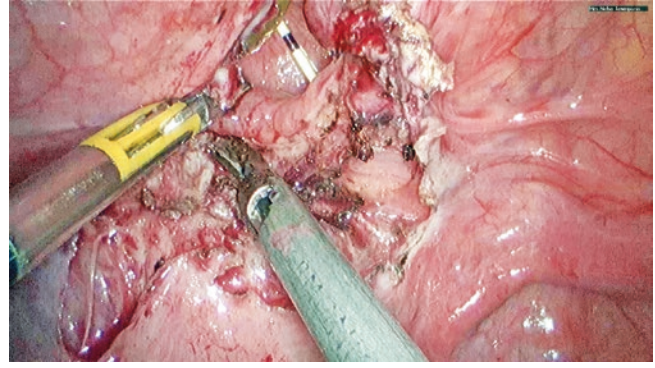


Fig. 31.12 Fistula disconnection in progress. Preplaced ureteric catheter is seen

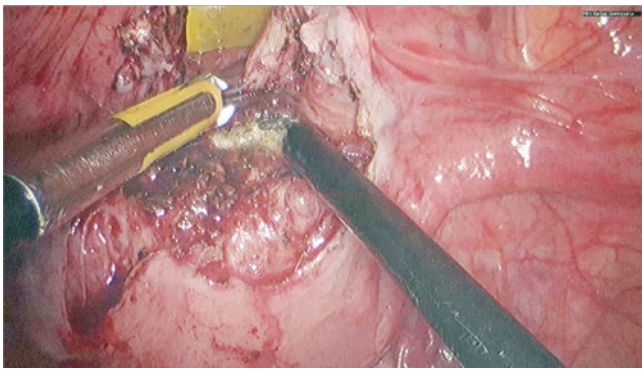


Fig. 31.13 Space being developed around the fistula using monopolar hook

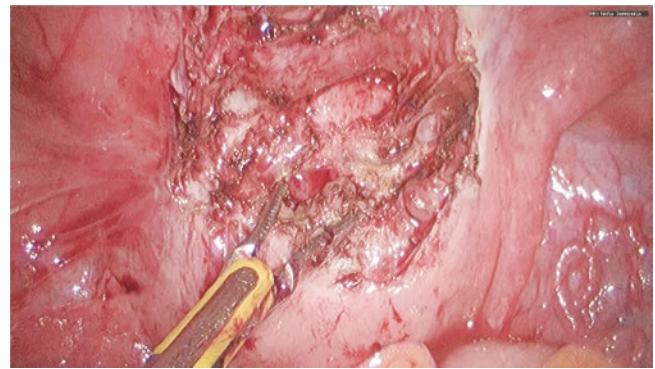

Fig. 31.14 Adequate space developed all around the fistula for closure (Grasper at the site of fistula)

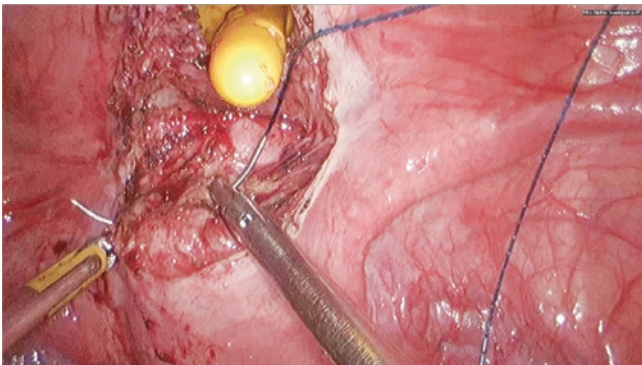


Fig. 31.15 Uterine defect closure started with 2-0 v loc suture

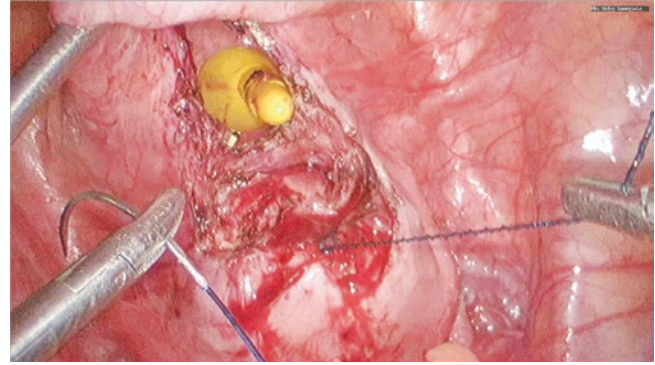


Fig. 31.16 Uterine defect closure in progress

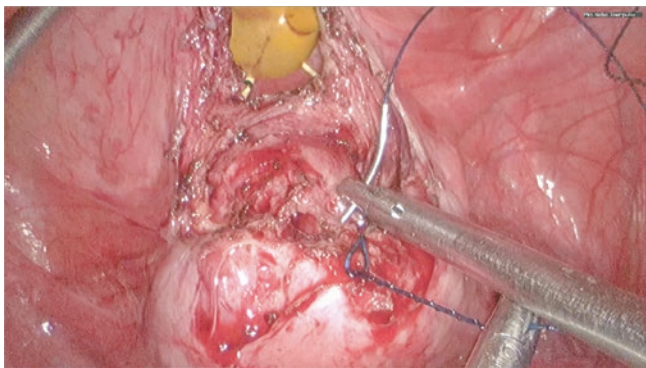


Fig. 31.17 Uterine rent closure in progress

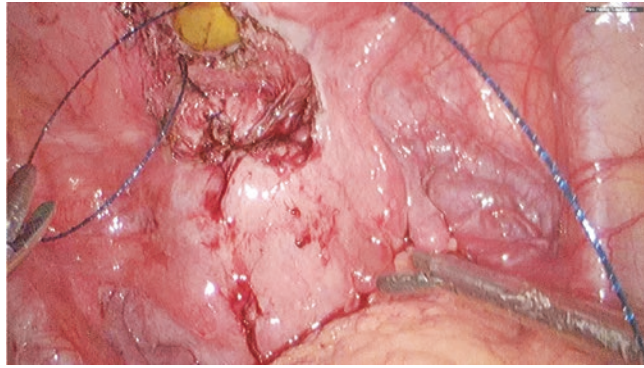


Fig. 31.18 Uterine rent closure completed

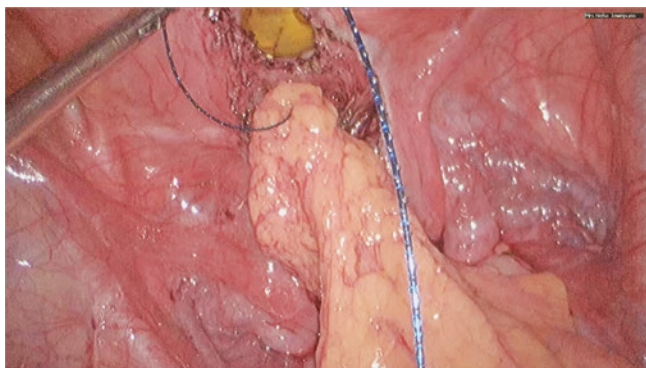

Fig. 31.19 Omental interposition started

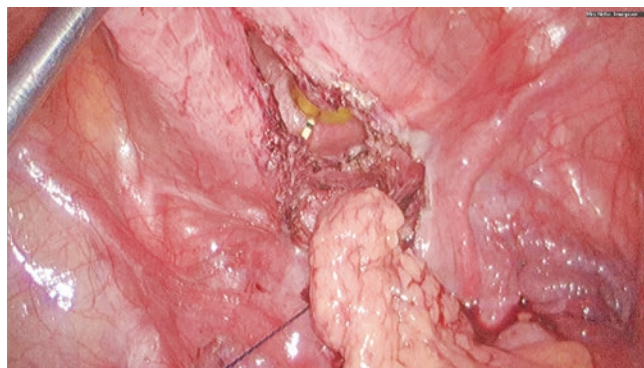


Fig. 31.20 Omental interposition completed

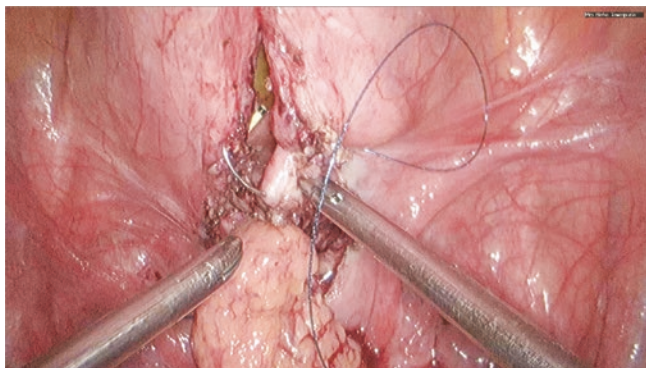


Fig. 31.21 Bladder closure with 3-0 V loc suture started

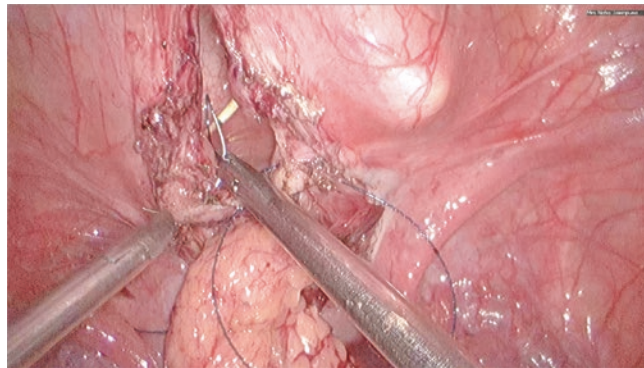


Fig. 31.22 Bladder closure as continuous suture in progress

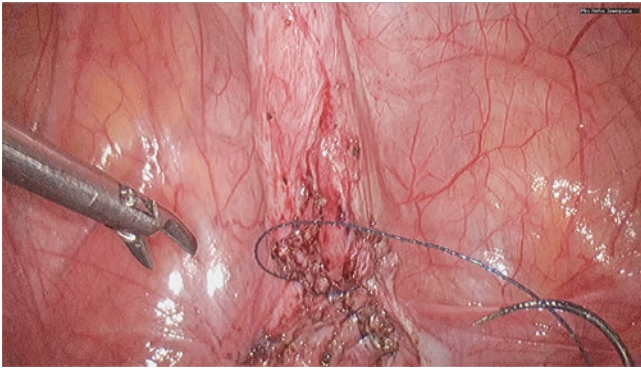


Fig. 31.23 Bladder closure in progress

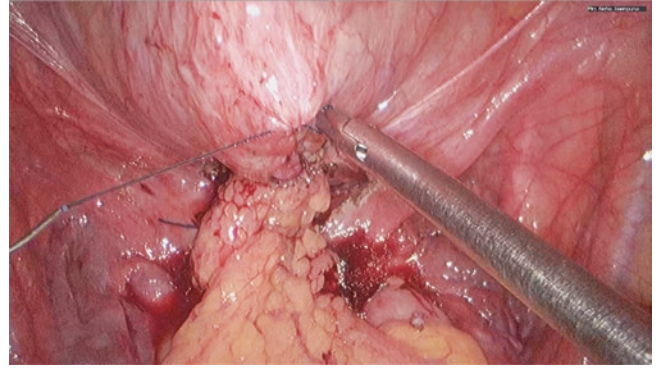


Fig. 31.24 Bladder closure completed

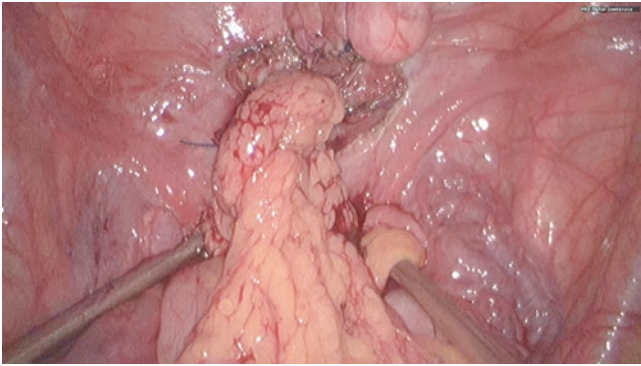


Fig. 31.25 Completed repair

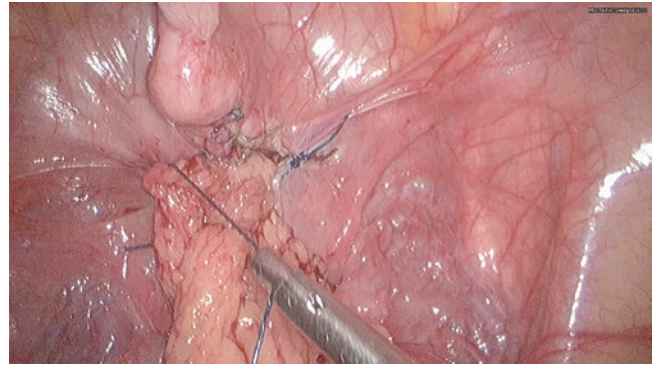


Fig. 31.26 Peritoneum closed

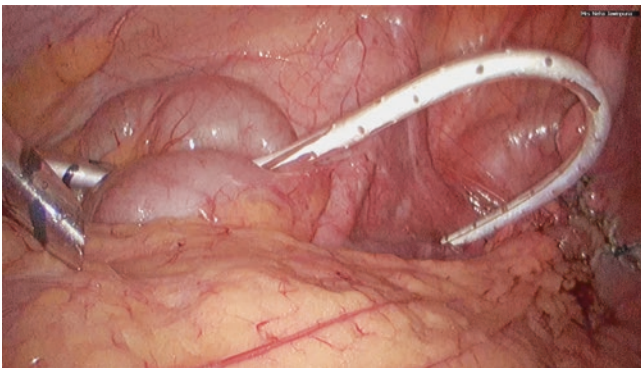


Fig. 31.27 Drain placed

References

1. Hemal AK, Kumar R, Nabi G. Post-cesarean cervicovesical fistula: technique of laparoscopic repair. *J Urol*. 2001;165(4):1167–8.
2. Ramalingam M, Senthil K, Renukadevi R, Pai MG. Laparoscopic repair of vesicouterine fistula – a case report. *Int Urogynecol J Pelvic Floor Dysfunct*. 2008;19(5):731–3. Epub 2007 Oct 27.

Renuka Ramalingam, Kallappan Senthil,
and Mahesh R. Desai

32.1 Introduction and Indications

Large T1 bladder tumours, amenable T2 bladder tumours, urachal tumours, tumours in diverticulum, symptomatic benign tumors of the urinary bladder like endometriosis which are not involving ureteral orifice, may be managed by laparoscopic partial cystectomy [1–3].

32.2 Preliminary Evaluation

CT Scan or MRI Scan and cystoscopic biopsy are helpful to plan the procedure. Cystoscopy and transurethral resection of lesion with multiple cold cup biopsies of base and adjoining area of tumor and suspicious areas is a must to confirm that there is no carcinoma in situ changes or tiny tumors.

32.3 Surgical Technique

Transperitoneal approach is preferable to access most of the areas of bladder.

The patient is in either lithotomy or supine position with Trendelenburg tilt. The bladder is approached using four ports (umbilical telescope port, two ports in the mid-clavicular line 5 cm below and lateral to umbilicus and a flank port for hand instruments). Provision for intraoperative cystoscopy helps in locating the lesion and decide the

probable line of cystotomy. Cystoscopic marking of the line of excision with Colling's knife is a useful step but is optional.

In the case of malignant tumors, initially bilateral iliac lymphnode dissection is carried out. This is done by incising the peritoneum over the external iliac artery and removing the lymphatic package between iliac vessels and obturator nerve (this may be sent for a frozen section biopsy). Subsequently, the probable area of tumor is located and a cystotomy is made at least 2 cm away from the likely edge of tumor in case of malignant tumours (if needed a cystoscopic guidance can be used).

Electrocautery or ultracision can be used for the cystotomy. Cystotomy close to the lesion is enough for benign lesions like endometriosis. Once the edge of the lesion is seen, it is easier to complete the excision. Bladder defect is closed with continuous or interrupted 2-0 vicryl sutures. Distending the bladder will reveal any leak which can be oversewn. Omental reinforcement on suture line is preferable. Tube drain is left in through the flank port. Specimen is entrapped and retrieved by a 5 cm muscle splitting incision in the iliac region or by colpotomy.

32.4 Follow-Up

Postoperative Cystogram is done on day 10 to rule out any extravasation and the foley catheter is removed.

R. Ramalingam • K. Senthil, MCh (Urol., FRCS) (✉)
Urology Clinic, Gowtham Annexe, Coimbatore, India
e-mail: renuram_d@yahoo.co.in; senthilsatya@hotmail.com

M.R. Desai
MUPH, Nadiad, India

32.5 Comment

Partial cystectomy is feasible and preferable for benign tumours and selected malignant tumours.

32.6 Partial Cystectomy for Solitary TCC

Patient is put in the lithotomy and head low position. Cystoscopic marking of the line of excision with beesting knife is a useful step but is optional. Using four ports bilateral iliac lymphnode dissection is carried out. This is done by incising the peritoneum over the external iliac artery and

removing the lymphatic package between iliac vessels and obturator nerve sweeping from lateral pelvic wall (this may be sent for a frozen section biopsy).

Subsequently the probable area of tumor is located and a cystotomy is made at least 2 cm away from the likely edge of tumor (if needed a cystoscopic guidance can be used). After making a small cystotomy the telescope is introduced through the cystotomy into the bladder to define the line of division. Electrocautery or ultracision is used to complete the excision of tumor with clear margin. Bladder defect is closed with continuous or interrupted 2-0 vicryl. Specimen is entrapped and retrieved by a 5 cm muscle splitting incision in the iliac region. Ports and wound are closed.

32.7 Partial Cystectomy: Endometriosis

Figures 32.1–32.16

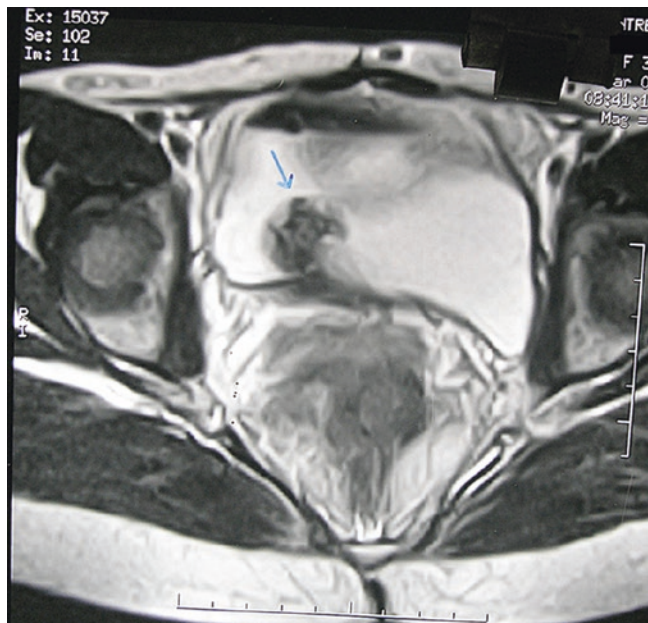


Fig. 32.1 MRI image of bladder mass

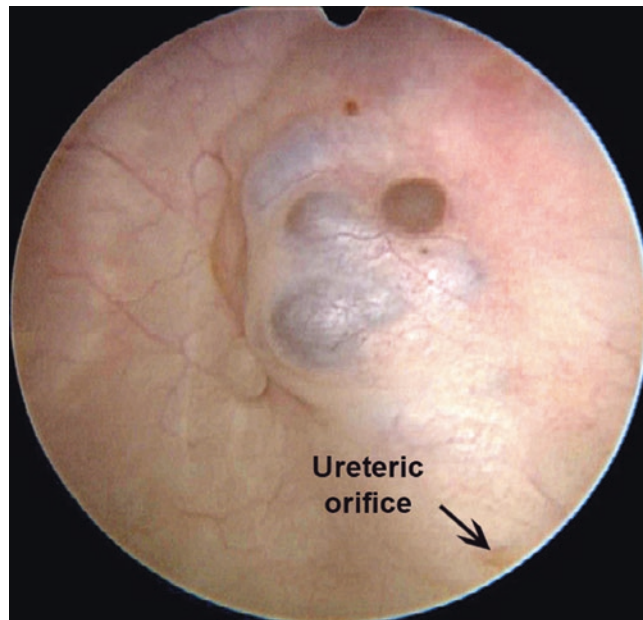


Fig. 32.2 Cystoscopy reveals a mass in the supratrigonal area

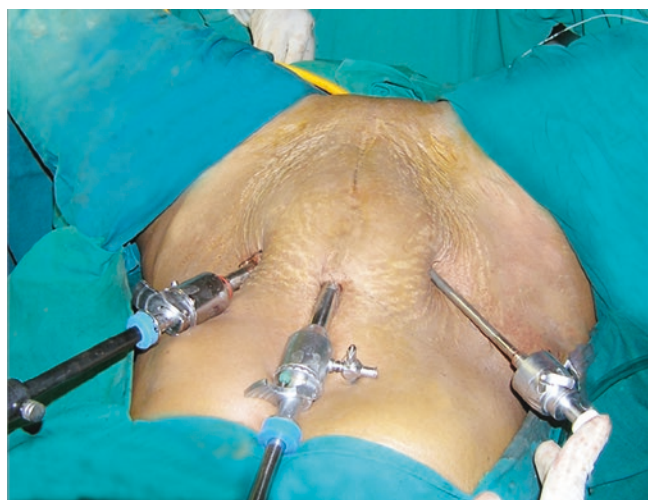


Fig. 32.3 Ports position

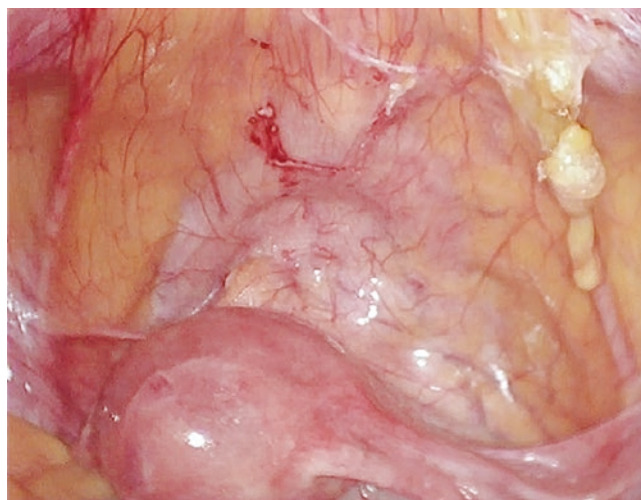


Fig. 32.4 Initial view of pelvis after release of omental adhesions

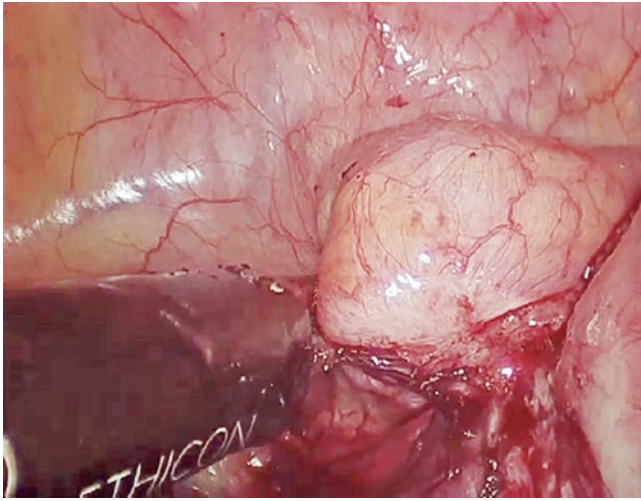


Fig. 32.5 Endometriotic mass seen in a collapsed bladder

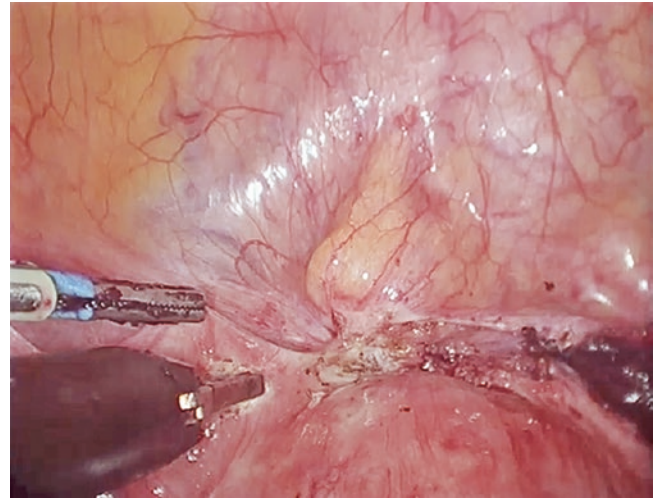


Fig. 32.6 Endometriotic mass felt to be arising from uterus

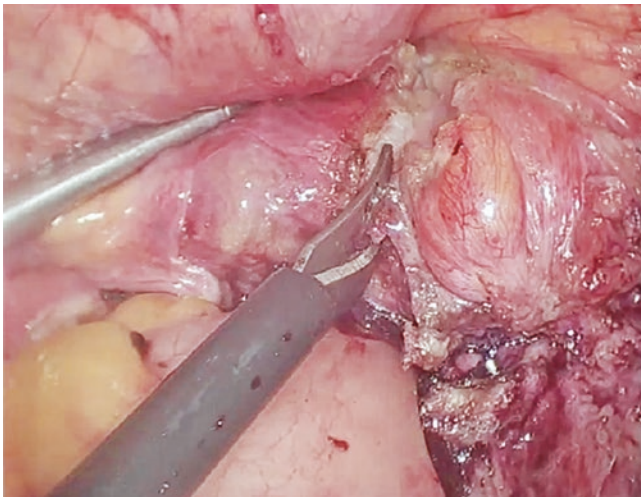


Fig. 32.7 Cystotomy being done around the mass

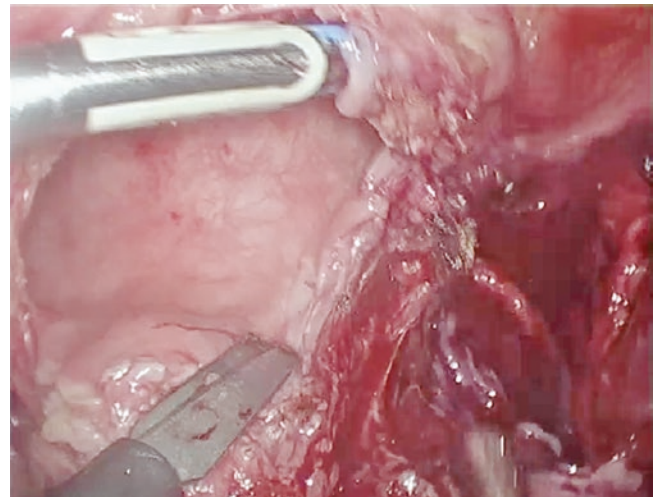


Fig. 32.8 Cystotomy done and endometriotic mass identified

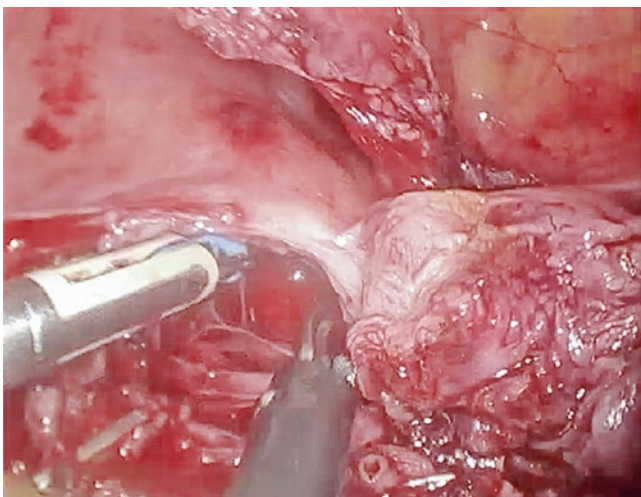


Fig. 32.9 Mass excised all around

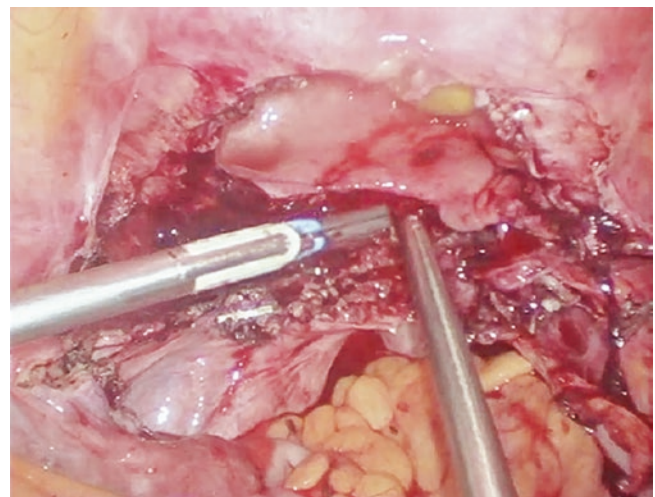


Fig. 32.10 Bladder after excision of mass

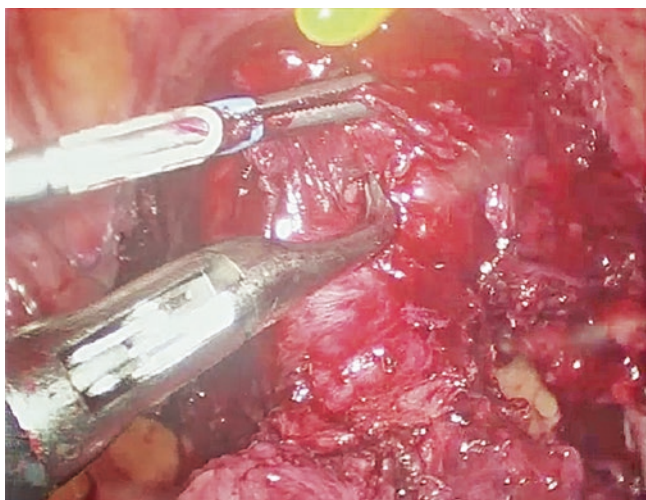


Fig. 32.11 Bladder further dissected off from uterus in preparation for Hysterectomy

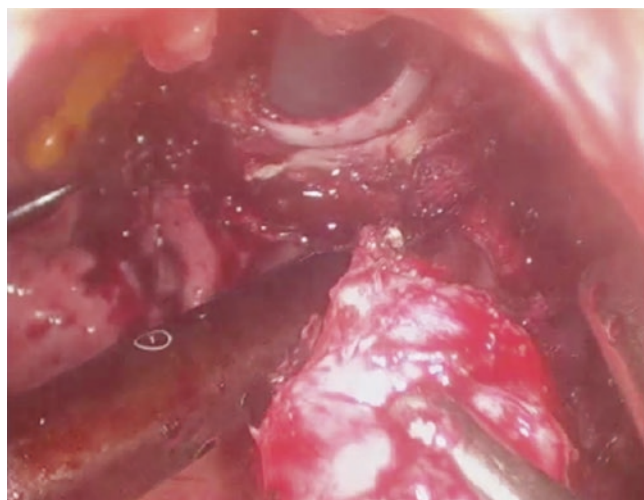

Fig. 32.12 Hysterectomy completed. Vaginal cone used to prevent pneumo-leak. Specimen along with uterus removed through colpotomy and vagina packed

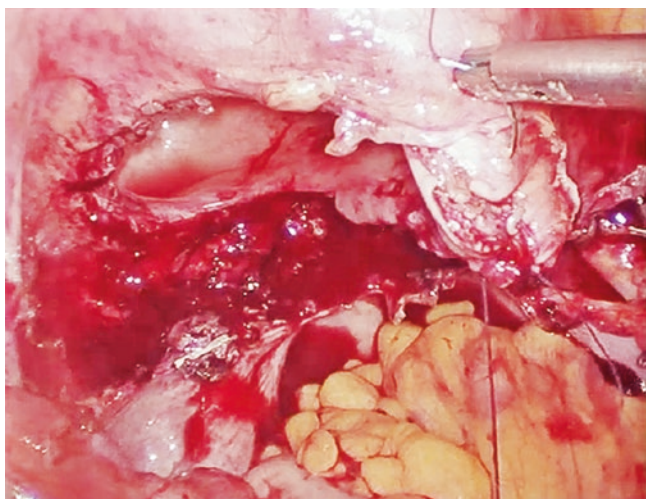


Fig. 32.13 Cystotomy closure with 3-0 vicryl suture in progress

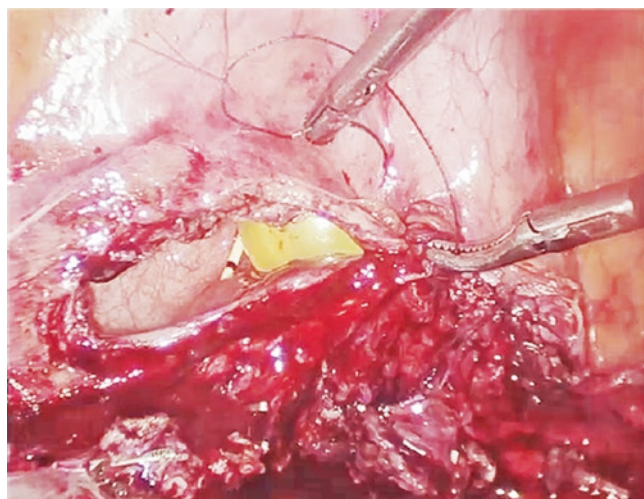


Fig. 32.14 Cystotomy closure in progress

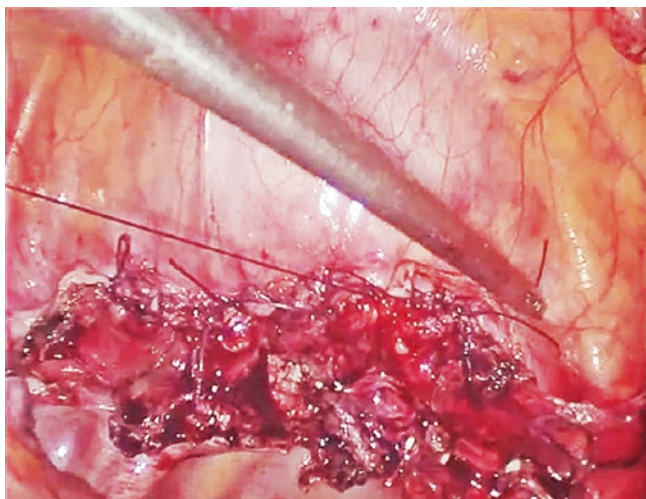


Fig. 32.15 Second layer closure with 2-0 vicryl completed. Bladder distended to check for leak

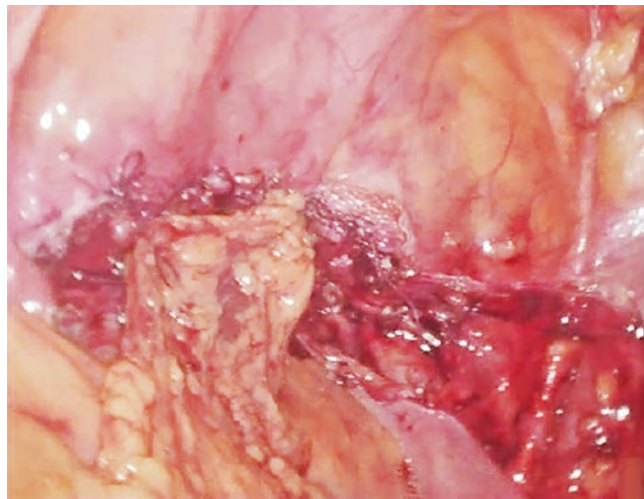


Fig. 32.16 Omental tacking over suture line

32.8 Partial Cystectomy in TCC

Figures 32.17–32.33

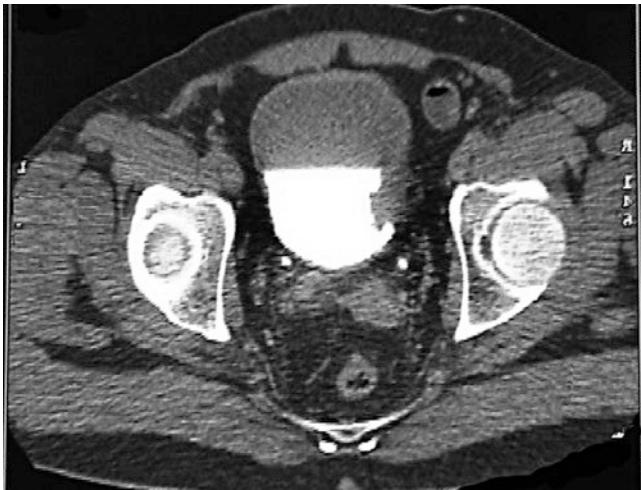

Fig. 32.17 CT Scan showing solitary bladder mass (TUR biopsy proved muscle invasive)

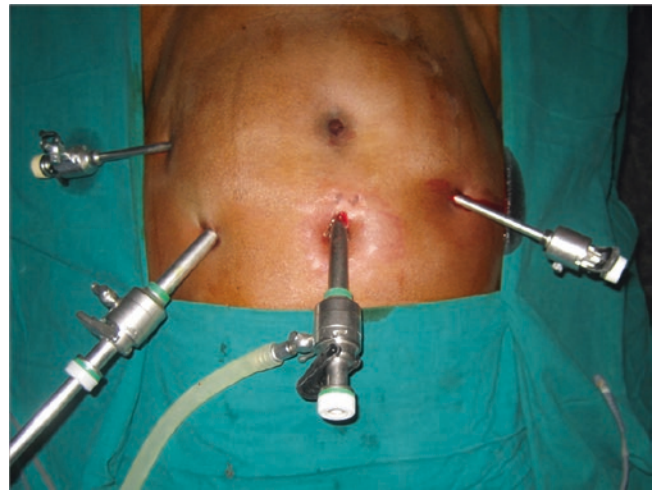

Fig. 32.18 Ports position

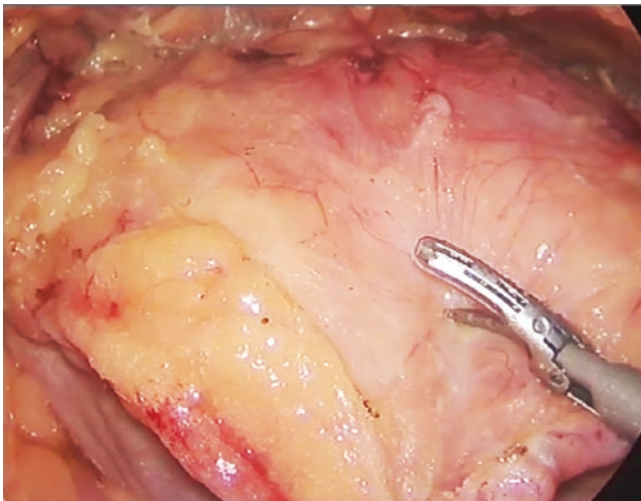


Fig. 32.19 Retzius space developed

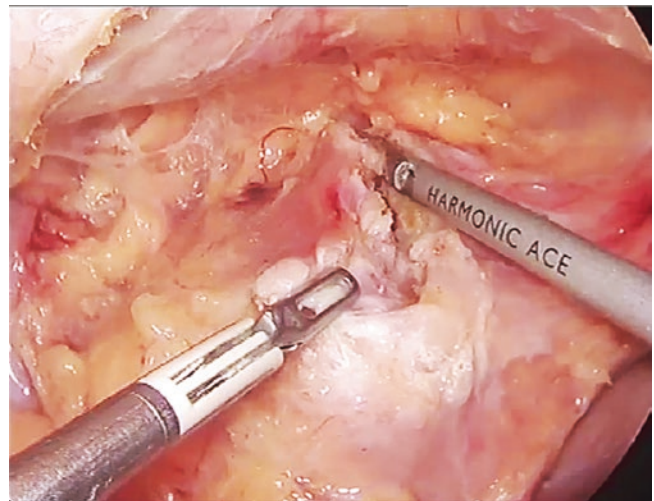


Fig. 32.20 Cystotomy along the left anterolateral wall, with approximately 1 cm margin from the tumour

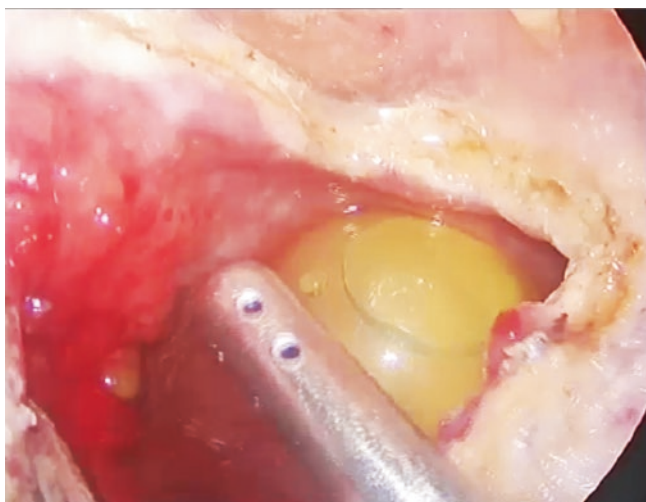


Fig. 32.21 Cystotomy extended and tumour visualized (post TUR BT)

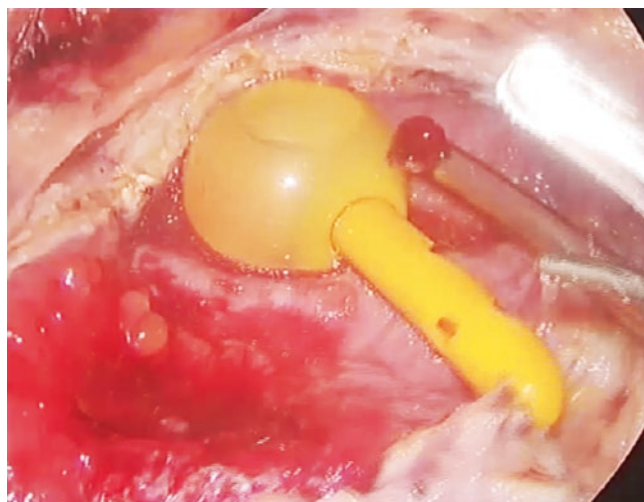


Fig. 32.22 Cystotomy extended distally beyond the tumour; ureteric orifice seen

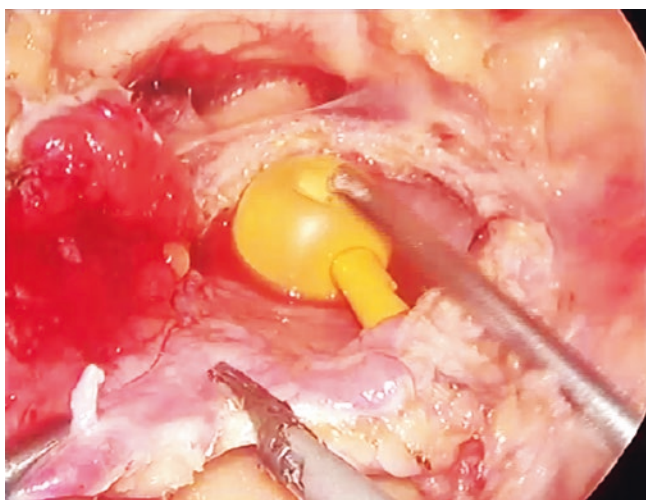


Fig. 32.23 Tumour excised from superior aspect

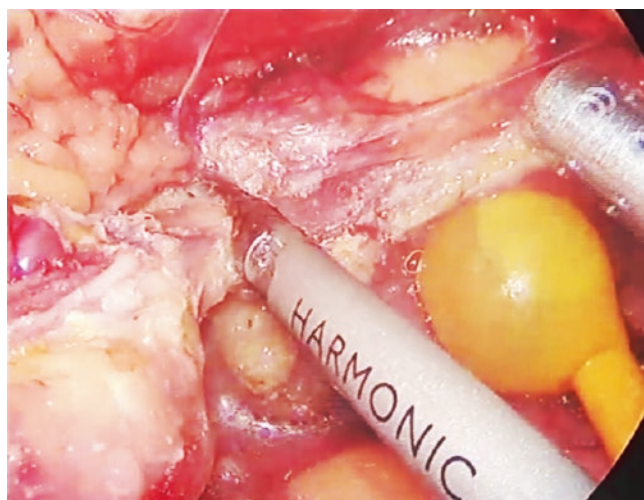

Fig. 32.24 Tumour completely excised with adequate margin

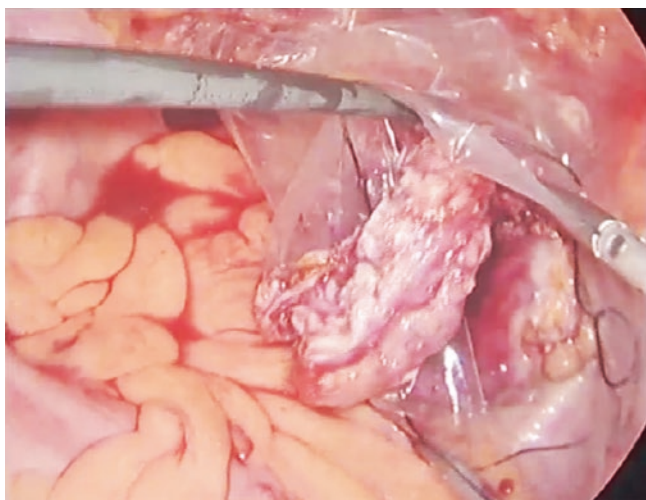


Fig. 32.25 Specimen bagged

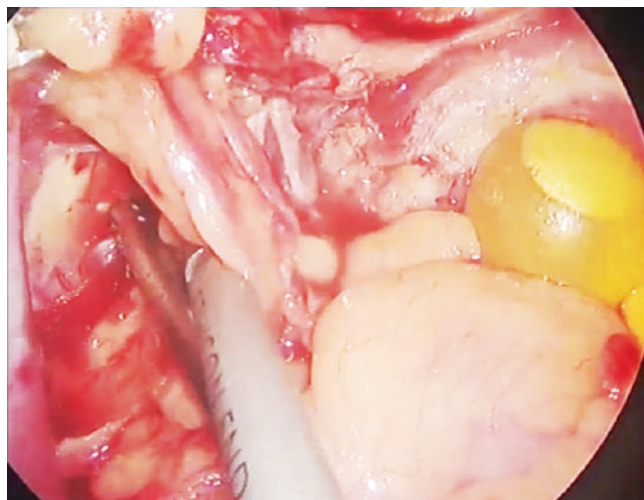


Fig. 32.26 Left pelvic lymphnode dissection in progress

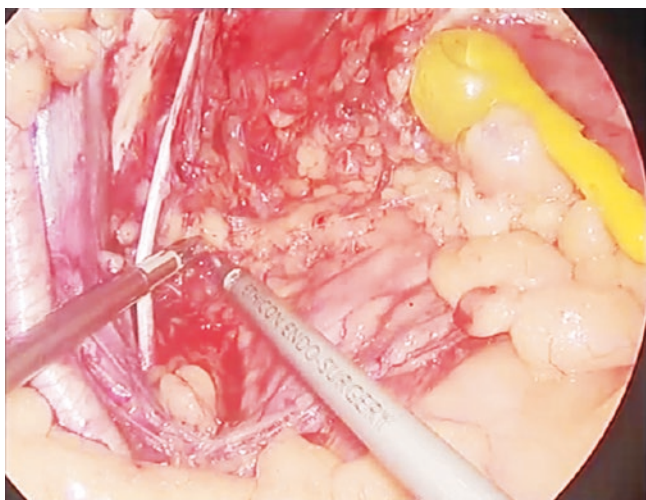


Fig. 32.27 Left pelvic lymphnode dissection complete

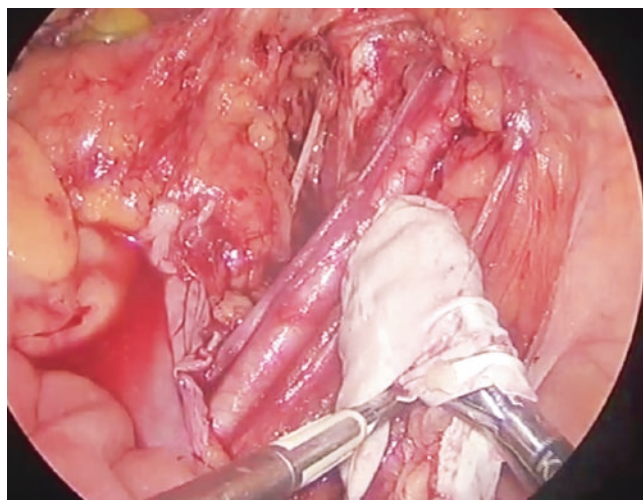


Fig. 32.28 Right pelvic lymphnode dissection complete and specimen bagged

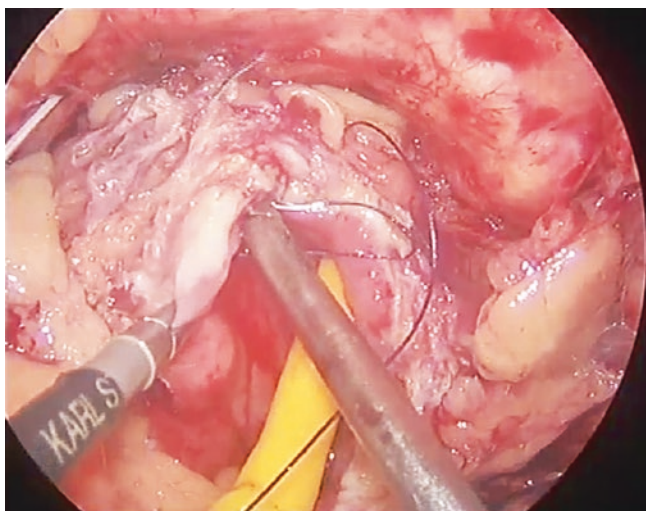


Fig. 32.29 Cystotomy closure with 2-0 vicryl suture started

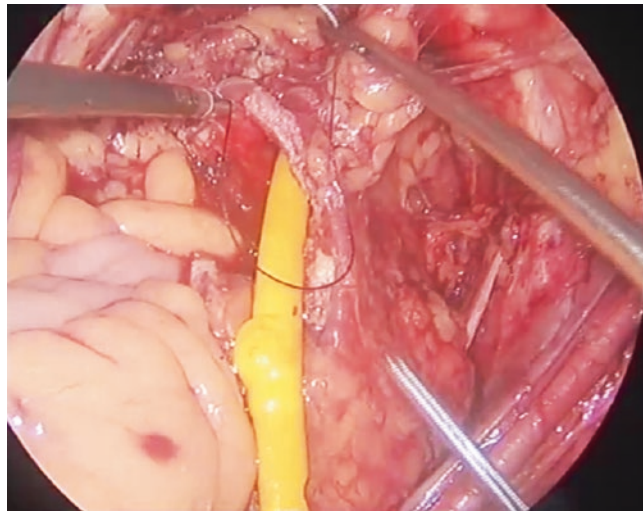


Fig. 32.30 Cystotomy closure with continuous suture in progress

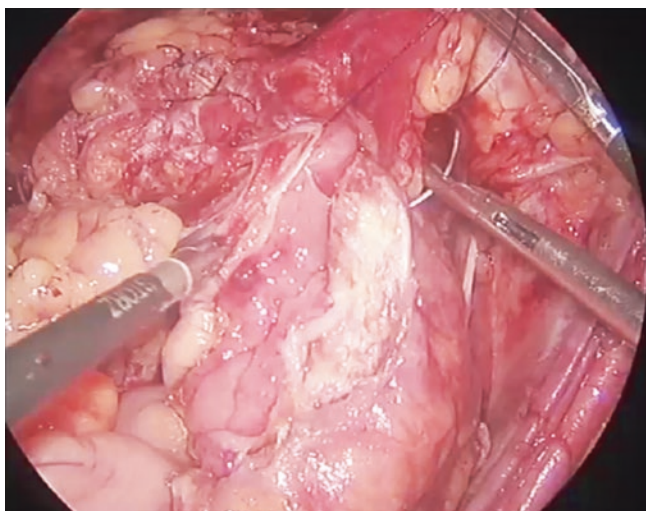


Fig. 32.31 Cystotomy closure in progress

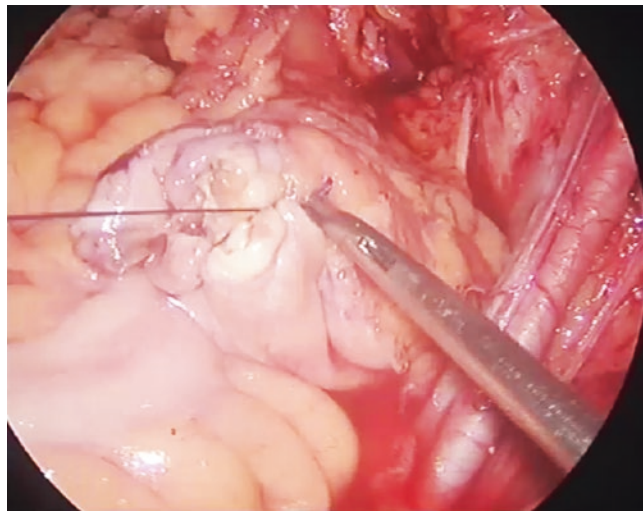


Fig. 32.32 First layer cystotomy closure completed

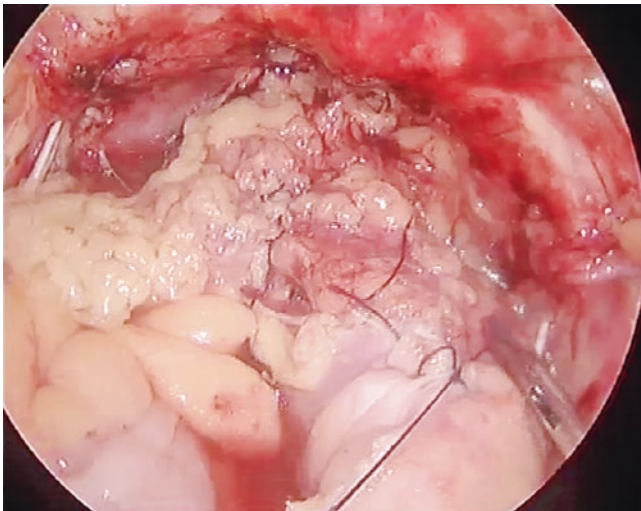


Fig. 32.33 Second layer closure completed

32.9 Partial Cystectomy in Urachal Tumour

Maresh R. Desai

32.9.1 Introduction and Indication

Partial cystectomy may be offered for patients with a small tumor usually in the dome, where a 2 cm clearance is possible. Tumor in a bladder diverticulum and urachal carcinoma are other possible indications for a partial cystectomy.

32.9.2 Preliminary Workup

CT Scan abdomen is done to rule out regional metastasis. Cystoscopy and transurethral resection of lesion with multiple cold cup biopsies of base and adjoining area of tumor and suspicious areas is a must to confirm that there is no carcinoma in situ changes or tiny tumors.

32.9.3 Surgical Technique

Patient is placed in lithotomy and head low position. Cystoscopic marking of the line of excision with beesting knife is a useful step but is optional. Using four ports bilateral iliac lymphnode dissection is carried out. This is done by incising the peritoneum over the external iliac artery and removing the lymphatic package between iliac vessels and obturator nerve sweeping from lateral pelvic wall (this may be sent for a frozen section biopsy).

Subsequently the probable area of tumor is located and a cystotomy is made at least 2 cm away from the likely edge of tumor (if needed a cystoscopic guidance can be used). After making a small cystotomy the telescope is introduced through the cystotomy into the bladder to define the line of division. Electrocautery or ultracision is used to complete the excision of tumor with clear margin. Bladder defect is closed with continuous or interrupted 2-0 vicryl. Specimen is entrapped and retrieved by a 5 cm muscle splitting incision in the iliac region. Ports and wound are closed.

Figures [32.34–32.45](#)

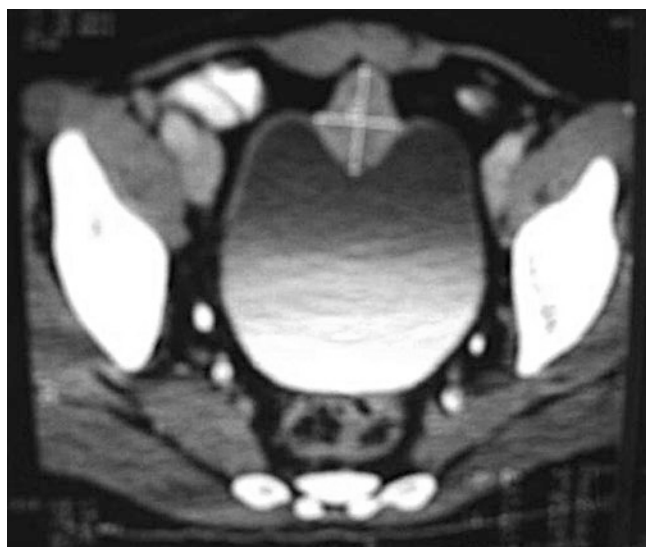


Fig. 32.34 CT Scan showing solitary urachal tumour apparently confined to bladder wall (about 3 cm diameter)

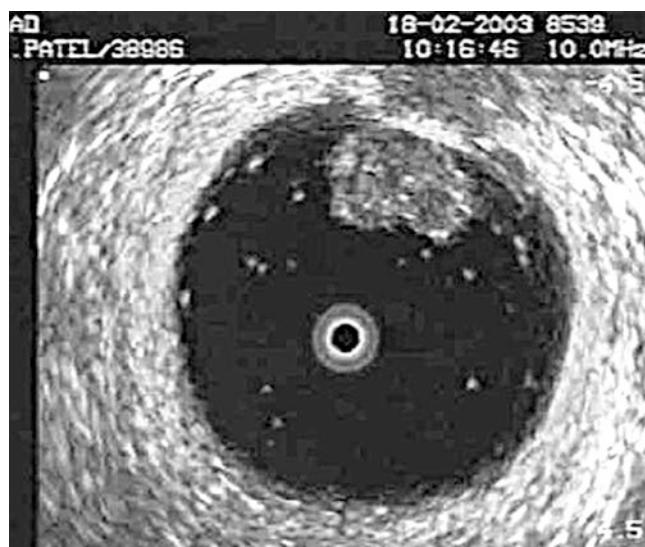

Fig. 32.35 Intracavitary ultrasound scan showing the tumour in the dome

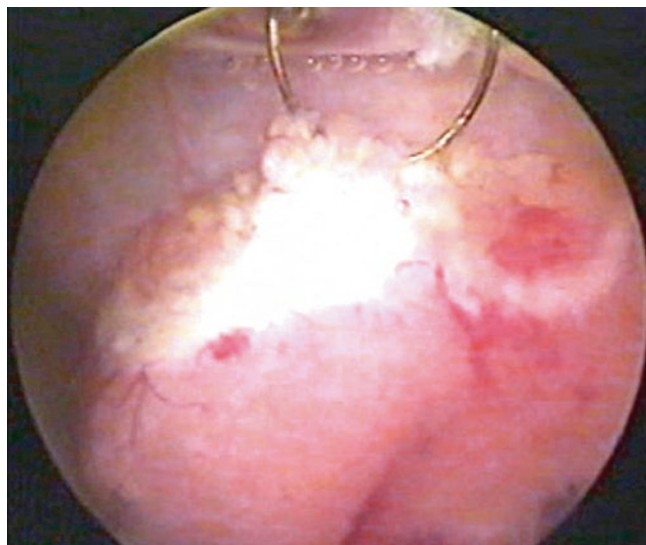


Fig. 32.36 Cystoscopy showing solid tumour in the dome of the bladder. TUR biopsy was reported as adenocarcinoma

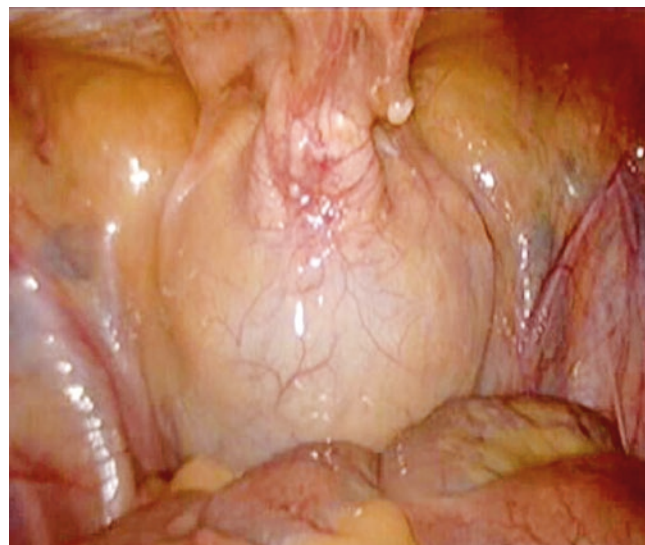


Fig. 32.37 Initial laparoscopic view showing tumour in the dome of the bladder

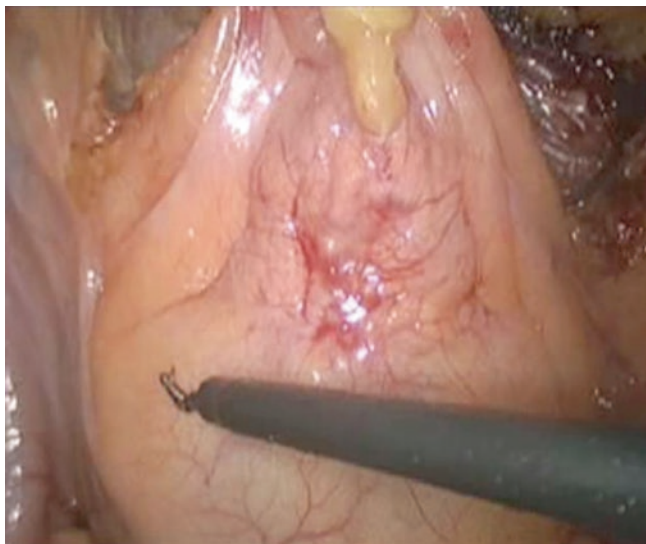

Fig. 32.38 Urachus dissected

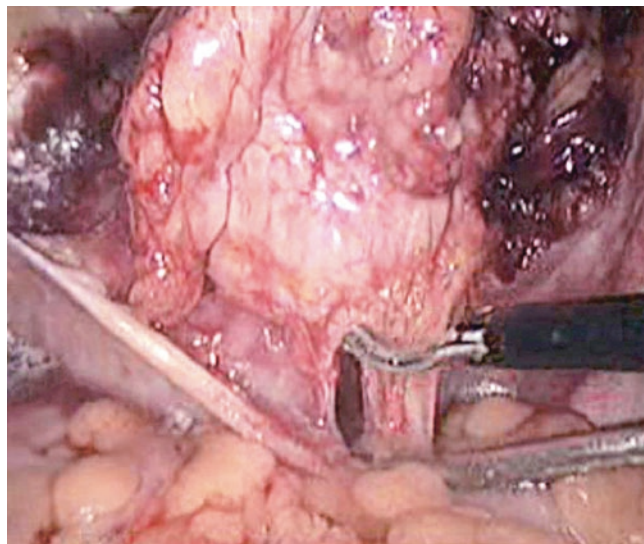


Fig. 32.39 Incision of the dome after dissecting the urachus

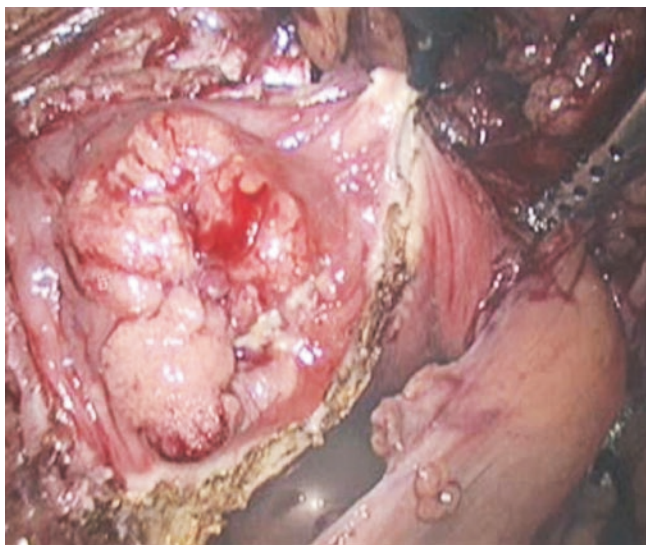


Fig. 32.40 Excision of the urachal tumour with clear margin

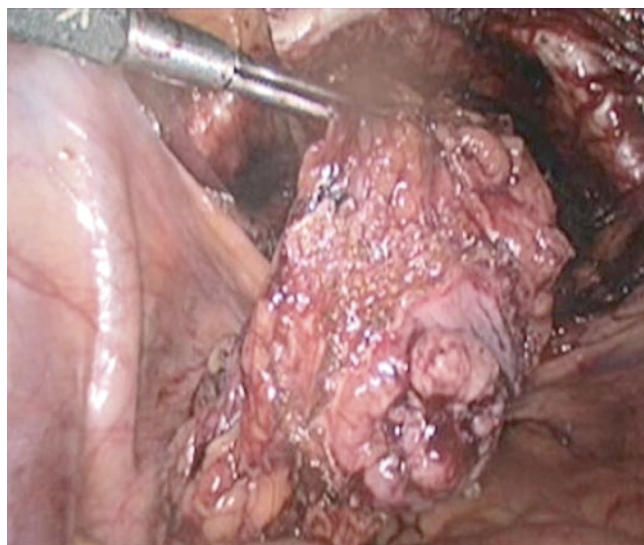


Fig. 32.41 Urachal tumour excised

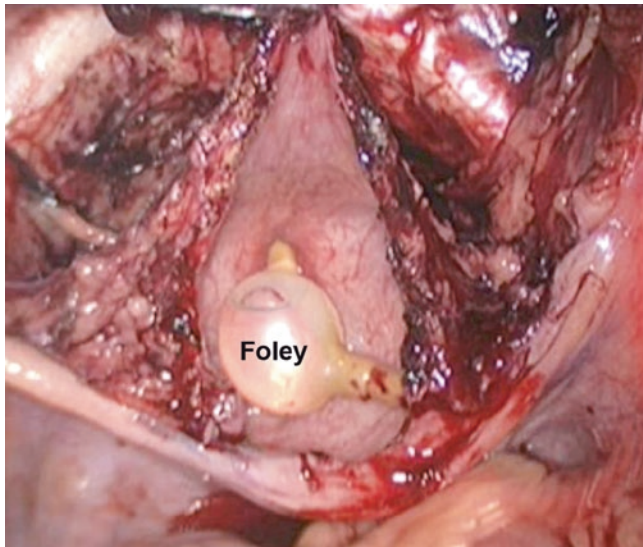


Fig. 32.42 View after excision of the tumour

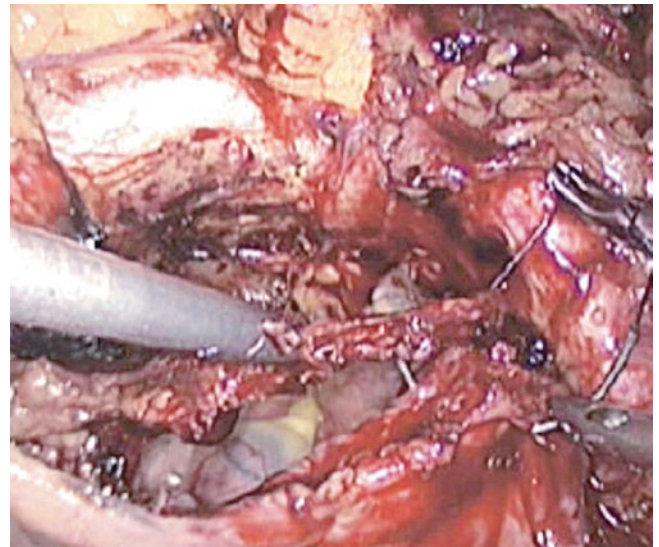


Fig. 32.43 Cystotomy closure using continuous 2-0 vicryl suture

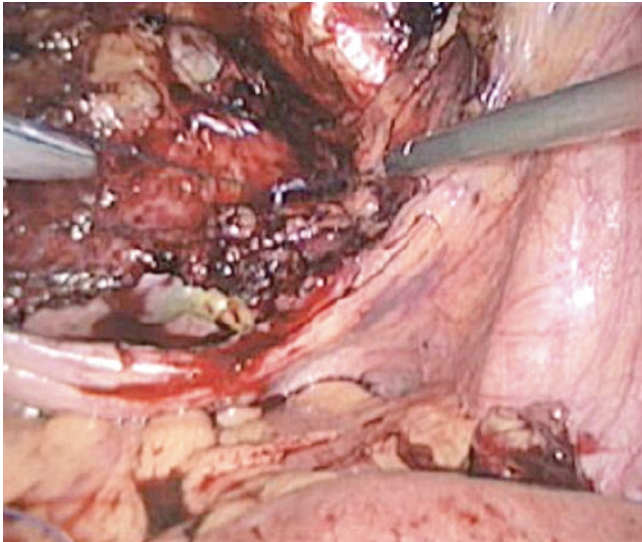


Fig. 32.44 Cystotomy closure in progress

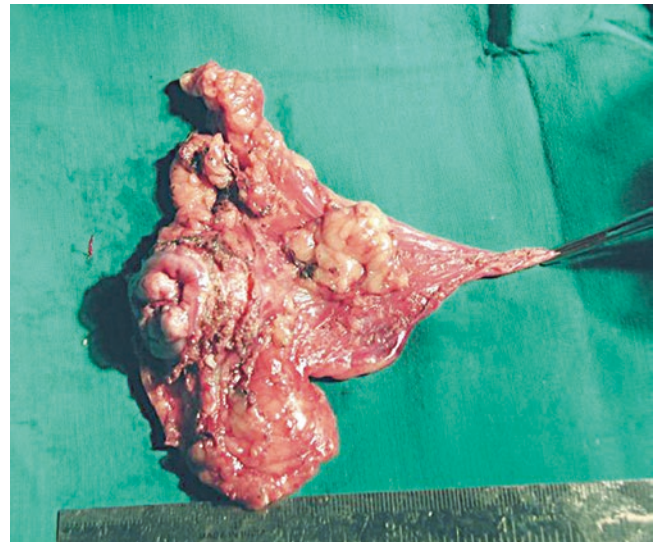


Fig. 32.45 Partial cystectomy specimen showing a good tumour free margin

References

1. Chapron C, Dubuisson JB, Jacob S, Fauconnier A, Da Costa Vieira M. Laparoscopy and bladder endometriosis. *Gynecol Obstet Fertil*. 2000;28(3):232–7.
2. Chapron C, Dubuisson JB. Laparoscopic management of bladder endometriosis. *Acta Obstet Gynecol Scand*. 1999;78(10):887–90.
3. Seracchioli R, Mannini D, Colomo FM, et al. Cystoscopy – assisted laparoscopic resection of extramucosal bladder tumor. *J Endourol*. 2002;16(9):663–6.

Arvind Ganpule and Mahesh R. Desai

33.1 Introduction and Indications

The advantages of robot are well known in pelvic surgeries. The advantage is multiplied particularly in reconstructions. The steps and indications of robotic partial cystectomy mirror that of laparoscopic partial cystectomy. The difference lies in the port position, as an additional 5 or 10 mm port should be inserted for the assistant [1–3] (Fig. 33.2).

33.2 Surgical Technique

The patient is placed in a steep trendelenburg position (Fig. 33.3). Special care should be taken to prevent pressure related injuries. The chest is strapped, the eyes are covered. In contrast to laparoscopic procedure the legs should be abducted and flexed in such a way that the robot can be docked in between the legs (Fig. 33.3). The port position is as shown in the figure (Fig. 33.2). The ports are placed in a fan shaped manner. The distance between the ports should be at least five fingers so as to avoid clashing in between the arms. Typically the telescope should be zero degree. The instruments used include a robotic shears, robotic large needle holder, robotic Maryland or robotic grasper (Intuitive surgicals Inc, Sunnyvale US).

Once the robot is docked, the peritoneum with the urachal remnants are taken down with the bladder. The bladder is dropped down. A partially filled bladder helps in this part of the dissection. The probable area of the tumour is localized using cystoscopic localization or using the drop down ultrasound probe.

In the event that the tumor is near the ureteric orifice a preplaced ureteric catheter helps in preventing injury to the ureteric orifice. The tumor is excised using a electrocautery (Fig. 33.8) keeping a margin from the tumor. The suturing of the bladder defect is done using a 3-0 or 4-0 vicryl suture in a continuous fashion (Fig. 33.13). The robotic trocars do not require closure. All ports larger than 10 mm in size are closed. The specimen is examined after retrieving the specimen in a retrieval bag. A lymph node dissection is performed which includes the obturator, external and internal iliac templates. Drain is necessarily placed.

33.3 Post Operative Care

The indwelling catheter is placed in position for 5 days. The drain is removed once the drain output is less than 50 ml.

A. Ganpule (✉)
Vice- Chairman, Department of Urology,
Muljibhai Patel Urological Hospital,
Dr Virendra Desai Road, Nadiad, Gujarat, India
e-mail: doctorarvind1@gmail.com

M.R. Desai
Department of Urology, MUPH,
Nadiad, Gujarat,
India

33.4 Robotic Partial Cystectomy

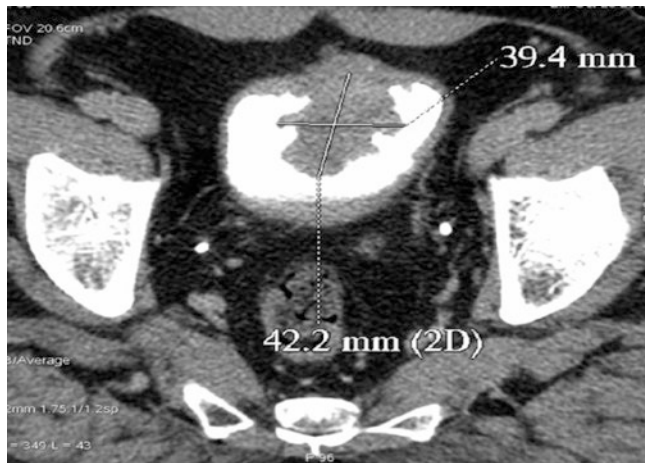


Fig. 33.1 CT scan showing urachal tumour

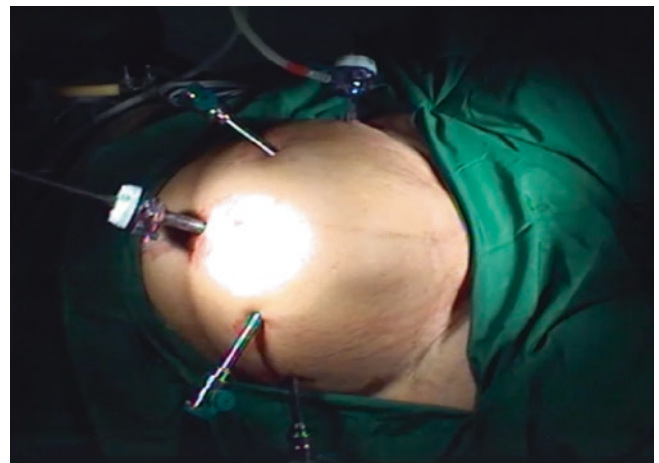


Fig. 33.2 Ports position

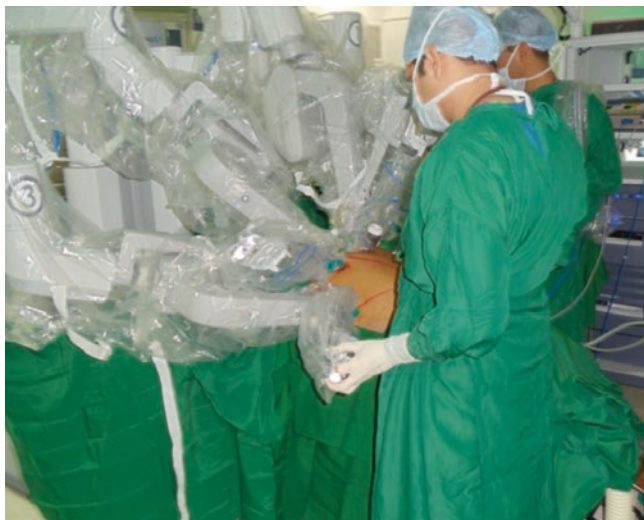

Fig. 33.3 Robot docked

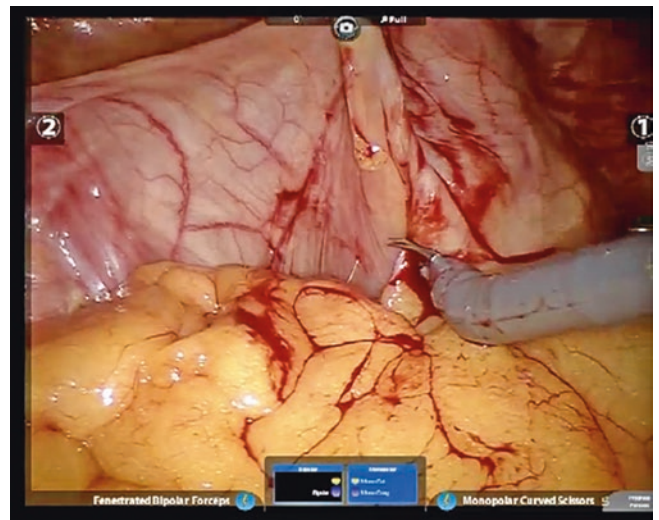


Fig. 33.4 Omental adhesions released

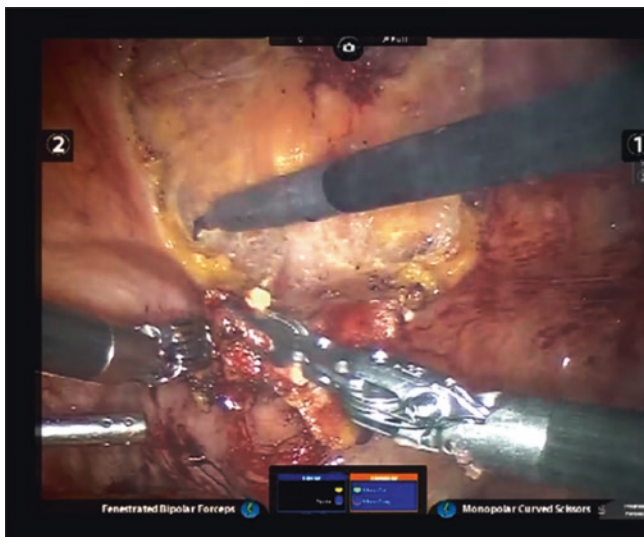

Fig. 33.5 Retzius space being developed

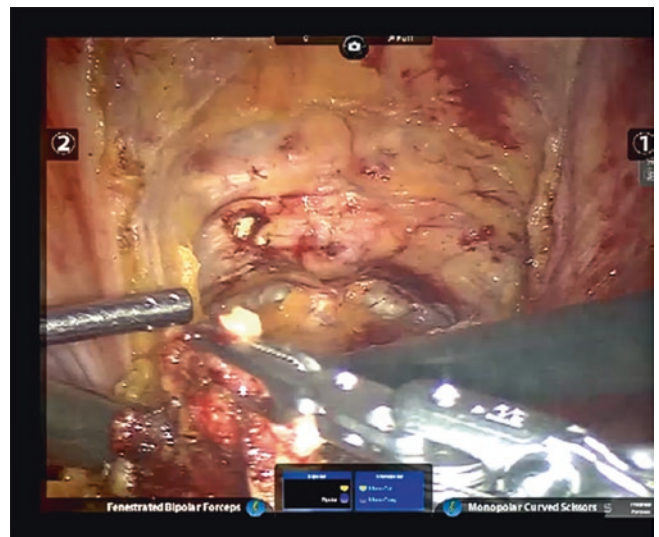


Fig. 33.6 Bladder completely dropped down

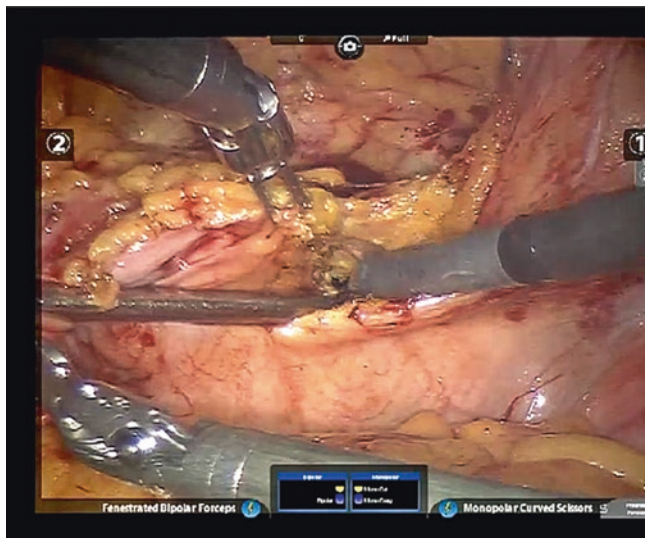


Fig. 33.7 Cystotomy being done laterally away from the mass

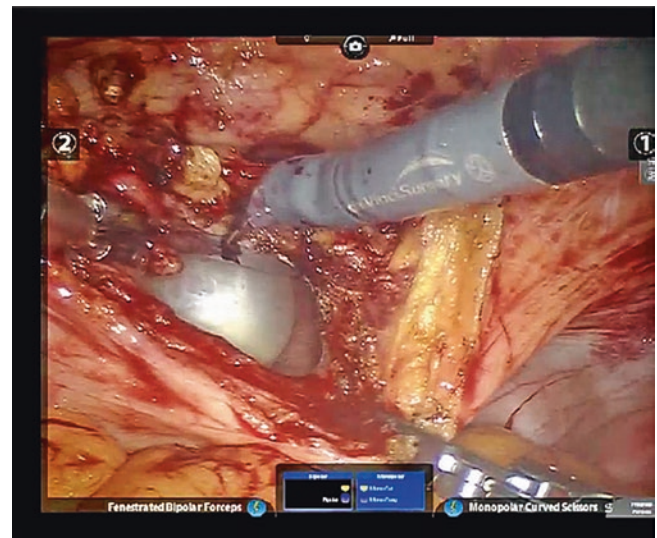


Fig. 33.8 Cystotomy extended

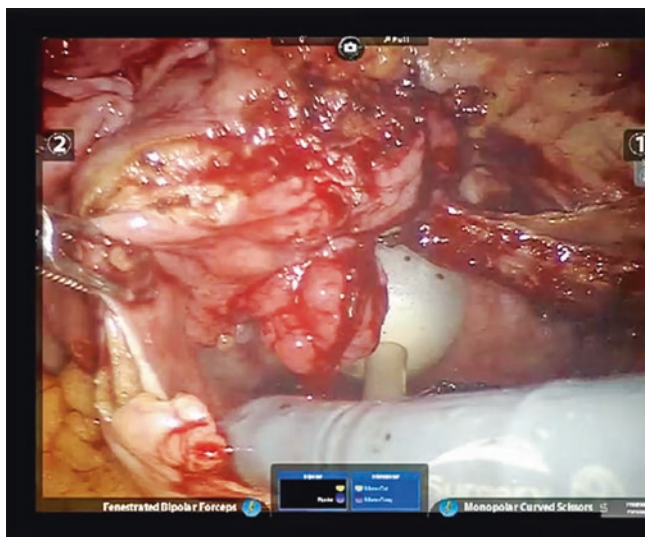


Fig. 33.9 Tumour visualised and cystotomy extended all around it

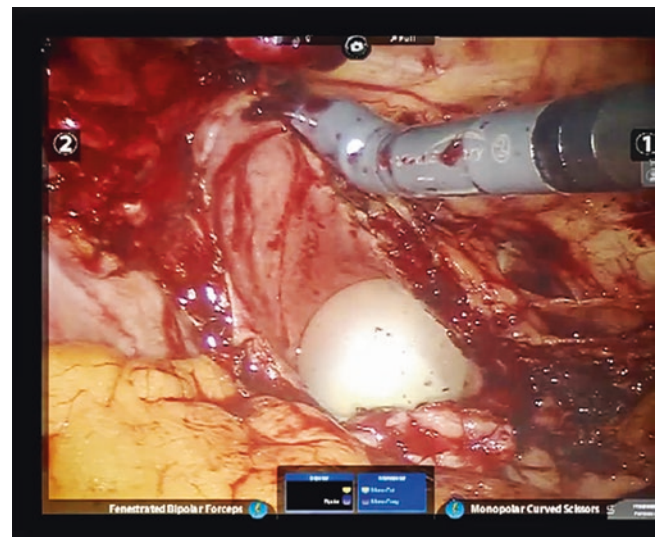


Fig. 33.10 Tumour excised

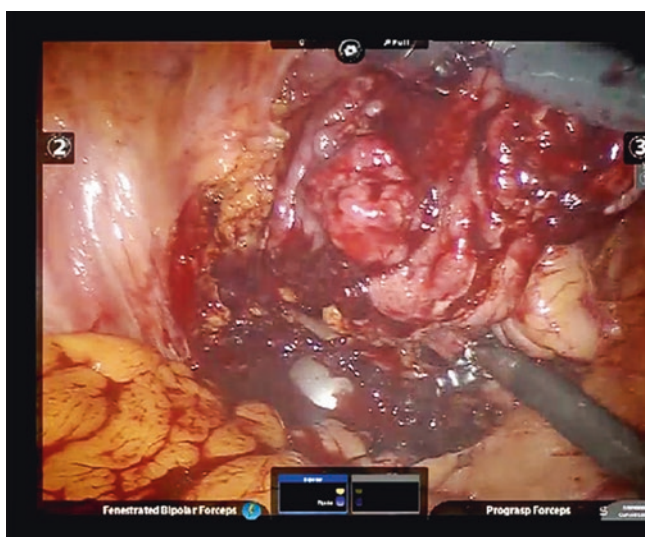


Fig. 33.11 Tumour completely excised with margin

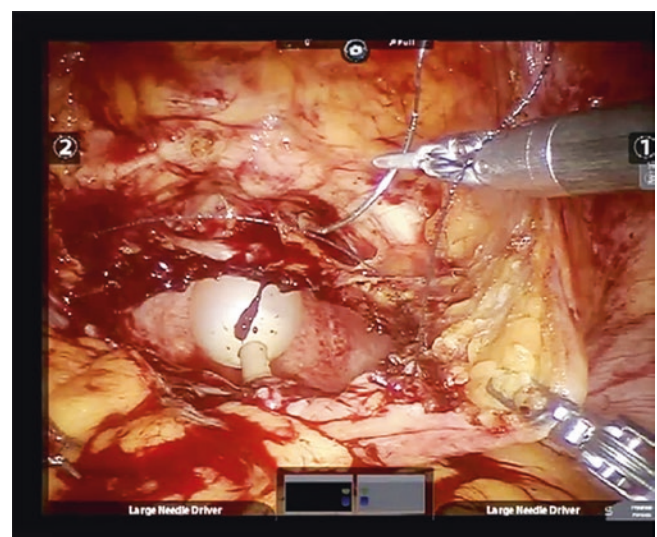


Fig. 33.12 Bladder closure started with 2-0 v lock sutures

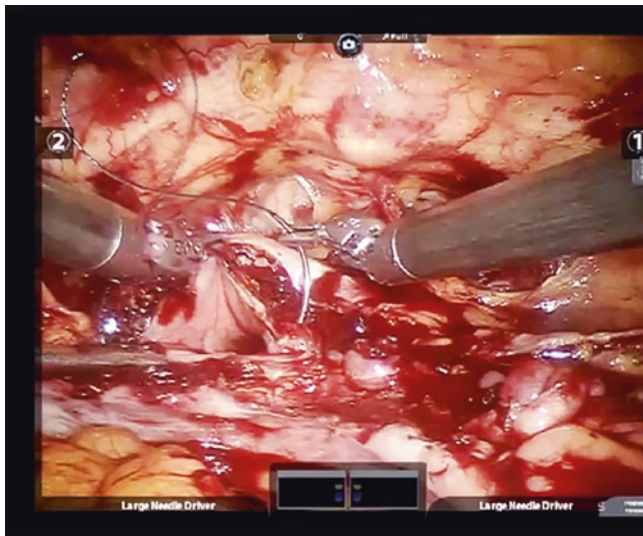


Fig. 33.13 Continuous suture in progress

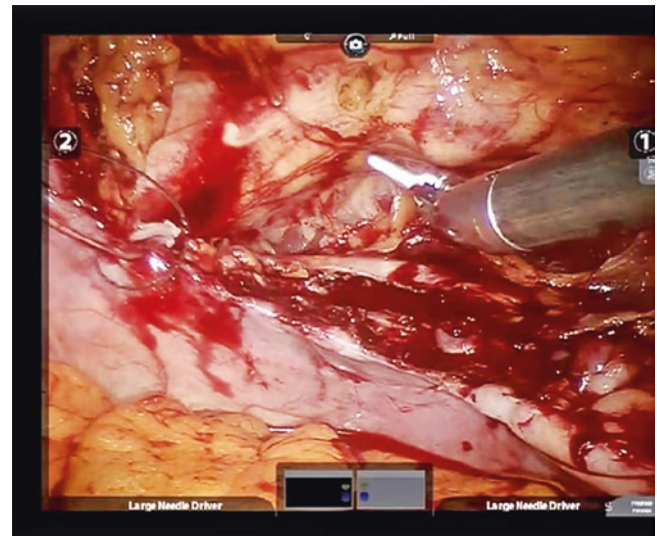

Fig. 33.14 First layer bladder closure complete

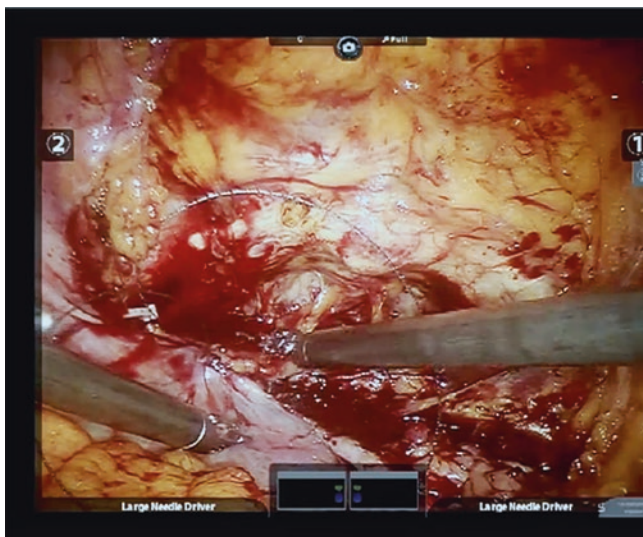


Fig. 33.15 Second layer bladder closure in progress

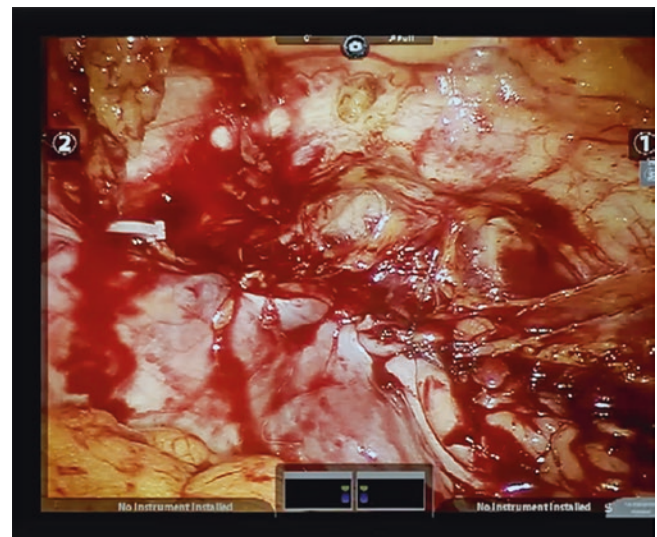

Fig. 33.16 Closure completed

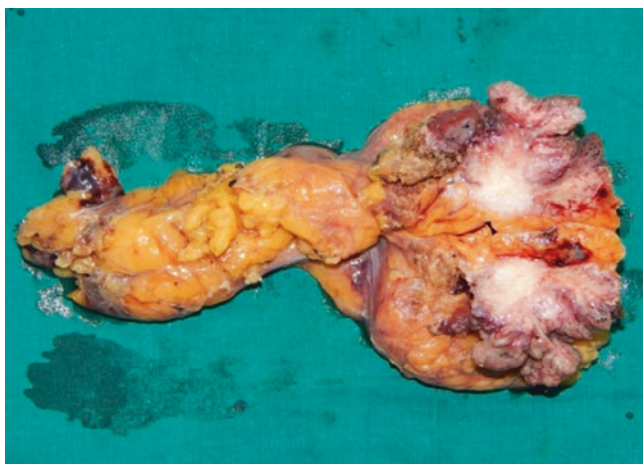

Fig. 33.17 Specimen with complete urachus and umbilicus

References

1. Williams CR, Chavda K. En bloc robot-assisted laparoscopic partial cystectomy, urachal resection, and pelvic lymphadenectomy for urachal adenocarcinoma. *Rev Urol.* 2015;17(1):46–9.
2. Rabah DM. Robot-assisted partial cystectomy for the treatment of urachal carcinoma. *Can J Urol.* 2007;14(4):3640–2.
3. Madeb R, Knopf JK, Nicholson C, Donahue LA, Adcock B, Dever D, Tan BJ, Valvo JR, Eichel L. The use of robotically assisted surgery for treating urachal anomalies. *BJU Int.* 2006;98(4):838–42.

34.1 Introduction

Urachus extends from the dome of bladder to the umbilicus. It has three distinct layers. Incomplete obliteration of the urachus manifests in various forms (i.e.) urachal cyst, urachal sinus, urachal diverticulum and patent urachal fistula. Symptomatic urachal cyst and patent urachal fistula warrant surgical excision and can be accomplished laparoscopically [1, 2]. Simple drainage of urachal cyst is associated with recurrent infections and even late occurrence of adenocarcinoma.

34.2 Surgical Technique

The patient is placed in the supine head low position. Initial cystoscopy is performed and the site of urachal fistula can be made out. In patient with patent urachal fistula, leak can be demonstrated through the umbilical sinus. A supra umbilical

10 mm camera port is inserted and two 5 mm working ports are inserted 4 cm lateral to the umbilicus. The fistula is detached at the umbilical end using ultracision or diathermy. It is rarely necessary to remove the umbilicus in benign lesions in children. The dissection is carried on till the dome of the bladder. The patent urachus with a rim of bladder is excised. The bladder defect is closed with 2-0 vicryl interrupted sutures and a Foley catheter is left indwelling urethrally. An omental patch may be tacked on top of the suture line in the bladder. The specimen can be retrieved through the 5 or 10 mm port. The umbilical defect gets closed secondarily without the need for any surgical closure.

34.3 Comment

Excision of urachal fistula can be completed laparoscopically with minimal morbidity to the patient. The chance of recurrent fistula is minimal with the use of an omental patch.

K. Senthil, MCh (Urol., FRCS) (✉)
Urology Clinic, Gowtham Annexe, Coimbatore, India
e-mail: senthilsatya@hotmail.com

M. Ramalingam
PSG Hospitals,
Coimbatore, India
e-mail: uroram@yahoo.com

34.4 Laparoscopic Excision of Urachal Remnant

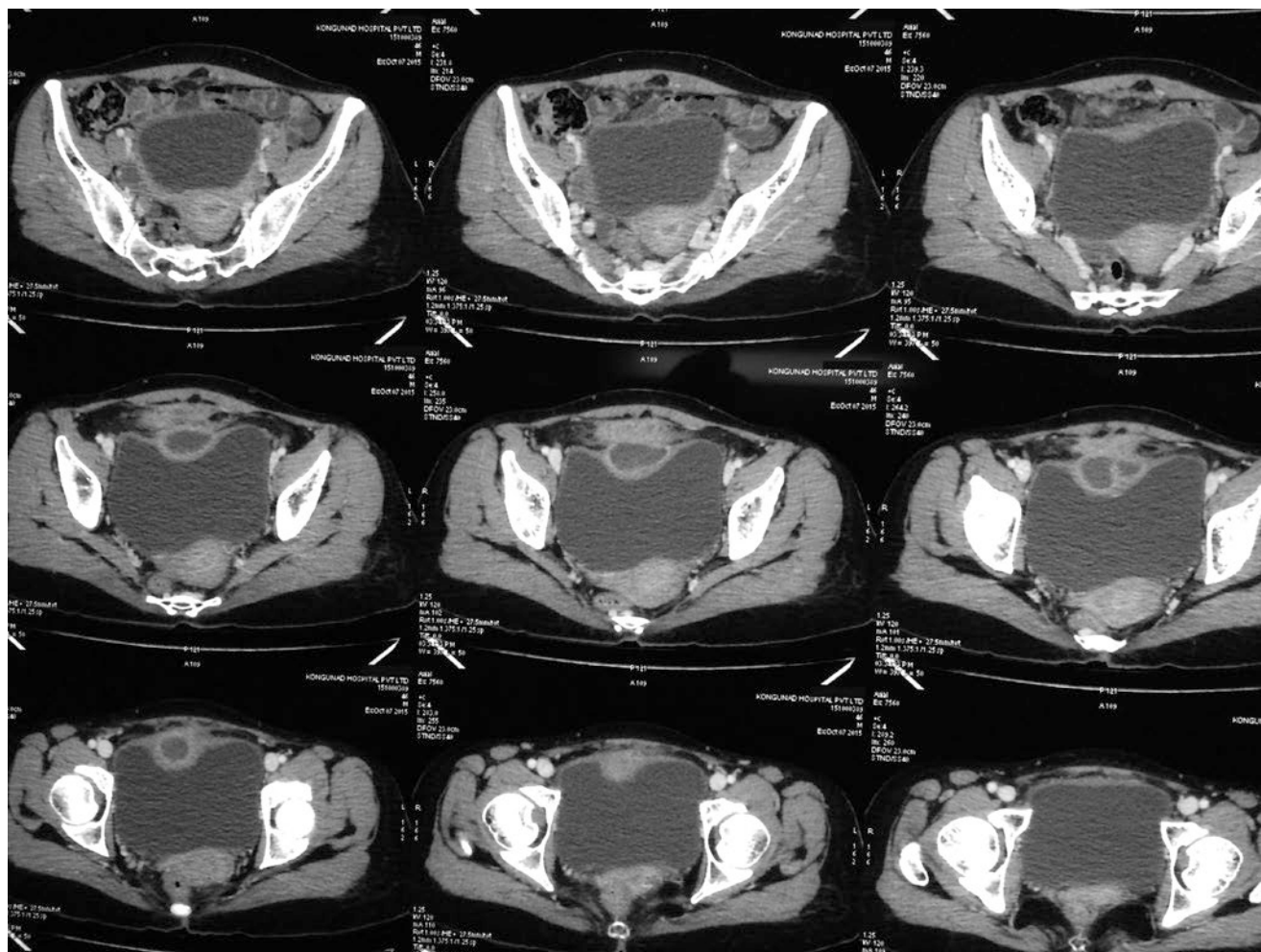


Fig. 34.1 CT image showing urachal cyst

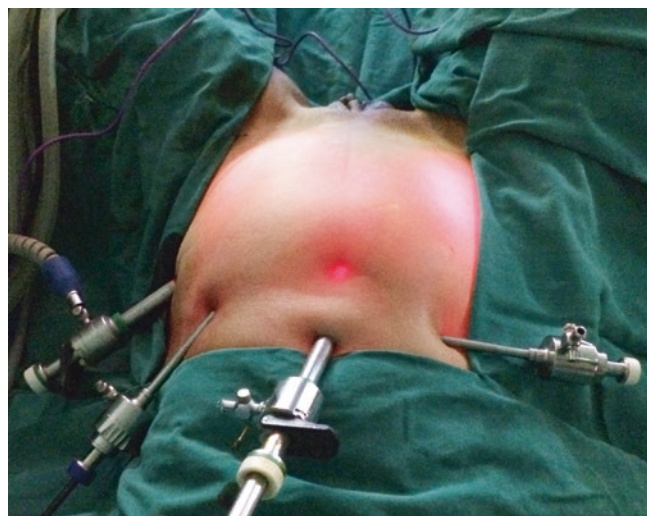

Fig. 34.2 Ports position

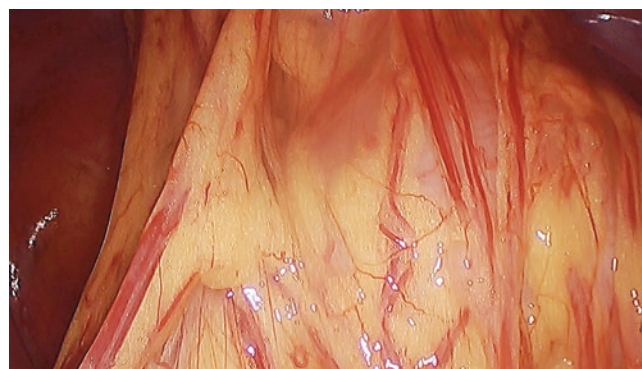


Fig. 34.3 Initial view of the urachal cyst

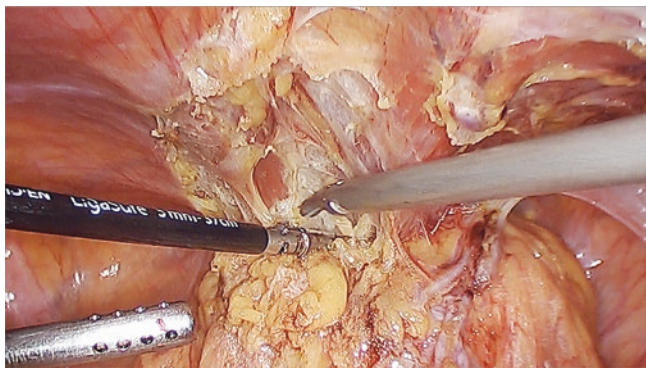


Fig. 34.4 Pre peritoneal space being developed anterior to cyst and extended down to bladder

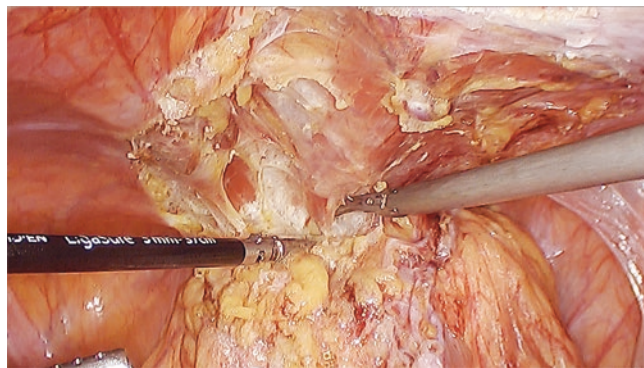


Fig. 34.5 Urachal remnant and cyst dropped down from the anterior abdominal wall

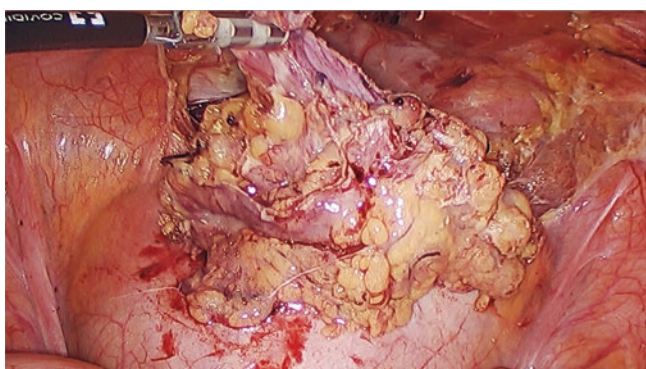


Fig. 34.6 Preperitoneal space completely developed and urachal cyst lifted (Grasper on urachus)

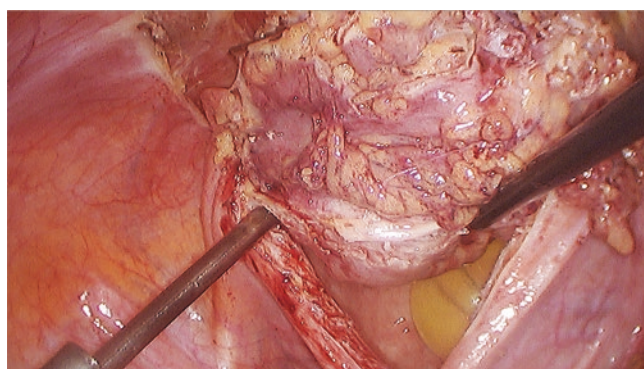


Fig. 34.7 Cystotomy posterior to mass to rule out bladder tumour

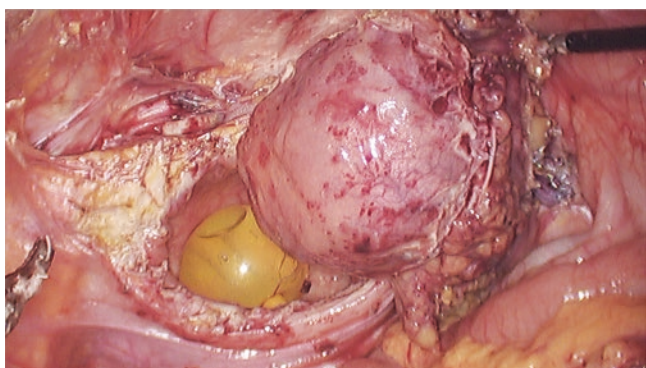


Fig. 34.8 Cystotomy extended all around and urachal cyst completely excised with part of dome of bladder

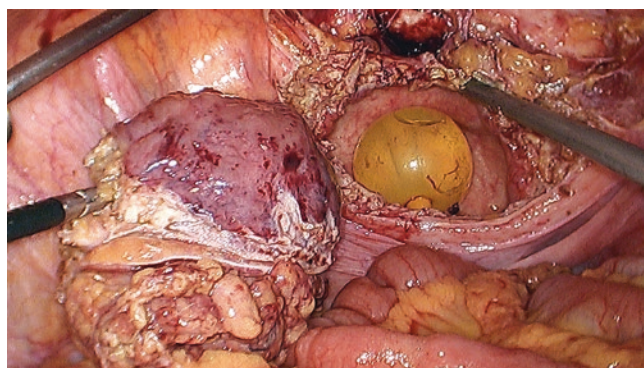


Fig. 34.9 Urachal cyst excised

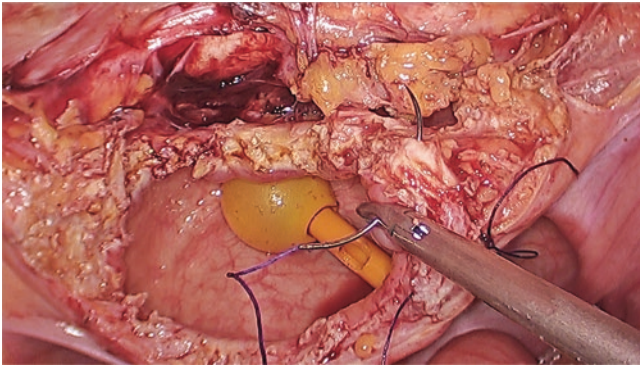


Fig. 34.10 Cystotomy closure started with 2-0 vicryl suture

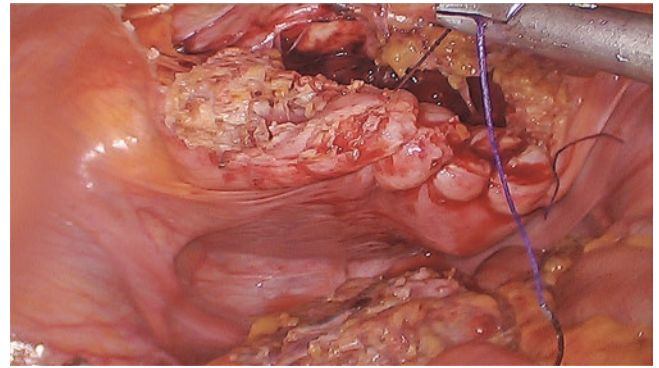


Fig. 34.11 Cystotomy closure with continuous sutures in progress

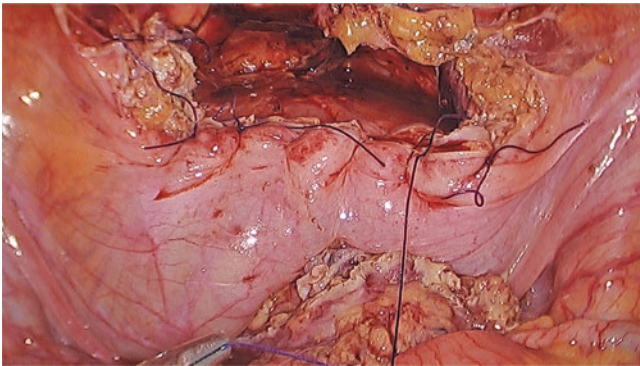


Fig. 34.12 Cystotomy closure complete

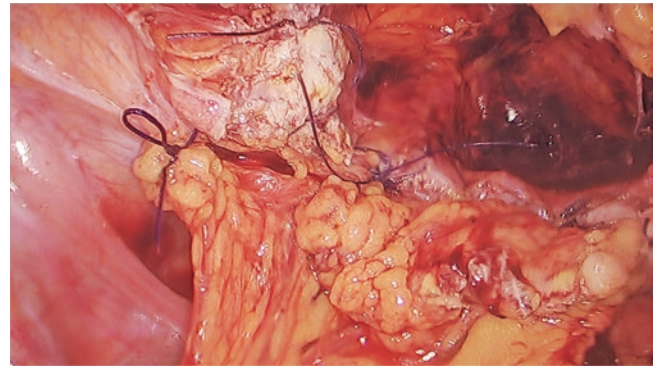


Fig. 34.13 Omental covering for suture line

34.5 Excision of Patent Urachus with Urachal Fistula

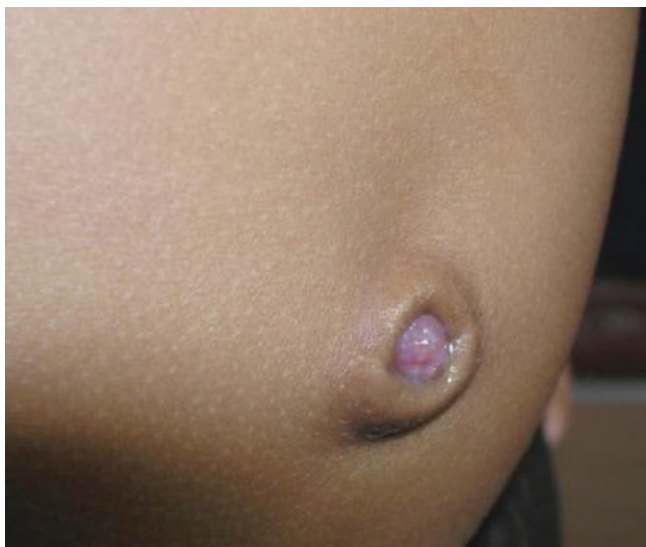

Fig. 34.14 Umbilical sinus through which urine dribbles continuously

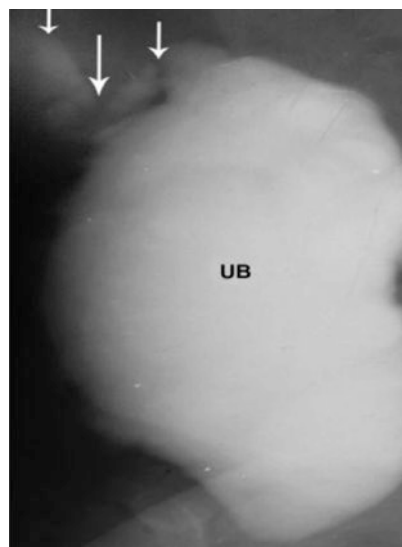


Fig. 34.15 MCU showing urachal fistula

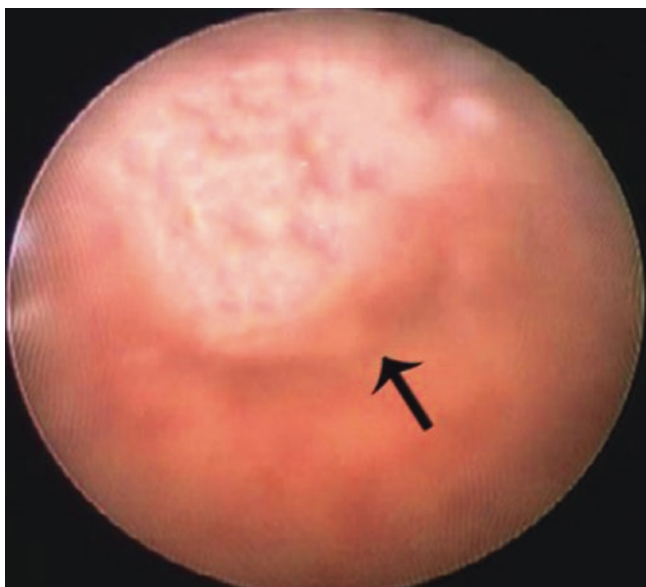


Fig. 34.16 Cystoscopy showing a sinus in the dome of the bladder (while the bladder is getting filled, saline escapes through the umbilical sinus)

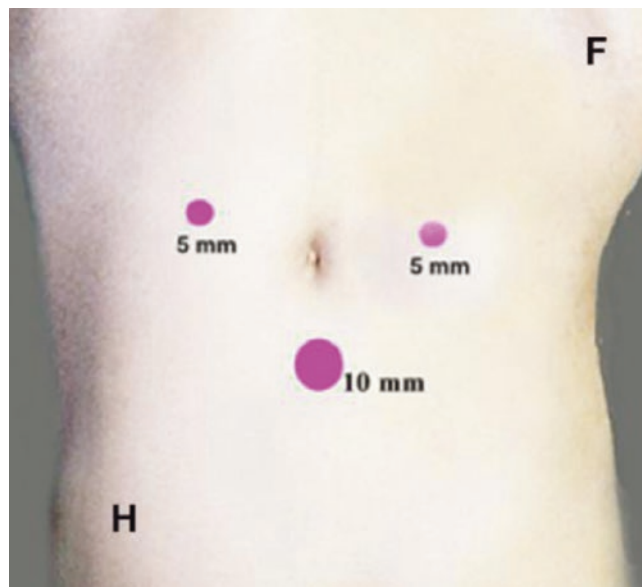


Fig. 34.17 Diagram showing ports position

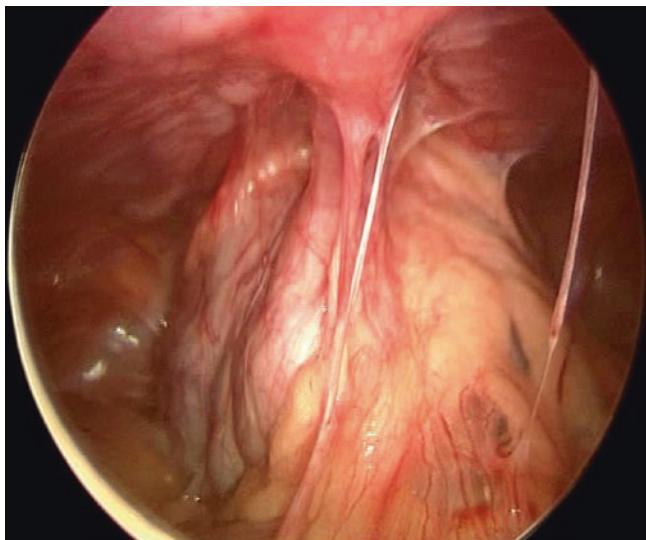


Fig. 34.18 Initial view of bladder with patent urachus

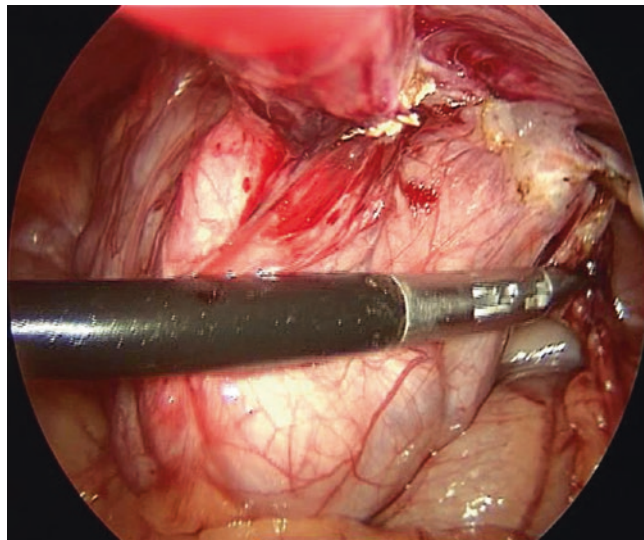


Fig. 34.19 Release of omental adhesions

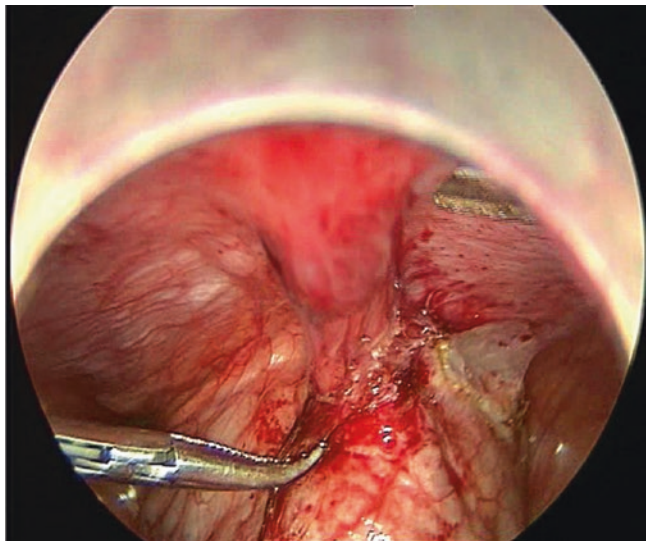


Fig. 34.20 Patent urachus clearly seen

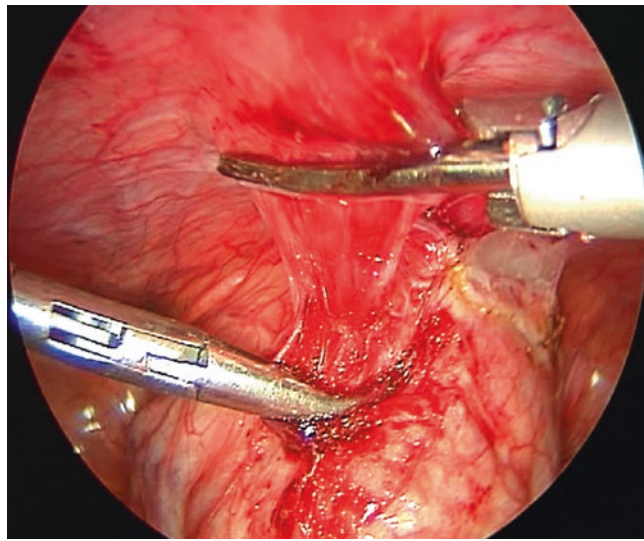


Fig. 34.21 Urachus being divided close to umbilicus

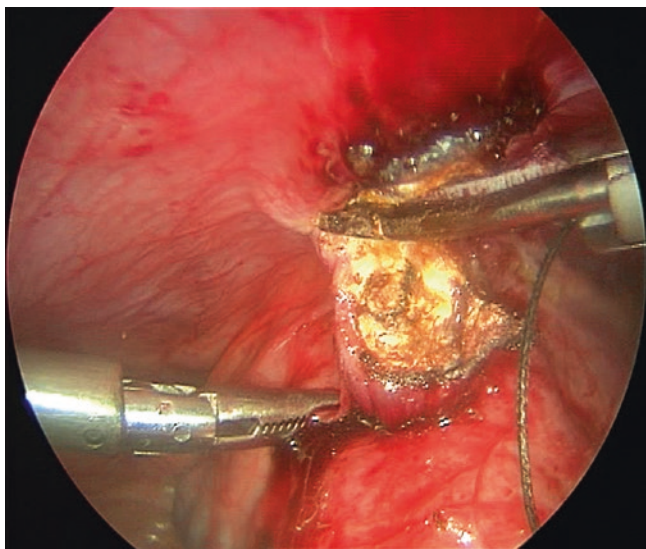


Fig. 34.22 Urachal division almost complete

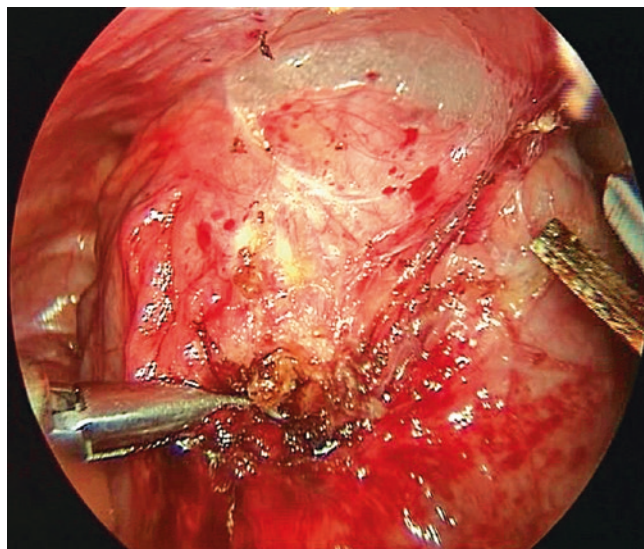


Fig. 34.23 Bladder being dropped down

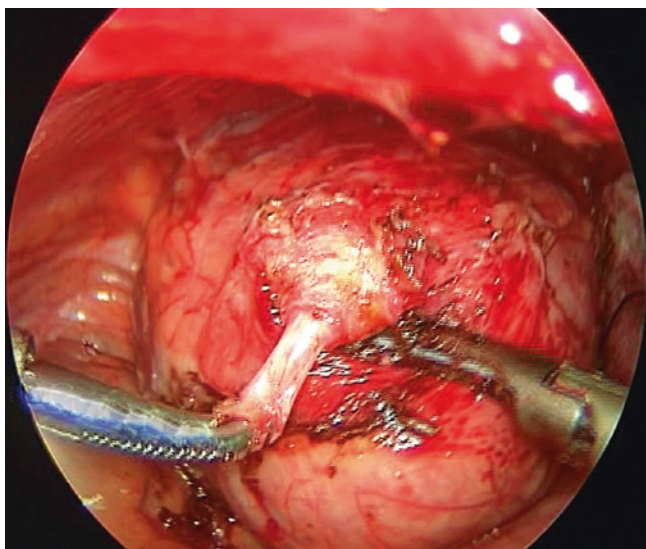


Fig. 34.24 Urachus being dissected from the detrusor

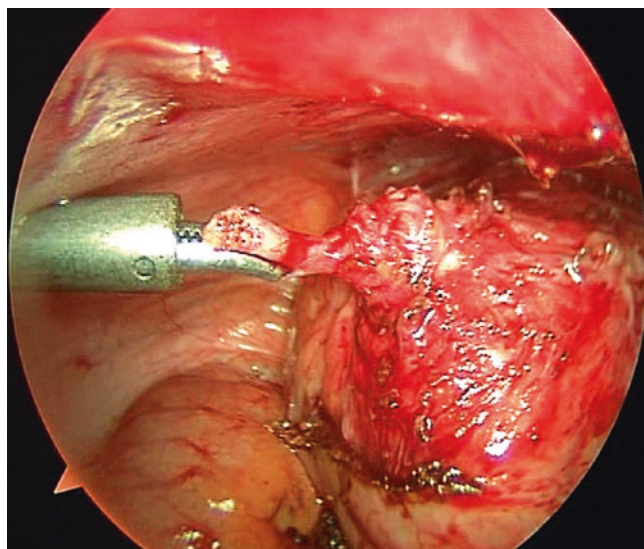


Fig. 34.25 Detrusor dissected all around from the urachus

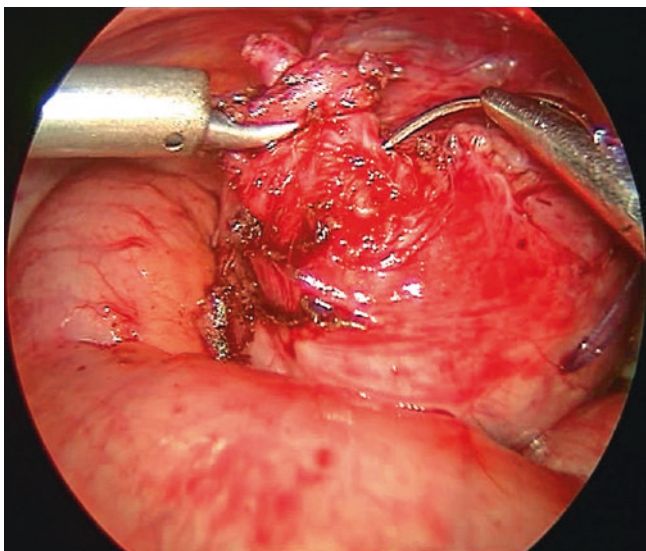


Fig. 34.26 Caudal end of urachus being transfixed

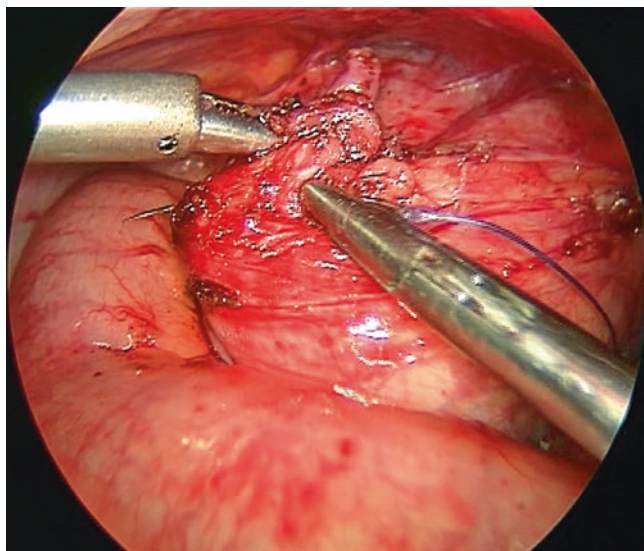


Fig. 34.27 Urachal transfixation in progress

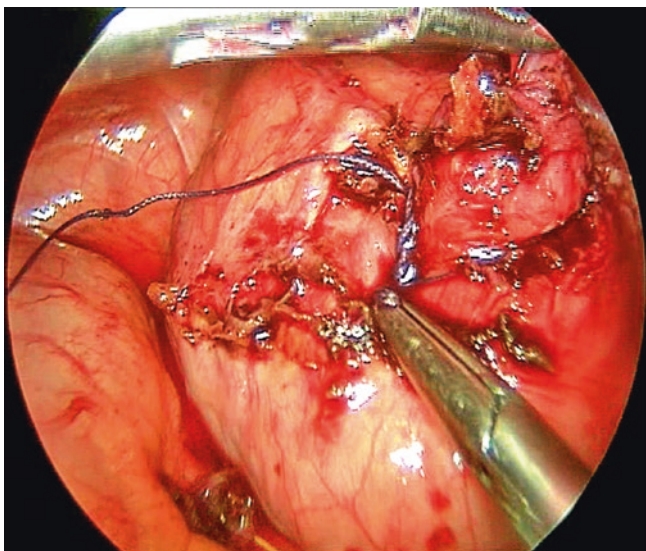


Fig. 34.28 Transfixation suturing in progress

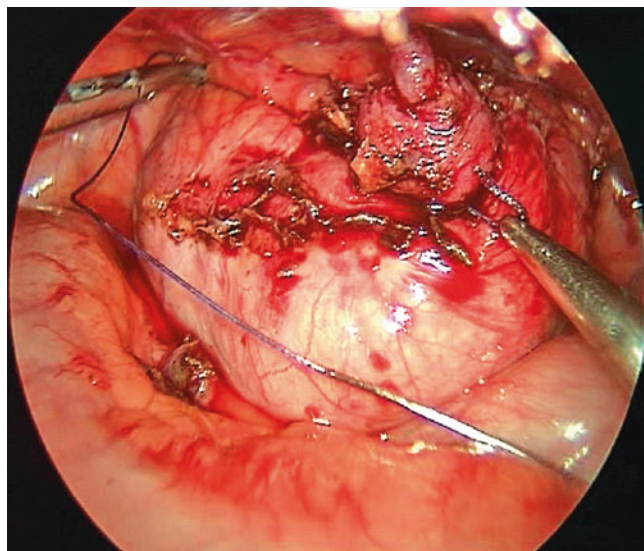


Fig. 34.29 Suturing complete

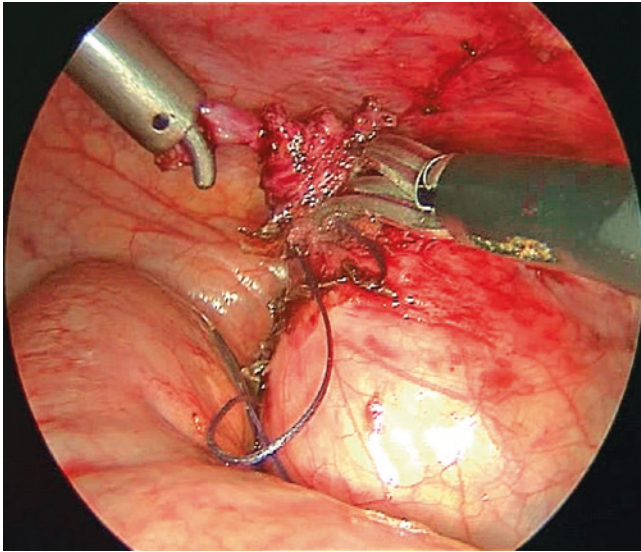


Fig. 34.30 Excess urachal tissue being excised

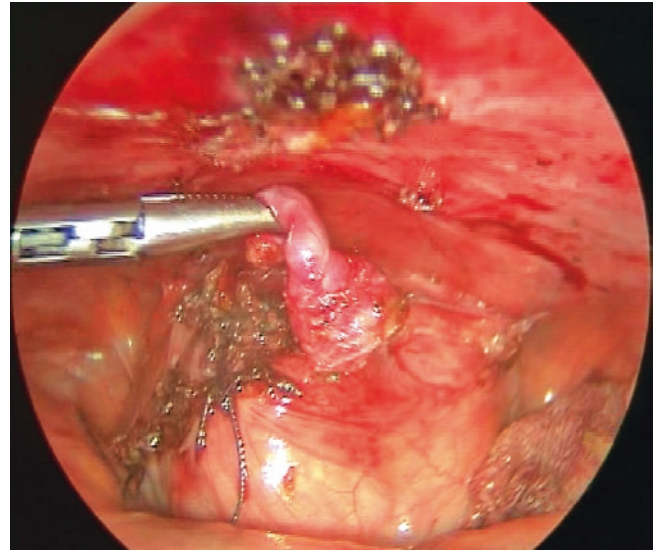


Fig. 34.31 Excised urachal tissue

References

1. Feigel M, Thalmann C. Laparoscopic excision of a urachus umbilical fistula. *Chirurg.* 1996;67(8):856–7.
2. Khurana S, Borzi PA. Laparoscopic management of complicated urachal disease in children. *J Urol.* 2002;168(4 Pt 1):1526–8.

Manickam Ramalingam and K. Selvarajan

35.1 Introduction and Indication

Autoaugmentation is a useful procedure in neurogenic bladders which have poor compliance, detrusor overactivity, reasonable capacity and refractory to medical management [1–4]. Autoaugmentation is an option prior to ileocystoplasty (which involves bowel with its inherent immediate and delayed complications).

35.2 Preliminary Evaluation

MCU, IVU, isotope renal study, cystometry and cystoscopy are done to know the baseline capacity, renal function, compliance and overactivity.

35.3 Surgical Technique

The patient is placed in Trendelenburg's position and using three ports (umbilical port for telescope, two ports in mid-clavicular line 5 cm below and lateral to umbilicus for

hand instruments), peritoneum over the bladder is incised. Subsequently using hook diathermy detrusor is divided. The incision starts vertically from close to the bladder neck and is extended posteriorly up to the trigone level and till mucosa bulges out. Care has to be taken not to use diathermy when dissecting close to the mucosa. It is preferable to raise a rectangular flap of detrusor from the anterior wall on one or either side which can be sutured to the Cooper's ligament to prevent reapproximation of detrusor fibers. Any inadvertent bladder mucosal injury can be sutured using 4-0 vicryl sutures.

There is no need for a drain if mucosa is not breached.

35.4 Comment

Laparoscopic autoaugmentation is an option in lieu of a major procedure like ileocystoplasty particularly in patients with adequate bladder capacity.

M. Ramalingam (✉)
PSG Hospitals,
Coimbatore, India
e-mail: uroram@yahoo.com

K. Selvarajan, MCh
Paediatric Surgery, K.G. Hospital and Postgraduate Institute,
Coimbatore, India

35.5 Laparoscopic Autoaugmentation of Bladder

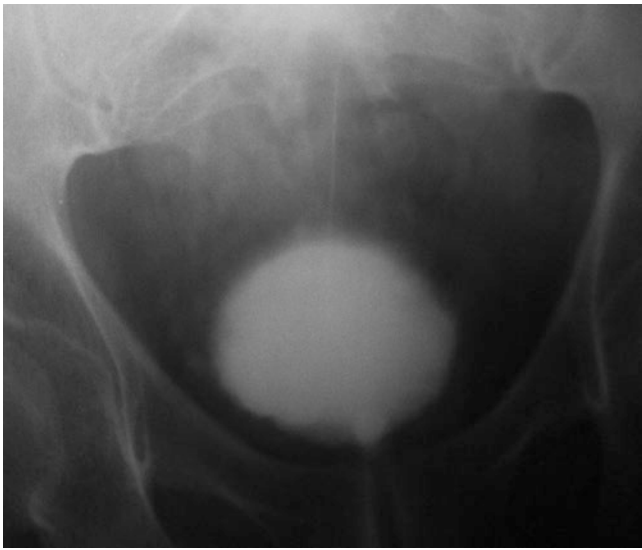

Fig. 35.1 Cystogram of a neurogenic bladder with moderate capacity

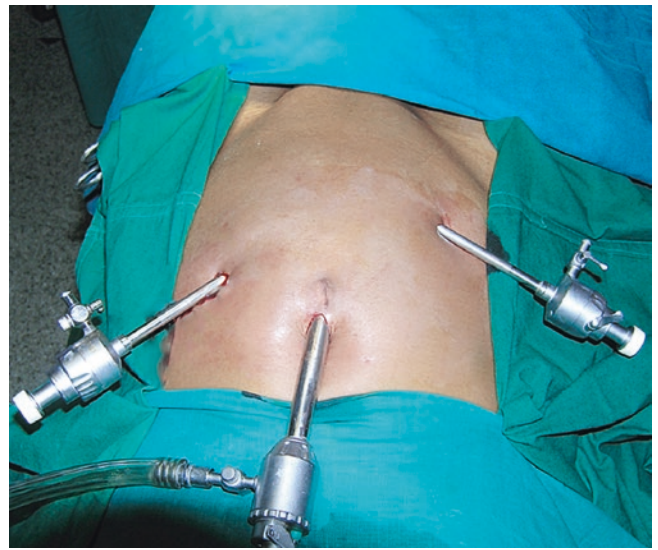

Fig. 35.2 Port position

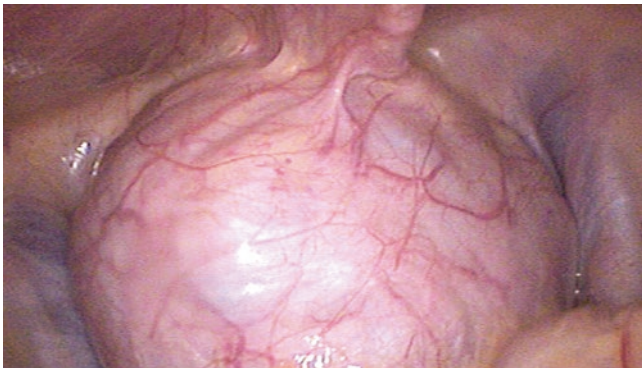

Fig. 35.3 Initial view of distended bladder

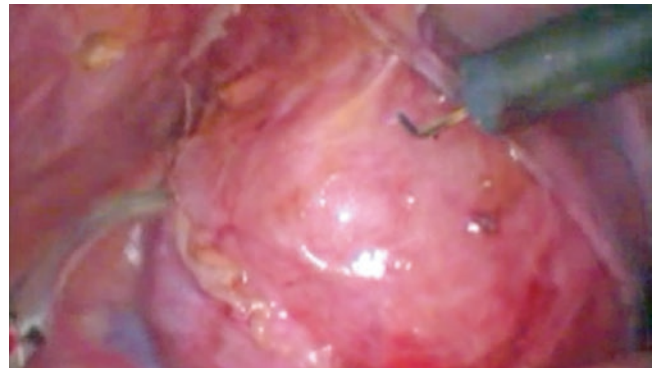


Fig. 35.4 Peritoneum incised vertically

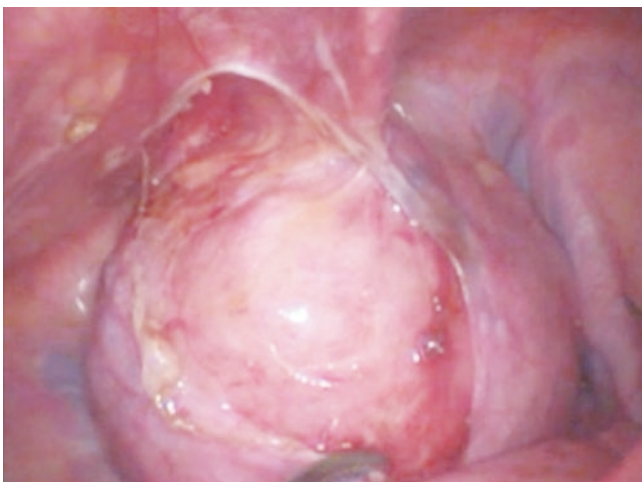


Fig. 35.5 Peritoneum separated from dome of the bladder

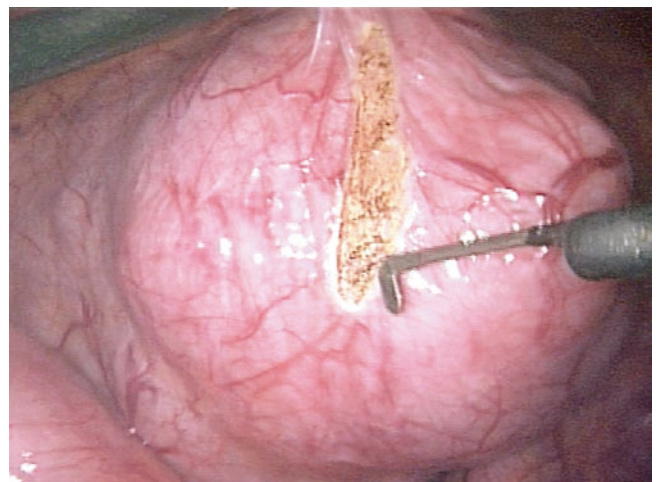


Fig. 35.6 Detrusor myotomy with L hook diathermy started

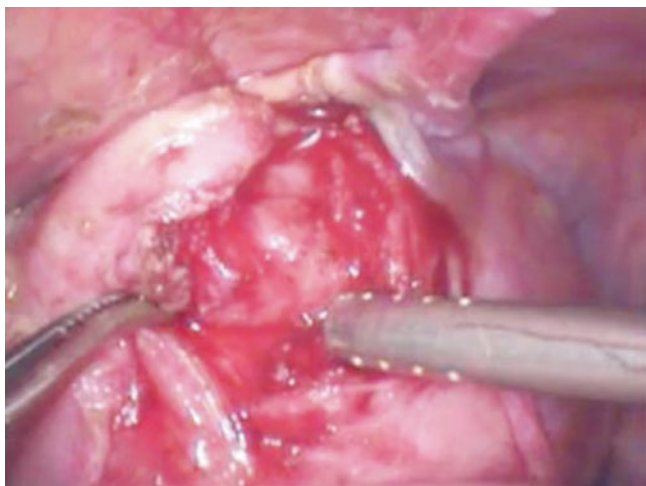

Fig. 35.7 Vertical detrusor myotomy deepened till bulging mucosa is seen

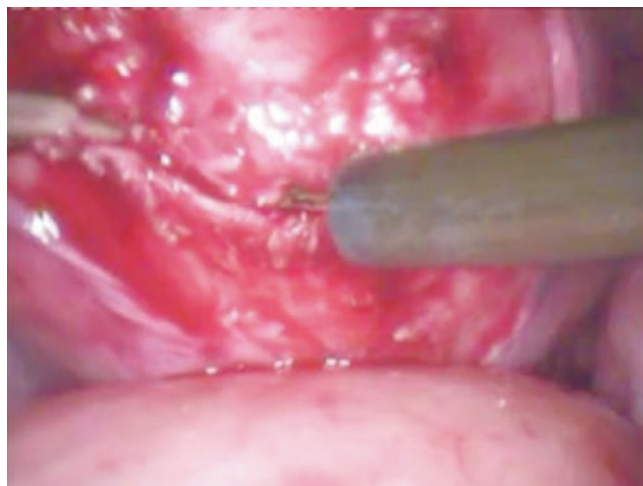

Fig. 35.8 Detrusor myotomy extended posteriorly along the same sub-mucosal plane

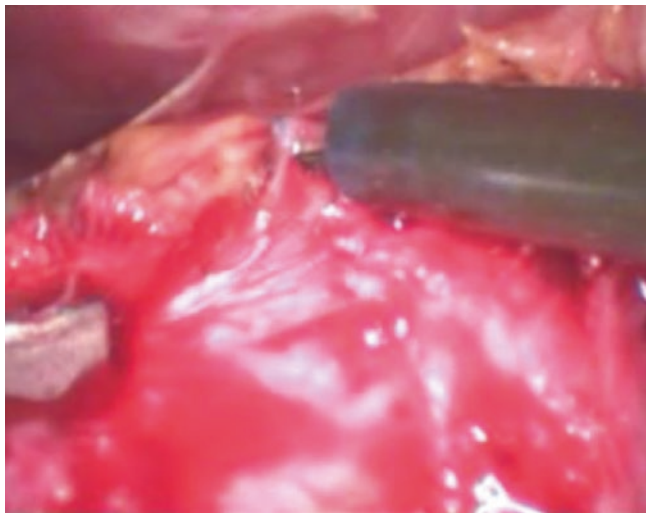


Fig. 35.9 Detrusor myotomy extended anteriorly

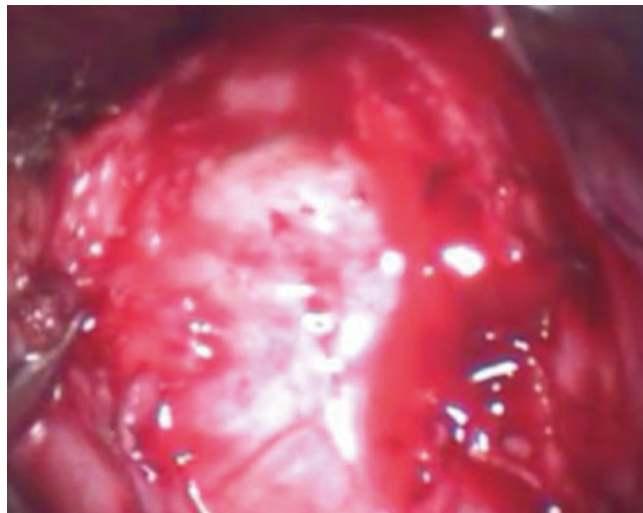


Fig. 35.10 Bulging mucosa seen confirming adequate detrusor myotomy and auto augmentation

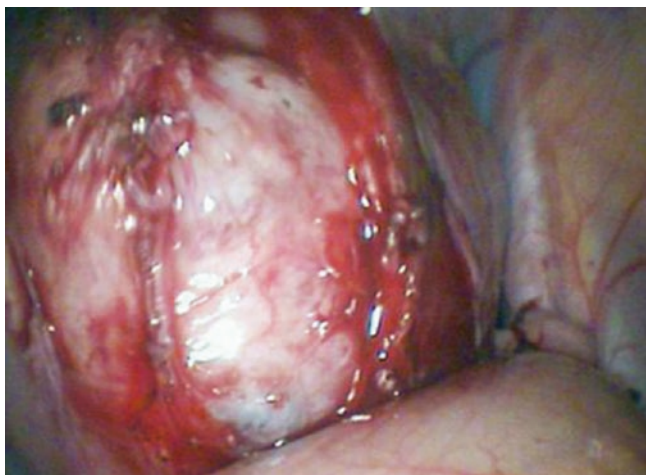

Fig. 35.11 Completed auto augmentation

References

1. Braren V, Bishop MR. Laparoscopic bladder auto augmentation in children. *Urol Clin North Am.* 1998;25:533–40.
2. Britanishy RG, Poppas DP, Shichman SN, et al. Laparoscopic laser-assisted bladder autoaugmentation. *Urology.* 1995;46:315.
3. Docimo SG, Moore RG, Adam J, Kavoussi LR. Laparoscopic bladder augmentation using stomach. *Urology.* 1995;46:565–9.
4. Snow BW, Cartwright PC. Bladder auto augmentation. *Urol Clin North Am.* 1996;23:323–31.

Manickam Ramalingam, Kallappan Senthil,
and Anandan Murugesan

36.1 Total Laparoscopic Ileocystoplasty

36.1.1 Introduction and Indications

Hyperreflexic, poorly compliant neurogenic bladders with reduced capacity are a threat to the upper tract. Augmentation with bowel (preferably ileum) is an option in these patients. Laparoscopic approach for ileocystoplasty has been described and the morbidity is quite less compared with open approach. Preliminary MCU, IVU, cystometry, cystoscopy and urine culture are essential. Good bowel preparation is mandatory [1–4].

36.1.2 Surgical Technique

36.1.2.1 Total Laparoscopic Ileocystoplasty

With the patient in supine position, using supraumbilical telescope port and two pararectus hand instrument ports, bladder and the bowel segment to be selected, are inspected. A 12 mm flank port is placed to accommodate an EndoGIA stapler. A fifth port from the opposite flank may be needed for suction and irrigation or retraction.

About 10–15 cm of ileal segment (atleast 10 cm away from ileocaecal junction) is isolated using EndoGIA stapler. The mesenteric vessels is dealt with EndoGIA stapler or with ultracision. The bowel continuity is restored with Endo GIA stapler. Bladder is divided horizontally using electrocautery or ultracision. The isolated ileal segment is detubularised and brought in alignment with the cystotomy wound taking care not to twist the mesentery. The posterior layer is sutured with continuous or interrupted 2-0 vicryl or barbed suture. An extraperitoneal trocar SPC is preferable. Subsequently the anterior layer is also closed in the same way. Whenever possible omental tacking is done. A tube drain is introduced through the flank port.

36.1.3 Comment

Laparoscopic ileocystoplasty is feasible but needs intracorporeal suturing skill to reduce operative time. Laparoscopically assisted ileocystoplasty is a good hybrid technique with advantages of being minimally invasive and time saving [5].

M. Ramalingam (✉)
PSG Hospitals,
Coimbatore, India
e-mail: uroram@yahoo.com

K. Senthil, MCh (Urol., FRCS)
Urology Clinic, Gowtham annexe, Coimbatore, India
e-mail: senthilsatya@hotmail.com

A. Murugesan, MBBS, MS, MCh
Department of Urology, PSG Institute of Medical Sciences
and Research, Peelamedu, Coimbatore, Tamil Nadu, India
e-mail: anandan79@gmail.com

36.2 Total Intracorporeal Ileocystoplasty

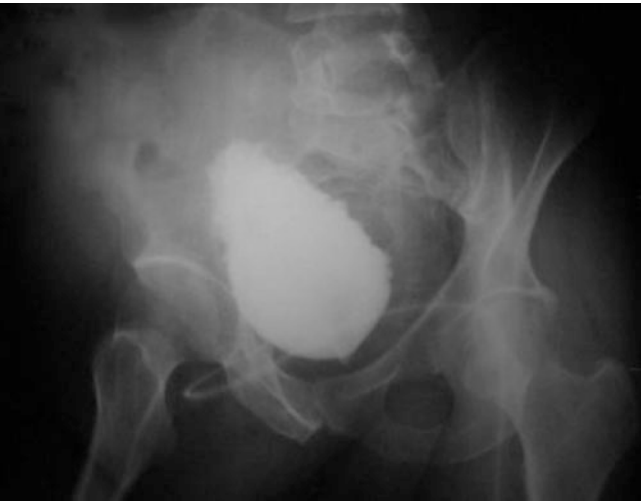

Fig. 36.1 Cystogram showing small capacity bladder in a Meningomyelocele patient

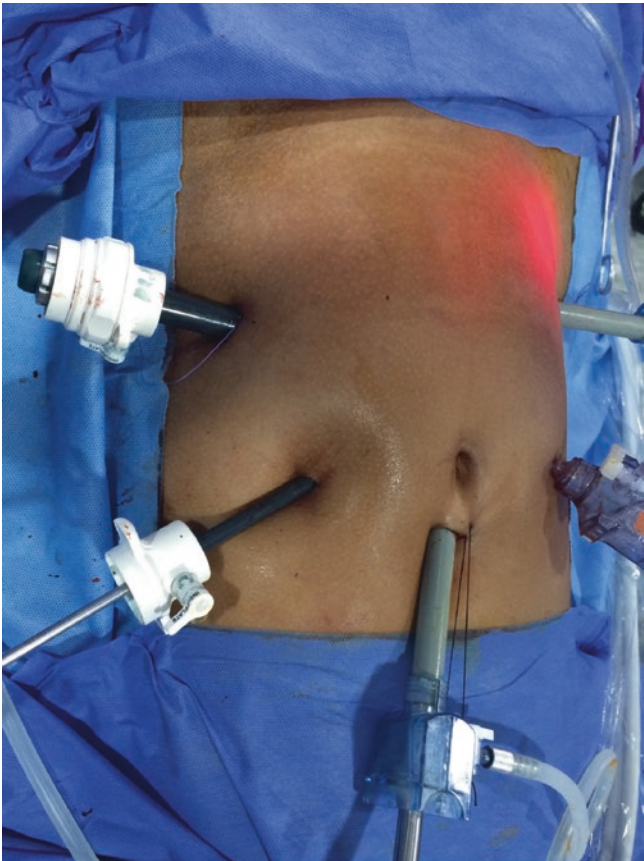

Fig. 36.3 Ports position

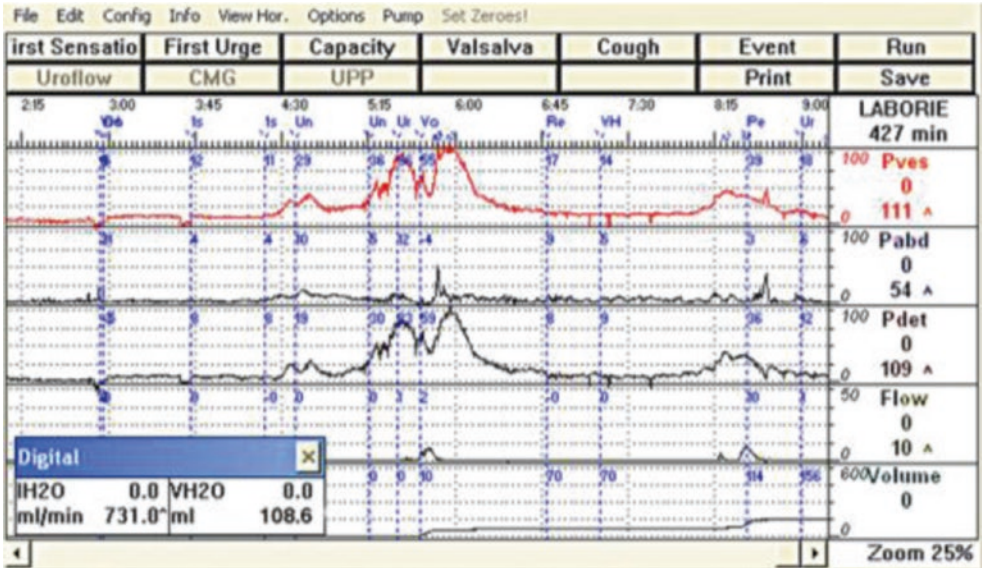


Fig. 36.2 Cystometry showing grossly unstable bladder

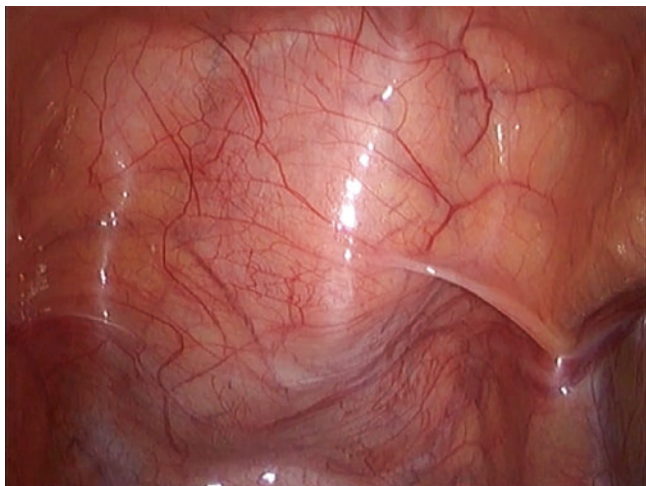


Fig. 36.4 Initial view of bladder

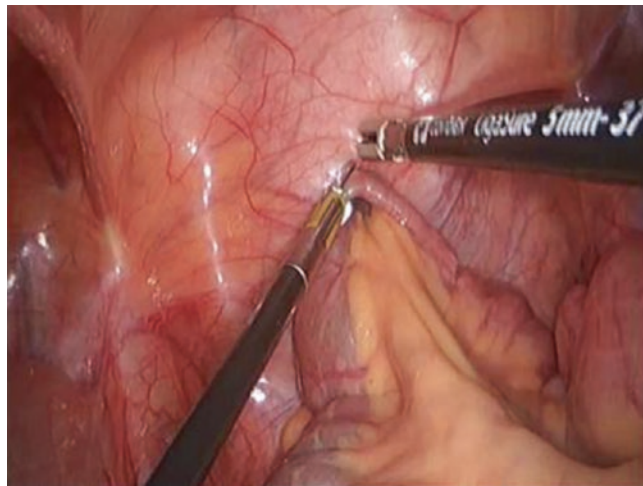


Fig. 36.5 Ileal loop freely moving into the pelvis is selected for bowel segment isolation

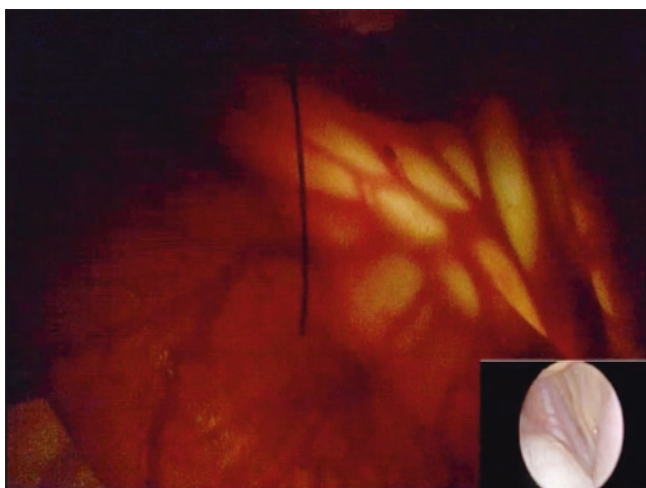


Fig. 36.6 Vascular arcade visualised using another telescope (through LIF port)

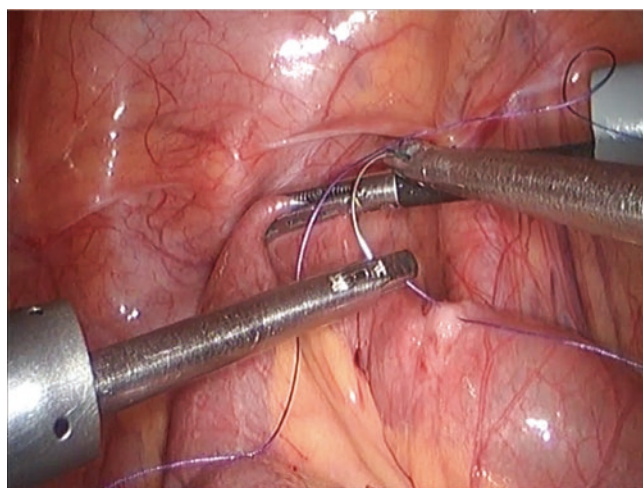


Fig. 36.7 Margins of bowel segment to be isolated are marked with vicryl sutures

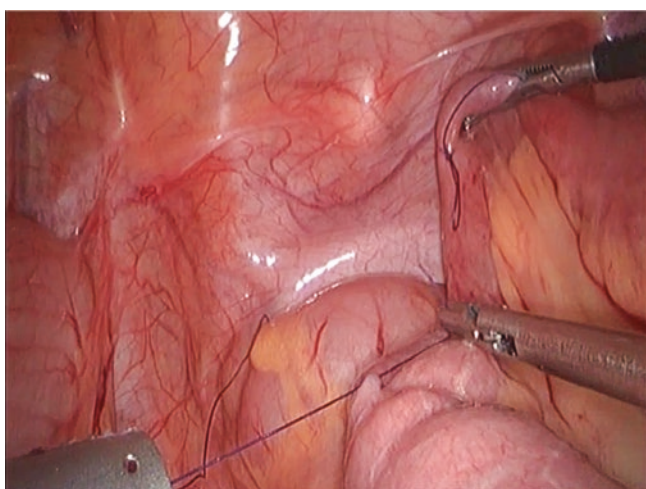


Fig. 36.8 Proximal margin is also marked

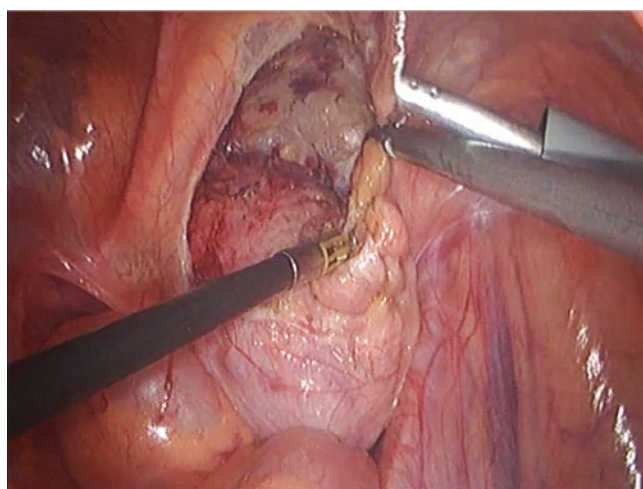


Fig. 36.9 Bladder being mobilised for cystotomy

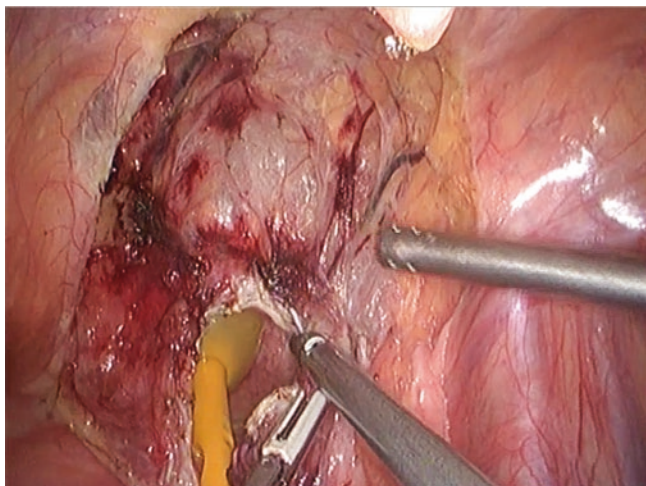


Fig. 36.10 Cystotomy done in inverted U shape from anterior wall of bladder

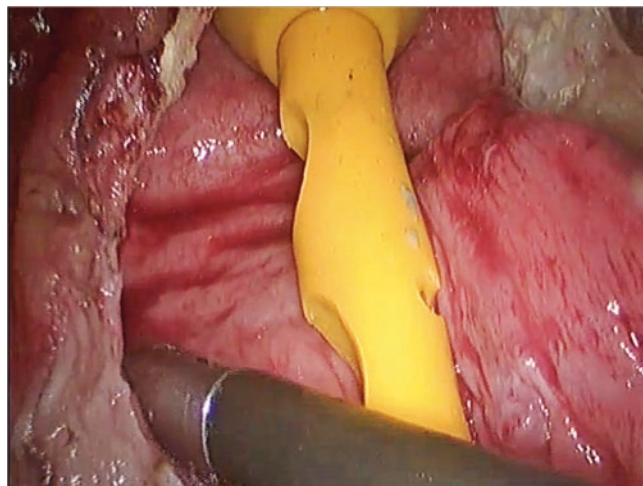


Fig. 36.11 Trigone and ureteric orifices seen through cystotomy

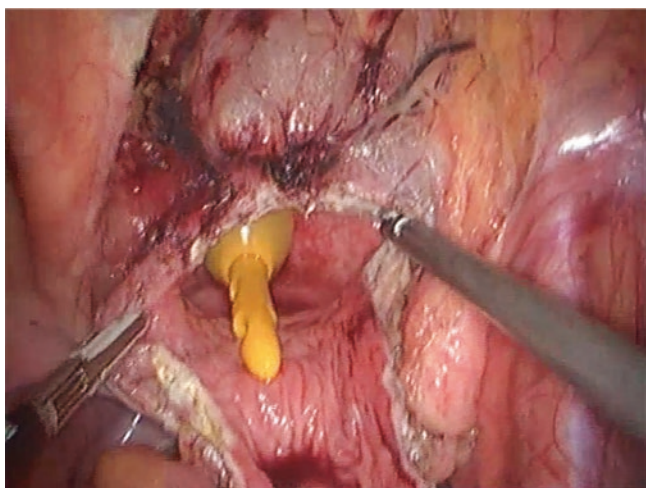


Fig. 36.12 Cystotomy completed safeguarding ureteric Orifices

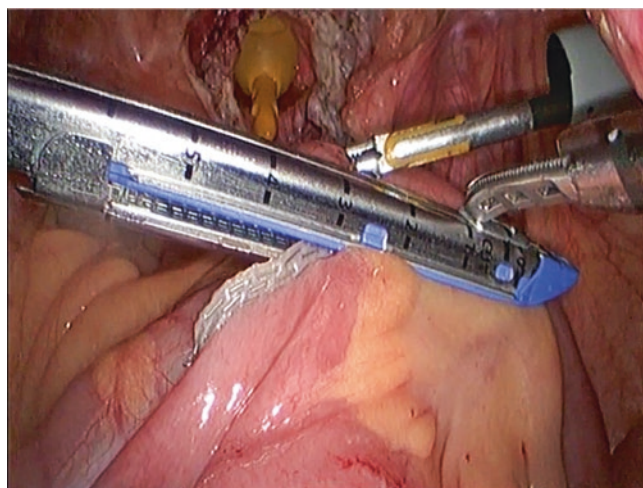


Fig. 36.13 Proximal margin division using stapler

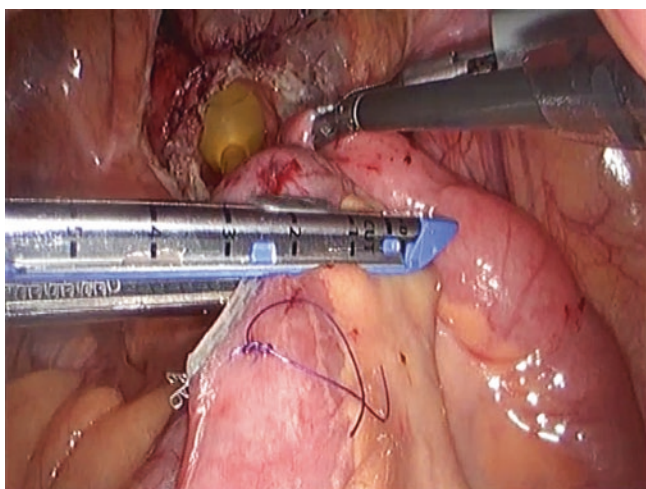


Fig. 36.14 Distal margin division using stapler

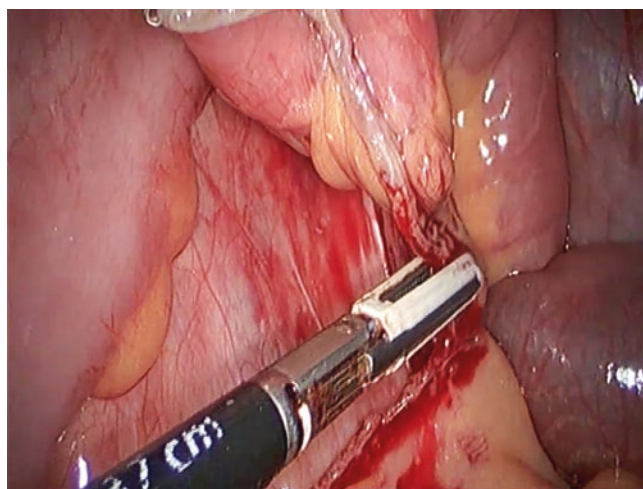


Fig. 36.15 Mesenteric bleeders if any, handled with vessel sealer

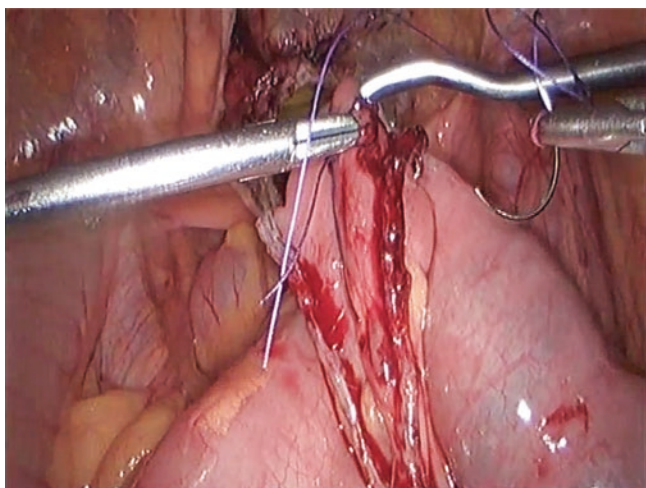


Fig. 36.16 Proximal and distal ileal divided segments tacked together to facilitate bowel anastomosis

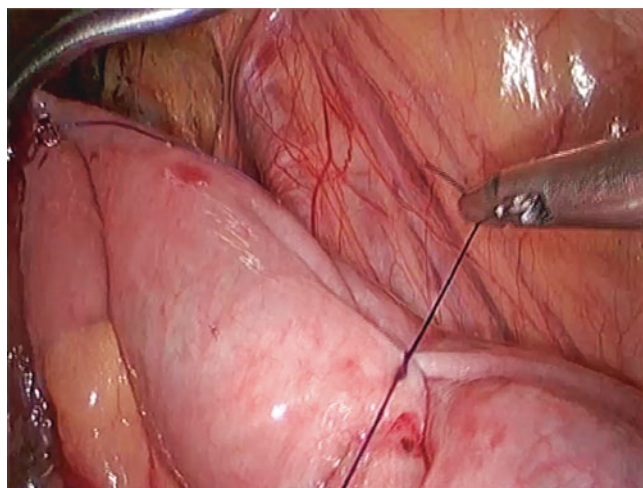


Fig. 36.17 Ileal segments aligned for about 10 cm to facilitate anastomosis

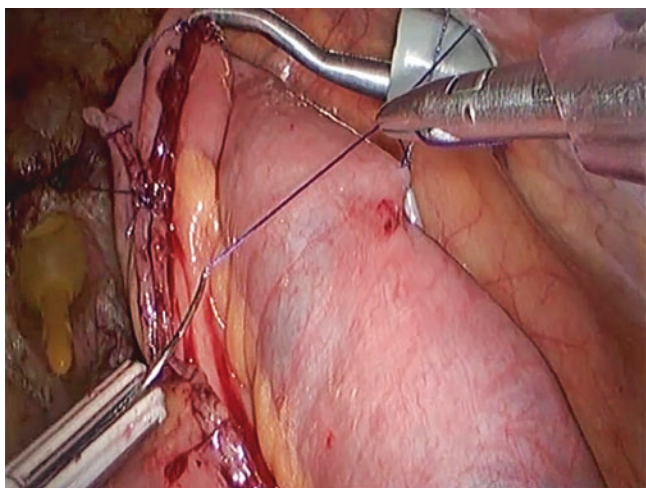


Fig. 36.18 Bowel segment tacked to abdominal wall to stabilise the bowel

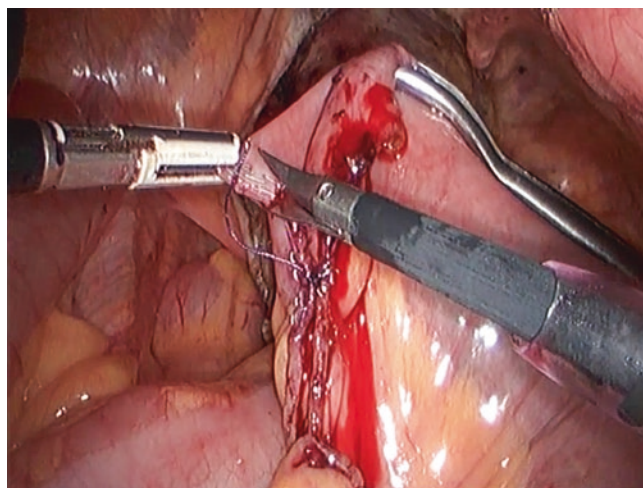


Fig. 36.19 Part of staple line excised for insertion of stapler

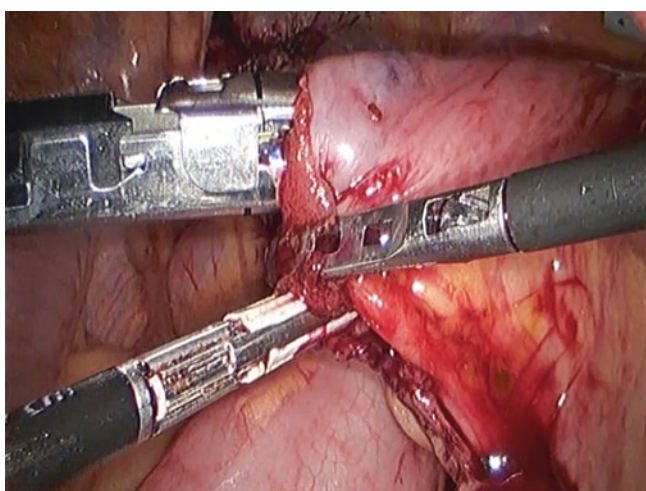


Fig. 36.20 Stapler inserted and fired – anastomosis completed

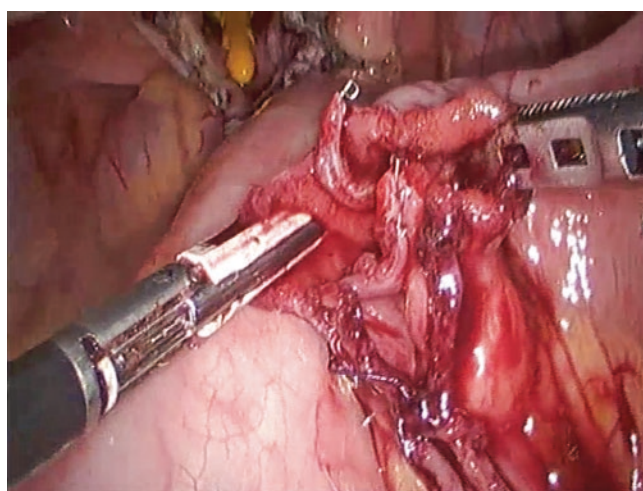


Fig. 36.21 View of anastomosis staple line

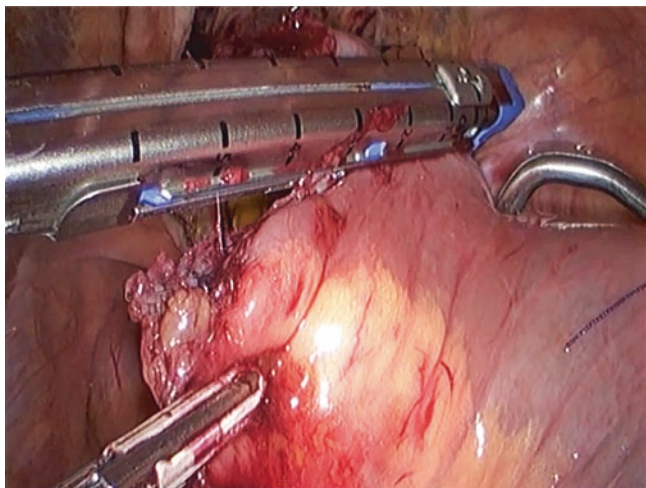


Fig. 36.22 Defect created for stapler insertion closed

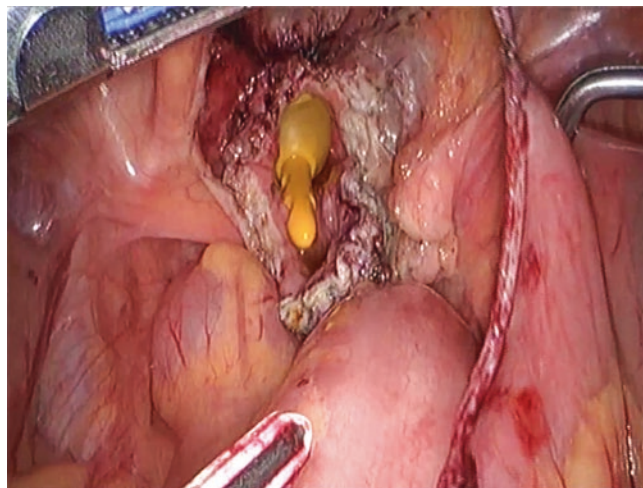


Fig. 36.23 Anastomosis completed (ileal continuity restored)

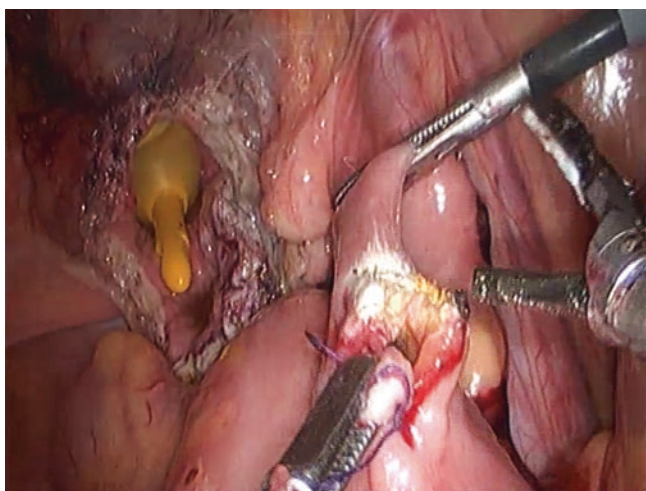


Fig. 36.24 Harvested bowel segment being detubularised

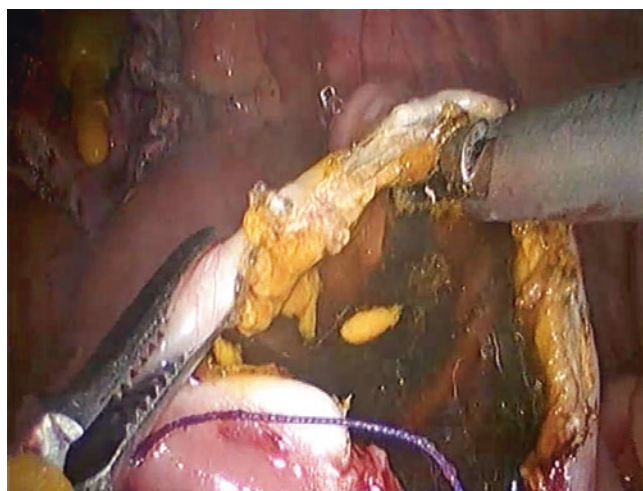

Fig. 36.25 Detubularisation in progress

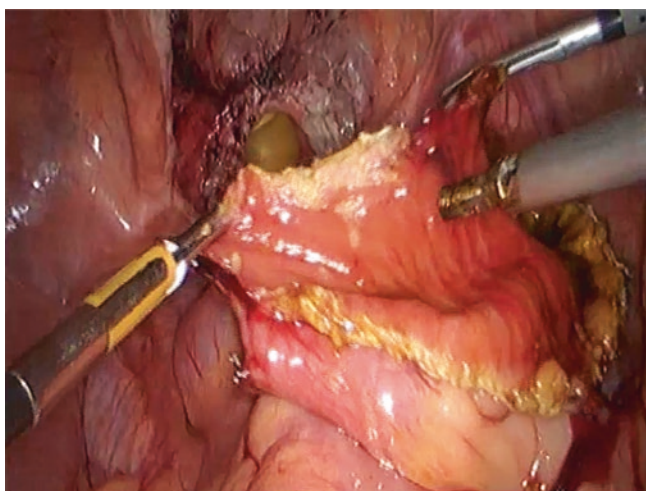


Fig. 36.26 Detrubularisation completed

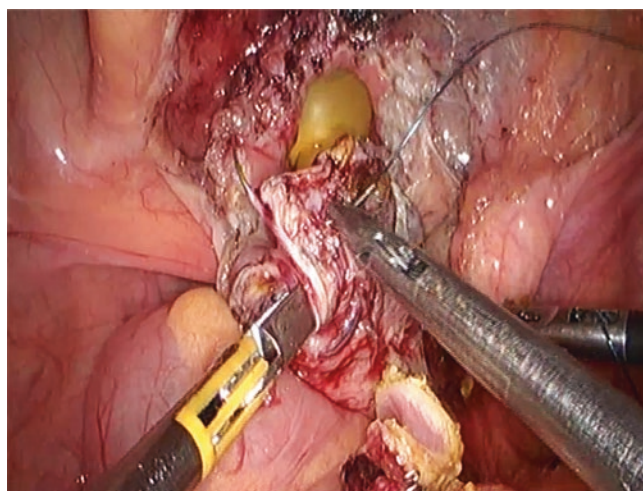


Fig. 36.27 Anastomosis started from the middle of posterior wall with 3-0 v loc (barbed)suture

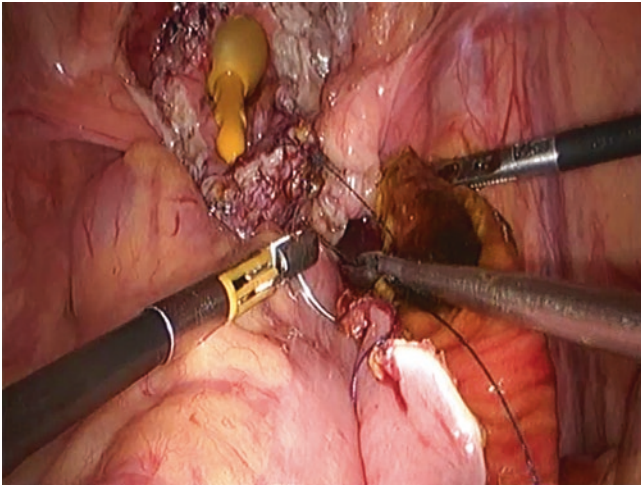


Fig. 36.28 Corresponding suture through detubularised ileum

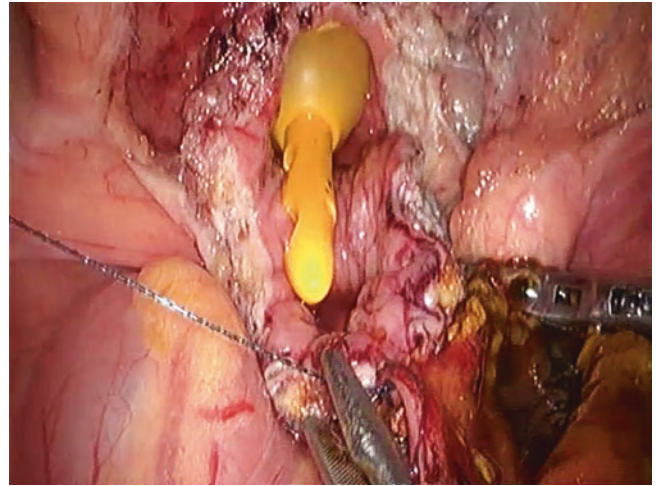


Fig. 36.29 First suture in place

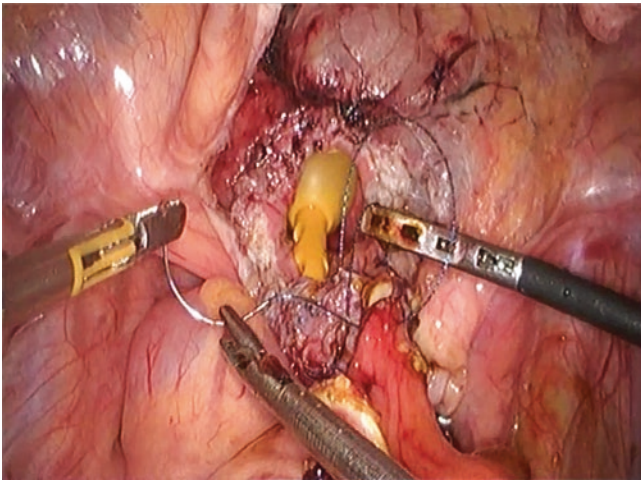


Fig. 36.30 Anastomosis as continuous suture in progress towards left side

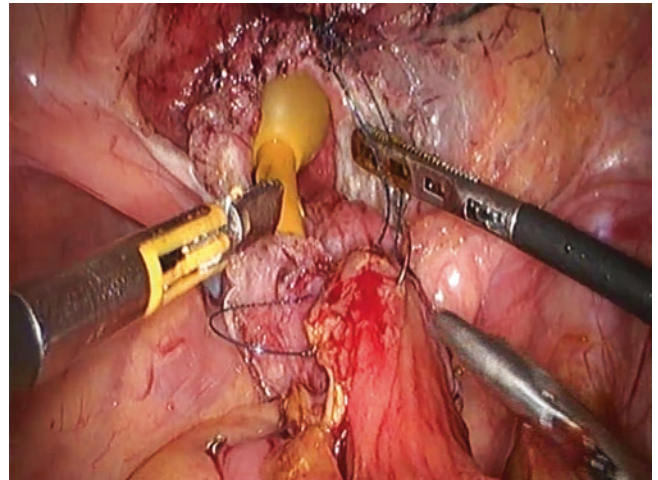


Fig. 36.31 Anastomosis in progress

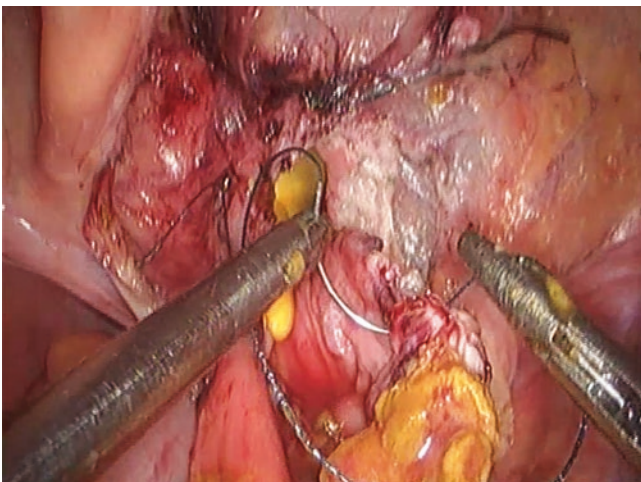


Fig. 36.32 Continuous suture on the right side

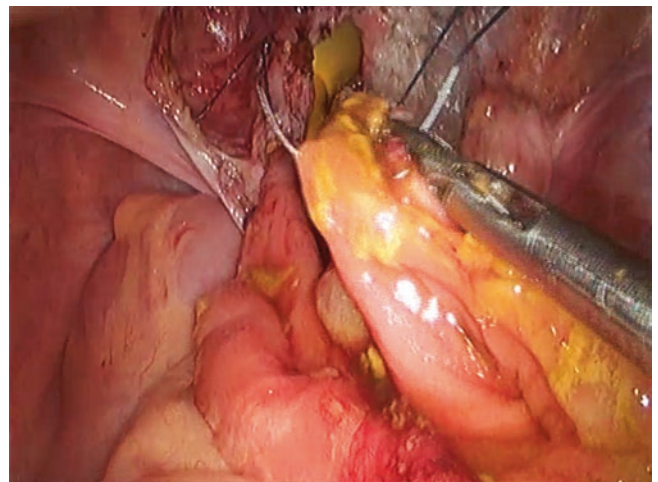


Fig. 36.33 Anastomosis in progress

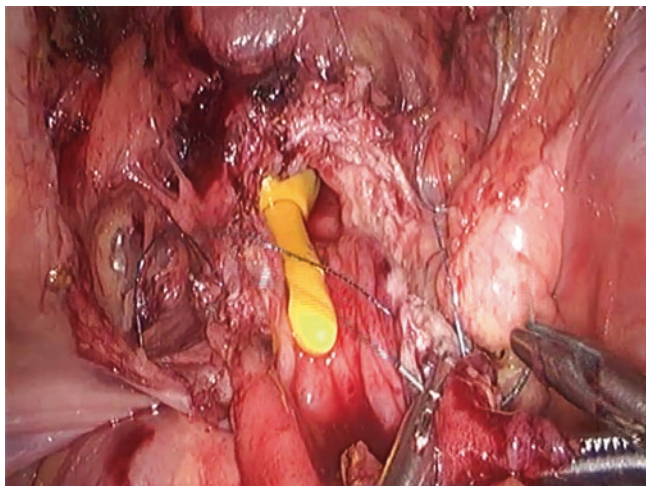


Fig. 36.34 Anastomosis in progress

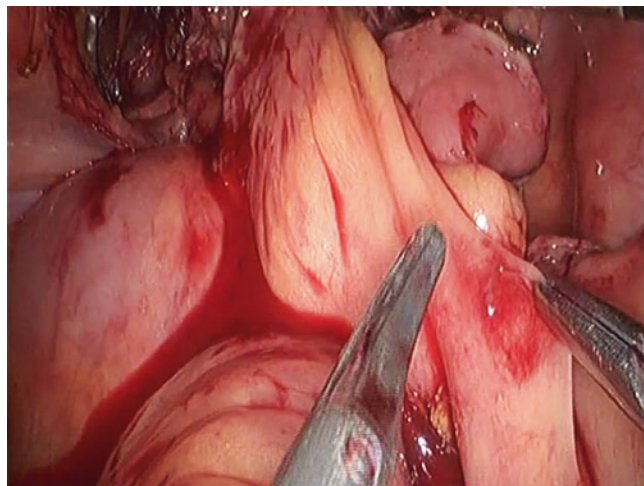


Fig. 36.35 Relaxing incision in the leaflet of mesentery

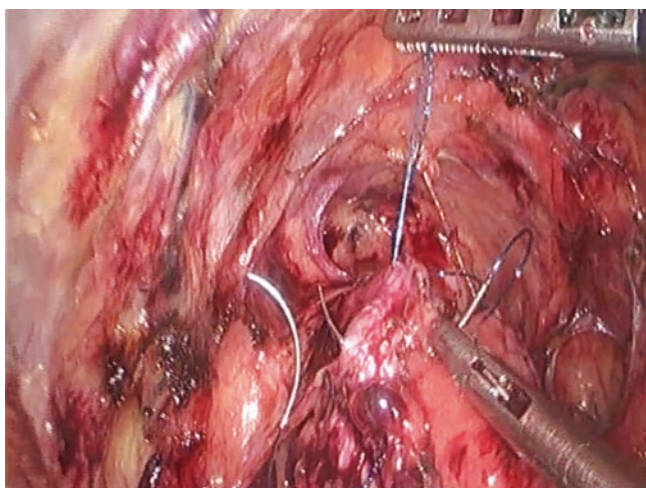


Fig. 36.36 Anterior layer suturing started at 12-o'clock position

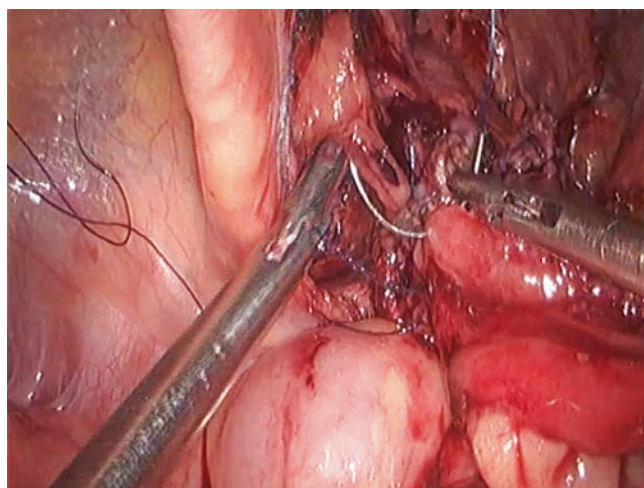


Fig. 36.37 Redundant ileal edges anastomosed together

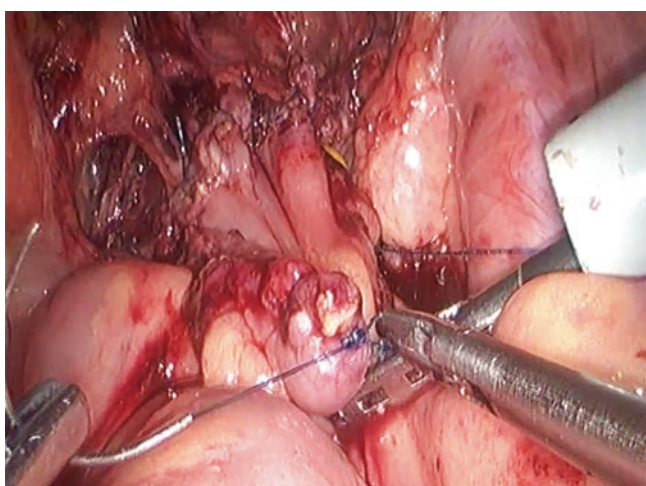


Fig. 36.38 Anastomosis almost complete

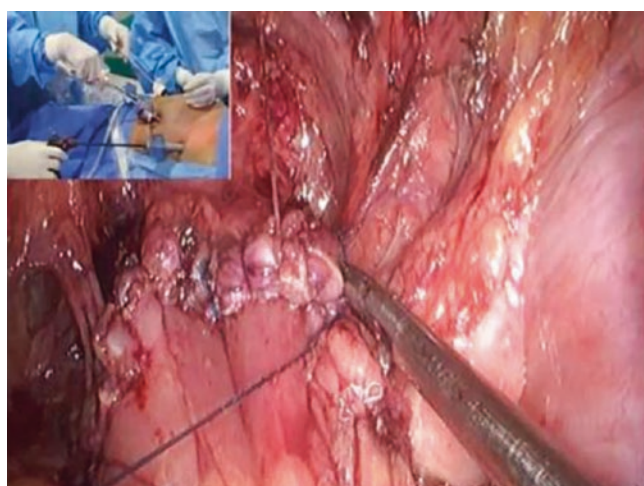


Fig. 36.39 Completed ileo vesical anastomosis

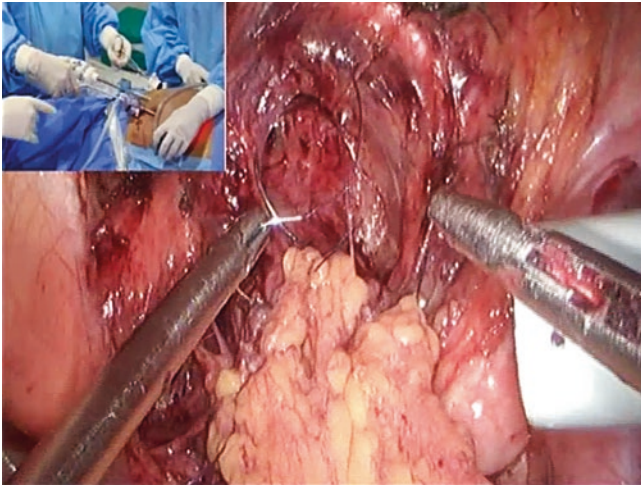


Fig. 36.40 Omental tacking over suture line

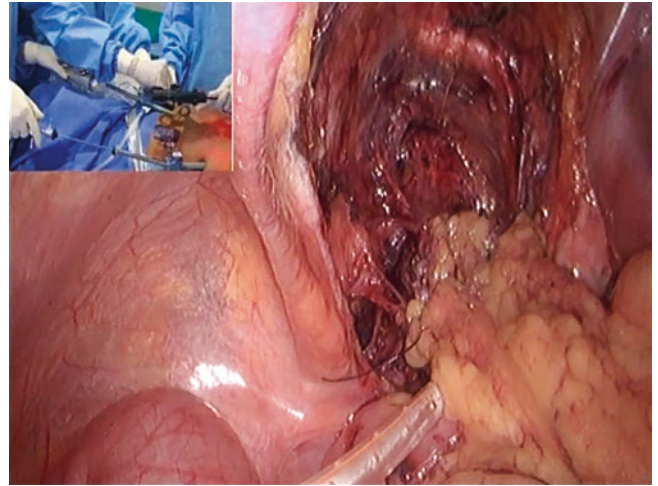


Fig. 36.41 Drain placed

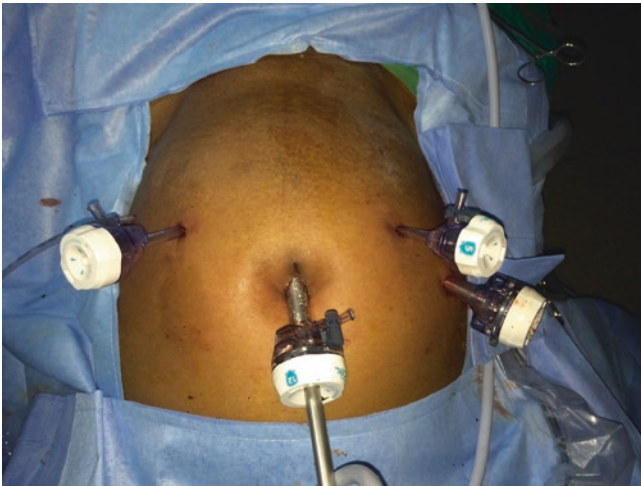

Fig. 36.42 Drain placed through left flank port

References

1. Gill IS, Rackley RR, Meraney AM, Marcello PW, Gyung TS. Laparoscopic enterocystoplasty. *Urology*. 2000;55:178.
2. Iliott SP, Meng MV, Anwar HP, Stoller ML. Complete laparoscopic ileal cystoplasty. *Urology*. 2002;59:939.
3. Ramalingam M, Senthil K, Selvarajan K, Pai MG. Laparoscopic ileocystoplasty – our experience in 3 patients (abstract). *J Endo*. 2006;20(1):A277.
4. Meng M, Anwar HP, Iliott, Stoller ML. Pure laparoscopic enterocystoplasty. *J Urol*. 2002;167:1386.
5. Ramalingam M, Senthil K, Pai MG. Modified technique of laparoscopy-assisted surgeries (transportal). *J Endourol*. 2008; 22(12):2681–5. 1089/end.2008.0209.

Manickam Ramalingam, Kallappan Senthil,
and Anandan Murugesan

37.1 Introduction

Laparoscopy assisted ileocystoplasty is a hybrid of open and laparoscopic approach. It gives the benefit of both minimally invasive approach (small incision) and open approach (less time consuming). Patient satisfaction is also better than open approach. [1–5].

37.2 Surgical Technique

With the patient in supine position, using supraumbilical telescope port and two pararectus hand instrument ports, bladder and the bowel segment to be selected, are inspected.

The supraumbilical port can be extended to about 3 cm to bring out the distal ileum for isolation and for restoring ileoileal continuity. Subsequently the bowel segment is pushed back into the peritoneal cavity and rectus incision is closed tightly around the camera port. Rest of augmentation is done with free hand suturing intracorporeally.

37.3 Comment

Laparoscopic ileocystoplasty needs intracorporeal suturing skill to reduce operative time. Laparoscopically assisted ileocystoplasty is a good hybrid technique with advantages of being minimally invasive and time saving.

M. Ramalingam (✉)
PSG Hospitals,
Coimbatore, India
e-mail: uroram@yahoo.com

K. Senthil, MCh (Urol., FRCS)
Urology Clinic, Gowtham annexe, Coimbatore, India
e-mail: senthilsatya@hotmail.com

A. Murugesan, MBBS, MS, MCh
Department of Urology, PSG Institute of Medical Sciences
and Research, Peelamedu, Coimbatore, Tamil Nadu, India
e-mail: anandan79@gmail.com

37.4 Laparoscopy Assisted Ileocystoplasty

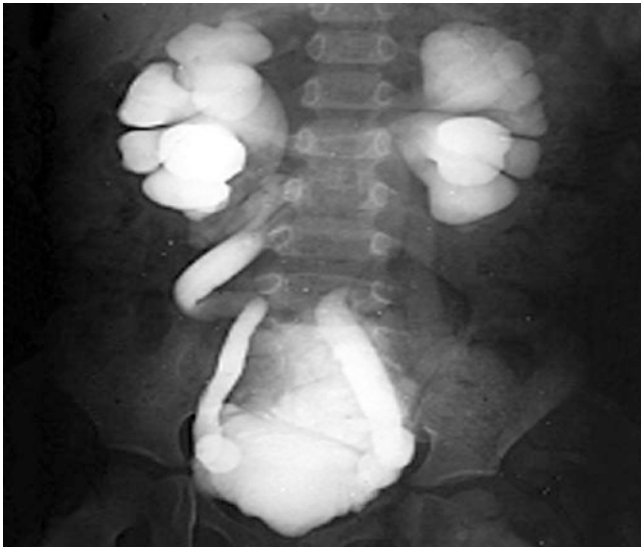

Fig. 37.1 MCU showing a grossly trabeculated bladder with bilateral reflux in a patient with neurogenic bladder

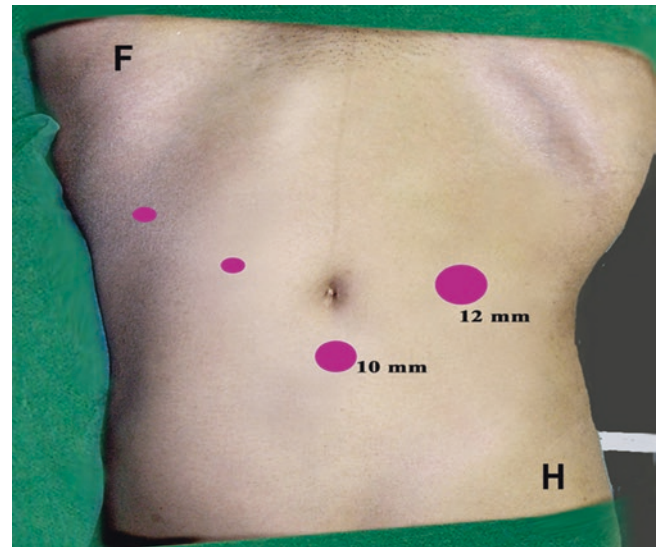


Fig. 37.2 Ports position

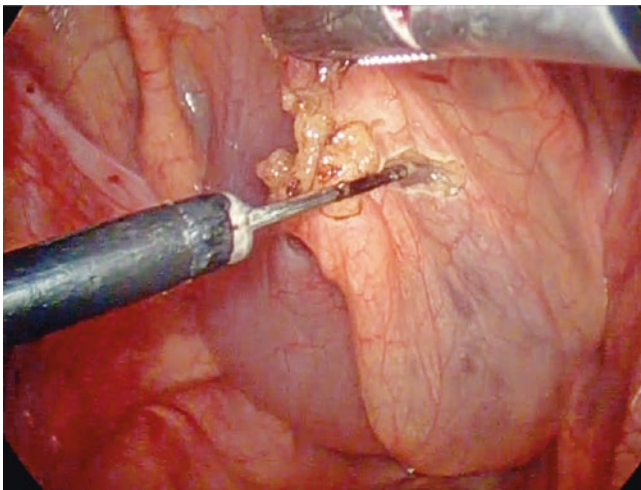


Fig. 37.3 Bladder mobilised partly

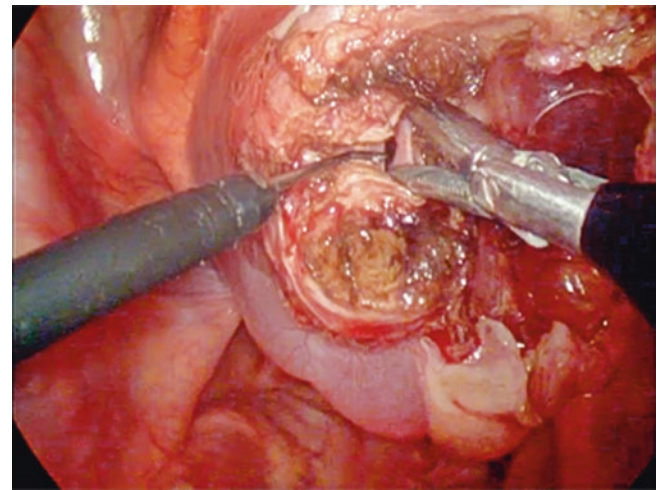


Fig. 37.4 Transverse cystotomy being done

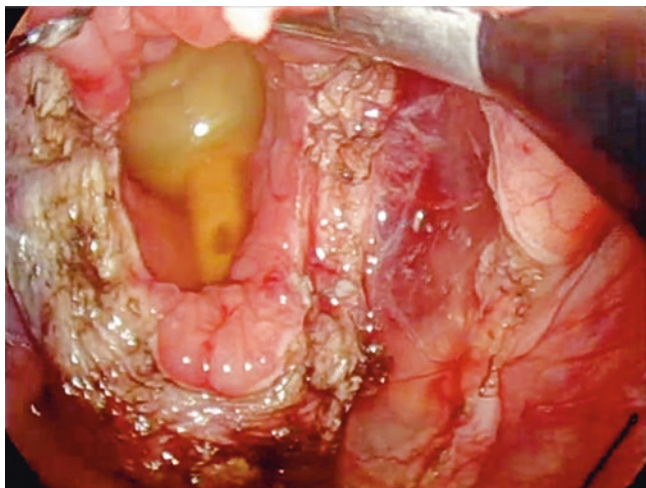


Fig. 37.5 Cystotomy complete. Note the thick walled bladder

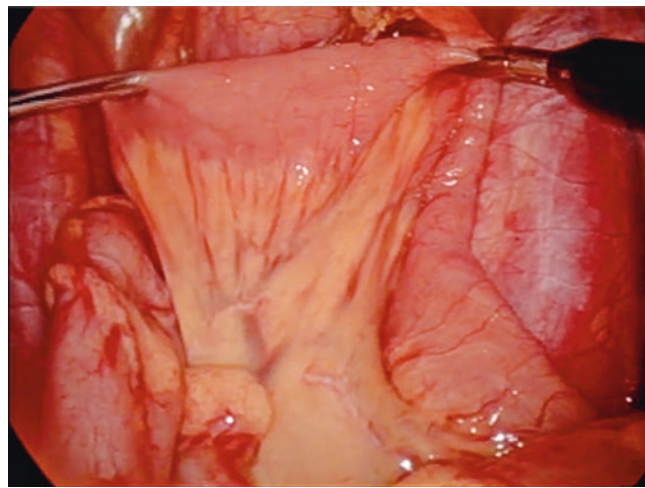


Fig. 37.6 Ileal loop being selected

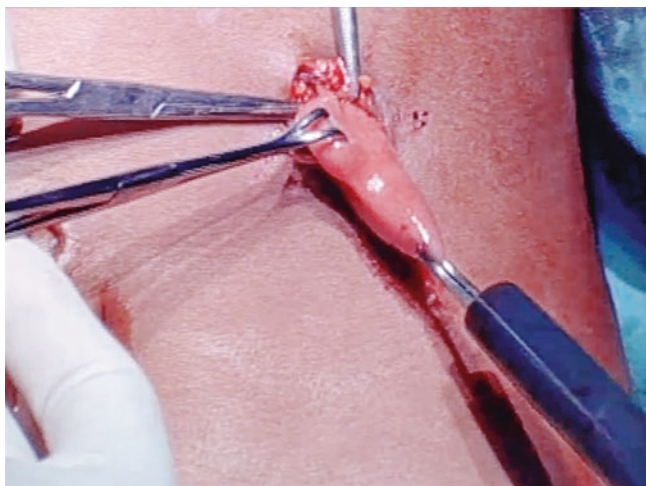


Fig. 37.7 Bowel loop brought out through 12 mm port site (or port site can be extended to exteriorise the ileum)

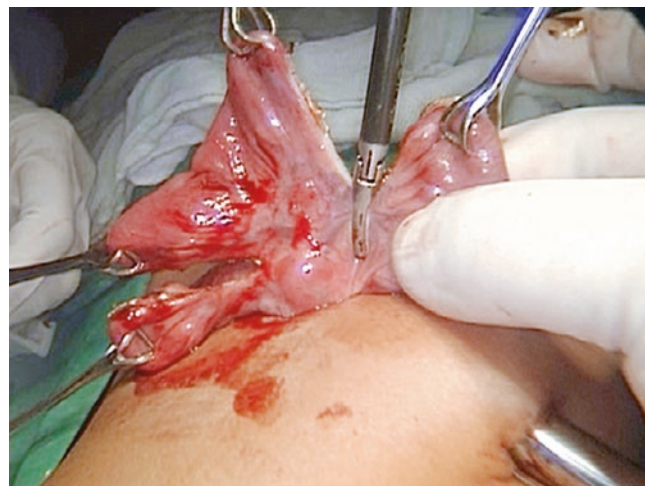

Fig. 37.8 Division of the ileum along with its mesentery with ultrasonic shear to prepare an ileal patch for augmentation of the bladder

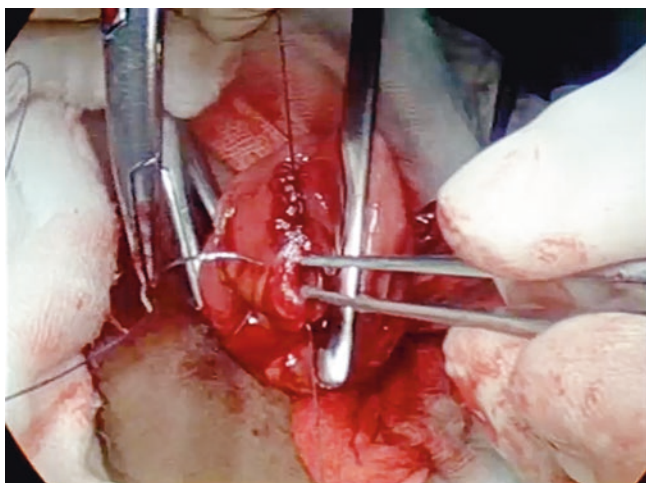


Fig. 37.9 Extracorporeal bowel isolation

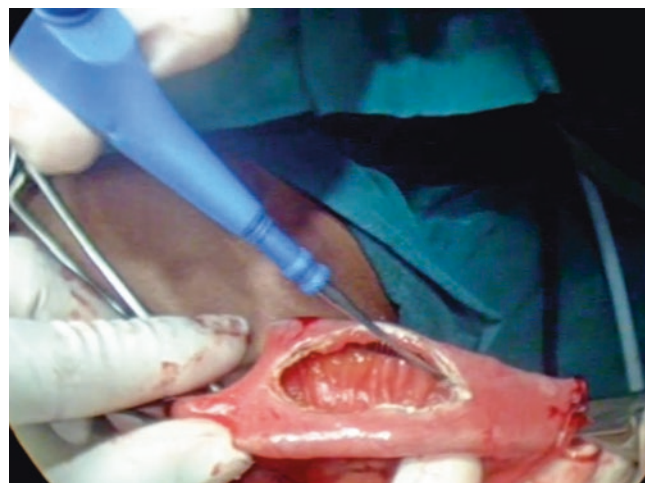

Fig. 37.10 Detubularisation of bowel

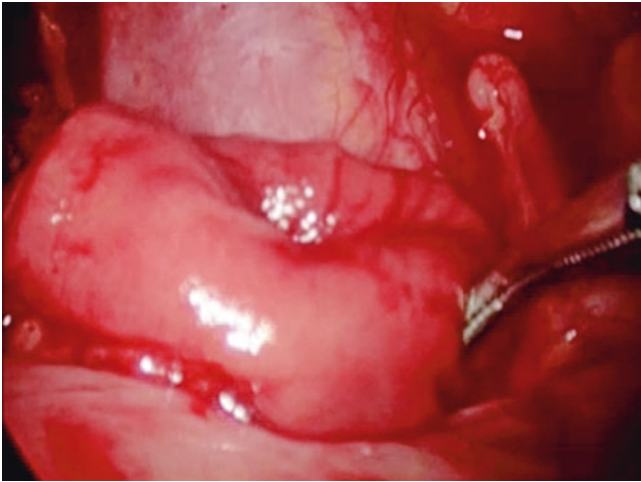


Fig. 37.11 Detubularised bowel intraperitonealised

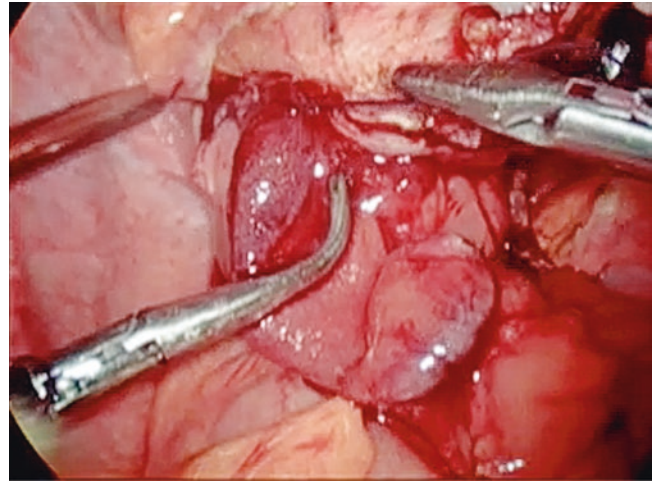


Fig. 37.12 Ileo vesical anastomosis of posterior layer started with 3-0 vicryl

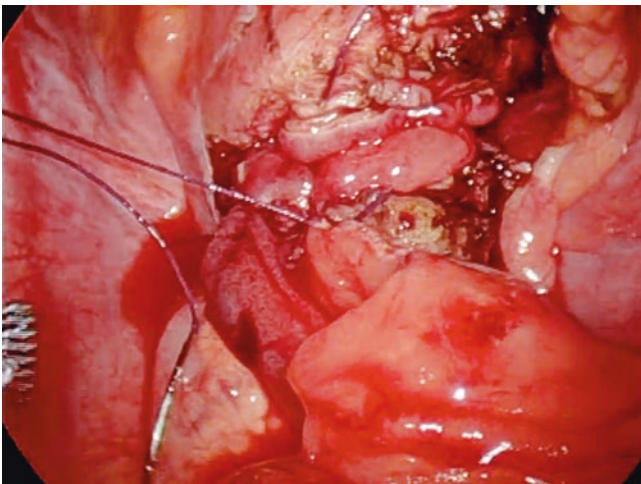


Fig. 37.13 Posterior layer suturing in progress

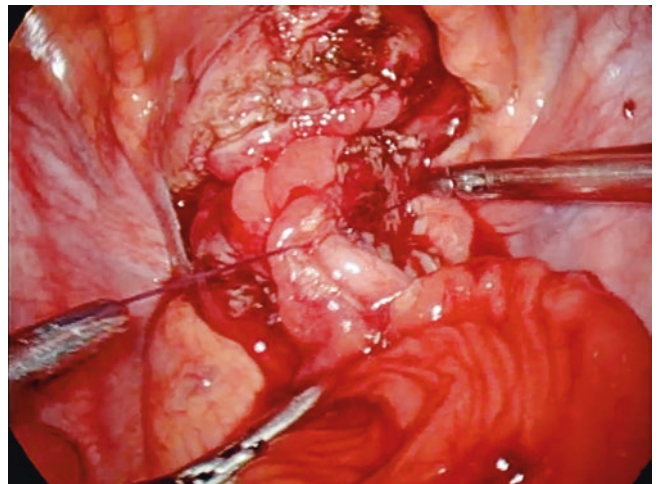


Fig. 37.14 Posterior layer suturing in progress

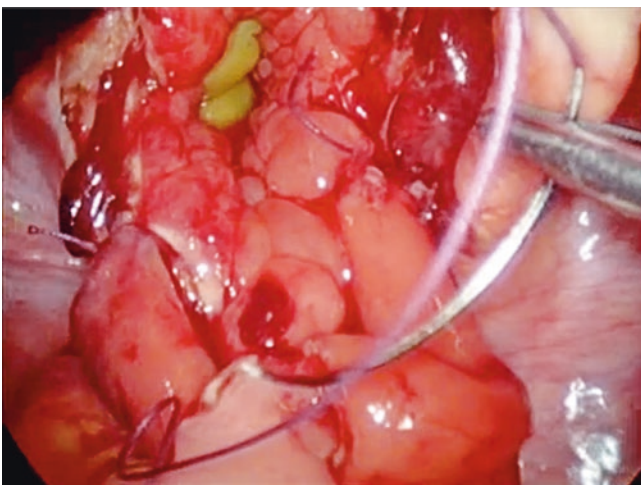


Fig. 37.15 Posterior layer suturing complete

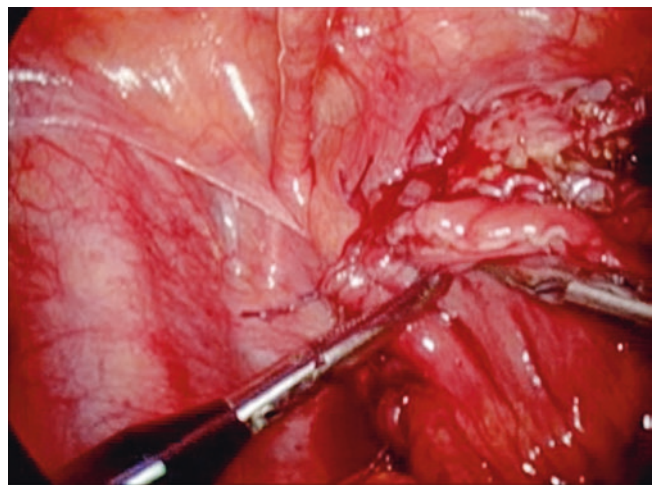


Fig. 37.16 Anterior layer continuous suturing in progress

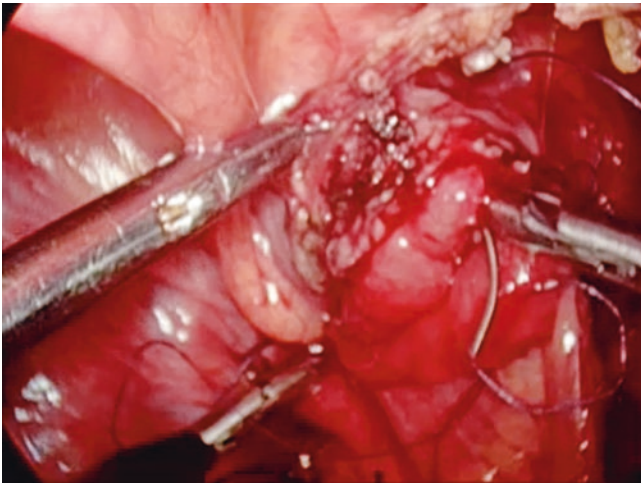


Fig. 37.17 Anterior layer suturing in progress

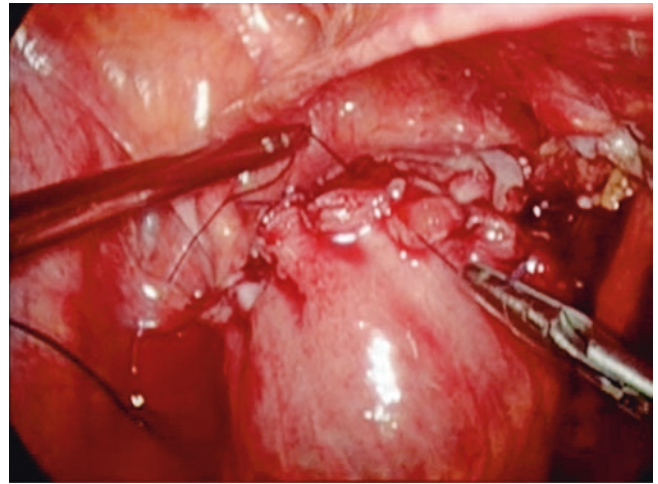


Fig. 37.18 Completed anastomosis. Bladder distended to look for leak

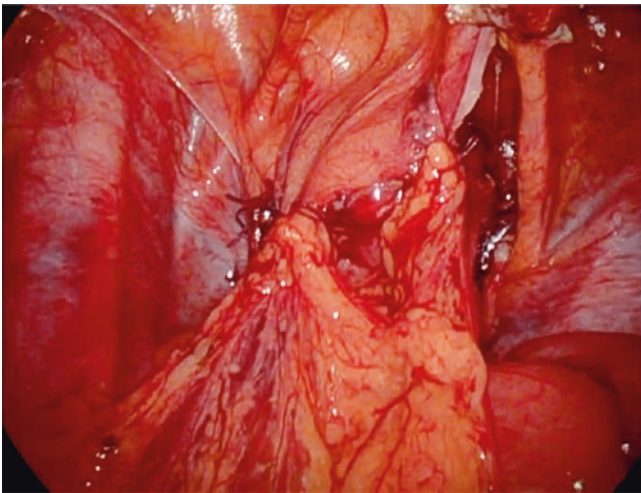


Fig. 37.19 Omentum tacked to suture line

References

1. Gill IS, Rackley RR, Meraney AM, Marcello PW, Gyung TS. Laparoscopic enterocystoplasty. *Urology*. 2000;55:178.
2. Elliott SP, Meng MV, Anwar HP, Stoller ML. Complete laparoscopic ileal cystoplasty. *Urology*. 2002;59:939.
3. Ramalingam M, Senthil K, Selvarajan K, Pai MG. Laparoscopic ileocystoplasty – our experience in 3 patients (abstract). *J Endo*. 2006;20(1):A277.
4. Meng M, Anwar HP, Elliott SP, Stoller ML. Pure laparoscopic enterocystoplasty. *J Urol*. 2002;167:1386.
5. Ramalingam M, Senthil K, Pai MG. Modified technique of laparoscopy-assisted surgeries (transportal). *J Endourol*. 2008; 22(12):2681–5. doi:[10.1089/end.2008.0209](https://doi.org/10.1089/end.2008.0209).

Manickam Ramalingam, Kallappan Senthil,
Anandan Murugesan, and Mizar G. Pai

38.1 Introduction

Ileal conduit is a temporary option in neurogenic bladder with compromised renal function or as a last option in neurogenic bladders when complex reconstruction is not preferred or possible [1]. Undiversion is performed when the patient prefers the procedure or when there are complications resulting from the diversion. In patients with compromised renal function, the ileal conduit can be undiverted once the renal function improves [2]. Undiversion performed laparoscopically will provide the benefit of minimal access surgery to these patients.

38.2 Indications and Evaluation

The main prerequisite for undiversion is normal renal function in the presence of ileal conduit. If this criterion is satisfied, any patient needing augmentation cystoplasty (with ileal conduit) is a candidate for laparoscopic undiversion and augmentation cystoplasty. Cystogram and urodynamic study is essential to evaluate the need and type of augmentation. Patient should be willing to comply with clean intermittent catheterization post operatively.

M. Ramalingam (✉)
PSG Hospitals,
Coimbatore, India
e-mail: uroram@yahoo.com

K. Senthil, MCh (Urol., FRCS)
Urology clinic, Gowtham annexe, Coimbatore, India
e-mail: senthilsatya@hotmail.com

A. Murugesan, MBBS, MS, MCh
Department of Urology, PSG Institute of Medical Sciences
and Research, Peelamedu, Coimbatore, Tamil Nadu, India
e-mail: anandan79@gmail.com

M.G. Pai
Urology clinic, Gowtham annexe, Coimbatore, India
e-mail: mizargpai@yahoo.co.in

38.3 Methods

Patient is under general anesthesia, and placed in supine position with Trendelenberg tilt. Five ports were inserted as shown in the figure. Adhesions due to previous surgery, are released initially taking care to preserve the ileal conduit. Bladder is dissected and dropped down. Circumferential incision is made around the ileal conduit stoma, and the conduit was released from the abdominal wall. The ileal stoma edges are freshened and closed in two layers using a 3-0 Vicryl suture. Conduit is pushed back into the peritoneum. The stoma site is closed to prevent gas leak. The ileal loop is opened along the antimesenteric border (for detubularization), except at the site of ureteric reimplantation. Transverse cystotomy was done from one ureteric orifice to the other, and the detubularized ileum is sutured to the cystotomy using continuous 3-0 Vicryl sutures. The posterior layer is sutured first. Omental wrapping is done. The ureteroenteric anastomosis is left undisturbed if it is not hindering the free movement of the conduit segment to the bladder. A suprapubic catheter, urethral catheter, and drain are placed, and the port sites are closed.

38.4 Discussion

Urinary undiversion is predominantly performed in pediatric patients with myelodysplasia and other neurogenic bladder dysfunctions [4]. Laparoscopic undiversion was first reported by Wolf et al. [5] in 1998 in a patient with bladder and rectal injuries. Laparoscopic-assisted undiversion to orthotopic neobladder was reported in 2006 by Castillo et al. [3, 6]. The laparoscopic approach is postulated to reduce ileus resulting from less bowel handling and less pain because of avoidance of abdominal wall retractors [6]. Laparoscopic undiversion with augmentation in a child was first reported by Ramalingam et al. in 2012 [7].

Conclusion

Laparoscopic undiversion with augmentation is a feasible, effective, and less-morbid procedure in a child and is possibly a better alternative to open undiversion.

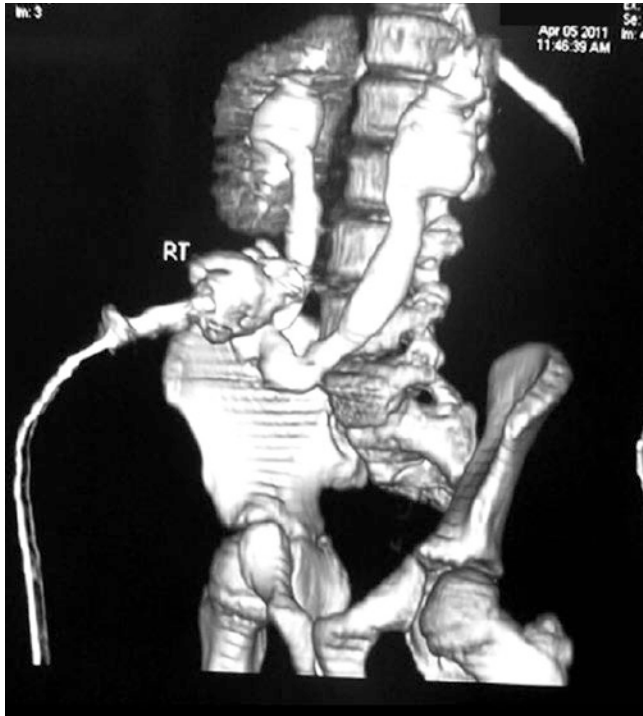


Fig. 38.1 CT scan of a sacral agencies patient with ileal conduit (neurogenic bladder with renal failure who improved in 3 years after diversion)

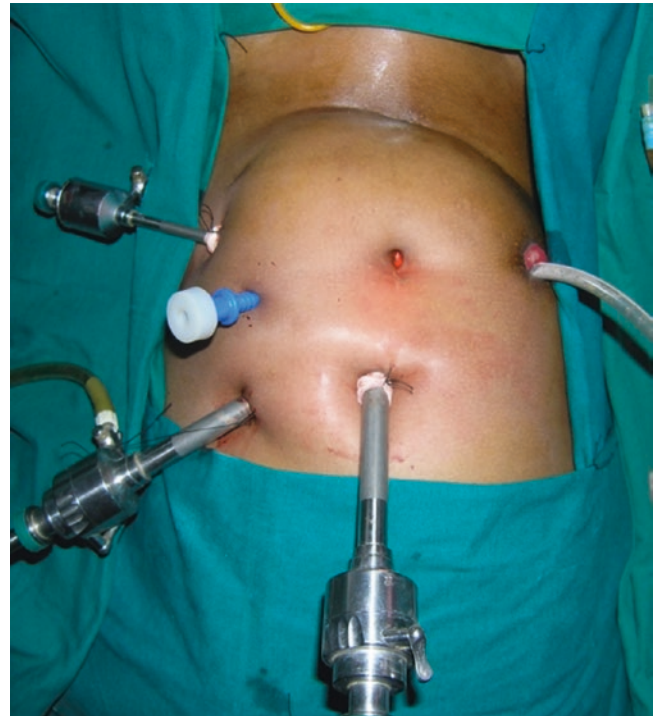

Fig. 38.2 Ports position and stoma location

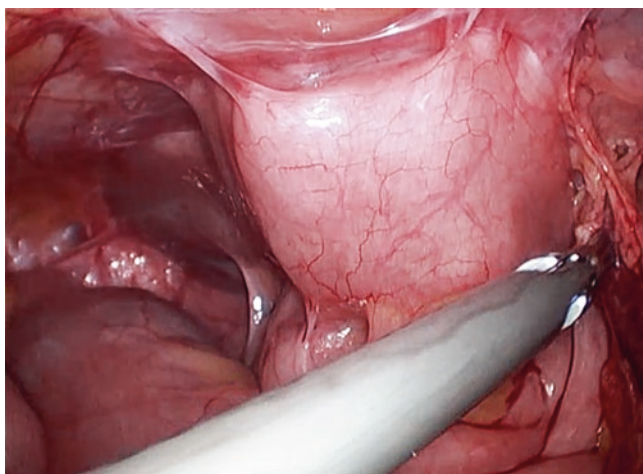


Fig. 38.3 Initial view of bowel adhesions

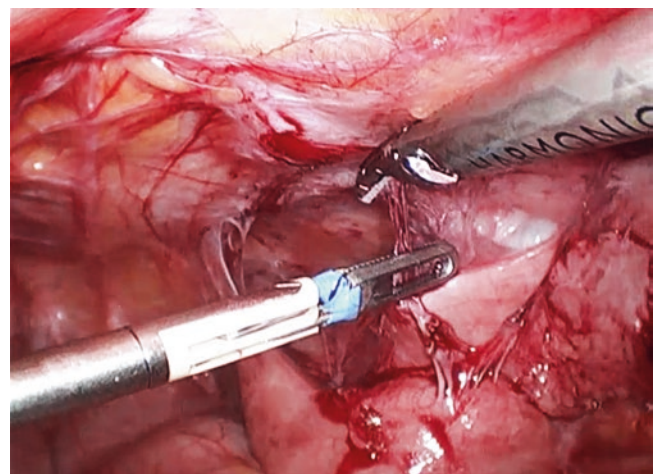


Fig. 38.4 Bowel adhesions being released

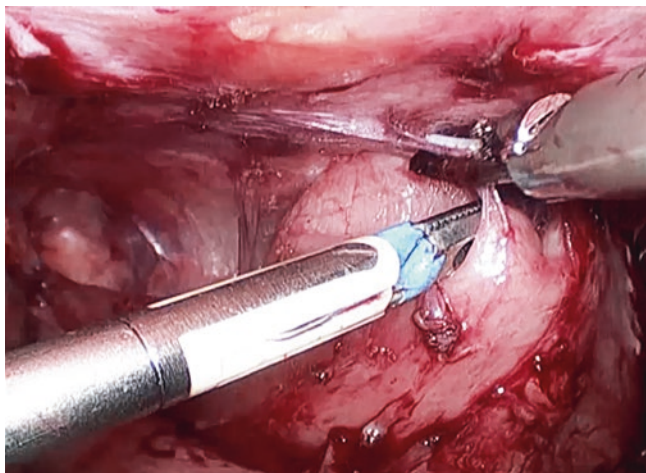


Fig. 38.5 Bowel adhesions being released

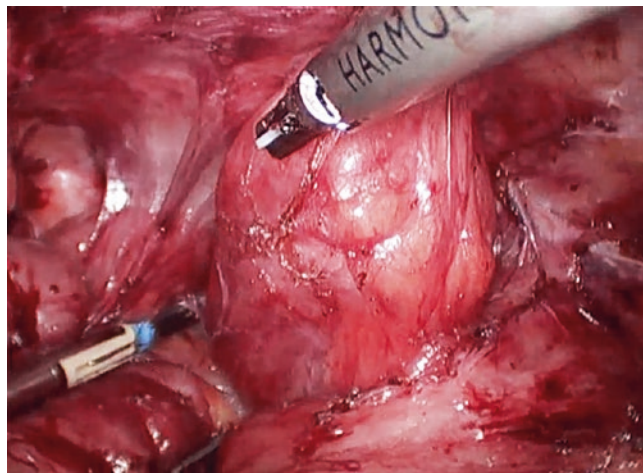


Fig. 38.6 Conduit as seen after release of bowel adhesions

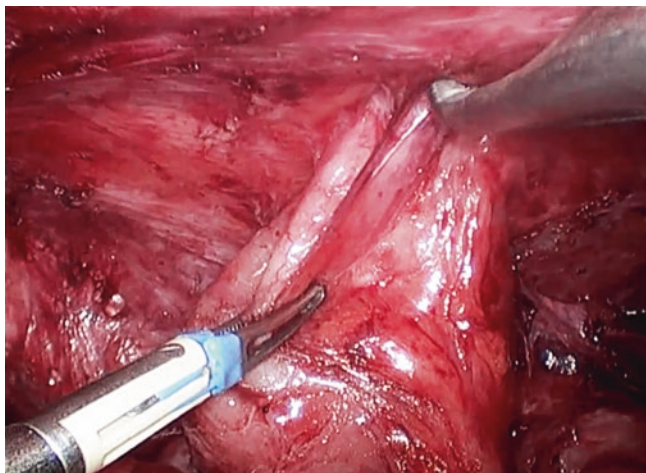


Fig. 38.7 Conduit being mobilised

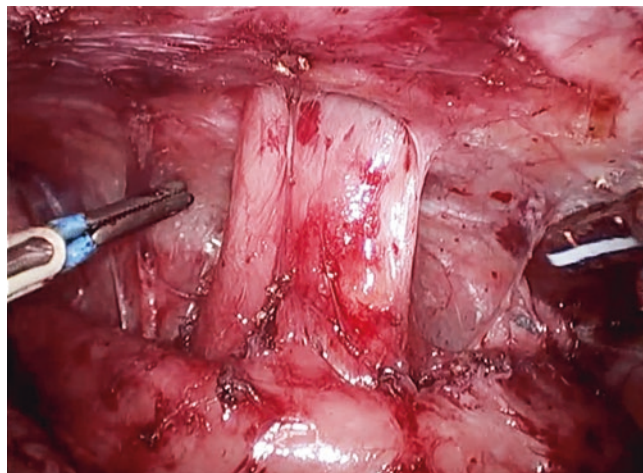


Fig. 38.8 Conduit dissected all around near the abdominal wall

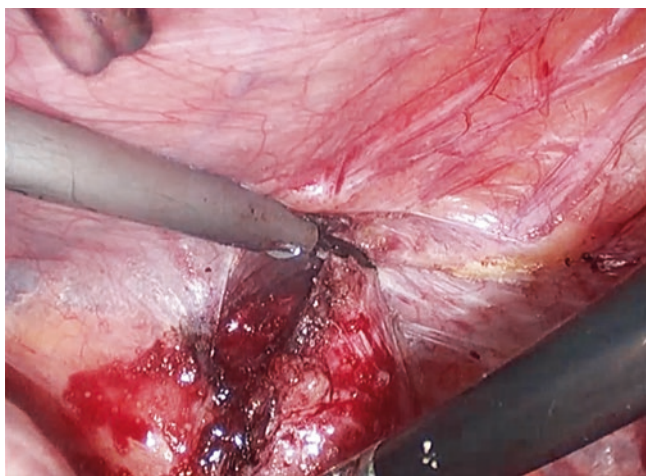


Fig. 38.9 Bladder being dropped down

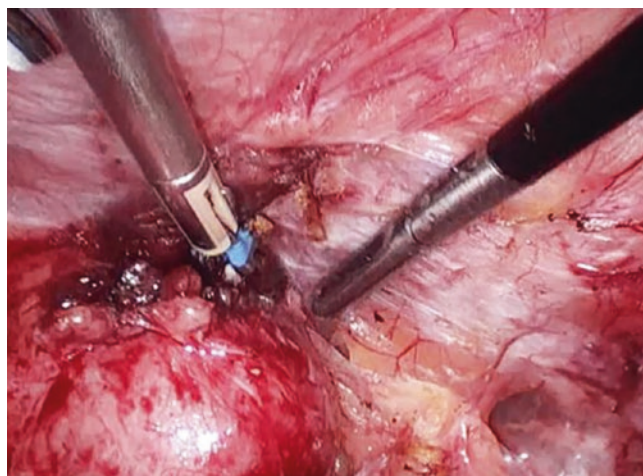


Fig. 38.10 Bladder completely mobilised down

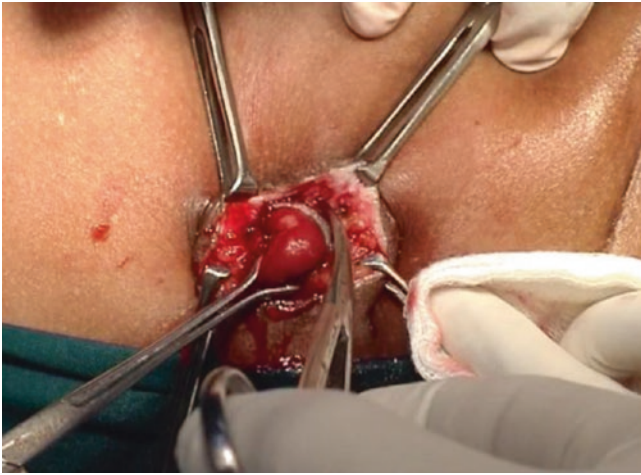


Fig. 38.11 Stoma dissected from abdominal wall and conduit about to be internalised

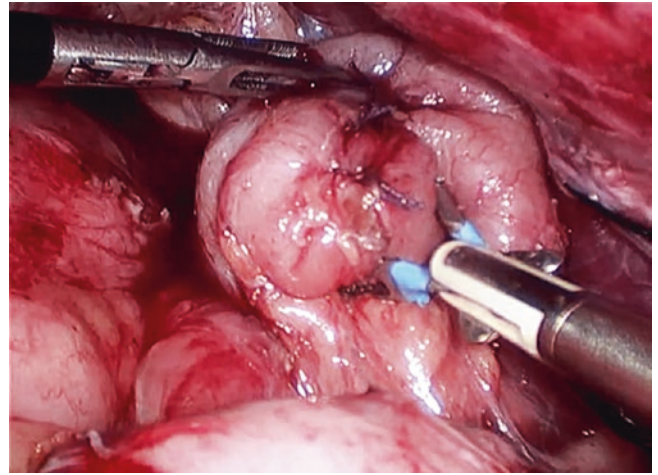


Fig. 38.12 Stoma separated from abdominal wall, closed and pushed into peritoneal cavity

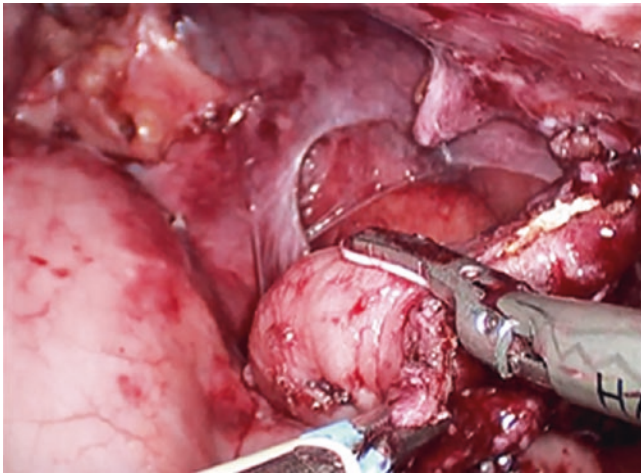


Fig. 38.13 Internalised conduit being detubularised

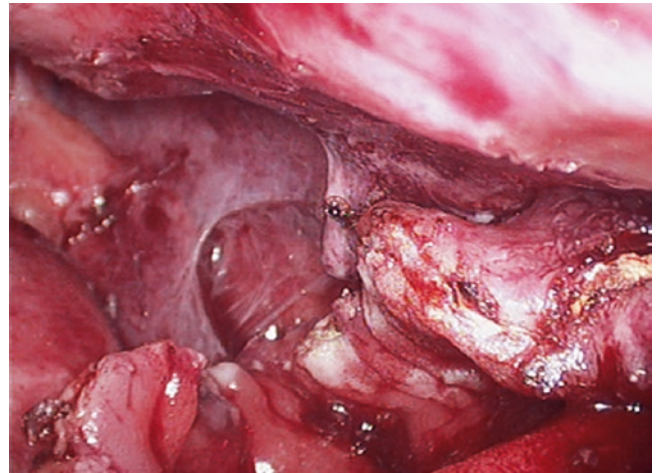


Fig. 38.14 Detubularisation complete

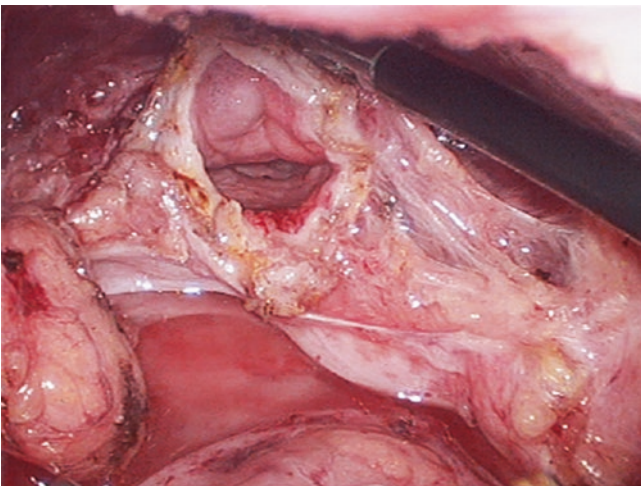


Fig. 38.15 Transverse cystotomy in progress

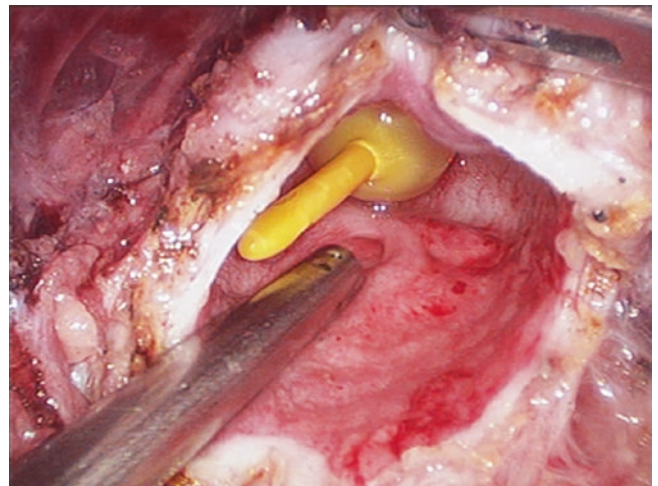


Fig. 38.16 Cystotomy completed

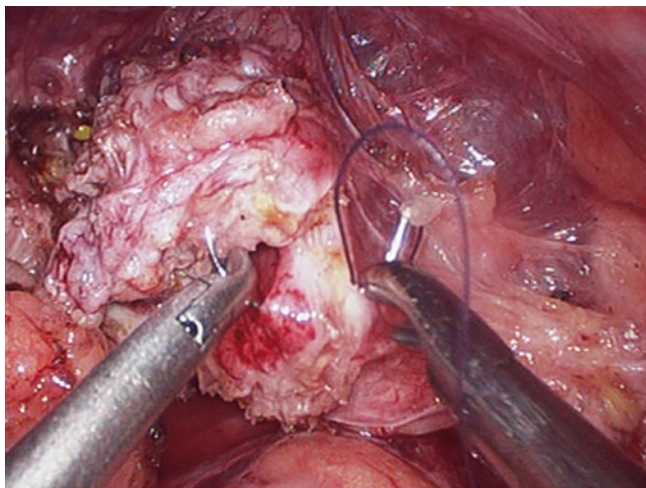


Fig. 38.17 Cystoplasty started with 2-0 vicryl suture out side – in through bladder

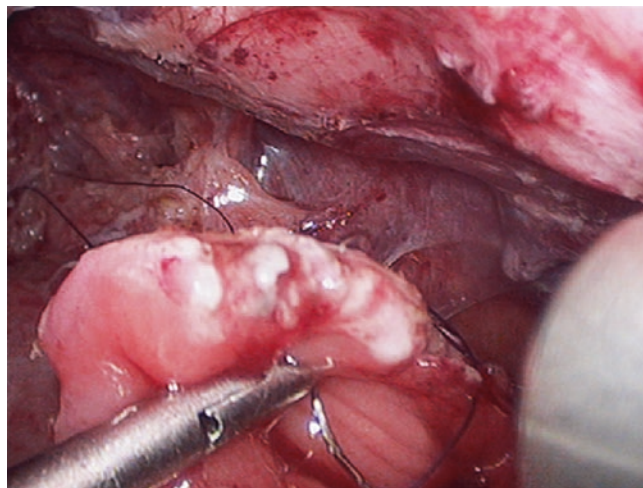


Fig. 38.18 First suture of posterior layer of ileum inside-out

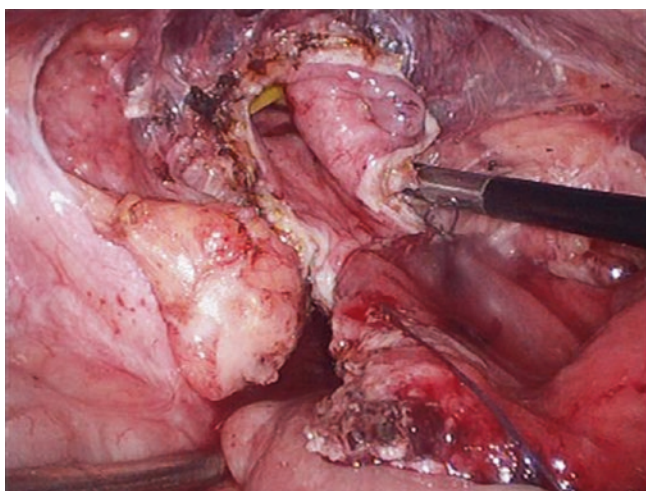


Fig. 38.19 Continuous suture of posterior layer in progress

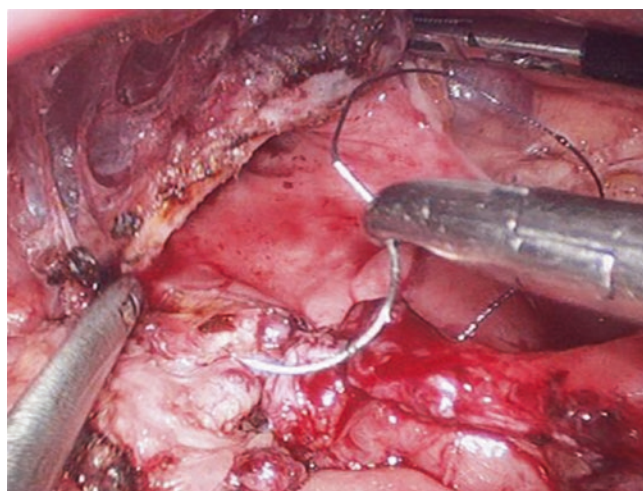


Fig. 38.20 Cystoplasty in progress

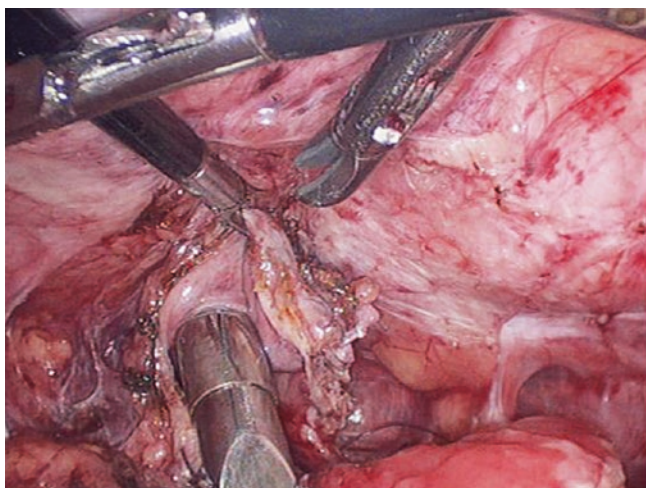


Fig. 38.21 Trocar for SPC insertion

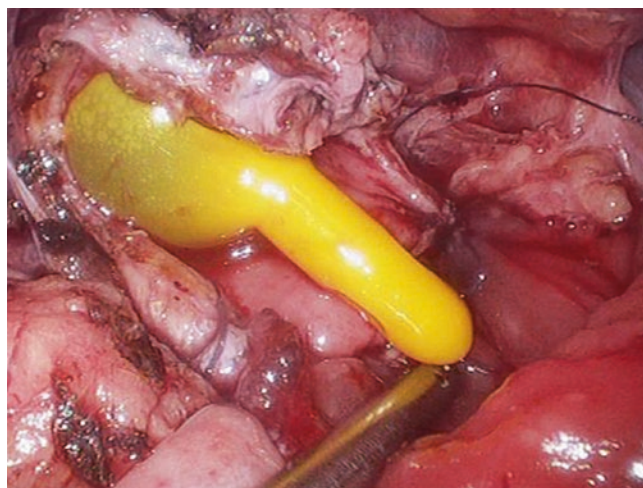


Fig. 38.22 SPC inserted

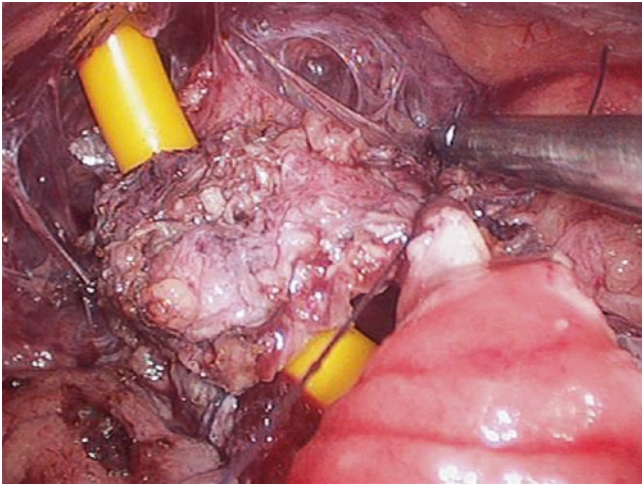


Fig. 38.23 Anterior layer suturing in progress

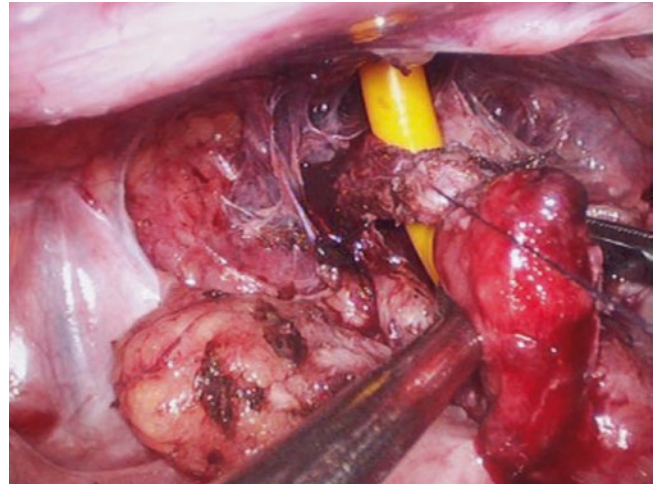


Fig. 38.24 Cystoplasty in progress

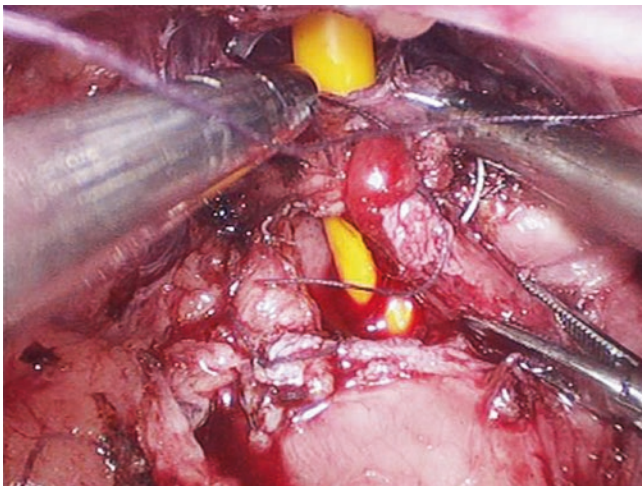


Fig. 38.25 Cystoplasty in progress

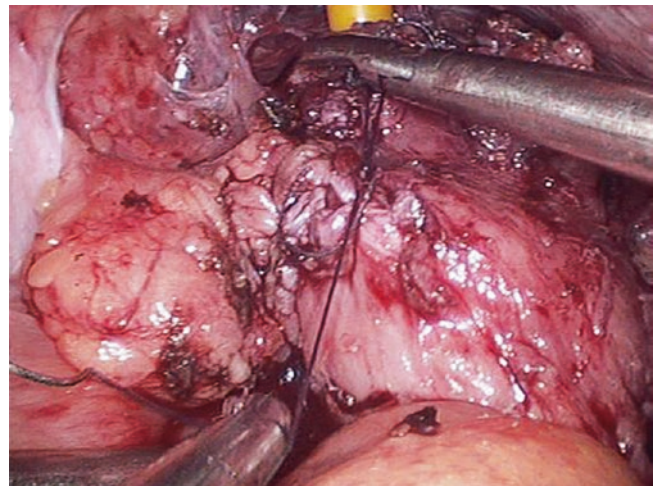


Fig. 38.26 Anterior layer suturing completed

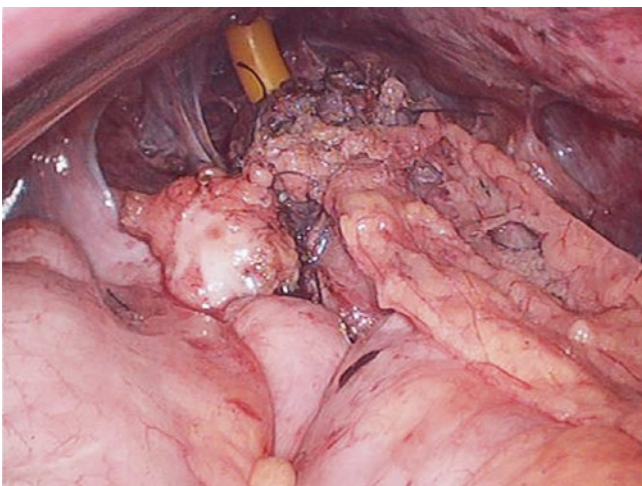


Fig. 38.27 Omental tacking of suture line

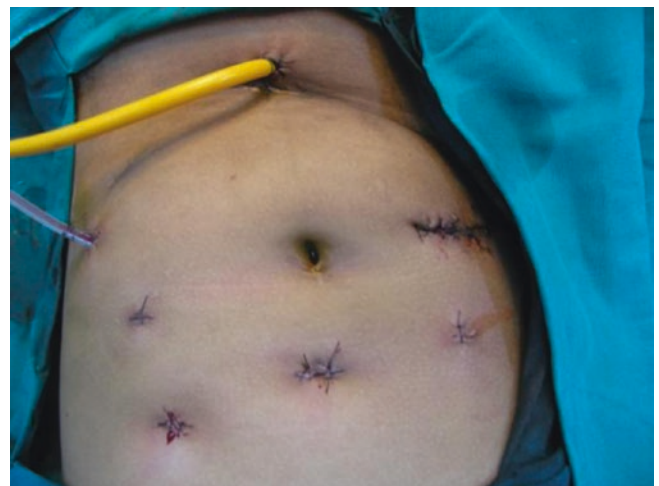

Fig. 38.28 Final view after undiversion

References

1. McDougal WS. Use of intestinal segments and urinary diversion. In: Walsh PC, Retik AB, Vaughan Jr ED, Wein AJ, editors. *Campbell's urology*. 8th ed. Philadelphia: WB Saunders; 2002. p. 3771.
2. Hendren WH. Urinary tract refunctionalisation after long term undiversion: a 20-year experience with 177 patients. *Ann Surg*. 1990;212:478.
3. Ramalingam M, Senthil K, Pai MG. Modified technique of laparoscopy-assisted surgeries (transportal). *J Endourol*. 2008;22:2681–5.
4. Robertson CN, King LR. Bladder substitution in children. *Urol Clin North Am*. 1986;13:333–44.
5. Wolf Jr JS, Taheri PA. Laparoscopic urinary undiversion. *J Urol*. 1998;159:198–9.
6. Castillo OA, Pinto I, Rossi R, Urena RD. Case report: laparoscopy-assisted urinary undiversion: transforming an ileal conduit into an orthotopic continent neobladder. *J Endourol*. 2006;20:899–903.
7. Ramalingam M, Senthil K, Murugesan A, Pai MG. Laparoscopic undiversion in a child with sacral agenesis into augmentation cystoplasty. *JSLs*. 2013;17(3):450–3.

39.1 Introduction

Augmentation of bladder is usually done with ileum. However in patients with unilateral nonfunctional kidney with gross hydroureteronephrosis; nephrectomy with ureterocystoplasty is an option. This technique is preferable, since it avoids the use of bowel in urinary tract and the associated electrolyte imbalances of bowel; especially in patients with decreased renal function [1–7].

39.2 Indication

Patients needing augmentation of bladder; with a dilated distal ureter, and associated nonfunctioning kidney.

Preliminary evaluation includes urine culture, MCU, IVU, isotope renal scan, cystometry and cystoscopy.

39.3 Surgical Technique

Nephrectomy is done in a nonfunctioning kidney through transperitoneal approach. This is done with the patient in 70° lateral tilt using four ports (umbilical camera port, subcostal, midclavicular and flank ports). Subsequently the patient is placed supine; and by adding one more pararectus port (on the contralateral side) ureterocystoplasty can be done.

The ureter which is selected to augment the bladder is detubularised using ultracision or hook diathermy up to the hiatus. A proportionate length of cystotomy is done in a

horizontal manner. The opened ureter is anastomosed to the bladder either as it is, or after reconfiguring (by folding in a ‘U’ configuration). Bladder augmentation is done with 3-0 vicryl continuous suture, posterior layer first and anterior layer subsequently. A single layer suture will suffice if reasonably watertight (as checked by distending the bladder through preplaced Foley catheter). If there is any leak few more interrupted sutures will be needed. Omental tacking to sutural line is preferable. A tube drain can be left through flank port.

39.4 Ureterocystoplasty in Functioning Kidney

In a functioning kidney with gross ureteral dilatation, ureterocystoplasty is done by a side-to-side anastomosis [2, 6].

If the kidney is functioning and the ureter is grossly dilated, side to side anastomosis of divided lower ureter with transureteroureterostomy of the rest of the segment may also be done. Transureteroureterostomy is discussed in Chap. 16.

39.5 Comment

Augmentation of bladder with ureter is preferable to augmentation using bowel. When it is done completely laparoscopically, it is less morbid and avoids problems encountered with bowel interposition.

M. Ramalingam (✉)
PSG Hospitals,
Coimbatore, India
e-mail: uroram@yahoo.com

K. Senthil, MCh (Urol., FRCS)
Urology clinic, Coimbatore, India
e-mail: senthilsatya@hotmail.com

39.6 Laparoscopic Ureterocystoplasty

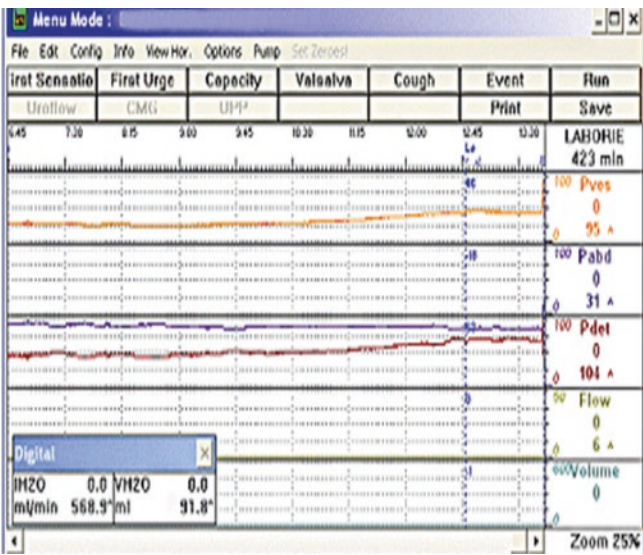


Fig. 39.1 Cystometrograph showing poor compliance bladder

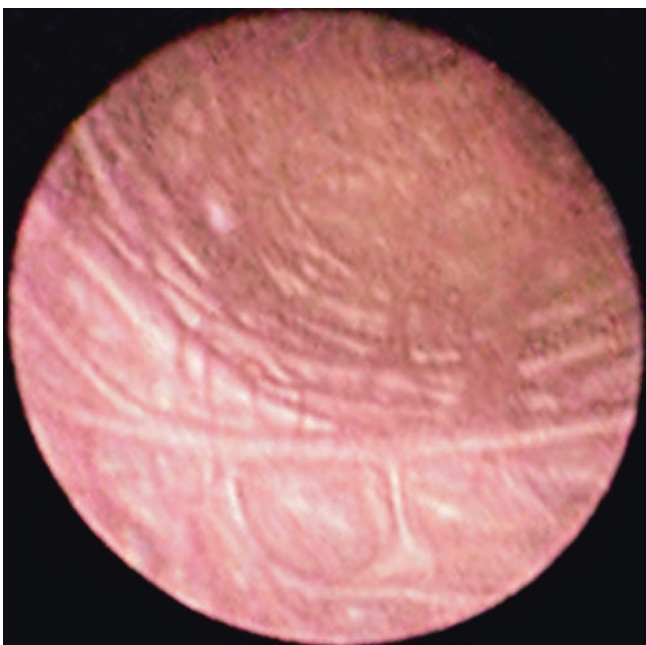


Fig 39.2 Cystoscopy showing trabeculated bladder (of 10 year old boy post PUV fulguration at 1 yr age)

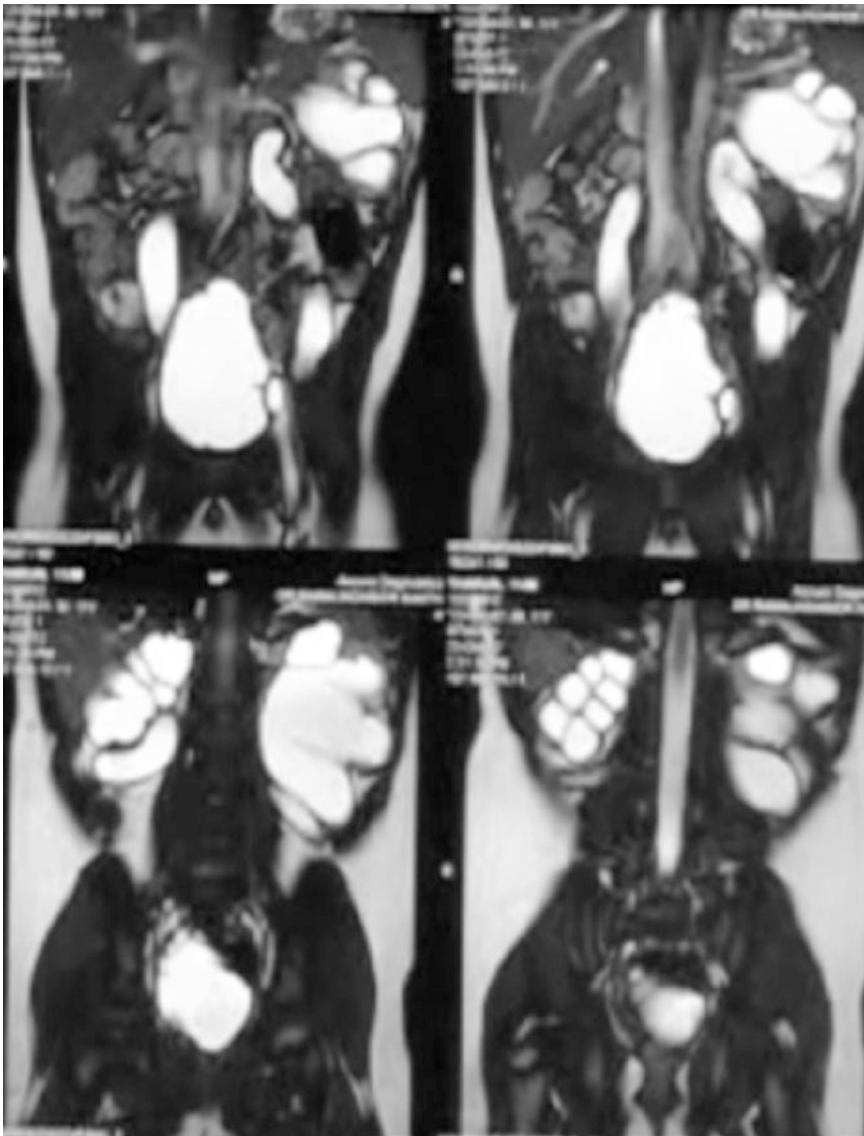


Fig. 39.3 CT scan showing small capacity irregular bladder, grossly dilated right ureter (non functioning kidney)

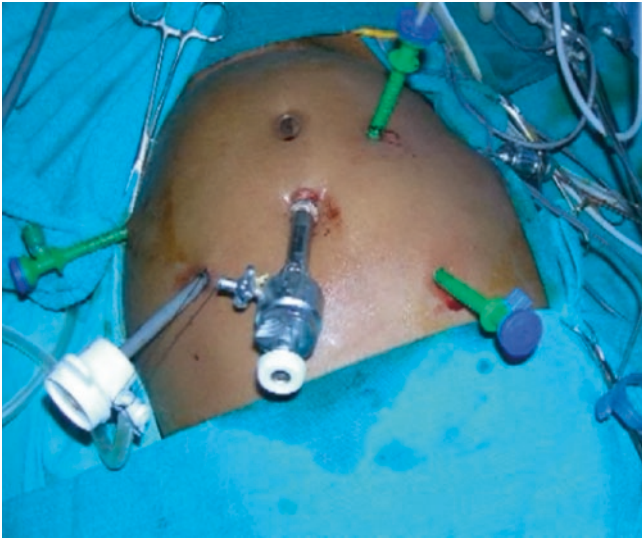


Fig 39.4 Ports position

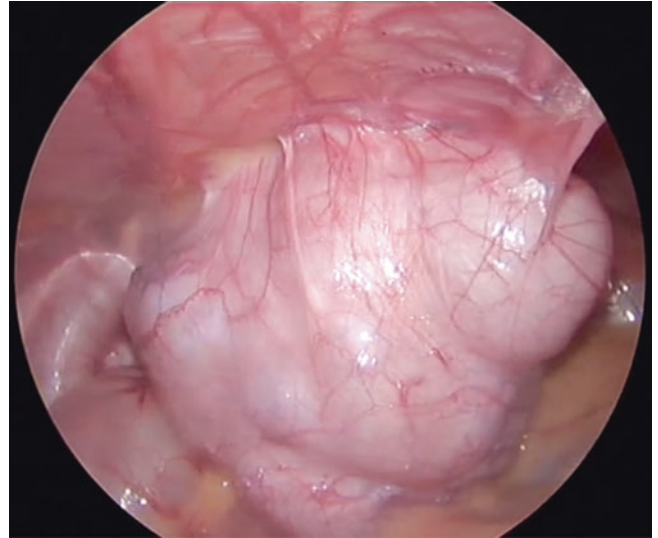


Fig. 39.5 Initial view of the distended bladder

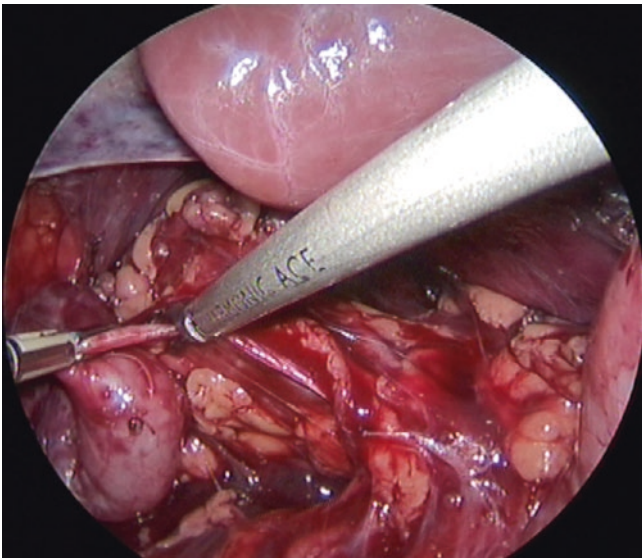


Fig. 39.6 Right ureter dissected till UPJ (subsequently nephrectomy done)

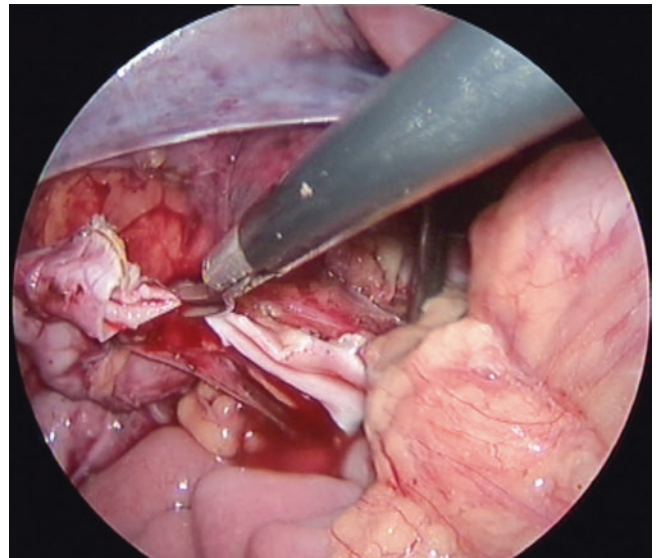


Fig. 39.7 Ureter divided near UPJ

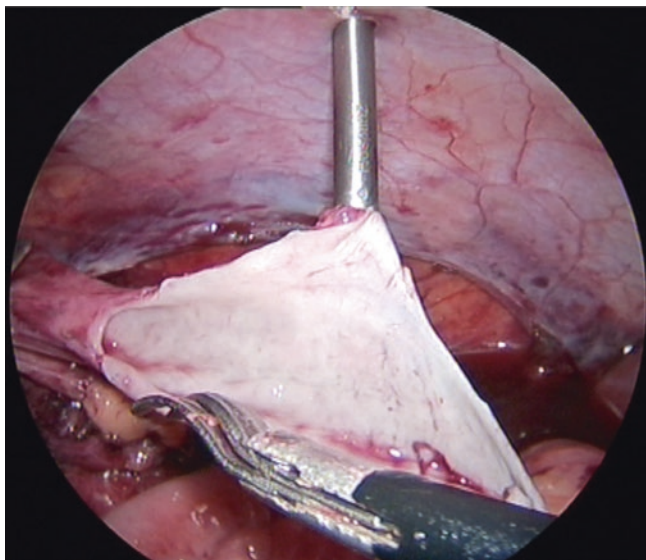


Fig. 39.8 Ureter detubularised on medial aspect

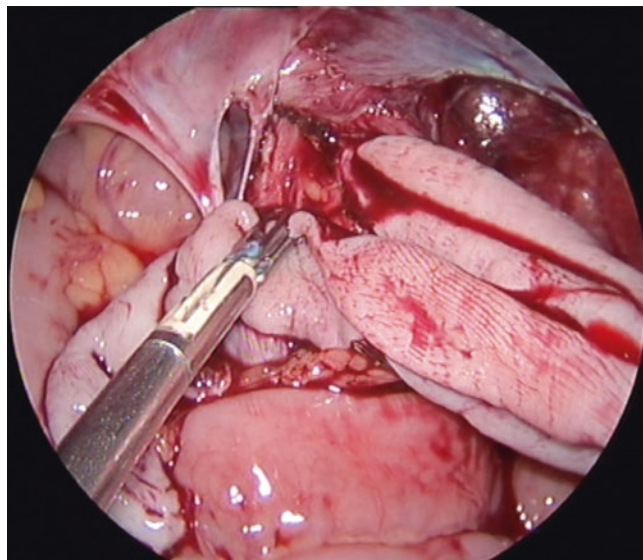


Fig. 39.9 Ureter broadened by folding in u configuration

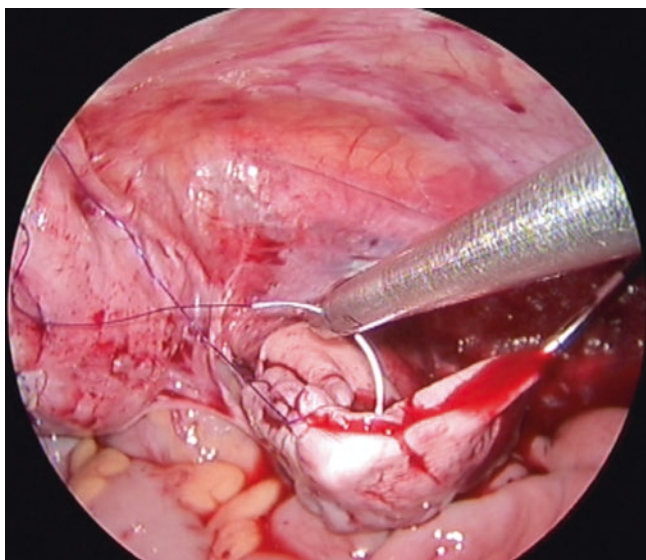


Fig. 39.10 Ureteric flap being reconfigured using 3-0 vicryl

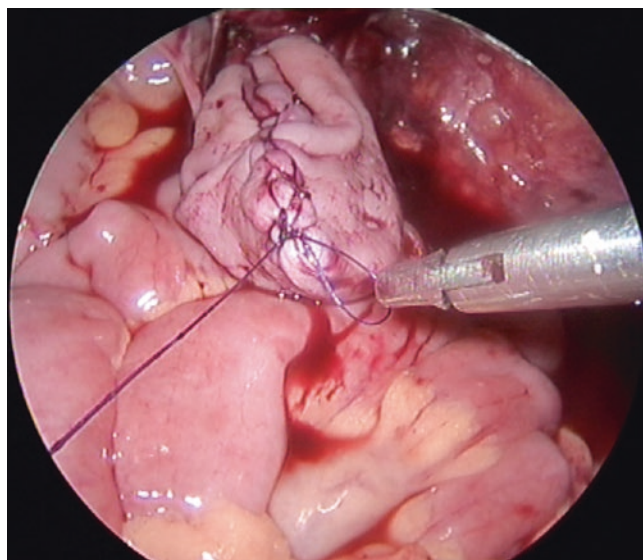


Fig. 39.11 Ureter completely refashioned

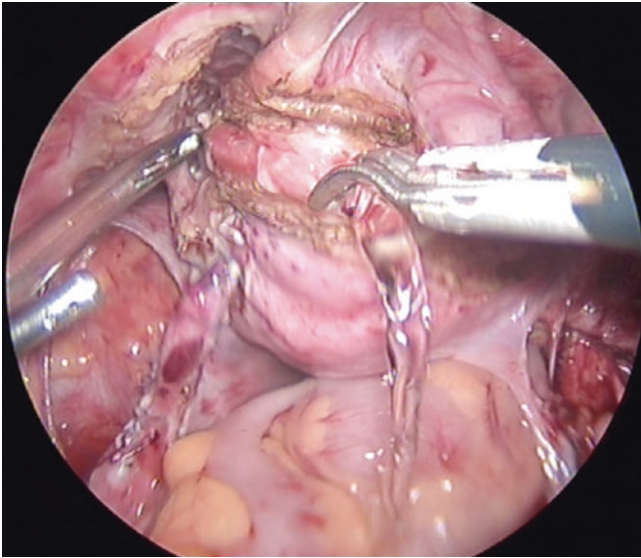


Fig. 39.12 Cystotomy in progress

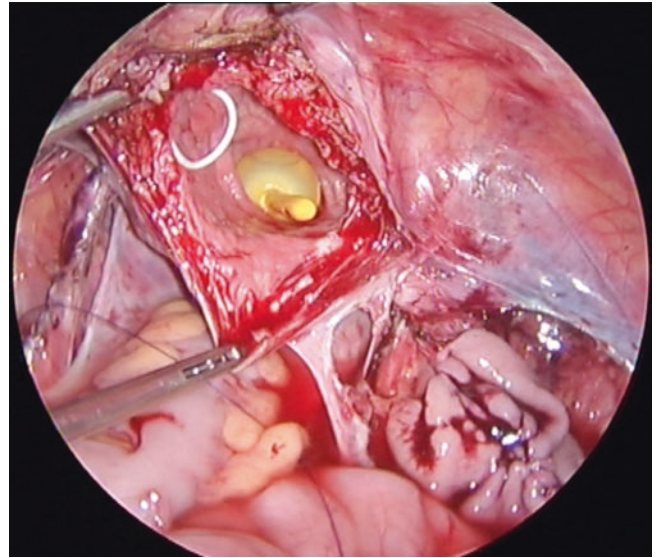


Fig. 39.13 Transverse cystotomy done

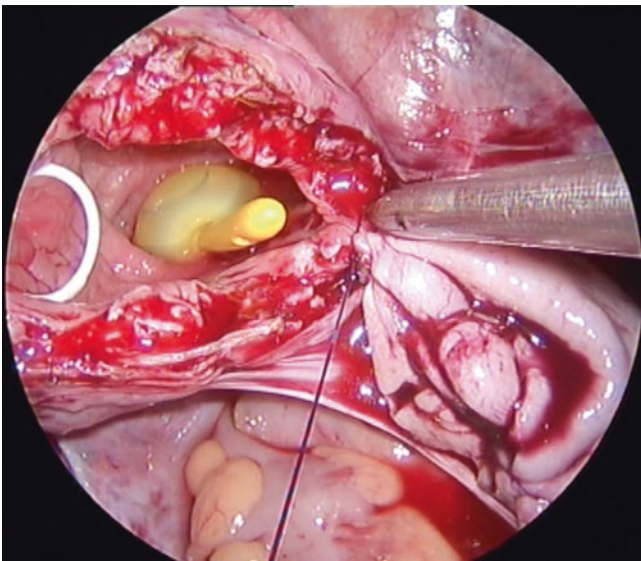


Fig. 39.14 Ureterovesical anastomosis started in one corner (near right UVJ)

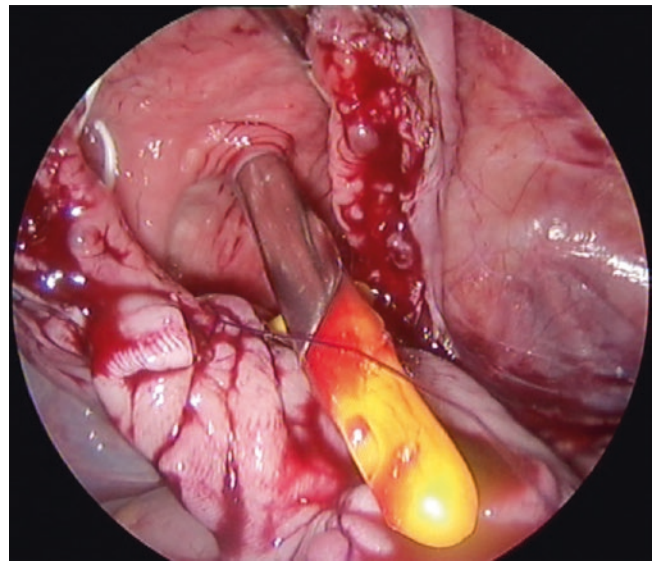


Fig. 39.15 SPC inserted after completing posterior layer

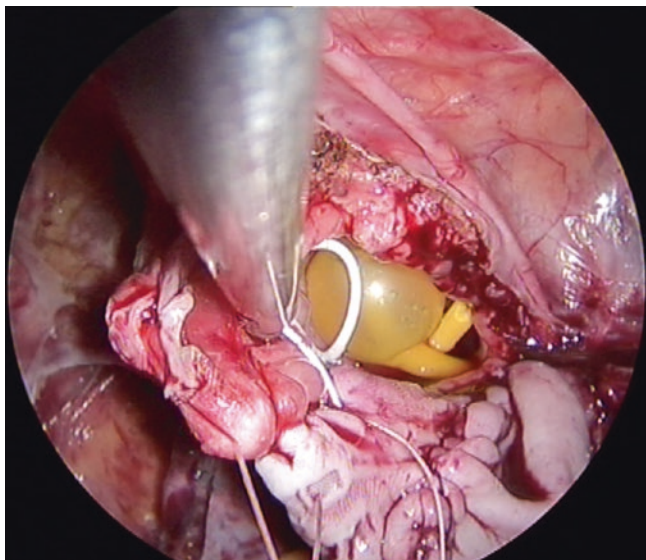


Fig. 39.16 Posterior layer suturing with 3-0 vicryl in continuous fashion

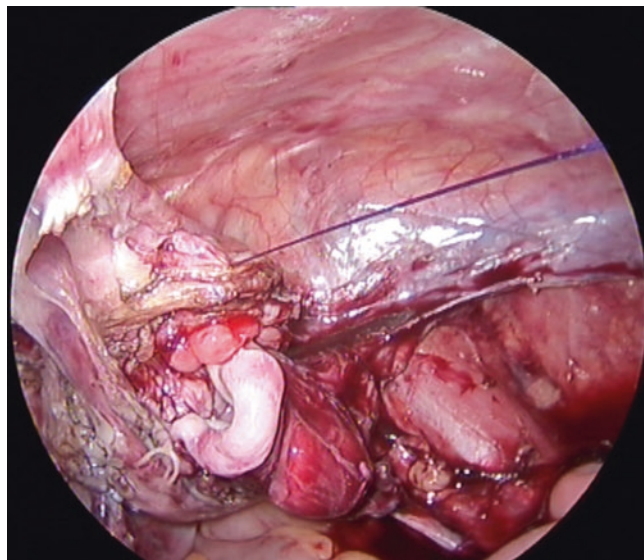


Fig. 39.17 Anterior layer suturing in progress

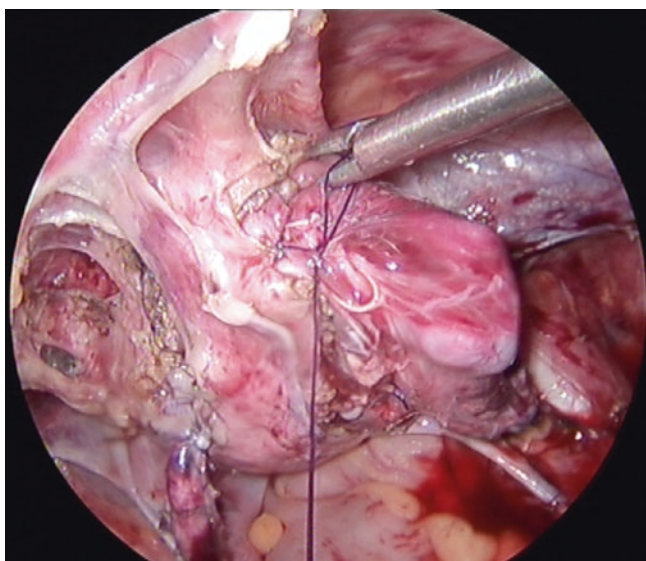


Fig. 39.18 Uretero cystoplasty completed

39.7 Side to Side In-Situ Ureterocystoplasty

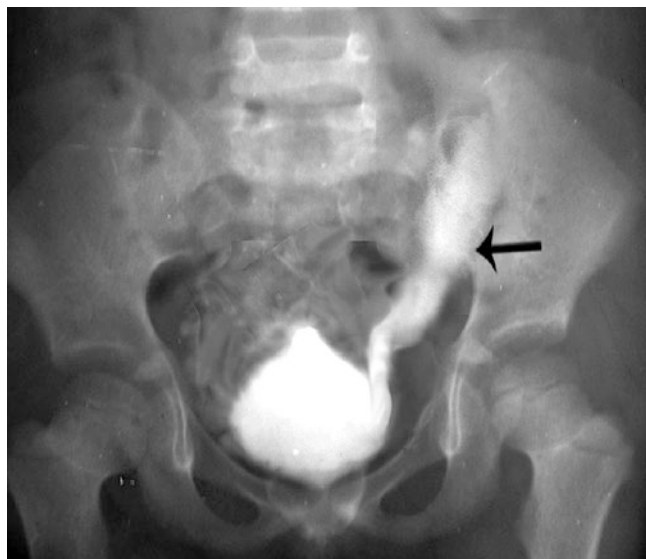

Fig. 39.19 MCU showing small capacity bladder and left VUR (neurogenic bladder)

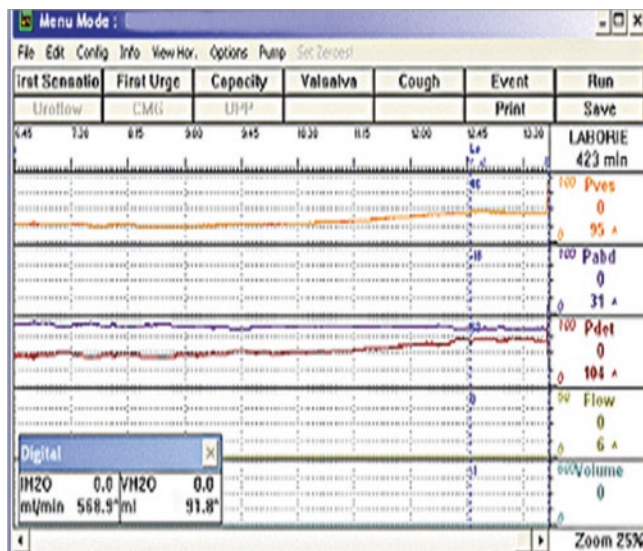


Fig. 39.20 Cystometry showing poorly compliant bladder in a 4 years old child

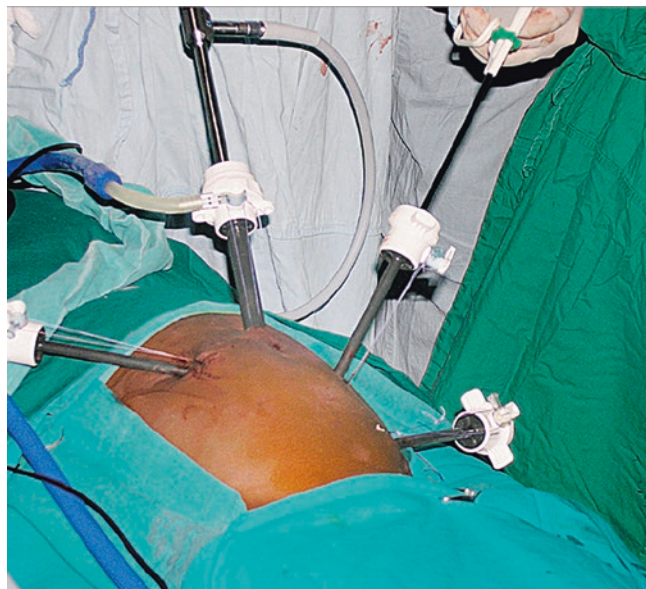

Fig. 39.21 External view of ports position

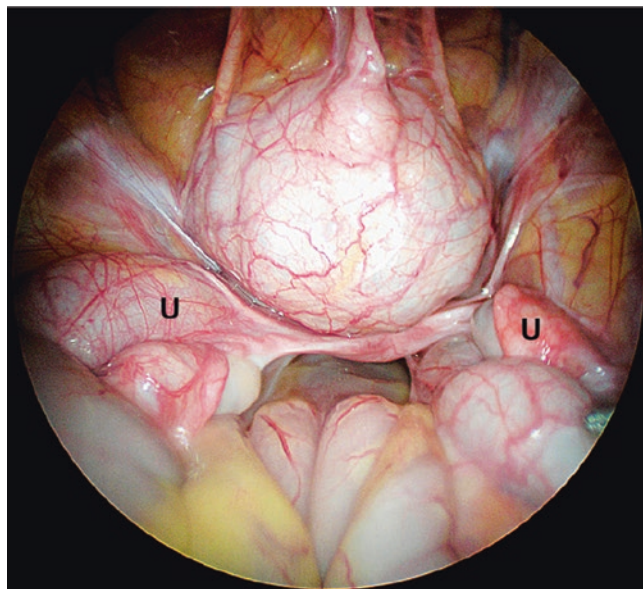


Fig. 39.22 Laparoscopic view of small capacity bladder and bilateral grossly dilated ureters. Left ureter was selected as there was reflux and more dilated, U ureter

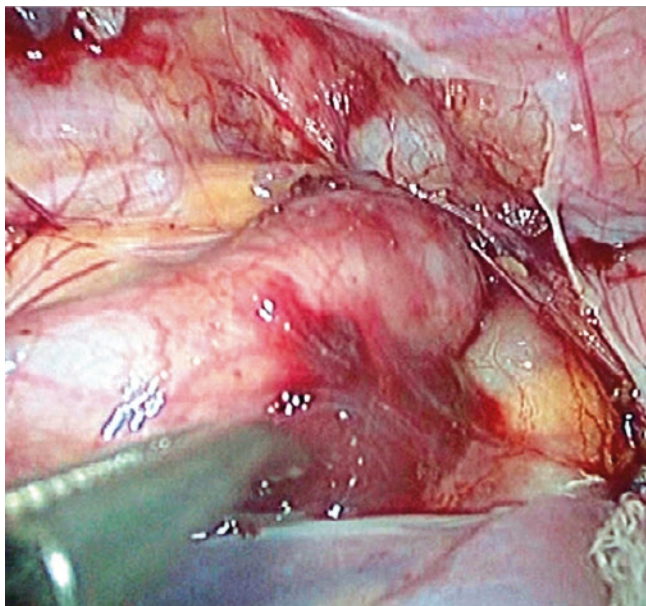


Fig. 39.23 Incision of peritoneum over left lower ureter

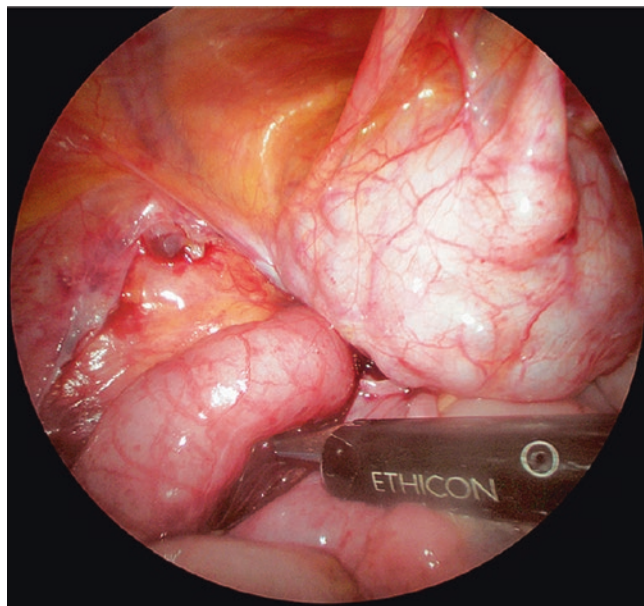


Fig. 39.24 Mobilising left lower ureter to oppose the bladder and plan the probable line of cystotomy

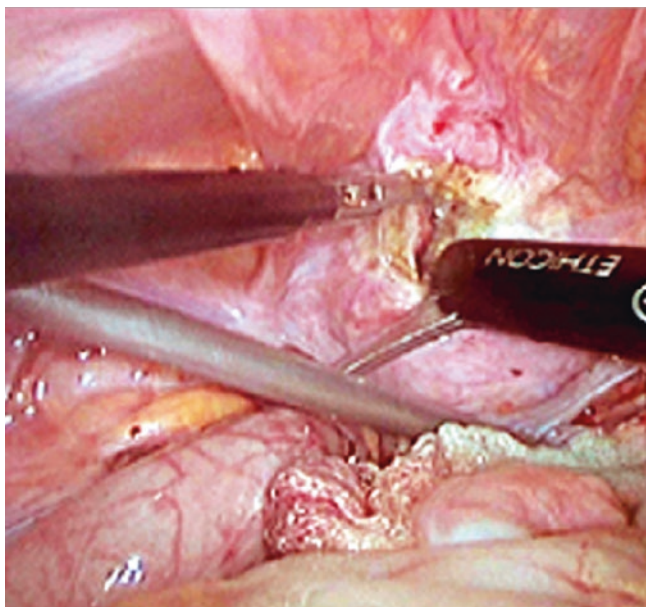


Fig. 39.25 Oblique cystotomy done and extended towards ureteric orifice

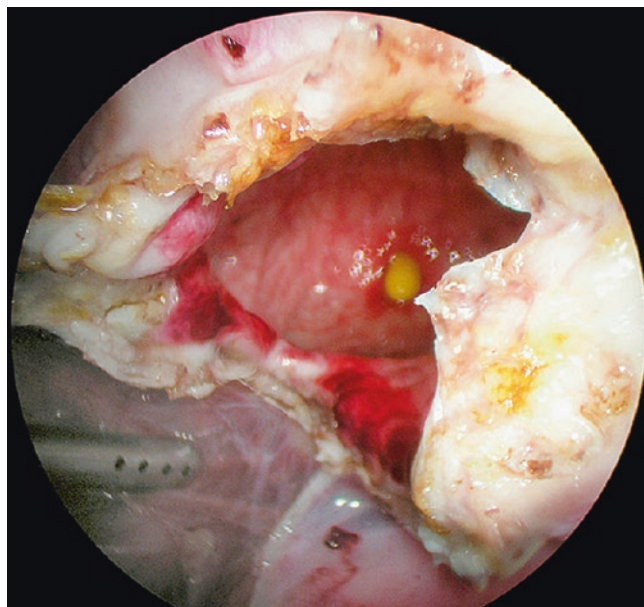


Fig. 39.26 Cystotomy completed (almost up to the left ureteric orifice)

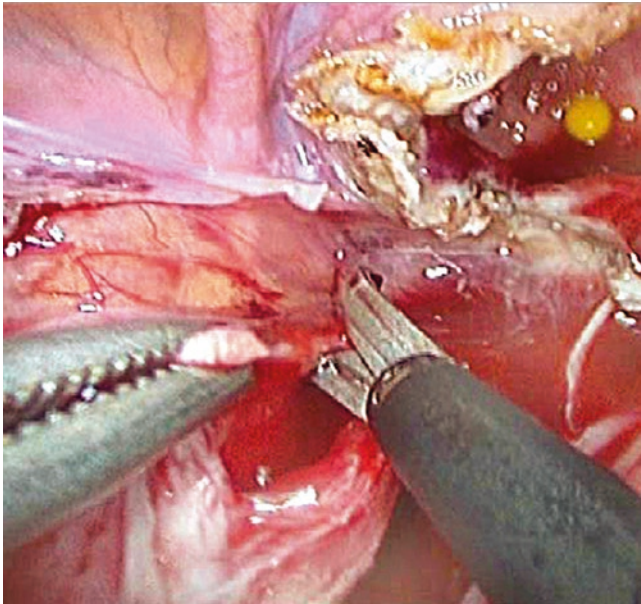


Fig. 39.27 Ureterotomy in progress, just opposing the cystotomy line to make tension free anastomosis

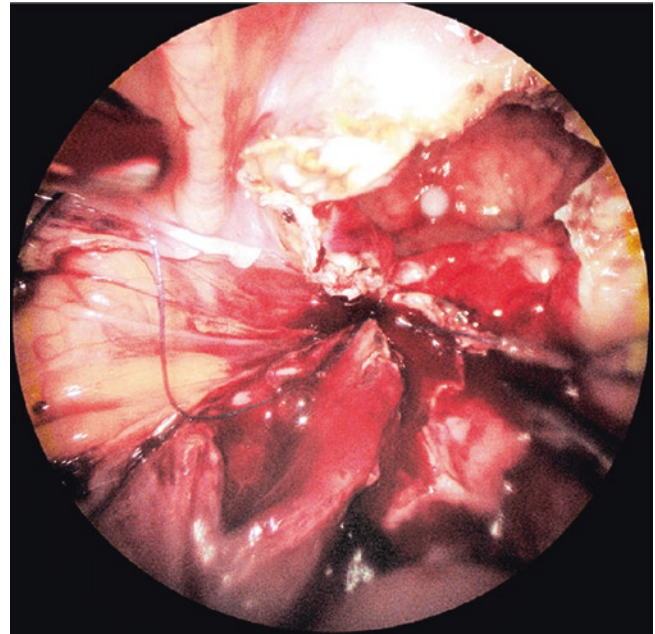


Fig. 39.28 Initial suture with 3-0 vicryl outside in of medial edge of ureterotomy

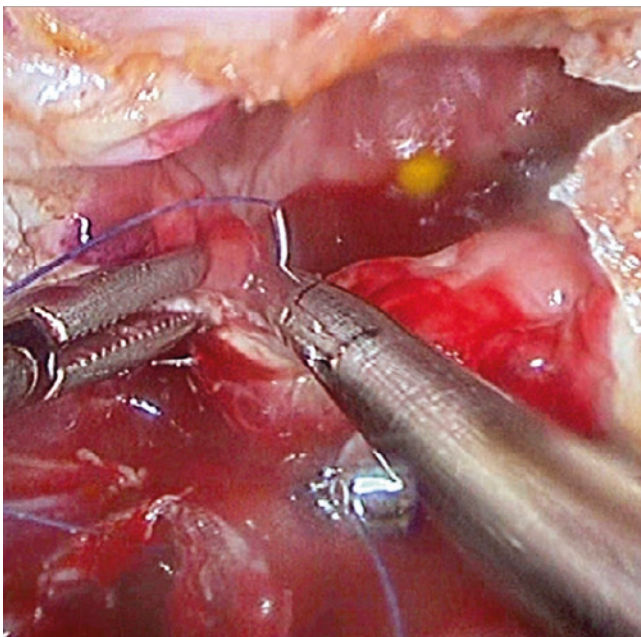


Fig. 39.29 Initial suture taken inside out at the edge of cystotomy

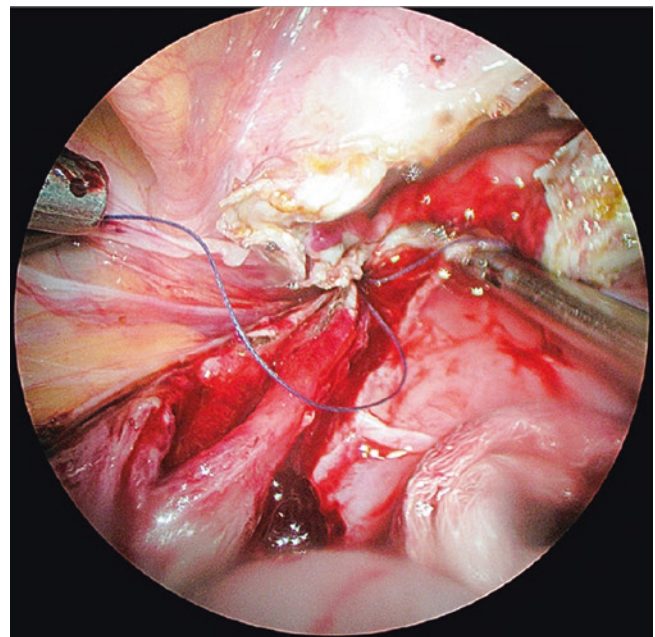


Fig. 39.30 View after initial knot

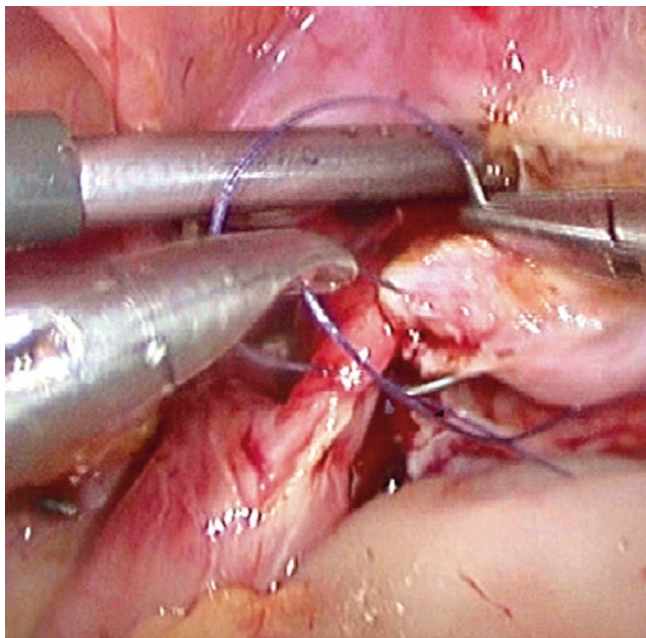


Fig. 39.31 Ureterovesical anastomosis is done using continuous sutures

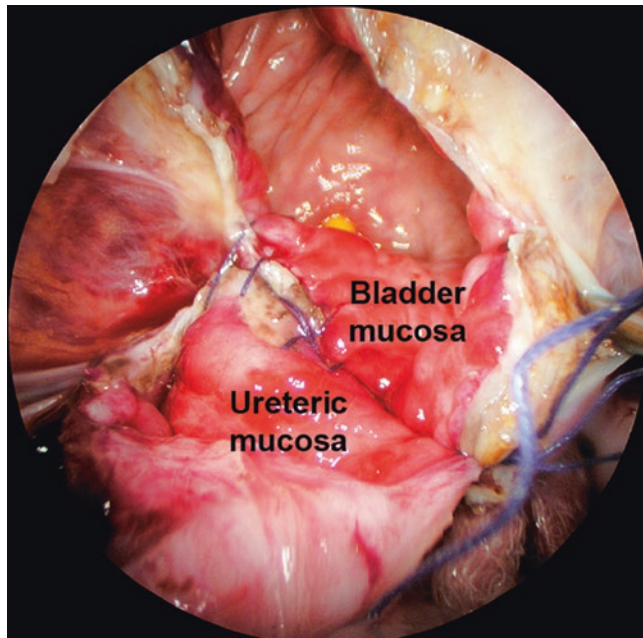


Fig. 39.32 Posterior layer of suture is nearly completed

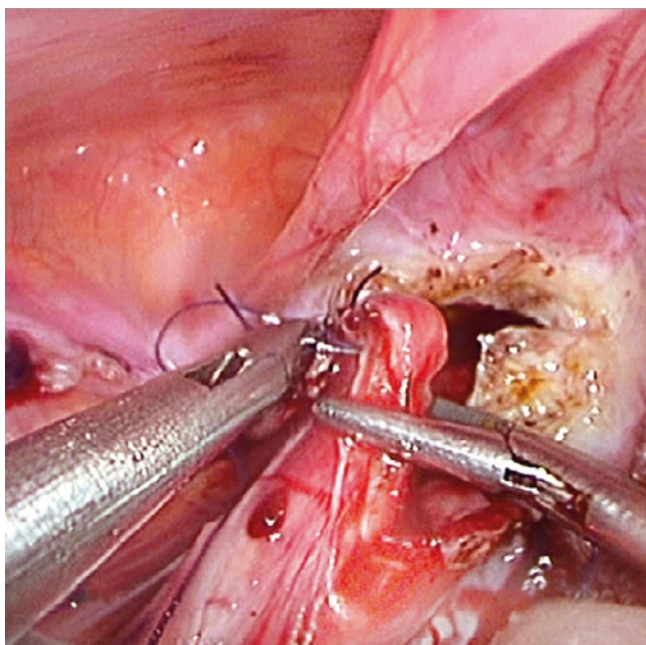


Fig. 39.33 Anterior layer suturing started at the lower end

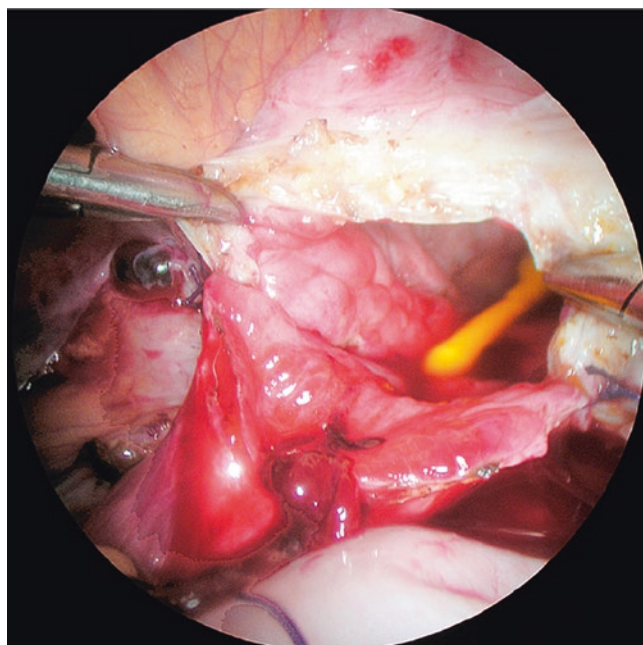


Fig. 39.34 Anterior layer suturing in progress

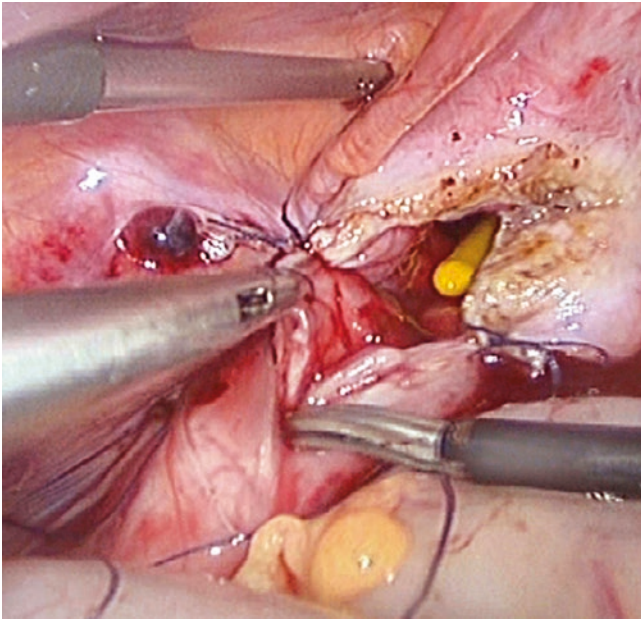


Fig. 39.35 Anterior layer suturing is nearly completed

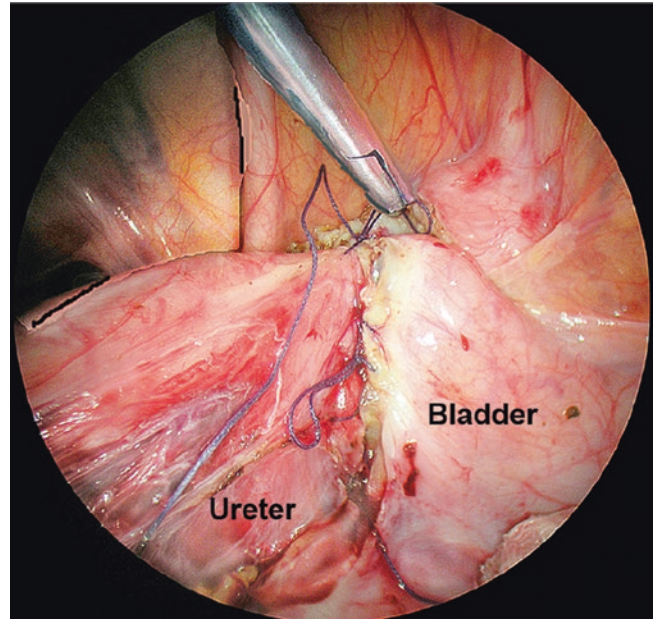


Fig. 39.36 Ureterotomy is extended to match the cystostomy incision

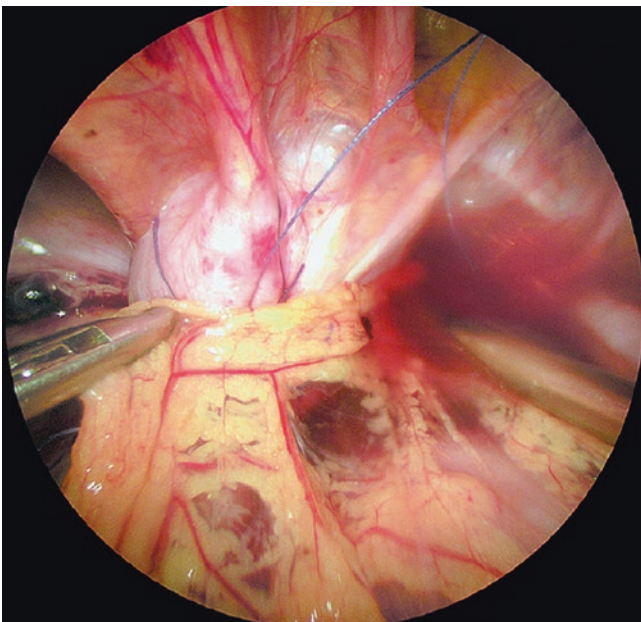


Fig. 39.37 Omental tacking on the anastomotic site

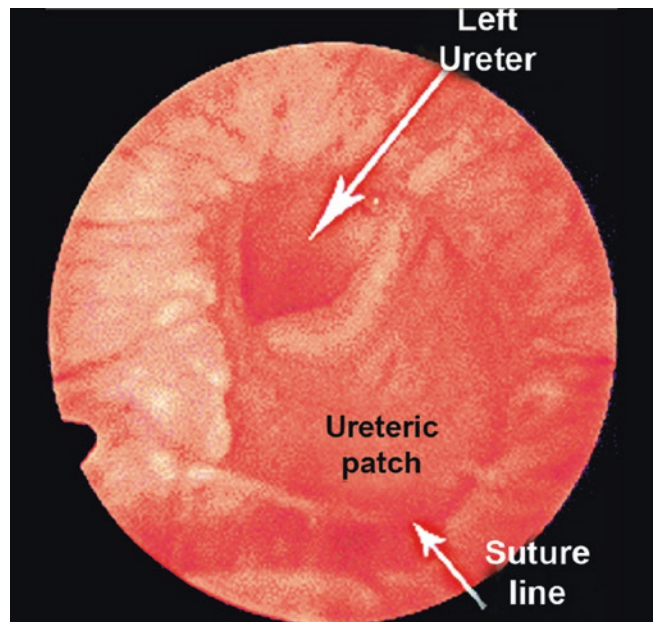


Fig. 39.38 One month postoperative cystoscopy revealed well healed sutured line

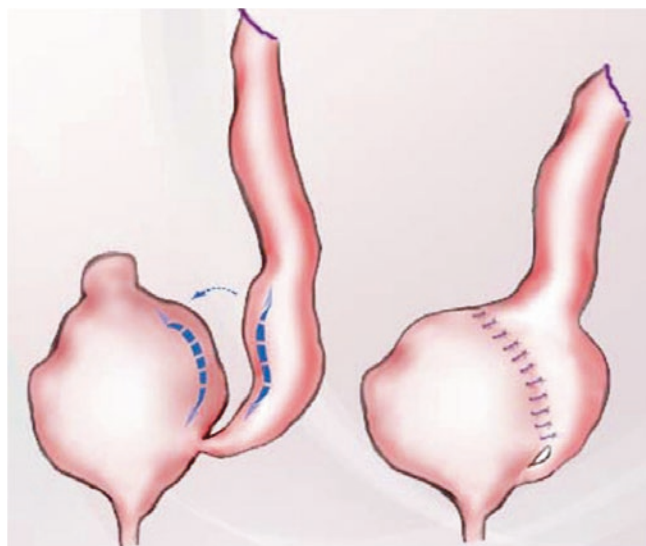


Fig. 39.39 Diagrammatic representation of ureterocystoplasty executed

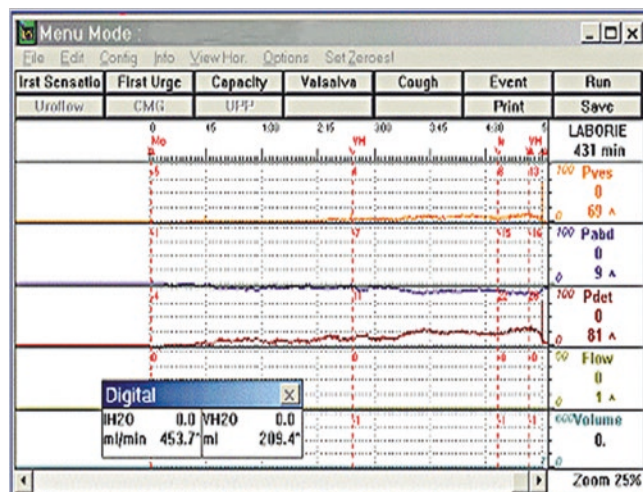


Fig. 39.40 Cystometry done 3 months later showing better compliant bladder

39.8 Side to Side Uretrocystoplasty

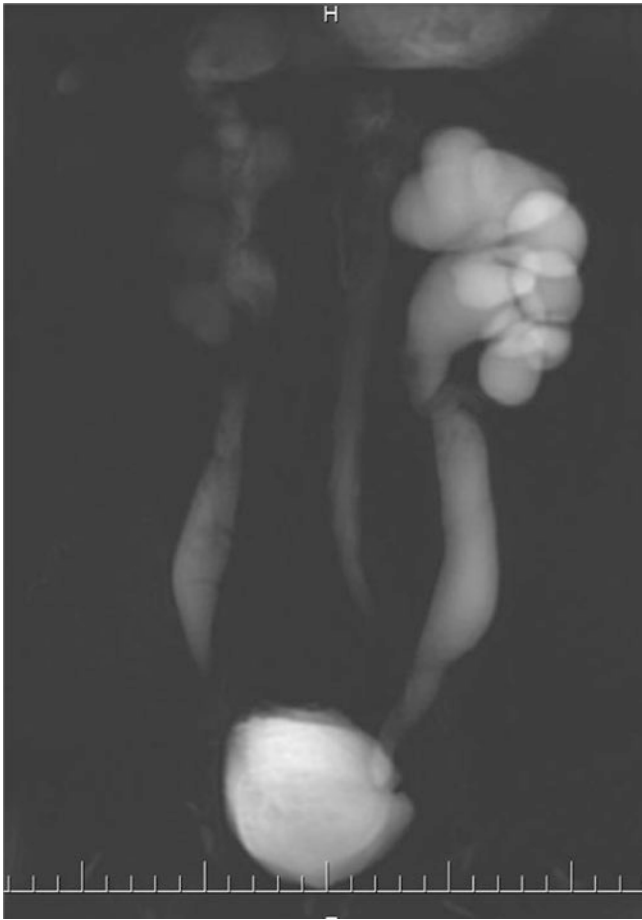

Fig. 39.41 MRI showing obstructed left ureter in a poor compliance bladder

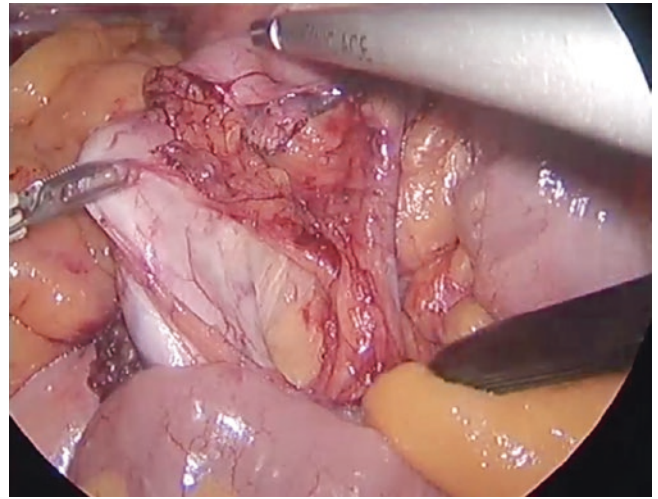


Fig. 39.42 Left ureter being dissected

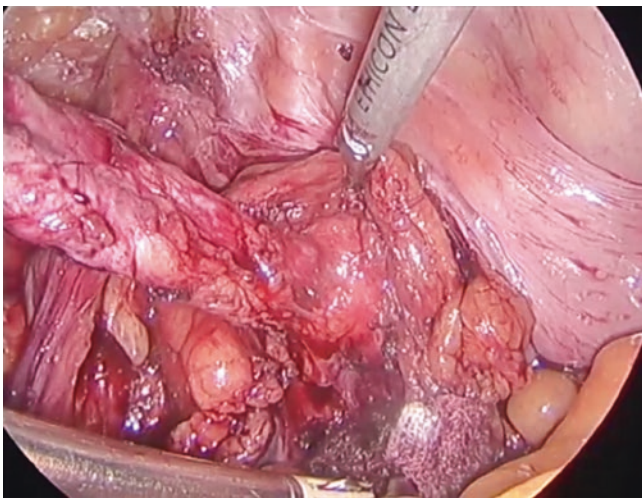


Fig. 39.43 Ureter dissected distally till bladder

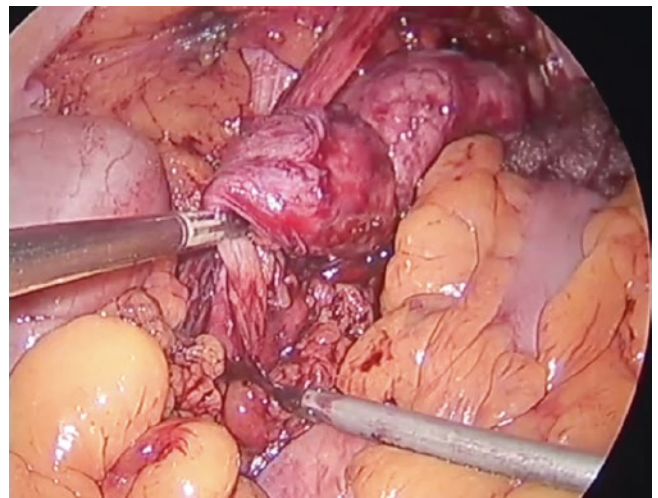


Fig. 39.44 Ureter dissected proximally till pelvic brim

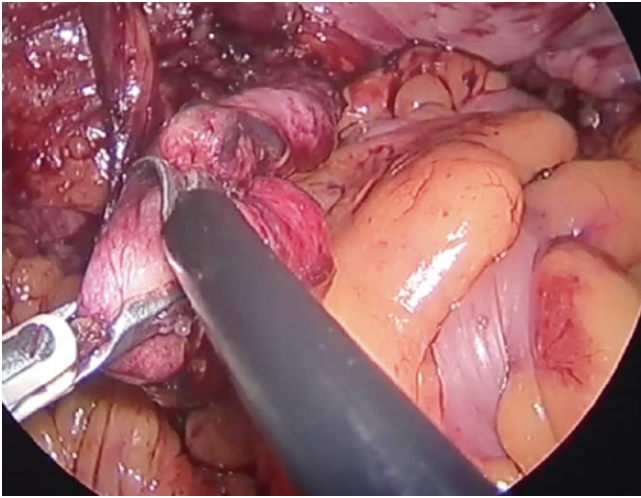


Fig. 39.45 Ureter being divided

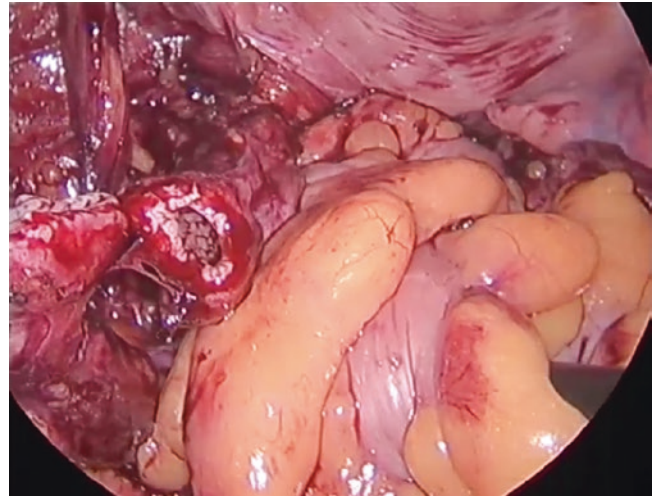


Fig. 39.46 Ureter divided

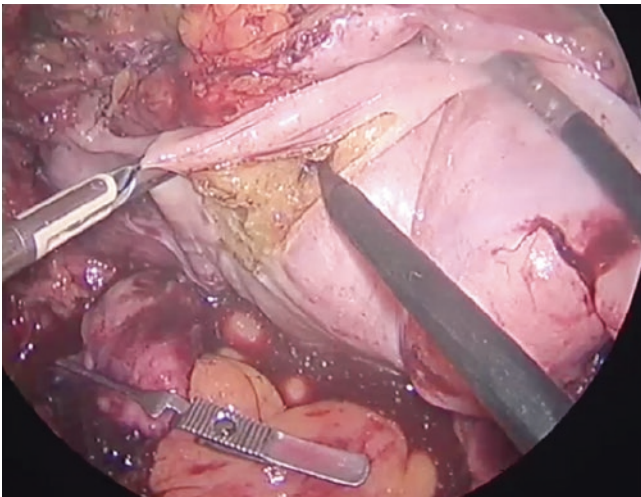


Fig. 39.47 Cystotomy in the lateral wall started

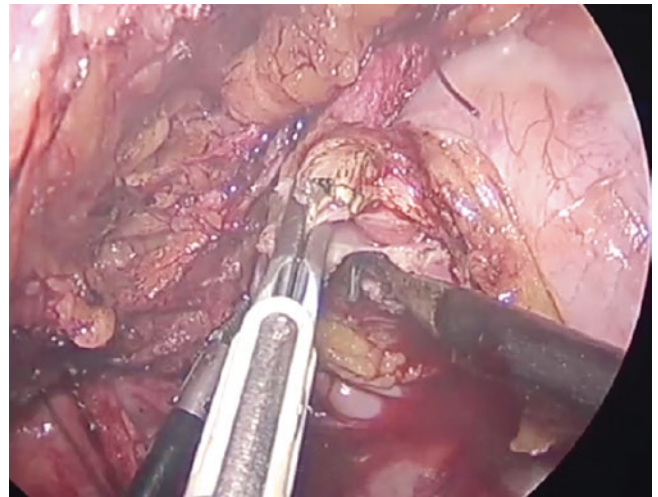


Fig. 39.48 Cystotomy in progress

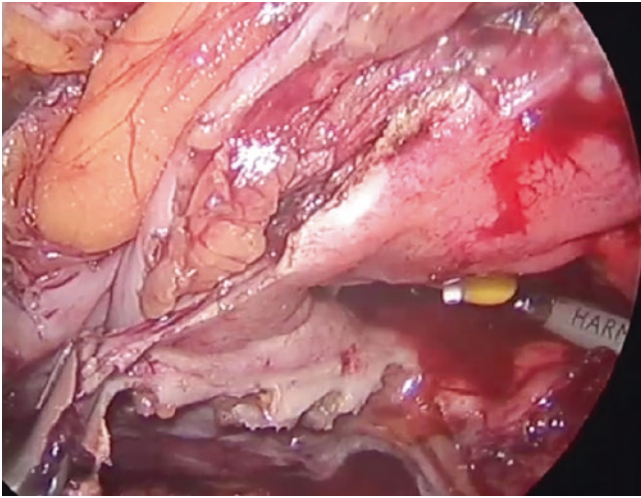


Fig. 39.49 Cystotomy completed

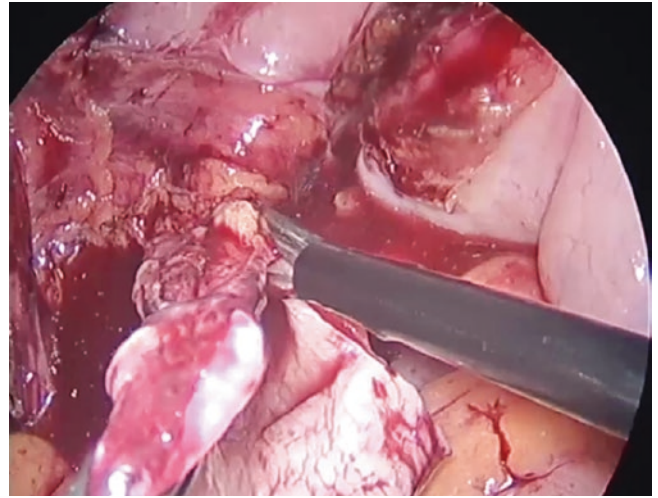


Fig. 39.50 Longitudinal ureterotomy in such a way to oppose cystotomy

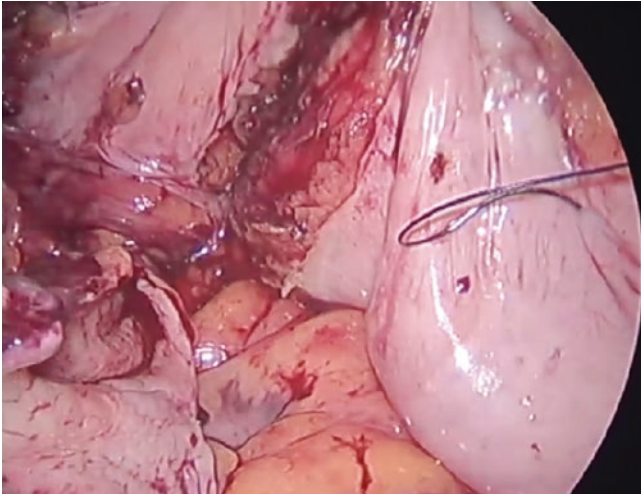


Fig. 39.51 Ureterotomy completed

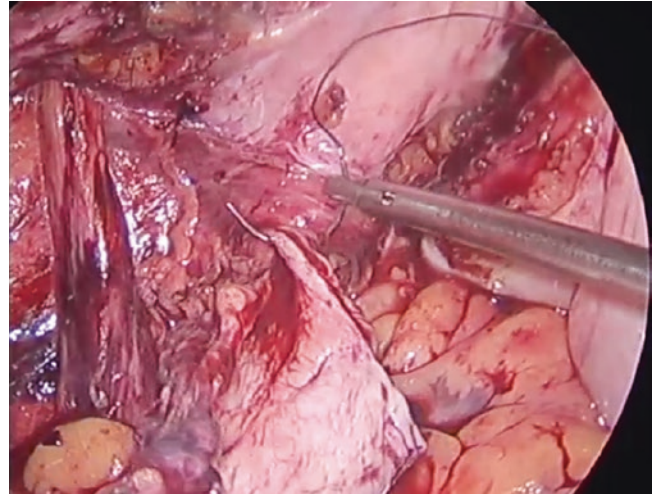


Fig. 39.52 Initial bite through apex of ureterotomy

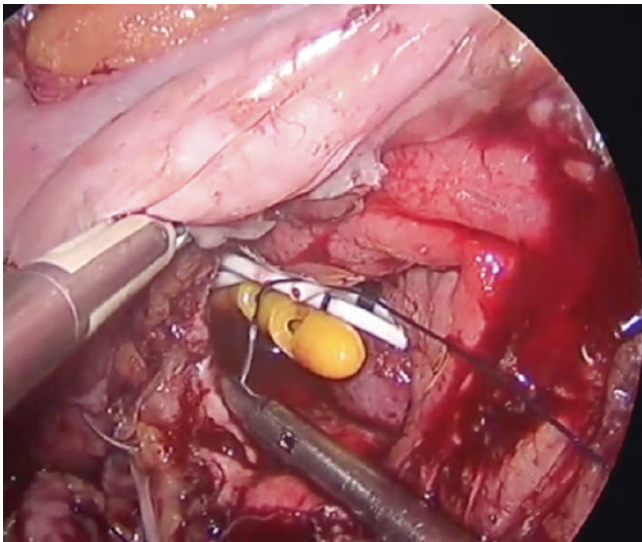


Fig. 39.53 Corresponding bite through apex of cystostomy

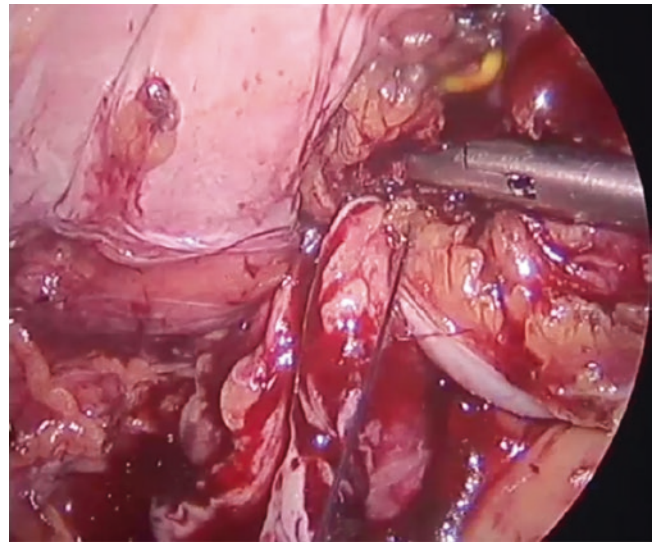


Fig. 39.54 Apical suture in place

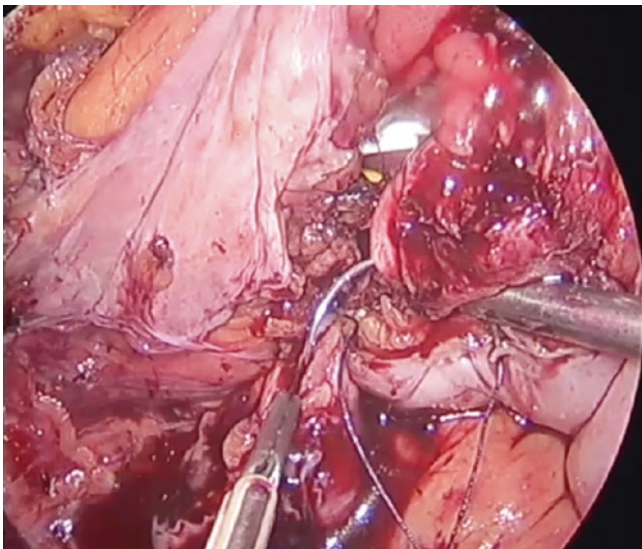


Fig. 39.55 Anterior layer suturing in progress

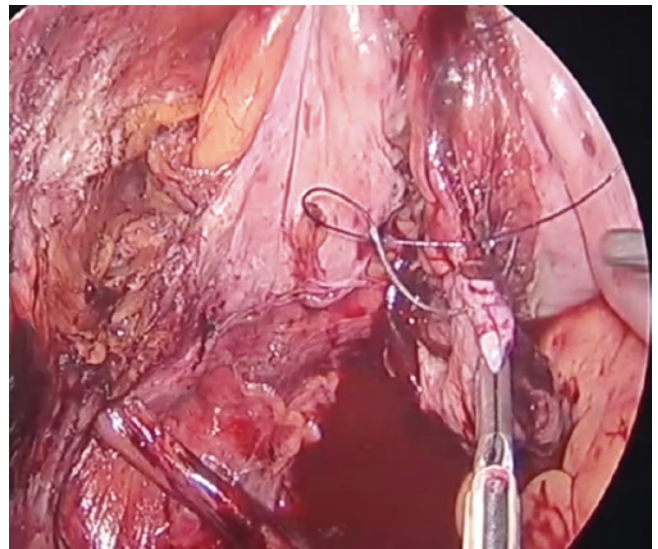


Fig. 39.56 Anterior layer suturing in progress

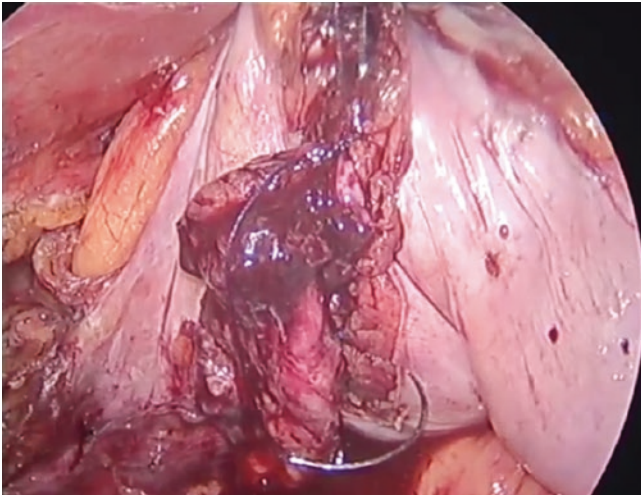


Fig. 39.57 Anterior layer completed

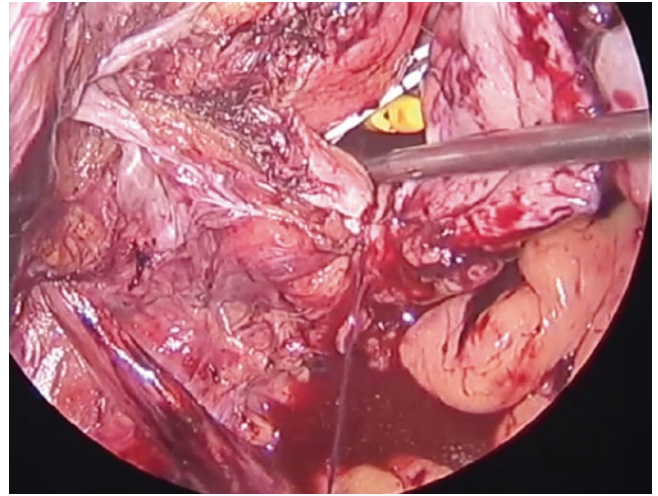


Fig. 39.58 Posterior layer started

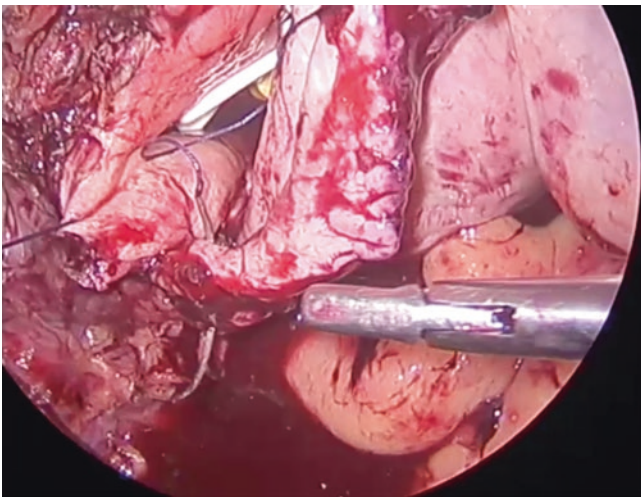


Fig. 39.59 Posterior layer in progress

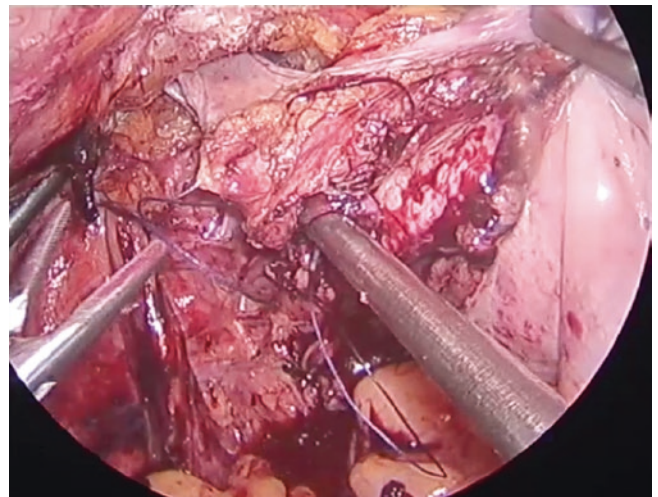


Fig. 39.60 Posterior layer in progress

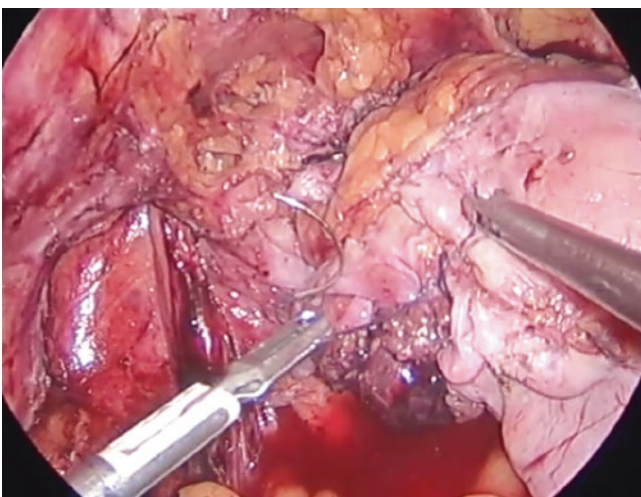


Fig. 39.61 Suturing completed

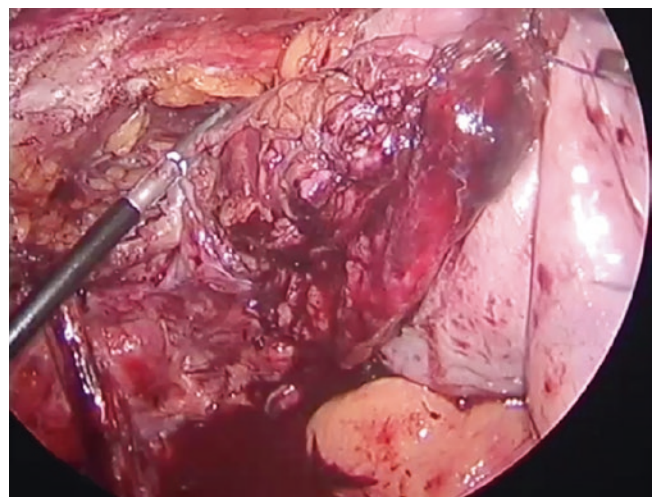


Fig. 39.62 Image of augmented ureter over bladder

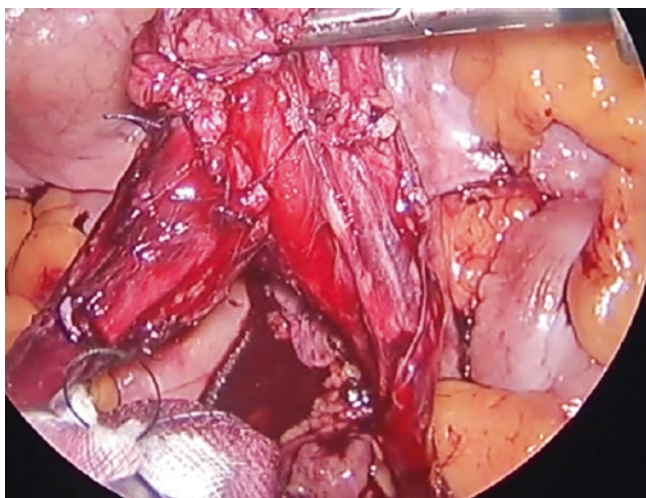


Fig. 39.63 Left (cut end) to right transureteroureterostomy done

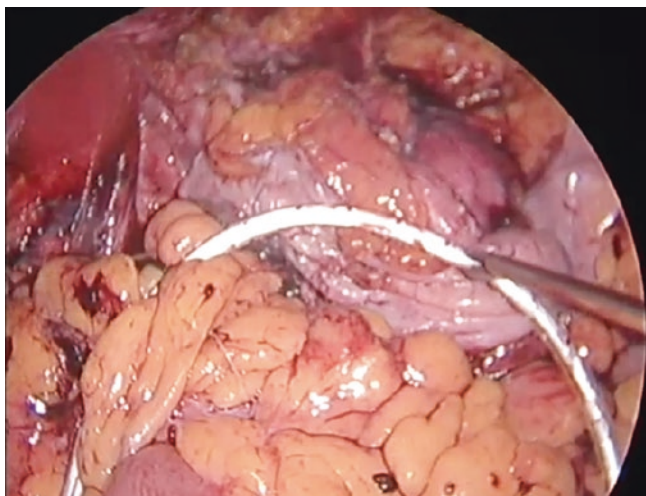


Fig. 39.64 Drain placed

References

1. Dewan PA, Anderson P. Ureterocystoplasty: the latest developments. *BJU Int.* 2001;8:744–51.
2. Desai MM, Gill IS, Goel M, et al. Ureteral tissue balloon expansion for laparoscopic bladder augmentation: survival study. *J Endourol.* 2003;17:283–93.
3. Moon D, Anderson PD, Dean PA. Ureterocystoplasty. New options. *Aust N Z J Surg.* 2001;71:189–92.
4. Provic SV, Vukadinovic VM, Djordjevic MLJ. Augmentation ureterocystoplasty could be performed more frequently. *J Urol.* 2000;164:924–7.
5. Ramalingam M, Senthil K, Pai MG, Balasubramanian R, Premkumar K. Laparoscopic ureterocystoplasty prior to kidney transplantation. *J Endourol.* 2008 Feb;22(2):321–5.
6. Ramalingam M, Senthil K, Selvarajan K, Pai MG. Laparoscopic ureterocystoplasty. *J Endourol.* 2005;19:A271.
7. Wolf Jr JS, Turzan CW. Augmentation ureterocystoplasty. *J Urol.* 1993;149:1095.

40.1 Introduction

Primary and secondary bladder diverticulae may be associated with bladder outlet obstruction like posterior urethral valve. In such patients with severe overactivity and poor compliance, diverticulum can be used for augmentation. This negates the use of bowel in the urinary tract [1, 2].

40.2 Technique

Under general anaesthesia, the child is placed in supine position with Trendelenberg tilt. Four ports are introduced (viz) 10 mm camera port 1 cm above umbilicus in the midline; two 5 mm ports 5 cm below and lateral to the camera port and a 10 mm port in the right iliac fossa in the anterior axillary line. In patients with Hutch diverticulum, ureters need to be dissected till the bladder to assess the need for reimplantation. If necessary, the ureters are divided. Transverse cystotomy is done superior to the diverticulum starting from the neck of diverticulum. The neck of the diverticulum is incised

for about half its circumference and the edges are excised. This helps in widening of the diverticulum. Cystoplasty is completed by suturing the diverticulum to the bladder using 3-0 polyglactin suture.

40.3 Discussion

Using bowels in the urinary tract of a child can cause problems in the long term.

Diverticulum does not cause problems of bowel augmentation like mucus secretion and electrolyte imbalances because of the urothelial lining.

40.4 Conclusion

Laparoscopic diverticulocystoplasty is a feasible option for patients with poorly compliant bladder with a large suitable diverticulum.

M. Ramalingam (✉)
PSG Hospitals,
Coimbatore, India
e-mail: uroram@yahoo.com

K. Senthil, MCh (Urol., FRCS)
Urology Clinic, Coimbatore, India
e-mail: senthilsatya@hotmail.com

40.5 Laparoscopic Diverticuloplasty

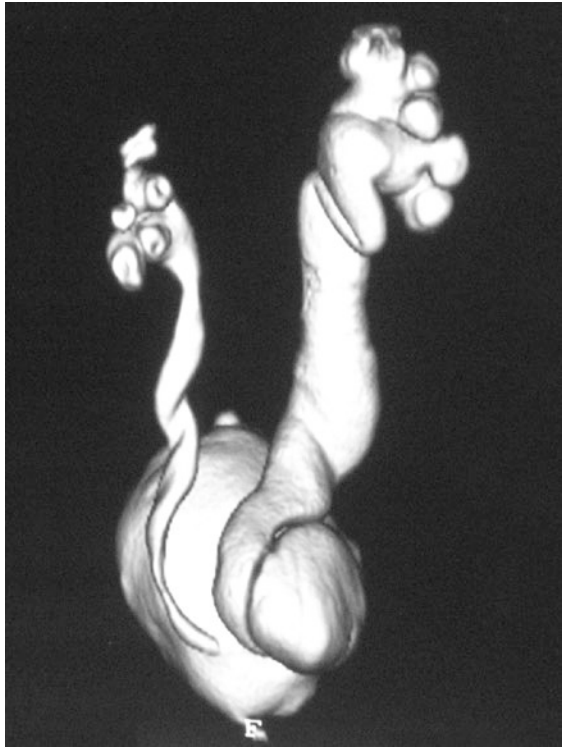

Fig. 40.1 CT cystogram showing a large diverticulum with right megaureter in a 9 years old male child

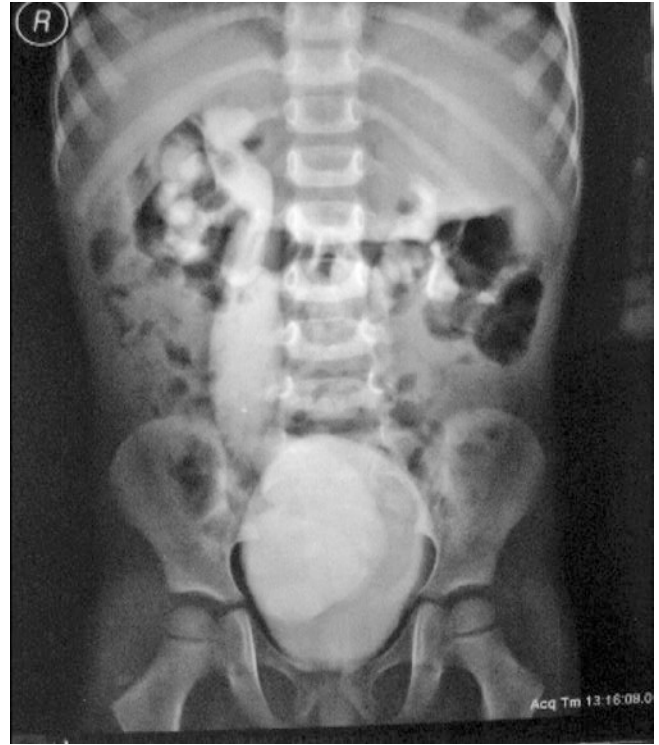

Fig. 40.2 IVU showing lower ureteric obstruction and a large diverticulum

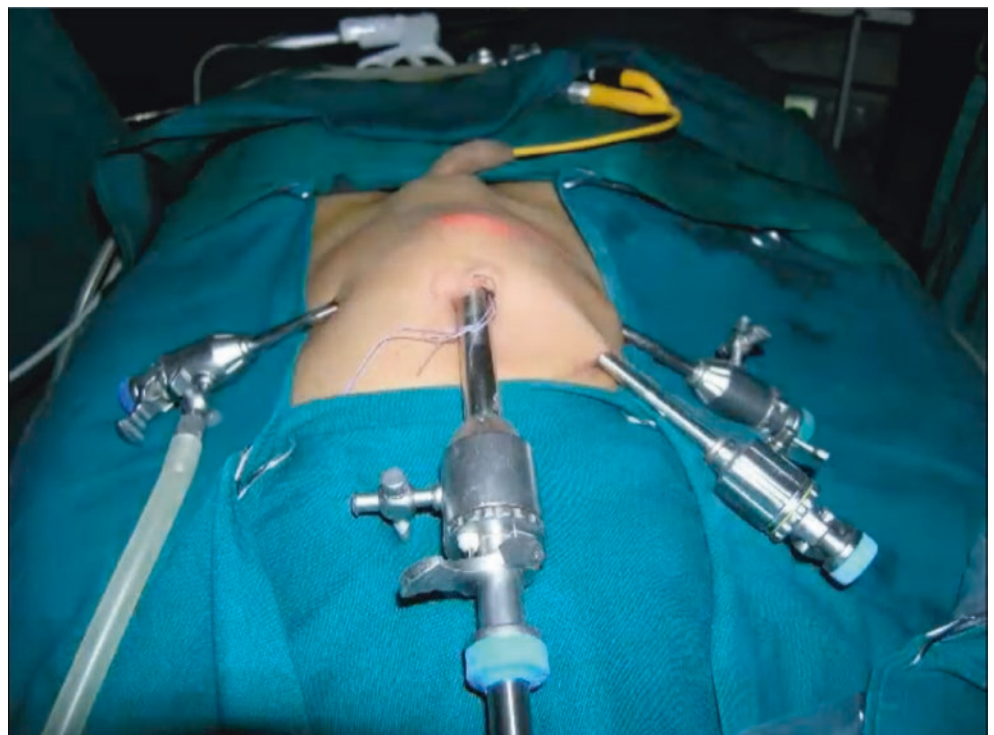

Fig. 40.3 Port position

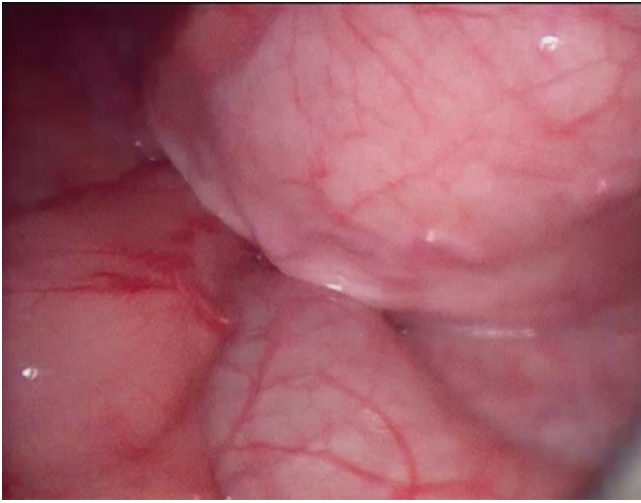


Fig. 40.4 Initial view showing obstructed right lower ureter and large paraureteral diverticulum

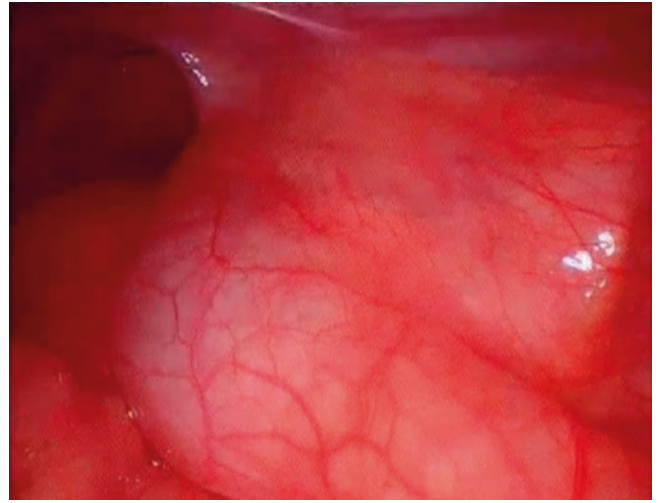


Fig. 40.5 Dilated right ureter is seen

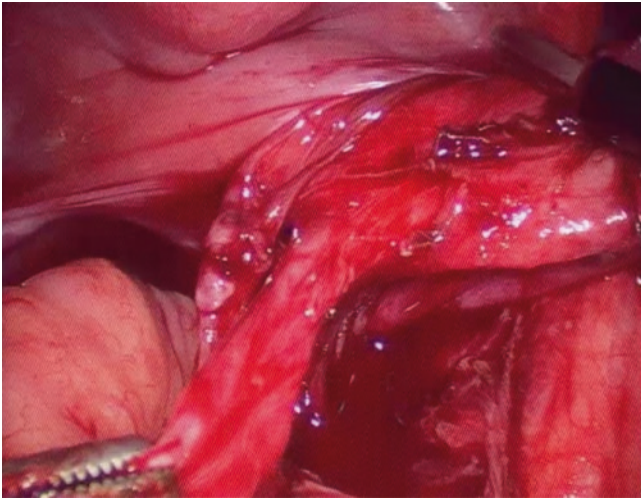


Fig. 40.6 Ureter dissected and is seen entering neck of diverticulum

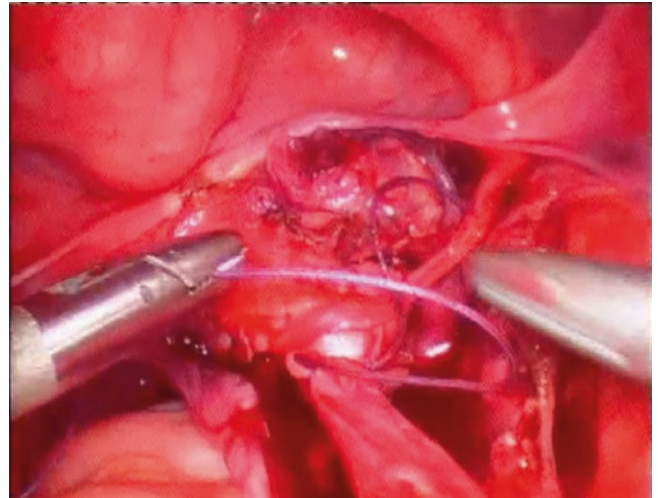


Fig. 40.7 Ureter entering diverticulum; ligated and cut

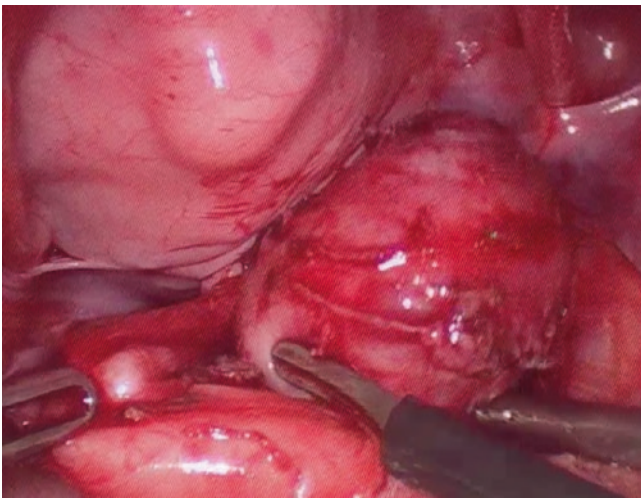


Fig. 40.8 Diverticulum dissected all around

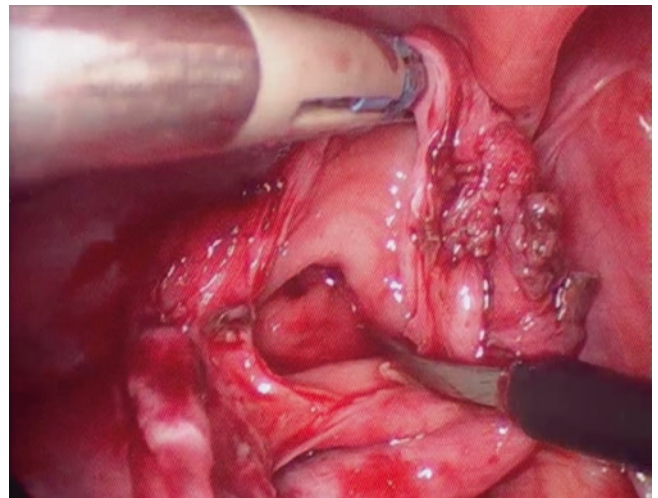


Fig. 40.9 Diverticulum opened near dome

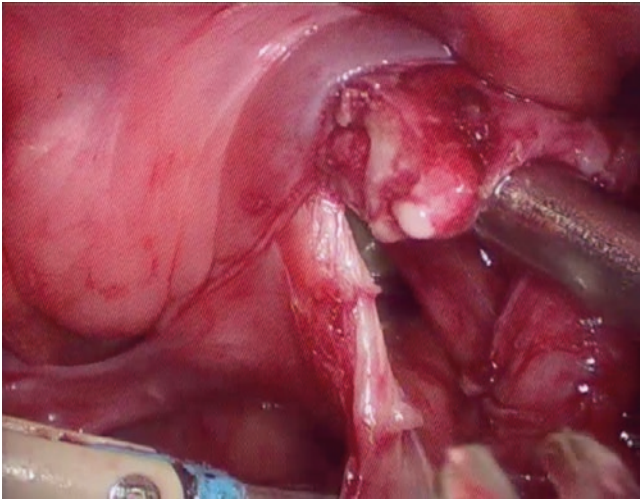


Fig. 40.10 Diverticulum neck opened

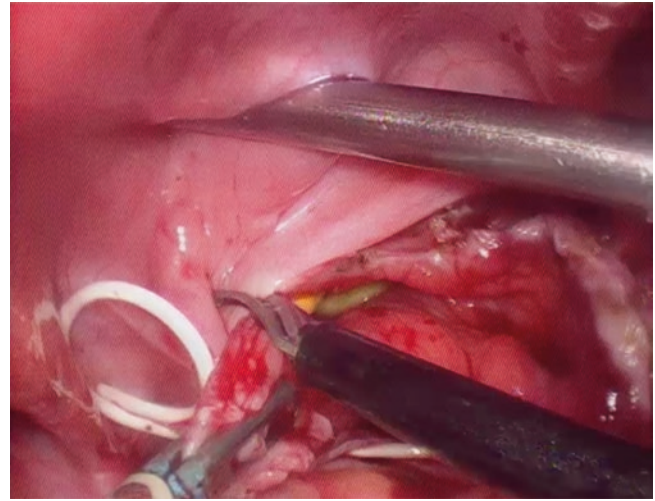


Fig. 40.11 Transverse cystotomy from neck of diverticulum

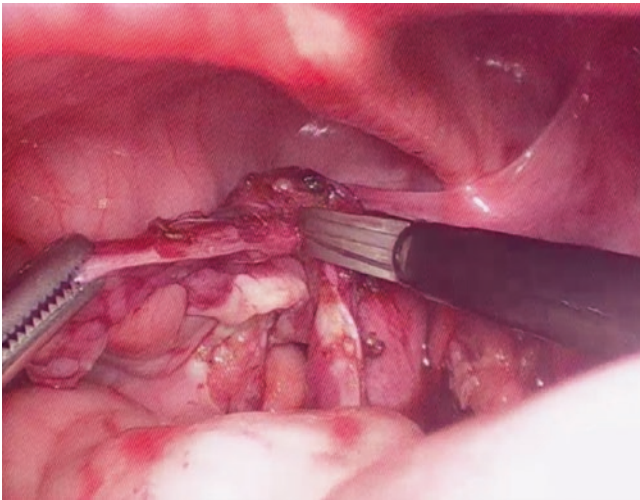


Fig. 40.12 Diverticulum opened as V and flap created

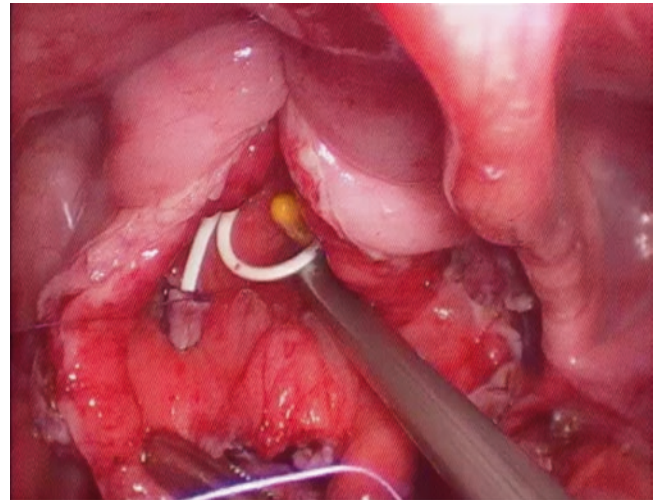


Fig. 40.13 Cystotomy completed. RT ureteric reimplantation in progress (Politano Leadbetter technique)

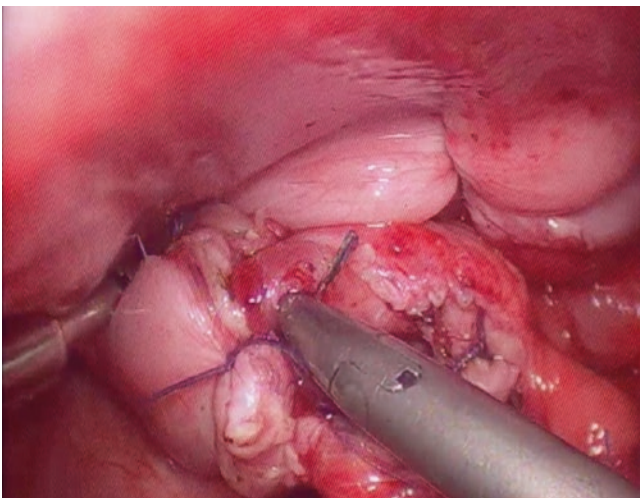


Fig. 40.14 Augmentation with diverticulum using 3-0 interrupted vicryl sutures started

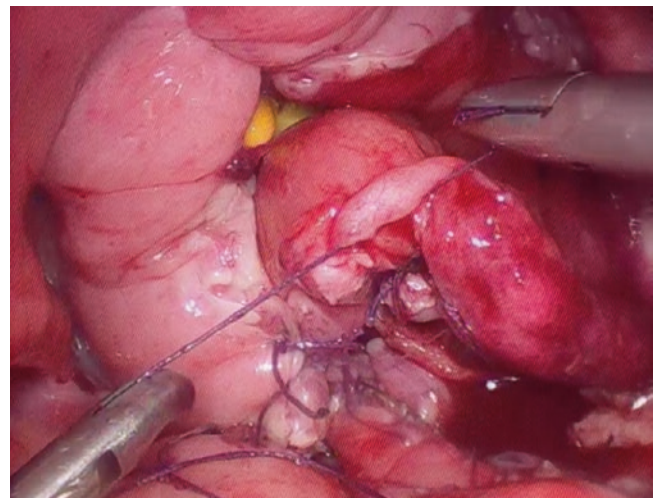


Fig. 40.15 Augmentation in progress

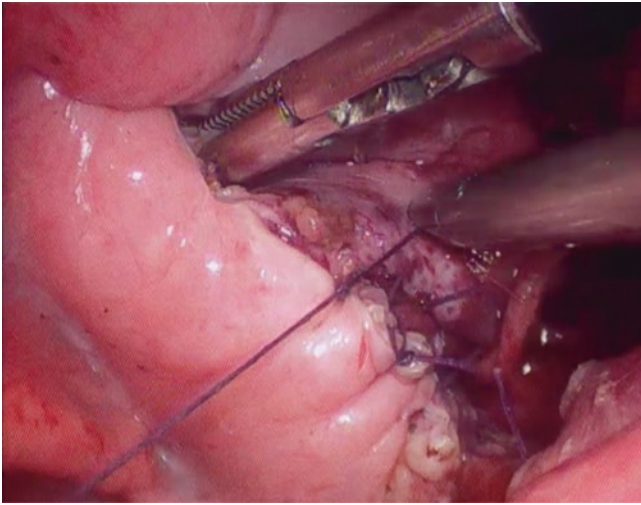


Fig. 40.16 Augmentation in progress

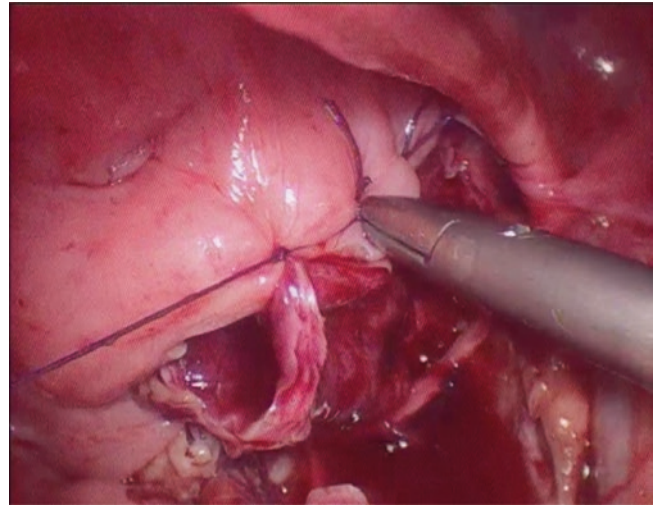


Fig. 40.17 Augmentation in progress

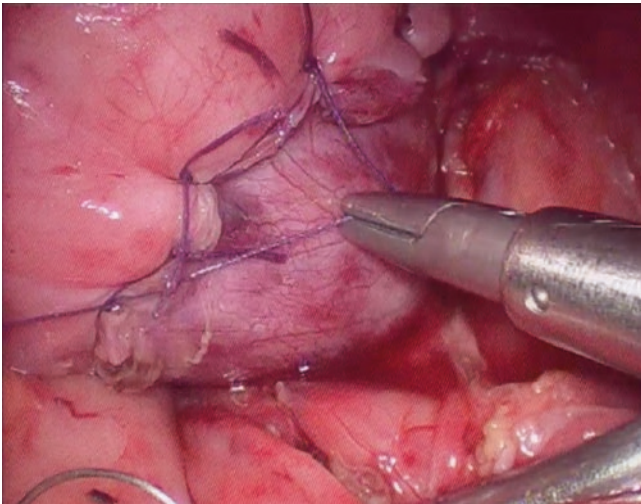


Fig. 40.18 Completed augmentation

References

1. Tabibi A, Nouralizadeh A. Diverticulocystoplasty in a case with decreased bladder capacity. *Urol J.* 2004;1(2):121–2.
2. Ramalingam M, Senthil K, Murugesan A, Pai MG. Laparoscopic diverticulocystoplasty for low compliance bladder in a child. *JSL.S.* 2012;16(3):498–502.

Manickam Ramalingam, Kallappan Senthil,
Anandan Murugesan, and T.S. Balashanmugam

41.1 Introduction

Ileal augmentation of the bladder is indicated in small poorly compliant bladder with or without refractory overactivity [1, 2]. However in patients with renal failure, with a serum creatinine greater than 2 mg/dl, use of ileum can result in worsening of acidosis and renal failure. Hence the use of a stomach flap is one of the options when a dilated ureter is not available to do ureterocystoplasty [3].

41.2 Technique

Under general anesthesia the patient is placed in reverse Trendelenberg position. Naso-gastric tube is placed. Five ports are inserted initially to isolate a gastric flap based on the right gastroepiploic artery. One 10 mm and 15 mm port each and three 5 mm ports are inserted. 10 mm port inserted in the supraumbilical region is used for the camera. Fifteen millimeter port is used for stapler.

Using ultrasonic shears a window is created in the middle of the greater curvature to insert the GIA stapling device. Five 60 mm stapler cartridges are used to fashion the gastric flap along the greater curvature almost up to the fundus. Thereby, a wide gastric tube of about 25 cm long is isolated based on the

right gastroepiploic artery along with the adjoining omentum. The isolated segment is narrow at the pyloric end (2 cm wide) and wider at the fundal end (5 cm). This segment is flipped down towards the pelvis. Subsequently, the patient is placed in Trendelenberg position. Two more trocars are inserted in the suprapubic area and left flank in order to approach the bladder. Bladder is opened vertically. The staples on gastric flap are excised. If there is associated ureteric stricture, the narrow end of the gastric flap is tubularised and sutured to the spatulated ureter. The flap is tubularised till it reached the bladder. Once the bladder is reached the gastric flap is sutured to the vertically opened bladder using 3-0 vicryl forming a patch to augment the bladder. If the ureters are normal, the gastric flap is sutured directly to the opened bladder similar to ileocystoplasty. A 22 Fr 3 way Foley catheter is placed in the bladder. Drain is placed in the pelvis and the port sites are closed.

41.3 Discussion

Gastrocystoplasty is mainly indicated in those with renal failure. The main complication is hematuria dysuria syndrome, which can be very distressing to the patients. This is due to acidic urine irritating the bladder and urethral mucosa. Excess use of antral tissue might increase the incidence of dyspeptic symptoms, due to loss of negative feedback on gastrin release. Patient needs to take antacids and H2 blockers for few months to even few years.

41.4 Conclusion

Gastrocystoplasty is a useful option for augmentation of bladder in specific indications like renal failure and short bowel. Laparoscopic approach is a feasible and less morbid option for performing gastrocystoplasty. Short-term benefits appear to be good in adults. Long term and large studies in adults are awaited [4]. Close periodic follow-up for early detection of metabolic changes, and pathological changes in the gastric flap would be mandatory.

M. Ramalingam (✉)
PSG Hospitals,
Coimbatore, India
e-mail: uroram@yahoo.com

K. Senthil, MCh (Urol., FRCS) (✉)
Urology clinic, Gowtham annexe, Coimbatore, India
e-mail: senthilsatya@hotmail.com

A. Murugesan, MBBS, MS, MCh
Department of Urology, PSG Institute of Medical Sciences
and Research, Peelamedu, Coimbatore, Tamil Nadu, India
e-mail: anandan79@gmail.com

T.S. Balashanmugam
Department of the General Surgery, PSG Hospitals,
Peelamedu/Coimbatore, Tamil Nadu 641004, India

41.5 Laparoscopic Gastrocystoplasty

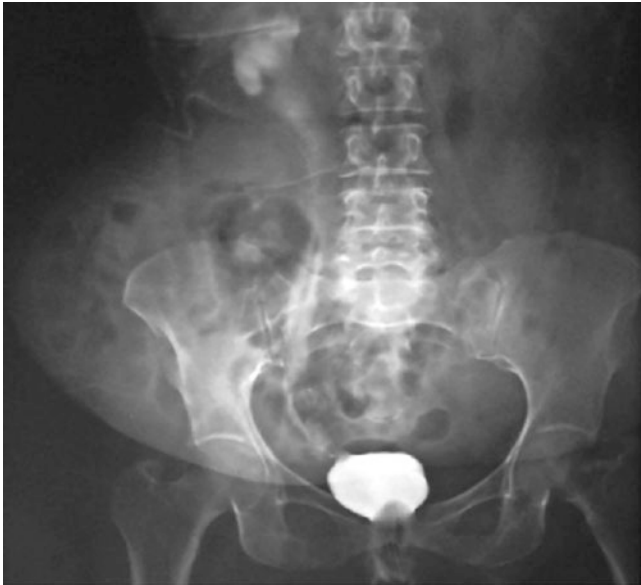

Fig. 41.1 Nephrostogram showing distal ureteric stricture with thin bladder in a single functioning kidney with renal failure (left nephrectomy done for TB pyonephrosis)

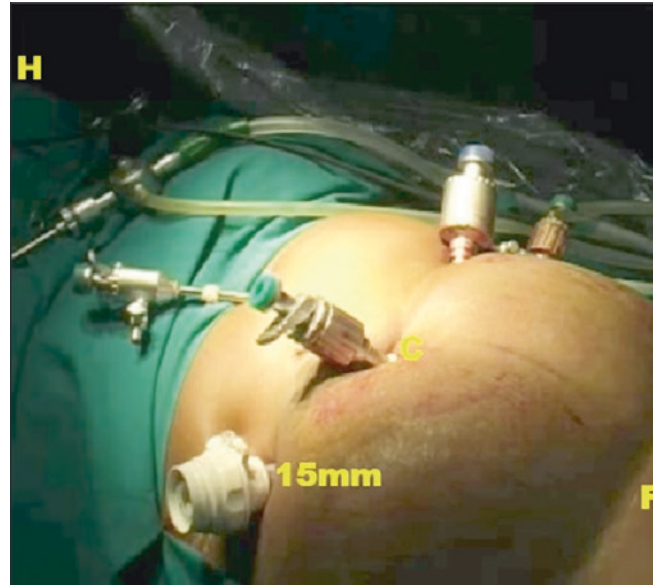


Fig. 41.2 Ports position as seen from foot end. C – camera port, 15 mm port for stapler

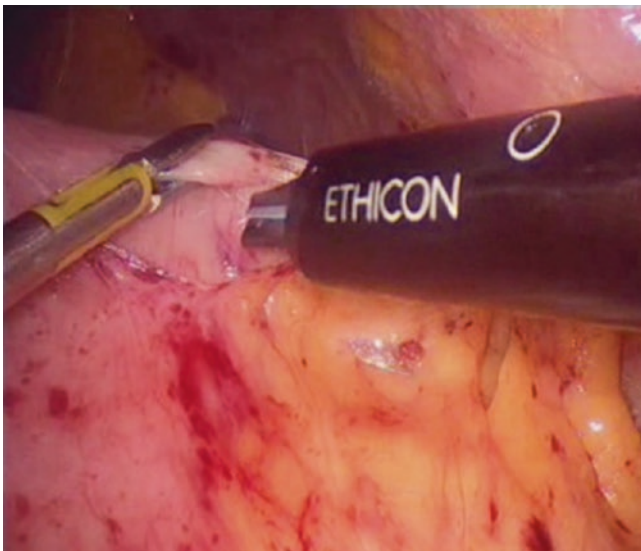


Fig. 41.3 Omentum divided from greater curvature preserving gastroepiploic arcade

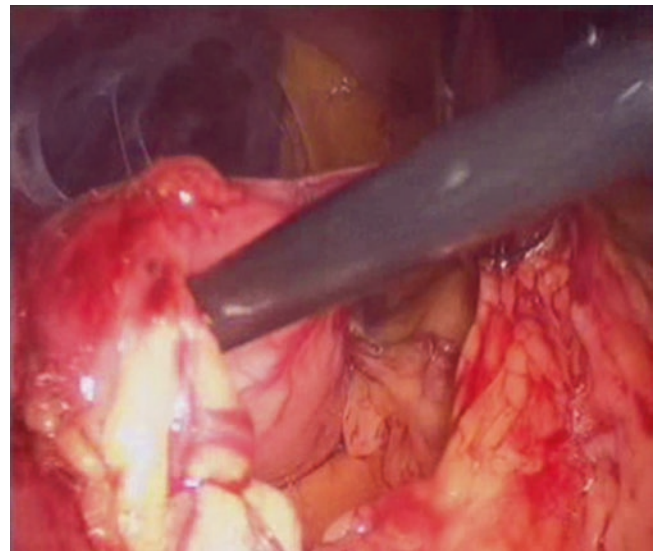


Fig. 41.4 Lesser sac space developed

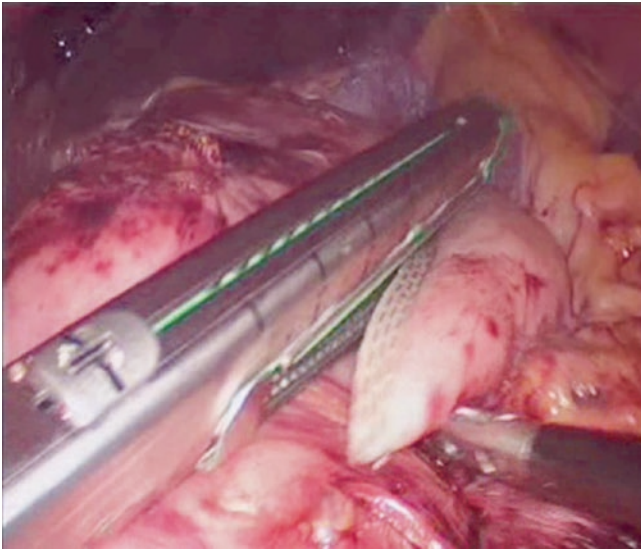


Fig. 41.5 Staplers (five or six may be needed) for isolating gastric flap based on right gastroepiploic artery

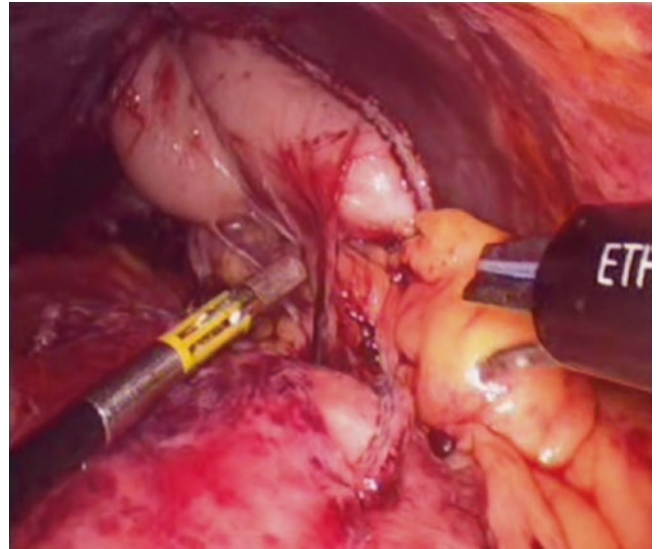


Fig. 41.6 Gastric flap developed

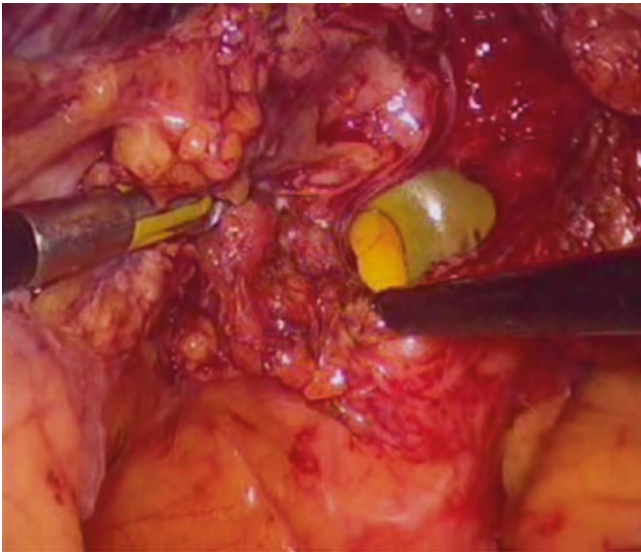


Fig. 41.7 Vertical cystotomy done after adding one more port in LIF (surgeon moves to left side of patient and foot end elevated)

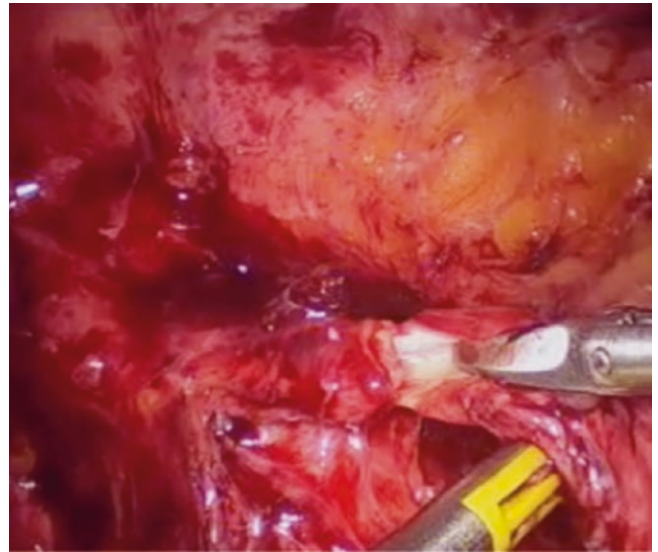


Fig. 41.8 Ureter being divided just above the level of stricture

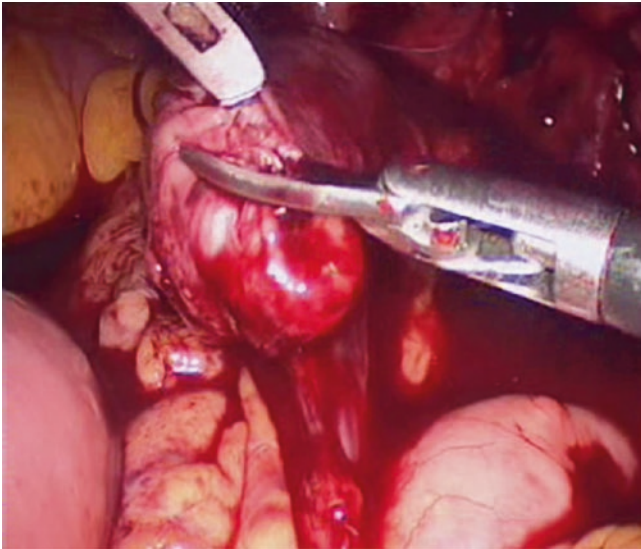


Fig. 41.9 After flipping (cranial to caudal end) the gastric flap, staple line being excised

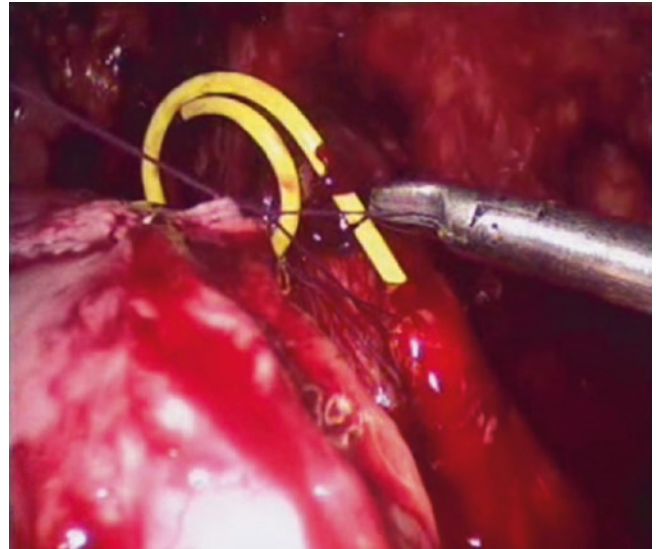


Fig. 41.10 Ureter anastomosed to narrow end of gastric flap

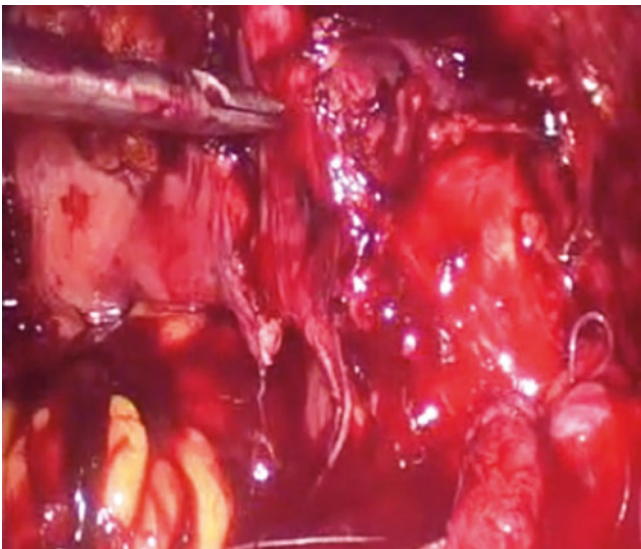


Fig. 41.11 Uretero gastric anastomosis complete

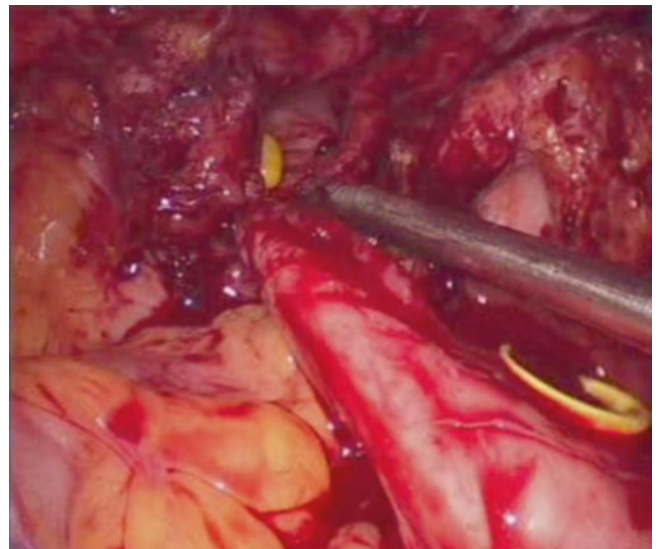


Fig. 41.12 Bladder augmentation with broader end of gastric flap using 2-0 vicryl interrupted sutures

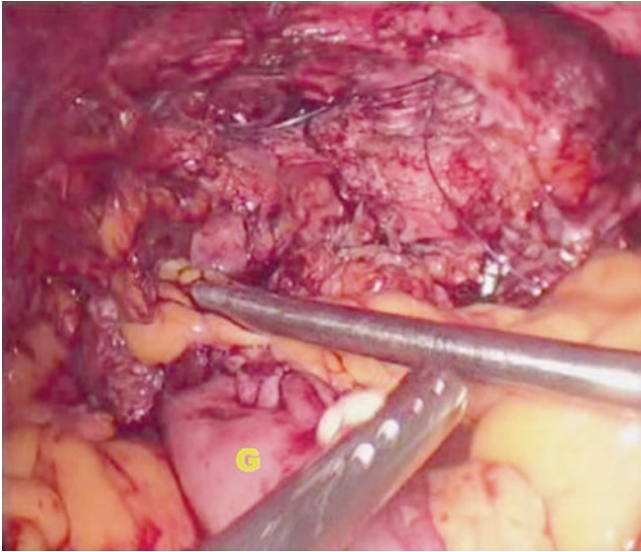


Fig. 41.13 Completed augmentation. Omentum tacked to suture line.
G gastric flap

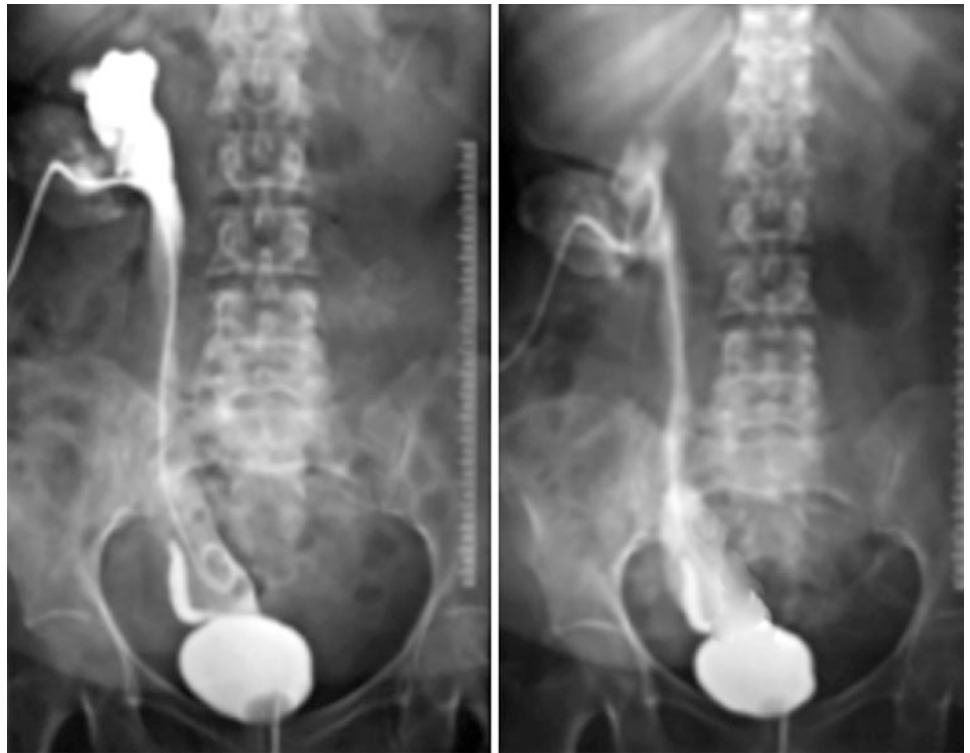

Fig. 41.14 MCU 3 months post gastrocystoplasty showing augmented bladder

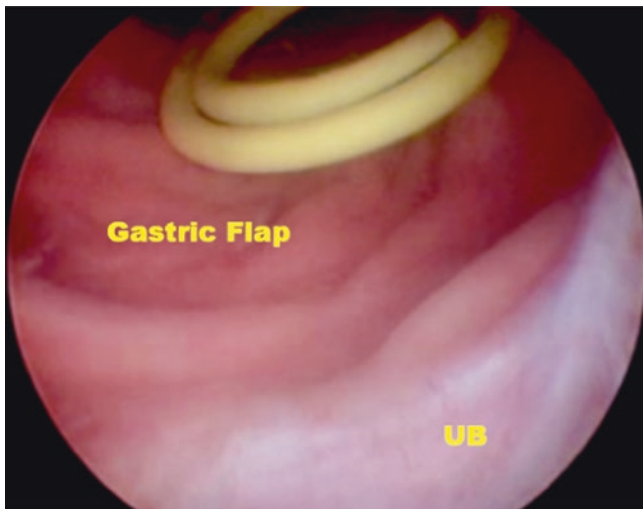


Fig. 41.15 3 months post operative – cystoscopic view showing gastric flap-augmented bladder

References

1. Veeratterapillay R, Thorpe AC, Harding C. Augmentation cystoplasty: contemporary indications, techniques and complications. *Indian J Urol.* 2013;29(4):322–7. doi:[10.4103/0970-1591.120114](https://doi.org/10.4103/0970-1591.120114).
2. Biers SM, Venn SN, Greenwell TJ. The past, present and future of augmentation cystoplasty. *BJU Int.* 2012;109(9):1280–93.
3. Carr MC, Mitchell ME. Gastrocystoplasty. *Sci World J.* 2004;4 Suppl 1:48–55.
4. Docimo SG, Moore RG, Adams J, Kavoussi LR. Laparoscopic bladder augmentation using stomach. *Urology.* 1995;46(4):565–9.

Manickam Ramalingam, K. Selvarajan,
and Kallappan Senthil

42.1 Introduction

Colovesical fistulae are uncommon complications of complex pelvic surgery, colonic diverticular disease or malignancy [1, 2]. The clinical presentation usually is storage lower urinary tract symptoms and pneumaturia. Evaluation includes CT cystography, cystoscopy and colonoscopy. Management is disconnection of fistula and treating underlying cause by open surgery or laparoscopy.

42.2 Surgical Technique

Patient is positioned in lithotomy for marking the area to be excised using cystoscopy. Using four ports (supra umbilical camera port, two midclavicular ports 5 cm below and lateral

to umbilicus and a flank port for suction cum irrigation) the site of fistula is inspected. Intraoperative colonoscopy is a useful guide.

The segment of colon adherent to bladder is disconnected, and the edges of bowel and bladder defects are trimmed. The defect in the bowel and bladder are closed with 2-0 or 3-0 interrupted vicryl sutures one after another. Omentum can be tacked over the area of cystorrhaphy. Ports are closed after leaving a tube drain. Bladder is drained with an optimum sized foley catheter for a week.

42.3 Comment

Laparoscopic repair for benign colovesical fistulae is a safe, effective and less morbid procedure.

M. Ramalingam (✉)
PSG Hospitals,
Coimbatore, India
e-mail: uroram@yahoo.com

K. Selvarajan, MCh
Paediatric Surgery, K.G. Hospital and Postgraduate Institute,
Coimbatore, India

K. Senthil, MCh (Urol., FRCS)
Urology clinic, Gowtham Annexe, Coimbatore, India
e-mail: senthilsatya@hotmail.com

42.4 Laparoscopic Repair of Colovesical Fistula

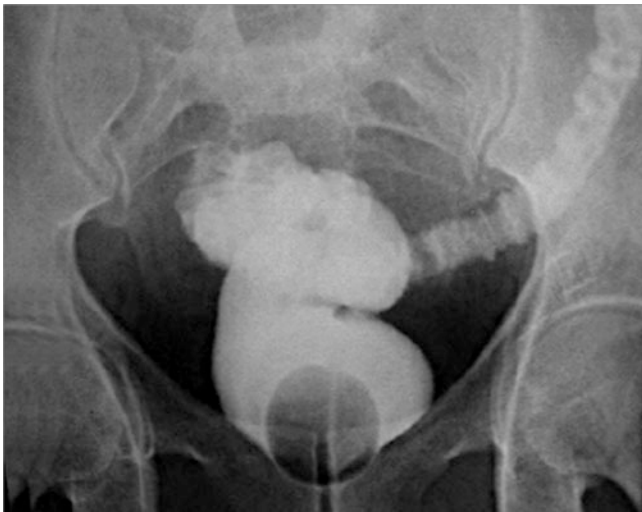


Fig. 42.1 Cystogram showing the fistulous communication with colon

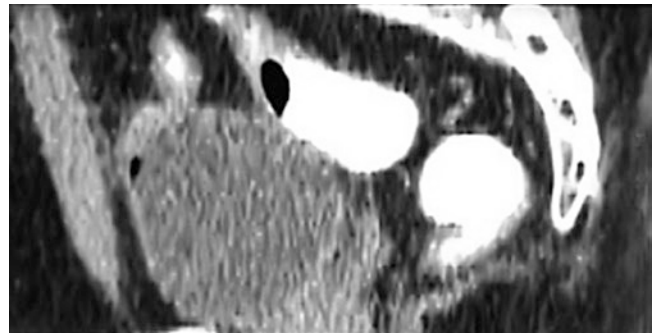


Fig. 42.2 CT image showing colovesical fistula (air and debris in bladder)

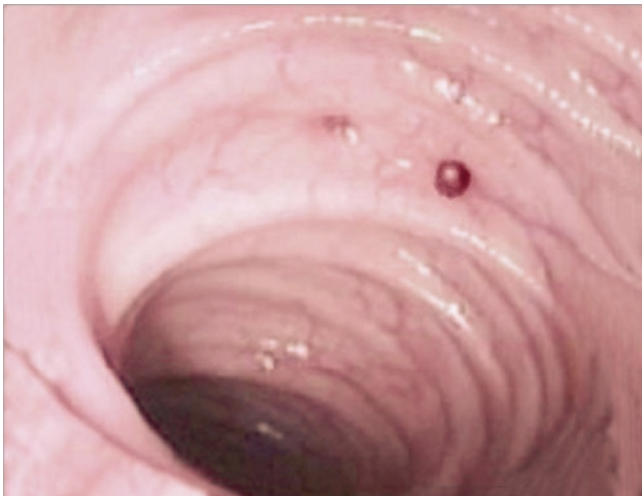

Fig. 42.3 Colonoscopic image showing fistula (multiple small sigmoid diverticulæ seen)

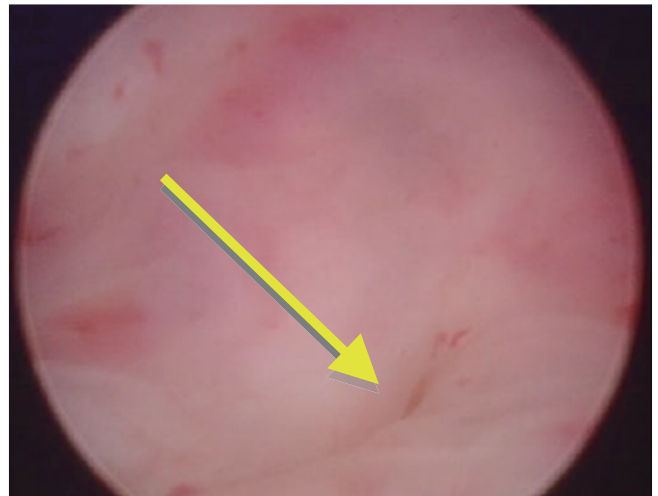


Fig. 42.4 Cystoscopic view of fistula near the fundus

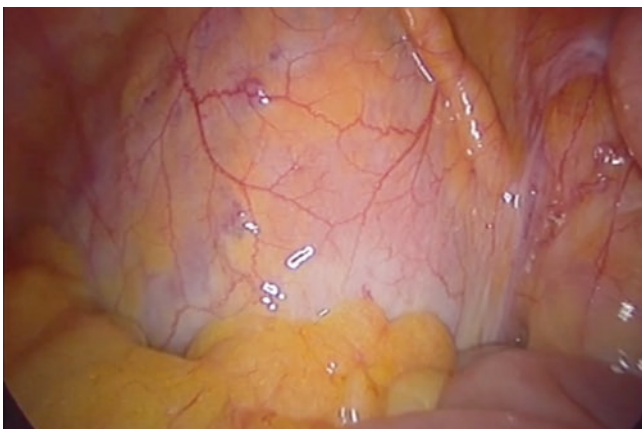


Fig. 42.5 Initial view with distended bladder

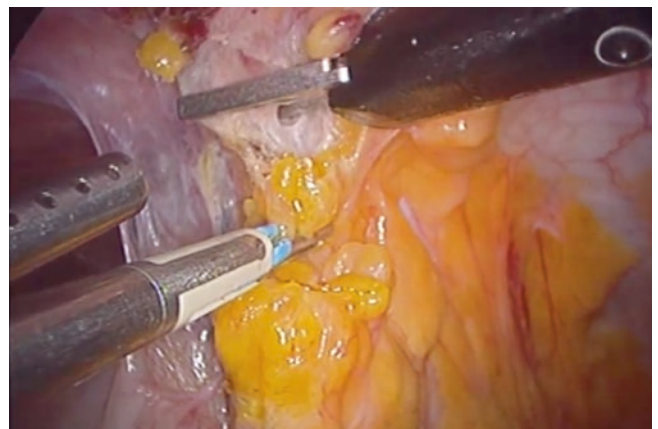

Fig. 42.6 Adhesiolysis

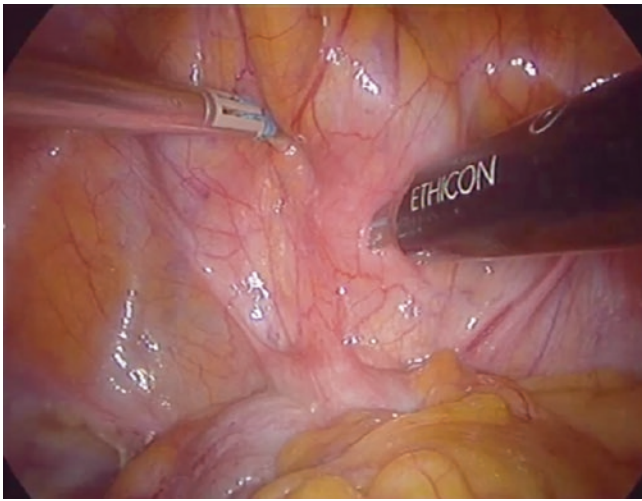


Fig. 42.7 Sigmoid colon adherent to bladder

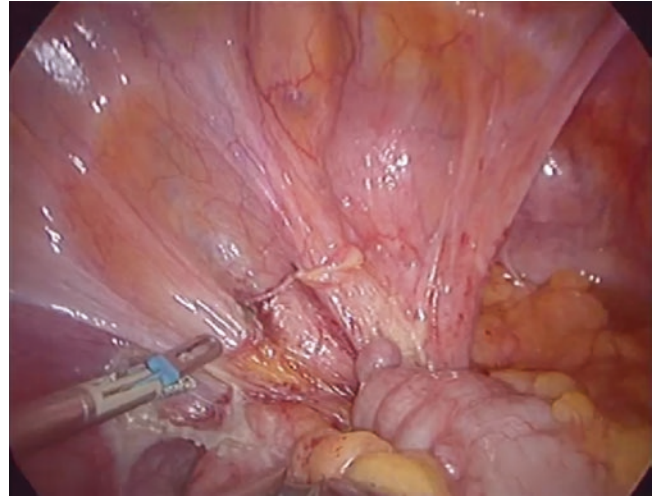


Fig. 42.8 Colon dissected away from bladder

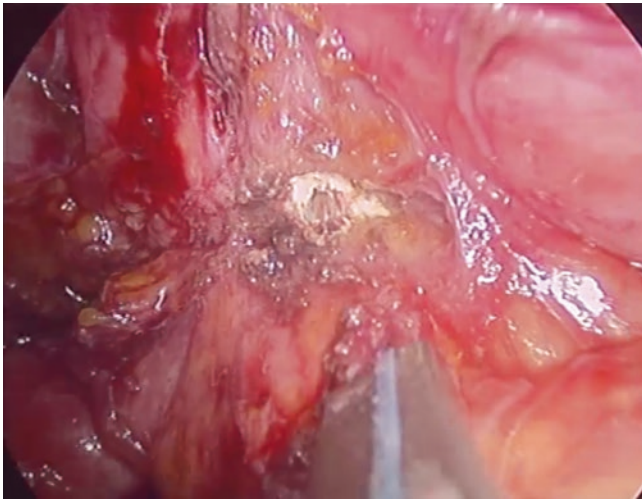


Fig. 42.9 Dissection of bladder from colon in progress

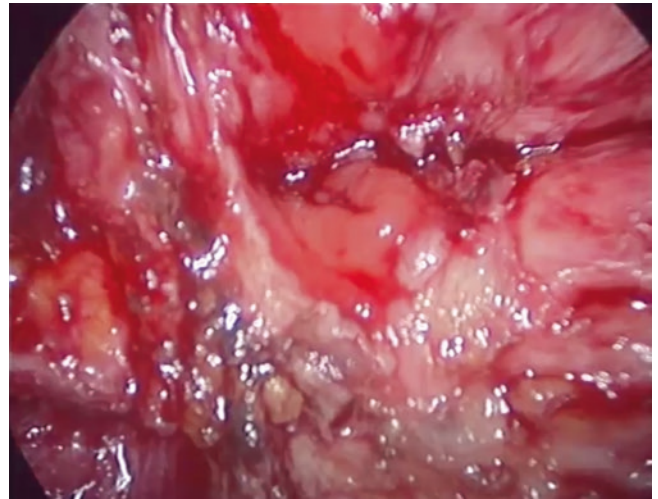


Fig. 42.10 Dissection between bladder and sigmoid colon reveals fistula

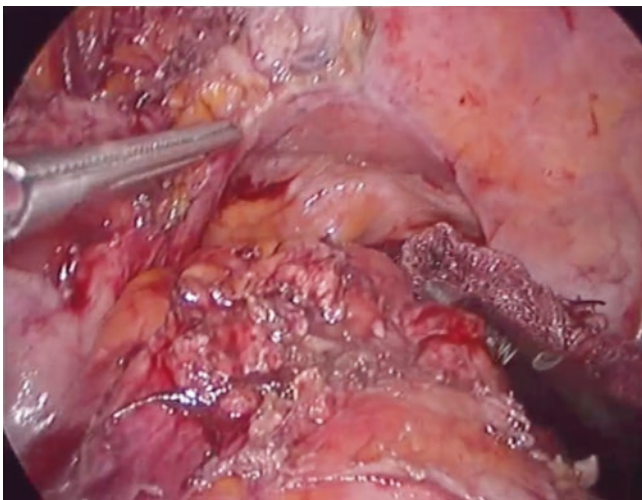


Fig. 42.11 Fistula completely disconnected

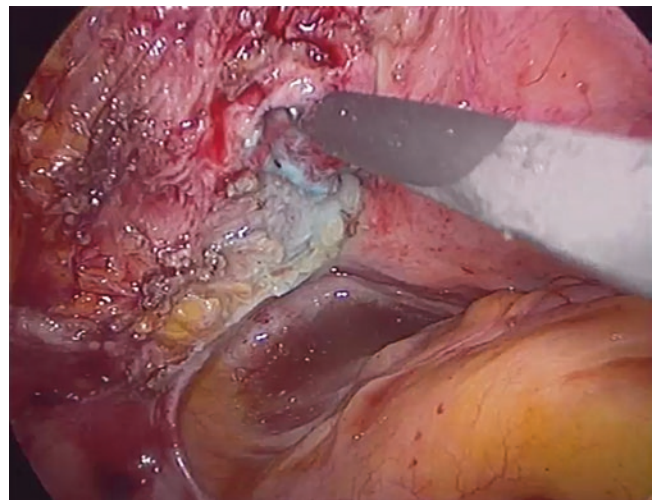


Fig. 42.12 Bladder end of fistula confirmed with methylene blue instillation into bladder

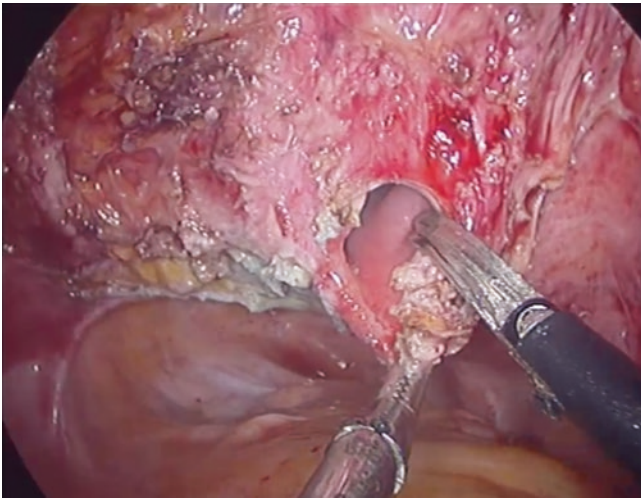


Fig. 42.13 Fistula margin excised from bladder end

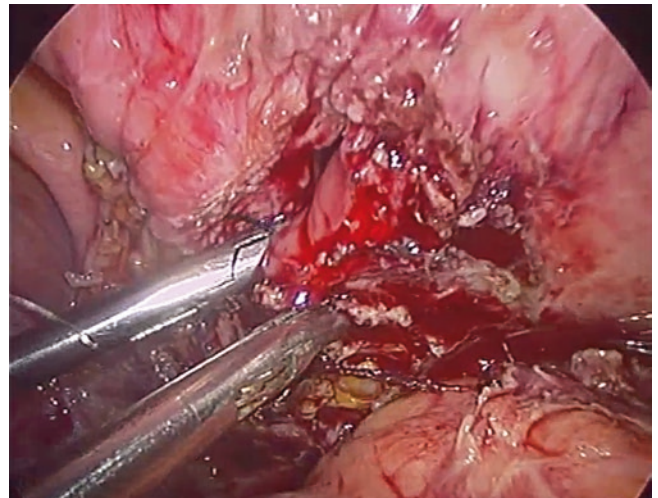


Fig. 42.14 Bladder rent closure with 3-0 vicryl started

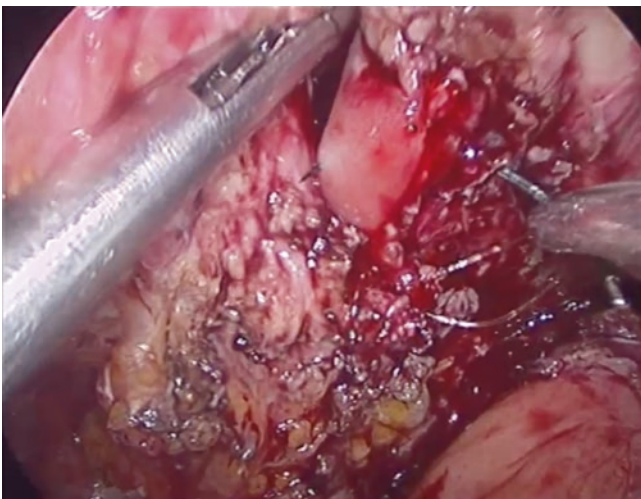


Fig. 42.15 Bladder closure with interrupted suture

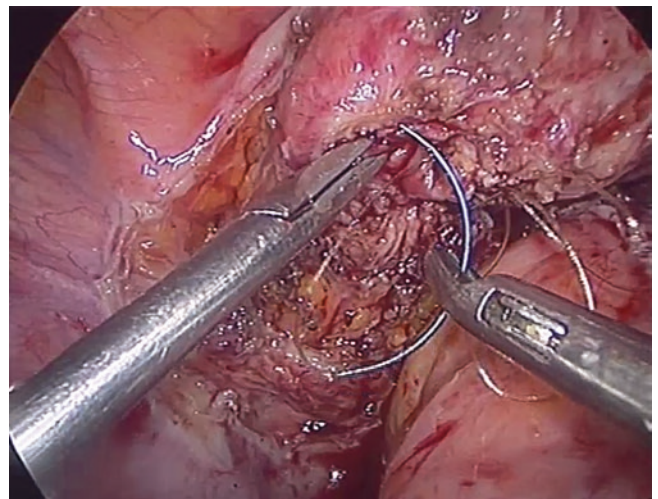


Fig. 42.16 Bladder closure in progress

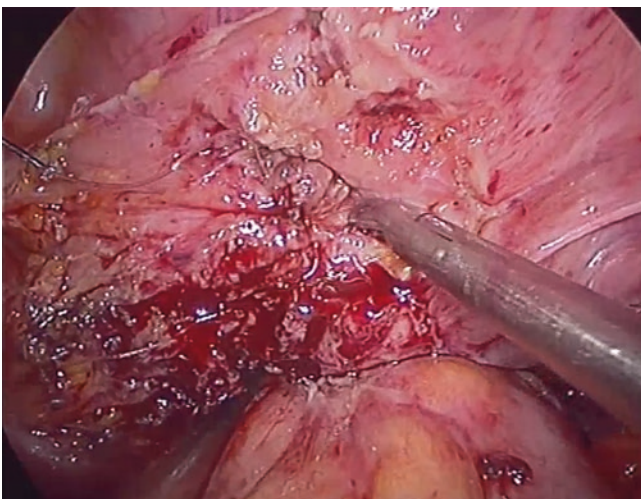


Fig. 42.17 First layer closure completed

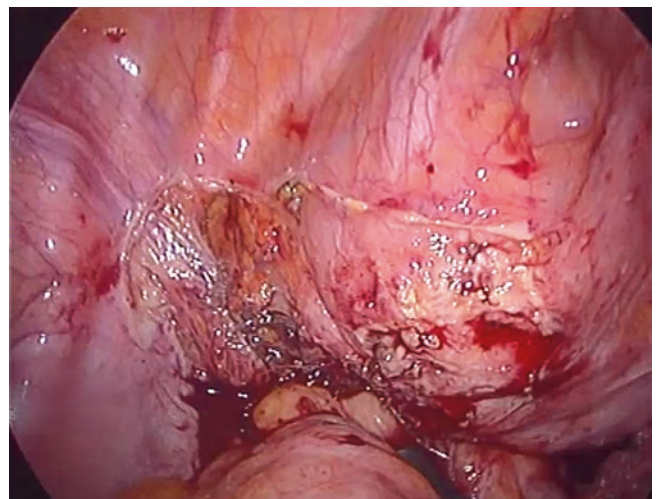


Fig. 42.18 No leak on distending bladder

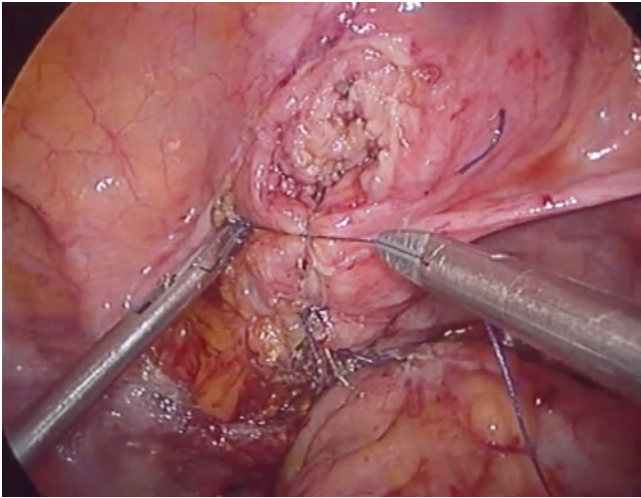


Fig. 42.19 Second layer closure in progress

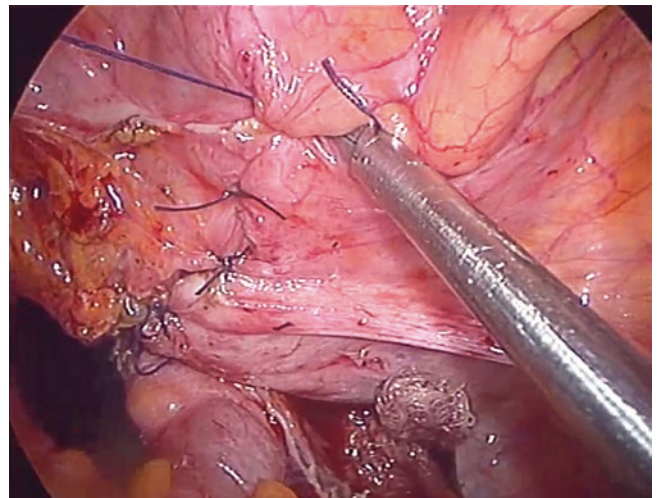


Fig. 42.20 Bladder closure completed

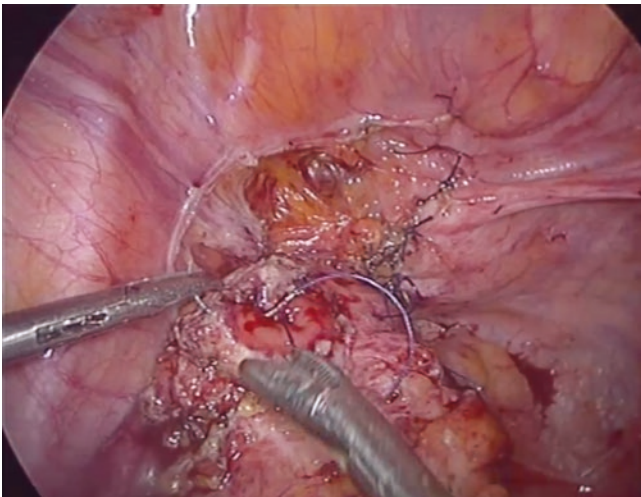


Fig. 42.21 Colonic rent closure with 3-0 vicryl started

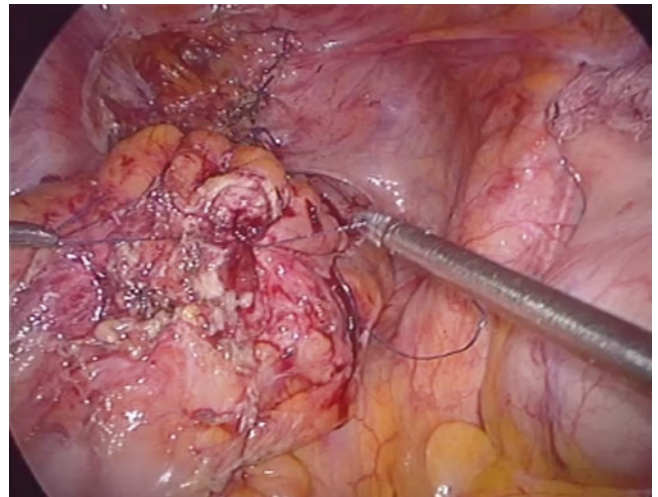


Fig. 42.22 Interrupted suture in progress

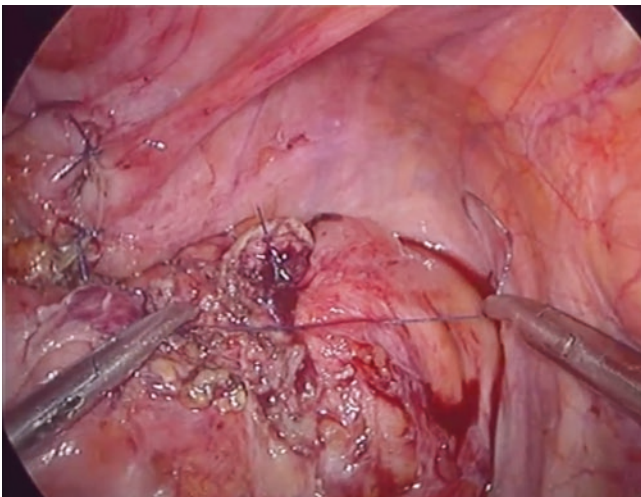


Fig. 42.23 Colonic rent closure in progress

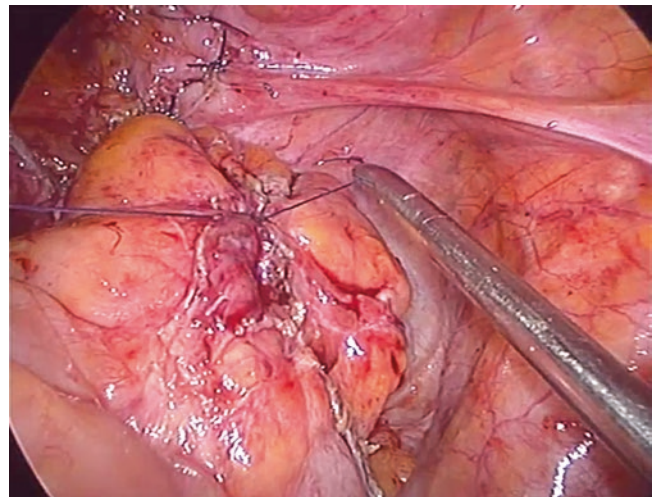


Fig. 42.24 Colonic rent closure complete

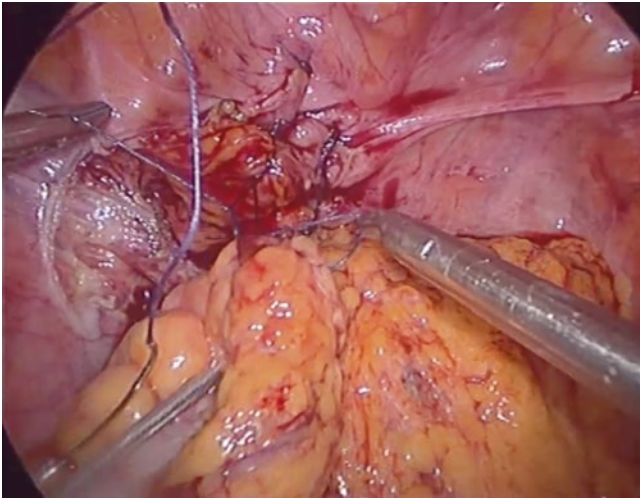


Fig. 42.25 Omental interposition

References

1. Bartus CM, Lipof T, Sarwar CM, Vignati PV, Johnson KH, Sardella WV, Cohen JL. Colovesical fistula: not a contraindication to elective laparoscopic colectomy. *Dis Colon Rectum*. 2005;48(2):233–6.
2. Ramalingam M, Senthil K, Pai MG. Pure laparoscopic repair of benign colovesical fistula without colectomy or proximal diversion: report of 2 cases. *UroToday Int J*. 2010;3(1). doi:10.3834/uij.1944-5784.2010.02.06

N. Mallikarjuna Reddy

43.1 Introduction

Following the introduction of clean self intermittent catheterization (CSIC) by Jack Lapides which revolutionized bladder drainage; many modifications have been done to achieve this. One popular technique is the Mitrofanoff procedure, using appendix as the continent catheterisable channel, through which CSIC can be performed without pain and the goal of intermittent bladder drainage can be achieved.

43.2 Indication

This is one of the most versatile surgeries done to perform CSIC. It is indicated in neurogenic bladder, in children who are not willing to do per urethral CSIC; in patients with spinal deformity like scoliosis, more so in females and rarely in bladder neck occlusion where urethral continuity cannot be established.

43.3 Preparation

Pre operative preparation is very important for performing this procedure successfully. A Micturating cysto urethrogram is necessary to assess the bladder capacity, bladder neck, and the way the bladder is positioned in the pelvis. If the bladder neck appears incompetent, bladder neck closure may be needed. Abdominal CT scan is done to know the approximate length of the appendix. Stoma site is marked depending on the patient's comfort, preferably at two sites. Prior surgeries and scars need to be taken into consideration in deciding the stoma site.

43.4 Procedure

43.4.1 Mitrofanoff with Appendix

The patient is placed supine and the bladder is catheterized. Patient is tilted to Trendelenberg position once the ports are placed and the appendix is assessed.

A midline 10 mm port or a 5 mm port is placed at the umbilicus or above the umbilicus and the abdomen is surveyed. The bladder is filled to assess the size. An additional 5 mm port is placed in the left iliac fossa and the length of the appendix and mobility of the meso-appendix is assessed (Fig. 43.1). Another 10 mm port is placed in the right iliac fossa possibly at the same place where the appendicular stoma is to be created. An additional port can be placed at the convenience of the surgeon (Fig. 43.2). The appendix is accessed and the mesoappendix is visualized (Figs. 43.3, 43.4). Base of the meso appendix is perforated and the appendix ligated close to the caecum. If the appendix is short, a cuff of caecum is taken to increase the length of the channel. Appendix is left in situ without cutting to prevent ooze from the cut end of the stump. Bladder is then dissected and dropped down from the anterior abdominal wall between the lateral umbilical ligaments (Fig. 43.5). It is our preference to place the appendix on the anterior wall of the bladder. It can also be placed on the posterior wall of the bladder. Bladder is filled and a sub mucosal tunnel is created for at least 4 cm, using an ureteric catheter as a guide for the length (Fig. 43.6). The tunnel is made as long as possible to prevent urine leak when the bladder is full. Appendix is now cut from the caecum (Figs. 43.7, 43.8). The most dependent end of the appendix is brought near the caudal end of the bladder sub mucosal tunnel. The tip of the appendix is spatulated for 1 cm (Fig. 43.9). The vesicoappendicular anastomosis is done with either interrupted or continuous sutures, as per the surgeon's preference (Fig. 43.10). After the completion of anastomosis, a 10 F Nelaton catheter is placed through the appendix across the anastomosis to assess the patency (Fig. 43.11). Catheter is left in situ and the appendix

N.M. Reddy
JJ Childrens Kidney and Urology Clinic, Global Hospitals
Lakdikapul, Hyderabad, India
e-mail: drnmreddy@gmail.com

is placed in the sub mucosal tunnel of the bladder, which is closed with running or interrupted 3-O or 4-O vicryl sutures (Fig. 43.12). The Nelaton catheter is withdrawn and the bladder is filled to ascertain that there is no leak from the appendix. Nelaton catheter is again inserted to check the patency and also evaluate any kinks in the appendix, which preclude the successful catheterization post operatively. Appendix is now tacked with a suture and brought out through the 10 mm port at the umbilicus or the right iliac fossa. An inverted V shaped incision is made in the skin where the apex of the V will be tucked into the appendix and the stoma created (Fig. 43.14). The stoma is catheterized many times and it is always our convention to allow our scrub nurse to do it at least twice before we are satisfied that the patient will be able to do it himself (Fig. 43.13). If needed a drain is placed through the 5 mm left iliac fossa port. The other ports are closed.

If the procedure is done for neurogenic bladder with an incompetent bladder neck, it has to be closed. This is done by opening the bladder and closing the bladder neck from within. Then the appendiculovesical anastomosis is completed.

43.5 Complications

The most common intraoperative complication is the inability to catheterize smoothly from the stoma. The other complication is the difficulty in bringing the end of the appendix to the skin. The other problem is bleeding from the edge of the appendix. Postoperative complications include stomal stenosis and inability to catheterize. Leak from the stoma is another complication which can be tackled by Deflux® injection.

43.6 Mitrofanoff Using Appendix

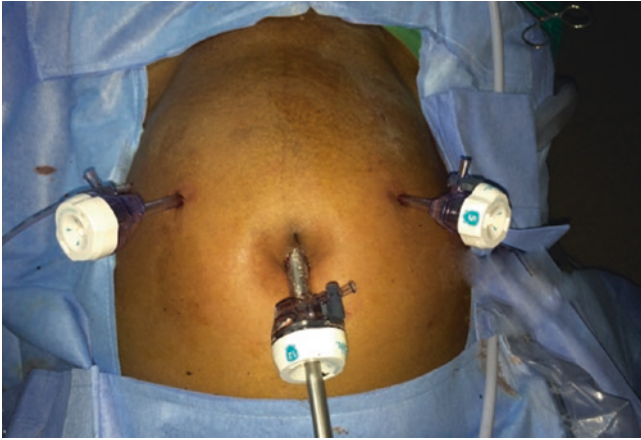

Fig. 43.1 Ports positions for mitrofanoff

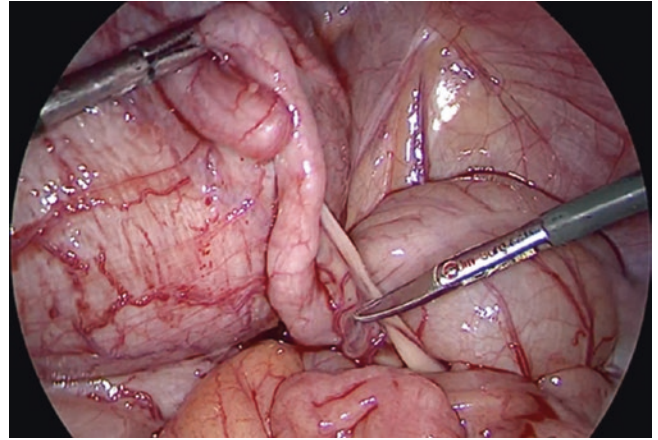


Fig. 43.2 Initial view of appendix – assessed for feasibility for conduit channel

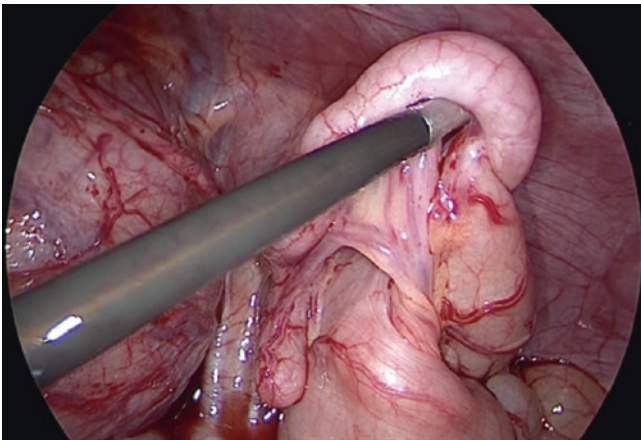


Fig. 43.3 Window in mesoappendix preserving the appendicular artery

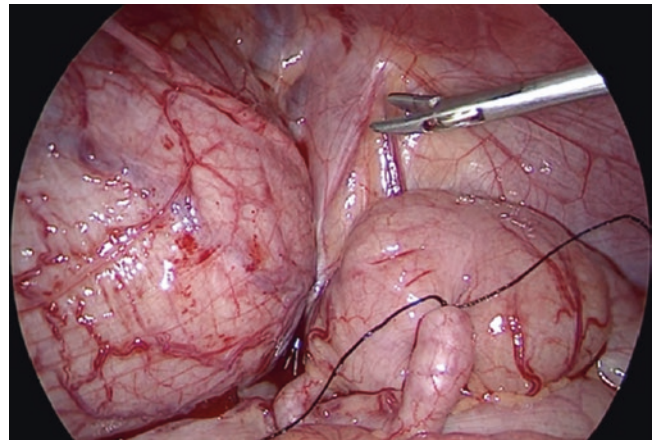


Fig. 43.4 Appendix base ligated

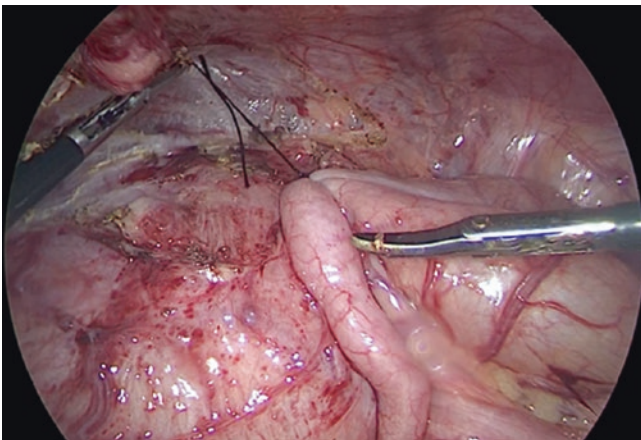


Fig. 43.5 Bladder minimally dropped down and probable area of anastomosis selected

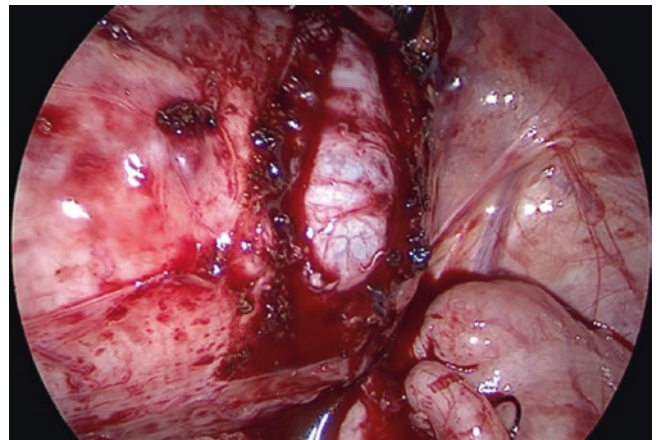


Fig. 43.6 Submucosal plane created in bladder

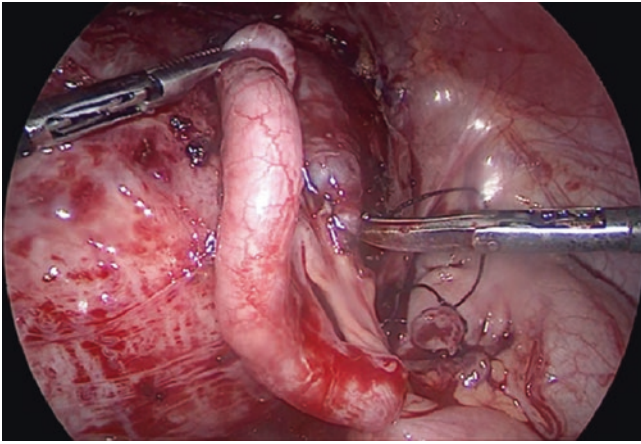


Fig. 43.7 Appendix divided just distal to ligature

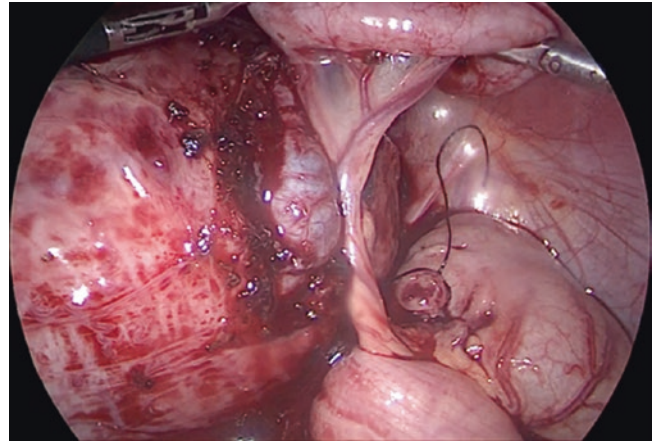


Fig. 43.8 Mesoappendix checked for twist

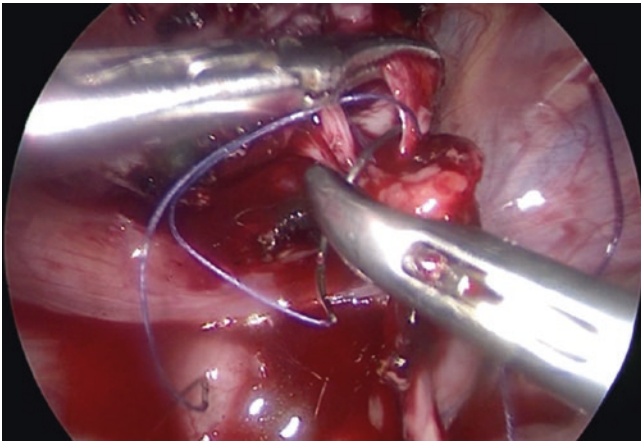


Fig. 43.9 Tip of appendix spatulated and sutured with the bladder mucosa

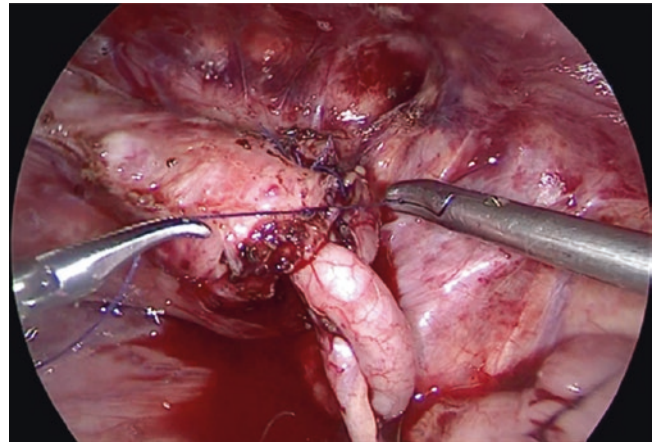


Fig. 43.10 With few more interrupted sutures anastomosis completed

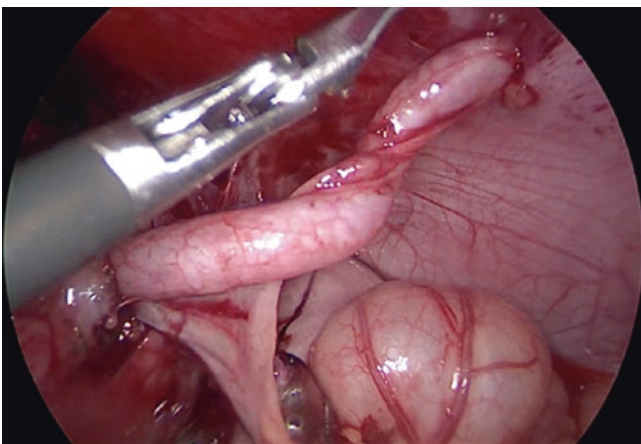


Fig. 43.11 Stump of appendix brought out to create stoma

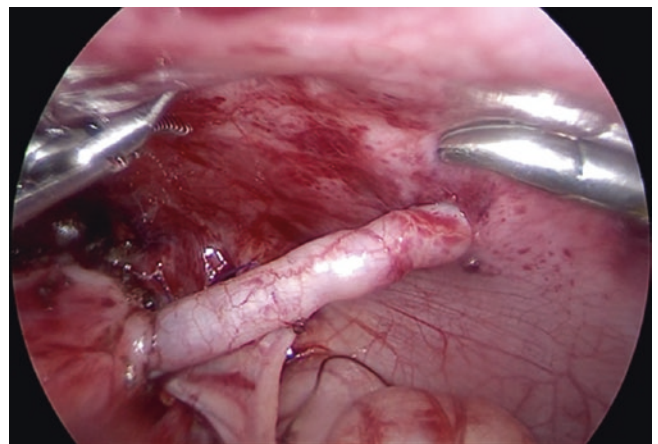


Fig. 43.12 Conduit with catheter in situ

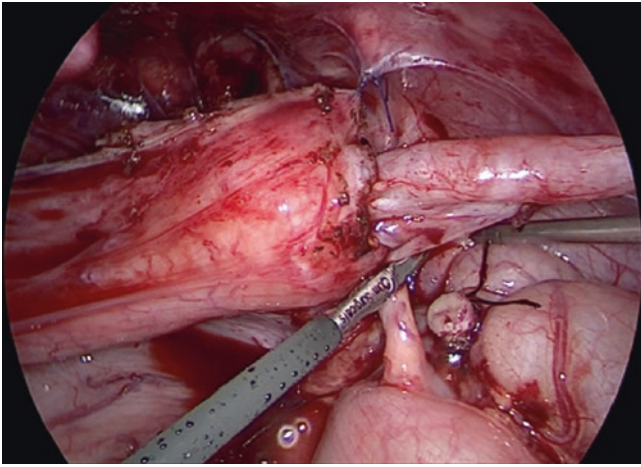


Fig. 43.13 Completed mitrofanoff

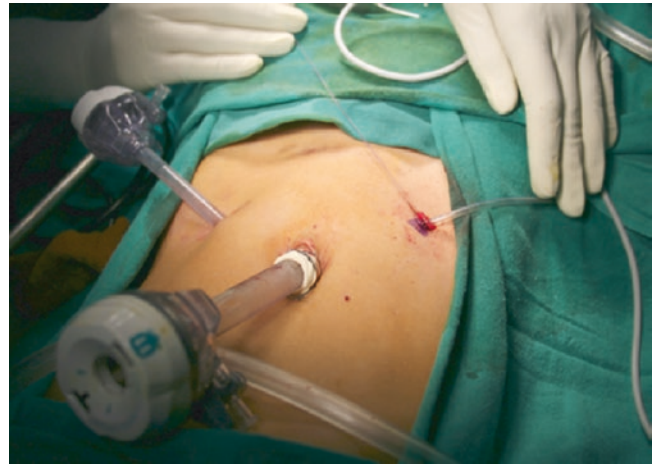

Fig. 43.14 Stoma located in the right iliac fossa (right hand port site)

Laparoscopy Assisted Ileocystoplasty with Mitrofanoff Procedure (Yang Monti Technique)

44

Manickam Ramalingam, Kallappan Senthil,
and Anandan Murugesan

In patients needing bladder augmentation, ileocystoplasty can be combined with catheterisable channel creation. In such cases, Yang-Monti tube can be constructed as a catheterisable channel. In laparoscopy assisted approach, bowel is brought out through a 5 cm subumbilical incision and bowel segment isolated. This 15–20 cm segment is used for both creation of Yang Monti tube and ileal patch for augmentation. Initially, submucosal plane is created in the right antero-

lateral aspect of the bladder and tunneled anastomosis is done with the Yang-Monti tube, similar to ureteric reimplantation. Cystotomy for augmentation is done in a slightly oblique angulation to avoid disturbing the Monti tube. The rest of the augmentation is similar to the classical ileocystoplasty. Suprapubic catheter is usually placed, if both procedures are combined.

M. Ramalingam (✉)
PSG Hospitals,
Coimbatore, India
e-mail: uroram@yahoo.com

K. Senthil, MCh (Urol., FRCS)
Urology Clinic, Gowtham Annexe, Coimbatore, India
e-mail: senthilsatya@hotmail.com

A. Murugesan, MBBS, MS, MCh
Department of Urology, PSG Institute of Medical Sciences and
Research, Peelamedu, Coimbatore, Tamil Nadu, India
e-mail: anandan79@gmail.com

44.1 Laparoscopy Assisted Ileocystoplasty with Mitrofanoff Catheterisable Channel (Yang Monti tube)

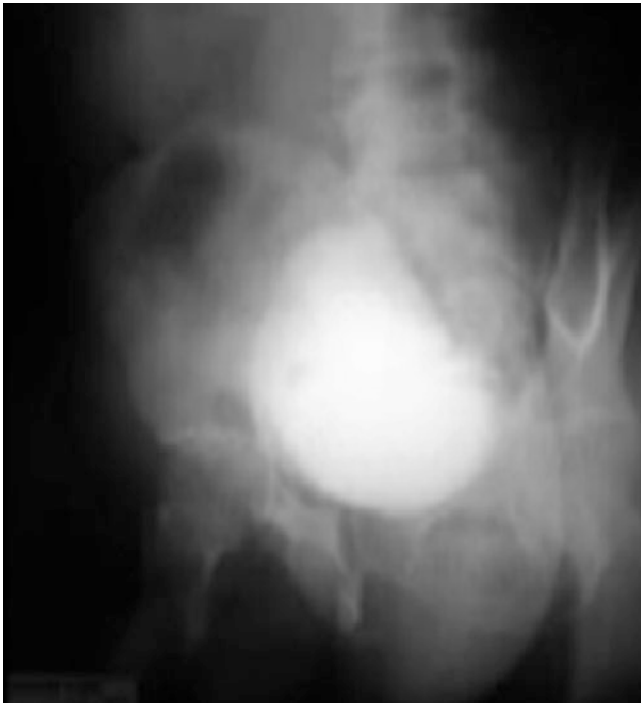

Fig. 44.1 Cystogram showing contracted trabeculated bladder

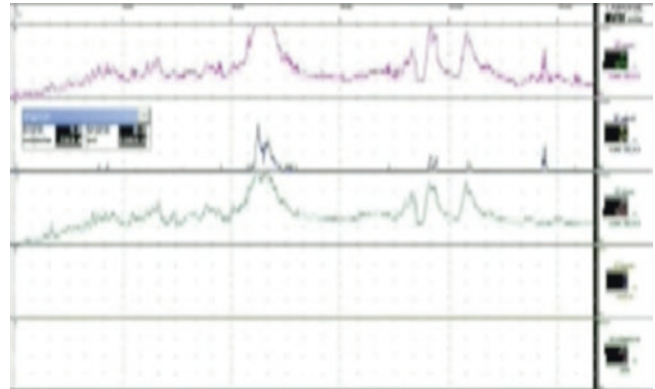
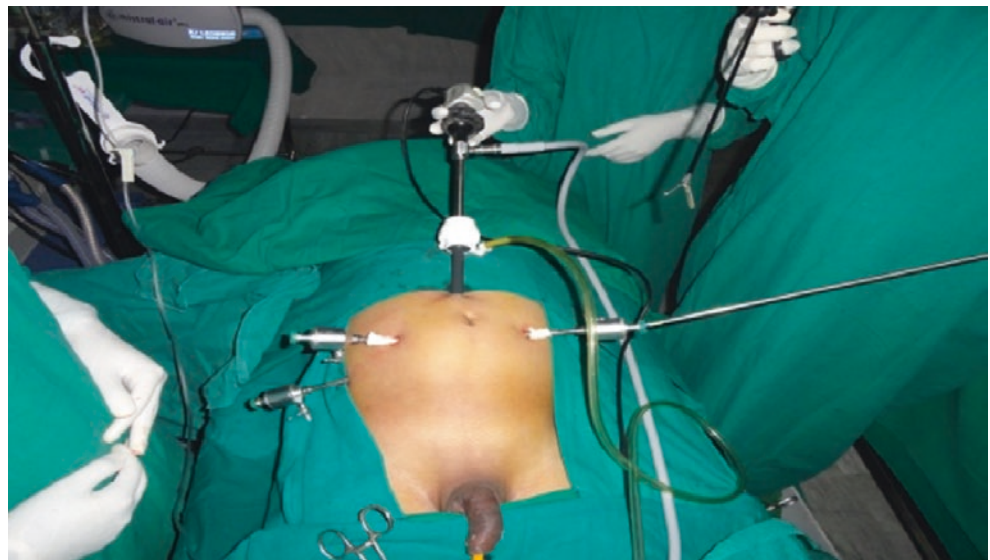

Fig. 44.2 UDE showing poor compliance bladder

Fig. 44.3 Ports position



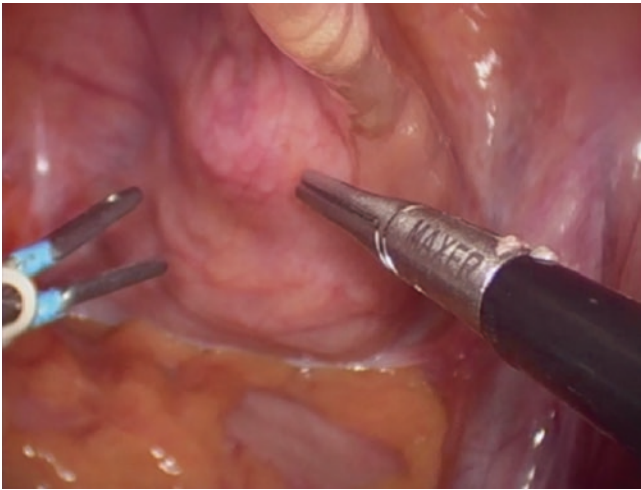


Fig. 44.4 Initial view of bladder

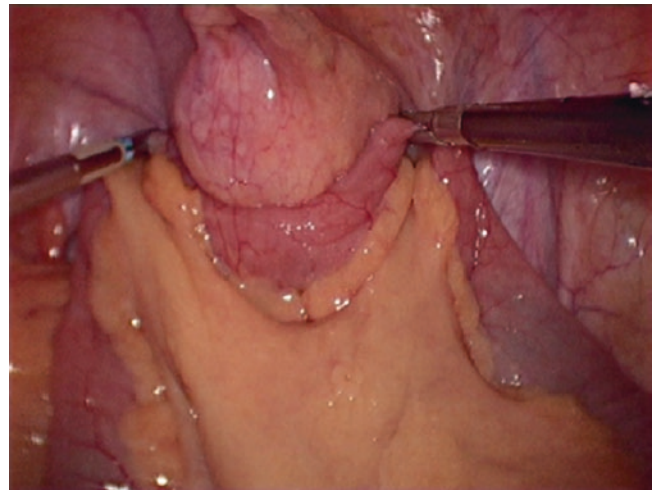


Fig. 44.5 Ileal loop about 20 cm from ileocaecal junction selected

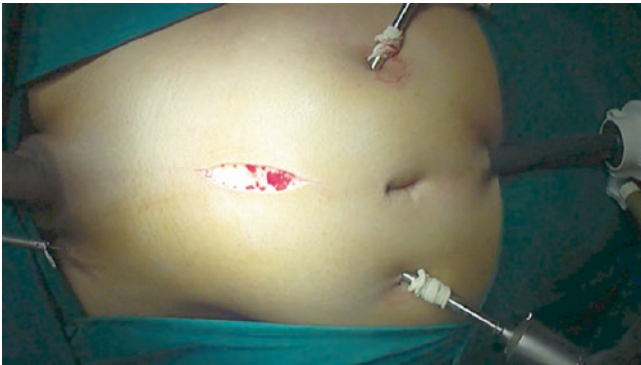

Fig. 44.6 5 cm subumbilical midline incision made for extra corporeal bowel isolation

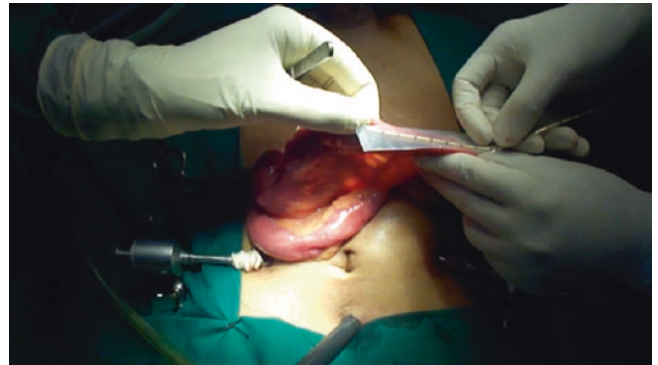


Fig. 44.7 15 cm ileal segment selected for augmentation (10 cm) and spiral Monti (5 cm)

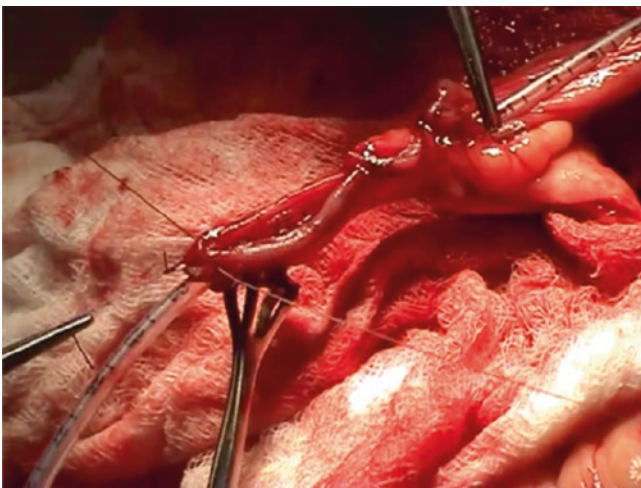


Fig. 44.8 Creation of catheterisable channel—spiral Monti in progress

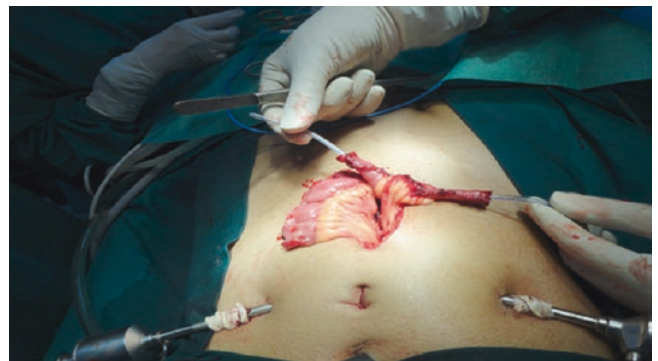

Fig. 44.9 Spiral Monti constructed

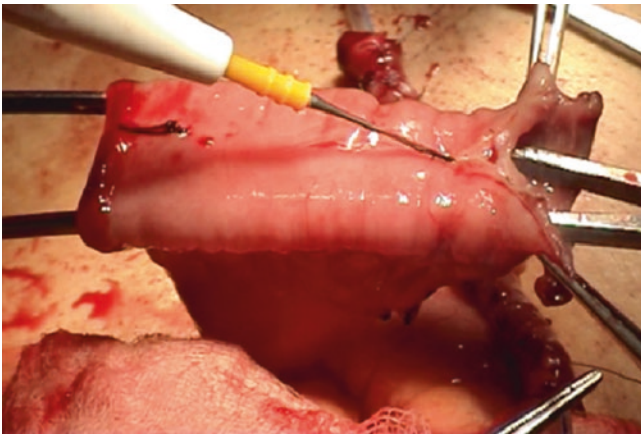


Fig. 44.10 Isolated ileal segment for augmentation detubularised

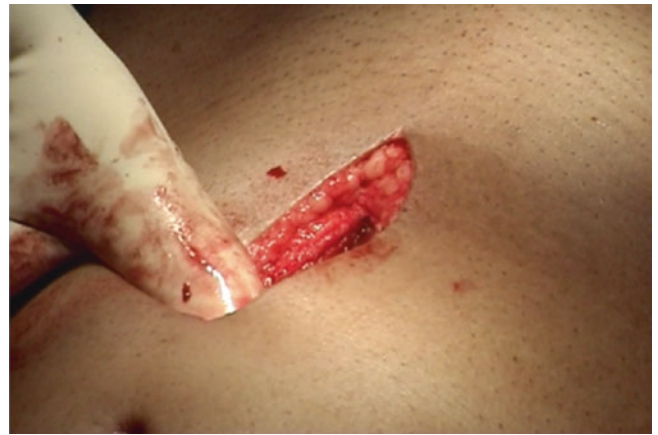

Fig. 44.11 Detubularised ileal segment and Yang Monti tube pushed back into abdomen

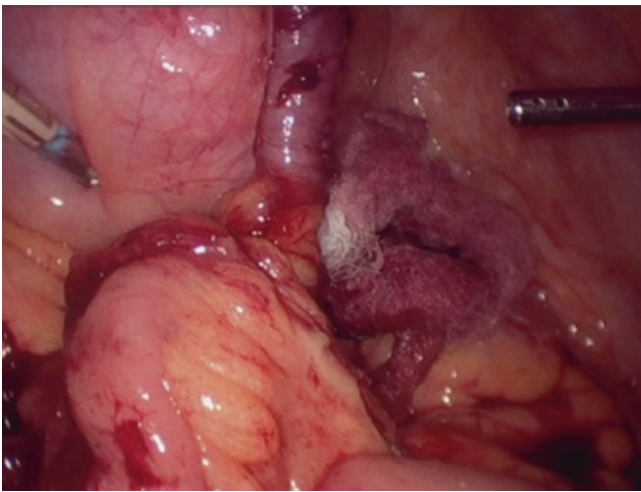


Fig. 44.12 Detubularised ileal segment and Yang-Monti tube lying tension free over bladder area

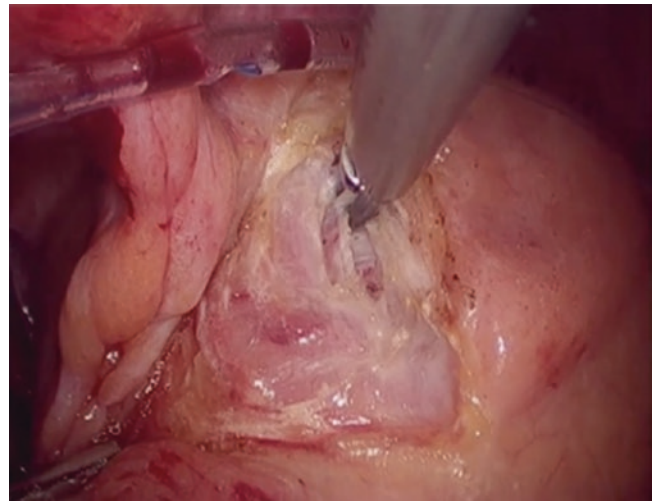


Fig. 44.13 Cystotomy in preparation for anastomosis of Monti tube

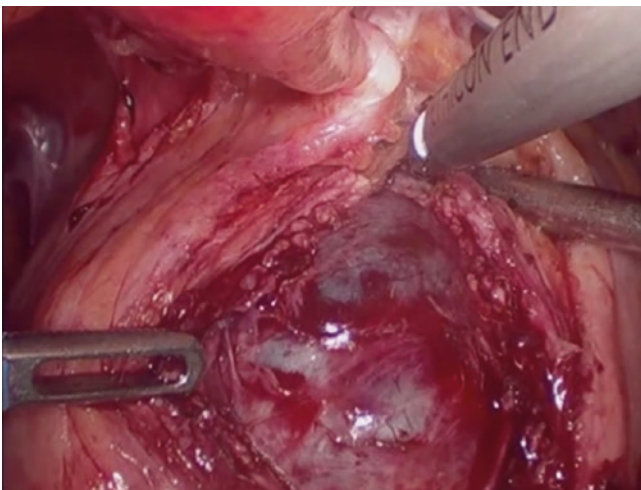


Fig. 44.14 Submucosal plane developed for tunnelling the catheterisable channel

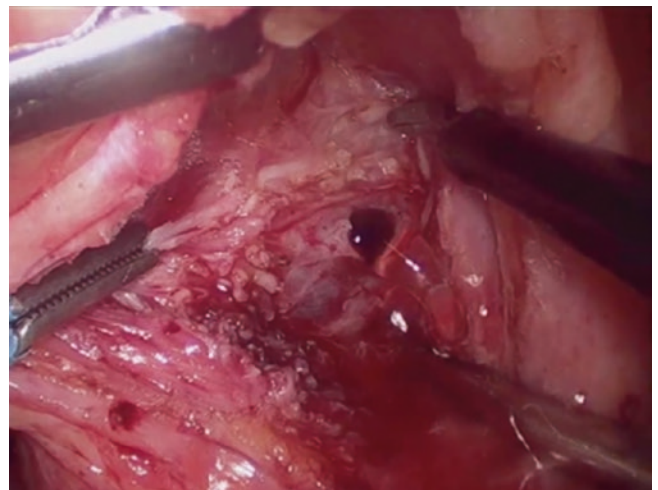


Fig. 44.15 Bladder mucosa opened distally

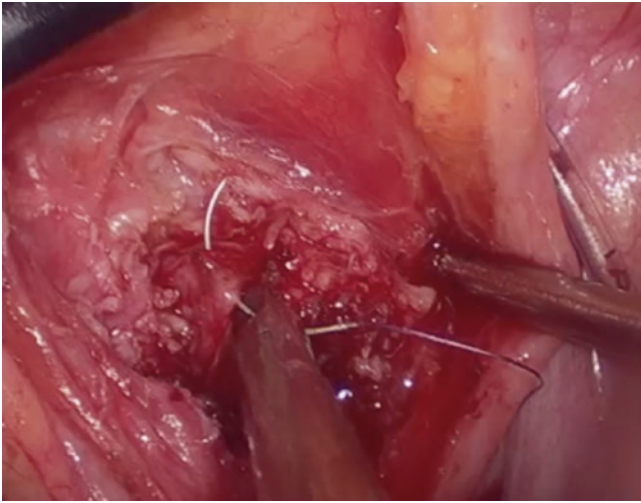


Fig. 44.16 Anastomosis of Yang Monti tube to bladder started

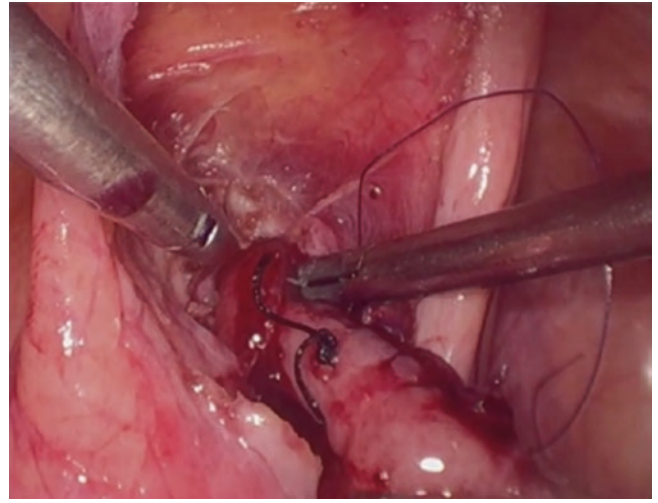


Fig. 44.17 Anastomosis with 4-0 vicryl suture in interrupted fashion

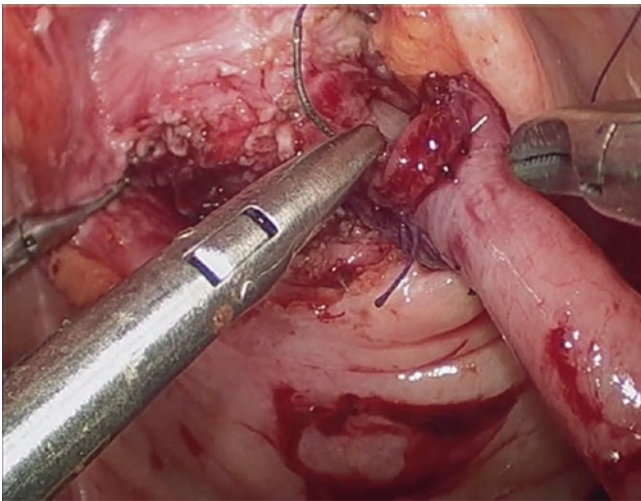


Fig. 44.18 Anastomosis in progress

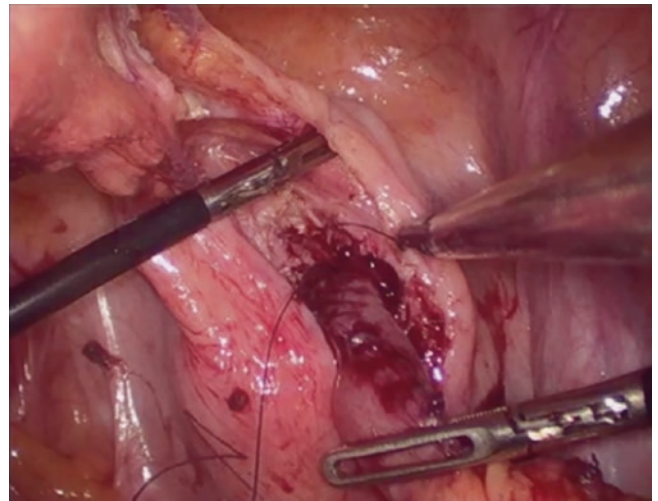


Fig. 44.19 Anastomosis in progress

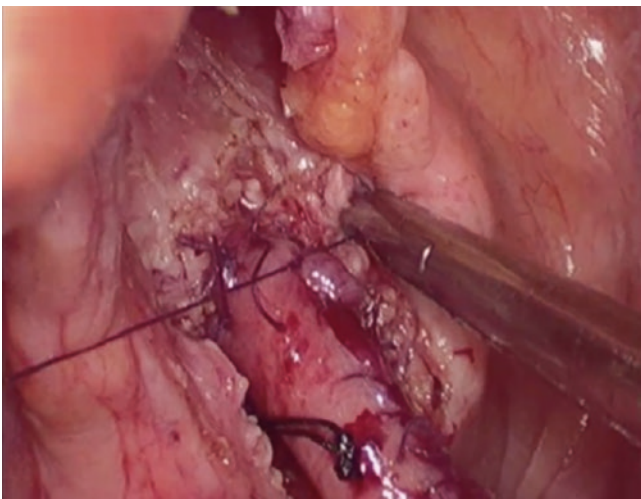


Fig. 44.20 Mucosal anastomosis completed

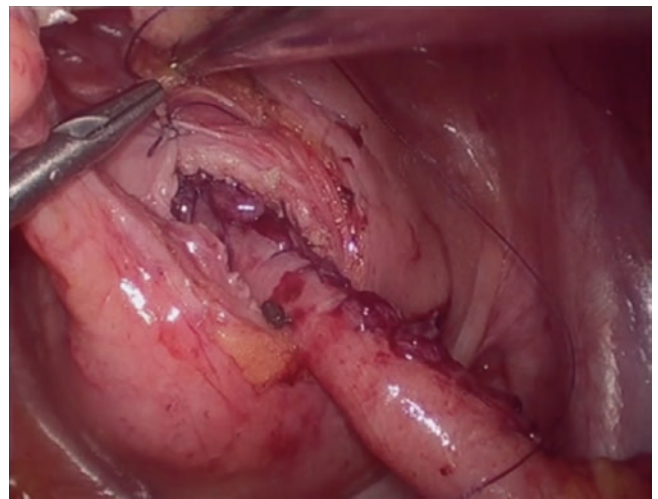


Fig. 44.21 Second layer for tunnelling with interrupted 3-0 vicryl suture

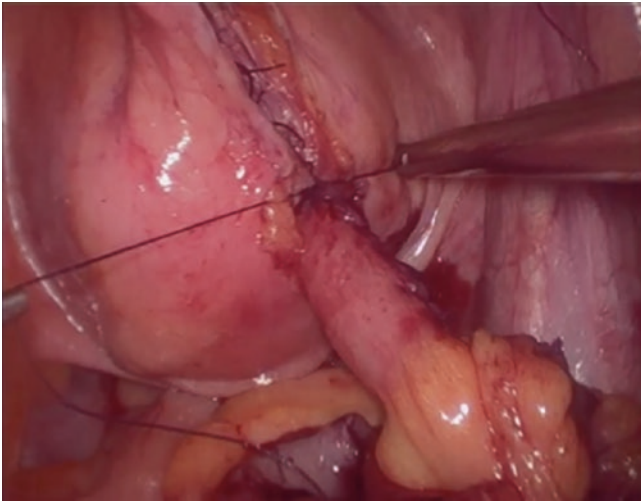


Fig. 44.22 Tunnelling completed

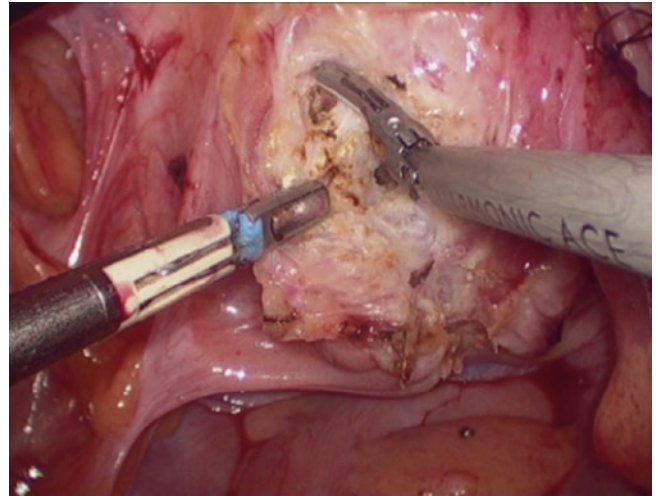


Fig. 44.23 Oblique cystotomy in preparation for augmentation

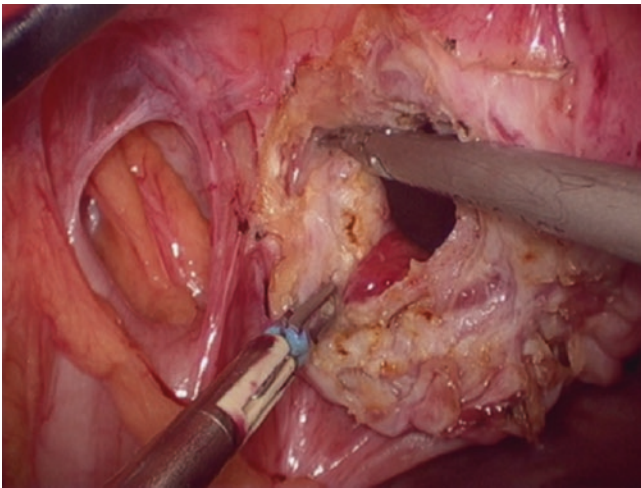


Fig. 44.24 Oblique cystotomy being done

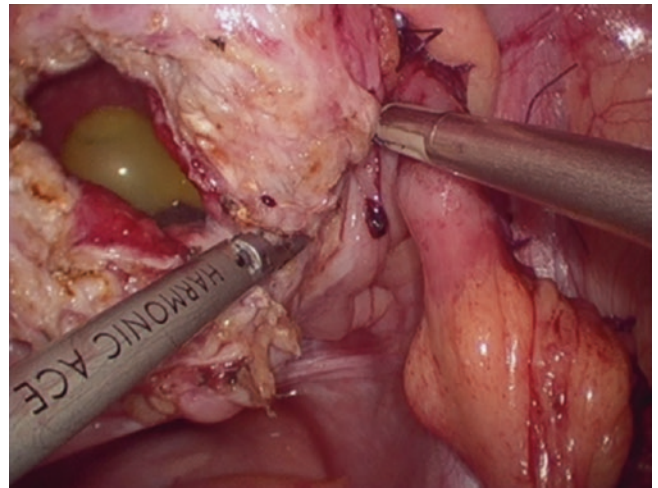


Fig. 44.25 Cystotomy extended posteriorly

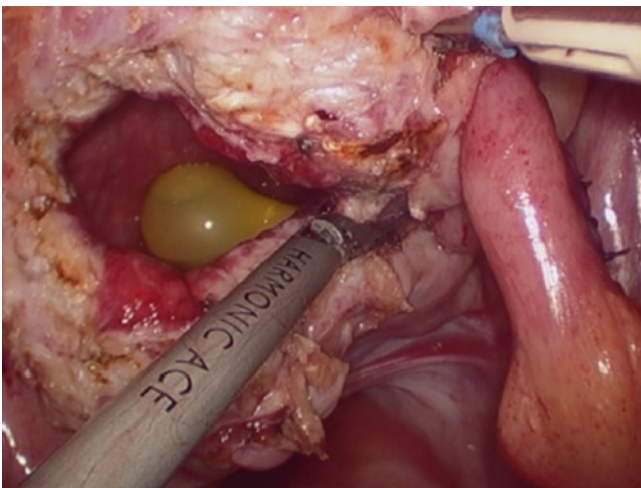


Fig. 44.26 Cystotomy completed

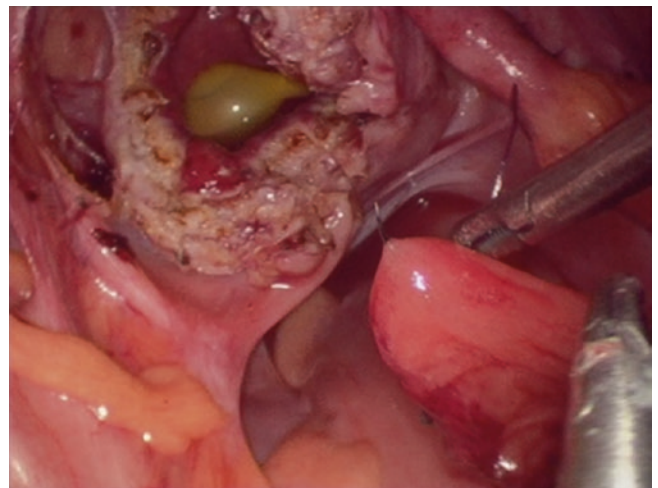


Fig. 44.27 Initial suture with 3-0 vicryl through detubularised ileum outside-in

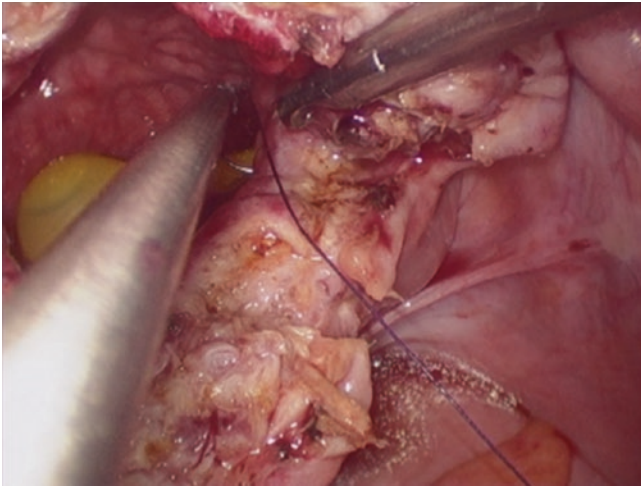


Fig. 44.28 Corresponding suture through posterior wall of bladder inside-out

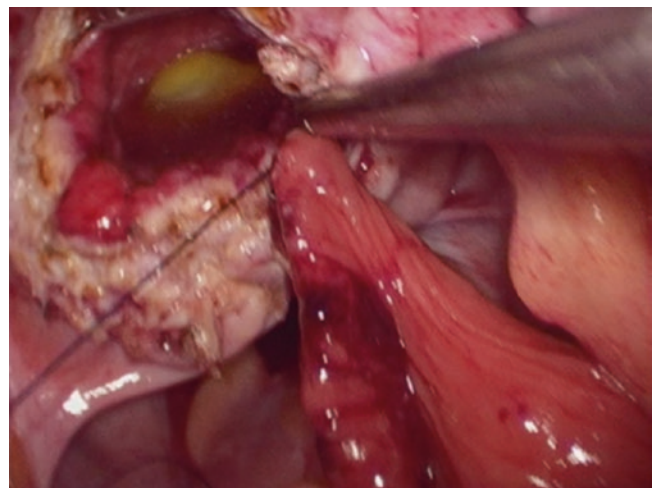


Fig. 44.29 Initial suture in place

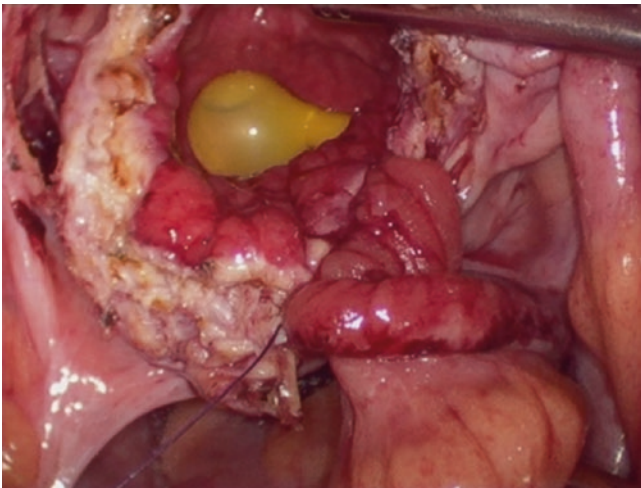


Fig. 44.30 Posterior wall continuous suturing in progress

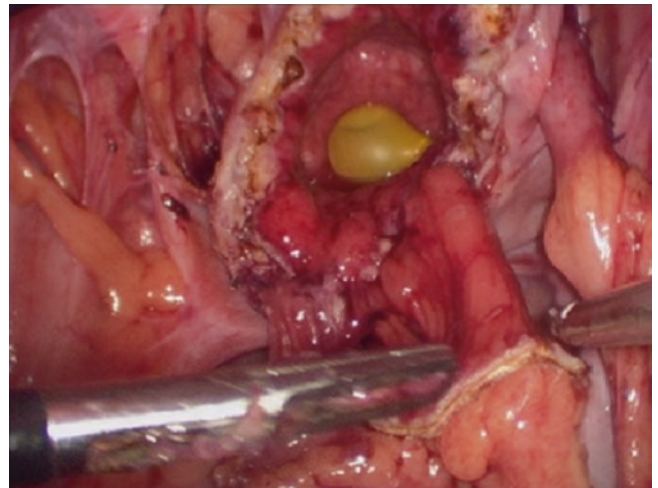


Fig. 44.31 Posterior layer suture continued

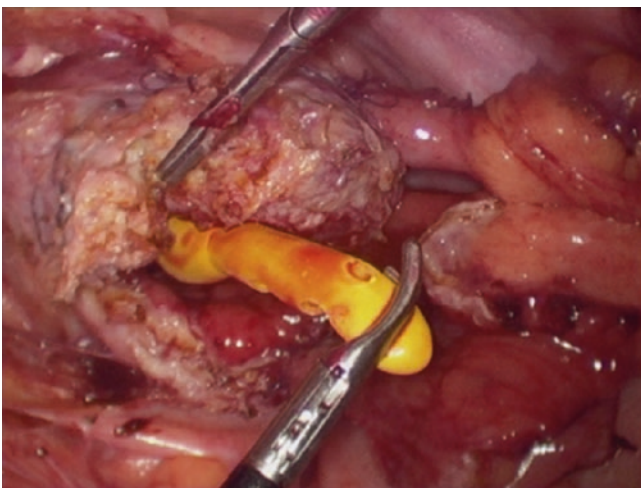


Fig. 44.32 Trocar SPC placed (Helpful in case of mucus obstruction post operatively)

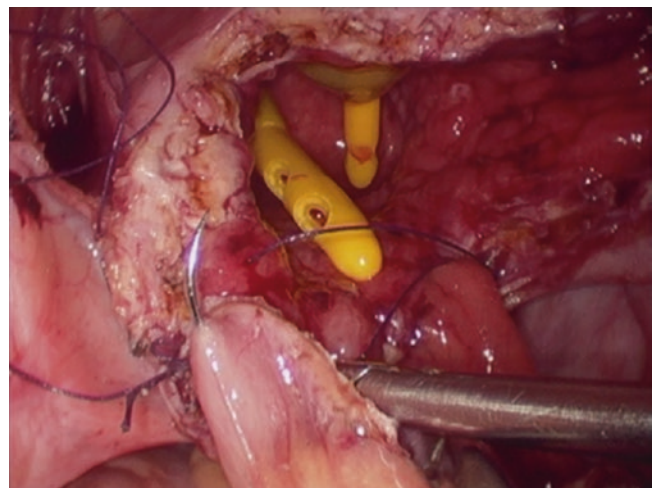


Fig. 44.33 Anterior layer suturing started from the left corner

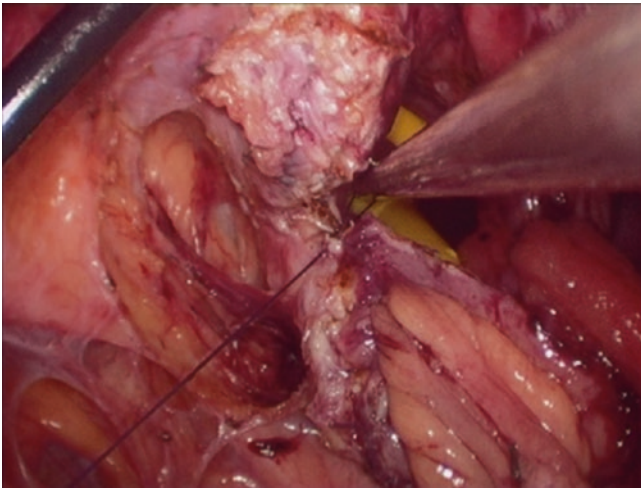


Fig. 44.34 Anterior layer suturing in continuous fashion

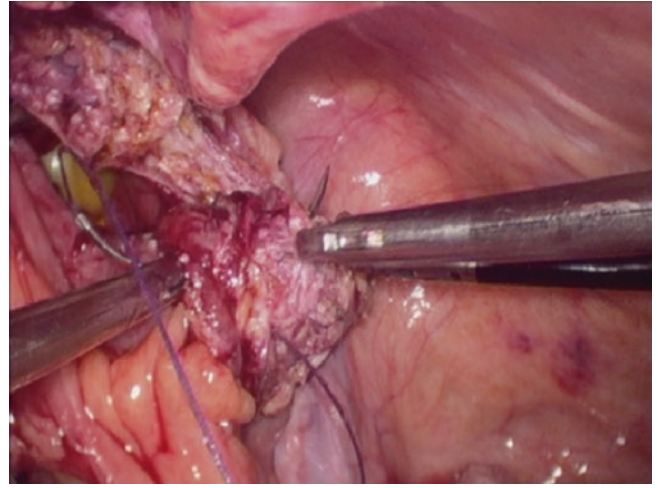


Fig. 44.35 Anterior layer suturing started in the right corner with another suture

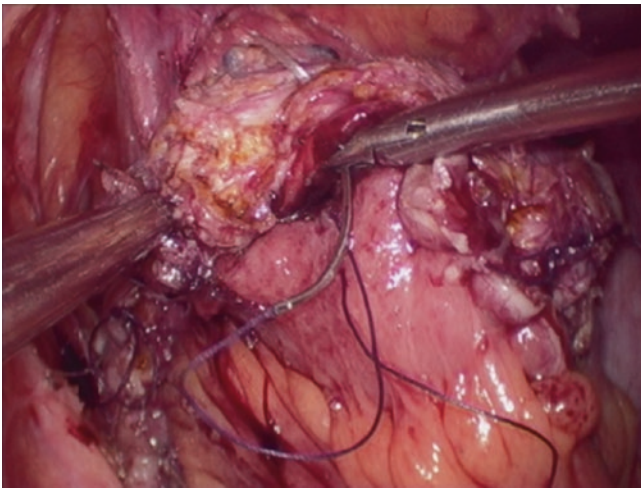


Fig. 44.36 Anterior layer suturing in progress

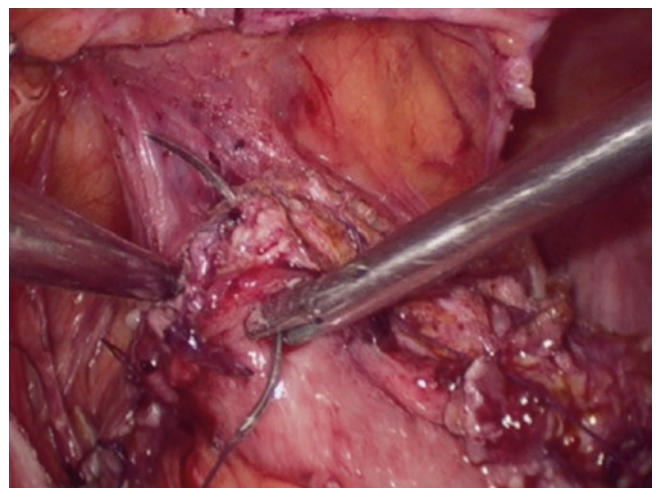


Fig. 44.37 Anterior layer suturing in progress

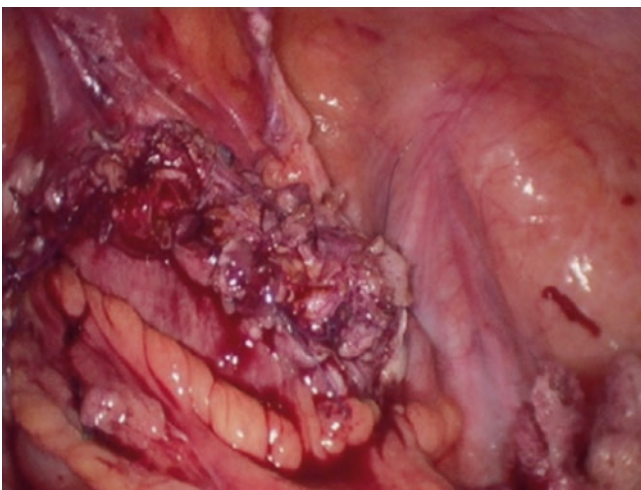

Fig. 44.38 Anterior layer suturing completed

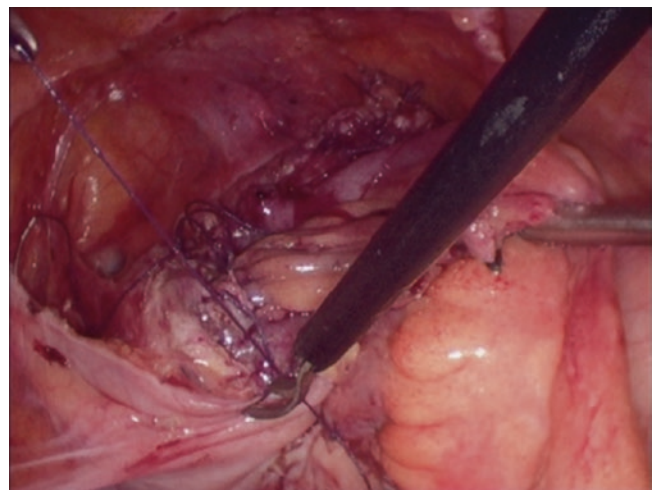


Fig. 44.39 Bladder distended and no leak noted

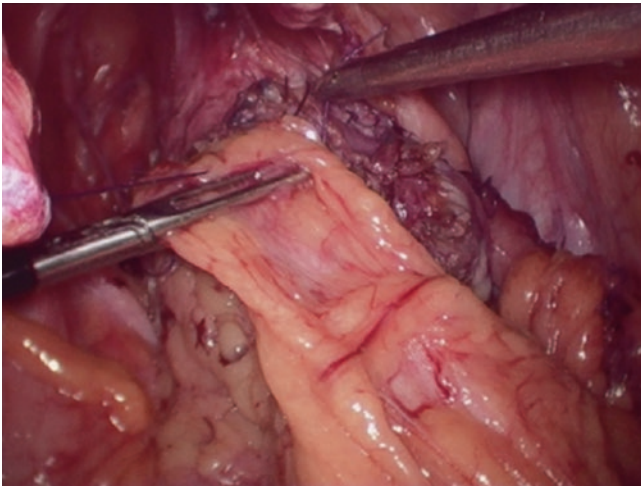


Fig. 44.40 Omentum tacked to suture line

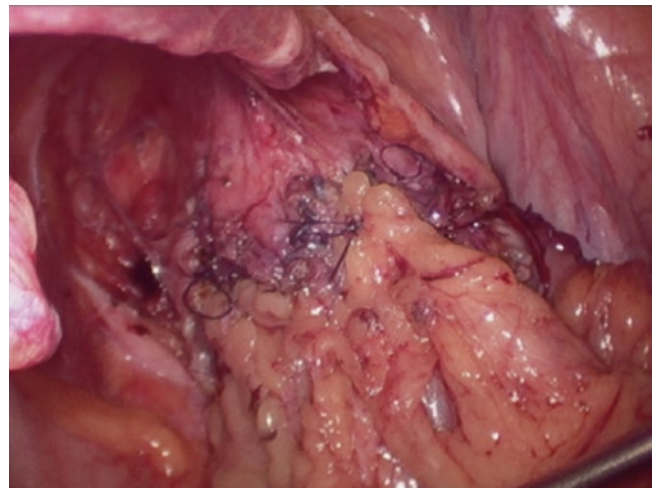


Fig. 44.41 Final view of augmentation cystoplasty along with Monti tube

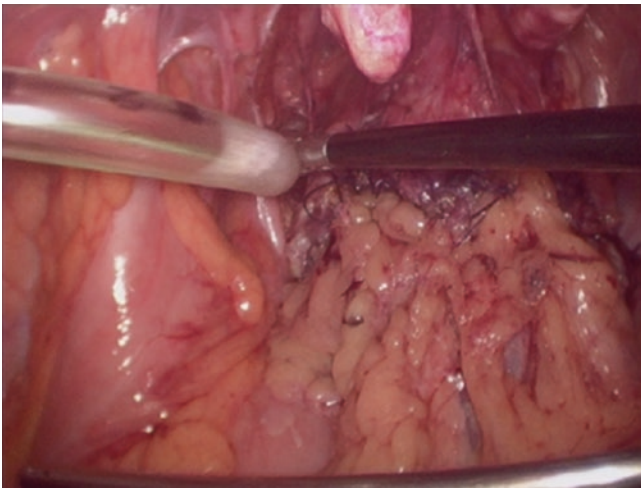


Fig. 44.42 Drain placed

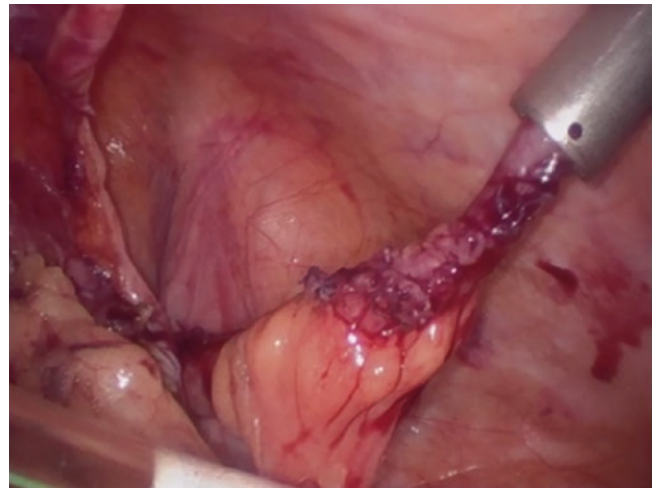

Fig. 44.43 Monti tube brought out through the trocar in right pararectus area

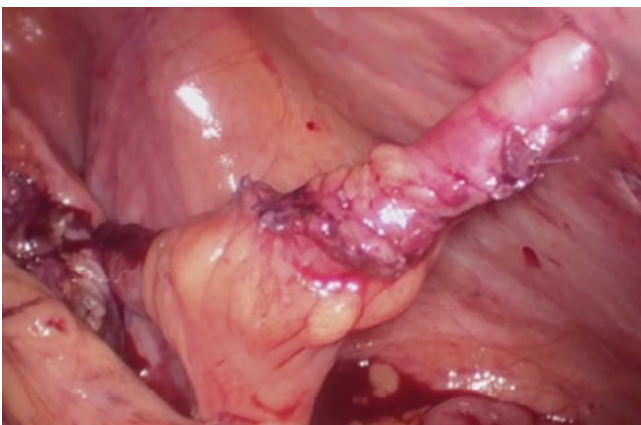


Fig. 44.44 Final view of the catheterisable channel

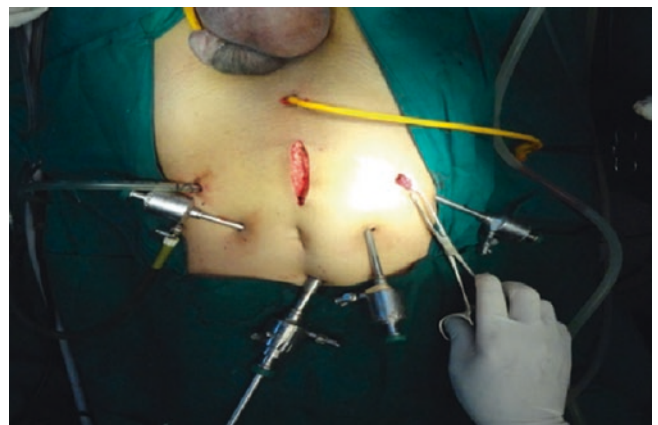


Fig. 44.45 Stoma located

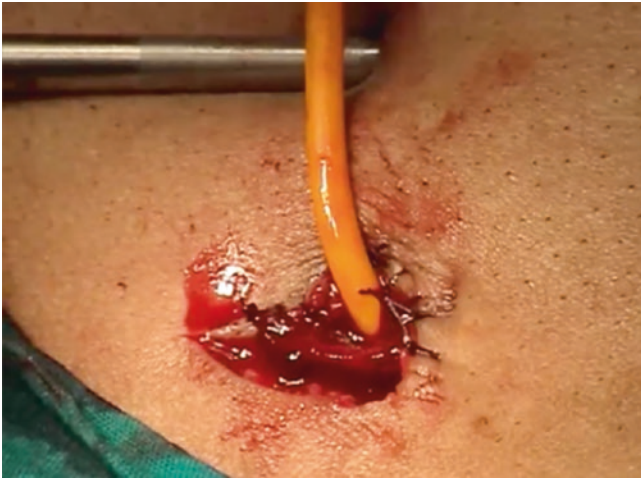

Fig. 44.46 External stoma being created

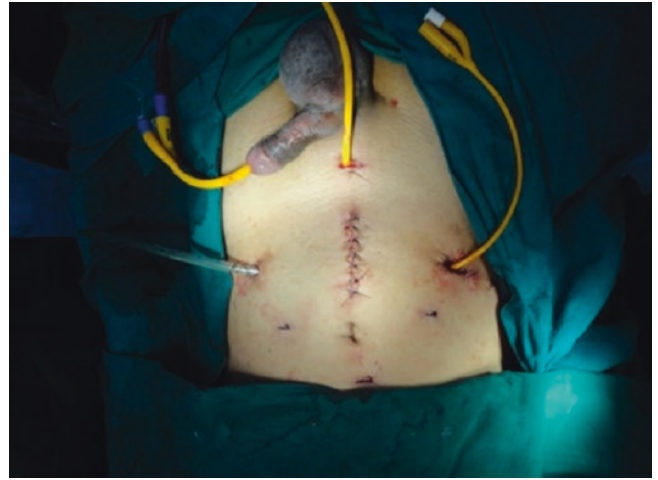

Fig. 44.47 Stoma fashioned, wound and ports closed

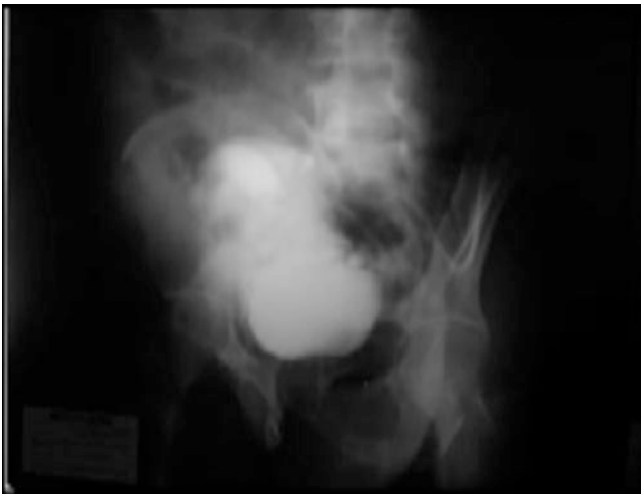

Fig. 44.48 Post op (6 weeks) cystogram showing augmented bladder with continent mitrofanoff channel

Robotic-Assisted Laparoscopic Mitrofanoff Appendicovesicostomy (RALMA)

45

Eric D. Schadler, Vignesh T. Packiam,
and Mohan S. Gundeti

45.1 Introduction

Robotic-assisted approaches are increasingly used for pediatric procedures. Neurogenic bladder and other emptying pathology pose a unique problem for pediatric patients who are limited in their ability to catheterize per urethra. The Mitrofanoff procedure creates an effective conduit to allow for effective bladder emptying while maintaining continence. While the Mitrofanoff procedure has traditionally been performed using an open surgery technique, robotic-assisted approaches have been associated with decreased hospital stay, reduced postoperative pain, and lessened cosmetic damage [1].

45.2 Indications

- Failure to empty type of neurogenic bladder (with or without myelomeningocele)
- If unable to perform CIC per urethra, performed concomitantly with augmentation
- Prune belly syndrome
- Idiopathic bladder dysfunction leading to failure to empty
- Urethral stricture disease not amenable to reconstruction

E.D. Schadler, MD
Pritzker School of Medicine, The University of Chicago Medical Center, Chicago, IL, USA

Section of Urology, Department of Surgery, Comer Children's Hospital, The University of Chicago Medicine, Chicago, IL 60637, USA

V.T. Packiam, MD • M.S. Gundeti, MBBS, MCh, FEBU, FRCS, FEAPU (✉)
Section of Urology, Department of Surgery, Comer Children's Hospital, The University of Chicago Medicine, Chicago, IL 60637, USA
e-mail: Vignesh.packiam@uchospitals.edu; mgundeti@surgery.bsd.uchicago.edu

45.3 Patient Selection

A prerequisite to utilizing the robotic-assisted approach for this procedure is appropriate counseling and family involvement. We suggest that counseling include a teaching video and multiple visits with the surgical team, including the physician and physician extender (nurse, nurse practitioner, physician assistant, etc.). Patients must be assessed for appropriate hand eye coordination and the optimal stoma location needs to be determined preoperatively, especially for wheelchair bound patients. Initial patient selection should include children at least 4–5 years of age (to maximize abdominal space), those willing and able to catheterize, and those without history of multiple prior abdominal surgeries. After proficiency in technique and outcomes, these criteria can be expanded to include younger patients, lower BMI, or children with scoliosis or are wheelchair bound.

Upper tract evaluation can be performed with ultrasound and a full anesthesia evaluation should evaluate comorbidities and fitness for surgery. Preoperative workup must evaluate the bladder neck and ensure bladder compliance, most preferably through videourodynamics. Diagnosis of neurogenic bowel is critical to plan for ACE, as different techniques are required based on anatomy: split appendix technique if a long appendix is present, cecal flap ACE, or cecostomy otherwise. Furthermore, bladder augmentation or cystoplasty may be required for patients with high bladder pressures, poor compliance and/or low bladder capacity.

45.4 Surgical Technique

We do not use bowel preparation, and typically administer preoperative Cefazolin, Gentamicin, and Metronidazole. Cefazolin can be exchanged for Vancomycin if a ventriculoperitoneal (VP) shunt is present. Place the patient in a modified lithotomy position with 25–30° Trendelenburg and place the Foley on the sterile field. As with all minimally invasive

procedures, port placement is critical for success. We recommend utilization of a 12-mm umbilical camera port, two 8-mm robotic arm ports, and a 5-mm LUQ assistant port, triangulated toward the RLQ (Fig. 45.1) [2]. An additional 12-mm port may be used if enterocystoplasty is planned. Ports should be placed 5–8 cm apart to avoid clashing, robotic arms should ideally be equidistant from the camera port, and the pubo-umbilical distance should be at least 10–12 cm. In cases of kyposcoliosis the primary camera port should be moved supraumbilically (Fig. 45.2).

45.4.1 Diagnostic Peritoneoscopy

Prior to docking the robot, especially in those with VP shunt and/or prior abdominal surgery, we recommend diagnostic peritoneoscopy to ensure adequate appendix length (5–6 cm) and caliber (to accommodate a 10–12 Fr catheter). The robot should only be docked between the legs of the patient after this is verified, since an open Monti procedure may otherwise be required.

45.4.2 VP Shunt Management

If a VP shunt is present, placement into an Endopouch Retriever (Ethicon, Cincinnati, OH) specimen bag is necessary. Withdrawal of the VP shunt from the bag should be done prior to removing robotic ports [3].

45.4.3 Catheterization Channel

We always prefer to utilize the appendix if it is of appropriate length. Spiral Monti catheterization channels have a significant complication rate (30–40%) and we have not attempted these procedures robotically at our institution yet, although it is technically feasible. Once the appendix is identified, placement of a stay stitch into the distal aspect of the appendix allows for manipulation and creation of a window between the appendiceal mesentery and cecum. We use the robotic endoscissors to dissect the appendix away at its base with a cecal cuff. Close the cecum with a 5-0 PDS purse-string suture followed by a running second layer. We use the robotic Potts scissors to open the distal 1-cm of the appendix. Spatulate this opening and catheterize it with an 8 Fr feeding tube.

45.4.4 Detrusorotomy Location Selection

45.4.4.1 Anterior Wall

For isolated Mitrofanoff, we recommend an anterior wall anastomosis as described previously by Wille et al. [4]

since it provides greater technical simplicity. Although there has been controversy regarding risk of urinary tract infections and bladder stones secondary to incomplete bladder emptying, we have not encountered these in our experience [5]. If the umbilicus is the desired exit point, utilize a midline tunnel through the detrusor. An oblique tunnel can be used for bringing the appendicovesicostomy off the midline of the patient's abdomen into the right iliac fossa.

45.4.4.2 Posterior Wall

Utilize an intravesical posterior wall anastomosis as described by Murthy et al. for patients undergoing concomitant augmentation cystoplasty in addition to the Mitrofanoff procedure [6].

45.4.4.3 Detrusorotomy

Use a stay suture on the dome of the bladder to retract during the detrusorotomy. We recommend filling the bladder partially with saline. Make a detrusorotomy on the anterior bladder wall to create a submucosal tunnel in the direction of the future stomal site.

45.4.4.4 Submucosal Length

Adequate length of the bladder submucosal channel is critical for stromal continence to be maintained; we recommend approximately 4 cm in length, although other surgeons have utilized as low as 3 cm [7]. Next, approximate the distal end of the appendix to the proximal end of the newly created detrusor tunnel using 5-0 PDS.

45.4.4.5 Anastomosis

The appendix is placed into the submucosal tunnel and a second suture used to approximate the spatulated appendix to the distal aspect of the bladder mucosa. Be sure to leave the needles in each suture so that a running anastomosis of the appendix and bladder can be performed. The edges of the detrusor muscle are approximated around the appendix to ensure continence later. To maintain orientation and prevent channel twisting, secure the 8 F feeding tube to the bladder mucosa using a stay suture. A V, VQ, or VQZ skin flap is created as a stromal site for anastomosis of the proximal spatulated appendix to the abdominal wall.

45.4.5 Postoperative Urinary Drainage

Secure the 8 F feeding tube from the appendicovesicostomy to the skin. A urethral foley is adequate for urinary drainage. However, if patient compliance is an issue we recommend placement of a suprapubic tube. Additionally, concomitant cystoplasty mandates placement of a suprapubic tube.

45.5 Postoperative Care

Patients should be given oral acetaminophen and intravenous non-steroidal anti-inflammatory medications such as ketorolac. Intravenous opioids should be given only for breakthrough pain. NPO is not necessary, and feeding can begin immediately. Discharge is reasonable once pain is controlled on oral medications, a regular diet is tolerated, and there are no postoperative concerns. A suprapubic tube, urethral Foley catheter, and capped Appendicovesicostomy tube are left in place for 4 weeks.

45.6 Follow-Up

Close communication and interval visits with the physician team are critical. During these visits, timing and interval between catheterizations can be adjusted.

On 4-week follow-up, the appendicovesicostomy and urethral Foley catheters are removed and CIC is started using a 10 F straight catheter. After 2 weeks, this catheter can be upsized to 12 F and the suprapubic tube removed.

Surveillance ultrasounds should be performed as appropriate based on underlying pathology. Stomal stenosis is a common complication that mostly occurs at the skin level.

ACE plugs (spigots) may be used for certain patients to prevent stomal stenosis. Stomal incontinence is another potential complication. If short tunnel length and bladder compliance issues are ruled out, we prefer endoscopic maneuvers such as Deflux as first line management for this complication.

45.7 Comparison to Open Approach

There are several small series assessing outcomes of robotic-assisted Mitrofanoff. Famakinwa et al. evaluated 18 patients who underwent appendicovesicostomy (10 with concomitant augmentation cystoplasty) and showed that 94.4 % of patients were continent at follow-up (median = 24.2 months) [7]. There were two (11 %) cases of stomal stenosis (one due to noncompliance) and one (6 %) instance of parastomal hernia. In comparison to a large open series of 169 patients, Leslie et al. reported a functional channel rate of 96 % [8]. In this study 39 % required surgical revision due to stomal stenosis (17 %), incontinence (10 %), stricture (8 %), or prolapse (4 %). Lastly, Grimsby et al. directly compared 39 robotic appendicovesicostomy procedures to 28 open procedures [9]. They found no difference in the number of complications ($p=0.788$) or reoperations ($p=0.791$) between groups.

45.8 Robotic-Assisted Laparoscopic Mitrofanoff Appendicovesicostomy (RALMA)

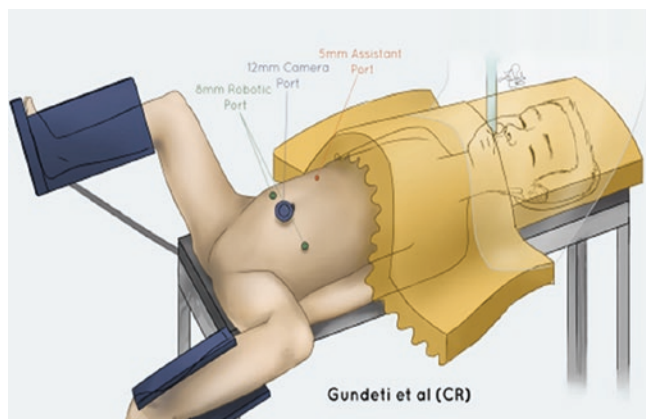


Fig. 45.1 Patient positioning and padding for robotic procedures

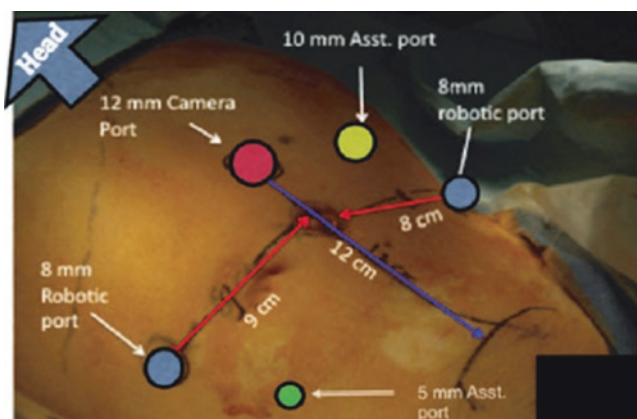


Fig. 45.2 Port placement of pelvic procedures. An additional 5-mm assistant port showing in green is placed if needed. In patients with kyposcoliosis the primary camera port is moved supraumbilically, to yield 12 cm of puboumbilical distance (From Chang et al. [10])

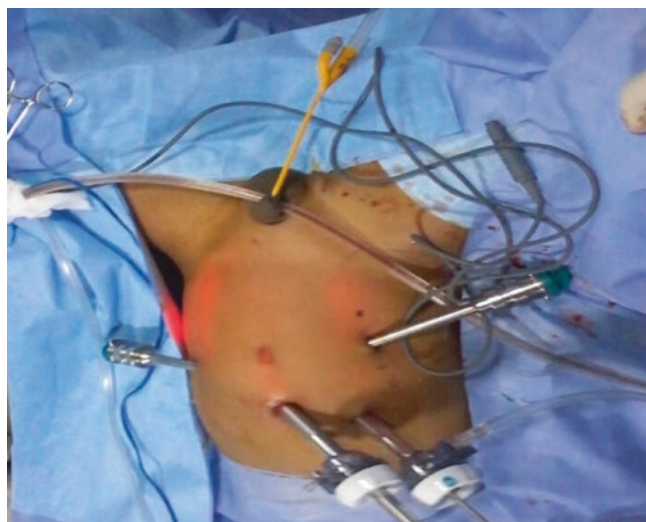

Fig. 45.3 Ports position

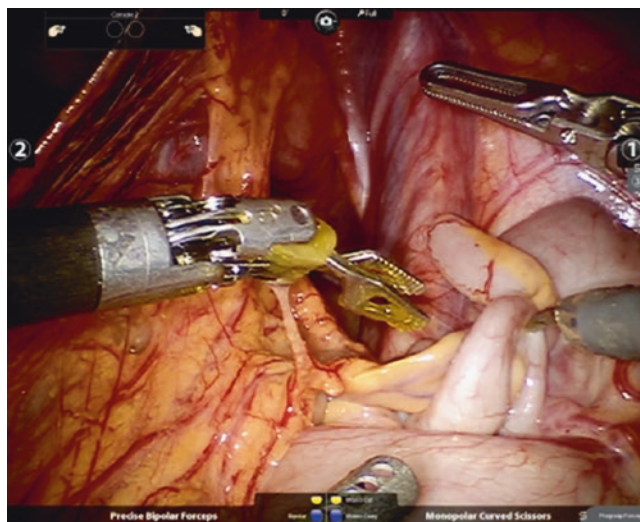


Fig. 45.4 Appendix prepared for isolation

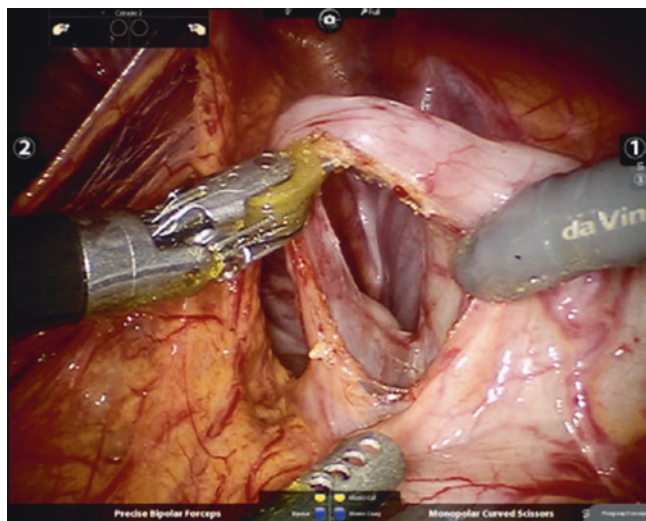


Fig. 45.5 Rent created in mesoappendix close to base, preserving appendicular artery

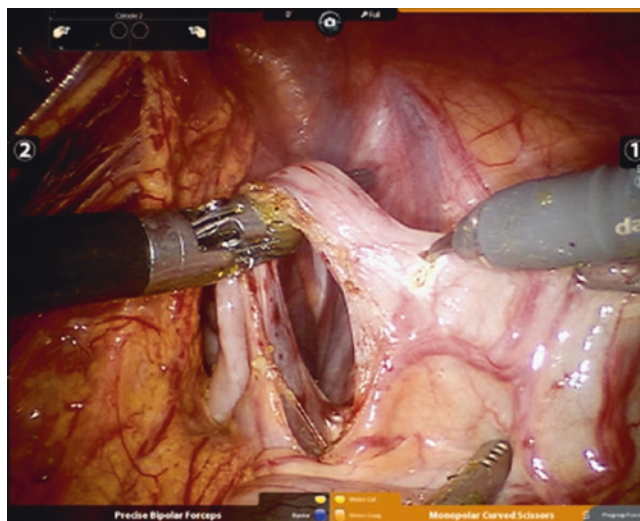


Fig. 45.6 Appendix being divided at the base

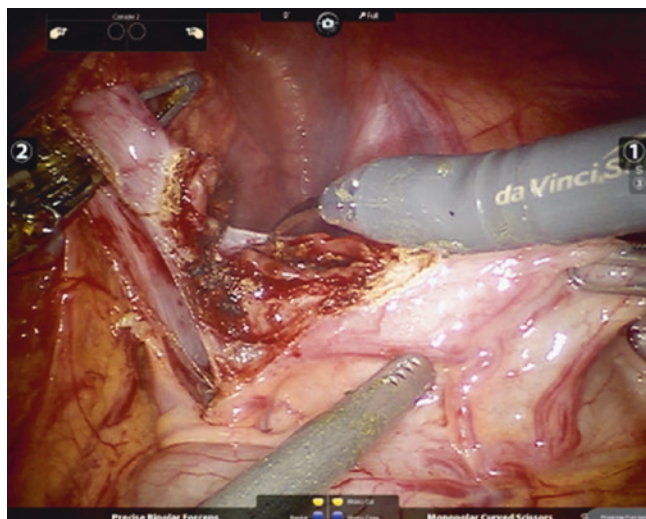


Fig. 45.7 Appendix division complete

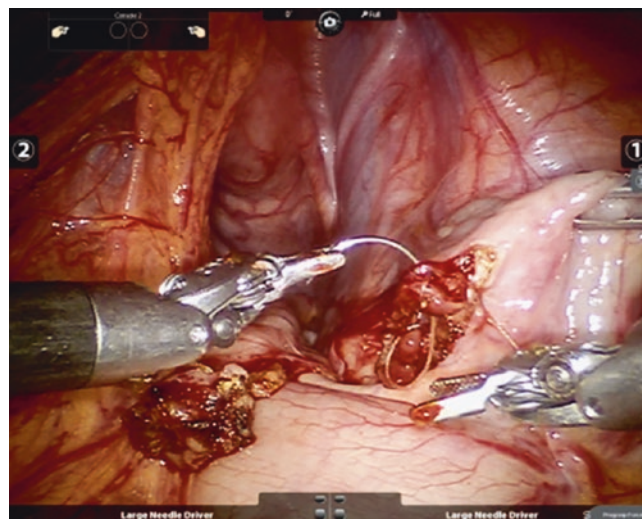


Fig. 45.8 Closure of caecum with 5-0 PDS in progress

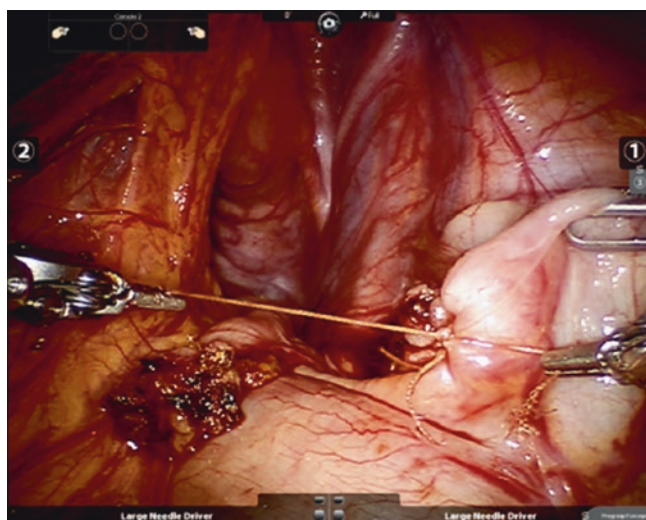


Fig. 45.9 Caecum closed and stump buried

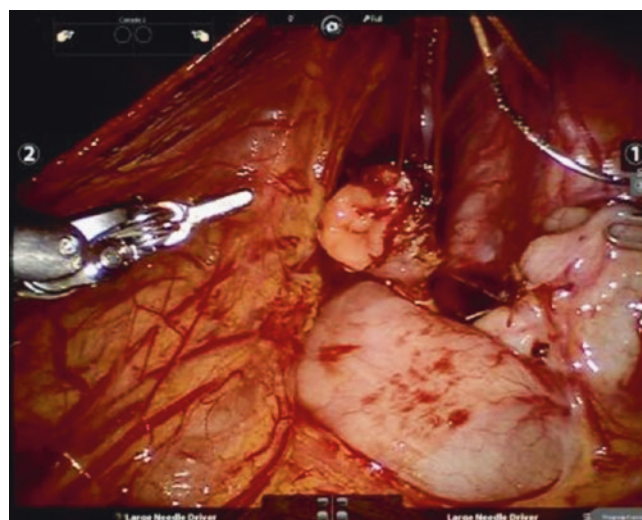


Fig. 45.10 Stay suture in appendix for identification

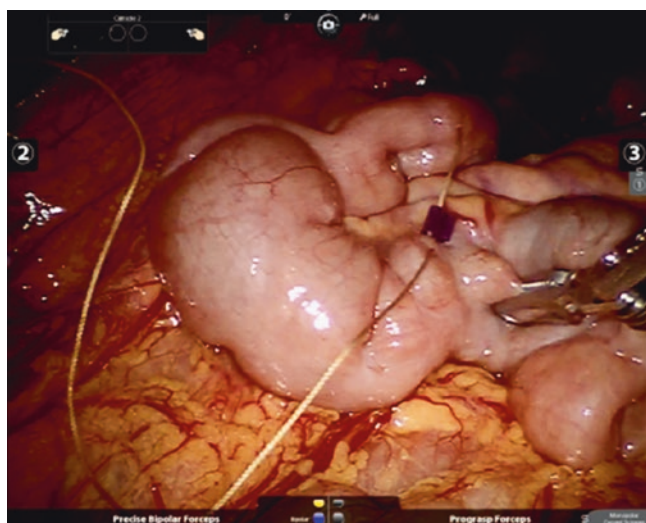

Fig. 45.11 Distal end of selected bowel segment marked with clips on vicryl suture. The suture length corresponds to the length of segment needed

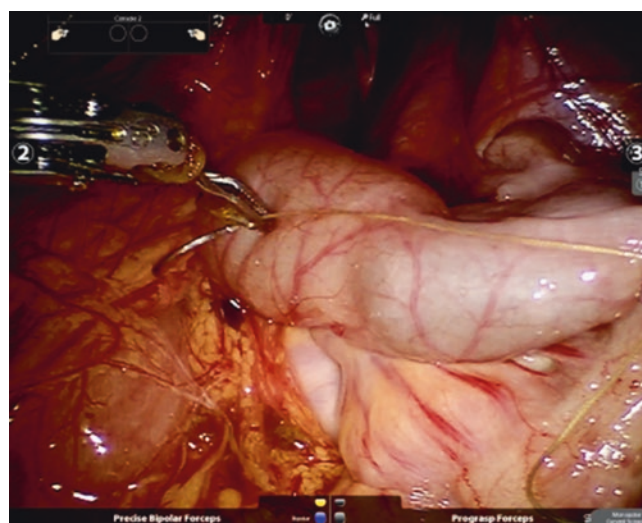


Fig. 45.12 Length of bowel segment measured with the suture. The proximal end of bowel segment selected is the needle end of the vicryl stay suture

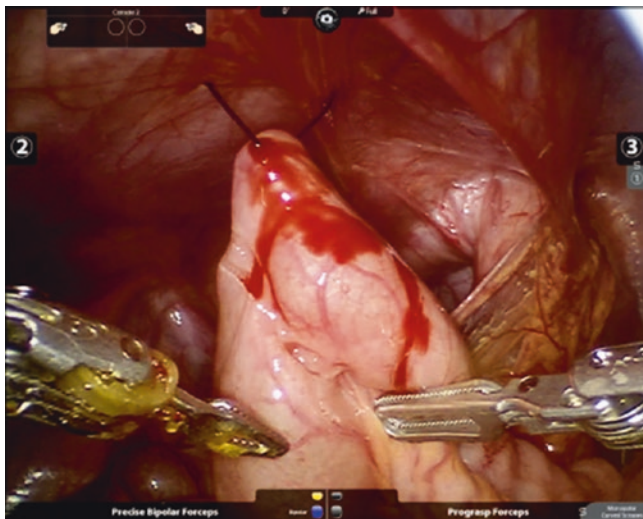


Fig. 45.13 Proximal end of selected bowel segment tacked to the anterior abdominal wall

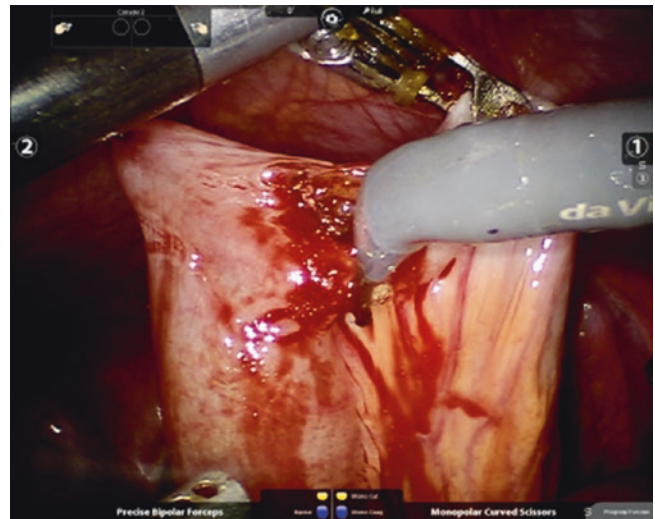


Fig. 45.14 Bowel segment proximal end division in progress

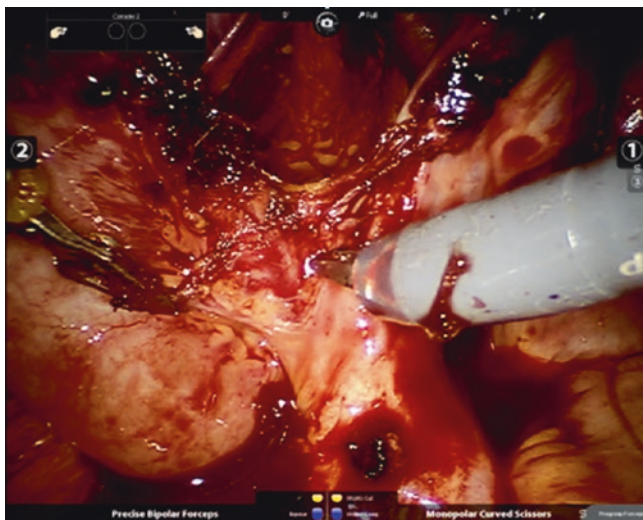


Fig. 45.15 Mesenteric division in progress

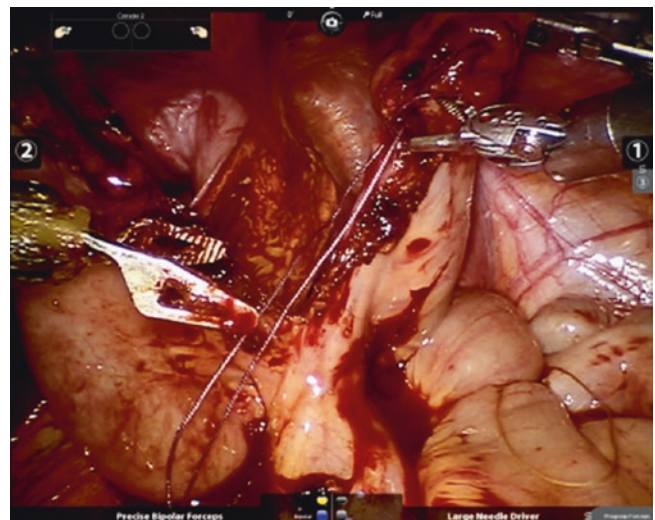


Fig. 45.16 Proximal end bowel segment division completed and stay suture at the distal end of bowel segment

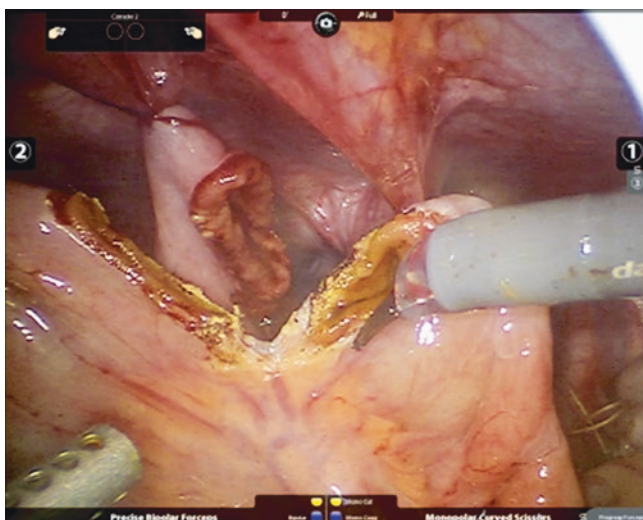


Fig. 45.17 Distal bowel segment end division in progress

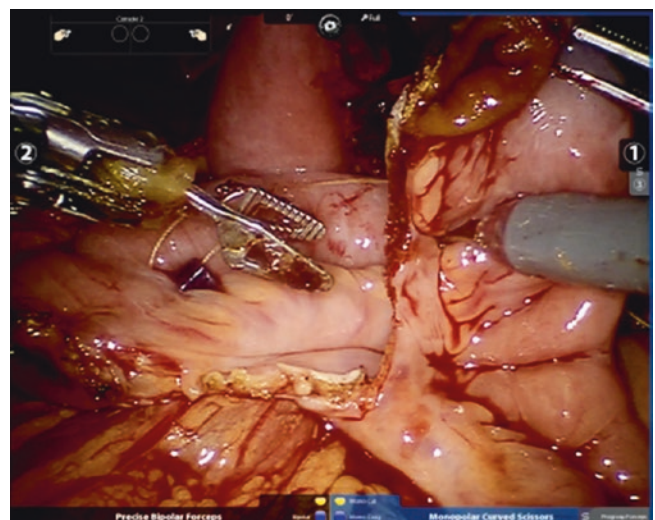

Fig. 45.18 Distal end bowel segment division completed

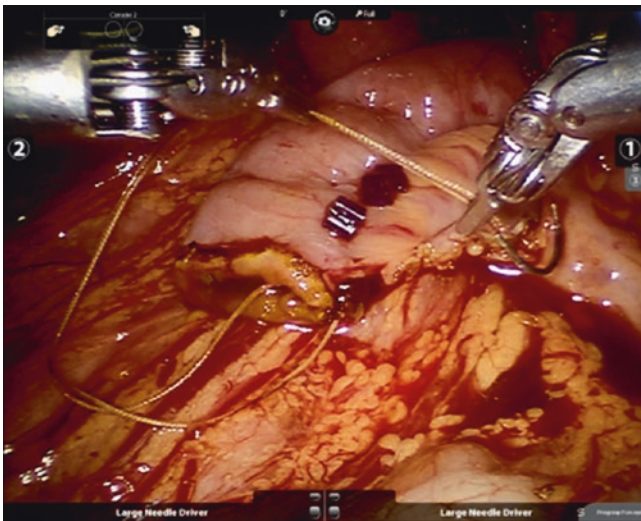


Fig. 45.19 Stay suture for distal end

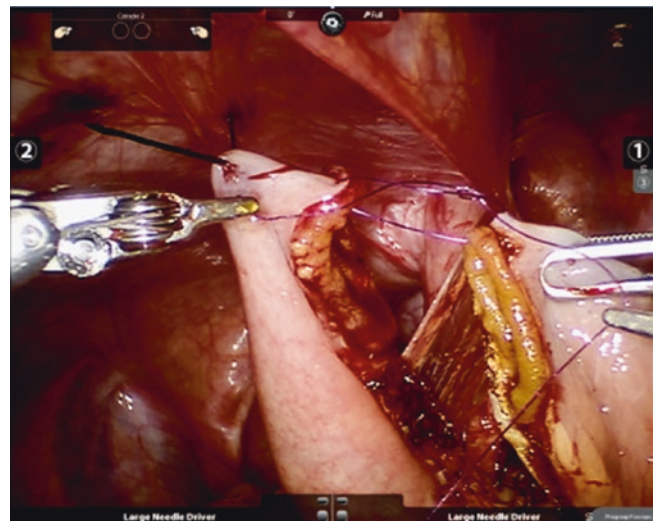


Fig. 45.20 Bowel anastomosis started with 4-0 PDS

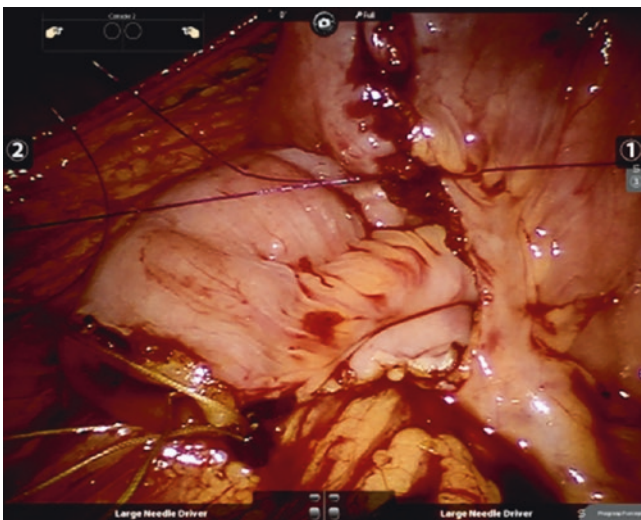


Fig. 45.21 Anterior layer suturing completed

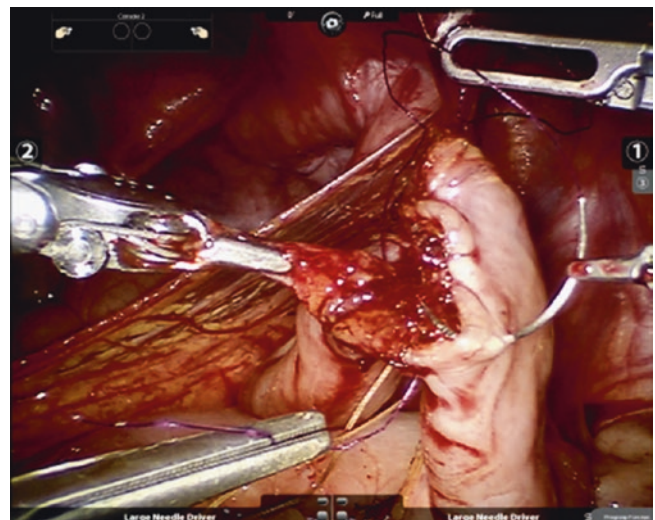


Fig. 45.22 Posterior layer suturing in progress

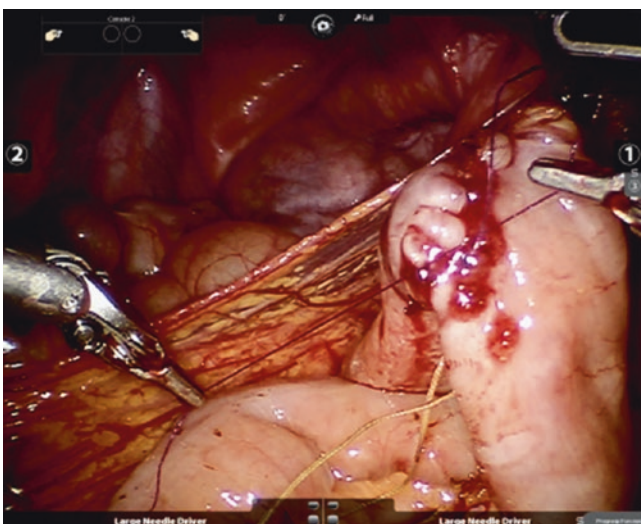


Fig. 45.23 Bowel anastomosis completed and ileoileal continuity restored

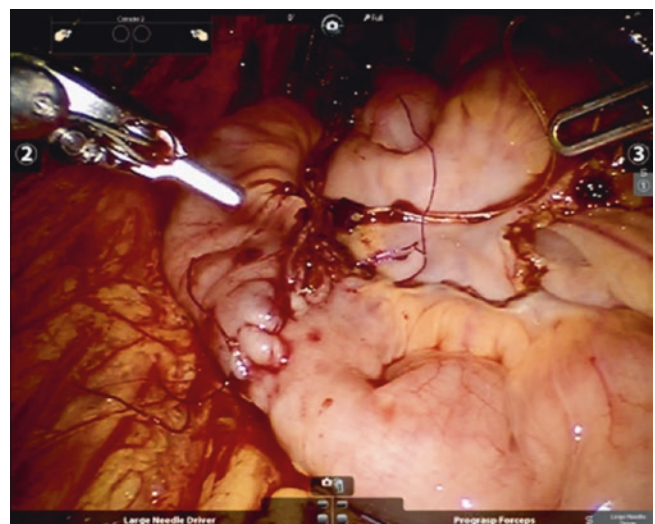

Fig. 45.24 Isolated segment brought beneath the anastomosis

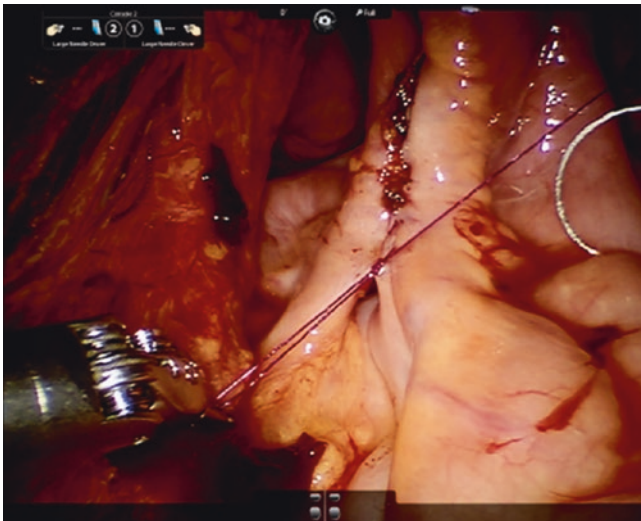


Fig. 45.25 Mesenteric rent closed

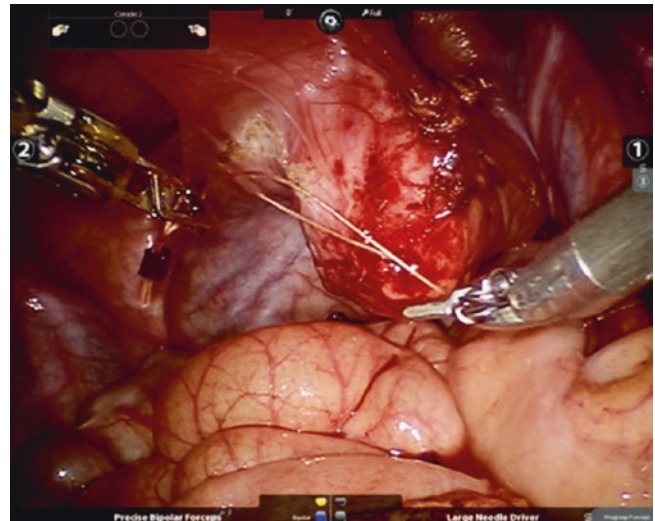


Fig. 45.26 Stay suture taken in the bladder

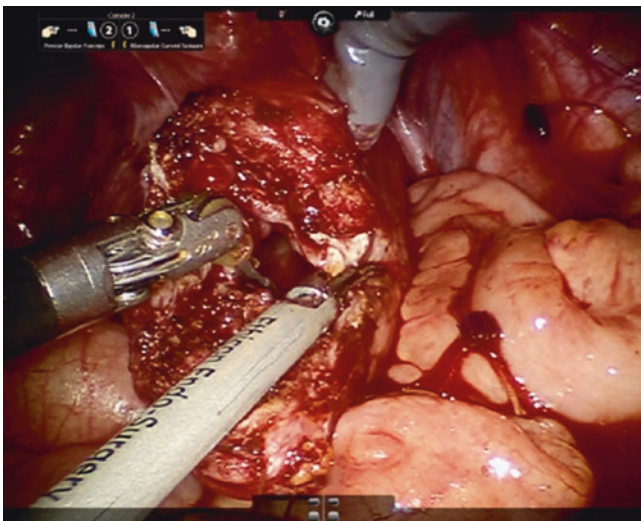


Fig. 45.27 Bladder bivalving in progress using ultrasonic shears

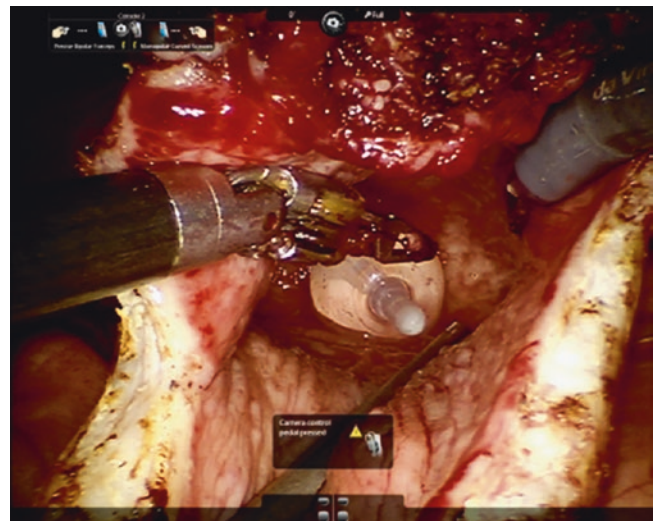


Fig. 45.28 Bladder incision in progress

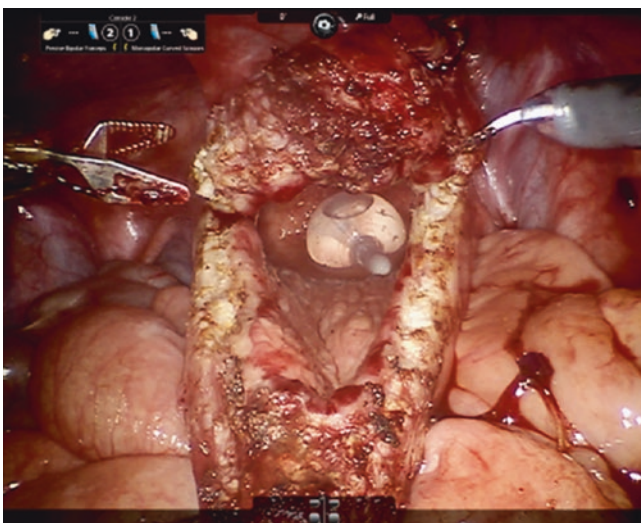


Fig. 45.29 Cystostomy completed

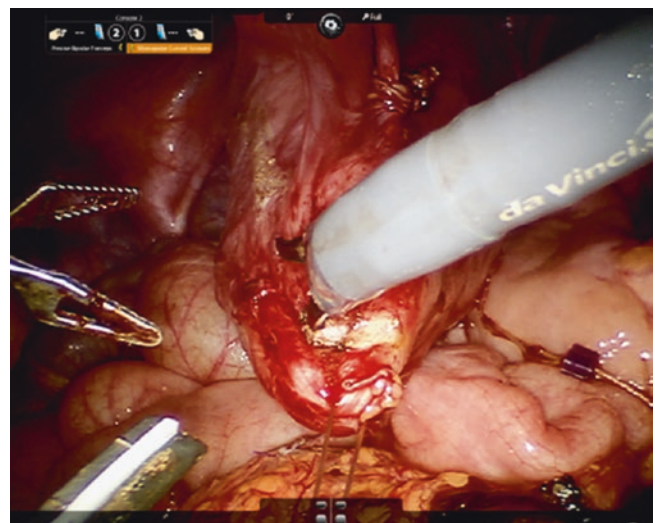


Fig. 45.30 Bladder opened by a separate incision (hiatus) to bring in appendix

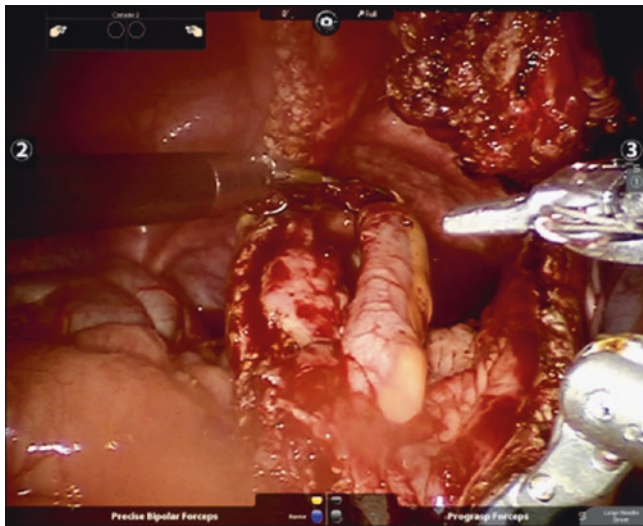

Fig. 45.31 Appendix brought into bladder

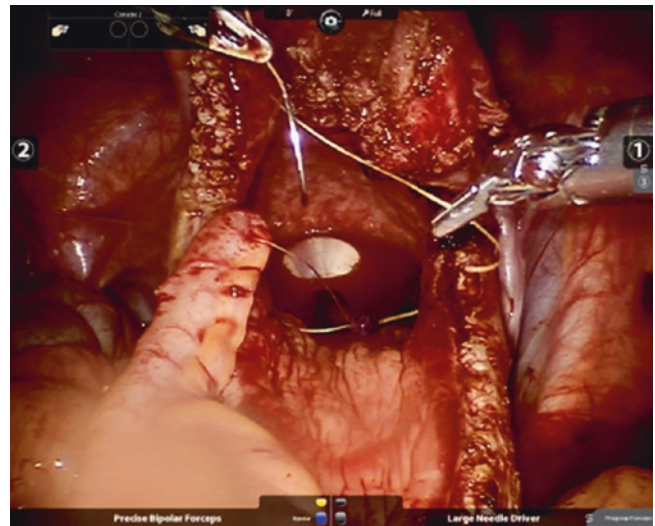

Fig. 45.32 Stay suture at the tip of appendix

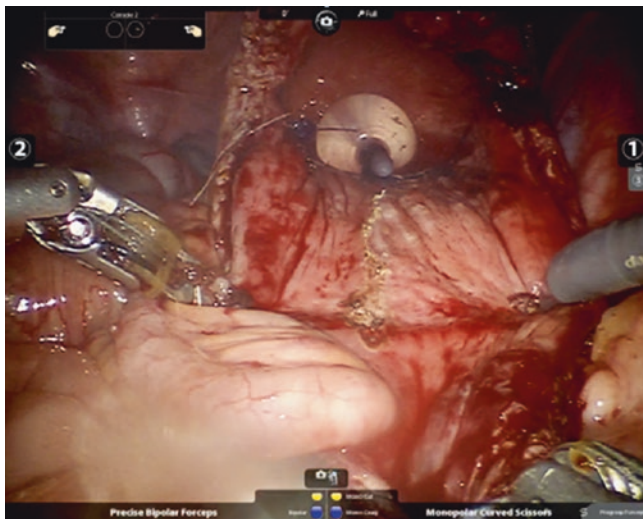


Fig. 45.33 Bladder mucosal incision for tunnelling of appendix

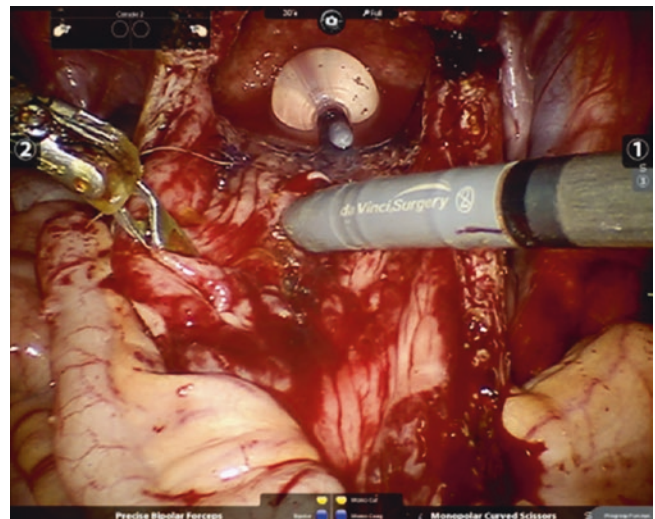


Fig. 45.34 Submucosal plane being created

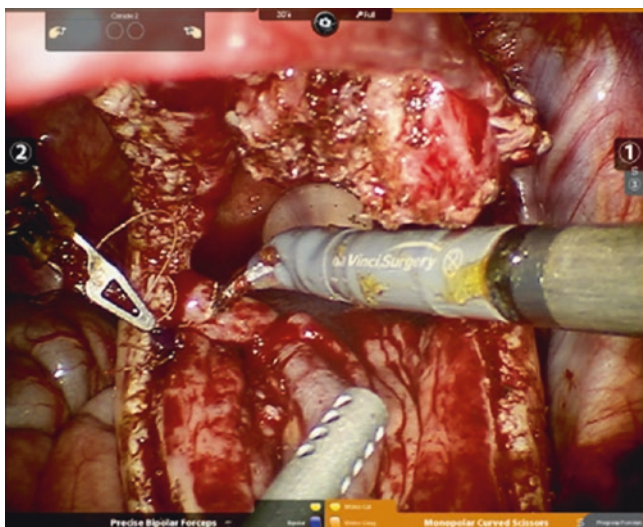


Fig. 45.35 Appendix tip cut

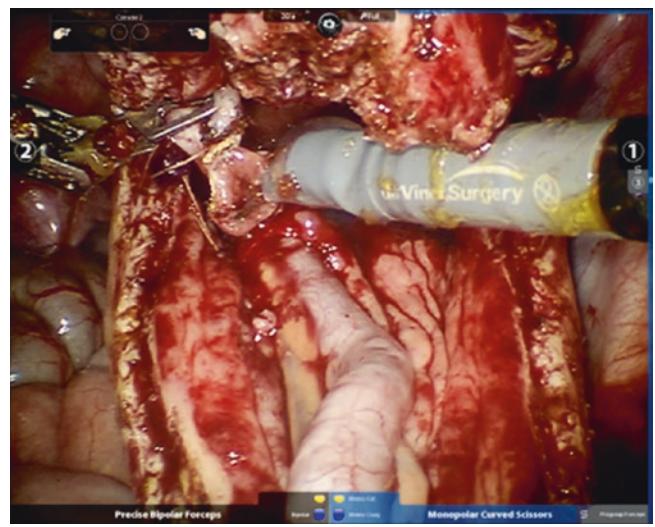

Fig. 45.36 Appendix tip spatulated

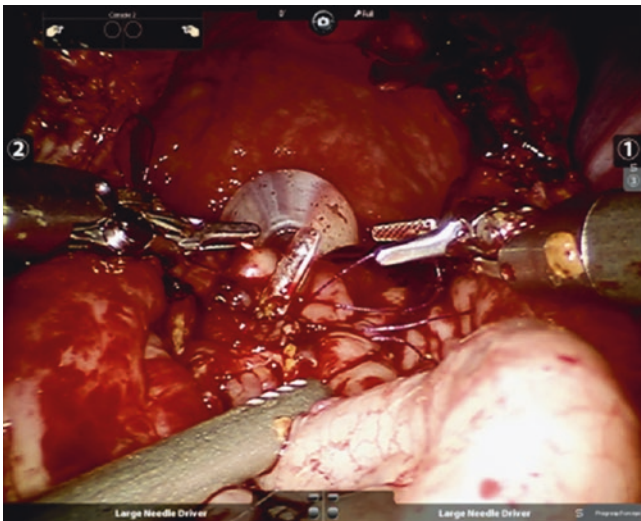


Fig. 45.37 Appendicovesicostomy with 5-0 PDS over 8 fr feeding tube

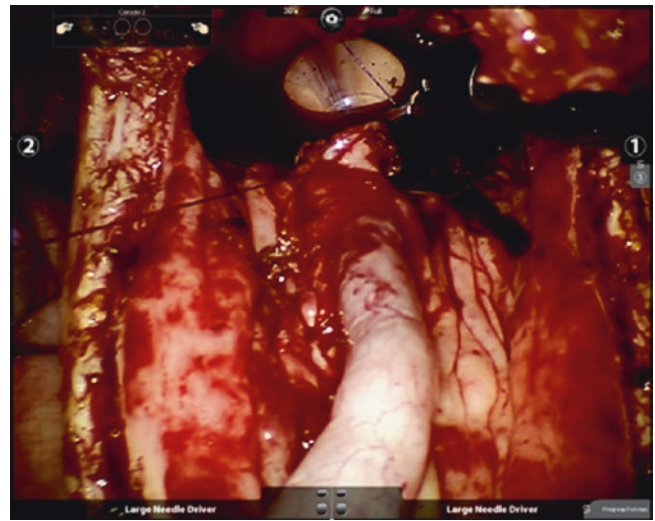


Fig. 45.38 Appendicovesicostomy in progress

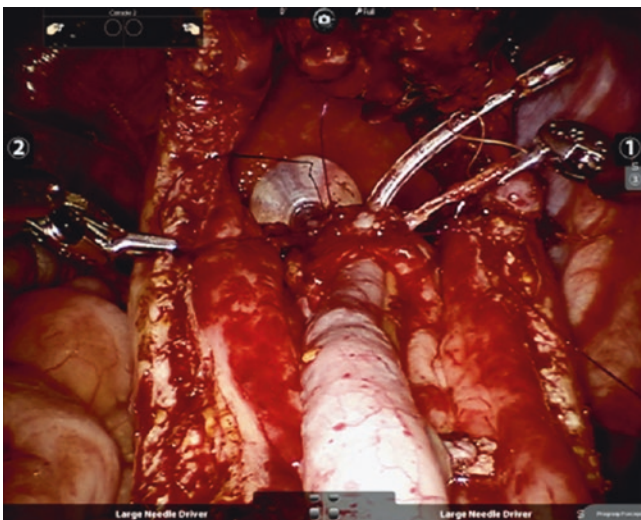


Fig. 45.39 Appendicovesicostomy in progress

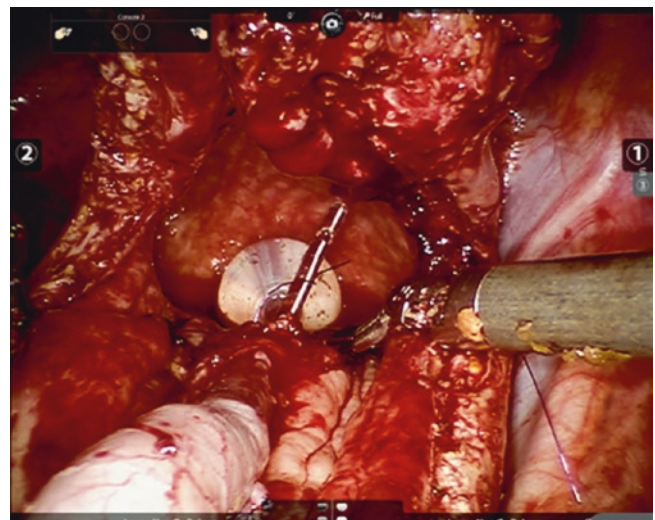


Fig. 45.40 Mucosal suturing completed

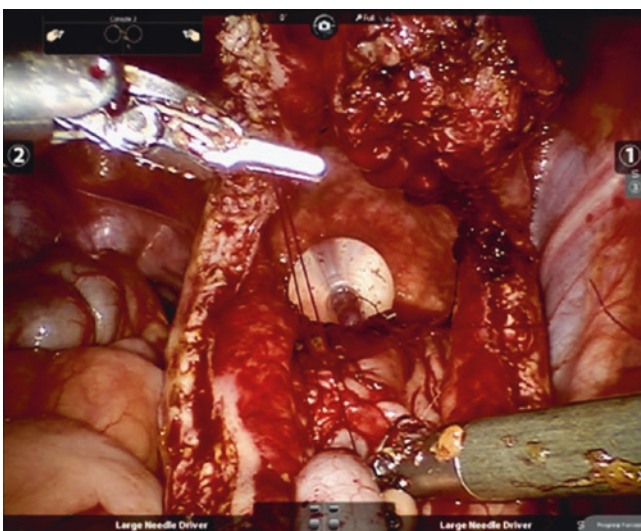


Fig. 45.41 Bladder mucosal covering over appendix in progress

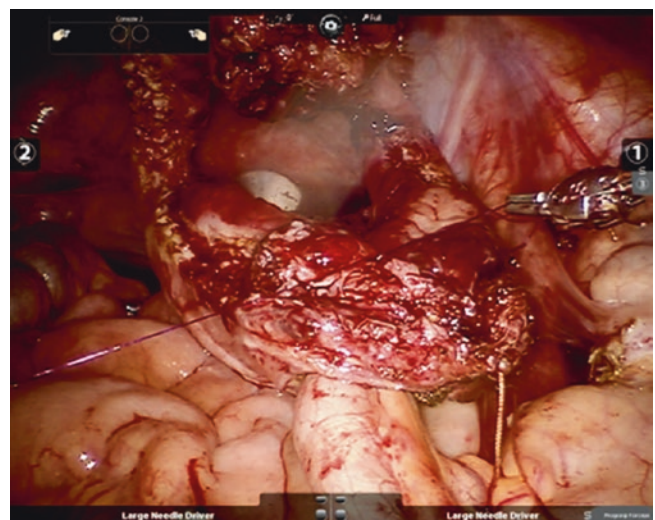


Fig. 45.42 Appendix completely buried in bladder mucosa

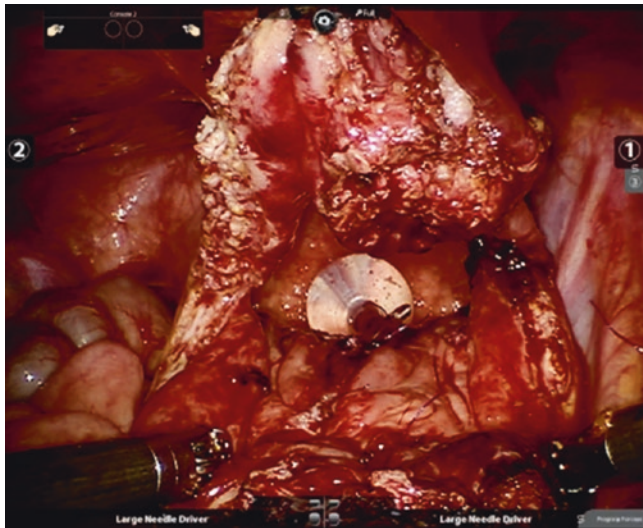


Fig. 45.43 Completed appendicovesicostomy

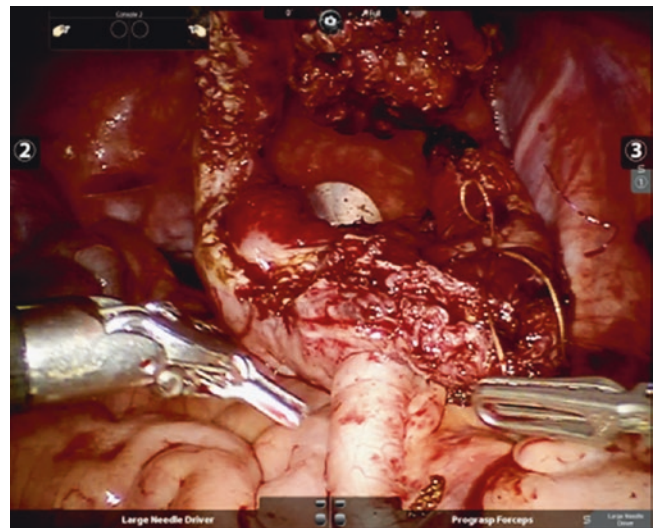


Fig. 45.44 Appendix seen entering the bladder

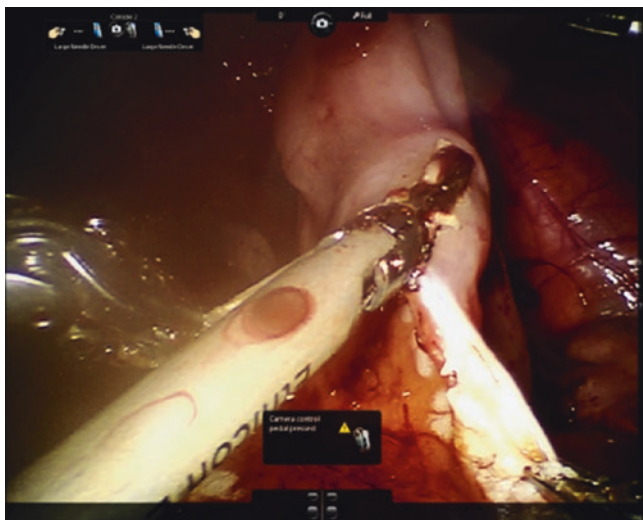


Fig. 45.45 Isolated ileum detubularised

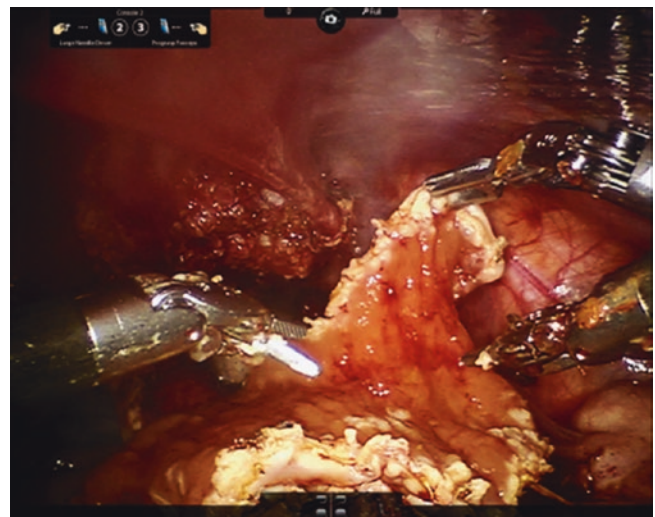


Fig. 45.46 Ileal detubularisation completed

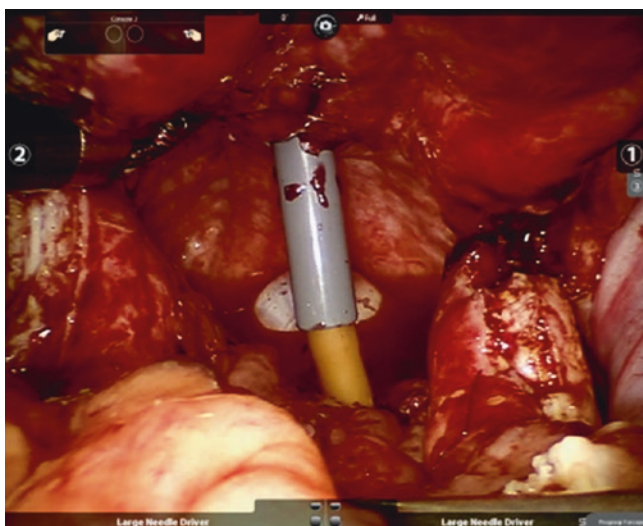


Fig. 45.47 Suprapubic catheter inserted

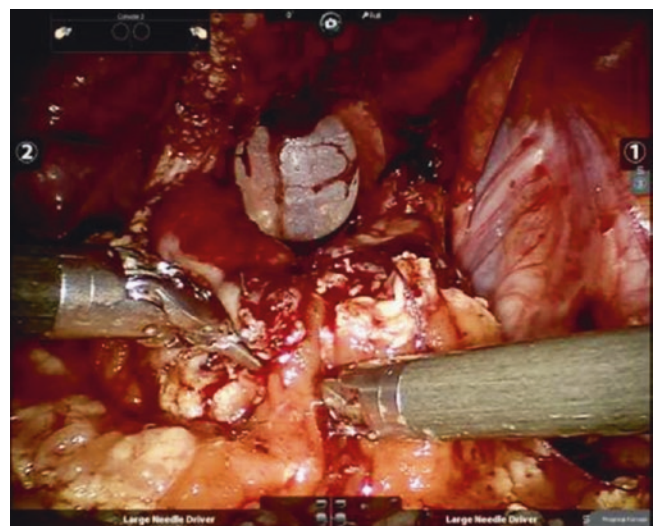


Fig. 45.48 Augmentation started from dome of bladder using 3-0 PDS suture

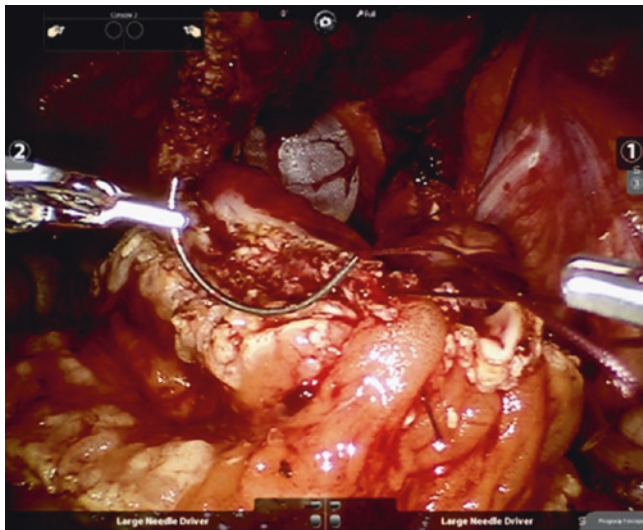


Fig. 45.49 Augmentation in progress

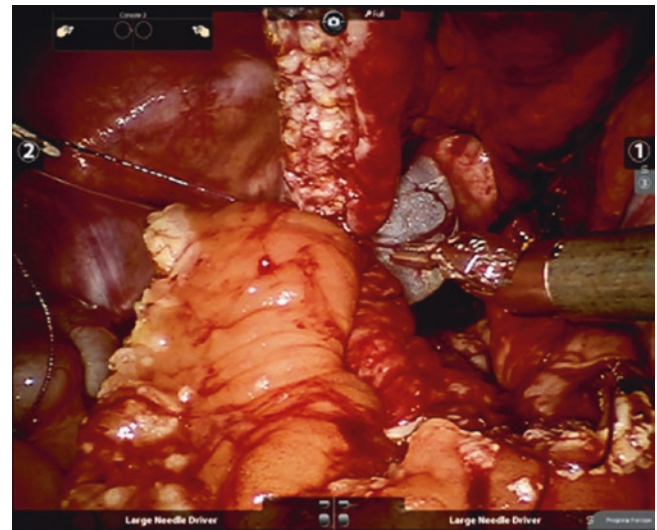


Fig. 45.50 Augmentation in progress – second suture started from left corner

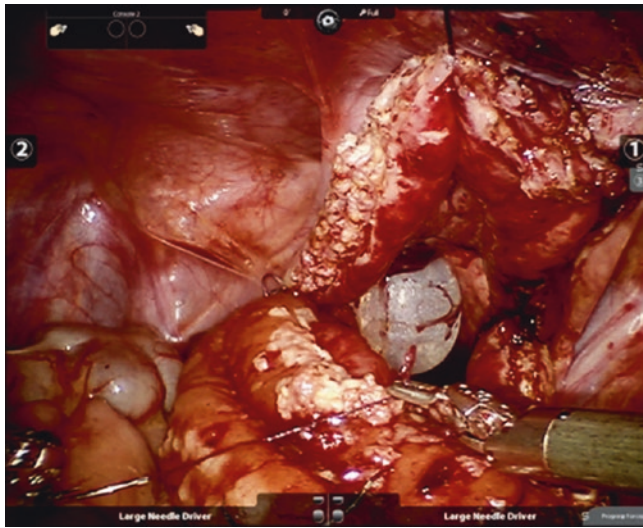


Fig. 45.51 Augmentation in progress

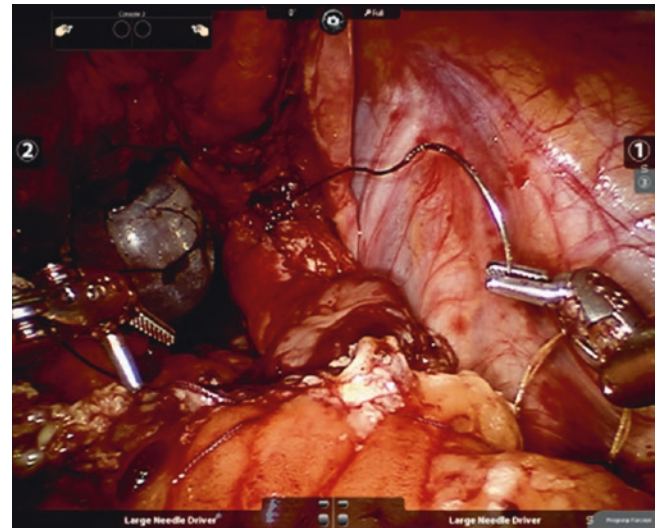


Fig. 45.52 Augmentation in progress – third suture from right corner

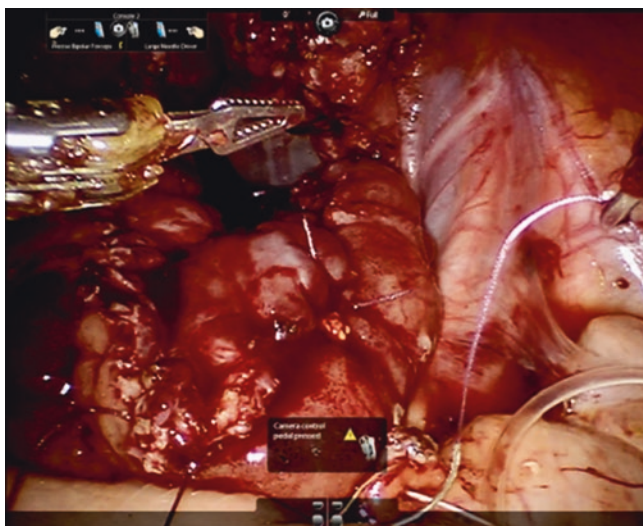


Fig. 45.53 Posterior layer completed

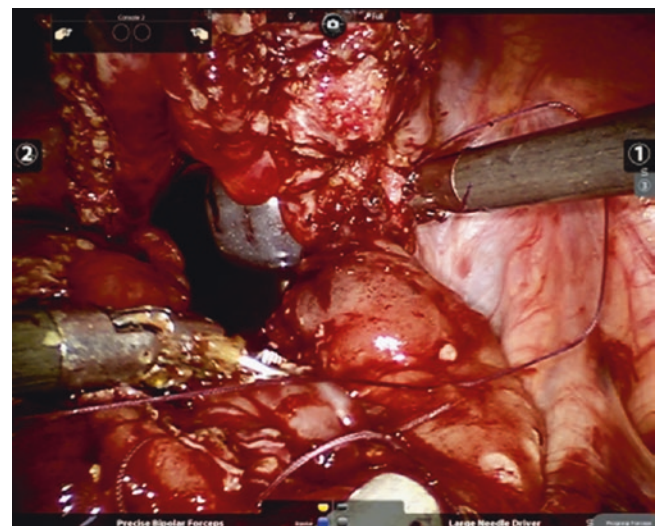


Fig. 45.54 Augmentation in progress – anterior layer started from right corner

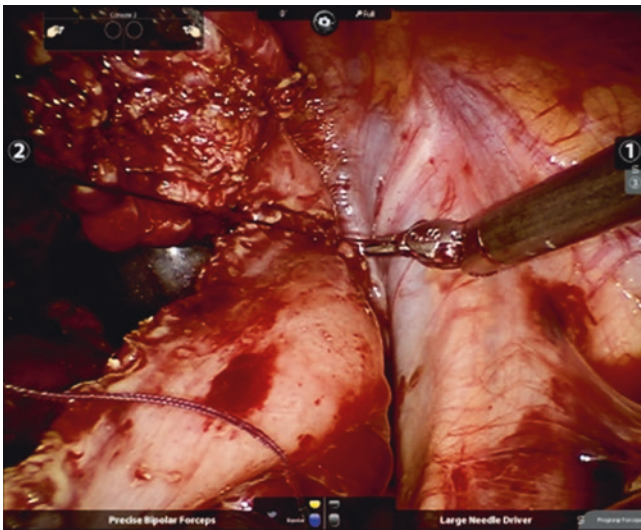


Fig. 45.55 Augmentation – anterior layer in progress

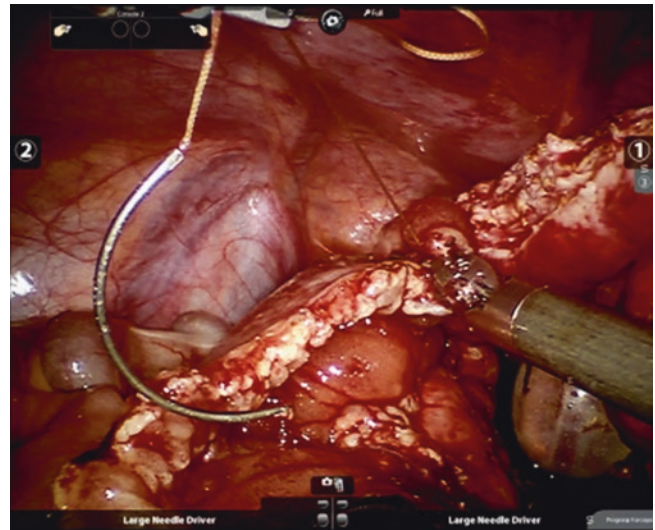


Fig. 45.56 Augmentation – anterior layer suture from left corner

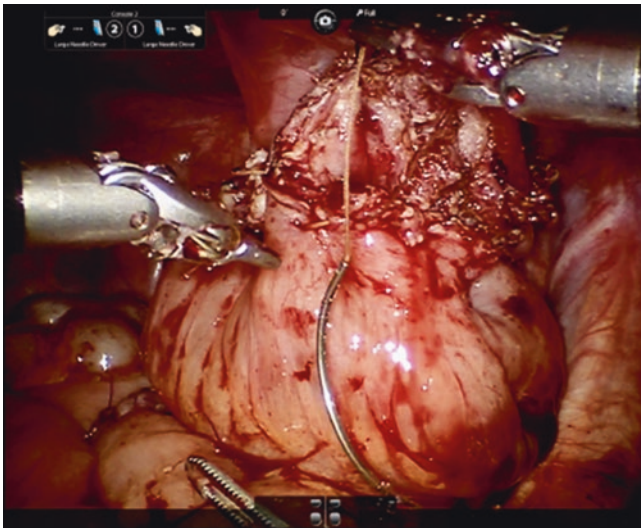


Fig. 45.57 Anterior layer completed

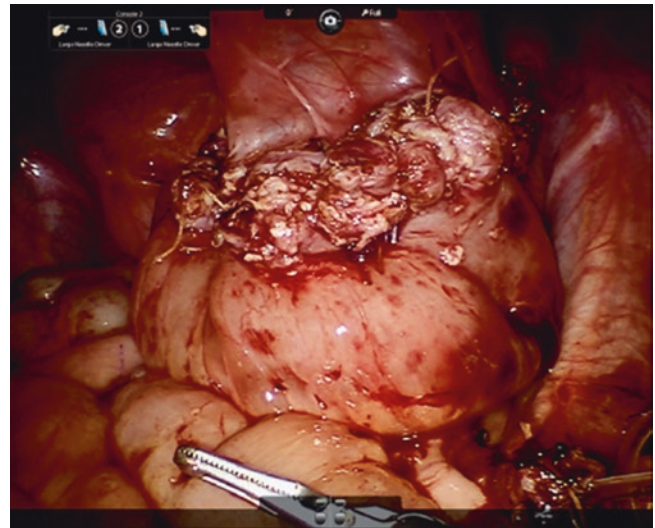


Fig. 45.58 Bladder distended to check for leak

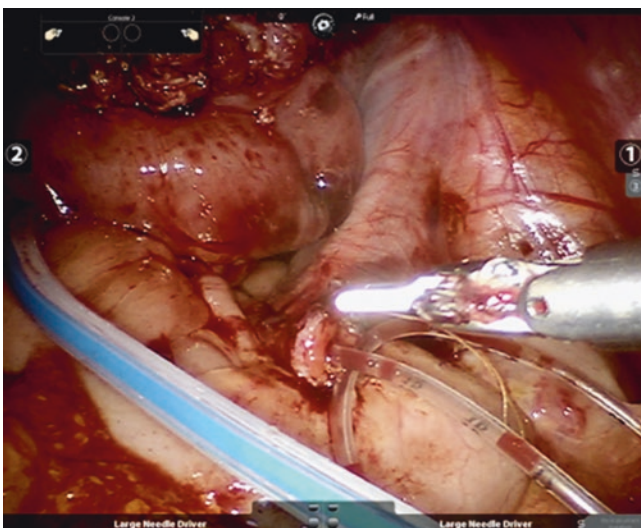


Fig. 45.59 Drain placed

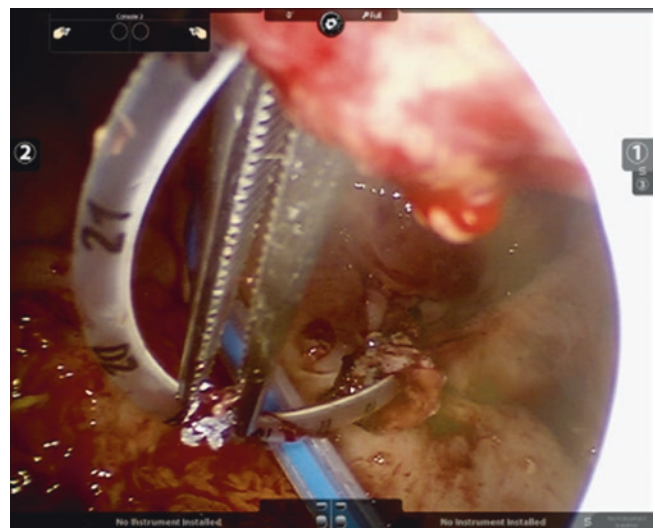


Fig. 45.60 Artery forceps inserted through abdominal wall stoma site and appendix stay suture grasped for stoma creation

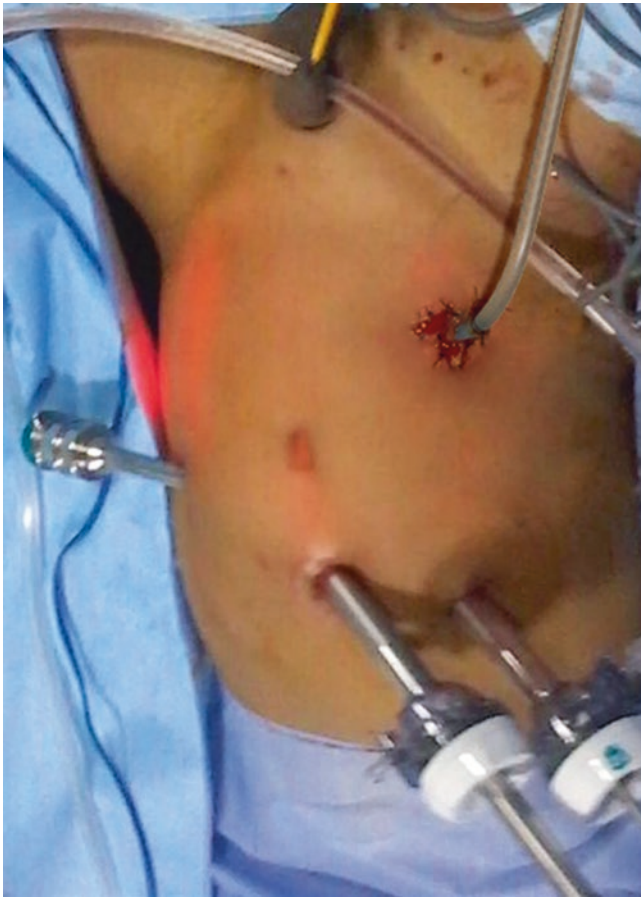

Fig. 45.61 Stoma location – external view

References

1. Famakinwa O, Gundeti MS. Robotic assisted laparoscopic mitrofanoff appendicovesicostomy (RALMA). *Curr Urol Rep.* 2013;14: 41–5.
2. Orvieto MA, Large M, Gundeti MS. Robotic paediatric urology. *BJU Int.* 2012;110:2–13.
3. Marchetti P, Razmaria A, Zagaja GP, et al. Management of the ventriculo-peritoneal shunt in pediatric patients during robot-assisted laparoscopic urologic procedures. *J Endourol.* 2011;25: 225–9.
4. Wille MA, Jayram G, Gundeti MS. Feasibility and early outcomes of robotic-assisted laparoscopic Mitrofanoff appendicovesicostomy in patients with prune belly syndrome: outcomes in patients with prune belly syndrome undergoing RALMA. *BJU Int.* 2012;109: 125–9.
5. Berkowitz J, North AC, Tripp R, et al. Mitrofanoff continent catheterizable conduits: top down or bottom up? *J Pediatr Urol.* 2009;5:122–5.
6. Murthy P, Cohn JA, Selig RB, et al. Robot-assisted laparoscopic augmentation ileocystoplasty and Mitrofanoff appendicovesicostomy in children: updated interim results. *Eur Urol.* 2015;68:1069–75.
7. Famakinwa OJ, Rosen AM, Gundeti MS. Robot-assisted laparoscopic Mitrofanoff appendicovesicostomy technique and outcomes of extravesical and intravesical approaches. *Eur Urol.* 2013;64:831–6.
8. Leslie B, Lorenzo AJ, Moore K, et al. Long-term followup and time to event outcome analysis of continent catheterizable channels. *J Urol.* 2011;185:2298–302.
9. Grimsby GM, Jacobs MA, Gargollo PC. Comparison of complications of robot-assisted laparoscopic and open appendicovesicostomy in children. *J Urol.* 2015;194:772–6.
10. Chang C, et al. Patient positioning and port placement for robot-assisted surgery. *J Endourol.* 2014;28(6):631–8.

Nian Zeng and Yinong Niu

46.1 Introduction

Radical cystectomy is the treatment of choice for muscle invasive carcinoma bladder [1]. Ileal conduit is the preferred type of urinary diversion, especially in patients with positive distal margins, prostatic urethral involvement and those not keen on self catheterization [2]. Completely intracorporeal ileal conduit urinary diversion avoids the need for larger incision as in laparoscopy assisted approach.

46.2 Method

Under general anesthesia patient is placed in supine position with steep Trendelenburg tilt. The steps of radical cystectomy are standardized. Initially peritoneotomy made over the iliac vessels, closer to the pelvic brim and the ureters are dissected out from the pelvic brim proximally to bladder distally. Then, peritoneotomy on both sides are joined on the posterior wall of the bladder. Peritoneum dissected away from the bladder, vas and seminal vesicles. Dissection proceeds as far inferiorly as possible towards the prostate apex in male patient and up to bladder neck in female patients. Lateral dissection is done and bladder mobilized from the lateral pelvic wall. This delineates the lateral pedicle which can be managed with staplers or clips. Bladder is dropped down and endopelvic fascia incised on both sides. Dorsal venous complex ligated and cut and prostatic pedicles clipped and cut. Denonvillier's fascia incised and prostate dissected from rectum.

Prostate apex dissected and urethra clipped and cut. Left ureter is tunneled towards the right iliac fossa beneath the sigmoid mesentery. Both ureters are fixed to the anterior abdominal wall for easy identification. A 15–20 cm terminal ileal segment is isolated using staplers. Ten centimeters long umbilical tape bit is used for measuring the lengths. Both ureters are stented and uretero ileal anastomosis done by Bricker method with 4-0 vicryl sutures, towards the proximal end of ileal segment. The distal end is brought out through the abdominal wall as conduit stoma. Specimen is retrieved through Pfannenstiel incision after placing a drain. In female patients cystectomy may be combined with hysterectomy and whole specimen can be removed through colpotomy.

46.3 Discussion

Intracorporeal ileal segment isolation and uretero ileal anastomosis is the most difficult part of the procedure. It requires adept handling of the bowel, staplers and fine suturing skills for uretero ileal anastomosis [3].

46.4 Conclusion

Totally intracorporeal ileal conduit urinary diversion, though technically demanding, is definitely feasible. It provides the patients with a real minimally invasive option, especially females, in whom specimen can be retrieved through the vagina.

N. Zeng (✉) • Y. Niu, MD
Beijing Chaoyang Hospital, Beijing, China
e-mail: nianzeng2006@vip.sina.com; niuyinong@urologist.md

46.5 Laparoscopic Radical Cystectomy with Intracorporeal Ileal Conduit

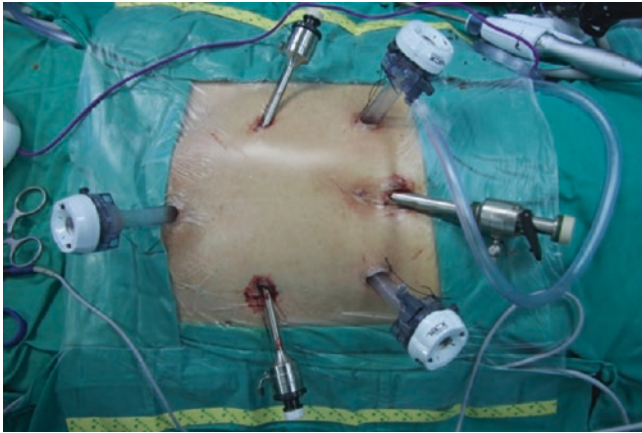


Fig. 46.1 Ports position

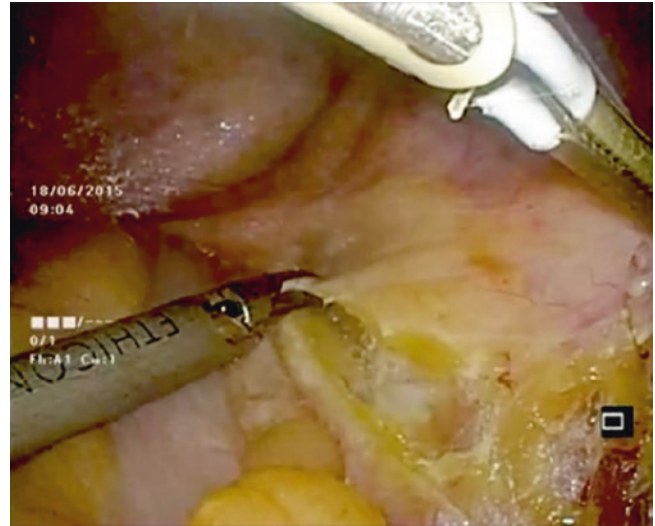


Fig. 46.2 Peritoneal incision over the iliac vessels to isolate right ureter

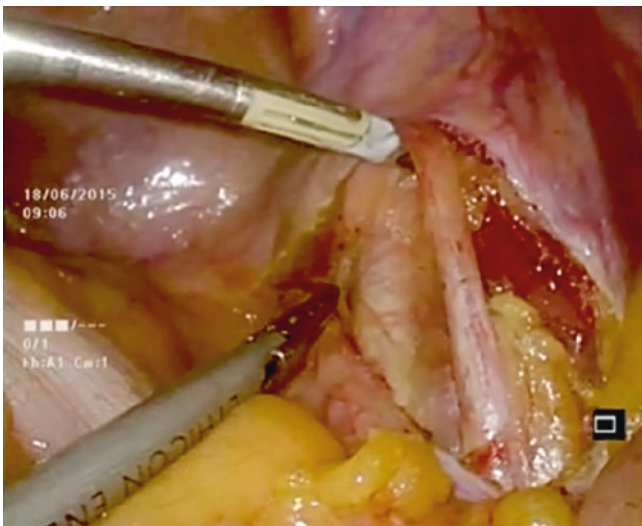


Fig. 46.3 Right ureter isolated

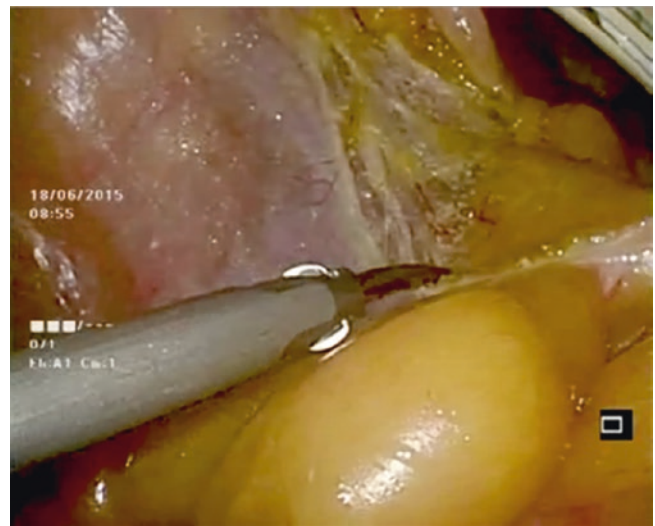


Fig. 46.4 Sigmoid colon reflected for left ureter isolation

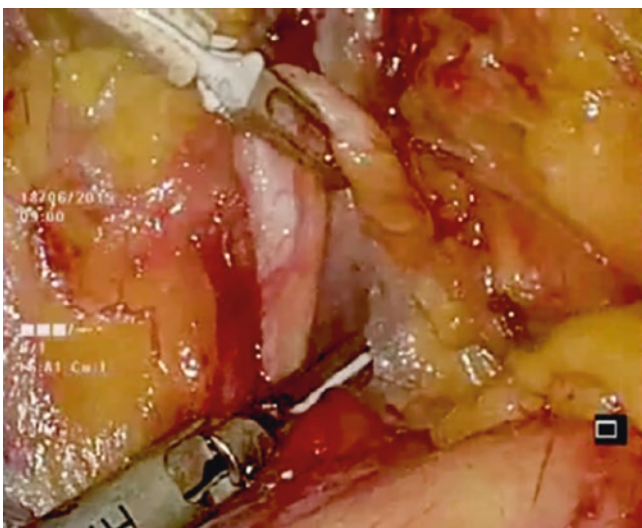


Fig. 46.5 Left ureter isolated

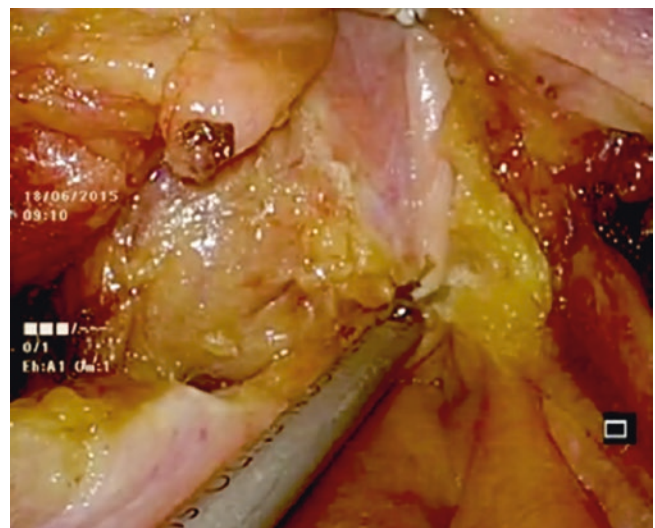


Fig. 46.6 Right and left peritoneal incisions connected in midline behind bladder

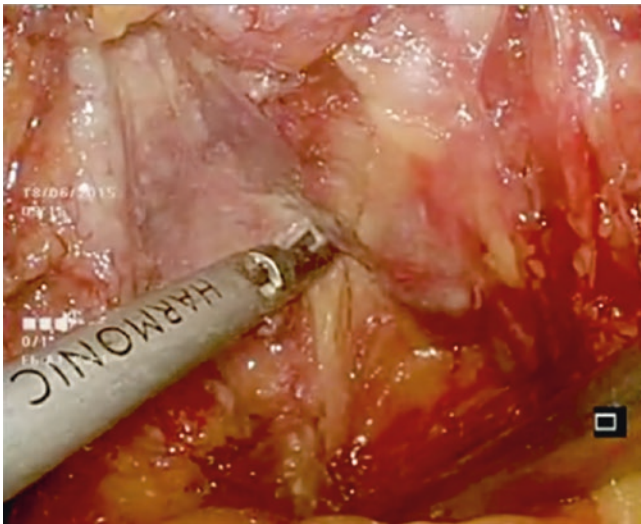


Fig. 46.7 Bladder dissected off the rectum

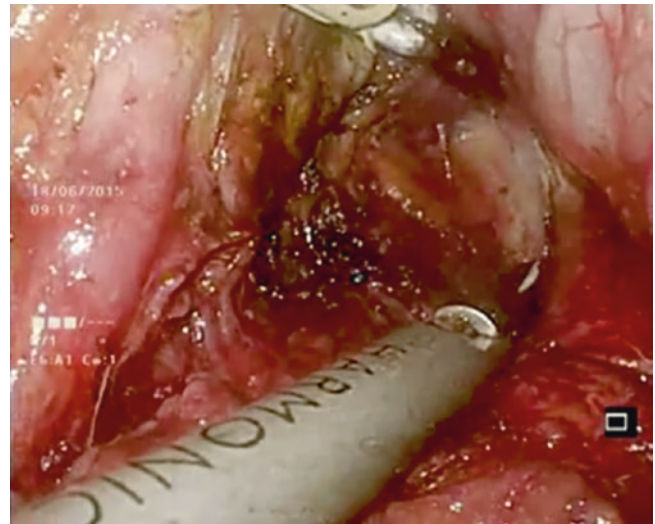


Fig. 46.8 Posterior dissection continued till prostate apex

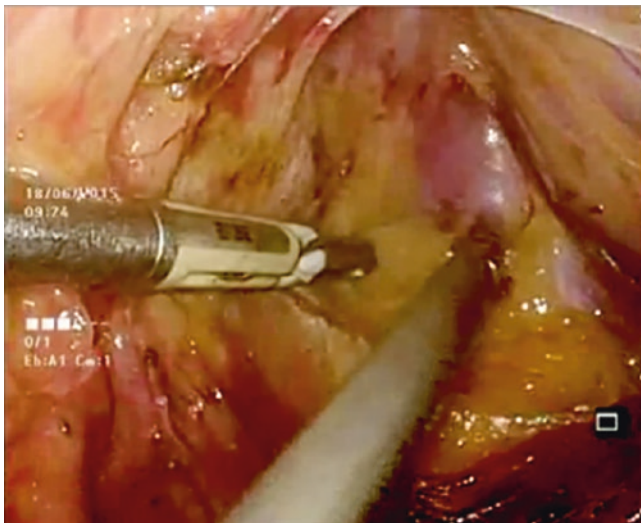


Fig. 46.9 Lateral dissection along the pelvic wall on the left side

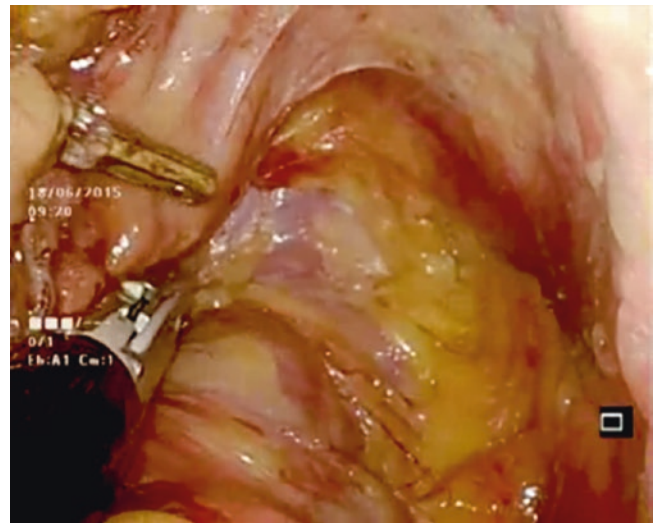


Fig. 46.10 Lateral dissection of the bladder along the lateral pelvic wall on the right side

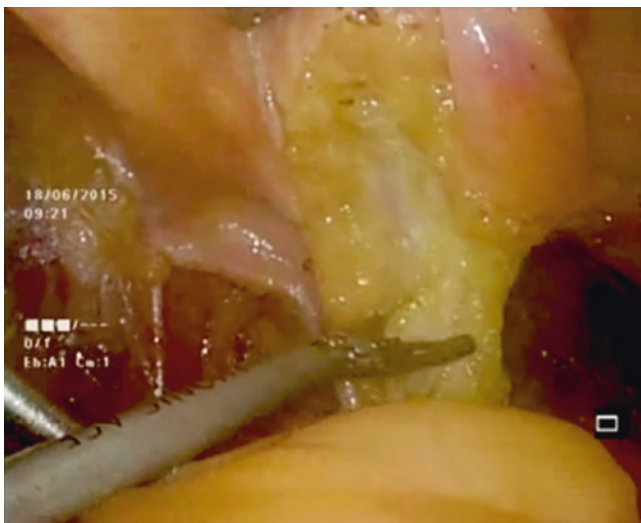


Fig. 46.11 Development of Retzius space by dividing umbilical ligaments

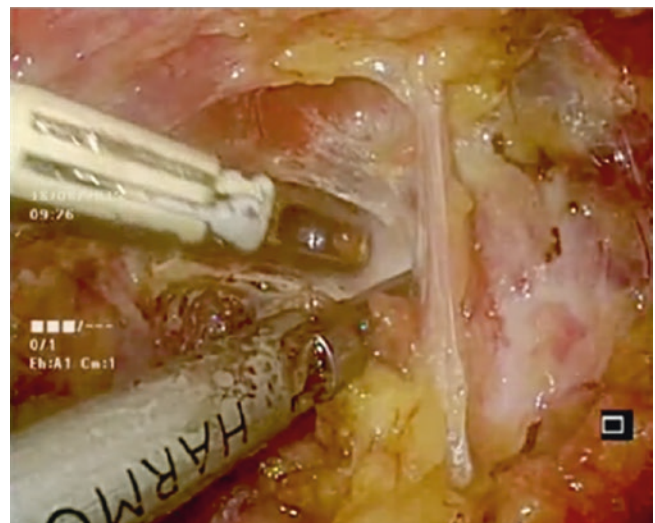


Fig. 46.12 Endopelvic fascia incised on the left side

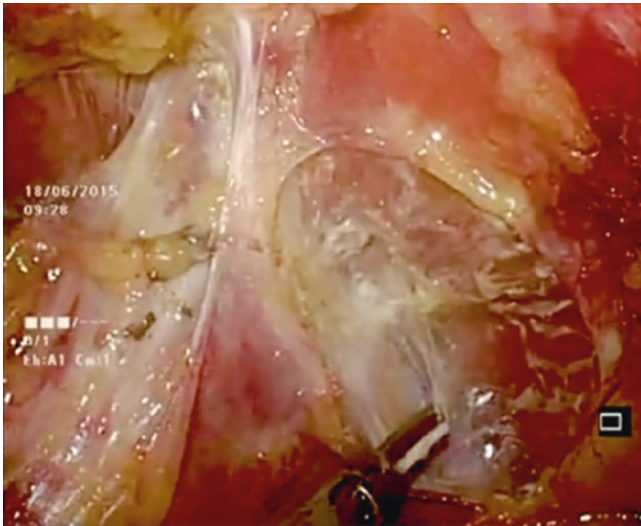


Fig. 46.13 Right side endopelvic fascia incised

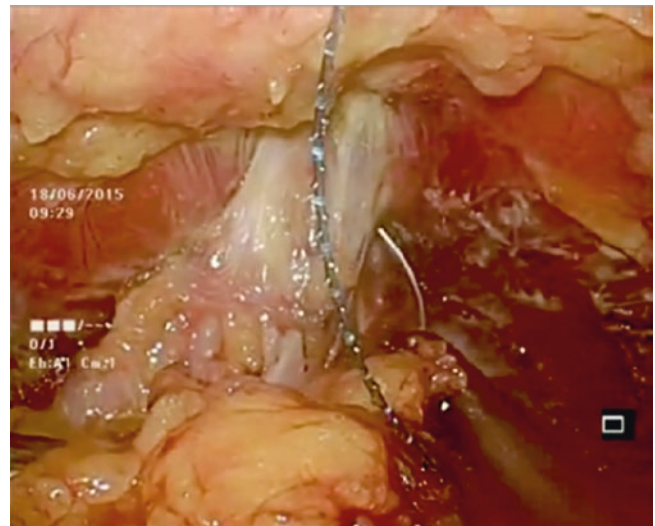


Fig. 46.14 DVC suturing in progress

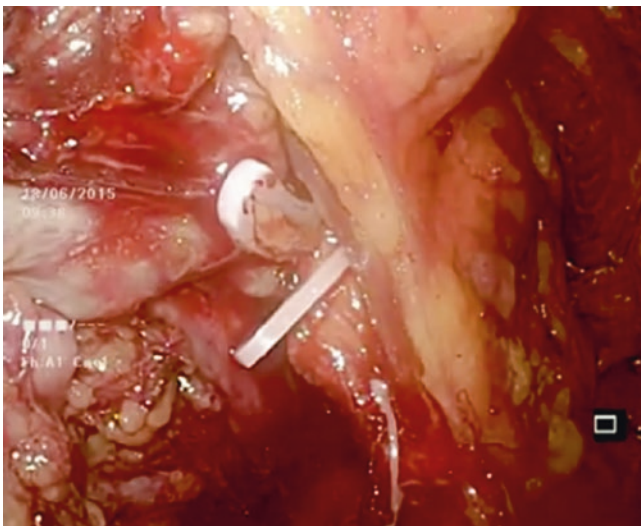


Fig. 46.15 Right lateral pedicle being controlled

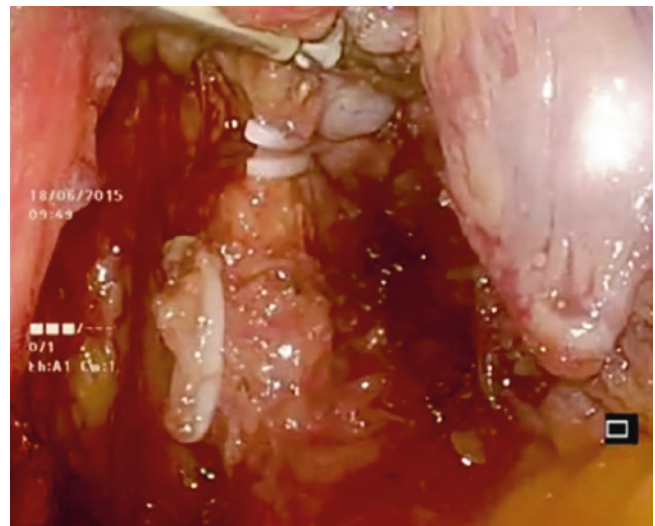


Fig. 46.16 Left lateral pedicle being controlled

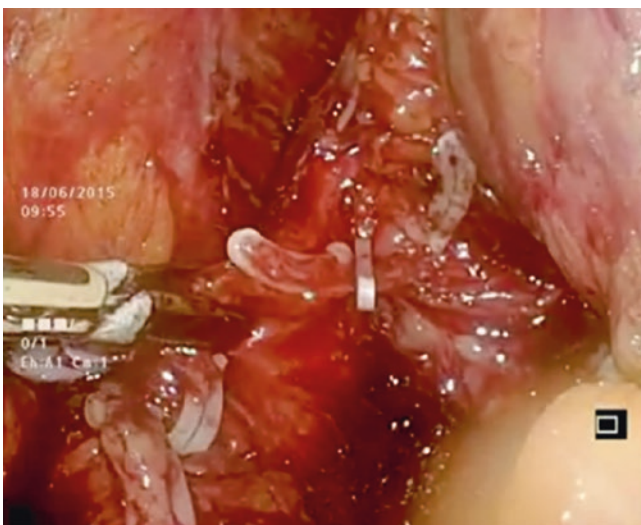


Fig. 46.17 Prostatic lateral pedicles being controlled

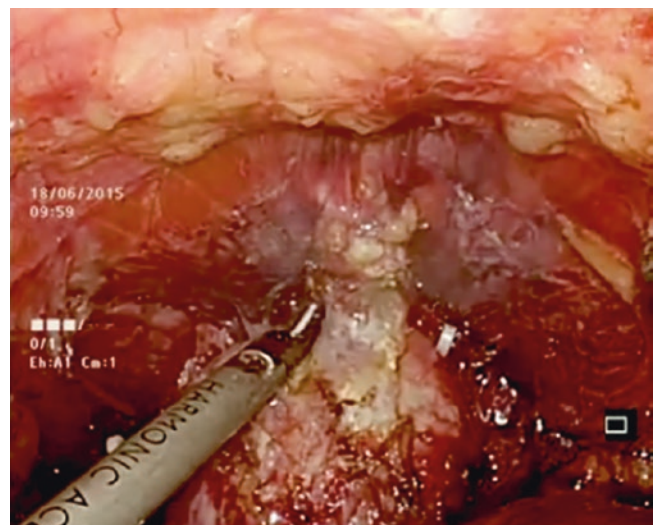


Fig. 46.18 DVC divided

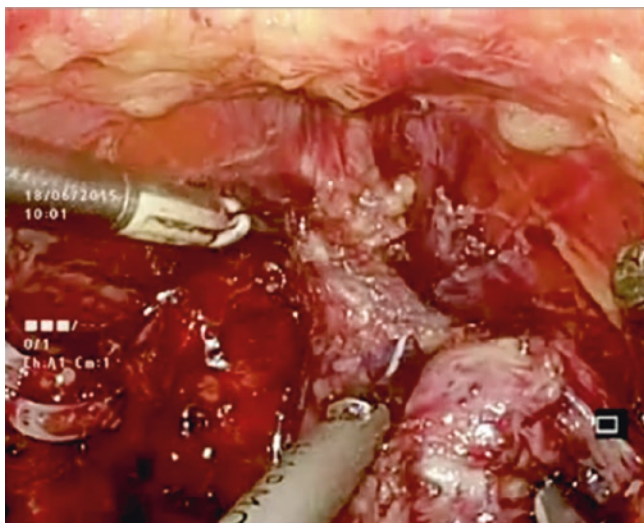


Fig. 46.19 Prostate apical dissection in progress

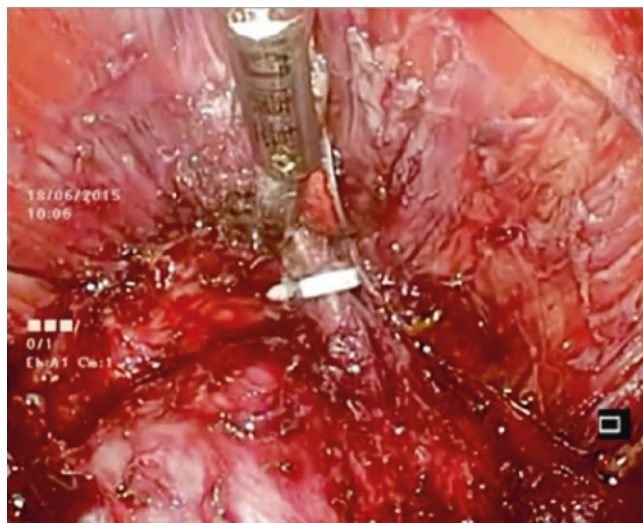


Fig. 46.20 Urethra clipped and divided

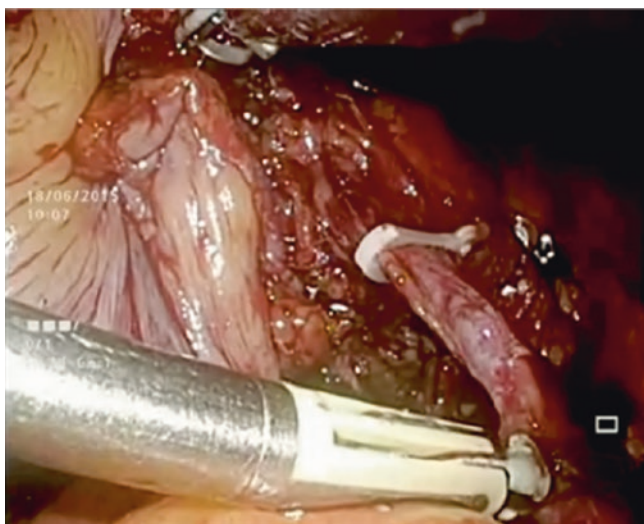


Fig. 46.21 Right ureter clipped and about to be divided

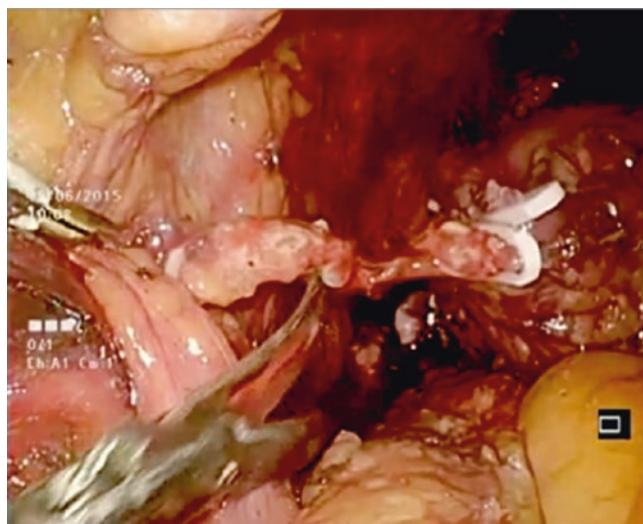

Fig. 46.22 Left ureter clipped and divided

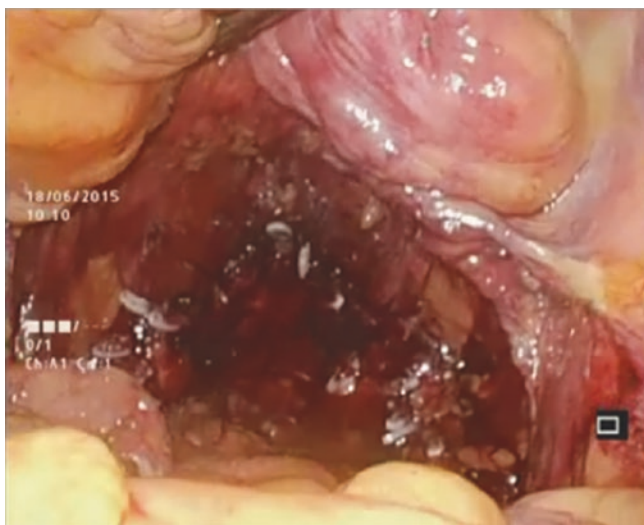

Fig. 46.23 Cystectomy bed

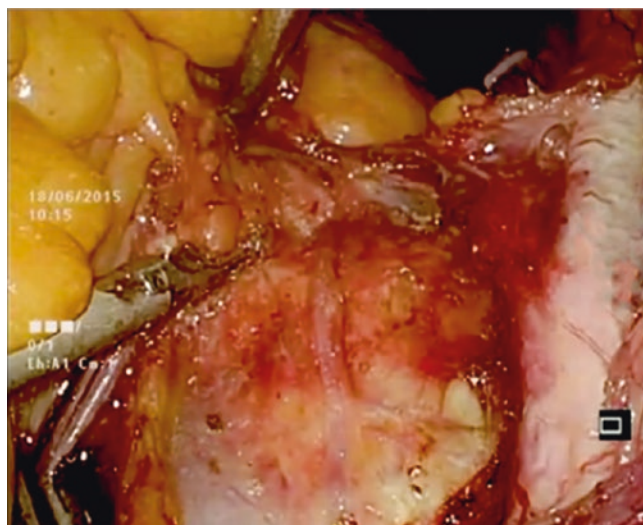


Fig. 46.24 Right extended iliac lymphadenectomy in progress

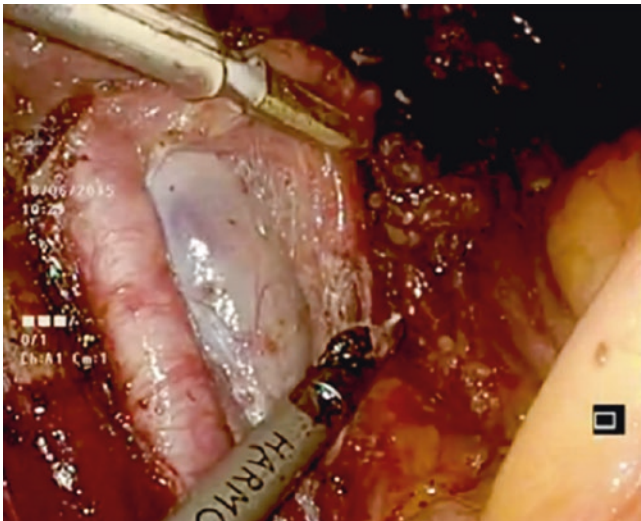


Fig. 46.25 Left extended iliac lymphadenectomy in progress

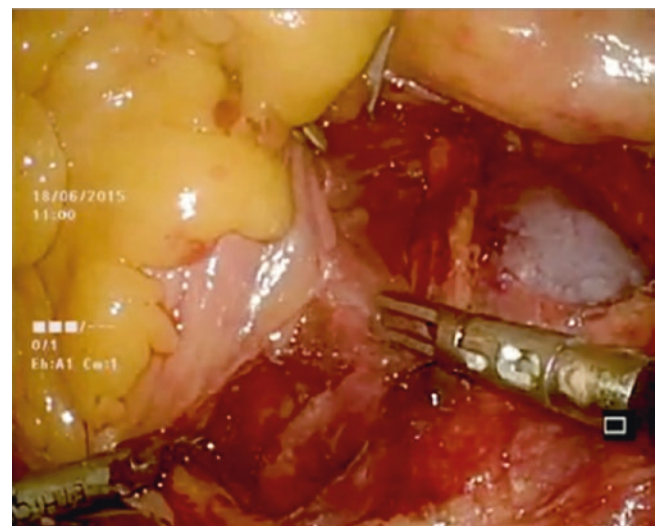


Fig. 46.26 Tunnelling of left ureter beneath sigmoid colon

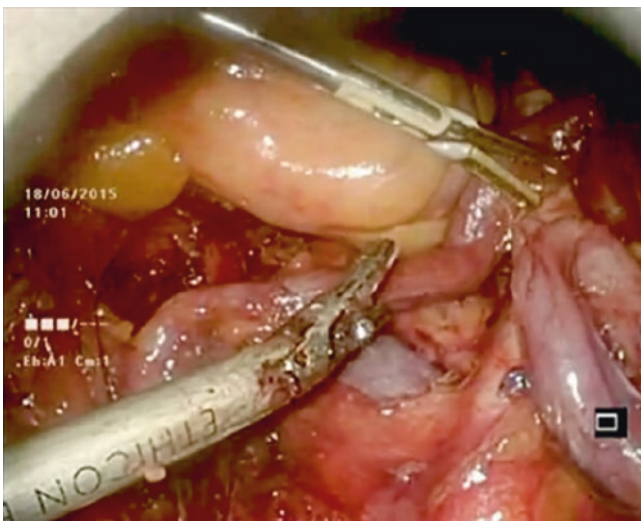


Fig. 46.27 Left ureter brought to right iliac fossa by tunneling under mesosigmoid

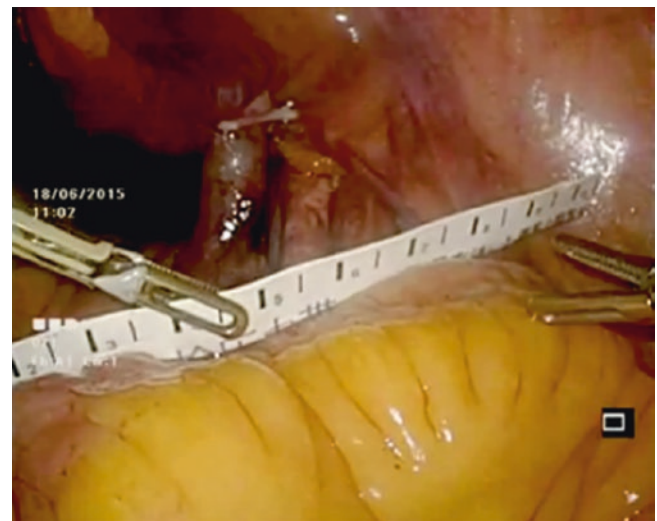


Fig. 46.28 Assessing the ileal segment for conduit – length and site (Note both ureters hinged to anterior abdominal wall using hem-o-lok clips)

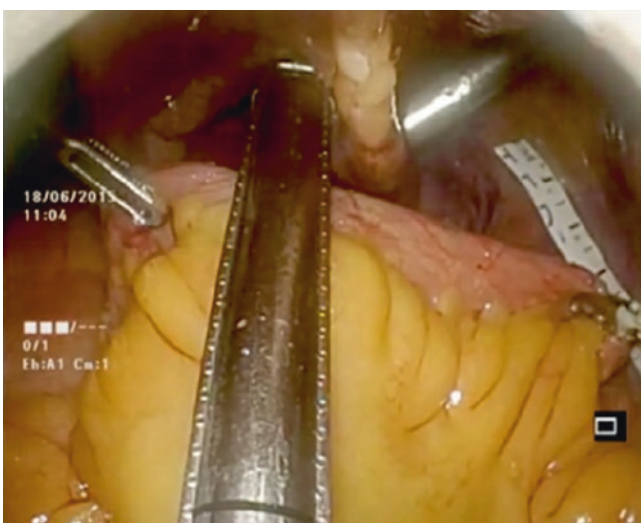


Fig. 46.29 Bowel segment isolation using staplers

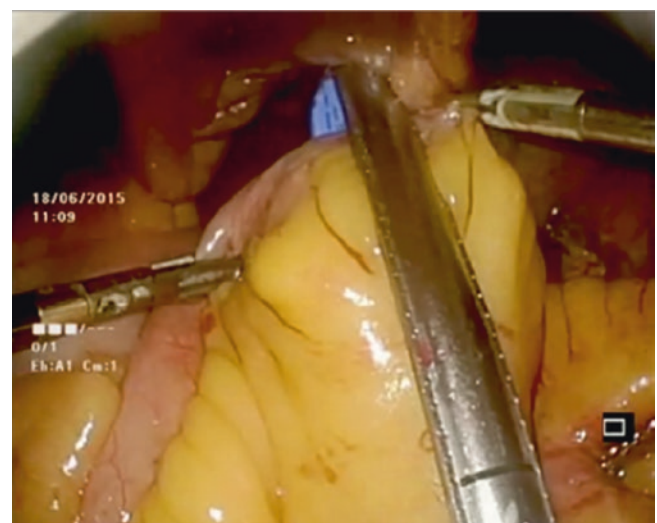


Fig. 46.30 Bowel segment isolation using staplers

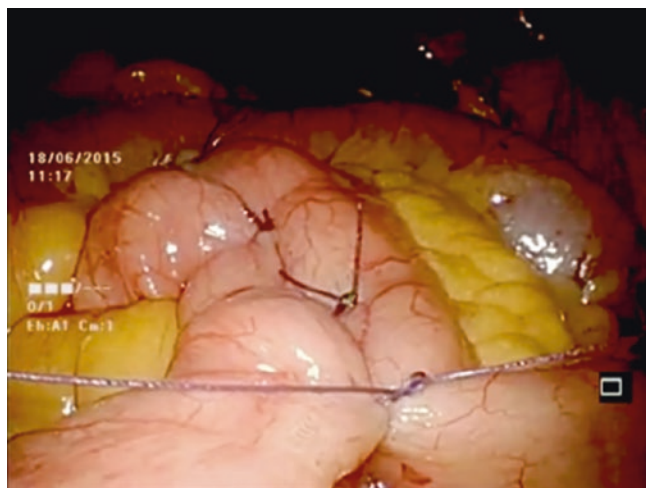


Fig. 46.31 Bowel segments tacked together to facilitate anastomosis with staplers

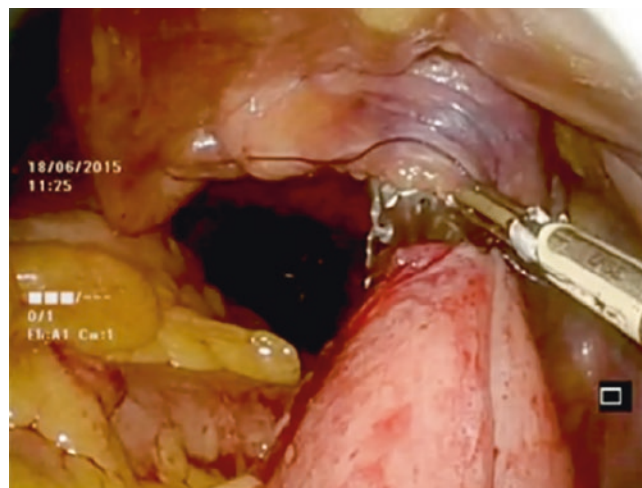


Fig. 46.32 Stapled bowel anastomosis, restoring ileal continuity

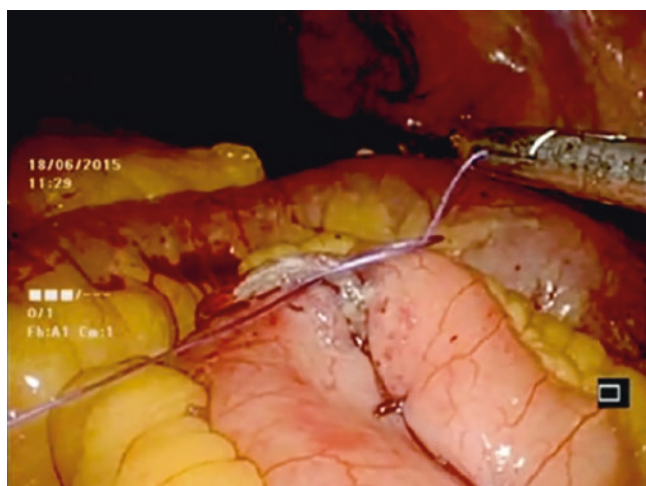


Fig. 46.33 Second layer of cover for bowel staples

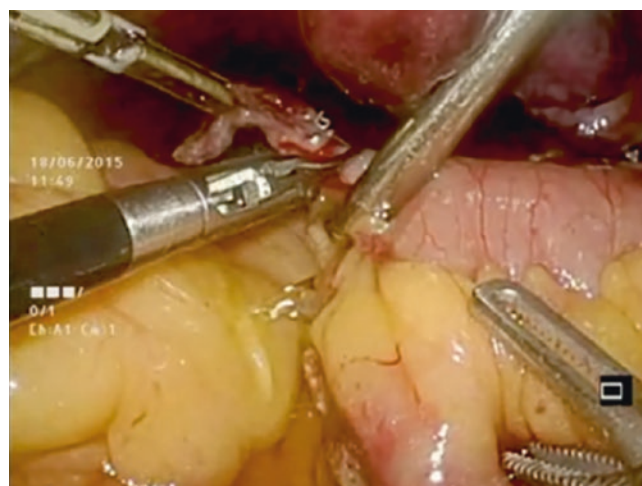


Fig. 46.34 Distal end of conduit opened

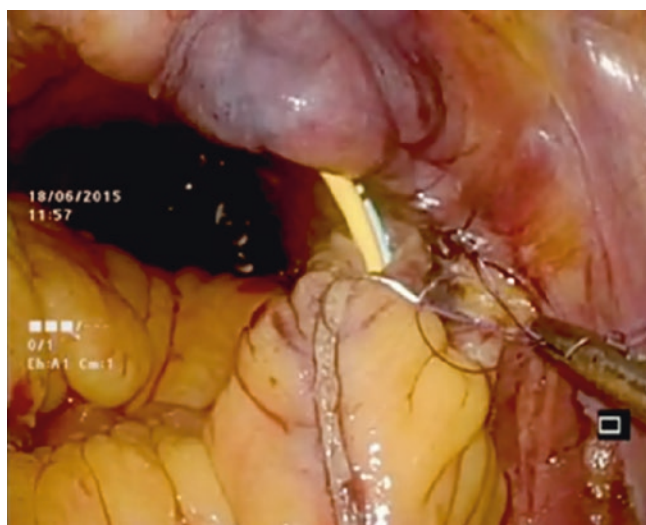


Fig. 46.35 Stents inserted into the conduit segment

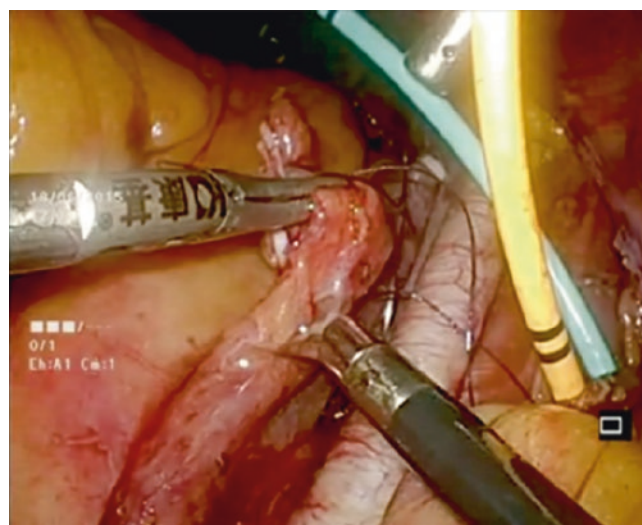


Fig. 46.36 Left ureter spatulated

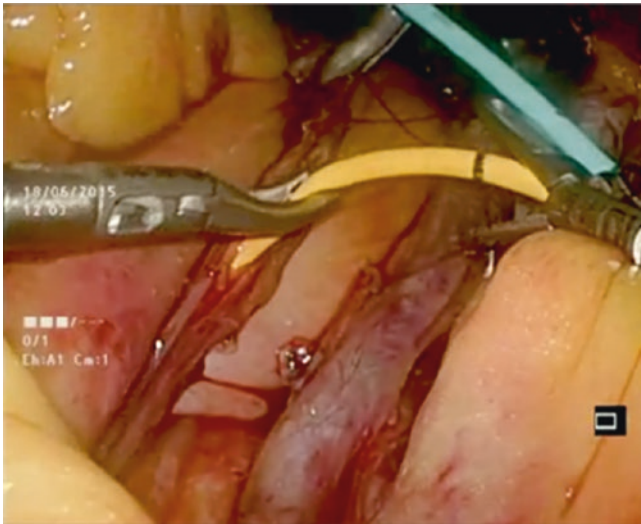


Fig. 46.37 Stent inserted to left ureter

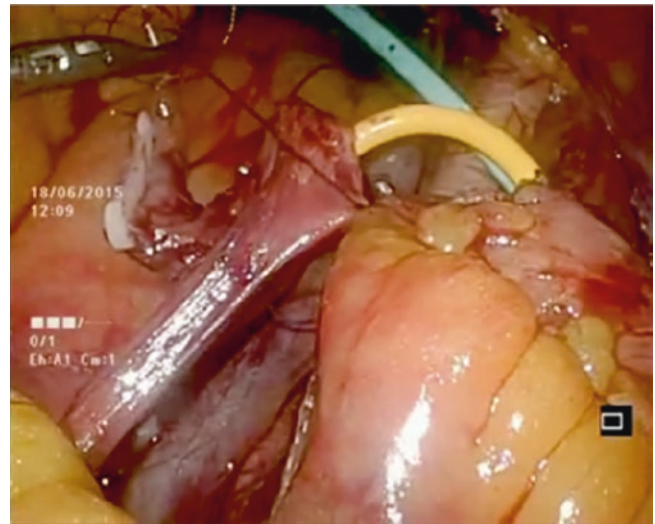


Fig. 46.38 Left ureteric anastomosis with 4-0 vicryl started (Bricker technique)

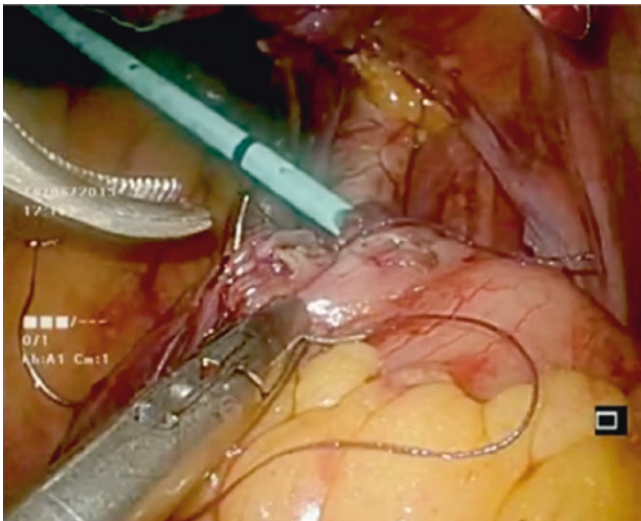


Fig. 46.39 Left uretero enteric anastomosis with 4-0 vicryl in progress

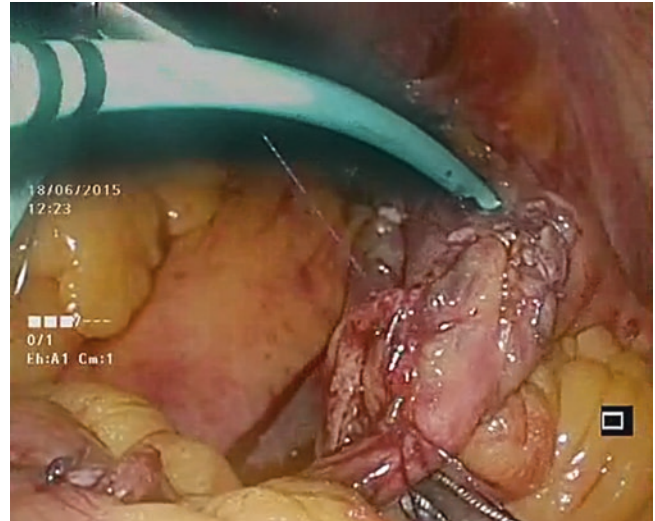


Fig. 46.40 Left uretero enteric anastomosis completed

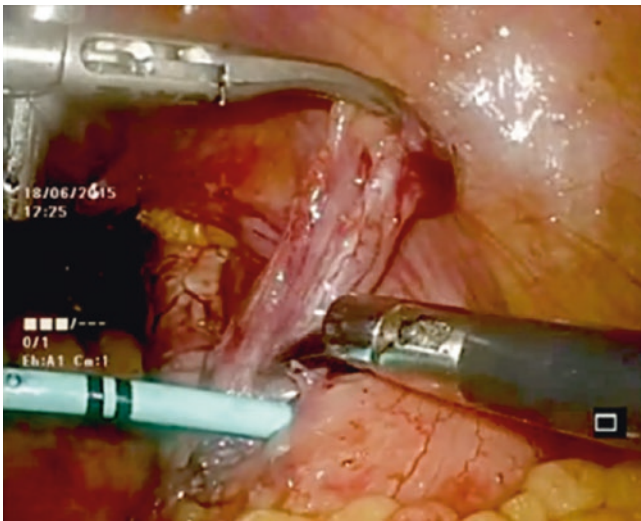

Fig. 46.41 Right ureteric spatulation

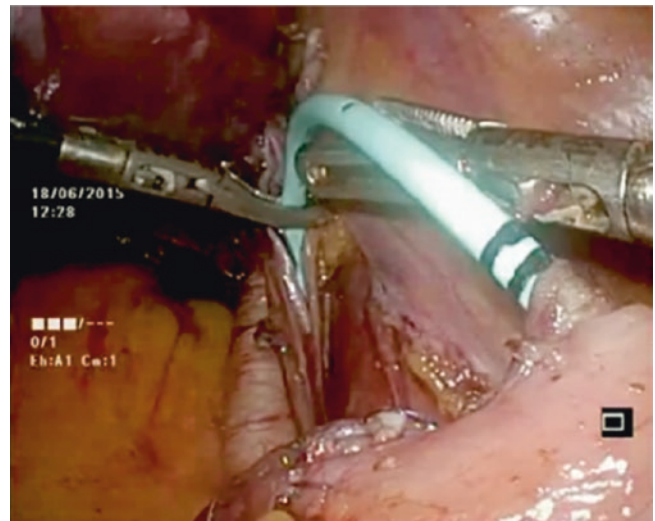


Fig. 46.42 Stent inserted into right ureter

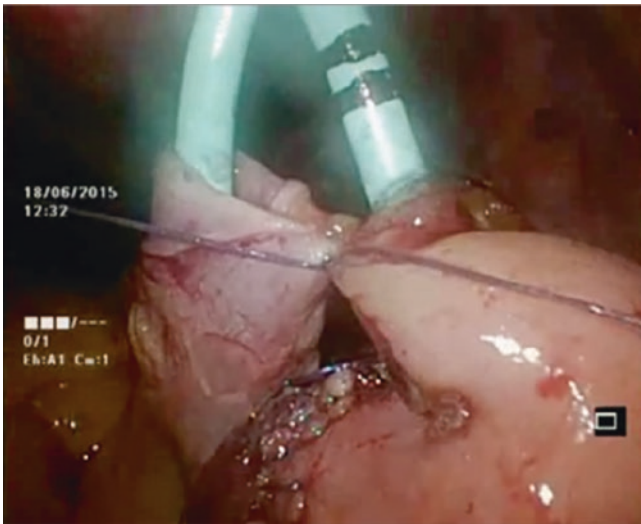


Fig. 46.43 Right uretero- enteric anastomosis with 4-0 vicryl in progress

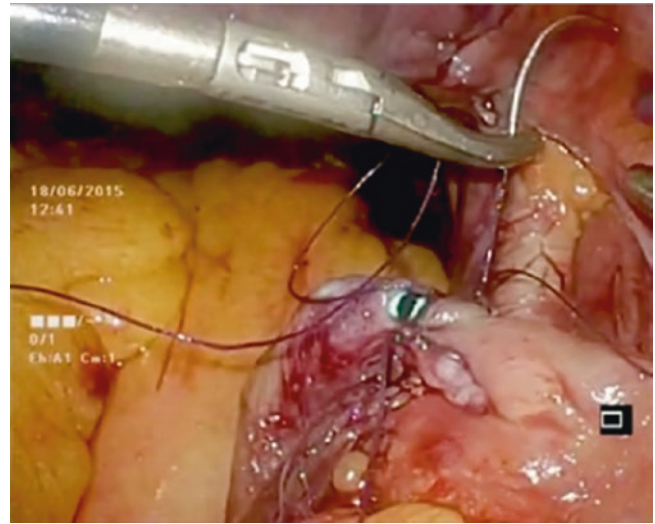


Fig. 46.44 Right uretero enteric anastomosis in progress

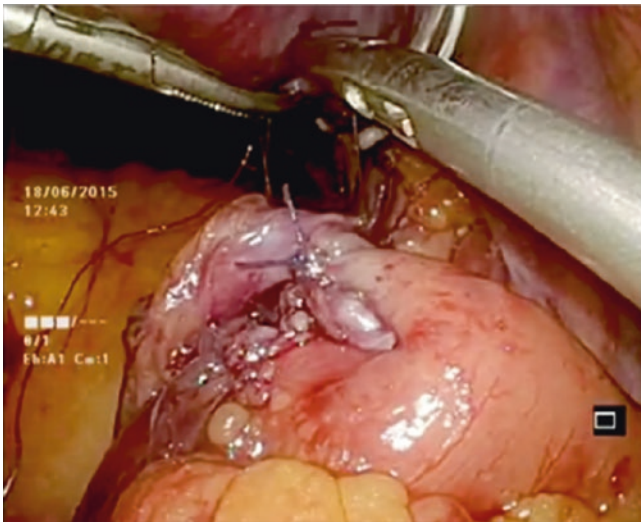


Fig. 46.45 Right ureteric anastomosis completed

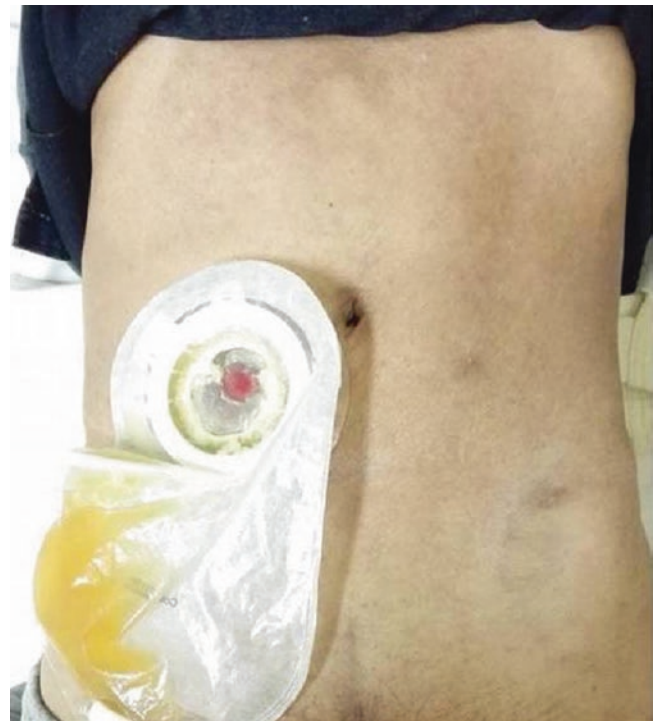

Fig. 46.46 Stoma location and port marks

References

1. Stein JP, Lieskovsky G, Cote R, Groshen S, Feng AC, Boyd S, Skinner E, Bochner B, Thangathurai D, Mikhail M, Raghavan D. Radical cystectomy in the treatment of invasive bladder cancer: long-term results in 1,054 patients. *J Clin Oncol*. 2001;19(3):666–75.
2. Porter MP, Penson DF. Health related quality of life after radical cystectomy and urinary diversion for bladder cancer: a systematic review and critical analysis of the literature. *J Urol*. 2005;173(4):1318–22.
3. Gupta NP, Gill IS, Fergany A, Nabi G. Laparoscopic radical cystectomy with intracorporeal ileal conduit diversion: five cases with a 2-year follow-up. *BJU Int*. 2002;90(4):391–6.

Manickam Ramalingam and Kallappan Senthil

47.1 Introduction

Management of neurogenic bladders can be frustrating as they present with complex and multiple problems. Though the clinician is concerned more about preserving renal function, the patient is concerned about normal voiding without leakage. In noncompliant bladders, one of the options is augmentation with intermittent self catheterization. Ileal conduit is done occasionally when major reconstructive procedures are not possible or not suitable when renal function is compromised [1, 2].

47.2 Surgical Technique

Adequate bowel preparation is important as children with neurogenic bladder have constipation as well. The patient is catheterised and put in the head low position. The primary port for the camera is inserted mid way between epigastrium and umbilicus to gain access to both ureters and ileum. A 12 mm port is inserted at the proposed site of the ileal conduit. A 5 mm port in midclavicular line is inserted in the left side at the level of the umbilicus. Another 5 mm left flank port is used for suction and irrigation. The ureters are identified where they cross the pelvic brim and dissected down upto the bladder, ligated and divided. The left ureter is brought to the right behind the sigmoid mesocolon. Stay suture taken through the ureters with 3-0 vicryl. The suture is brought out of the 12 mm trocar. The trocar is removed

and reintroduced by the side of the suture. The ileocaecal junction is identified and the loop of ileum to be harvested is selected. The loop is held with a 5 mm bowel holding clamp through the right sided 12 mm port and the port is sleeved up on the instrument with the tip of the instrument kept intra abdominally. The sutures holding the ureter are gently pulled to bring the ureters out first and then the loop of ileum is brought out. As the pneumoperitoneum collapses the ileal loop comes out easily in children. In adults, about 4 cm incision may be made in subumbilical area. The loop of ileum for the conduit is harvested extracorporeally. The ileo ileal anastomosis is carried out in the usual manner and the mesenteric defect is closed. Uretero ileal anastomosis is done using 5-0 vicryl with a 5 Fr. infant feeding tube as stent. Once the anastomosis is carried out the pneumoperitoneum is again created and the ileal loop and conduit are pulled back into the peritoneal cavity. The ureteroileal anastomosis is retroperitonealised with a 3-0 vicryl suture and the ileal conduit is tacked on to the lateral peritoneum to prevent any internal herniation. The ileal conduit stoma is fashioned in the usual manner. A drain is placed through the left 5 mm port.

47.3 Conclusion

Laparoscopy assisted procedures reduce the morbidity and overall operating time and hence may be suitable in select situations.

M. Ramalingam (✉)
PSG Hospitals,
Coimbatore, India
e-mail: uroram@yahoo.com

K. Senthil, MCh (Urol, FRCS)
Urology Clinic, Gowtham Annexe, Coimbatore, India
e-mail: senthilsatya@hotmail.com

47.4 Laparoscopy Assisted Ileal Conduit (in Neurogenic Bladder)

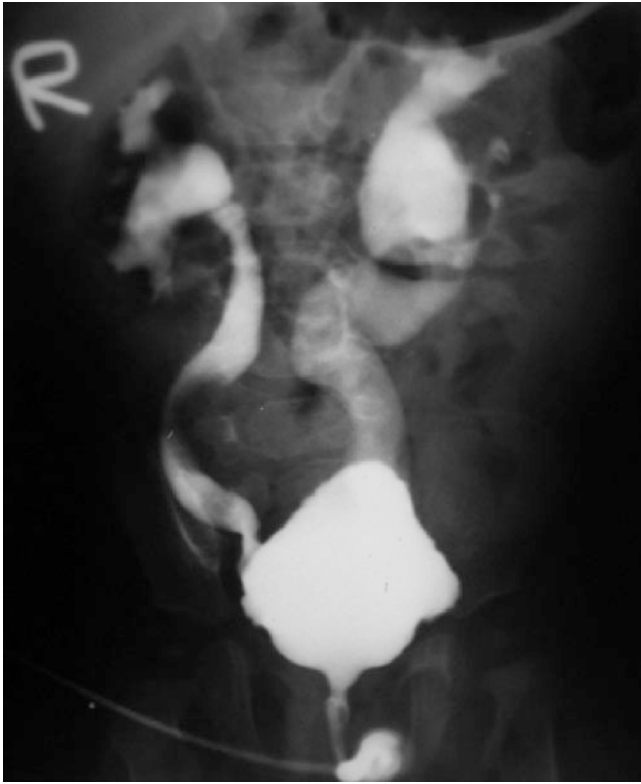

Fig. 47.1 MCU of a neurogenic bladder patient with grade IV reflux and renal failure in a 4 year old boy

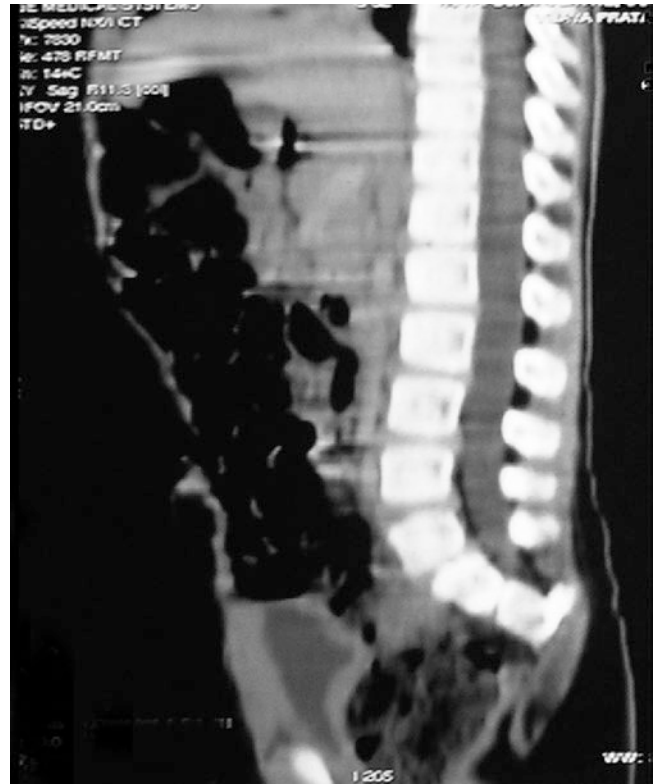


Fig. 47.2 CT urogram revealing sacral agenesis

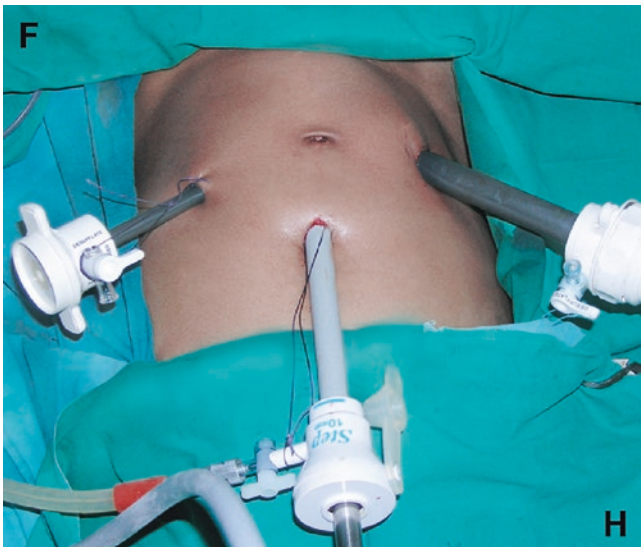


Fig. 47.3 Ports position

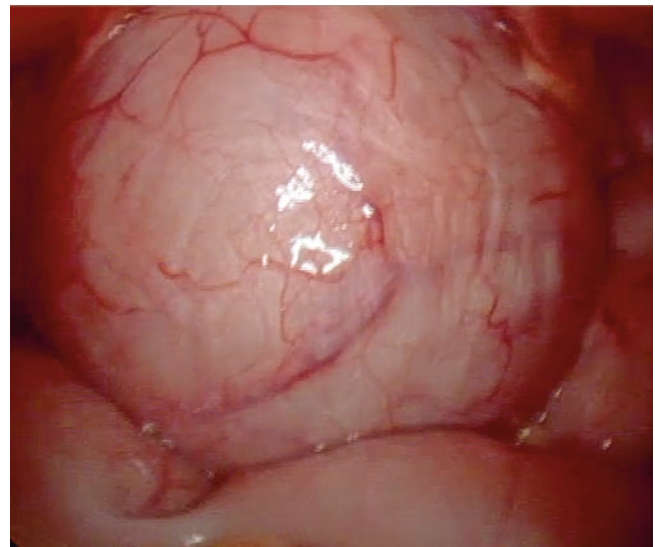


Fig. 47.4 Initial view of bladder

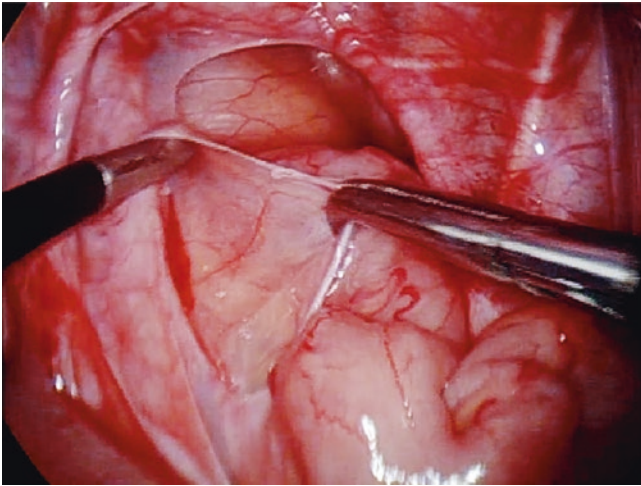


Fig. 47.5 Peritoneal incisor for left ureter dissection

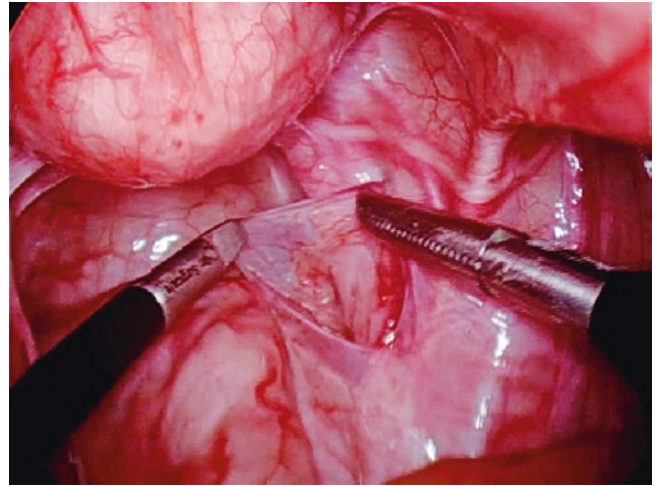


Fig. 47.6 Peritoneal incision for right ureter dissection

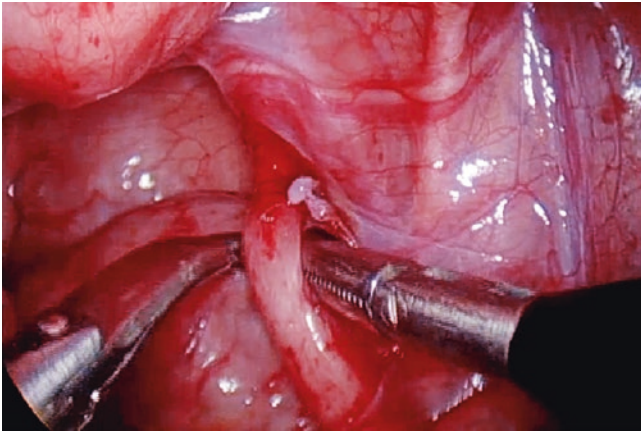


Fig. 47.7 Right ureter being dissected

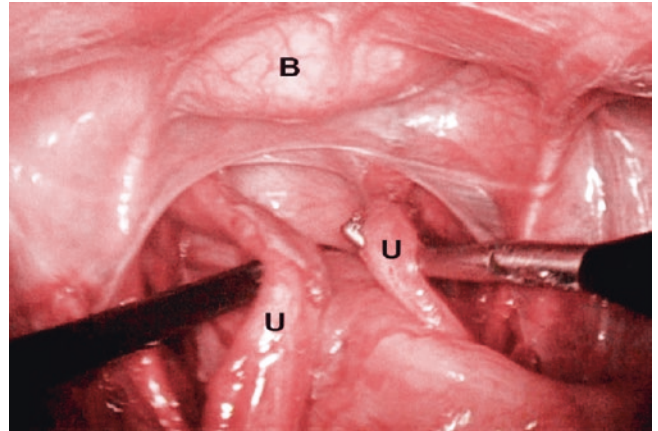


Fig. 47.8 Both ureters are mobilised

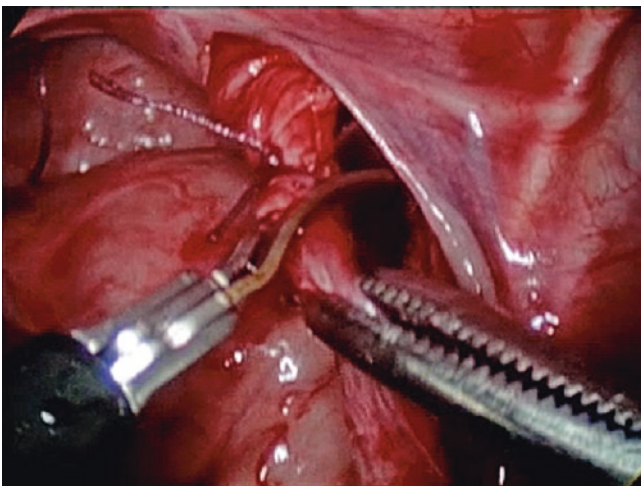


Fig. 47.9 Right ureter divided

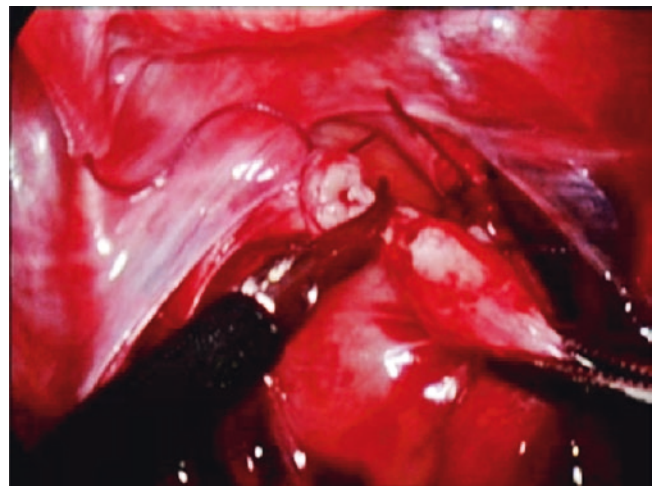


Fig. 47.10 Left ureter divided

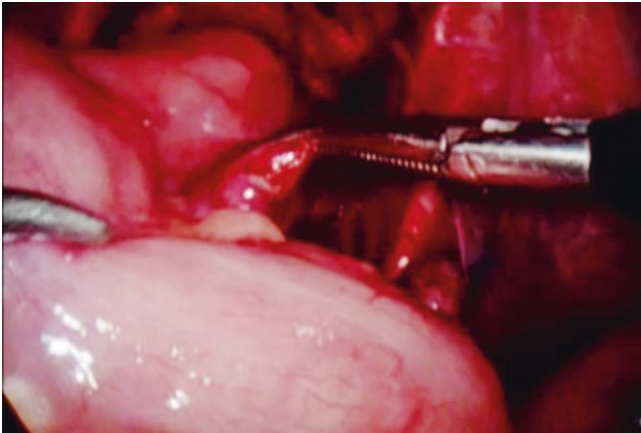


Fig. 47.11 Left ureter tunneled to the right beneath the sigmoid colon. *B* bladder, *U* ureter

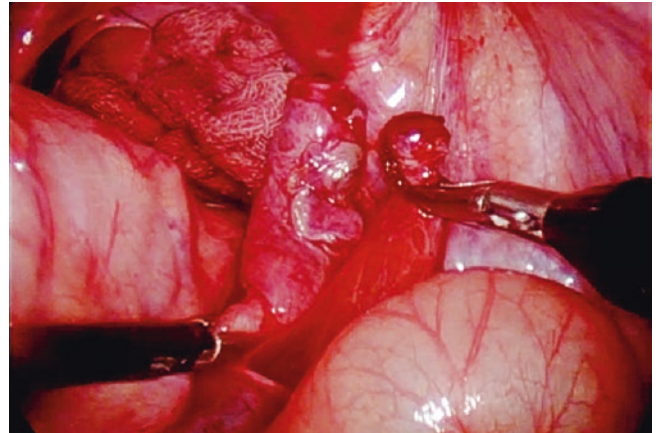


Fig. 47.12 Both ureters aligned for suturing

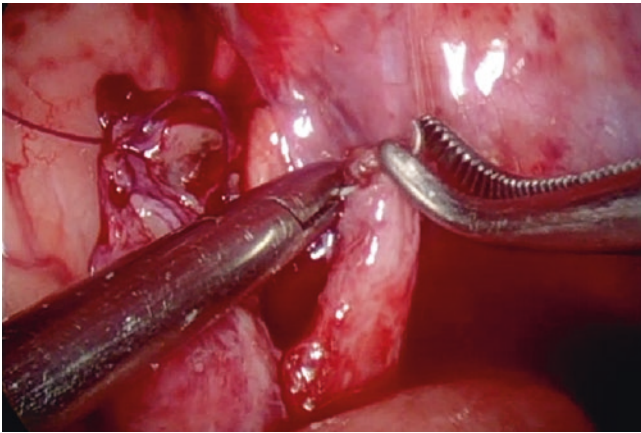


Fig. 47.13 Both ureters tacked together with a stitch

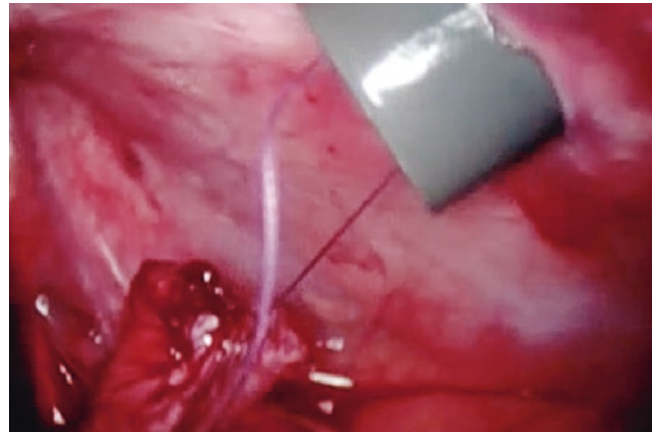


Fig. 47.14 Both ureters tied together and pulled out through the port

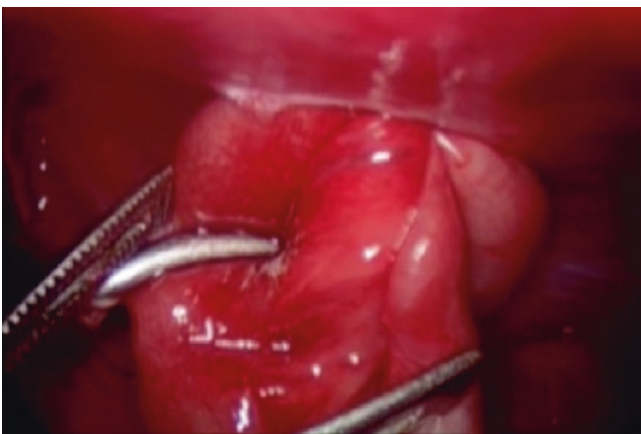


Fig. 47.15 Bowel loop brought out through 12 mm port-site

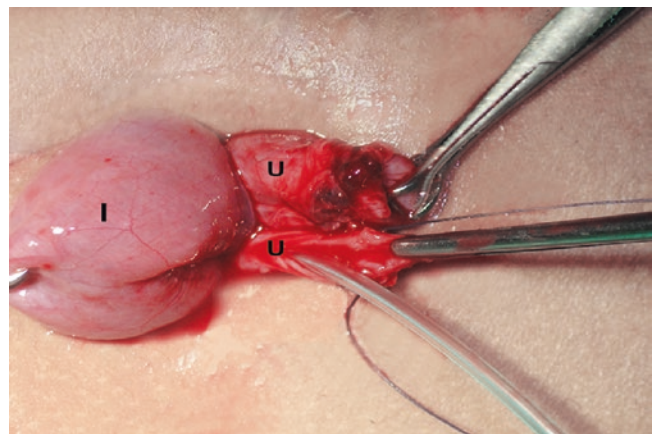


Fig. 47.16 Both ureters and ileum lying tension free (*U*-ureter, *I*- ileum)

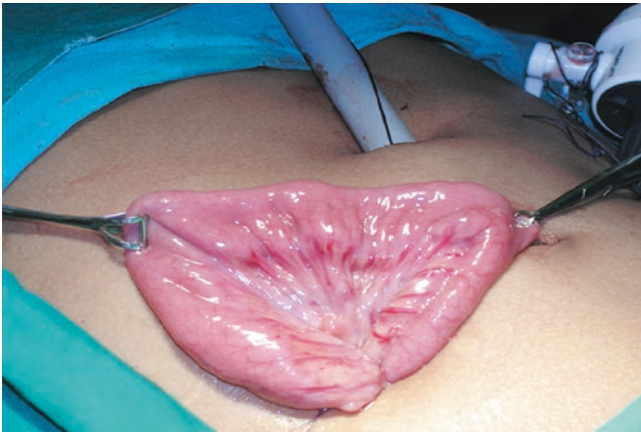


Fig. 47.17 Loop of ileum selected for conduit

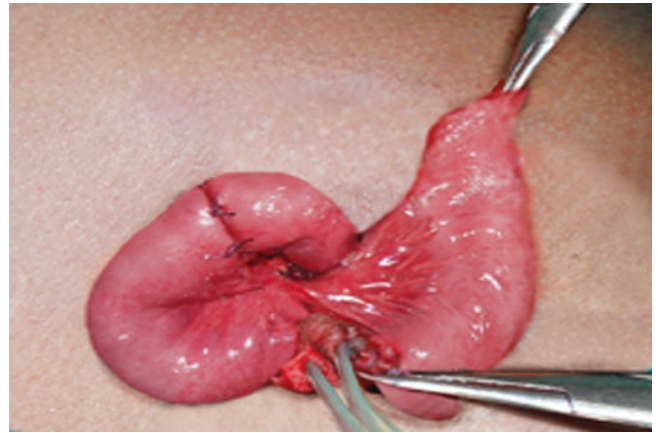

Fig. 47.18 Ileal loop for conduit isolated. Ureteroileal anastomosis in progress. Ureteric stents inserted

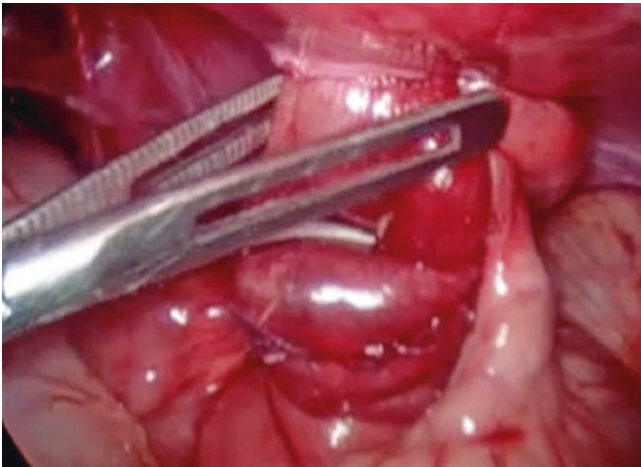


Fig. 47.19 Ileum and proximal part of conduit being pulled back into peritoneal cavity

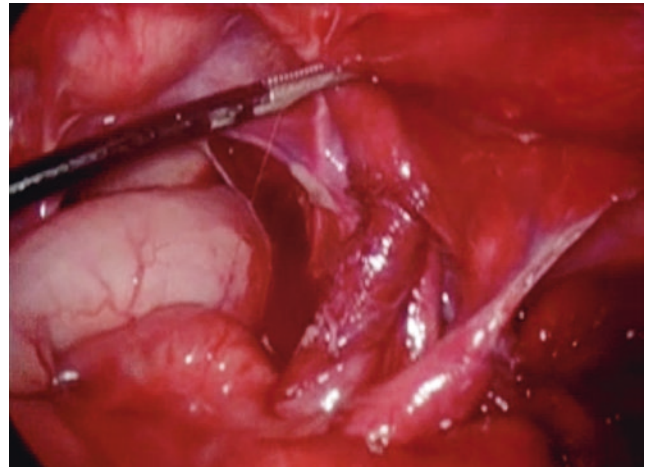


Fig. 47.20 Internal view of uretero ileal anastomosis

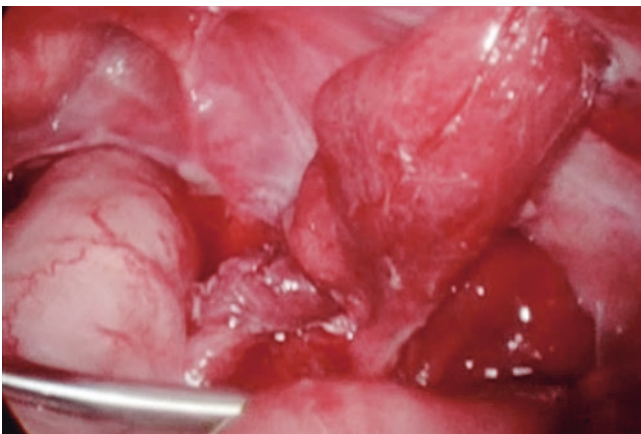


Fig. 47.21 Conduit view from inside

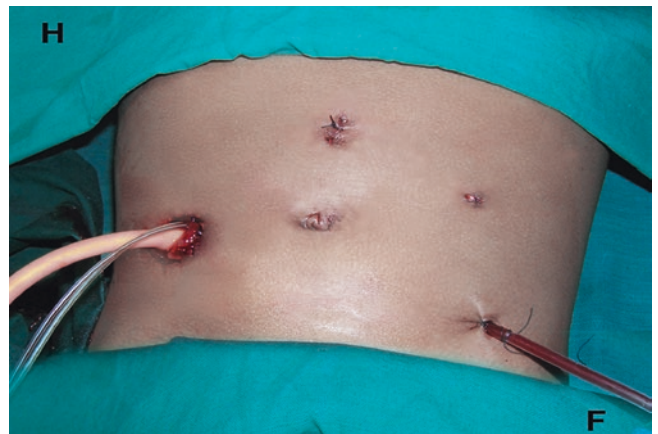

Fig. 47.22 Final external view of stoma and drain site

References

1. Potter SR, Charambura TC, Adams 2nd JB, Kavoussi LR. Laparoscopic ileal conduit: five-year follow-up. *Urology*. 2000; 56:22.
2. Ramalingam M, Senthil K, Pai MG. Laparoscopy assisted ileal conduit in sacral agenesis. *J Laparoendosc Adv Surg Tech A*. 2008; 18(2):335–9.

Anandan Murugesan, Gagan Gautam,
and Rajesh Ahlawat

48.1 Introduction

Radical cystectomy is one of the most technically demanding and morbid urological procedures. Robot assisted radical cystectomy (RARC) is now increasingly being preferred over the open approach in institutions where robotic surgical systems are available [1]. A robot assisted approach to radical cystectomy may be better accomplished than a pure laparoscopic approach and offers the advantage of a shorter learning curve, better vision and improved surgeon ergonomics [2]. This may prove beneficial in performing complex steps in the procedure such as extended lymphadenectomy, control of dorsal venous complex and urinary diversion. While the jury is still not out on the best method to perform urinary diversion during RARC (extracorporeal versus intracorporeal), some preliminary level 3 data indicate that an intracorporeal diversion may hasten recovery and decrease GI and infectious complications as compared to an extracorporeal technique [3]. The downside is the increased operating time, technical difficulty and learning curve involved in performing an intracorporeal diversion [1]. However, with growing experience, standardization of technique and evolution of structured training programs, intracorporeal urinary diversion is rapidly being adopted at centers of excellence around the world and is likely to gain further acceptability in the years to come.

A. Murugesan, MBBS, MS, MCh (✉)
Department of Urology, PSG Institute of Medical Sciences and Research, Peelamedu, Tamil Nadu, Coimbatore, India
e-mail: anandan79@gmail.com

G. Gautam
Urologic Oncology & Robotic Surgery, Max Institute of Cancer Care, Saket, New Delhi, India

R. Ahlawat, MBBS, MS, MNAMS, MCh, FIMSA
Division of Urology and Renal Transplant, Fortis Escorts Kidney and Urology Institute, Okhla Road, New Delhi, India
e-mail: rajesh.ahlawat@fortishealthcare.com

48.2 Indications

The classical indications of radical cystectomy hold good for robot assisted radical cystectomy too. These are

1. Muscle invasive bladder cancer
2. Non muscle invasive bladder cancer (NMIBC) refractory to intravesical therapy
3. Selected cases of high risk NMIBC

48.2.1 Preoperative Preparation

RARC is a prolonged surgery and has a bearing on the cardio respiratory reserve of the patient. Pre operative evaluation by a cardiologist regarding the cardiac status is desirable. We do not prefer mechanical bowel preparation since it may increase post operative ileus and increase susceptibility to *Clostridium difficile* infections. Bisacodyl tablets are given on the night before surgery to clear the colon. Adequate blood products need to be arranged. Standard antibiotics as per the policy of the institute are to be used.

48.3 Procedure

Hydration status (Central venous pressure) and the arterial pressure need to be monitored. Under general anesthesia he/she is placed in low lithotomy position with steep Trendelenberg tilt of 30°. Exposed areas of the patient are completely covered to prevent hypothermia. Patient is securely padded and strapped as depicted in the picture. 18 Fr Foleys catheter and nasogastric tube are placed. Pneumoperitoneum is created and standard six ports are placed (three 12 mm ports and three 8 mm robotic ports). The port position is shown in the picture. Robot is docked from the foot end.

Steps:

1. Ureteric dissection
2. Lymphnode dissection
3. Lateral pedicle control
4. Posterior dissection of vas and seminal vesicles
5. Anterior dissection
6. Prostate dissection
7. Division of Dorsal venous complex and urethra
8. Bowel segment isolation
9. Ureteroileal anastomosis
10. Exteriorisation of conduit

Peritoneum is incised lateral to the ureter. Ureter is dissected till the urinary bladder. Dissection is done preserving the periadventitial tissue. Lower end of the ureter is clipped and cut. Distal margin is sent for frozen section.

The margins of lymphadenectomy extends from genitofemoral nerve to lateral bladder wall. Aortic bifurcation forms the proximal extent of dissection in extended lymphadenectomy. All the fibrofatty tissues are removed till endopelvic fascia is seen. After peritoneal incision, iliac artery and vein are dissected free from the fibrofatty tissue. Tissues are mobilised medially from the psoas and dissected posteriorly till the endopelvic fascia. Obturator vessels and nerve are identified and preserved. Vas is divided when it is encountered close to the inguinal ring. All the tissues lateral to the medial umbilical ligament are removed. Dissection medial to the medial umbilical ligament at this stage might injure the vesical blood vessels and cause bleeding. Fourth arm is used for retraction of the medial umbilical ligament and assistant grasper is used on the left side.

With the completion of lymphadenectomy and ureter isolation, the lateral pedicles of the bladder are exposed. Sixty millimeter Endo GIA stapler can be used to control the lateral pedicles en masse or the individual vessels can be clipped and cut.

Rectovesical pouch is incised and vas and seminal vesicles are dissected. The peritoneal incision connects the lymphadenectomy incision on both sides. Dissecting in the plane just behind the seminal vesicles facilitates easier dissection. As we move distally, the pearly white fibres of Denonvillier's fascia are encountered. These fibres are incised and prostate dissected from the rectum till the posterior apex.

Next step is development of Retzius space. Medial umbilical ligament is retracted posteromedially to identify the plane of dissection. An avascular plane is developed by both sharp and blunt dissection bilaterally. The urachus and medial umbilical ligament are diathermised with bipolar cautery close to the umbilicus. The spaces developed from both sides are joined together.

Endopelvic fascia is incised medial to the arcuate line. An avascular plane is developed between the prostatic fascia and levator fascia. Dorsal venous complex (DVC) is sutured using no.1 polyglactin sutures with ½ circle needle. Moving the catheter helps identification of groove between DVC and urethra.

The lateral pedicles of the prostate are encountered distal to the seminal vesicles. Minimal cautery near the tip of seminal vesicles decreases damage to the pelvic plexus. According to the patient's baseline sexual function and disease status, nerve sparing can be performed during control of prostatic pedicles. The details of the nerve sparing technique are described elsewhere in this book.

DVC is incised and urethra is completely freed all around. Urethra is clipped prior to division to decrease chances of spillage and the specimen is now free to be bagged.

Sigmoid mesentery is lifted anteriorly at the level of the sacral promontory and left ureter is tunneled to the right side. This plane is developed better by the bedside assistant using the graspers with help from the console surgeon.

48.4 Ileal Conduit Diversion

Bowel work for intracorporeal ileal conduit diversion is facilitated by decreasing the angle of the Trendelenberg position to about 10°. The robotic system needs to be undocked and redocked for this maneuver. Fifteen to 20 cm of terminal ileum 20–30 cm from the ileocaecal junction is selected. The desired bowel length is measured using a 10 cm long umbilical tape. The proximal and distal end of the conduit segment are marked with different coloured sutures. The bowel segment is divided and continuity restored using staplers as depicted in the pictures. The staplers in the proximal end of the conduit segment are isolated using vicryl running suture just distal to staplers.

Uretero ileal anastomosis is performed close to the proximal end of the ileal conduit, where ureters can be placed without tension. The type of anastomosis (Bricker versus Wallace) depends on the surgeon's preference. 4-0 PDS continuous sutures with few onlay interrupted sutures provide a secure uretero ileal anastomosis. Infant feeding tubes of different sizes are used as stents for the ureters. Infant feeding tubes are fixed using catgut sutures to prevent slipping. The ends of the tube are brought out through the distal end. 2-0 polyglactin sutures are tagged to the distal end of the conduit.

Specimen is removed through a lower midline or Pfannenstiel incision and wound is closed in layers.

The incision for stoma is made in the predesignated site and peritoneum entered. Using laparoscopic vision, the suture is grabbed and pulled out using Babcock forceps. Stoma is matured.

48.5 Conclusion

Robot assisted radical cystectomy with intracorporeal ileal conduit is a complex surgical procedure. However, with

growing experience, standardization of technique and a team based approach, it can be performed safely and potentially provides tangible benefits to patients by speeding up post operative recovery and decreasing morbidity.

48.6 Robot Assisted Laparoscopic Ileal Conduit

Fig. 48.1 Ports positions

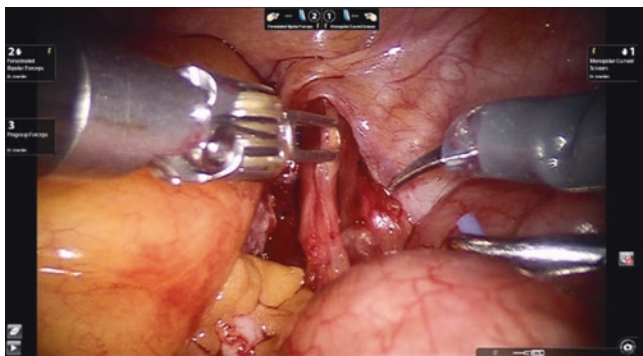
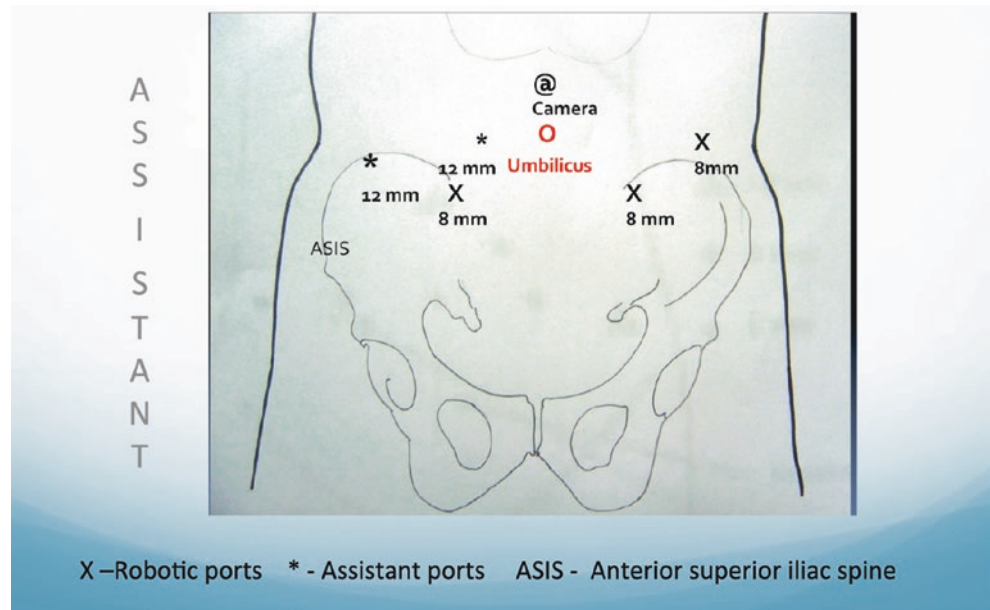


Fig. 48.2 Right ureter dissected

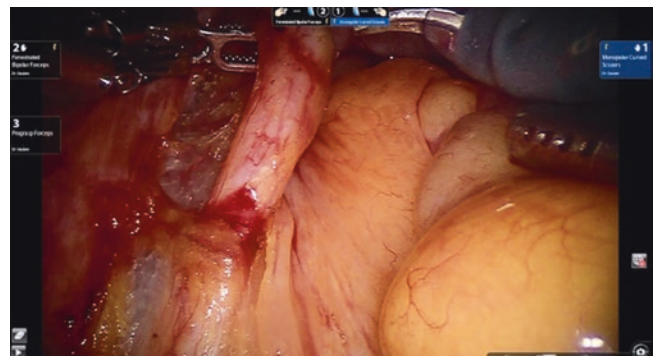


Fig. 48.3 Left ureter dissected

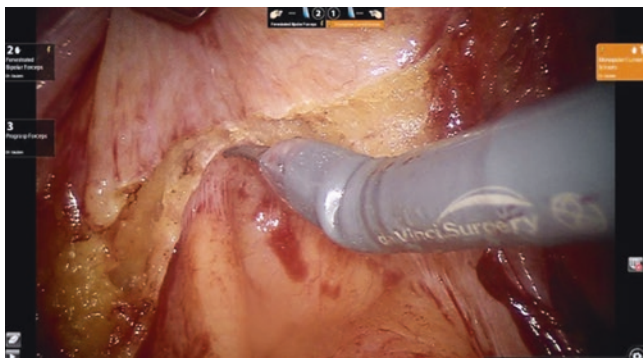


Fig. 48.4 Right and left peritoneal incisions connected behind the bladder

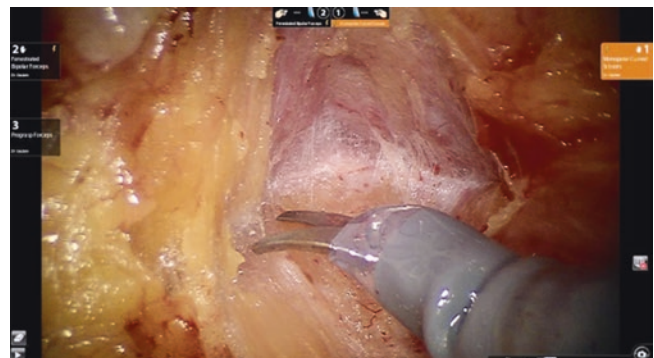


Fig. 48.5 Posterior dissection in progress

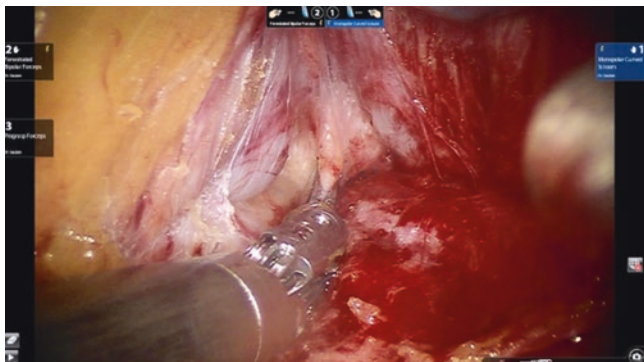


Fig. 48.6 Posterior dissection in progress

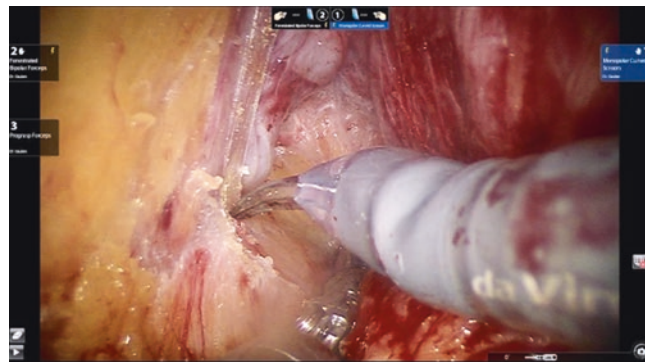


Fig. 48.7 Left seminal vesicle dissected

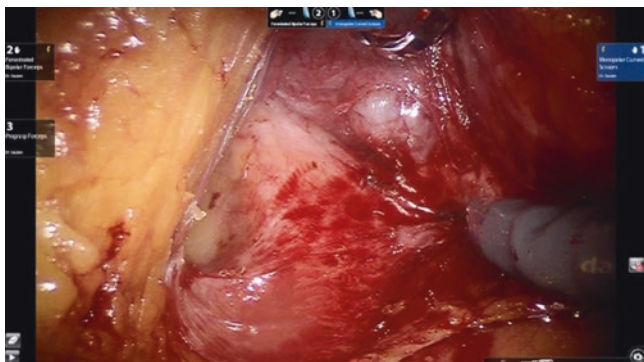


Fig. 48.8 Right seminal vesicle dissected

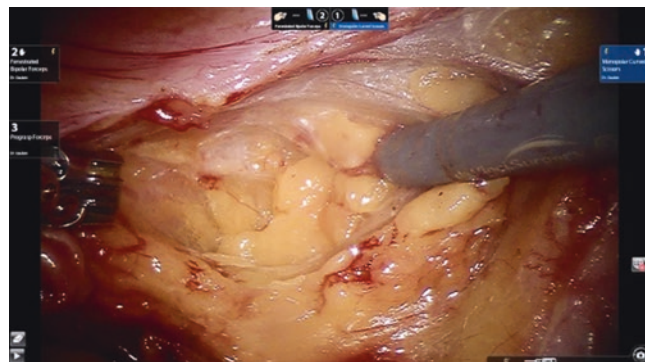


Fig. 48.9 Lateral pedicle dissection lateral to perivesical fat

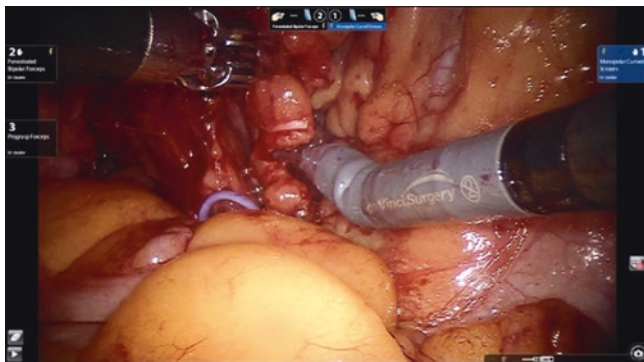

Fig. 48.10 Right obliterated umbilical artery clipped and divided

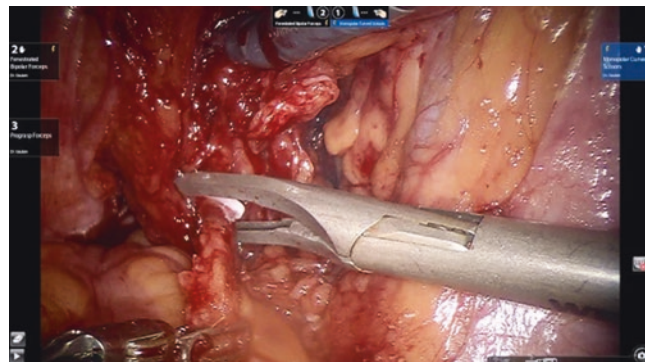


Fig. 48.11 Right ureter clipped

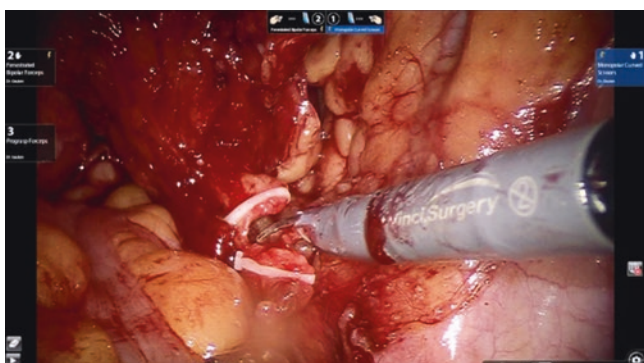


Fig. 48.12 Right ureter divided between clips

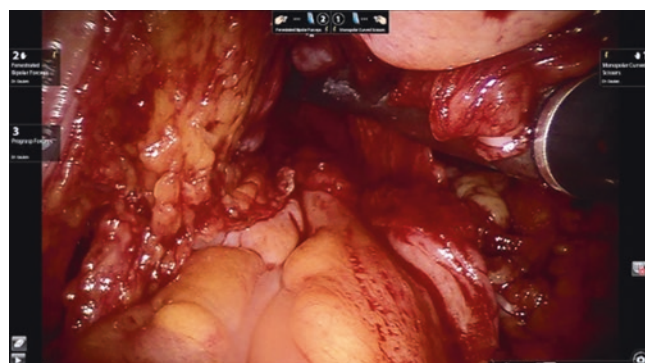


Fig. 48.13 Right lateral pedicle handled with stapler

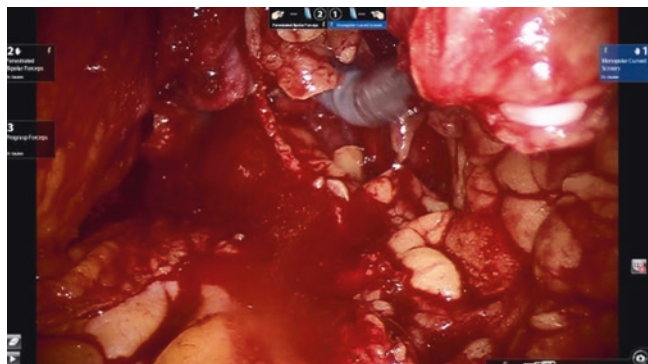


Fig. 48.14 Stapled right lateral pedicle

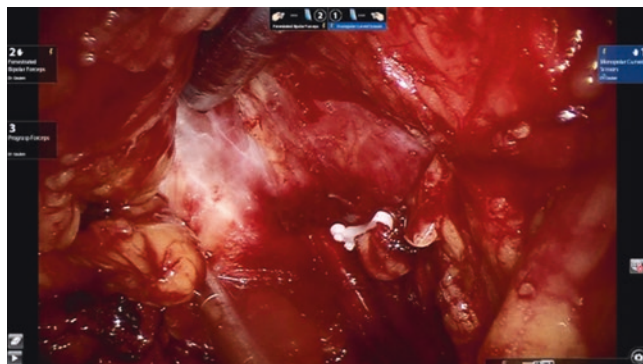


Fig. 48.15 Endopelvic fascia exposed on right side

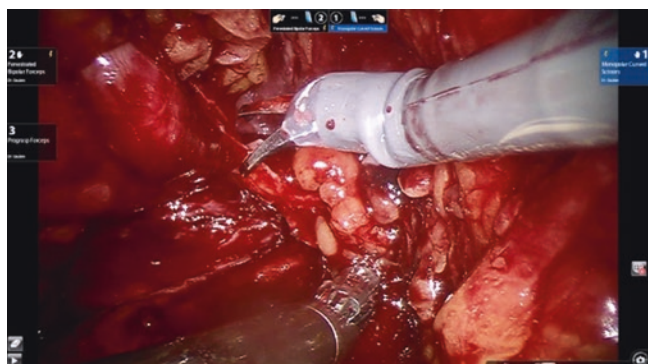


Fig. 48.16 Right lateral prostatic pedicle control

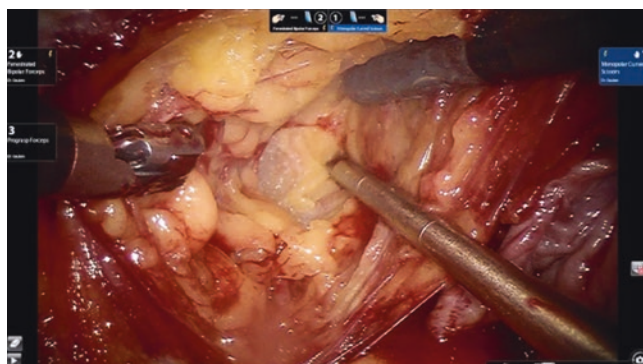


Fig. 48.17 Dissection lateral to perivesical fat on the left side for control of left lateral pedicle

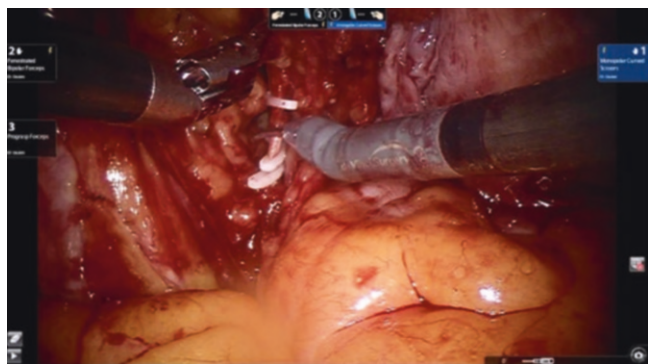


Fig. 48.18 Left superior vesical artery clipped and divided

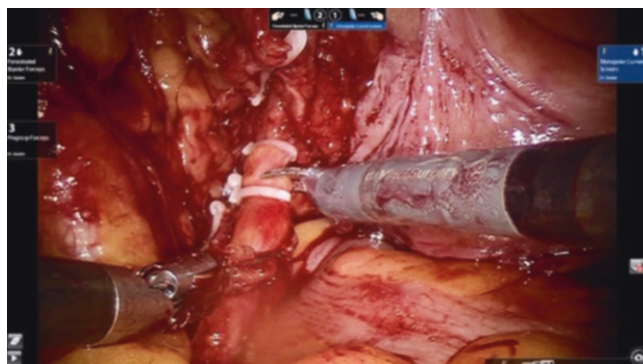


Fig. 48.19 Left ureter clipped and divided

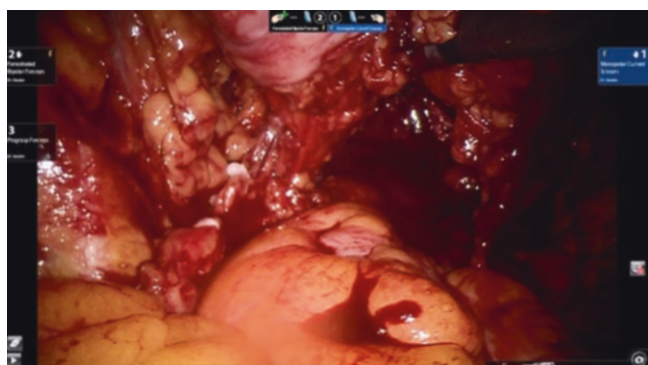


Fig. 48.20 Left lateral pedicle delineated

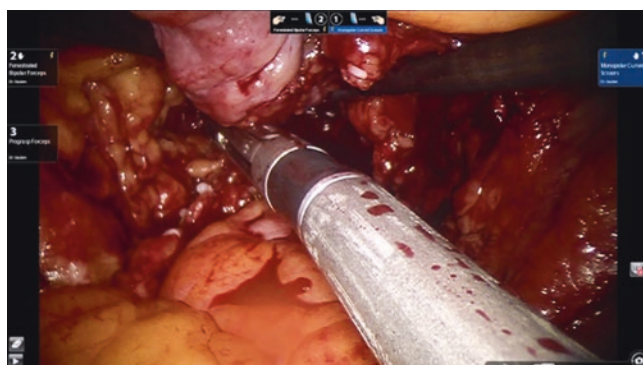


Fig. 48.21 Left lateral pedicle stapled

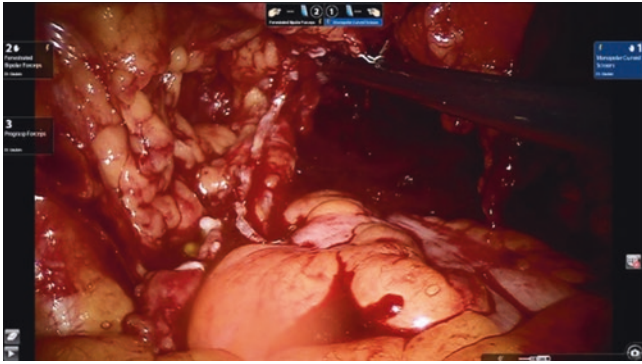


Fig. 48.22 Left lateral pedicle staple lines

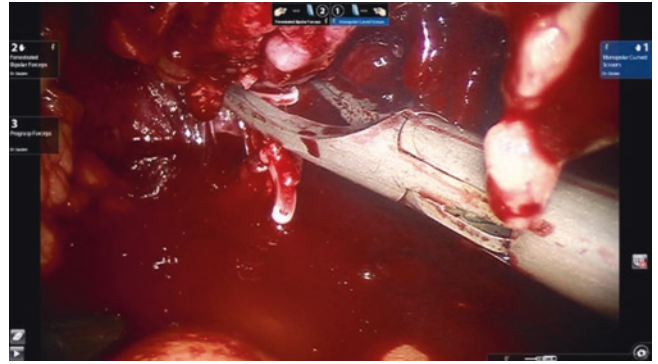


Fig. 48.23 Lateral pedicle of prostate controlled on the left side

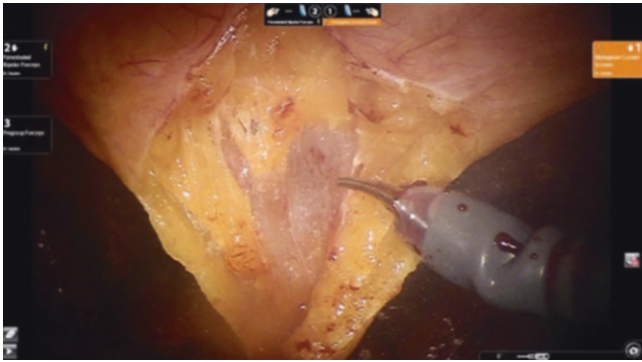


Fig. 48.24 Bladder drop in progress

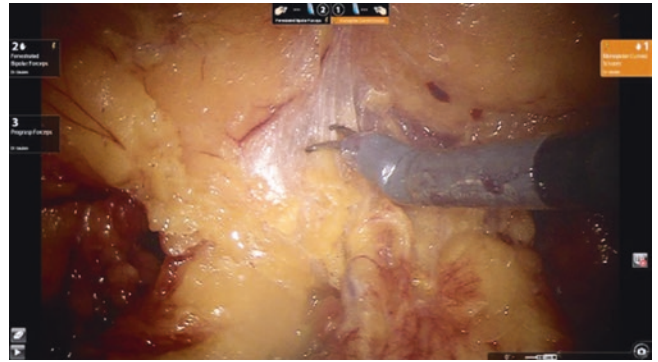


Fig. 48.25 Bladder drop completed

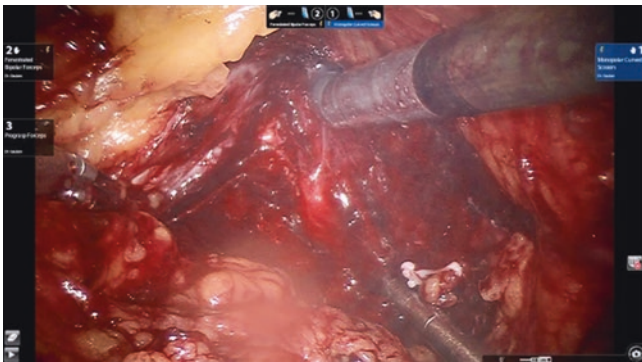


Fig. 48.26 Right side endopelvic fascia being incised

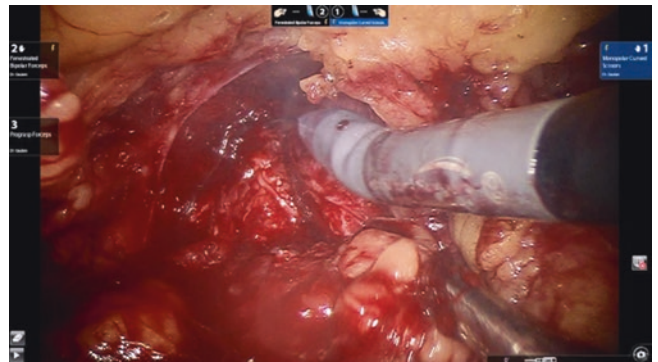


Fig. 48.27 Left side endopelvic fascia being incised

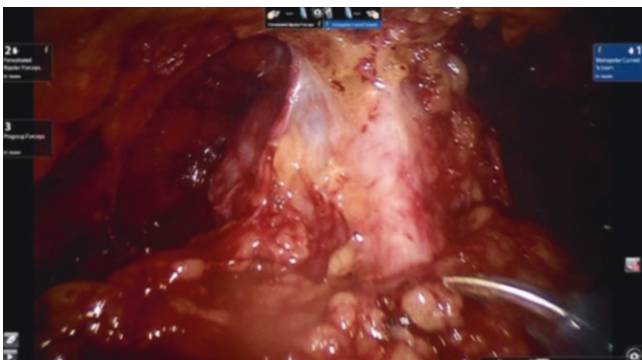


Fig. 48.28 Prostate defatting complete

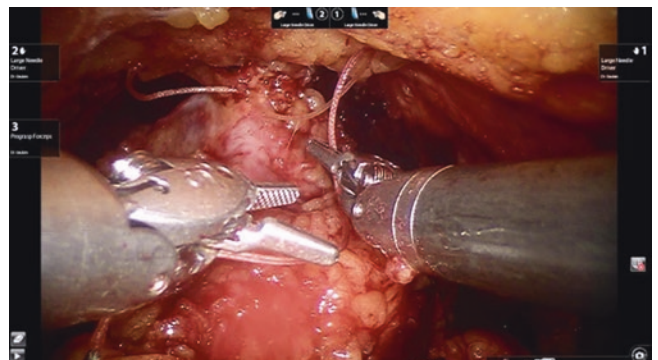


Fig. 48.29 Dorsal venous complex suturing in progress

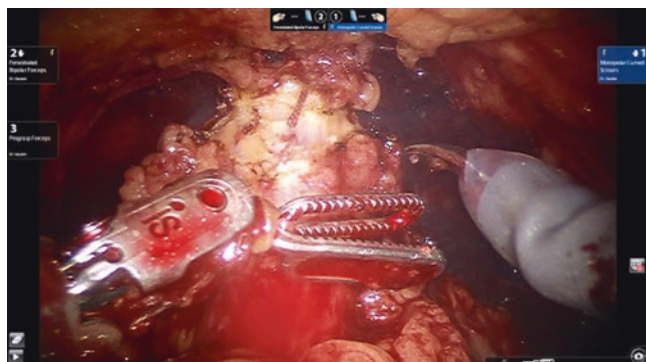


Fig. 48.30 Dorsal venous complex divided and prostatic apex dissected

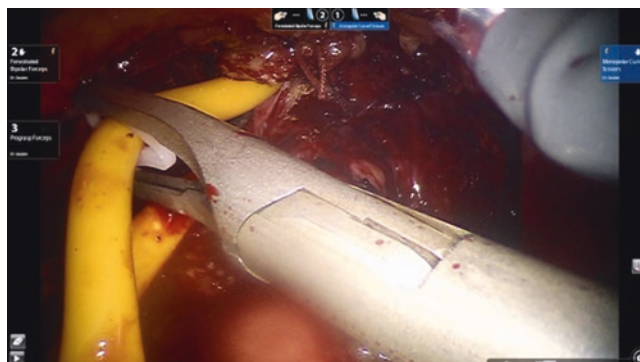


Fig. 48.31 Catheter clipped to prevent spill

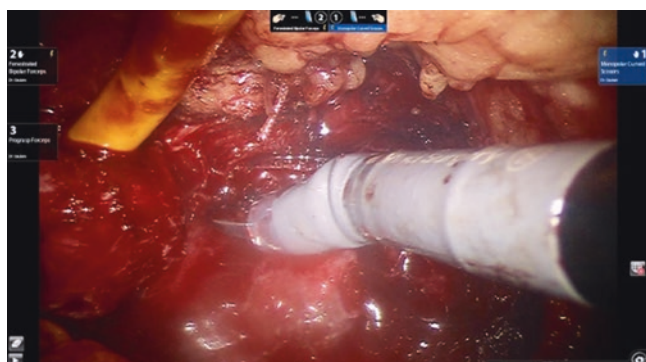


Fig. 48.32 Rectourethral tissue being divided

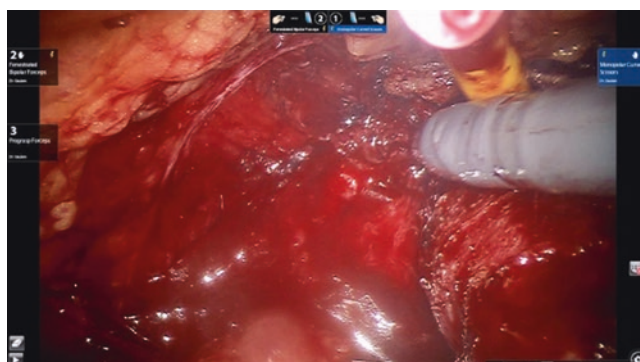


Fig. 48.33 Prostate dissected from rectum

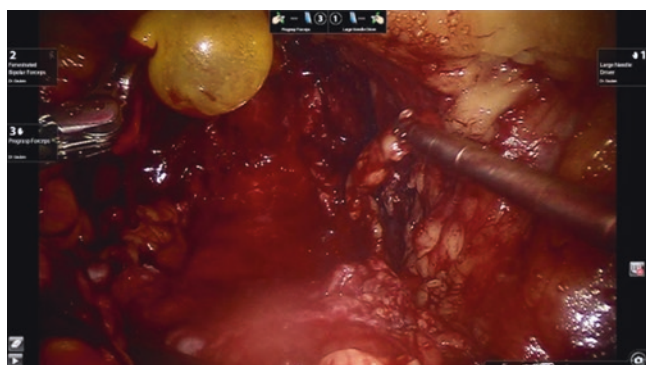


Fig. 48.34 Bladder bed

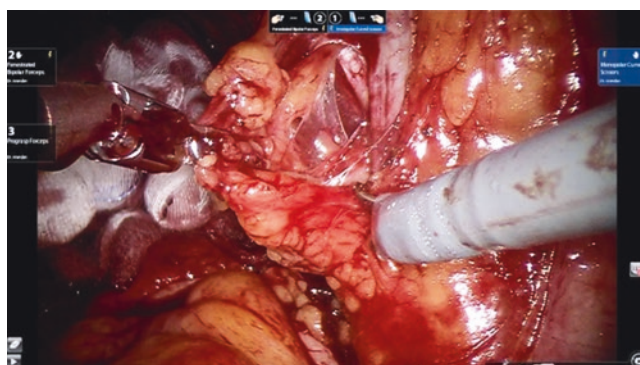


Fig. 48.35 Right lymphadenectomy started

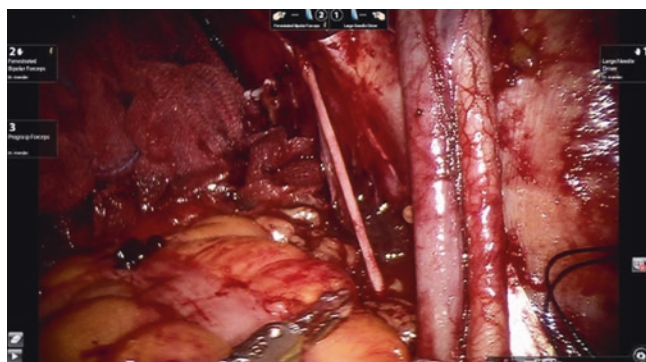


Fig. 48.36 Right iliac lymphadenectomy completed

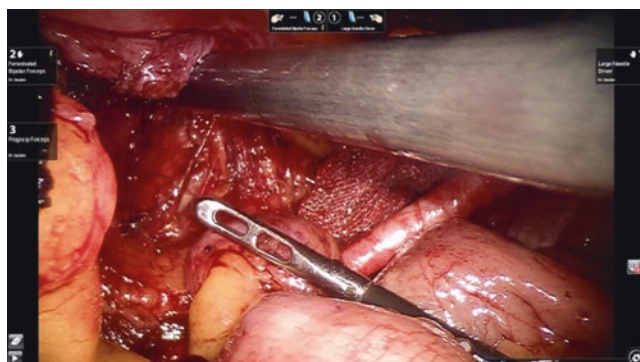

Fig. 48.37 Dissection below sigmoid mesocolon for tunneling ureter

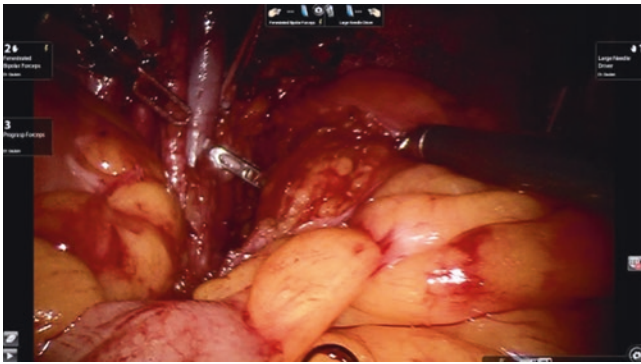


Fig. 48.38 Left ureter grasped by assistant's forceps

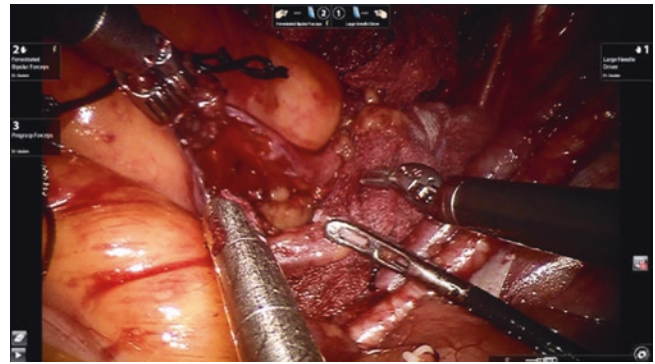


Fig. 48.39 Left ureter tunneled beneath sigmoid

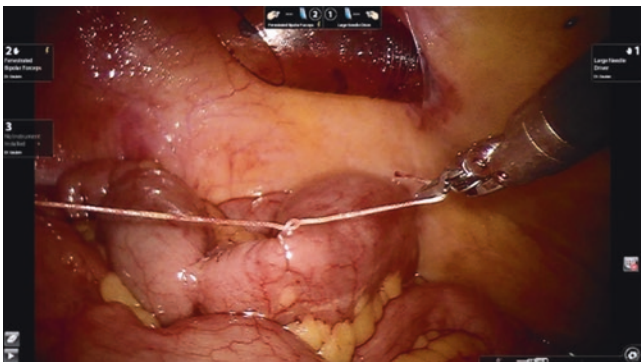


Fig. 48.40 Distal end of ileal segment to be isolated, marked with vicryl suture

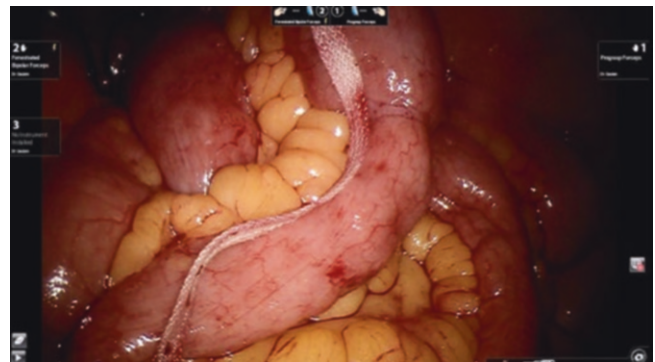

Fig. 48.41 Ileal length measured with 10 cm long umbilical tape

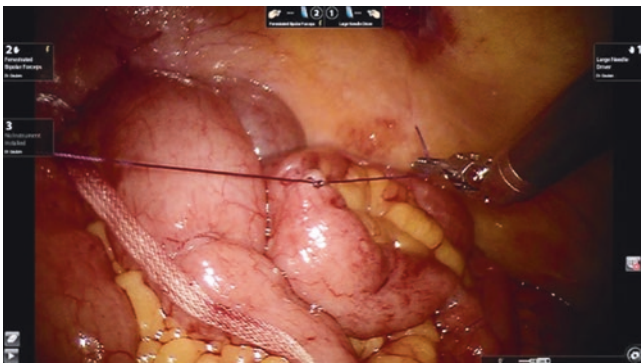


Fig. 48.42 Proximal ileal segment end marked with vicryl of different colour for orientation

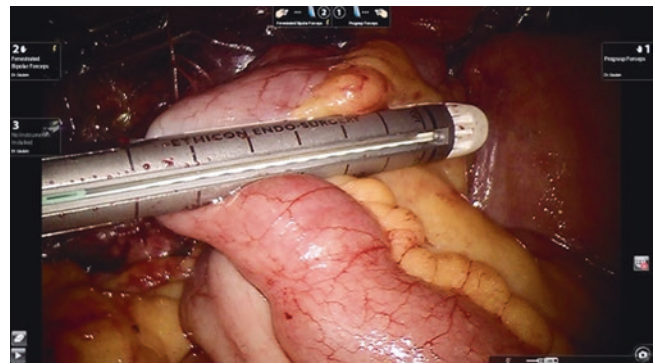


Fig. 48.43 Stapler for bowel isolation

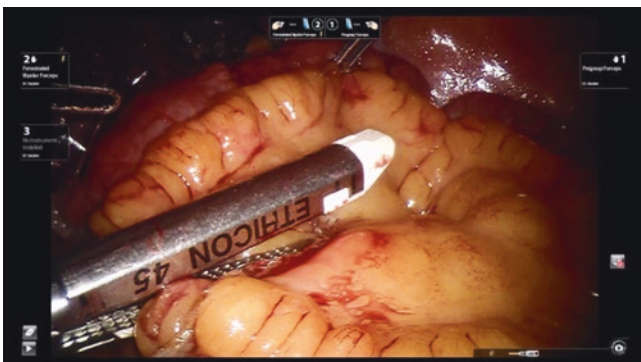

Fig. 48.44 Stapler for mesenteric control

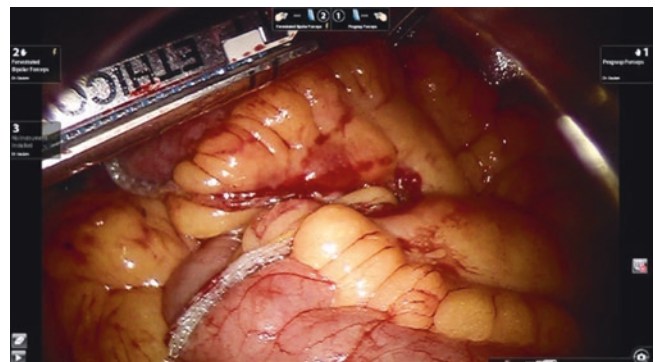


Fig. 48.45 Proximal end of isolated bowel segment after stapler isolation

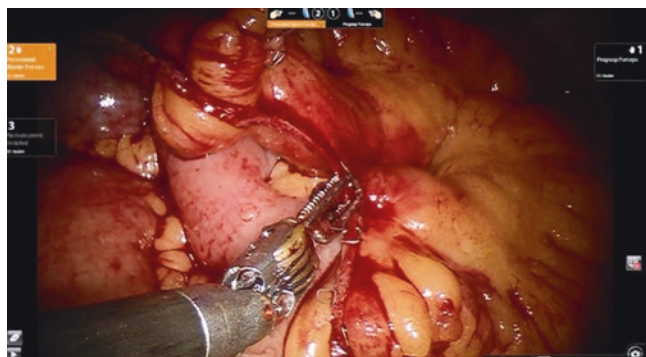


Fig. 48.46 Distal end of isolated bowel segment

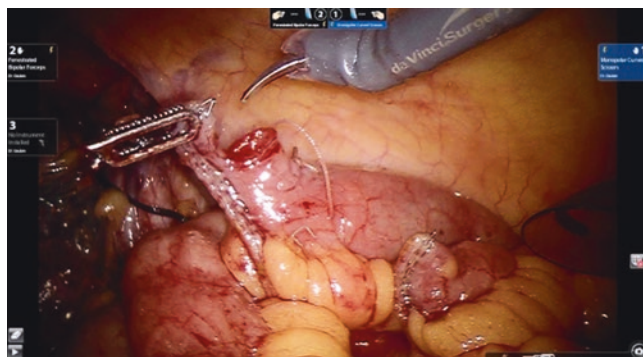


Fig. 48.47 Bowel prepared for stapled anastomosis

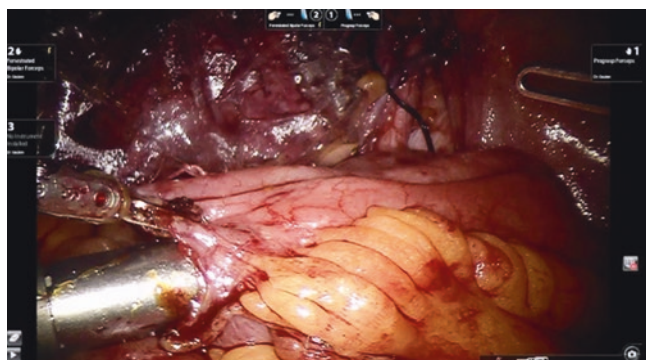


Fig. 48.48 Stapled bowel anastomosis to restore ileal continuity in progress

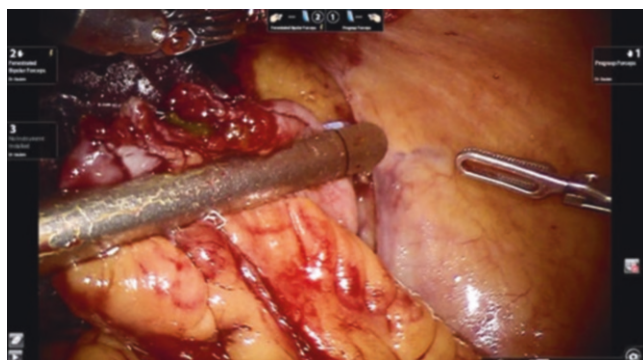

Fig. 48.49 Stapled bowel anastomosis in progress

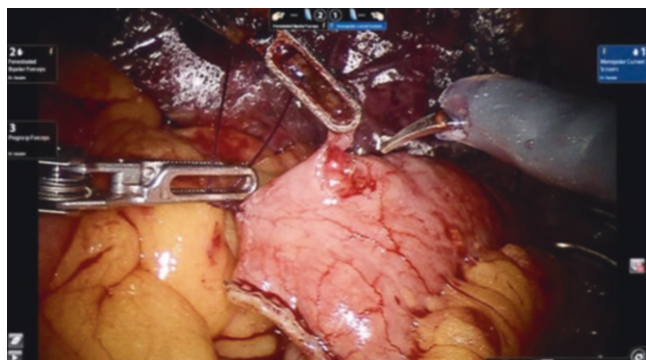


Fig. 48.50 Ileal conduit opened at proximal end for ureteric anastomosis

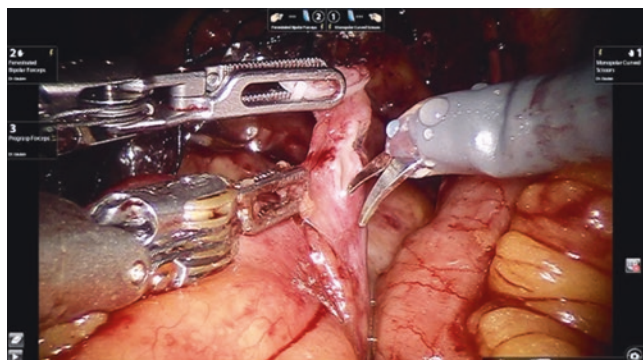


Fig. 48.51 Left ureter spatulated for anastomosis

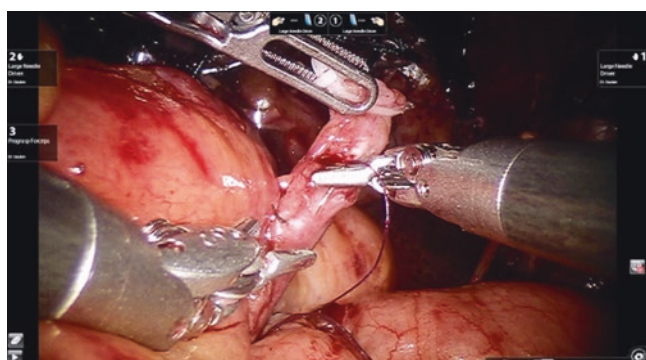


Fig. 48.52 Uretero enteric anastomosis with 4-0 PDS started

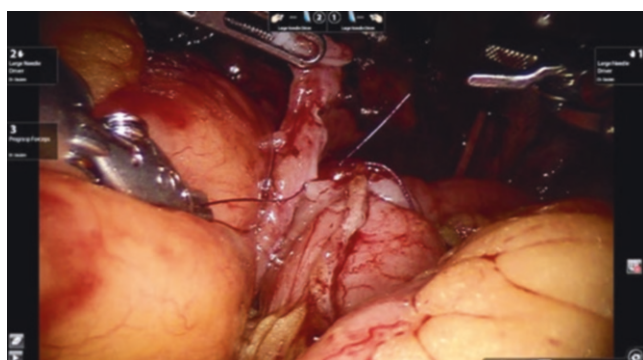


Fig. 48.53 Uretero enteric anastomosis in progress

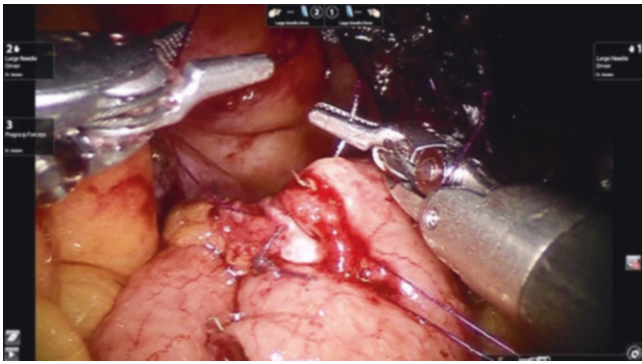


Fig. 48.54 Left uretero enteric anastomosis in progress

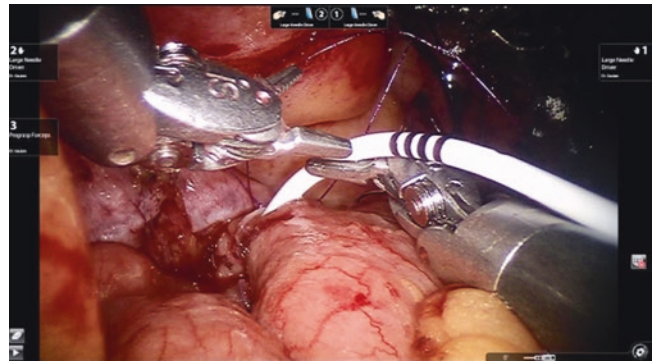


Fig. 48.55 Left ureter being stented

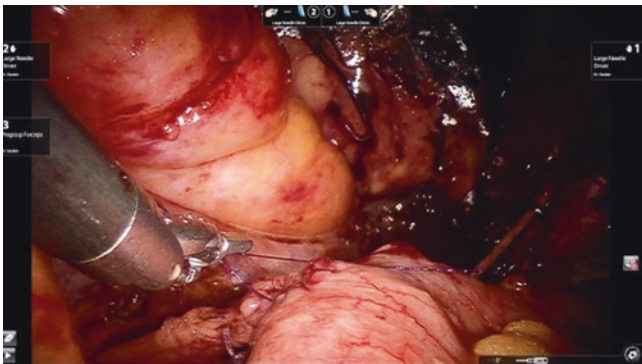


Fig. 48.56 Left uretero enteric anastomosis in progress

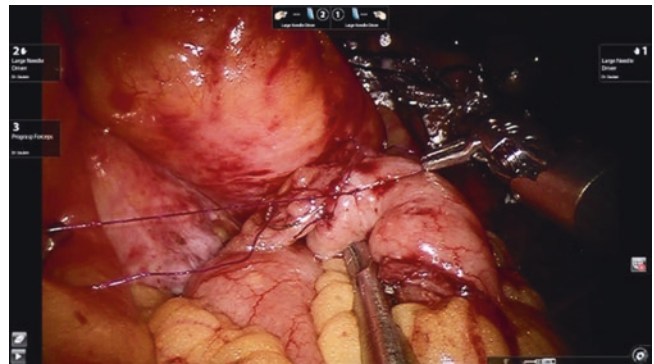


Fig. 48.57 Left uretero enteric anastomosis completed

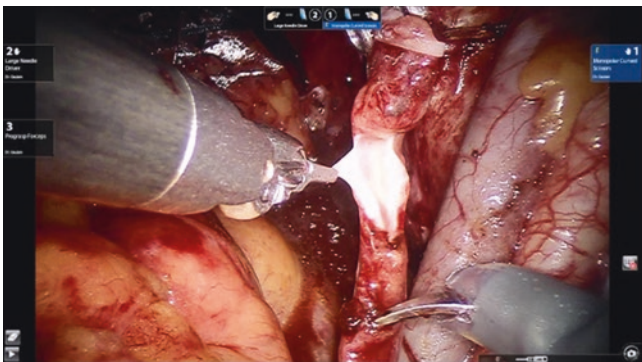


Fig. 48.58 Right ureter being spatulated

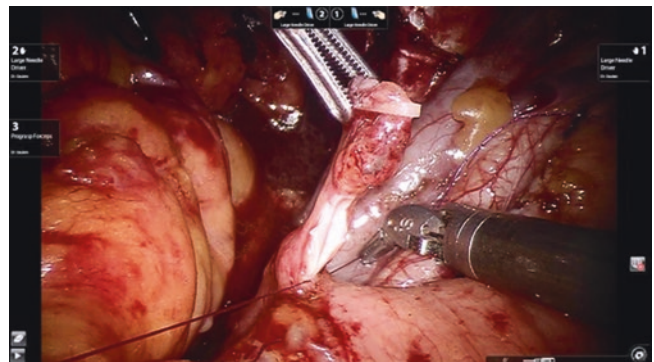


Fig. 48.59 Right uretero enteric anastomosis with 4-0 PDS started

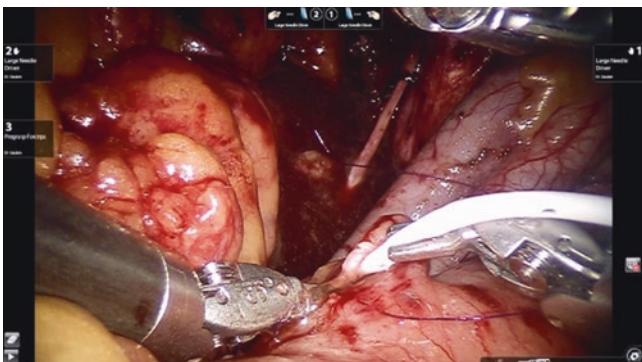


Fig. 48.60 Right ureteric stenting in progress

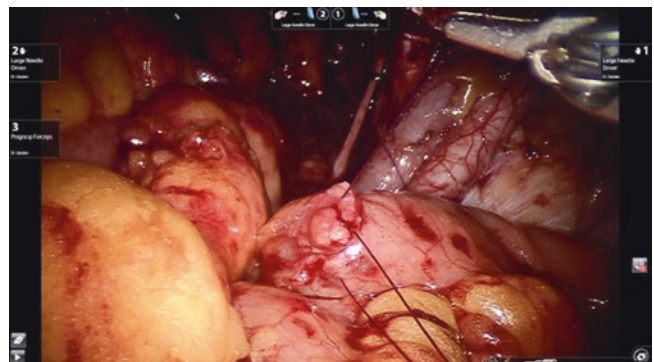

Fig. 48.61 Right uretero enteric anastomosis in progress

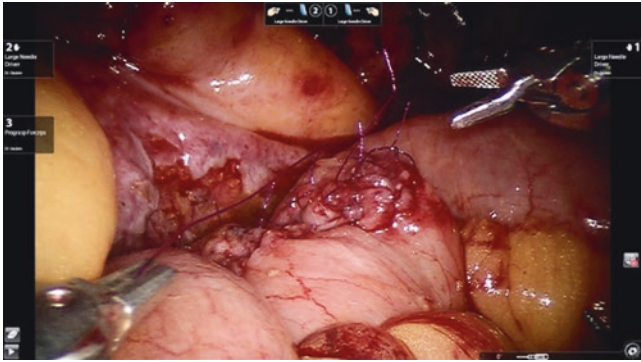


Fig. 48.62 Right uretero-enteric anastomosis completed

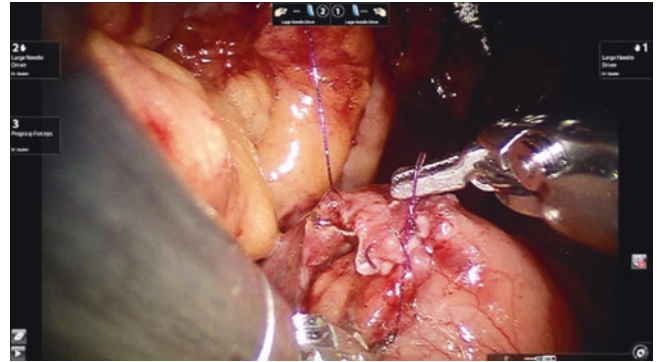


Fig. 48.63 Right uretero-enteric anastomosis in progress – post-stenting

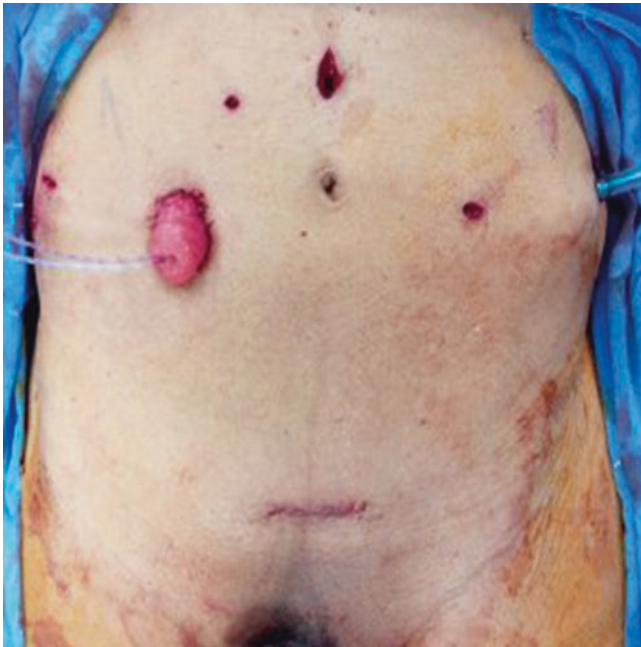

Fig. 48.64 Final view of stoma, port site and specimen retrieval site

References

1. Fonseca T, Ahmed K, Froghi S, Khan SA, Dasgupta P, Shamim KM. Comparing robotic, laparoscopic and open cystectomy: a systematic review and meta-analysis. *Arch Ital Urol Androl.* 2015;87(1):41–8.
2. Azzouni FS, Din R, Rehman S, Khan A, Shi Y, Stegemann A, Sharif M, Wilding GE, Guru KA. The first 100 consecutive, robot-assisted, intracorporeal ileal conduits: evolution of technique and 90-day outcomes. *Eur Urol.* 2013;63(4):637–43.
3. Ahmed K, Khan SA, Hayn MH, Agarwal PK, Badani KK, Balbay MD, Castle EP, Dasgupta P, Ghavamian R, Guru KA, Hemal AK, Hollenbeck BK, Kibel AS, Menon M, Mottrie A, Nepple K, Pattaras JG, Peabody JO, Poulakis V, Pruthi RS, Redorta JP, Rha KH, Richstone L, Saar M, Scherr DS, Siemer S, Stoeckle M, Wallen EM, Weizer AZ, Wiklund P, Wilson T, Woods M, Khan MS. Analysis of intracorporeal compared with extracorporeal urinary diversion after robot-assisted radical cystectomy: results from the International Robotic Cystectomy Consortium. *Eur Urol.* 2014;65(2):340–7.

Allen Sim and Christian Schwentner

49.1 Introduction

Radical cystectomy (RC) with pelvic lymph node dissection is considered to be the most effective treatment for muscle-invasive bladder cancer (BC). Moreover, it is an option in high-grade non-muscle invasive disease refractory to intravesical instillation therapy. In the majority of cases, the preferred choice of diversion is either ileal conduit or orthotopic neobladder. Open radical cystectomy is still regarded as the gold standard treatment for muscle invasive bladder cancer and high-risk non-muscle invasive bladder cancer.

However, recently minimally invasive radical cystectomy techniques have been gaining popularity. It has been shown that minimally invasive techniques are equivalent to open radical cystectomy in terms of oncological outcomes and superior when it comes to the perioperative outcomes such as shorter hospital stay and blood loss. Surrogate parameters such as nodal yield and positive surgical margins have been used to compare oncological outcomes with the open technique. Wiklund and associates have pioneered the technique of intracorporeal urinary diversion creating both neobladders and ileal conduits completely intracorporeally. The technique is to be credited as an almost identical replication of open surgical principles. Recently, the group reported their oncologic and functional outcomes of their RARC cohort showing comparable results to open series. Equally, Desai and Gill presented remarkable outcomes using a modification of the aforementioned technique.

Strict adherence to the basic surgical principles with few technical modifications is helpful in performing laparoscopic radical cystectomy and intracorporeal ileal neobladder.

However, this remains technically challenging and should be performed in high-volume centers by high-volume surgeons with considerable laparoscopic experience.

49.2 Surgical Technique

Laparoscopic radical cystectomy and intracorporeal neobladder is done using a conventional laparoscopy set. A 0° telescope is used. The patient is placed in Trendelenburg position and special care is taken to ensure proper positioning and adequate padding. This is essential due to prevent post-operative neuro-vascular injury during the long surgical procedure. Port position is shown in the picture (Fig. 49.1) Nerve sparing is attempted in both sexes, whenever oncologically sound. Extended pelvic node dissection included the external, internal and common iliac nodes, the obturator fossa and the presacral area. Para-aortic nodes are only removed when enlarged in order to preserve the hypogastric plexus as much as possible. The bladder specimen and the lymph nodes are put into impermeable retrieval bags until removal at the end. Both ureters are clipped early and the left ureter is transposed beneath the sigmoid mesocolon. They are then tagged to the lateral abdominal wall until reimplantation. At this point, the table can be flattened by 30° to reduce the amount of time patient spent in steep Trendelenburg position and also to allow the bowel to drop down to the pelvis. A 50 cm loop of terminal ileum is selected approximately 20 cm proximal to the ileocecal valve. The most dependent part is opened and anastomosed to the urethral stump using a running suture. The ileal loop is then transected proximally and distally using a 60 mm Endo-GIA stapler (Covidien) and bowel continuity is restored using a stapled side-to-side anastomosis. The isolated loop is consequently opened according to Studer's technique leaving a 15–20 cm afferent segment. The posterior plate is then reconstructed with running sutures using a 3/0 absorbable suture material. The neobladder is then asymmetrically

A. Sim (✉)

Department of Urology, Singapore General Hospital,
Outram Road, Singapore, Singapore
e-mail: Allen.sim.s.p@singhealth.com.sg

C. Schwentner

Department of Urology, Eberhard-Karls University Tuebingen,
Tuebingen, Germany

folded to a spherical reservoir applying the same suture. A 20 Fr Foley catheter is then advanced into the reservoir and it is checked for watertight closure. Transected ends of both ureters are joined by Wallace technique using a 4/0 absorbable suture. Single-J stents are placed over guide wire and the ends are advanced through the wall of the reservoir. Uretero enteric anastomosis is done to the afferent limb using a 4/0 absorbable suture. Stents are advanced to the skin through the 12 mm trocar and two drains are placed. Specimens are finally retrieved through a separate incision (Specimen may be retrieved via the vagina in women).

49.3 Tips and Tricks

Laparoscopic radical cystectomy with intracorporeal ileal neobladder is undeniably a technically challenging procedure. It is important to adhere to well-defined surgical principles while performing surgery of such complexity. From our experience we found that stepwise progression of the surgery is an important element in successful minimally invasive radical cystectomy with intracorporeal neobladder, that provides patient with good oncological, functional and perioperative outcomes. It helps to have a dedicated team, since familiarization is important not just for the surgeon, but also for the assistants, scrub team as well as the theatre staff.

The assistant should be familiar with standardized surgical steps; the scrub team should be well equipped with all the instruments, sutures and staplers required; and the OT staff should know the proper patient positioning and necessary protection. In a surgery of such high complexity, teamwork from all the members involved is crucial to ensure a smooth sailing surgery and reduce complications, conversion rate and operating time.

With adequate experience, refinement of surgical techniques also contributes to the safety and feasibility of intracorporeal neobladder. A hallmark of a good ileal neobladder is a large capacity, low pressure and high compliance reservoir for continence and ability to void voluntarily with minimal residual urine. A conventional spherical pouch has been proven urodynamically to be of high volume and low pressure and gives excellent functional outcomes. Various types of ileal neobladder have been created in patients who underwent open radical cystectomy. One study showed similar perioperative and functional outcomes using a non-spherical pouch. Some of these less complicated techniques can be adapted into laparoscopic intracorporeal neobladder and could further shorten the operating time.

In our experience, exposure to comparatively less complex intracorporeal surgeries like laparoscopic or robotic intracorporeal ileal ureter is helpful in familiarizing the steps involved in intracorporeal bowel resection and anastomosis.

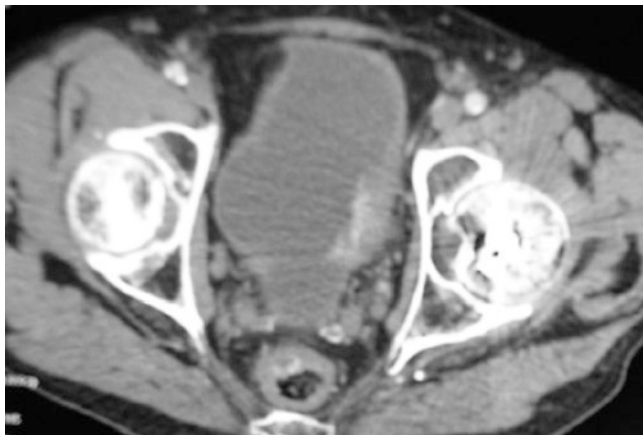


Fig. 49.1 CT image showing the invasive tumour (post TURBT)

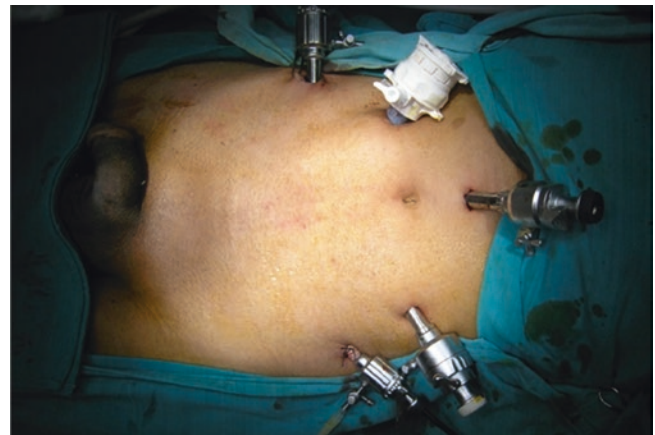

Fig. 49.2 Ports position

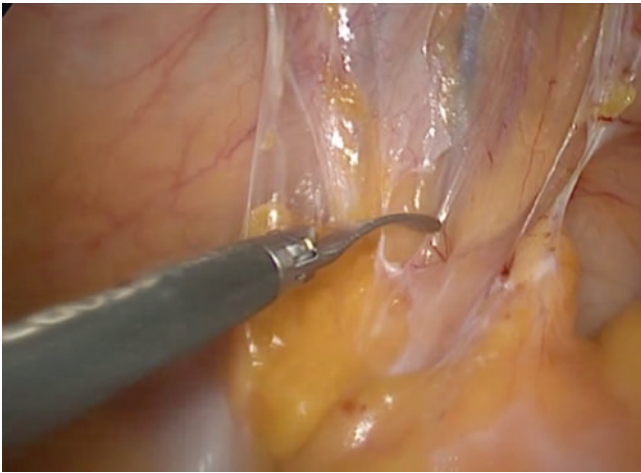


Fig. 49.3 Sigmoid adhesions being released

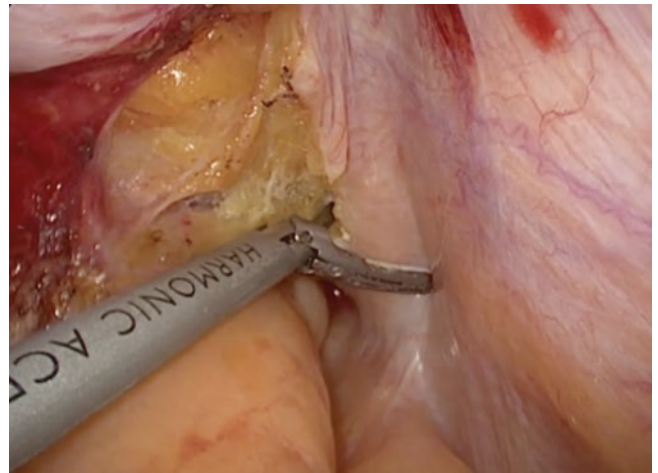


Fig. 49.4 Posterior dissection started by incising peritoneum behind bladder

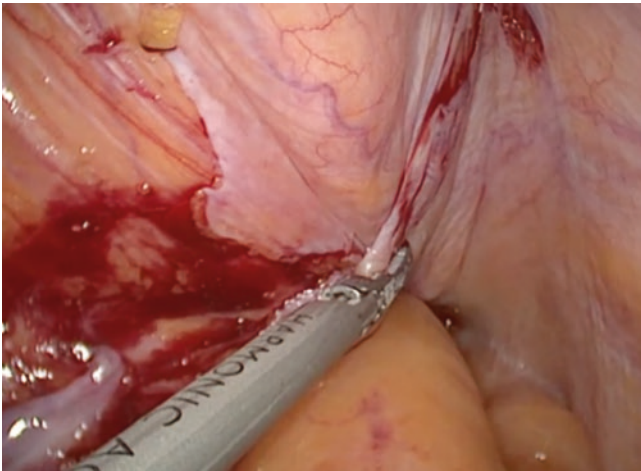


Fig. 49.5 Incision continued towards opposite side

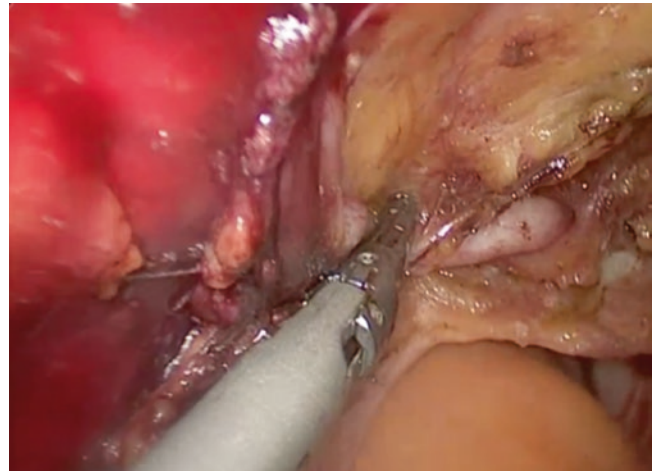


Fig. 49.6 Left vas being divided

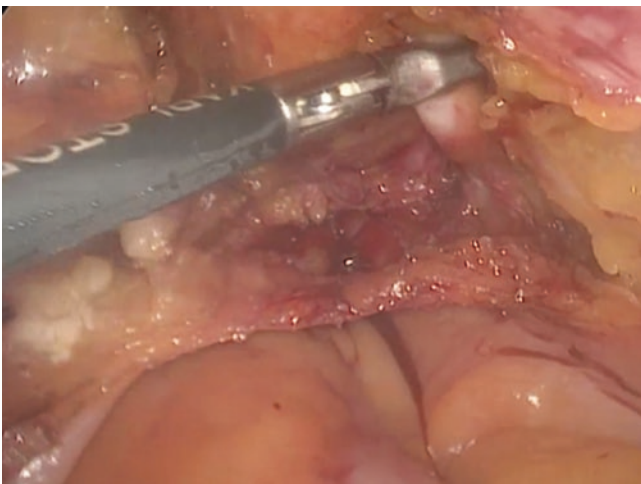

Fig. 49.7 Right vas being divided

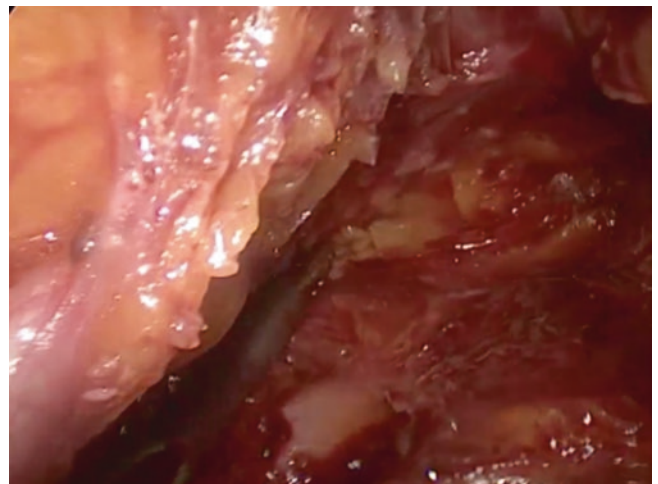


Fig. 49.8 Posterior dissection extending beyond the seminal vesicles

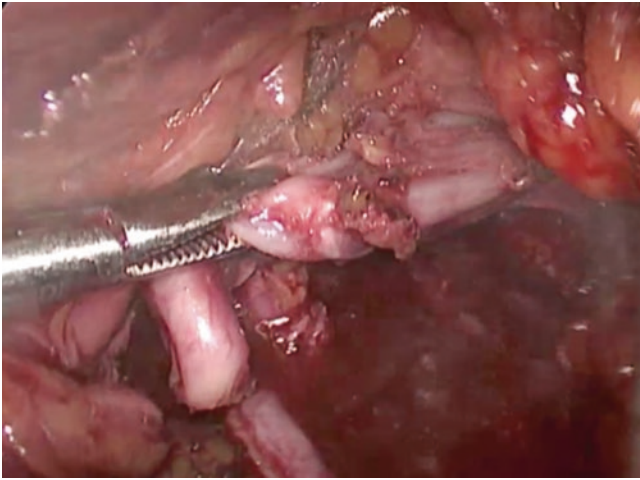


Fig. 49.9 Right seminal vesicle being dissected

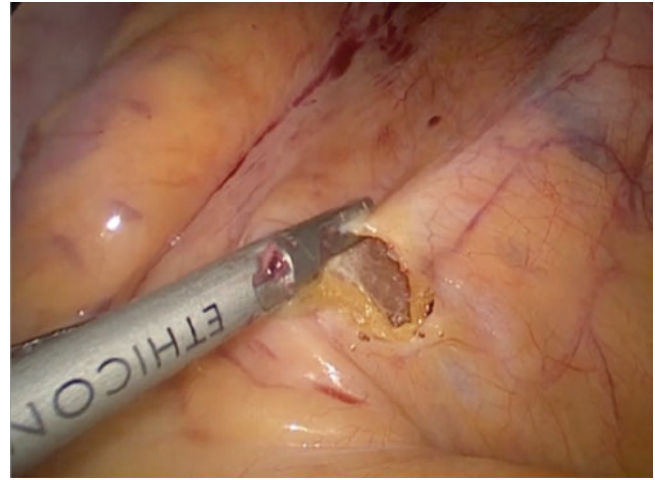


Fig. 49.10 Peritoneotomy over right iliac vessels for right ureter dissection

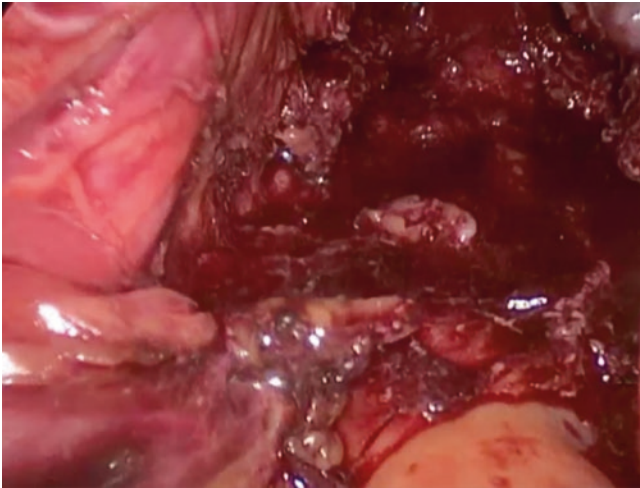


Fig. 49.11 Posterior dissection completed

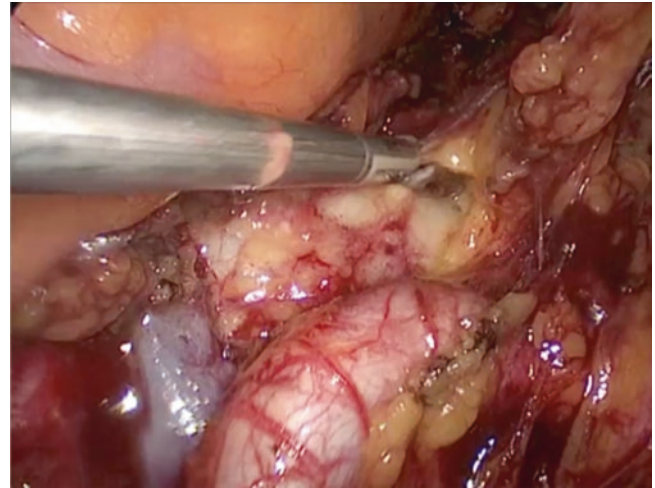


Fig. 49.12 Right iliac lymphadenectomy in progress

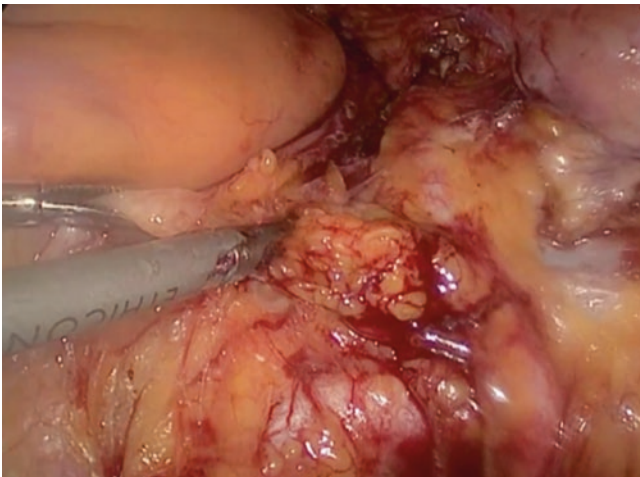


Fig. 49.13 Right ureter being dissected

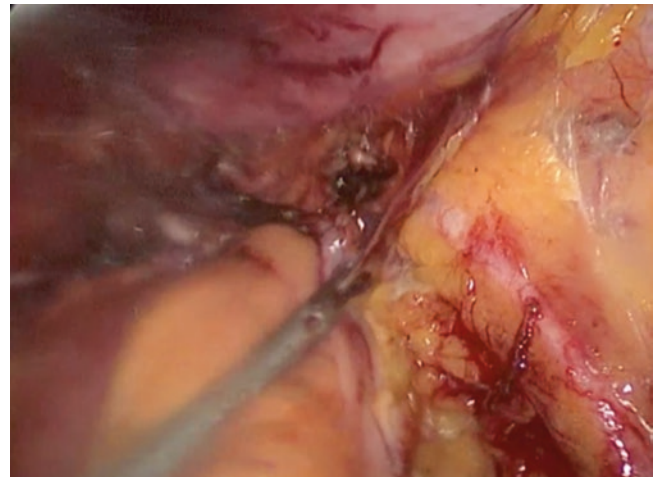


Fig. 49.14 Right ureter dissection in progress

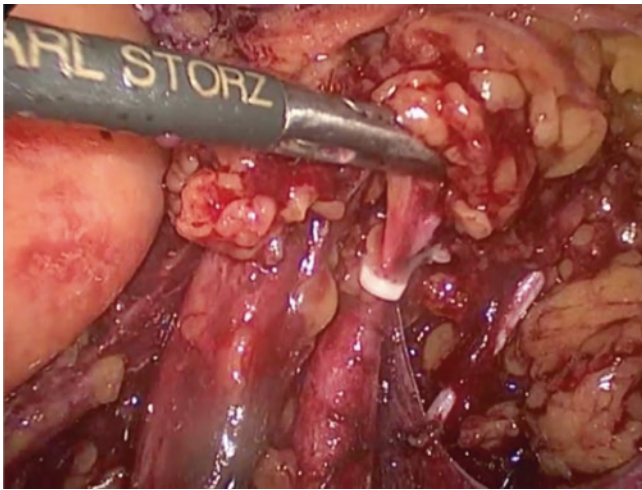


Fig. 49.15 Right obliterated umbilical artery clipped

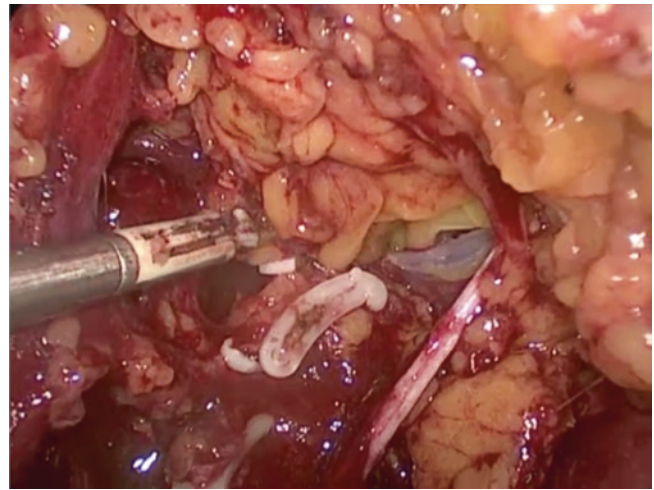


Fig. 49.16 Right lateral vesical pedicle handled with hemolock clips

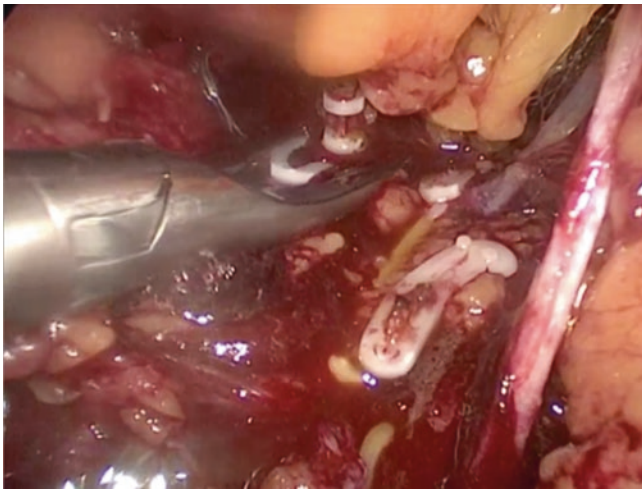


Fig. 49.17 Right lateral pedicle control

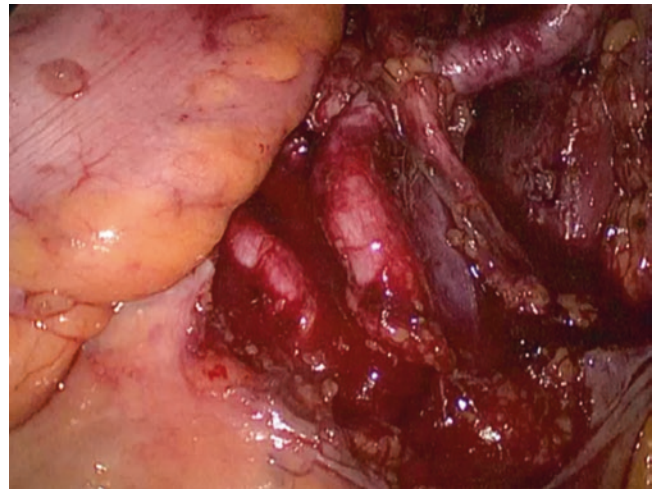


Fig. 49.18 Right extended lymphadenectomy completed

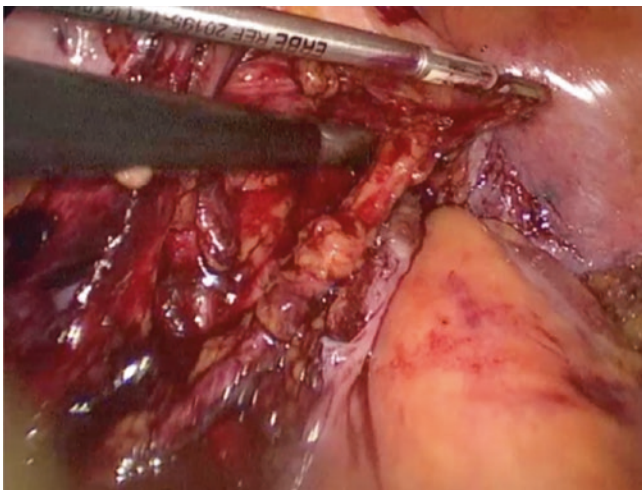


Fig. 49.19 Left ureteric dissection in progress

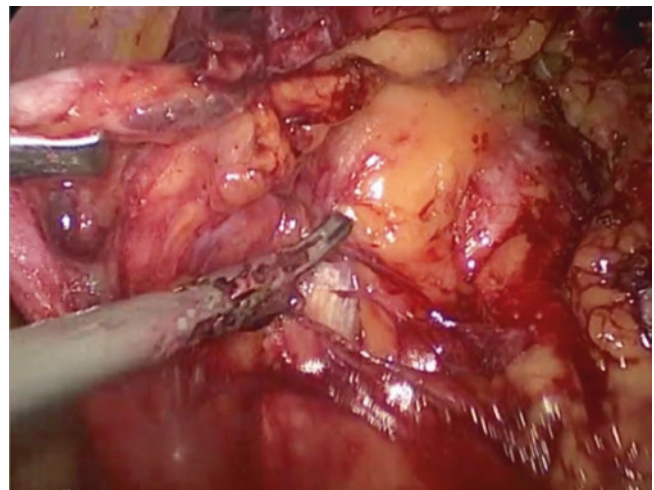


Fig. 49.20 Left iliac lymphadenectomy in progress

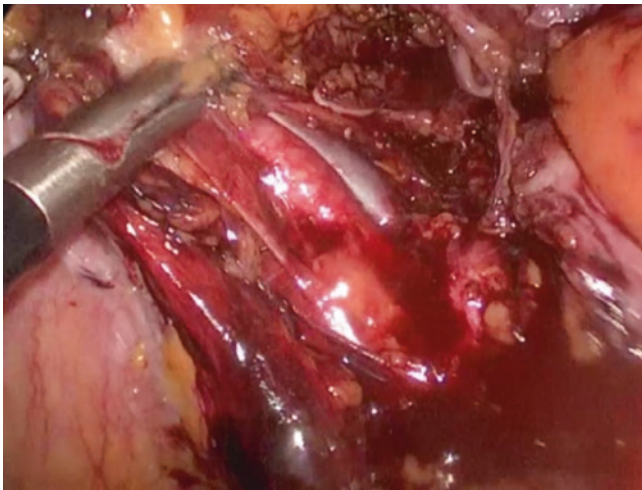


Fig. 49.21 Left iliac lymphadenectomy in progress

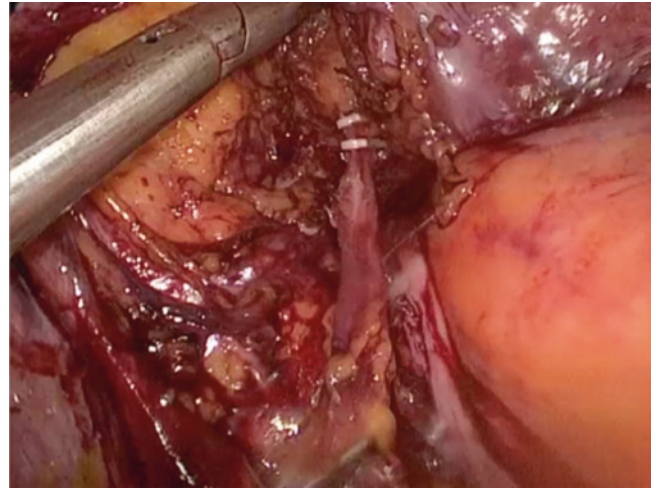


Fig. 49.22 Left ureter clipped

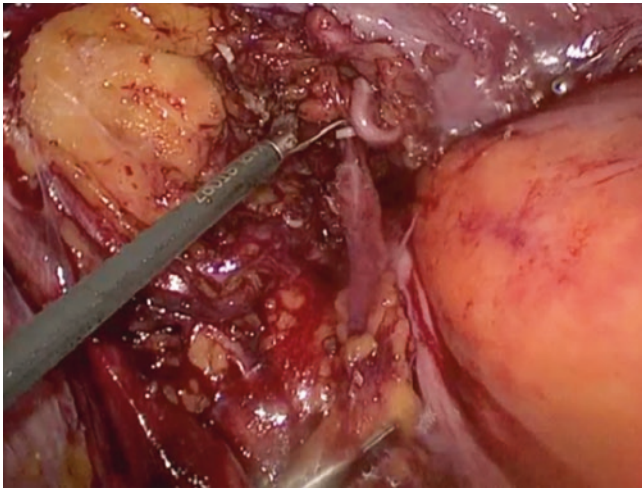


Fig. 49.23 Left ureter being divided

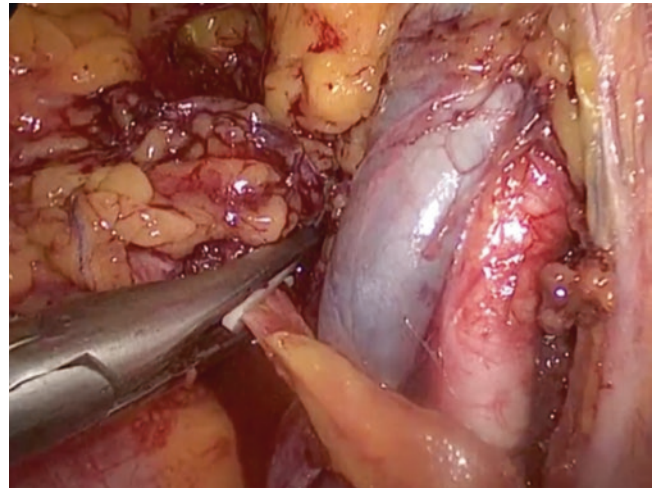


Fig. 49.24 Right ureter clipped

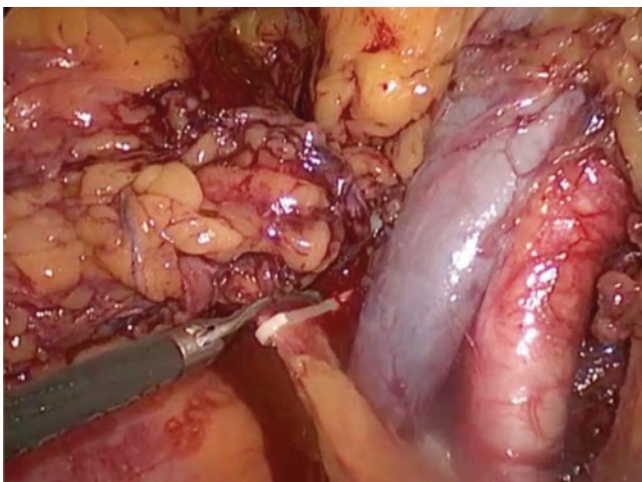


Fig. 49.25 Right ureter divided

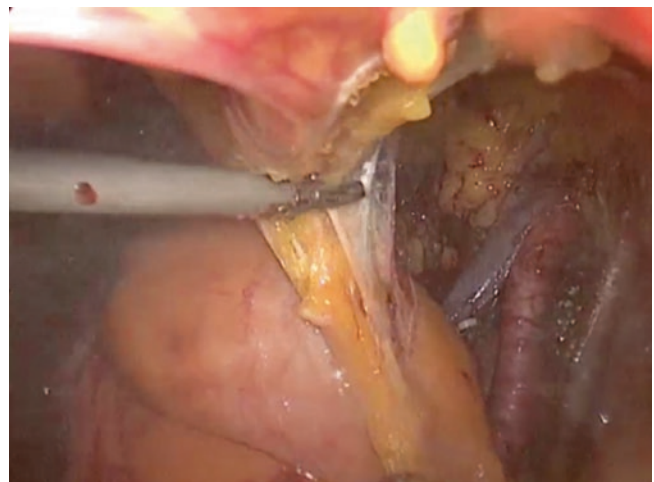


Fig. 49.26 Bladder dropped down

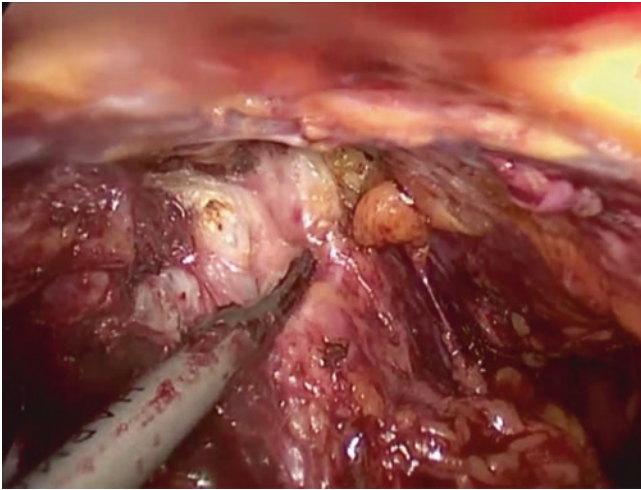


Fig. 49.27 Control of superficial dorsal vein with ultrasonic shears

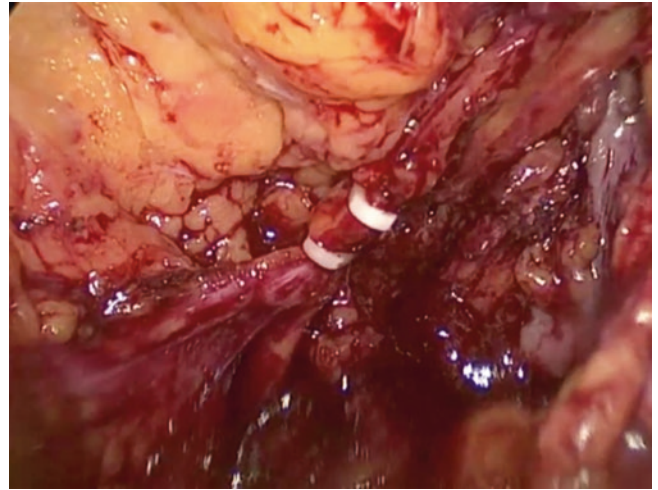


Fig. 49.28 Left lateral pedicle control

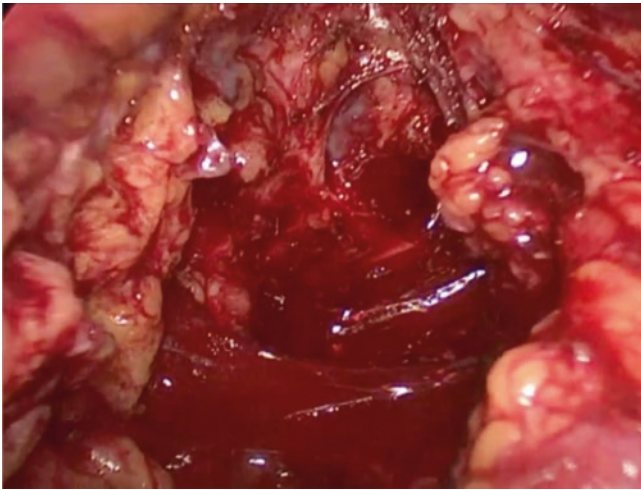


Fig. 49.29 Left endopelvic fascia incised

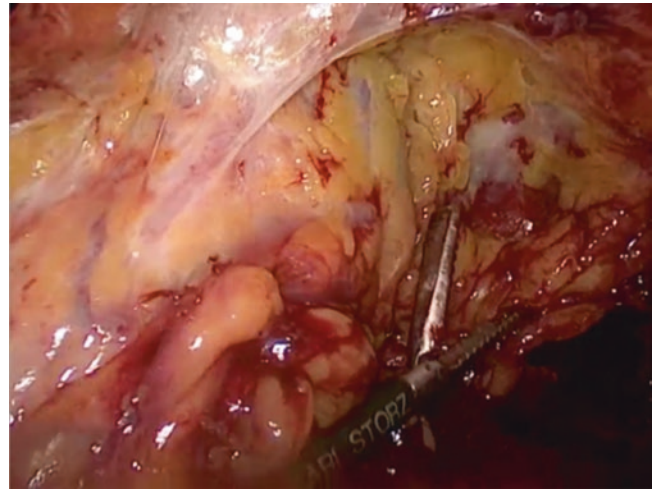


Fig. 49.30 Right endopelvic fascia being dissected

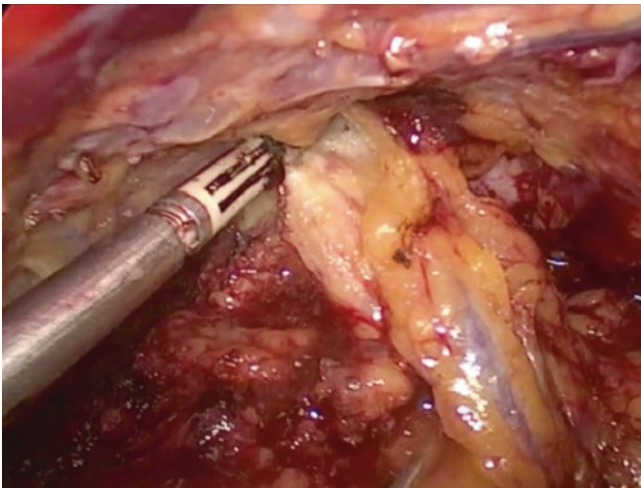


Fig. 49.31 Dorsal venous complex controlled with bipolar diathermy

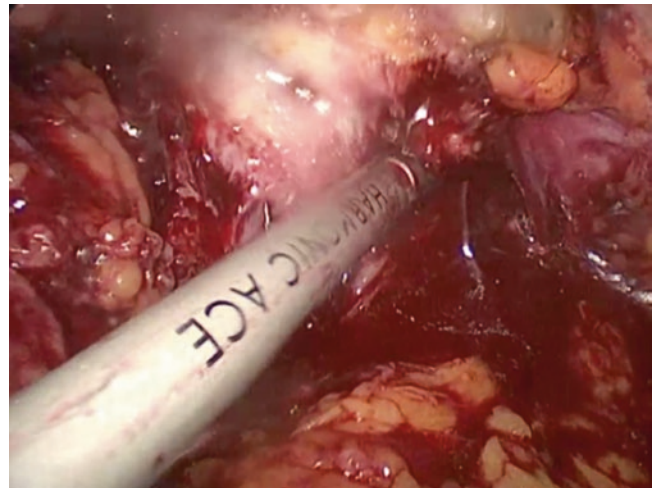


Fig. 49.32 Right lateral pedicle of prostate being controlled

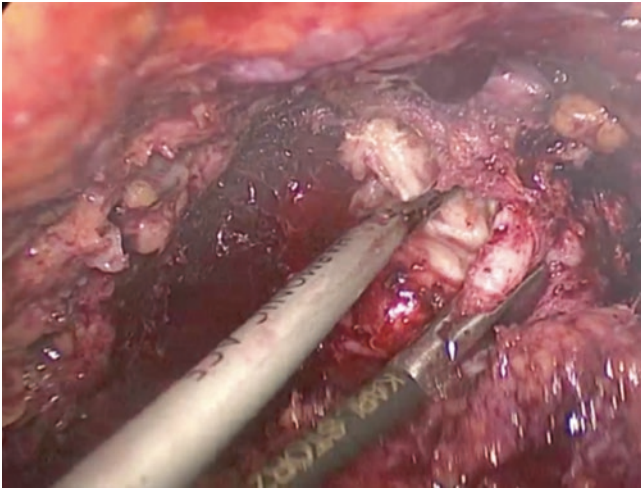


Fig. 49.33 Prostatic apex divided with ultrasonic shears

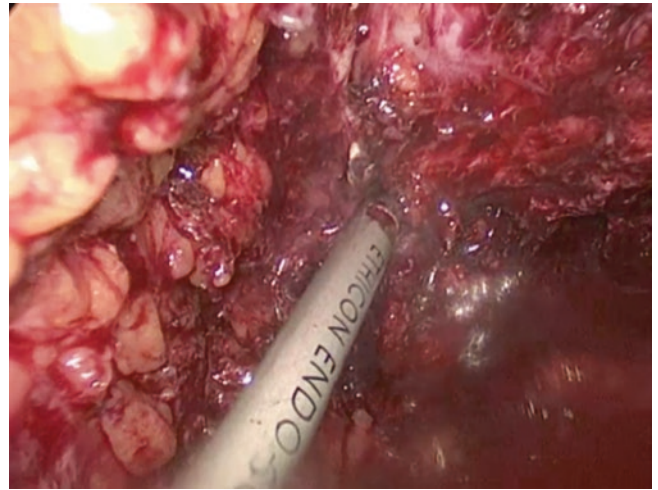


Fig. 49.34 Prostatic lateral pedicle control

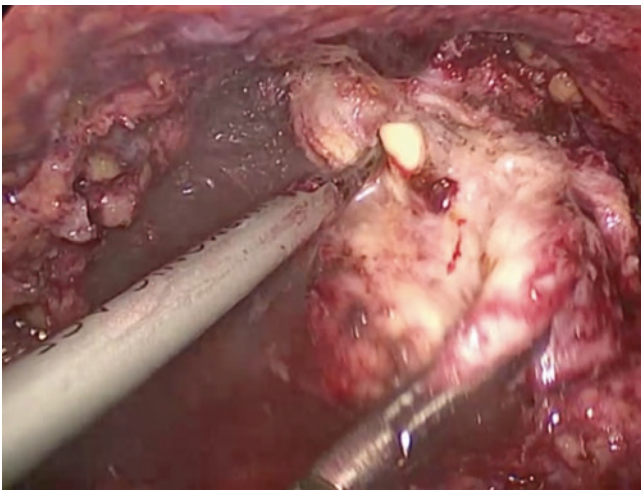


Fig. 49.35 Division of prostatic apex in progress

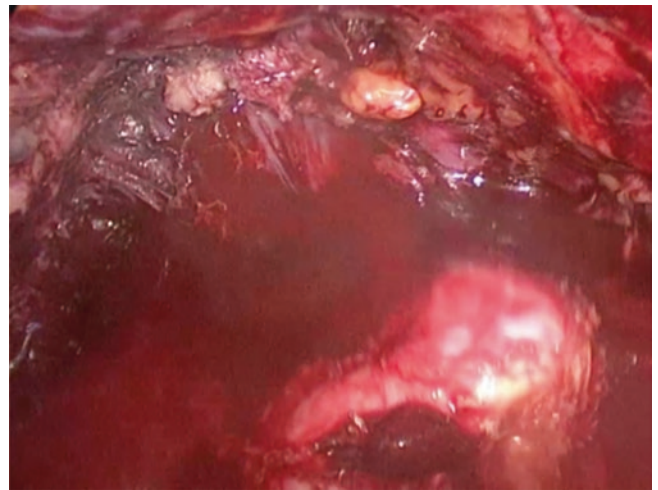


Fig. 49.36 Prostate being dissected off rectum

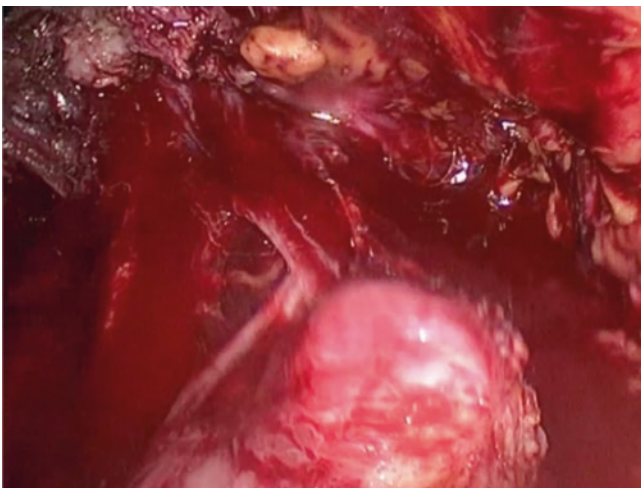


Fig. 49.37 Prostate lifted from Denonvilliers fascia

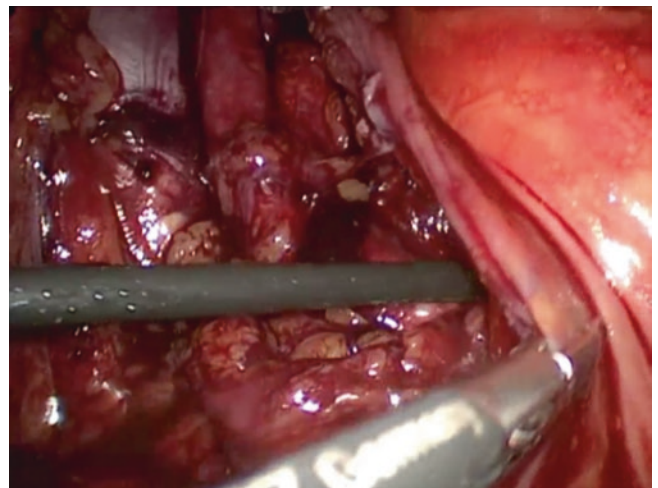


Fig. 49.38 Left ureter tunneled beneath sigmoid

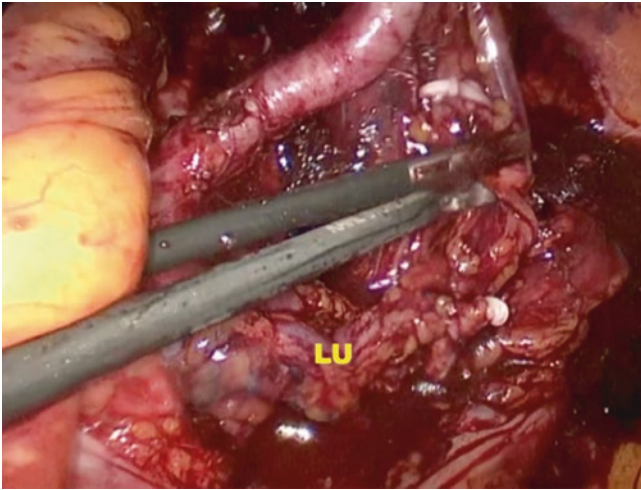


Fig. 49.39 Left ureter brought to right iliac fossa

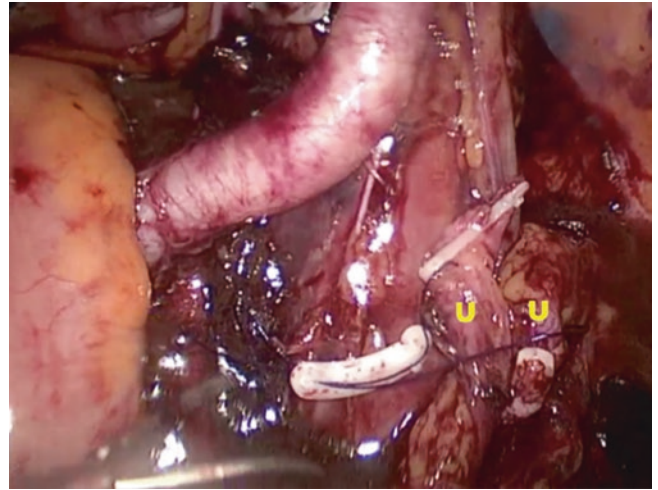


Fig. 49.40 Both ureters tacked over right psoas

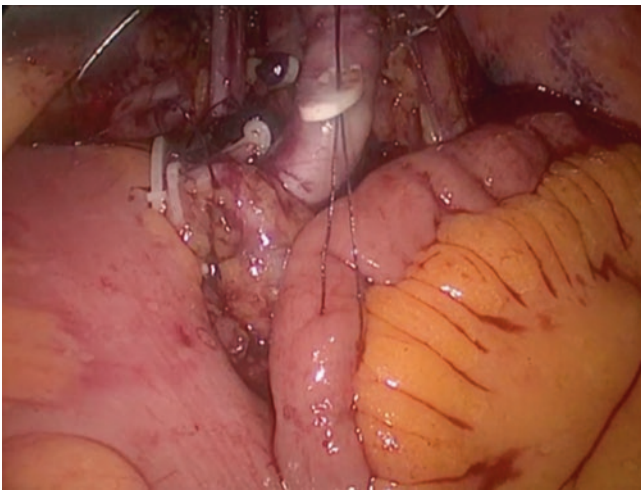


Fig. 49.41 One end of ileal segment marked with clip

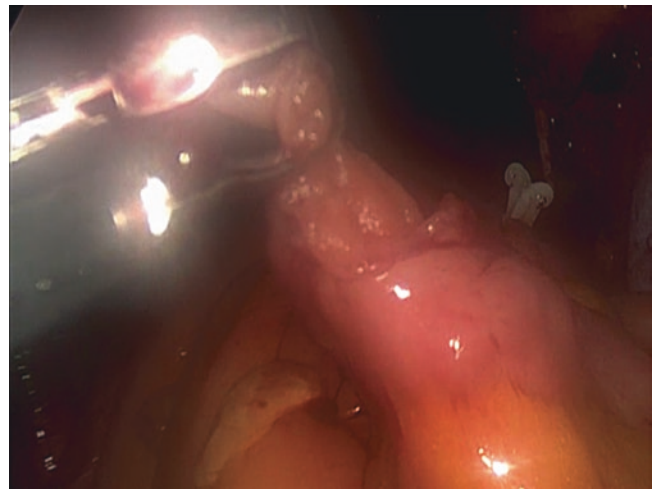


Fig. 49.42 Button of ileum excised for urethral anastomosis

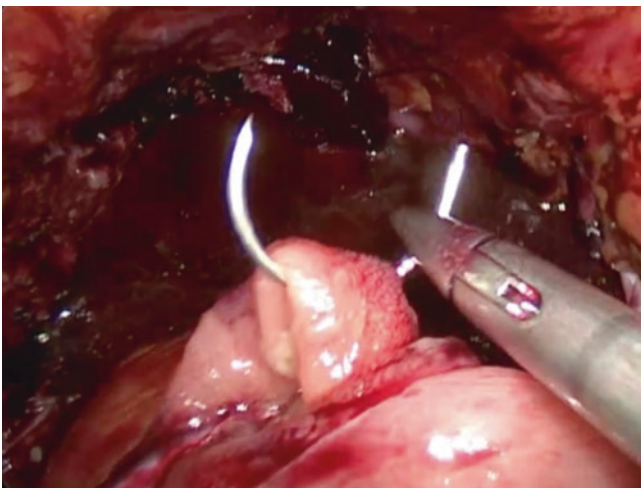


Fig. 49.43 Initial suture with CT1 needle outside in through the ileal end

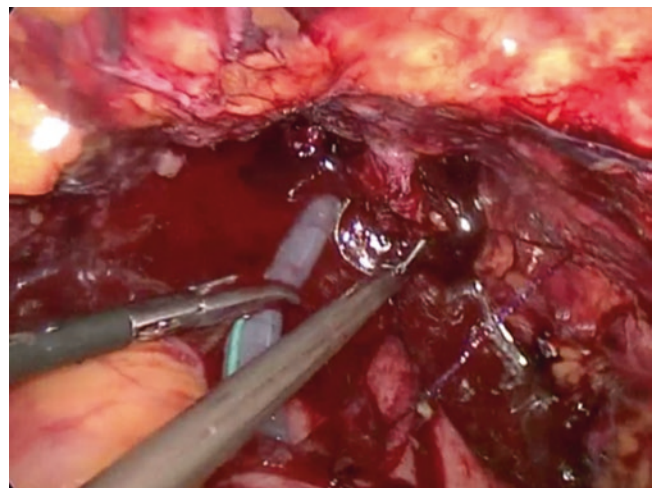


Fig. 49.44 Corresponding suture inside out of urethral end

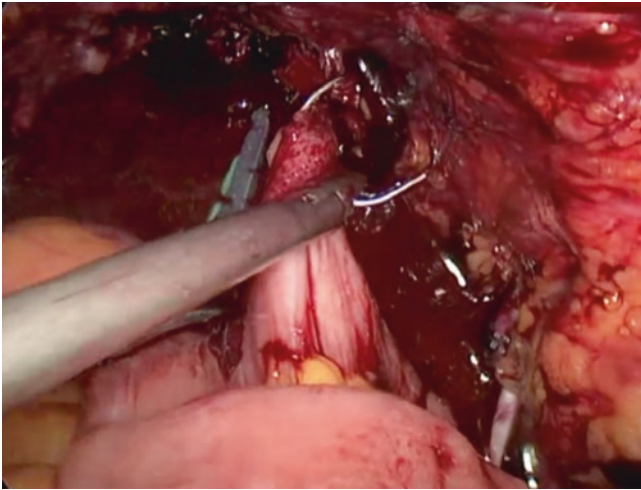


Fig. 49.45 Vesico urethral anastomosis by continuous suture in progress

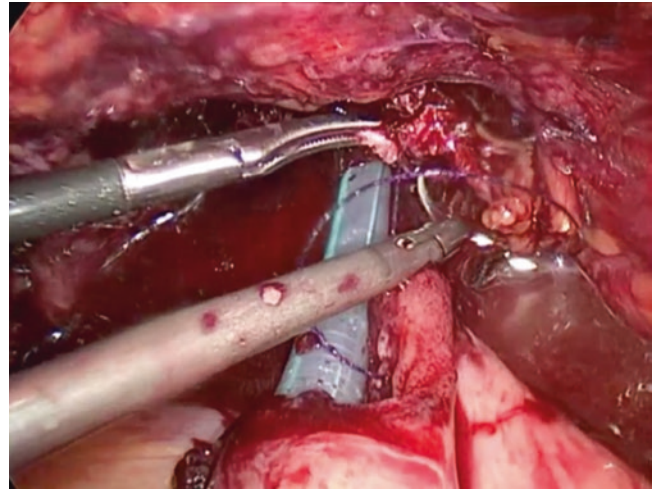


Fig. 49.46 Vesico urethral anastomosis in progress

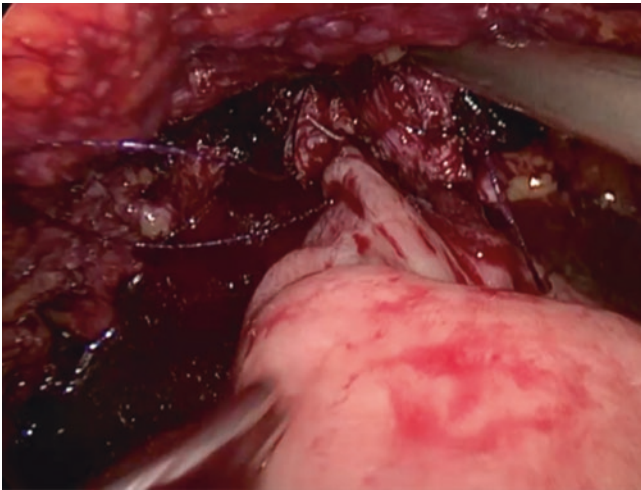


Fig. 49.47 Vesico urethral anastomosis in progress

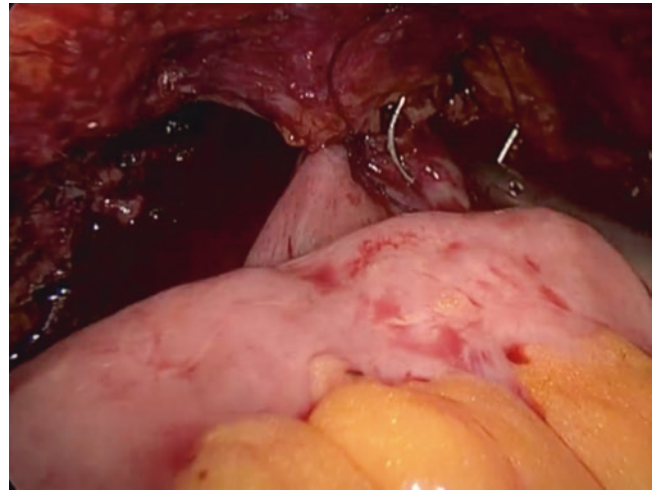


Fig. 49.48 Vesico urethral anastomosis in progress

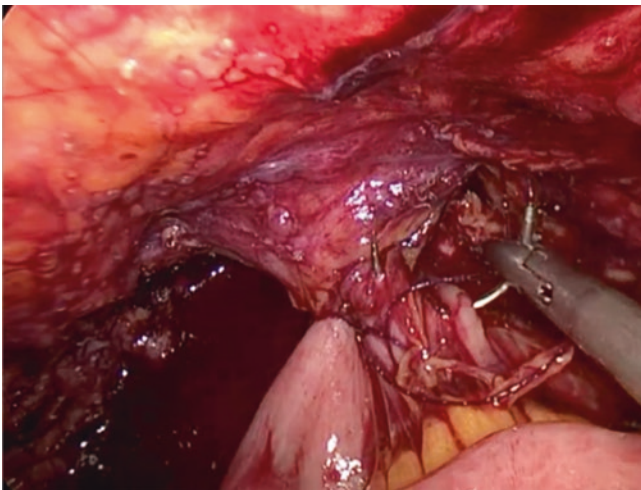


Fig. 49.49 Final suture of vesico urethral anastomosis in progress

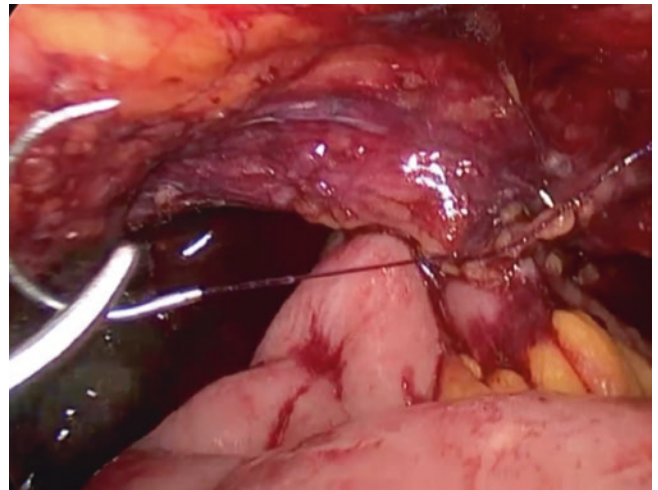


Fig. 49.50 Vesico urethral anastomosis complete

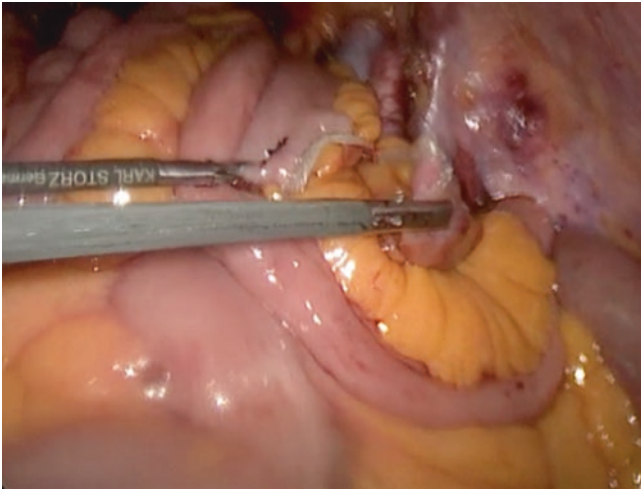


Fig. 49.51 Bowel isolation with stapler1 ???

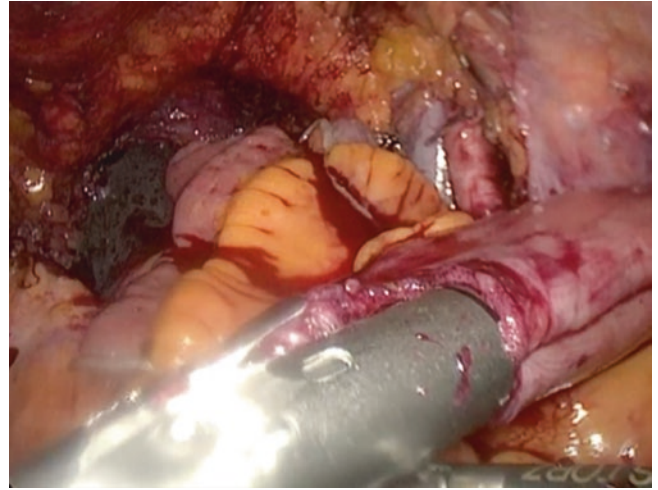


Fig. 49.52 Stapled anastomosis of bowel for restoring ileal continuity

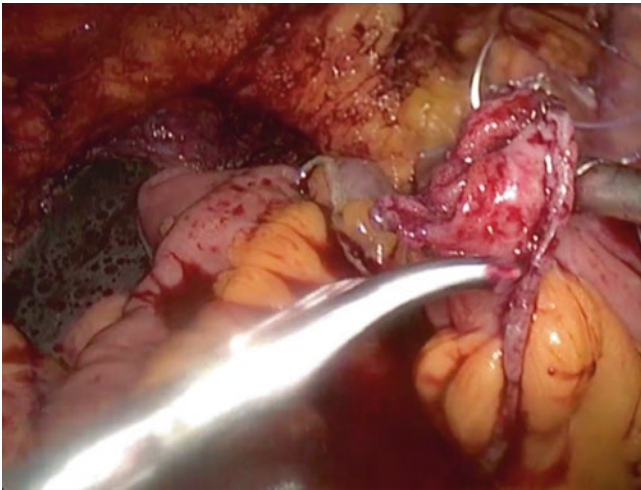

Fig. 49.53 Closure of staple rent with vicryl

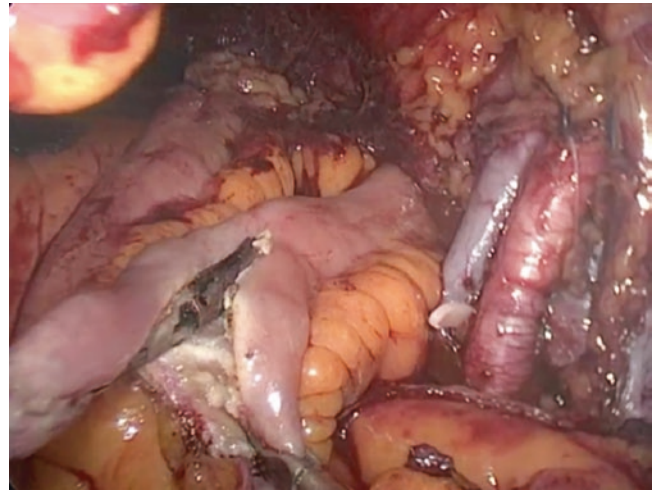

Fig. 49.54 Isolated ileal segment being detubularised

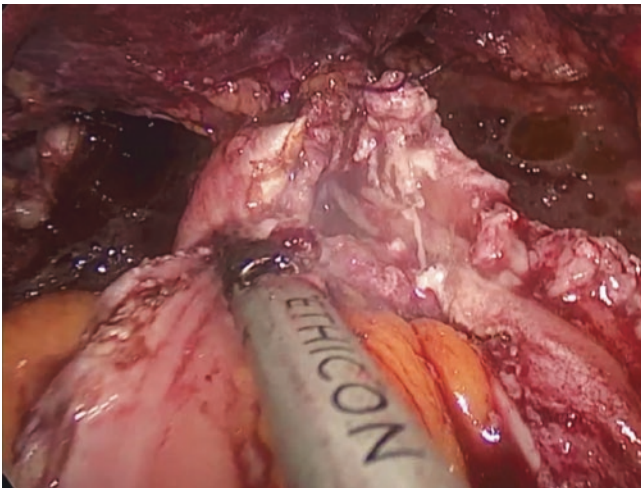


Fig. 49.55 Detubularisation in progress

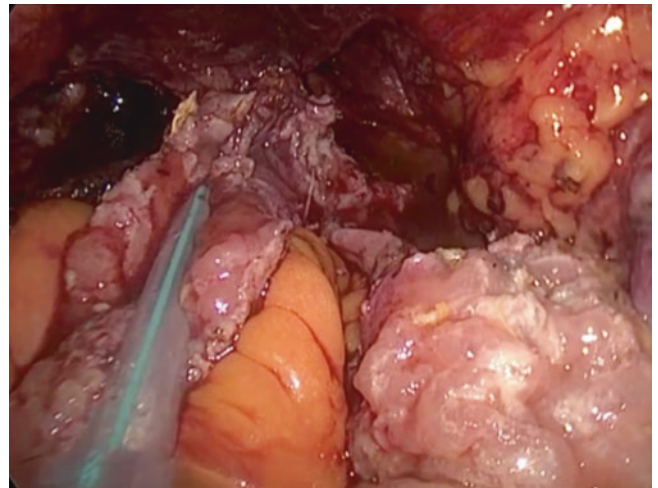


Fig. 49.56 Completely detubularised bowel

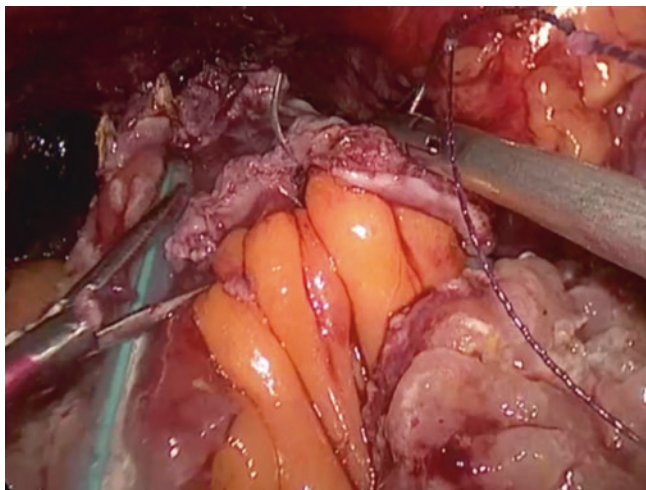


Fig. 49.57 Neobladder Reconstruction with 2-0 V Lock continuous suture started

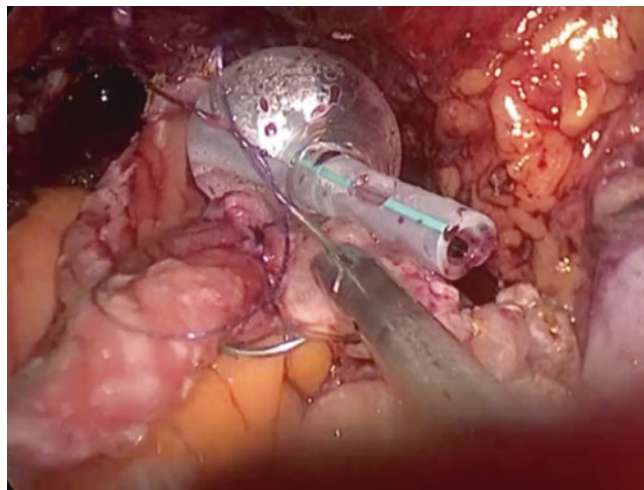


Fig. 49.58 Posterior layer suturing

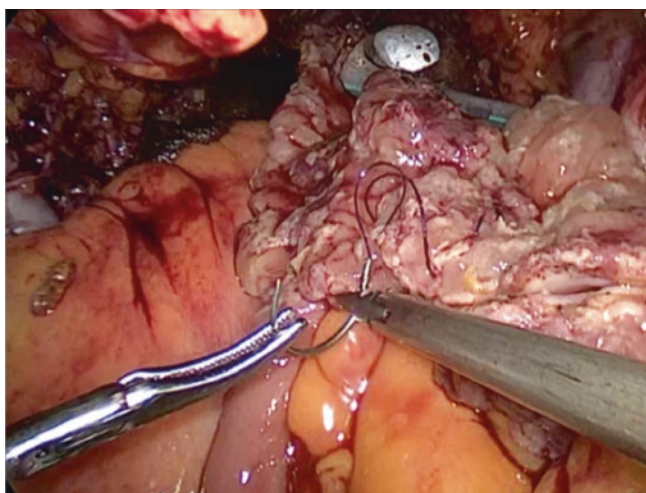


Fig. 49.59 Posterior wall suturing completed

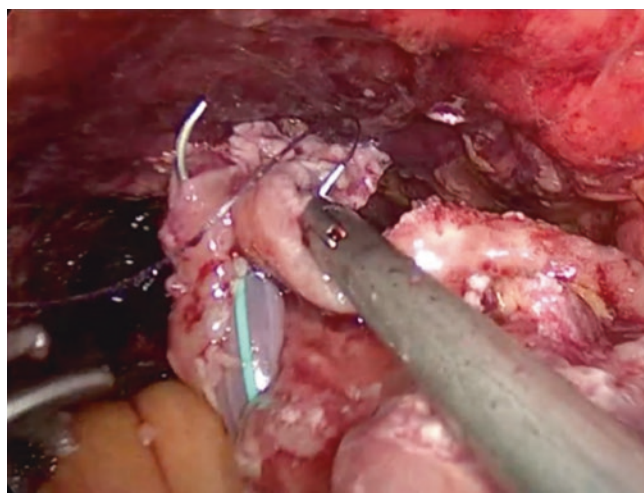


Fig. 49.60 Anterior layer suturing in progress

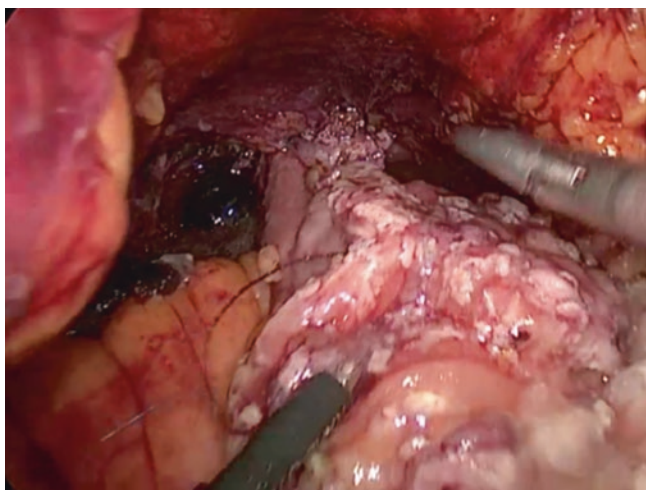


Fig. 49.61 Anterior layer reconstruction in progress

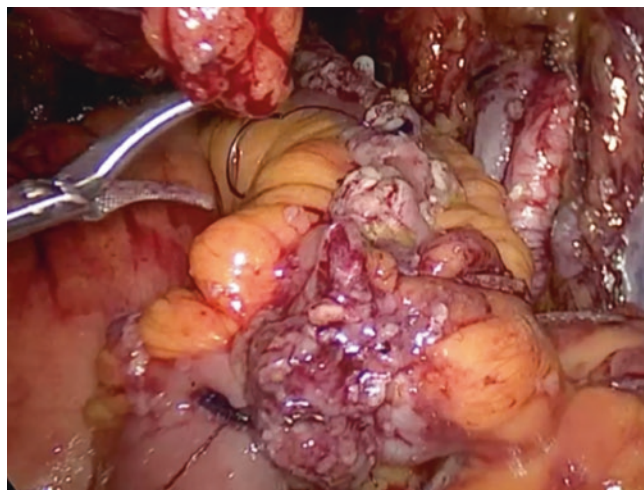

Fig. 49.62 Reconstruction complete

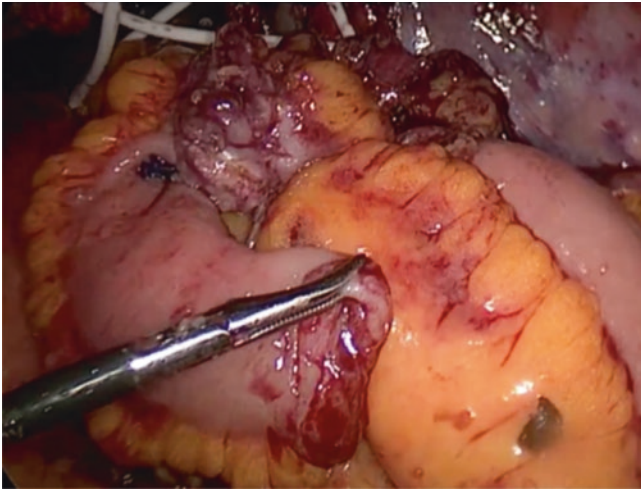


Fig. 49.63 Proximal end prepared for ureteric anastomosis

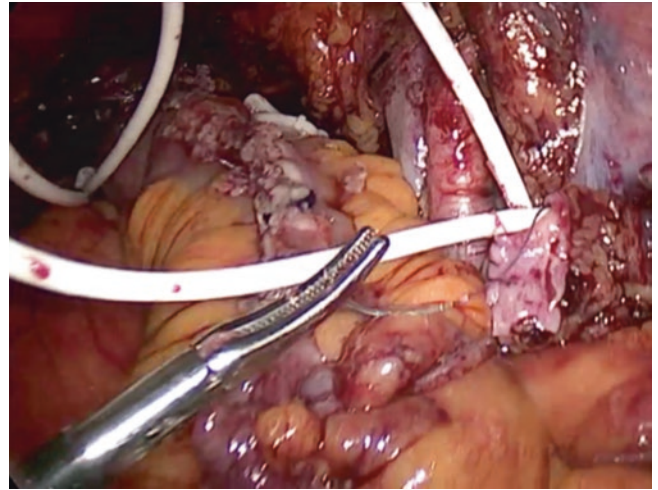


Fig. 49.64 Stents placed. Uretero enteric anastomosis by Wallace technique

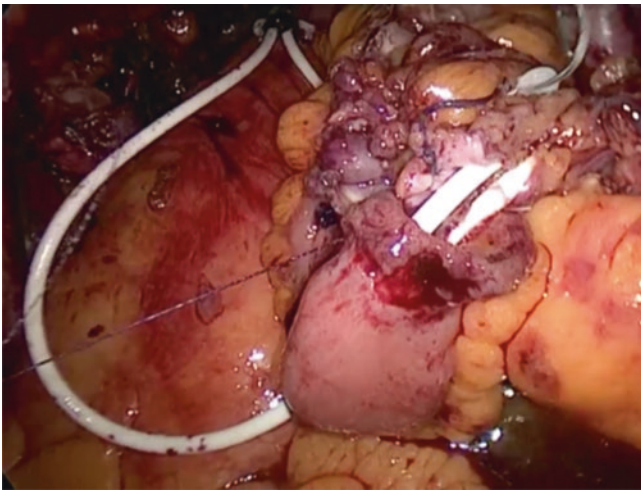


Fig. 49.65 Reimplantation in progress

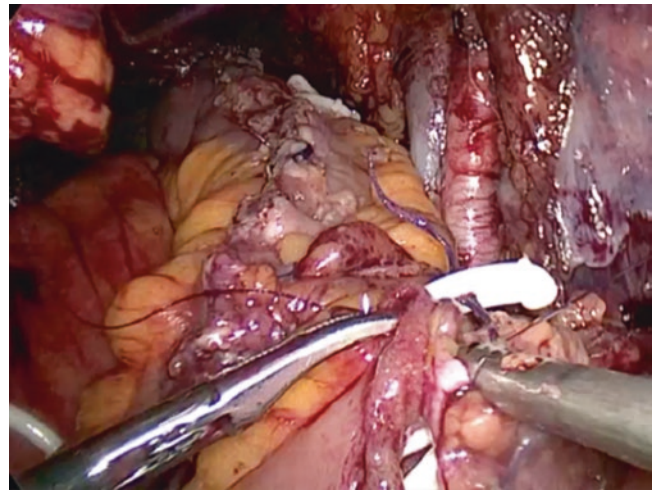


Fig. 49.66 Uretero enteric anastomosis in progress

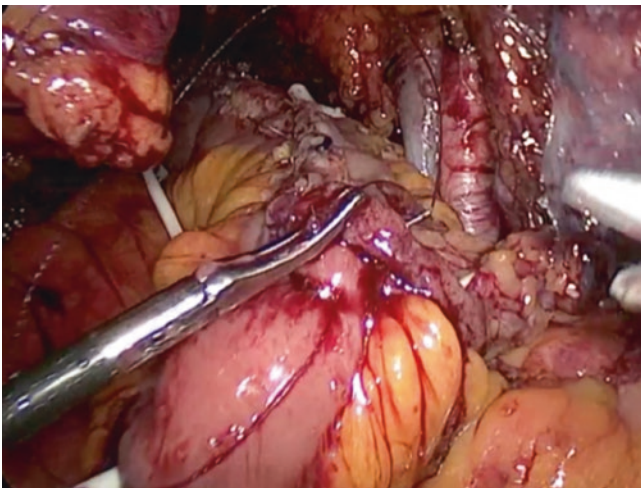


Fig. 49.67 Uretero enteric anastomosis in progress

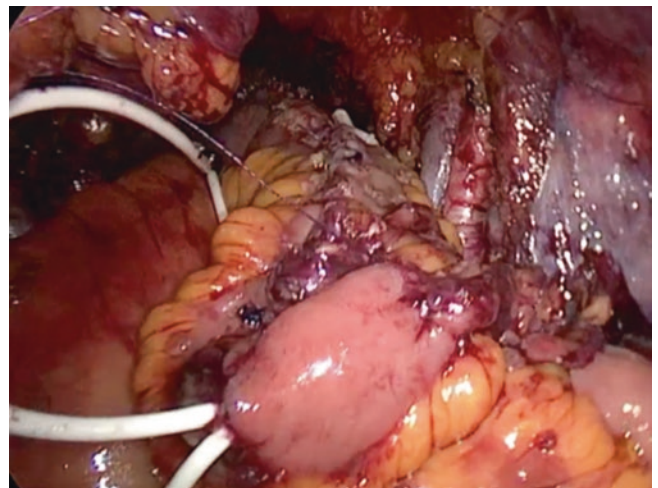


Fig. 49.68 Ureteric reimplantation complete

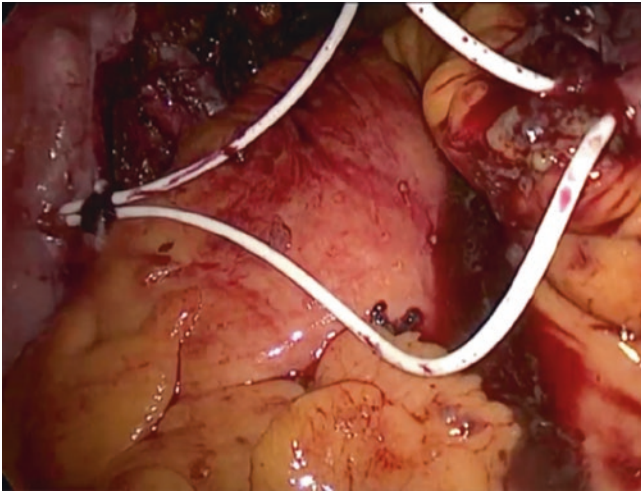


Fig. 49.69 Exteriorised stent

Specimen retrieval.

Final view stoma-Faridha, photoshop or email Alen

Manickam Ramalingam, Kallappan Senthil,
Anandan Murugesan, and Mizar G. Pai

Laparoscopic radical cystectomy with extracorporeal neobladder.

50.1 Introduction

Orthotopic neobladder is the preferred form of urinary diversion after radical cystectomy. Completely laparoscopic intracorporeal neobladder, though preferable, is time consuming and needs very high level of laparoscopy skills [1, 2]. Extracorporeal neobladder reconstruction helps to reduce the overall surgery duration and also provides the benefit of two teams working in tandem, reducing surgeon fatigue. The almost inevitable abdominal incision to remove the bladder can be used for exteriorizing the bowel for extracorporeal neobladder reconstruction.

50.2 Method

Anesthesia, port position, technique of radical cystectomy are similar to that used for other types of diversion. This is explained in detail elsewhere in this book. After completion

M. Ramalingam (✉)
PSG Hospitals,
Coimbatore, India
e-mail: uroram@yahoo.com

K. Senthil
Urology Clinic, Gowtham Annexe, Coimbatore, India
e-mail: senthilsatya@hotmail.com

A. Murugesan
Department of Urology, PSG Institute of Medical Sciences
and Research, Peelamedu, Coimbatore, Tamil Nadu, India
e-mail: anandan79@gmail.com

M.G. Pai
Urology Clinic, 3/1054, Gowtham Annexe, Avinashi Road,
Coimbatore 641018, India
e-mail: mizargpai@yahoo.co.in

of cystectomy, the left ureter is tunneled to the right iliac fossa and both the ureters are fixed together. The bowel segment needed for neobladder reconstruction is identified. The ileal segment which could reach the pelvis without tension in the mesentery is selected. Proximal and distal ends of the selected segment are marked with two different coloured sutures for identification. An 8 cm midline incision below umbilicus is made, bladder specimen removed and bowel segment exteriorized.

Neobladder is created extracorporeally and the uretero ileal anastomosis is completed if the ureters can be brought out with minimal stretch. The neobladder is intraperitonealised and abdomen closed. Urethro vesical anastomosis is done by Von Velthoven technique using 3-0 monocril sutures. Uretero ileal anastomosis, if not done earlier, can be done by Bricker method over a stent with 4-0 vicryl sutures. Suprapubic catheter, urethral catheter and drain are placed.

50.3 Discussion

Laparoscopic radical cystectomy with extracorporeal neobladder reconstruction is the viable option, since it provides the benefit of both minimally invasive option, less time consuming and no extra morbidity (Incision used for specimen retrieval).

Conclusion

Laparoscopic radical cystectomy with extracorporeal neobladder reconstruction is an effective and feasible option in patients with muscle invasive bladder cancer fit for neobladder reconstruction.

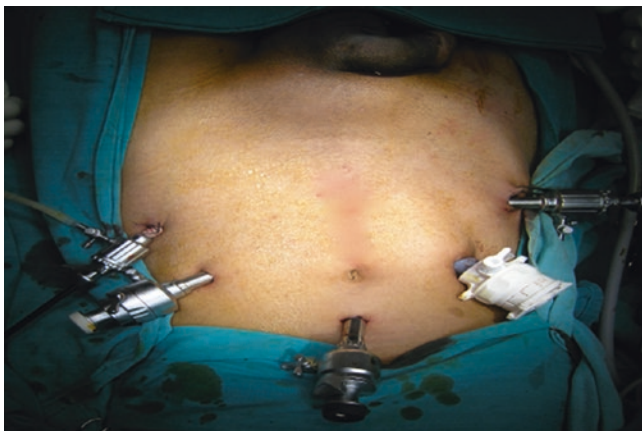

Fig. 50.1 Ports position

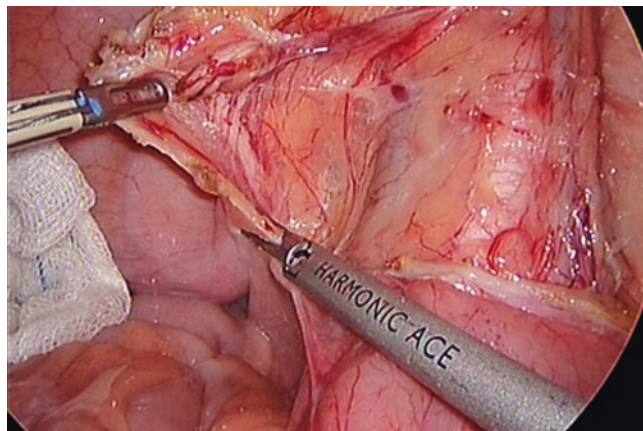


Fig. 50.2 Right iliac fossa peritoneum dissected and ureter identified

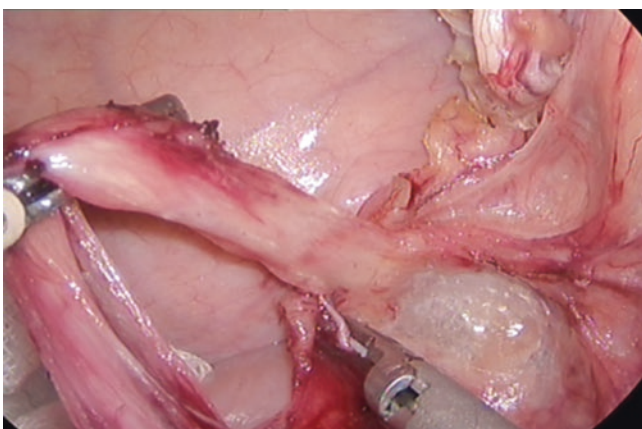


Fig. 50.3 Right ureter being dissected

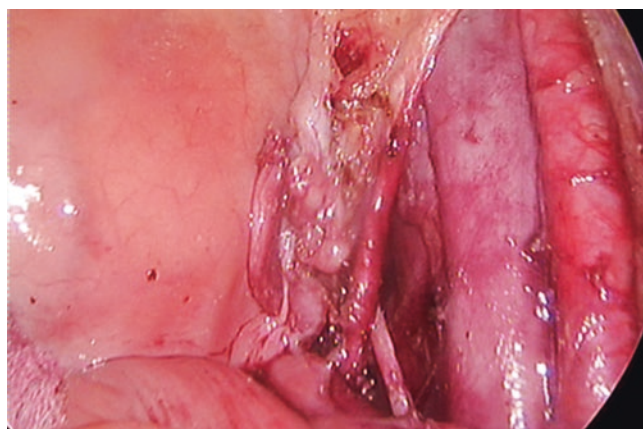


Fig. 50.4 Right iliac lymphadenectomy completed

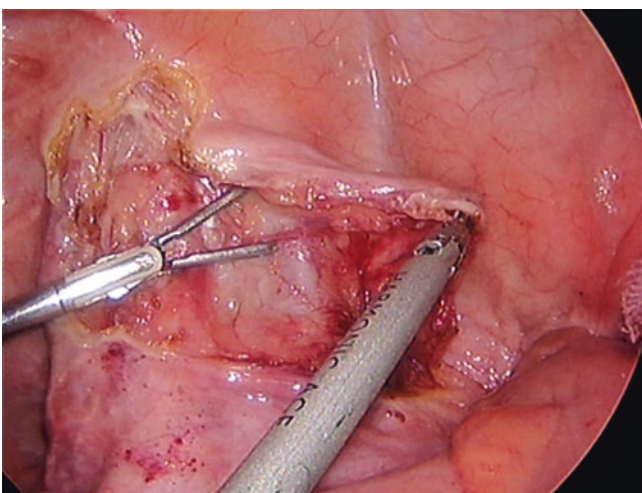


Fig. 50.5 Left iliac lymphadenectomy started

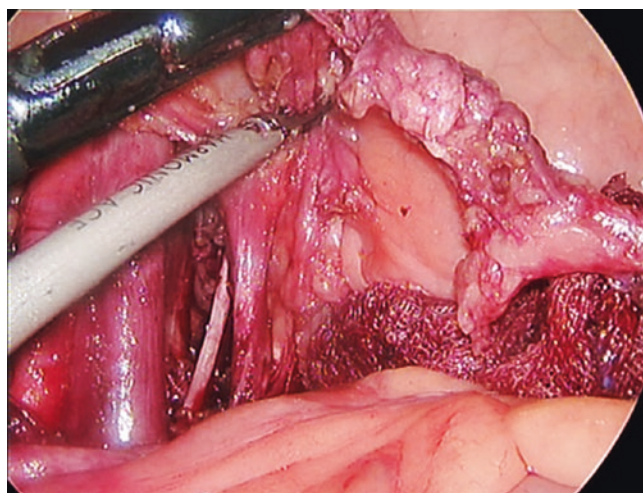


Fig. 50.6 Left iliac lymphadenectomy completed

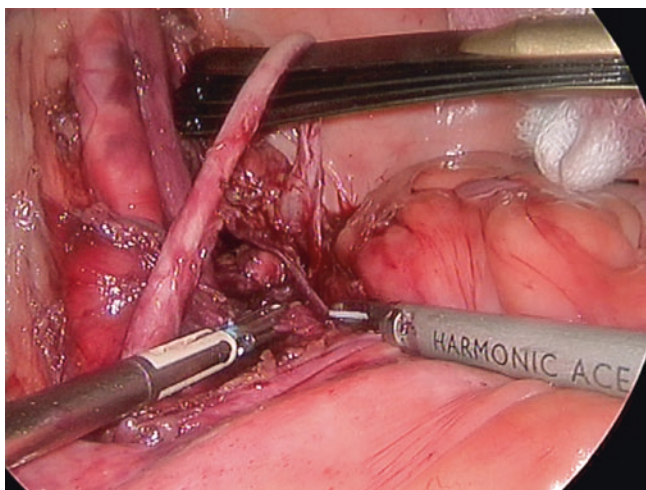


Fig. 50.7 Left ureter dissected

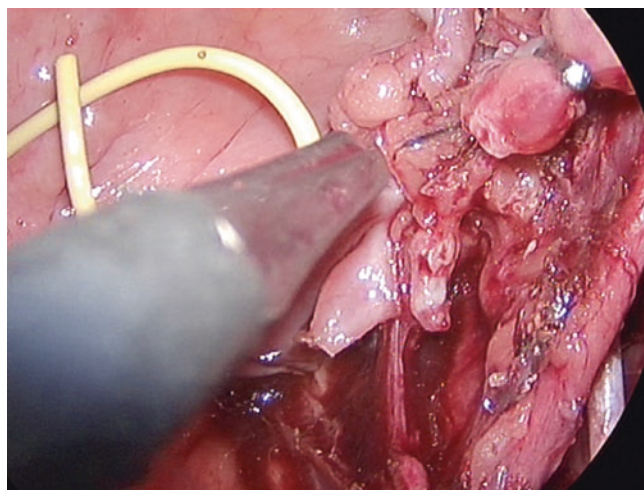


Fig. 50.8 Right ureter divided

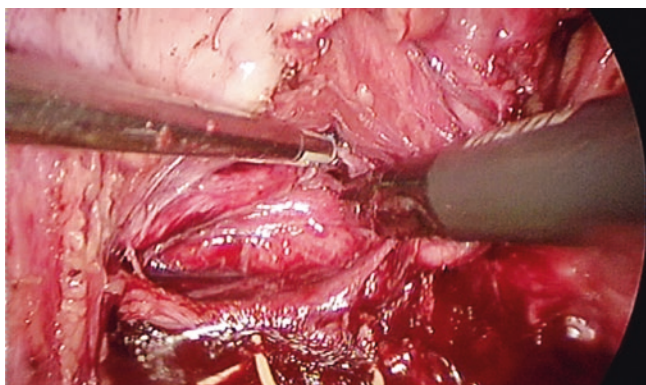


Fig. 50.9 Bladder mobilized posteriorly

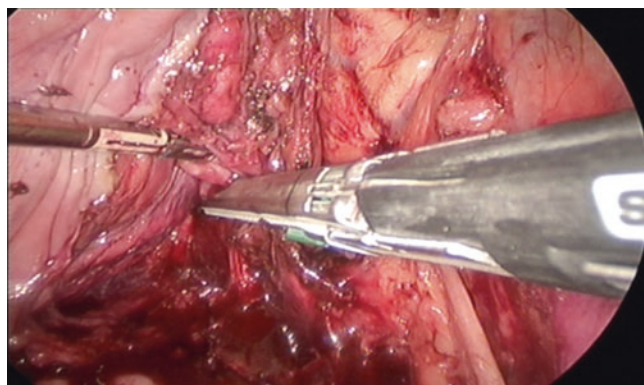


Fig. 50.10 Right lateral pedicle being controlled with stapler

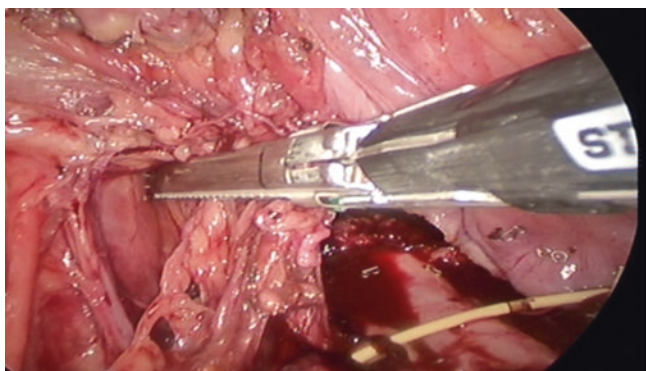


Fig. 50.11 Left lateral pedicle being controlled with stapler

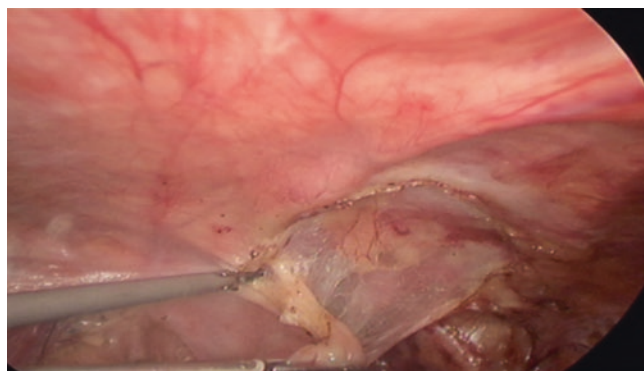


Fig. 50.12 Bladder being dropped down

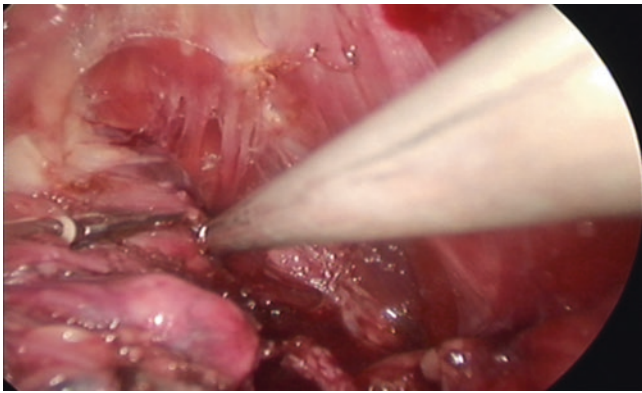


Fig. 50.13 Right lateral prostatic dissection

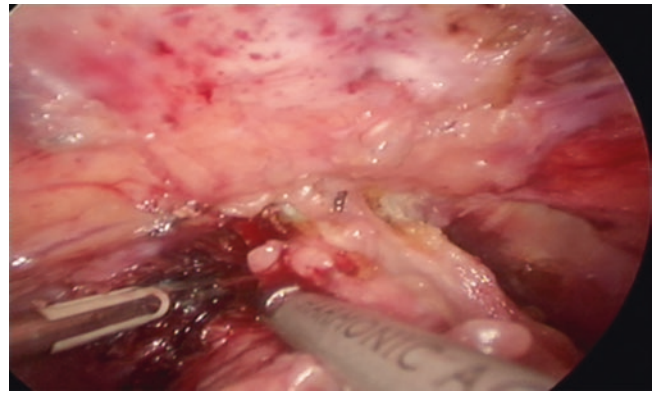


Fig. 50.14 Left lateral prostatic dissection

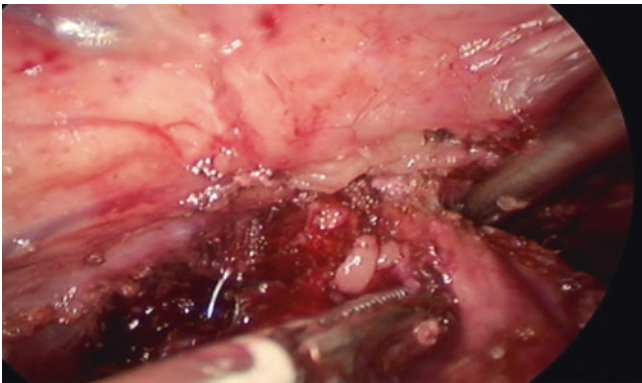


Fig. 50.15 Dorsal venous complex suture in progress

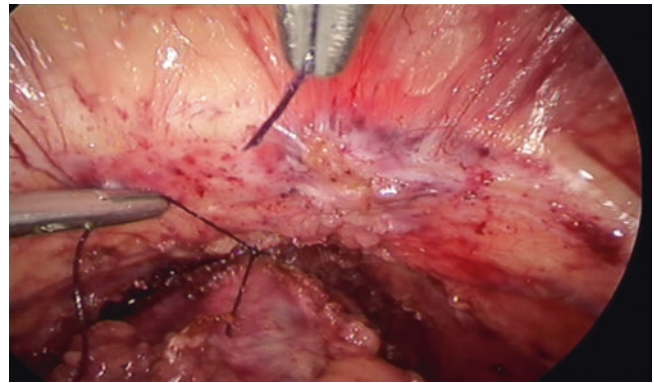


Fig. 50.16 Dorsal venous complex suture complete

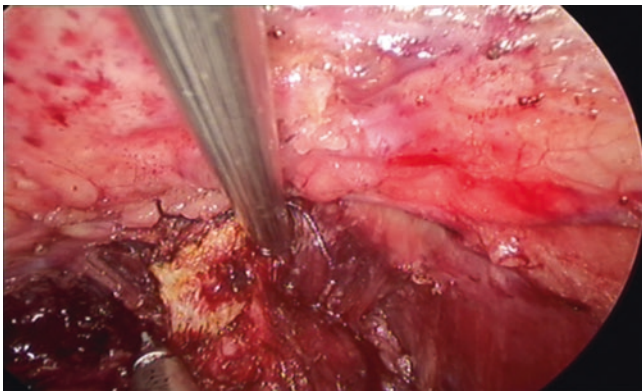


Fig. 50.17 Prostatic apical dissection

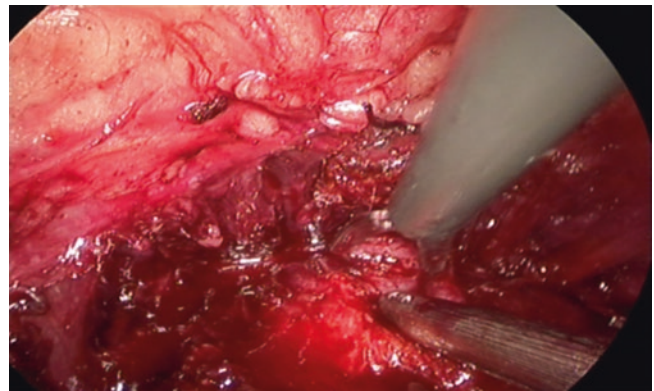


Fig. 50.18 Urethral being divided

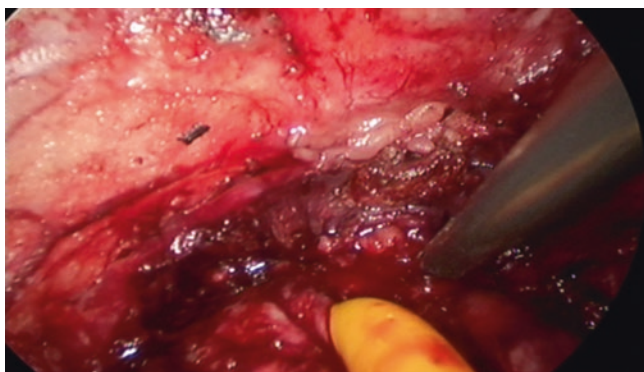


Fig. 50.19 Urethral division complete

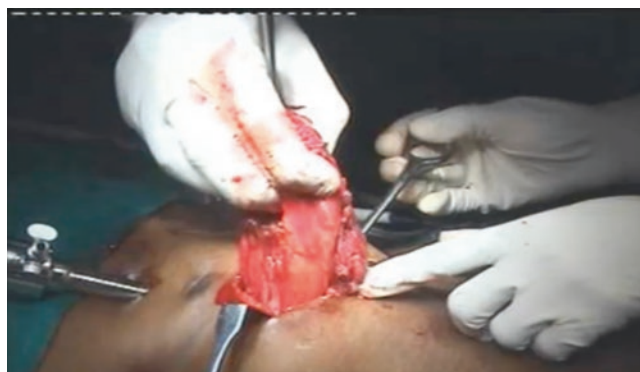

Fig. 50.20 Specimen being retrieved by 6 cm incision over the subumbilical area

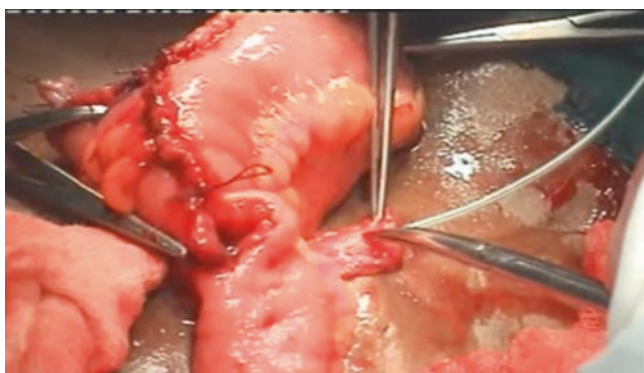


Fig. 50.21 Neobladder reconstructed and ureteric reimplantation started

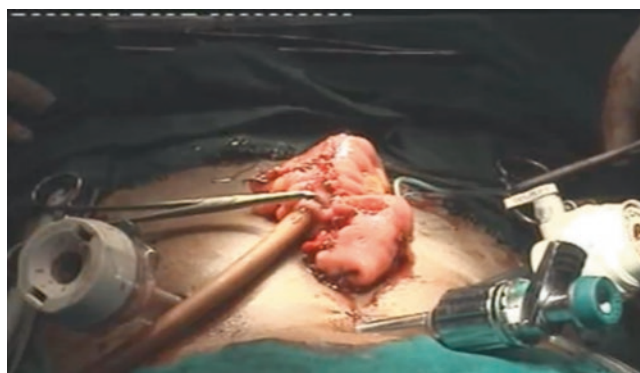


Fig. 50.22 SPC placed and neobladder ready to be pushed into abdomen

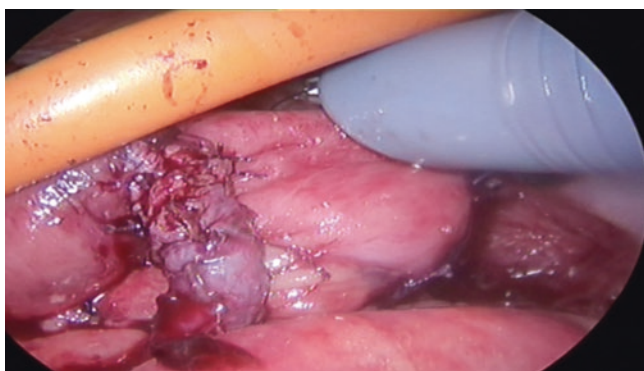


Fig. 50.23 Neobladder seen within abdomen after closing the rectus

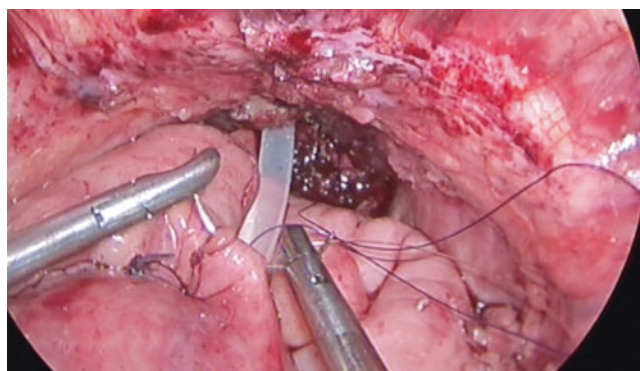


Fig. 50.24 Urethrovesical anastomosis started with 3-0 monocryl suture at 6 o'clock position of neobladder

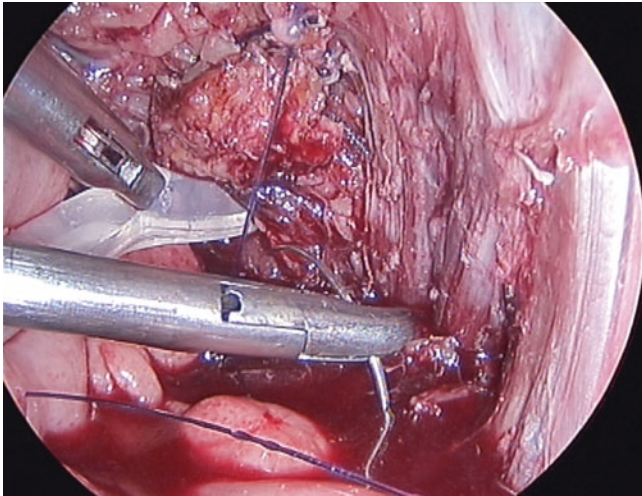


Fig. 50.25 Corresponding suture through urethra at 6 o clock position

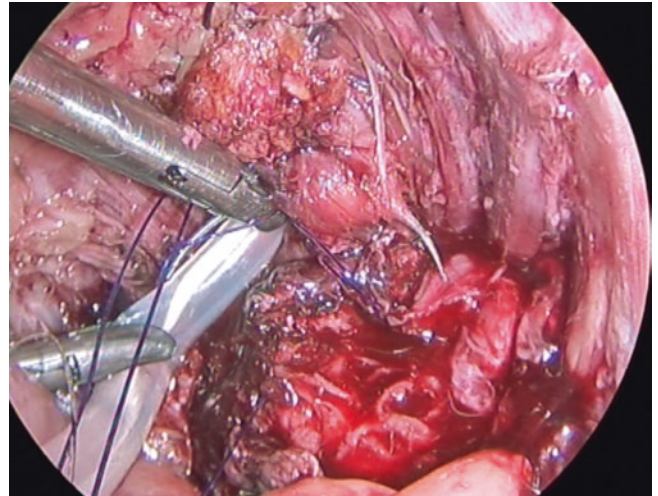


Fig. 50.26 Urethro vesical anastomosis in progress (von Velthoven technique)

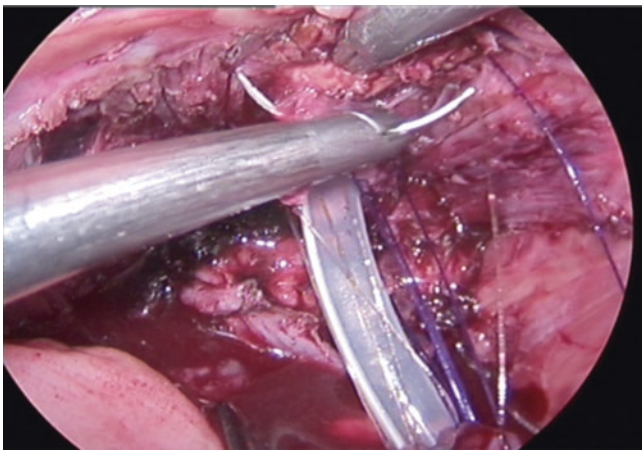


Fig. 50.27 Urethrovesical anastomosis in progress

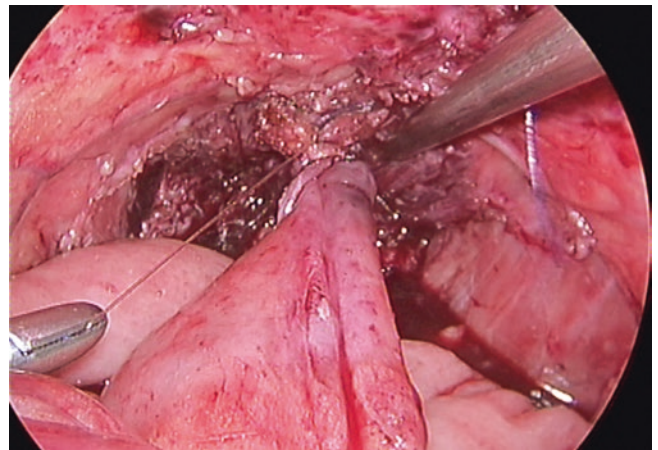


Fig. 50.28 Urethrovesical anastomosis complete

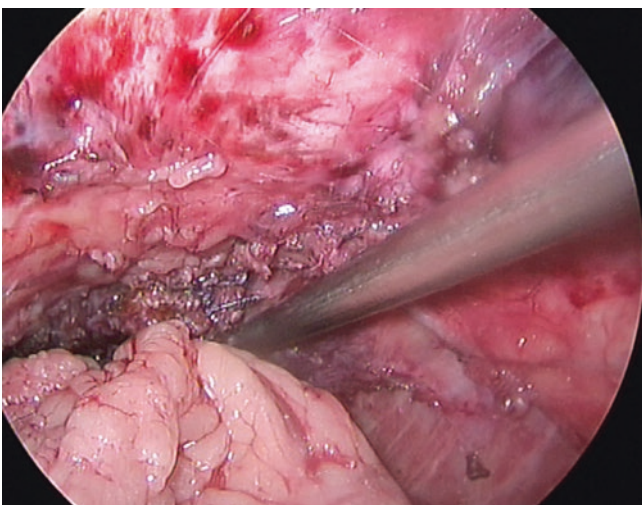


Fig. 50.29 Completed neobladder. Omental wrap done

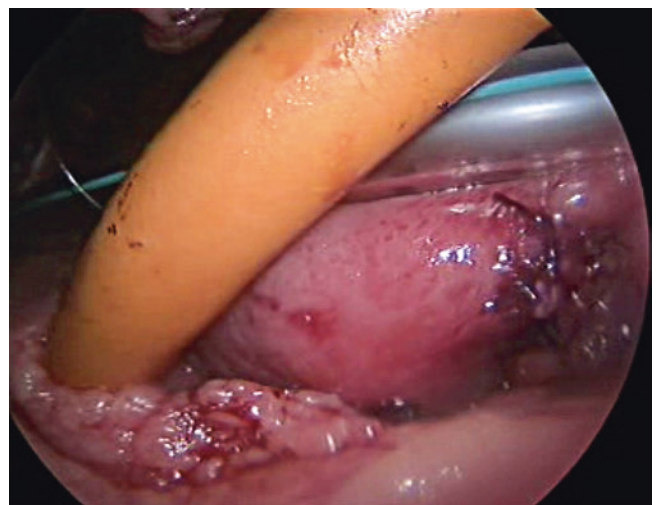


Fig. 50.30 Drain placed over the neobladder

References

1. Hemal AK, Kolla SB, Wadhwa P, Dogra PN, Gupta NP. Laparoscopic radical cystectomy and extracorporeal urinary diversion: a single center experience of 48 cases with three years of follow-up. *Urology*. 2008;71(1):41–6.
2. Cathelineau X, Jaffe J. Laparoscopic radical cystectomy with urinary diversion: what is the optimal technique? *Curr Opin Urol*. 2007;17(2):93–7.

Robotic Assisted Intracorporeal Neobladder Reconstruction: Surgical Technique

51

Murugesan Manoharan, Ahmed Saeed Goolam,
Nikhil Vasdev, and Peter Wiklund

51.1 Introduction

The use of Minimally Invasive Surgery (MIS) and in particular robotic assisted approaches for urologic oncology has gained popularity over the last decade. Recent data has indicated that the vast majority of radical prostatectomy cases are performed robotically. Over the last few years, there has been an increase in robotic assisted radical cystectomy (RARC).

With the popularity of robotic assisted radical prostatectomy, RARC has become commonplace. Performing the neobladder in an open fashion following robotic cystectomy is thought to diminish some of the advantages of MIS. As such, there has been a trend to performing the urinary diversion in an intra-corporeal manner.

In this chapter, we describe the surgical technique for creating a neobladder using a robotic approach.

51.2 Pre-operative Preparation

We do not use pre-operative bowel preparation. Patients are instructed to maintain a low residue diet for 48 h and clear fluids for 24 h preceding the procedure. At the induction of anesthesia, IV Cephazolin and Gentamicin is administered for antibiotic prophylaxis. A 16-Fr nasogastric tube (NGT) is placed following intubation, which is to remain in place

post-operatively. The patient is placed in a low lithotomy position with the arms adducted and padded. Pneumatic sequential calf compression devices are attached to the patient. The patient is secured to the operating table using the TrendGuard™ (D.A. Surgical, Chagrin Falls, OH) positioning system.

Once the operative field has been prepared and drapes applied, an 18-Fr Foley urinary catheter is placed.

51.3 Surgical Technique

51.3.1 Trocar Placement

For RARC, extended pelvic lymph node dissection (ePLND) and intracorporeal neobladder, appropriate port placement is crucial to the success of the procedure. We utilize six ports (four robotic and two assistant ports) for this procedure. The camera port is placed 4–5 cm above the umbilicus in the midline to improve vision for the ePLND and neobladder formation. Two further robotic ports are placed in line with the umbilicus but on either side along the lateral edge of the rectus muscle (approximately 8–10 cm from the midline). The remaining robotic arm is a 15 mm hybrid robotic port and placed approximately 2 cm above and medial to the left anterior superior iliac spine (ASIS). The two assistant ports are placed in the patients right lower and upper quadrant. A 12 mm Airseal® port (SurgiQuest, Milford, CT) used for the right lower lateral most assistant port.

Tip

We have found that an alternate port arrangement whereby the assistant is on the patient's left side has some advantages. The surgeon has the third arm on the patient's right side, which allows for grasping forceps being assigned in both left and right hands improving bowel manipulation. It also allows for the third arm to remain in place whilst the assistant utilizes a left lateral dedicated assistant port to insert the Laparoscopic

M. Manoharan (✉)
Miami Cancer Institute, Baptist Health South Florida,
Miami, FL, USA
e-mail: mmanoharan@baptisthealth.net

A.S. Goolam
Hornsby Hospital, Hornsby, NSW, Australia

N. Vasdev
Department of Urology, Lister Hospital, Stevenage, UK

P. Wiklund
Department of Urology, Karolinska University Hospital,
Stockholm, Sweden

endoscopic GIA stapler rather than removing the robotic arm to accomplish this in the aforementioned setup.

51.3.2 Preparing for Neobladder Creation Post Cystectomy

51.3.2.1 Re-positioning of the Patient

The operating table is placed in a 30° Trendelenburg position for the cystectomy and lymphadenectomy portions of the procedure. Following this, the robot is un-docked and the operating table placed in 10–12° of Trendelenburg positioning. The robot is once again docked. This positioning assists in bringing the desired bowel segments down into the pelvis.

The reconstruction is carried out in the following sequence

1. Isolation of bowel segment
2. Urethro-ileal anastomosis
3. Restoring bowel continuity
4. Detubularization of isolated bowel segment for neobladder creation
5. Closure of the posterior wall and part of the anterior wall
6. Uretero-ileal anastomosis and placement of ureteric stents
7. Closure of the remaining anterior wall

Step 1. Isolation of the Bowel Segment

The Studer neobladder lends itself to the robotic approach with relatively few suture lines and fewer steps in its creation. However, the suture lines are long and care is needed to ensure that the sutures remain tensioned to maintain a watertight reservoir. Approximately 55 cm of terminal ileum is used for the neobladder creation.

The terminal portion of the ileum is inspected identifying a mobile segment approximately 30 cm from the ileocecal junction. This will be the point of the urethral anastomosis. Ensuring that the bowel and mesentery come down to the pelvis in a tension free manner prior to bowel resection is important for a successful urethro-ileal anastomosis. Measuring 15 cm distal to this point marks the distal end of the bowel segment required for neobladder construction. Using an Endo-GIA stapler, the ileum is stapled and divided at this point ensuring that the stapler is placed perpendicular to the bowel. A single application of a 60 mm long stapler is generally sufficient. A second point 40 cm proximal to the anastomotic site marks the proximal end. The Endo-GIA stapler is once again applied at this point dividing the bowel and allowing for a 55 cm segment to be isolated.

Tip

During isolation of the bowel segment, care needs to be taken to apply the stapler perpendicular to the direction of the bowel. Using a 60 mm long stapler provides enough

length to traverse the bowel and mobilize sufficient length of mesentery for neobladder creation. Using a longer stapler or applying the stapler a second time on the mesentery may compromise the vascularity of isolated bowel segment.

Although not entirely applicable to this chapter, it is worth noting that during isolation of shorter bowel segments (e.g. for intracorporeal ileal conduit formation), there is a greater risk of creating a very narrow pedicle of mesentery and compromising vascularity if the stapler is either too long or not placed perpendicularly to the bowel.

Step 2. Urethro-ileal Anastomosis

Using the Cadiere robotic forceps, the distal limb of the isolated bowel segment and mesentery are gently moved into the pelvis allowing this point to be brought to the urethra. A point approximately 15 cm from the distal end of the isolated segment is chosen. This point will be used to anastomose the neobladder to the urethra. The third arm is used to hold the bowel and mesentery down in place. Using a V-Loc (Covidien/Medtronic, Minneapolis, MN), 3-0 barbed suture, a Rocco stitch is placed ensuring that the remaining layer of Denonvillier's fascia along with peritoneum is sutured to the bowel at the proposed point of anastomosis. It is important to ensure that the excess suture length is not pulled through until 3 or 4 passes have been made with the needle. Using a parachuting technique and sequentially tightening each suture results in the tension being distributed along a broader length of bowel segment preventing tearing of the bowel.

Once the Rocco stitch has been completed, an opening is created in the ileum just above the Rocco layer. This is performed using "cold" scissors to create an anti-mesenteric opening approximately 20Fr in caliber. The urethro-ileal anastomosis is performed using two 16 cm interlocked 2-0 V-Loc sutures. We aim to place approximately ten sutures in a continuous manner following the van Velthoven technique. A 20-Fr two-way catheter is placed into the neobladder and 15 ml of fluid placed into the balloon on completion of the anastomosis.

Step 3. Restoring Bowel Continuity

The small bowel continuity is restored in a side-to-side manner. The neobladder bowel segment must be left caudal and underneath the planned bowel anastomosis. Along the anti-mesenteric borders of each bowel limb, an opening is created using cautery or cold scissors. The 60 mm Endo-GIA stapler is inserted into the bowel lumen ensuring that both anti-mesenteric borders are aligned. A further 60 mm Endo-GIA stapler reload is applied perpendicular to the lumen of the newly anastomosed bowel ends to seal them.

We routinely close the mesenteric defect with a continuous 3-0 silk suture as well as placing a future suture at the "crotch" of the two limbs of the bowel anastomosis.

Tip

We have found that in the learning phase of this procedure, placement of a simple stitch approximately 2 and 5 cm from the stapled end approximates and aligns both bowel segments and facilitates passage of the stapler. This step can be omitted with surgical experience.

Step 4. Detubularization of the Isolated Bowel Segment**Segment**

The proximal 15 cm of the isolated bowel segment is reserved for the chimney and insertion of the ureters. This maintains isoperistalsis and propagation of urine into the reservoir. The distal 40 cm of bowel is detubularized along the anti-mesenteric border with cold scissors.

Step 5. Closure of the Posterior Wall and Part of the Anterior Wall

Once this is completed, the posterior wall of the Studer neobladder is formed by using continuous 3-0 V-Loc sutures. The sutures are seromuscular in depth avoiding incorporating the mucosa in the suture line. The anterior wall of the neobladder commences at the apex working proximally with continuous 3-0 V-Loc® sutures. The anterior wall is not closed completely, stopping approximately half way to allow passage of the ureteric stents and completion of the uretero-ileal anastomosis. The final part of the anterior wall is closed last.

Tip

Performing the urethro-ileal anastomosis first assists with the formation of the neobladder by fixing the bowel segment in the pelvis. Using a barbed suture such as V-Loc® or Quill™ (Surgical Specialties Corporation™, Wyomissing, PA) assists in maintaining the tension along the suture line improving efficiency and maintaining a water-tight closure.

Step 6. Uretero-ileal Anastomosis and Ureteric Stent Placement

When performing the mobilization of the ureters, it is useful to tie a 6 cm piece of suture material to the Hem-o-lok® clip (Teleflex®, Morrisville, NC) which is used to clip the ureter prior to its transection. The uretero-ileal anastomosis is performed using a Wallace technique. Both left and right ureters are suspended by the suture material attached to the Hem-o-lok® clips on each ureter. These are held up by the 4th robotic arm. The ureters are spatulated for approximately 2 cm using cold scissors ensuring that the edge of both ureters are clearly seen. The posterior wall of both ureters are then sutured together in a side-to-side manner using a 4-0 absorbable suture (e.g. Biosyn™- Medtronic, Minneapolis, MN) measuring 15 cm in length. Once this is complete, two Single-J ureteric stents are passed through two separate 4 mm incision in the abdominal wall into the peritoneal

cavity. The stents are placed over guidewires and are fed up the afferent limb (chimney) of the neobladder using Cadere forceps. They are then passed individually up both ureters ensuring the proximal end of the stents are within the renal pelvis. The ureters are then sutured to end of the afferent limb of the neobladder using two separate 16 cm barbed sutures (V-Loc®, Quill™) in a continuous manner.

Tip

The ureteric stents may be passed via the assistant port and guided up the afferent (chimney) limb of the neobladder and then up both ureters using Cadere forceps by the surgeon. The tail end of the stents can be placed into the neobladder in the interim whilst the uretero-ileal anastomosis is being complete. Once this is completed, the stents may be carefully removed from the neobladder prior to completing the anterior wall suture line. The stents are then retrieved via the right paramedian robotic port site by undocking this arm prior to the entire robot being undocked.

Step 7. Closure of the Anterior Wall

Once this is completed, the remaining anterior wall of the neobladder is closed with running 3-0 V-Lok® sutures. The neobladder is filled with 50–100 ml of saline to test for leaks. Extra sutures (3-0 Vicryl) may be required to ensure a water-tight anastomosis. This is important in reducing post-operative complications.

A 19-Fr pelvic drain is placed into the pelvis and is not placed on suction. We do not place a suprapubic catheter.

51.4 Post-operative Care and Management of Drainage Catheters

The neobladder is irrigated by a member of the urology team twice a day for the duration of the hospital admission. The ureteric catheters are carefully inspected daily and flushed with 10mls of saline daily.

The drain remains in situ for 48 h to ensure no leak is present. It is important to avoid suction on the drain if possible in an effort to reduce the likelihood of leak.

The Foley and ureteric stents are left in place on discharge. The ureteric stents are removed 2 weeks post-operatively. The Foley catheter is removed a week later (Figs. [51.1](#), [51.2](#), [51.3](#), [51.4](#), [51.5](#), [51.6](#), [51.7](#), [51.8](#), [51.9](#), [51.10](#), [51.11](#), [51.12](#), [51.13](#), [51.14](#), [51.15](#), [51.16](#), [51.17](#), [51.18](#), [51.19](#), [51.20](#), [51.21](#), [51.22](#), [51.23](#), [51.24](#), [51.25](#), [51.26](#), [51.27](#), [51.28](#), [51.29](#), [51.30](#), [51.31](#), [51.32](#), [51.33](#), [51.34](#), [51.35](#), [51.36](#), [51.37](#), [51.38](#), [51.39](#), [51.40](#), [51.41](#), [51.42](#), [51.43](#), [51.44](#), [51.45](#), [51.46](#), [51.47](#), [51.48](#), [51.49](#), [51.50](#), [51.51](#), [51.52](#), and [51.53](#)).

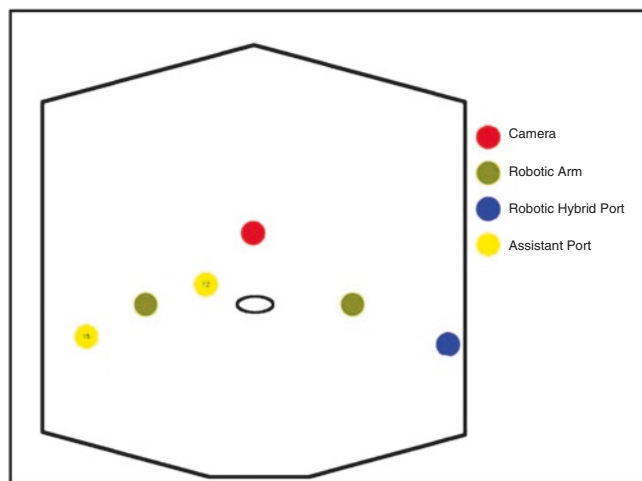


Fig. 51.1 Standard port placement

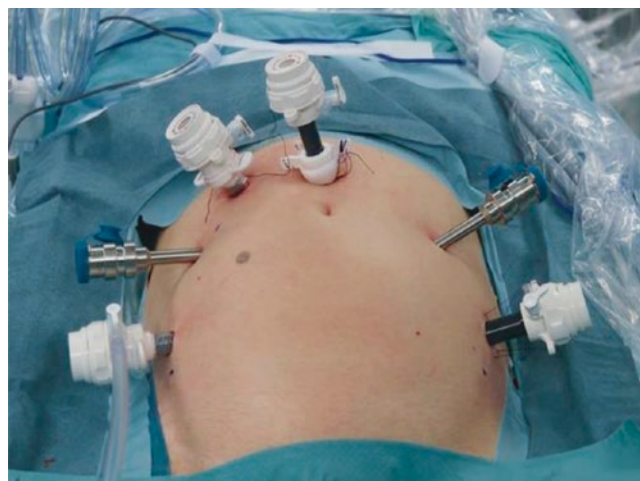

Fig. 51.2 Standard port placement

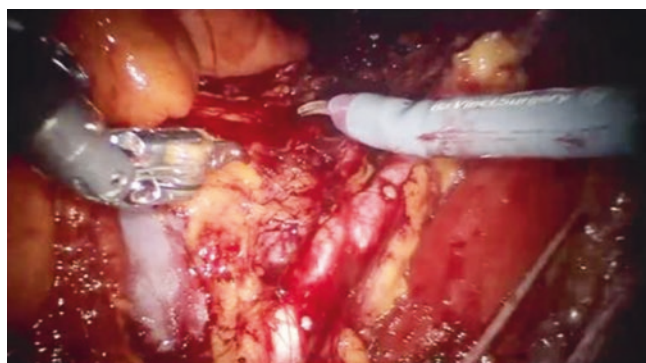

Fig. 51.3 Dissection at the level of aortic bifurcation facilitating tunneling of left ureter

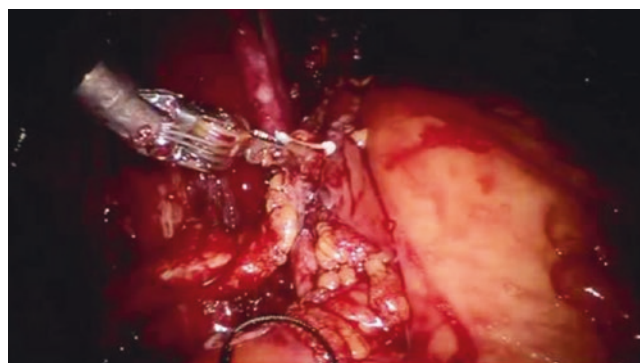


Fig. 51.4 Left ureter prepared for tunneling beneath the sigmoid

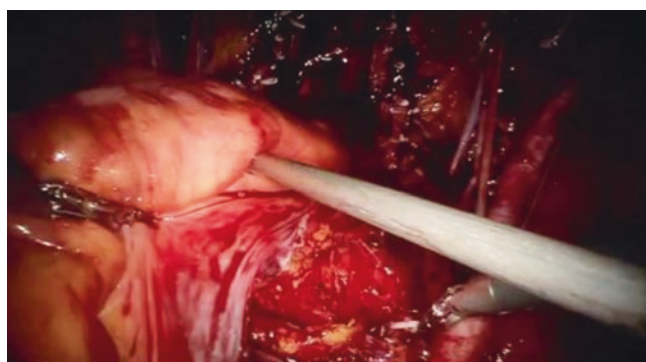


Fig. 51.5 Left ureter tunneled beneath the sigmoid

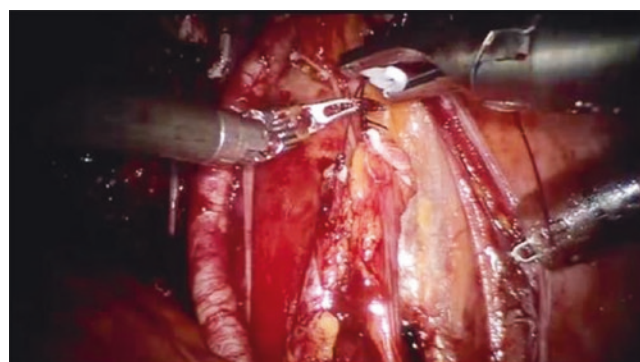


Fig. 51.6 Right ureter mobilized and both ureters tacked to the anterior abdominal wall

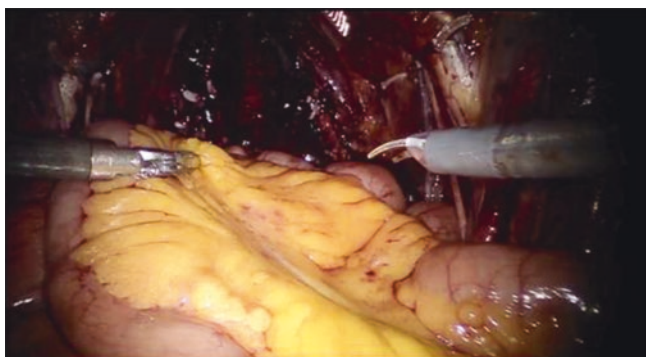


Fig. 51.7 Ileal loop moving to the pelvis without tension, with a long mesentery, minimum 30 cm from ileocecal junction was selected

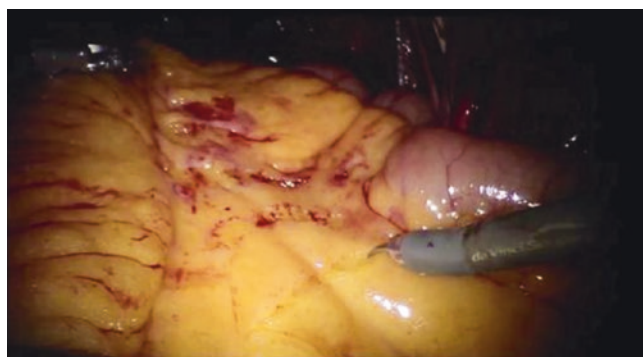


Fig. 51.8 Multiple transverse release incisions made in the mesentery to facilitate mobilisation of the bowel segment to pelvis

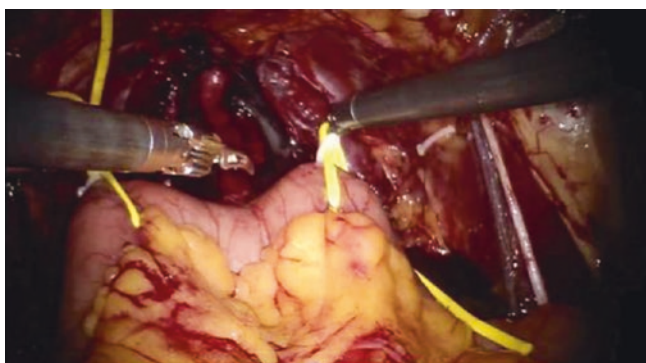


Fig. 51.9 Vessel loop passed through the mesentery at the ends of the bowel loop segment selected for urethral anastomosis

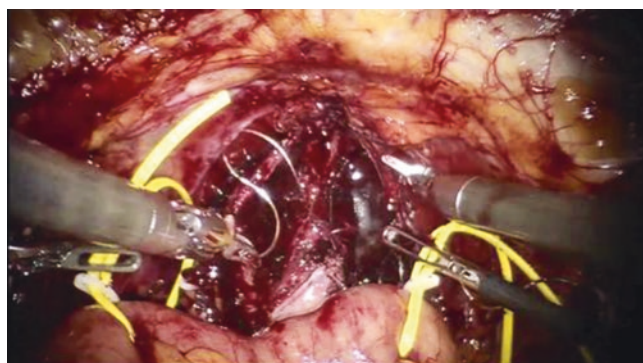


Fig. 51.10 Initial part of posterior reconstruction performed by suturing the cut end of Denonvillier's fascia to the peritoneum with 3-0 quilted sutures

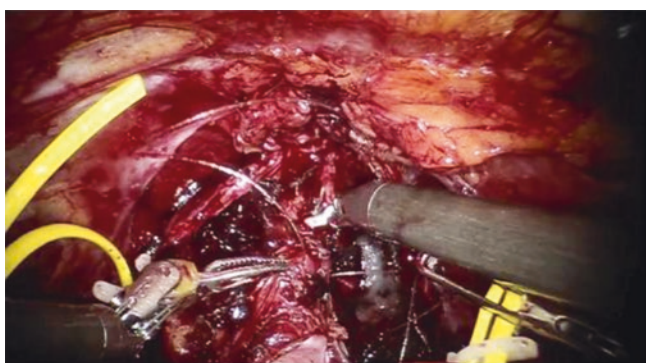


Fig. 51.11 Posterior plate reconstruction in progress

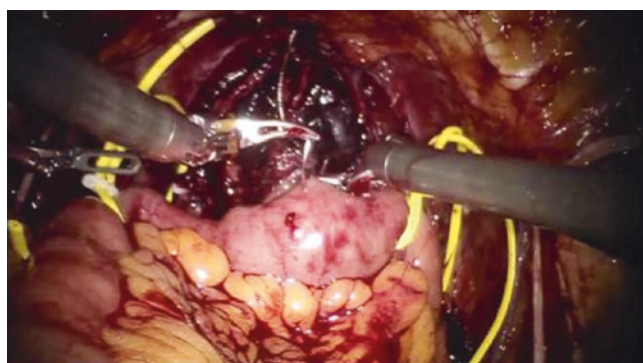


Fig. 51.12 Posterior plate sutures continued from the Denonvillier's fascia to the antimesenteric border of selected ileal loop

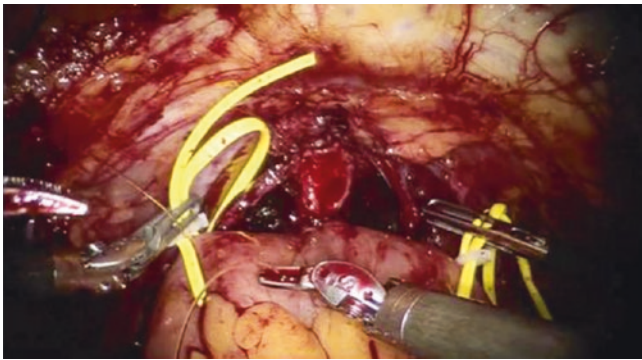


Fig. 51.13 Posterior plate reconstruction completed

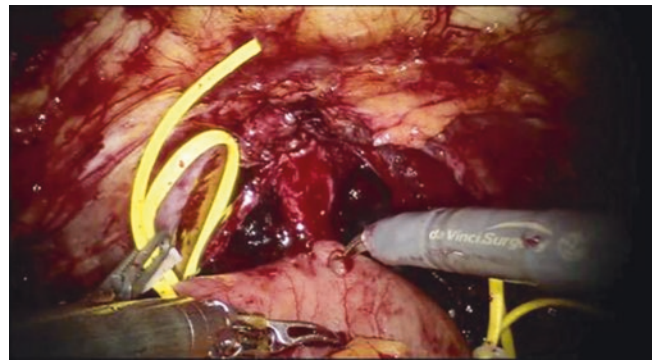


Fig. 51.14 Ileum opened for urethral anastomosis

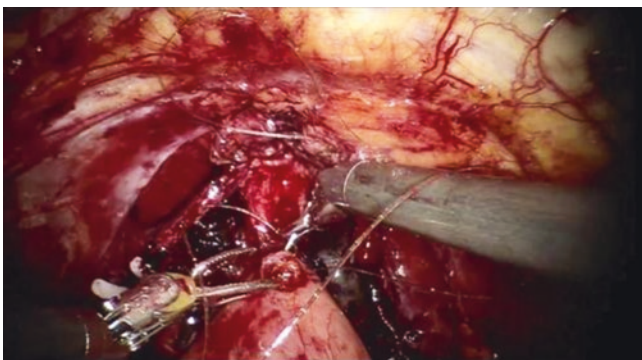


Fig. 51.15 Urethro vesical anastomosis started with 3-0 barbed suture

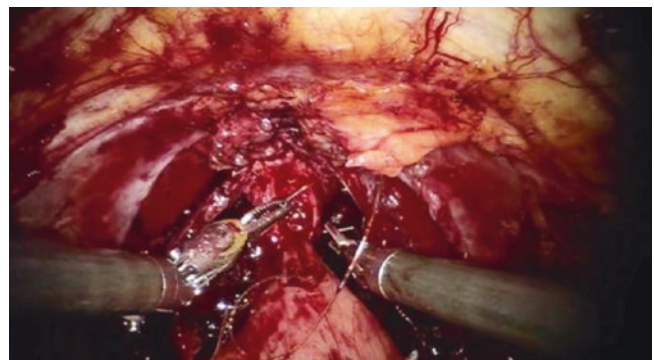


Fig. 51.16 Corresponding suture through urethra

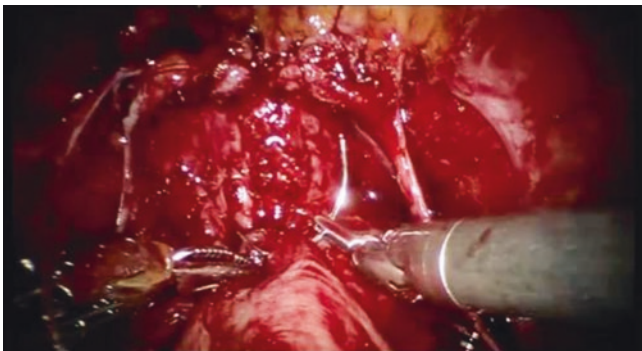


Fig. 51.17 Urethro vesical anastomosis in continuous manner

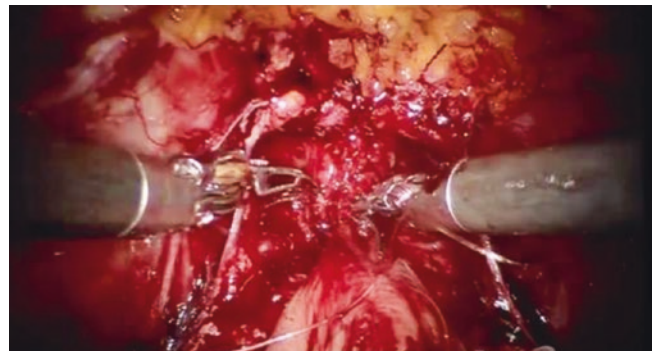


Fig. 51.18 Urethrovesical anastomosis in progress

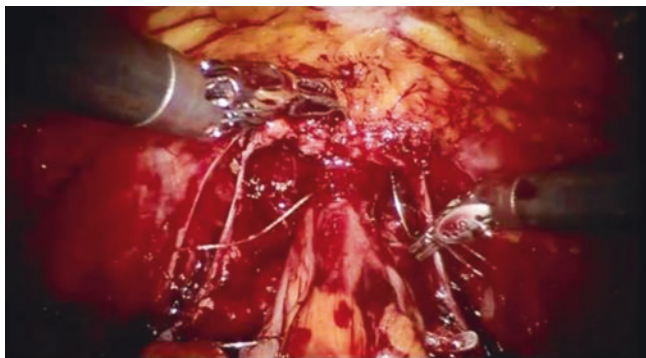


Fig. 51.19 Urethro vesical anastomosis completed

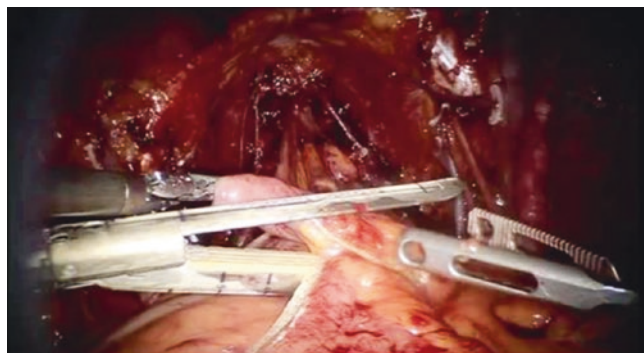


Fig. 51.20 Stapled bowel isolation on the right side 15 cm away from the urethral anastomosis

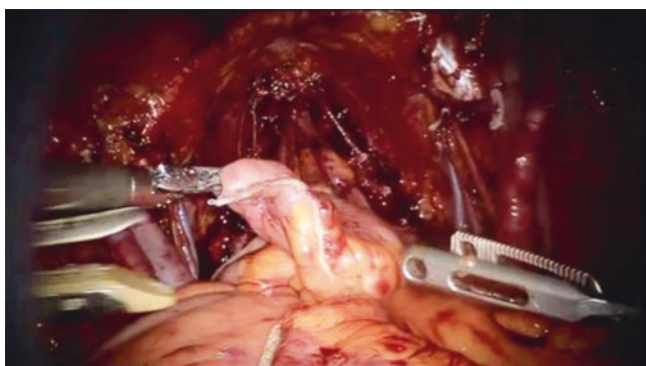


Fig. 51.21 Stapled bowel isolation 40 cm from the urethral anastomosis on the left side

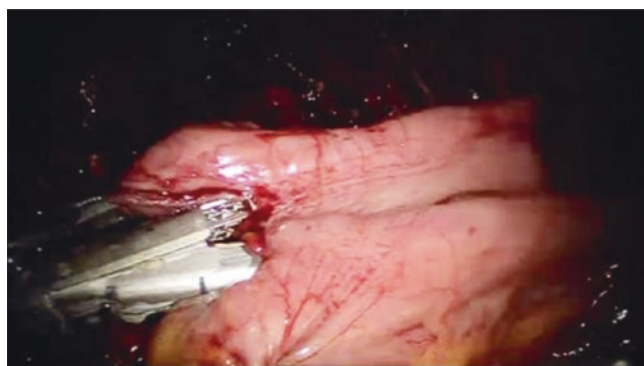

Fig. 51.22 Stapled bowel anastomosis to restore ileal continuity

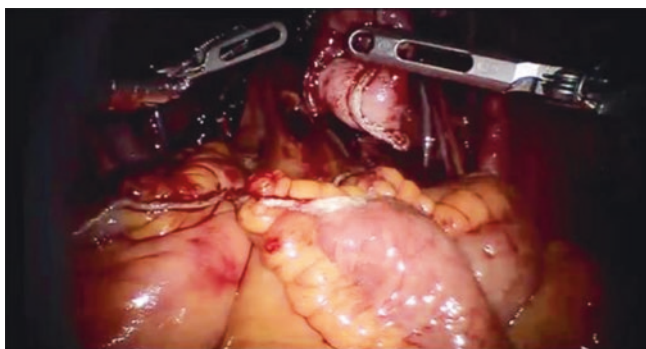


Fig. 51.23 Completed bowel anastomosis

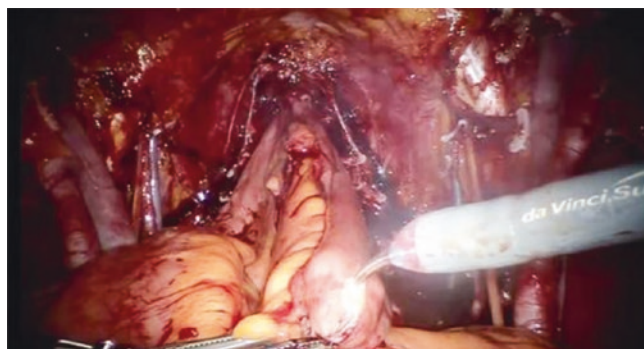


Fig. 51.24 Isolated ileal segment detubularisation started

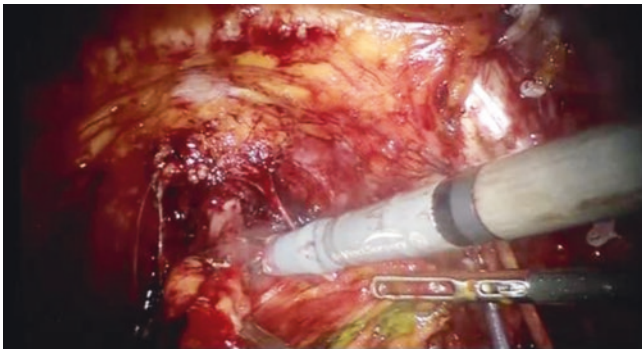


Fig. 51.25 Ileal loop detubularisation in progress

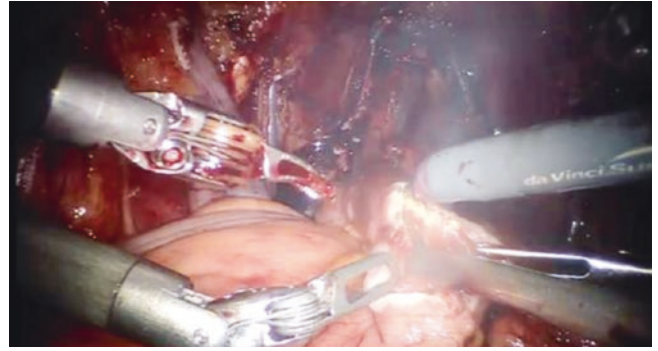


Fig. 51.26 Ileal loop detubularisation in progress

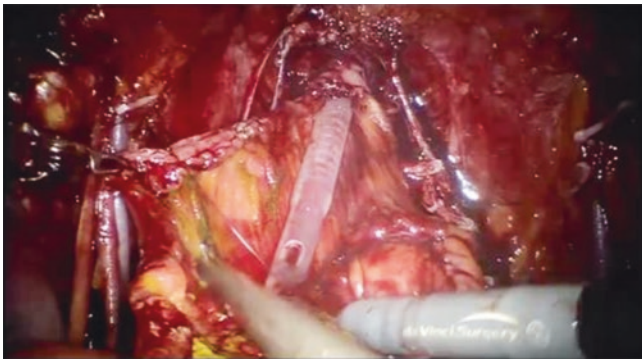


Fig. 51.27 Completed detubularisation

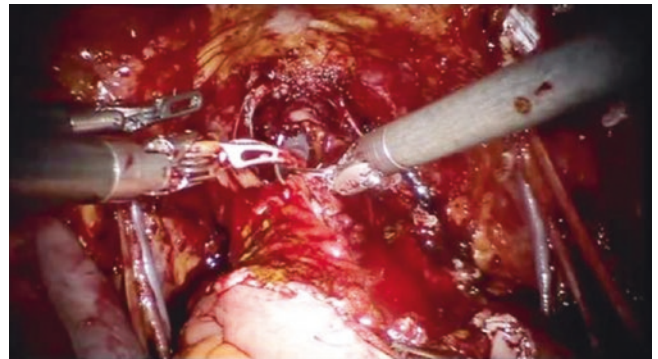


Fig. 51.28 Stay sutures approximating the detubularised segments to create the posterior layer of neobladder

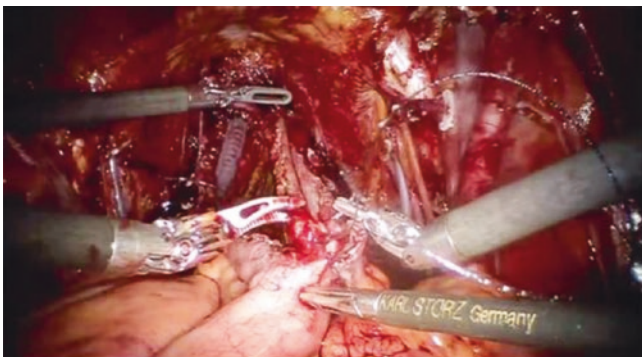


Fig. 51.29 Posterior layer closure as continuous suture with 3-0 vlok suture

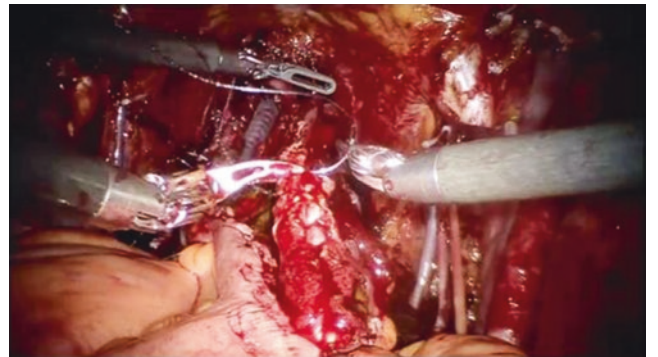


Fig. 51.30 Posterior layer closure in progress

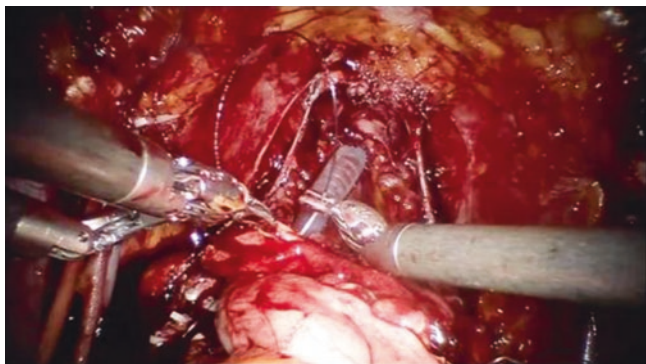


Fig. 51.31 Posterior layer closure in progress

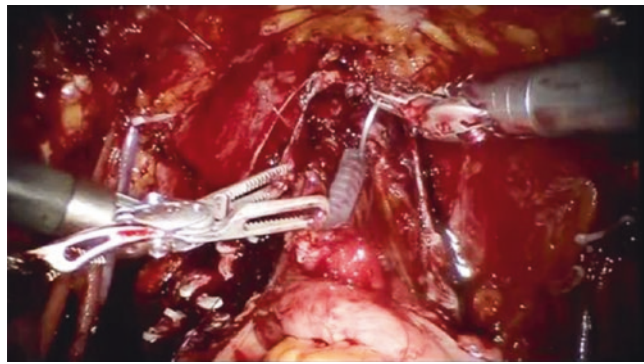


Fig. 51.32 Posterior layer closure completed

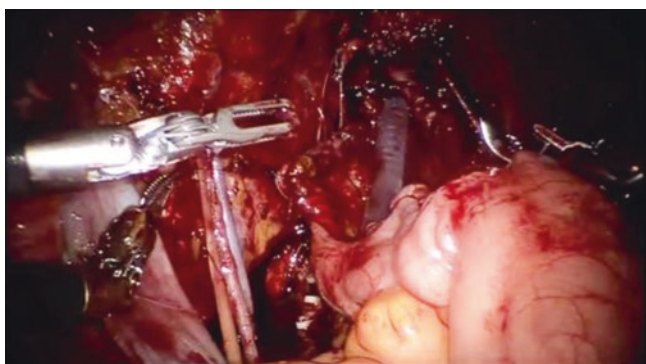


Fig. 51.33 Closure of the anterior layer of neobladder started with initial bite through the middle of the segment with 3-0 vlok suture

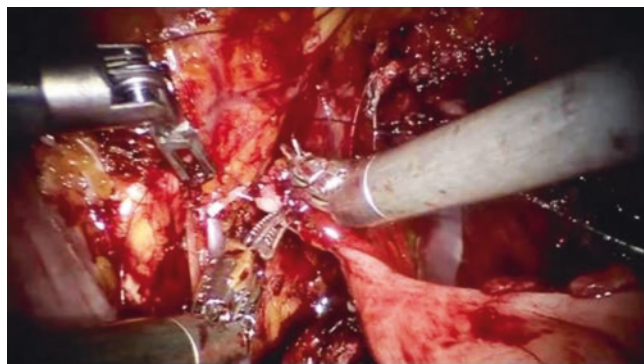


Fig. 51.34 Corresponding suture through the lateral margin so as to form a wider upper part of neobladder

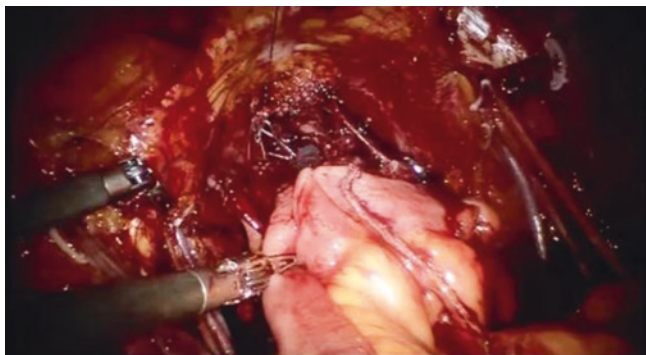


Fig. 51.35 First anterior layer suture in place

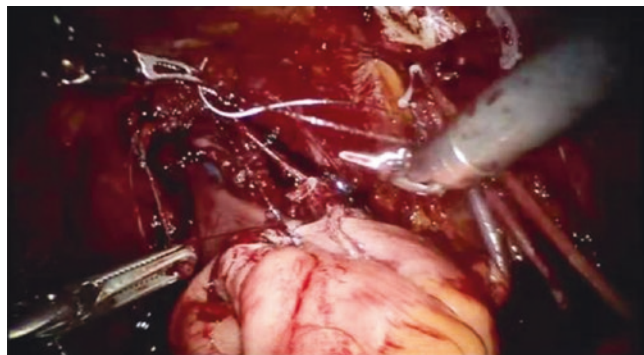


Fig. 51.36 Anterior layer reconstruction in progress

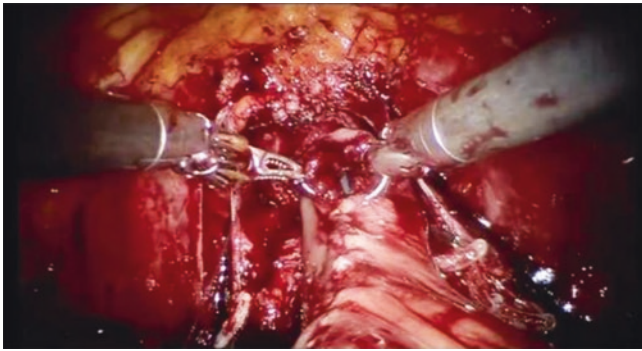


Fig. 51.37 Anterior layer reconstruction in progress

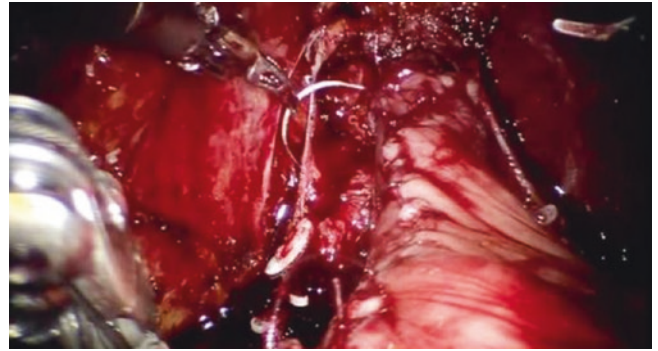


Fig. 51.38 Anterior layer completed distally

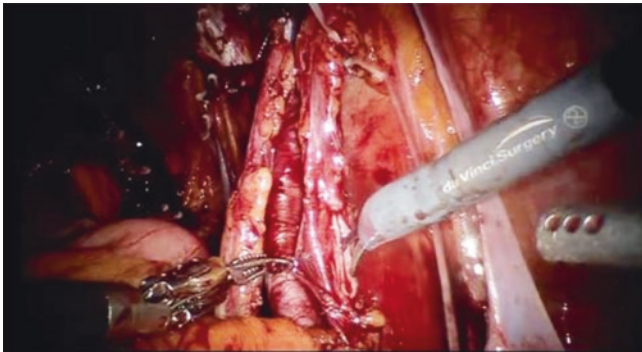


Fig. 51.39 Spatulation of right ureter

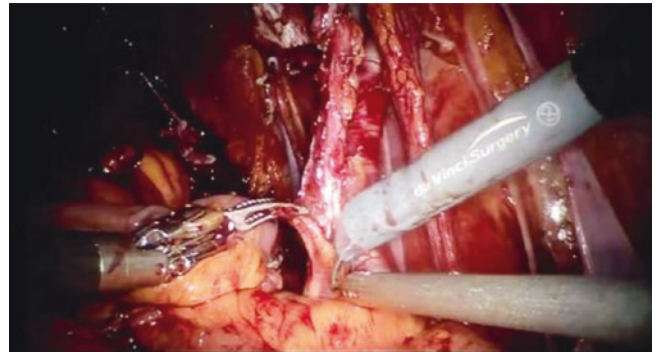


Fig. 51.40 Spatulation of left ureter

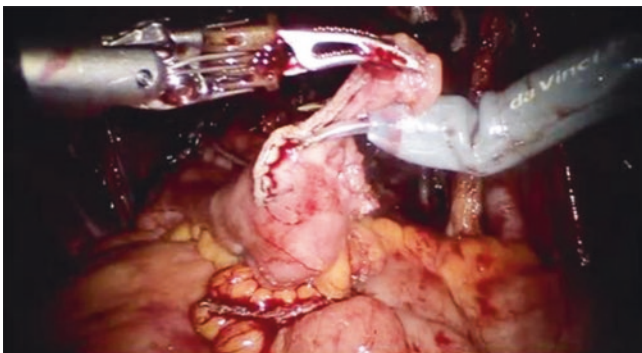


Fig. 51.41 Stapled end of ileal loop excised

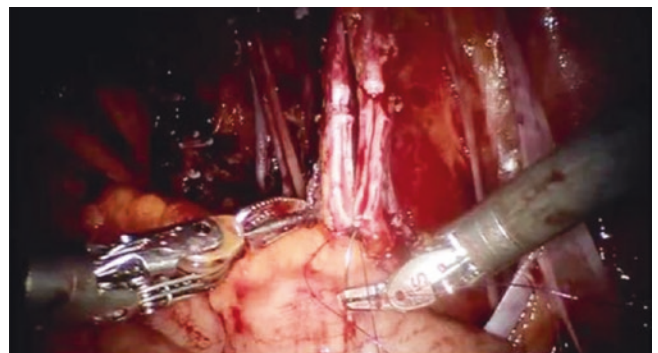


Fig. 51.42 Wallace plate creation started by suturing the apex of both ureterotomies with 5-0 PDS sutures

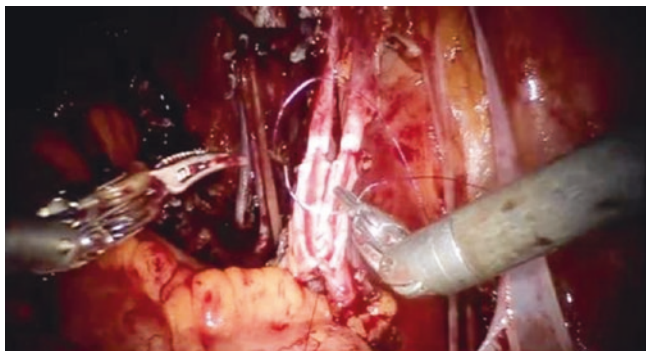


Fig. 51.43 Wallace plate creation in progress

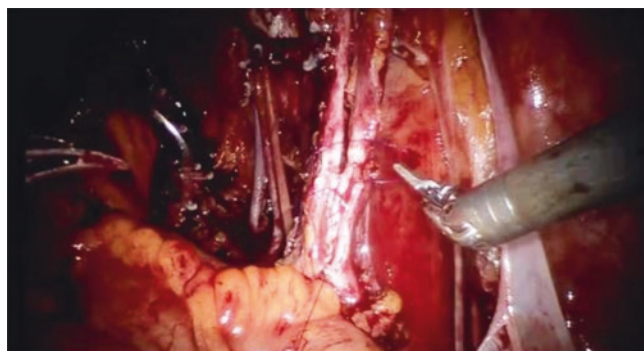


Fig. 51.44 Wallace plate created

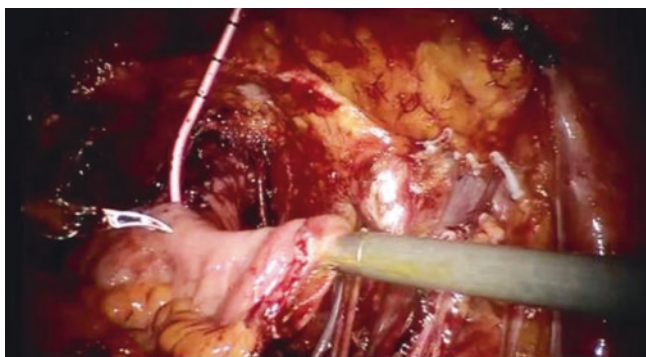


Fig. 51.45 Stent being inserted

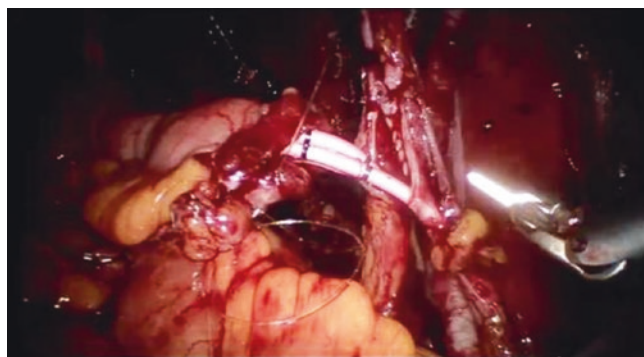


Fig. 51.46 Both ureters stented retrograde

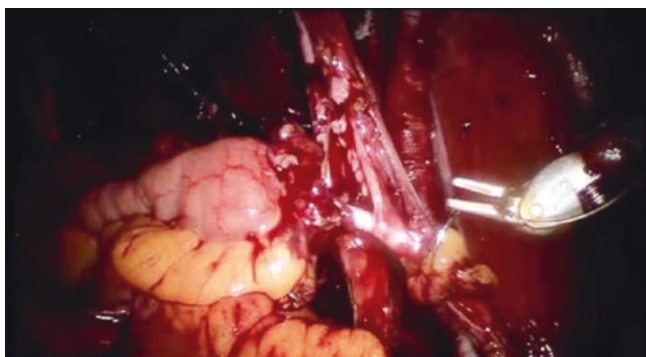


Fig. 51.47 Wallace uretero ileal anastomosis with 4-0 barbed suture

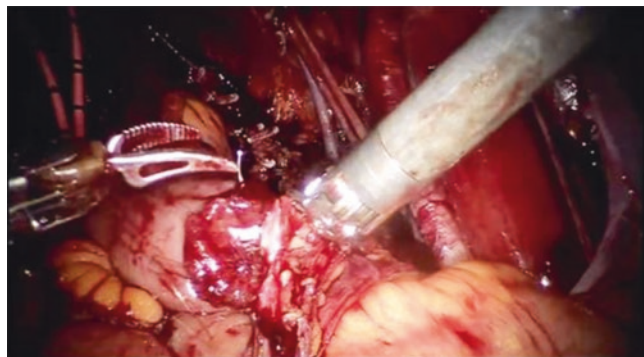


Fig. 51.48 Continuous suture in progress

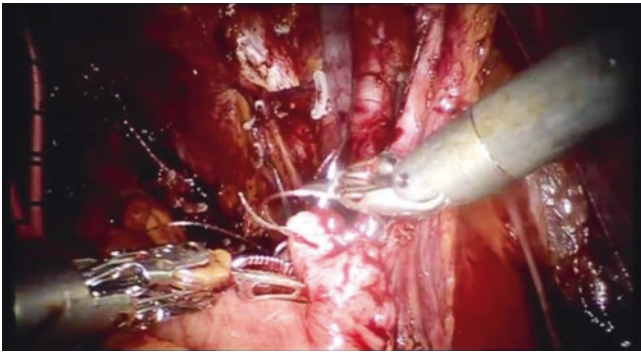


Fig. 51.49 Wallace uretero ileal anastomosis in progress

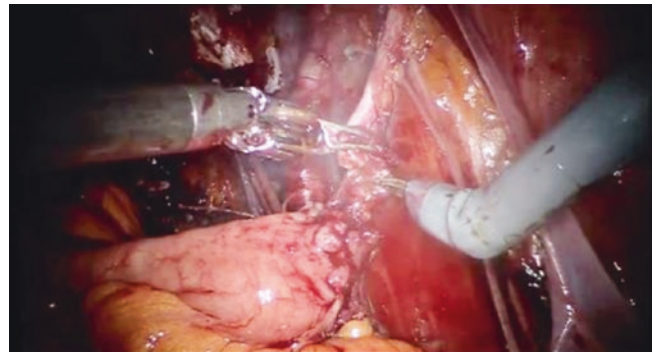


Fig. 51.50 Uretero ileal anastomosis completed and redundant ureter excised

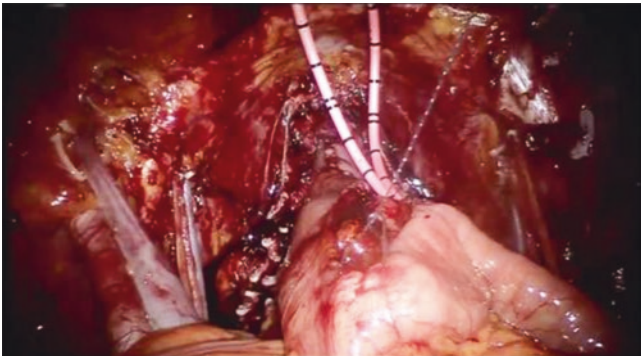


Fig. 51.51 Remaining anterior layer being closed

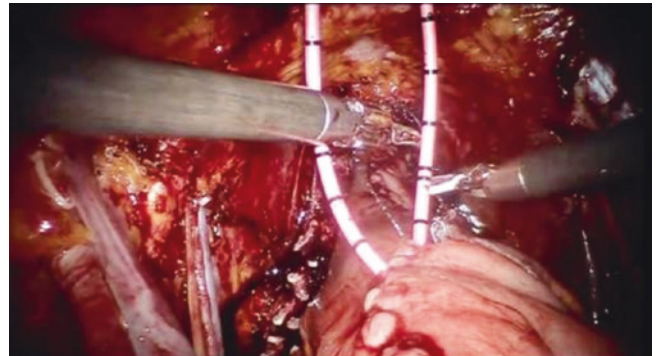


Fig. 51.52 Anterior layer closure completed

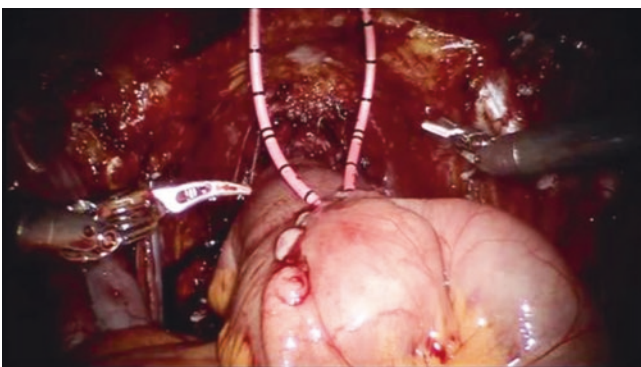

Fig. 51.53 Bladder distended with saline to check for any leak

Part V

Reconstructive Procedures on Prostate

Said Abdallah Al-Mamari and Jean-Luc Hoepffner

Abbreviations

DF	Denonvillier's fascia (synonymous of pPF/SVF)
DVC	Deep veinous complex
ePLND	Extended pelvic lymph nodes dissection
LAF	Levator ani fascia
LPF	Lateral prostatic fascia
LRP	Laparoscopic radical prostatectomy
NVB	Neurovascular bundles
pPF	Posterior prostatic fascia
pPF/SVF	Posterior prostatic fascia and seminal vesicle fascia (synonymous of DF)
PPFs	Periprostatic fascias
PPLs	Puboprostatic ligament
RALP (or RARP)	Robotic-assisted laparoscopic radical prostatectomy
SV	Seminal vesicle
SVF	Seminal vesicle fascia
VPM	Vesico-prostatic muscle

52.1 Introduction

Laparoscopic Radical Prostatectomy (LRP), which was initially reported two decades back, is being increasingly performed now [1–4]. Several studies have demonstrated the superiority of LRP compared to the open retropubic radical prostatectomy (ORP) in terms of reduced intra-operative

blood loss, post-operative morbidity, hospital stay and early recovery of activity [5–7]. However no significant advantage has yet been proven for either technique with regard to oncological or functional outcomes, and there is growing evidence that surgeon's experience is more relevant than the chosen surgical approach [8].

When comparing the extraperitoneal and transperitoneal approaches of LRP, studies have shown the advantages of the former in relation to operative time, pain control, complications rate (less ileus, less risk of intraperitoneal sepsis), length of hospital stay and even early continence recovery [9–11]. Nonetheless, the intraperitoneal route offers some compensatory advantages including better access to the iliac vessels, prevention of lymphocele, avoidance of eventual hernia mesh implants, and easy peri-prostatic dissection when there is a history of a transvesical prostatic adenomectomy. In addition, the advent of the Robotic-assisted laparoscopic radical prostatectomy (RALP or RARP) which is mostly performed through the transperitoneal route has rendered this access more familiar. Consequently our initial practice which consisted almost exclusively of an extraperitoneal approach in the past has now progressed to include the transperitoneal route. Nowadays we routinely perform either technique depending on the patient's history and the surgeon's preference.

We, in this chapter, bring henceforth our contribution to the learning process of this technique through the descending approach developed in Saint-Augustine Clinic since nearly 20 years [3]. We have included in this edition a short account on surgical anatomy of the prostate and the periprostatic structures, as well as a detail of the required instruments.

52.2 Surgical Anatomy of the Prostate and Periprostatic Fascias

The anatomy of the prostate is usually described on the basis of the Gil-Vernet model and the McNeal's zonal anatomy [12, 13]. The former study described three prostatic parts: a caudal, a cranial and an intermediate gland defined by the opening of their respective ducts into the urethral lumen. The

S.A. Al-Mamari
Urology Department, The Royal Hospital, Muscat, Oman
Former Fellow at Saint-Augustine Clinic, Bordeaux, France
J.-L. Hoepffner, MD (✉)
Surgeon, Lap and Robotic Oncological Urologic Surgery, Clinique
Saint-Augustin, 114 Avenue Dares, 33074 Bordeaux, France
e-mail: j.hoepffner@bordeaux.unicancer.fr

latter model considered the urethra as the central anatomic reference point in relation to which four zones were defined: the peripheral zone (70 % of the prostate) which is the origin of almost all carcinomas, the central zone (25 % of the prostate), the preprostatic region, and the anterior fibromuscular stroma [14].

The importance of a better definition of the peri-prostatic fascias (PPFs) has become obvious with the increased necessity of a nerve-sparing procedure. We present hereafter a practical summary relevant to radical prostatectomy.

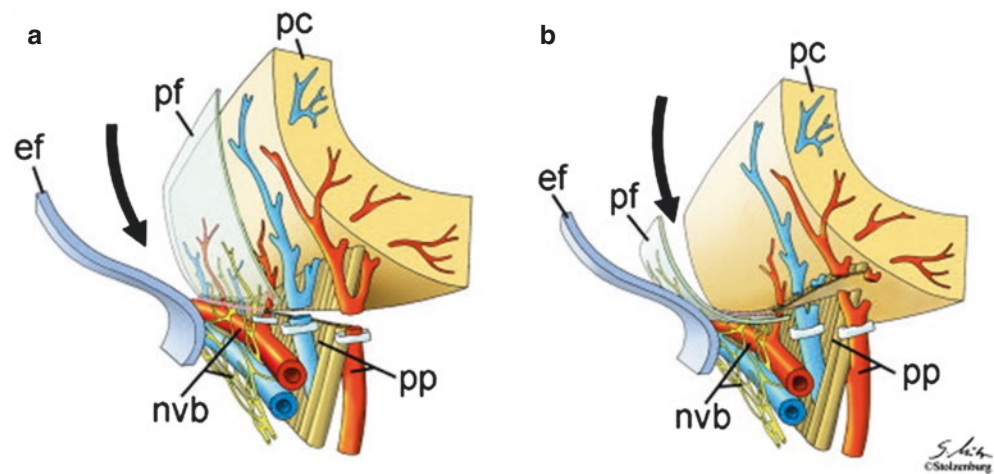
The endopelvic fascia can be described to have a parietal or outer layer i.e. the levator ani fascia (LAF), and a visceral or inner layer i.e. the lateral prostatic fascia (LPF). The two layers fuse in a whitish line named the fascial tendinous arch of the pelvis, which stretches from the puboprostatic ligament to the ischial spine [15–17]. The anterior prostatic fascia is a visceral part of the endopelvic fascia which covers the detrusor apron and the dorsal venous complex (DVC). The Denonvillier's fascia (DF) covers posteriorly the so-called "prostatic capsule" and is derived from the fusion of the posterior prostatic fascia (pPF), which is merely a continuation of the lateral prostatic fascia, with the seminal vesicles fascia (SVF). The descriptive terms "posterior prostatic fascia/seminal vesicles fascia (pPF/SVF)" also refers to this structure

[17]. It separates the prostate from the pre-rectal fatty tissue. Historically a DF layer was described anterior to the seminal vesicles and was reportedly incised to access the vasa deferentia and seminal vesicles from the posterior bladder neck. But this was refuted by a recent histological study [18].

In relation to the above mentioned structures, three dissection planes are grossly proposed: the intrafascial way which progresses flush to the so-called prostatic capsule, staying medial to the LPF and anterior to the DF, the interfascial route which is performed between the LPF and the LAF and the extrafascial technique which is carried out lateral to the LAF [17, 19, 20]. Therefore, it appears that posteriorly, no distinction can be made between the interfascial and the extrafascial dissections as they are both carried out behind the DF.

As the neuro-vascular bundles (NVB) are mainly encountered in the postero-lateral aspect of the prostatic gland between the LPF and the LAF, the intrafascial dissection in this region aims at preserving a maximum of NVB to optimize the functional outcomes (Fig. 52.1a, b), the extrafascial approach will be a non-preserving option which will enhance the oncological results (in locally advanced tumours) and sacrifice the functional ones, and the interfascial approach will be a compromise between the former two options [21, 22].

Fig. 52.1 (a, b) Schematic drawing of interfascial (a) and intrafascial nerve-sparing prostatectomy. *Ef* endopelvic fascia (this corresponds to the parietal layer of endopelvic fascia, i.e. levator ani fascia LAF), *pf* periprostatic layer (this correspond to the lateral prostatic fascia LPF), *pc* prostatic capsule, *pp* prostatic pedicle, *nvb* neurovascular bundle (By Stolzenburg et al. [20], with permission from "Elsevier" in lieu of "Springer".)



52.3 Indications and Contraindications of Descending Technique of Laparoscopic Radical Prostatectomy

The indications for the descending technique is the same as that of any radical prostatectomy. The contraindications are those conditions which preclude any laparoscopic surgery.

52.4 Required Instruments

The required material is simple and comprises (Fig. 52.2a–g):

1. A 0° camera + endoscope, and a video + insufflator column.
2. Five cannulas (trocars): One 10-mm for the endoscope and four 5-mm threaded cannulas for the instruments.
3. Laparoscopic instruments: One each of fenestrated forceps (Johan's grasper), fine forceps, monopolar scissor, bipolar grasper, suction-irrigation device, needle-holder and 5-mm clip-applier.
4. Suture materials: One 26-cm long 3/0 V-Loc™ thread mounted on a 25-mm needle, one 3/0 Monocryl® (polyglactone 25) mounted on a 26-mm needle, one no 1 Vicryl® (polyglactin 910), one 4/0 rapid Vicryl® or one stapler.
5. Tissue retrieval pouch: One Lapbag® 75 × 150 mm.
6. Basic open surgery items:

Characteristically we do not use Hem-o-lock® clips, Ligasure™ vessel sealing, or Harmonic scalpel (Ultracision®). We rarely use the Veress insufflation needle.




Fig. 52.2 View of the basic instruments needed for a LRP: (a) The five trocars. (b) The components of a 5-mm trocar: obturator, threaded cannula and seals. (c) A sealed 10-mm cannula and obturator. (d) Suction-

irrigation cannula. (e) Fenestrated grasper (Johan). (f) Bipolar grasper, monopolar scissor, fine forceps and needle-holder. (g) Clips applicer (Aesculap®)

52.5 Details of the Technique

1. Patient's skin preparation and installation: Once patient is under general anesthesia, sterile drapes are placed. The patient is then catheterized using a 2-way 18-Fr Foley's device, 5 cc water is used to inflate the balloon. Prophylactic antibiotic is given. The patient's positioning is supine in 30° Trendelenberg position with the legs kept slightly apart, and the video column is placed between the legs.
2. Ports placement (Fig. 52.3):

The following port description applies for a right-handed surgeon who will stand on the left side of the patient. A 10-mm incision is made in the skin and the rectus sheath just 1 cm below or above the umbilicus respectively for the extraperitoneal or transperitoneal approach. For the extraperitoneal technique, a 10-mm trocar (port 1) is obliquely inserted at an angle of about 45°, while for the transperitoneal access the insertion is performed in a more perpendicular direction.

Telescope tip is used in combination with pneumodissection to create a larger working space in the extraperitoneal technique, until the Retzius space is developed, and the bladder neck, the pubic arch, i.e. the symphysis pubis + the horizontal pubic rami, and the inferior epigastric arteries are clearly visualized. Rest of the trocars are placed as shown in the figure (Fig. 52.3).

Port 2 and 4 are the left hand and right hand surgeon working port respectively. Port 3 and 5 are for the assistant.

3. Surgical steps:

Note: When the transperitoneal technique is performed, the procedure starts posteriorly by releasing the

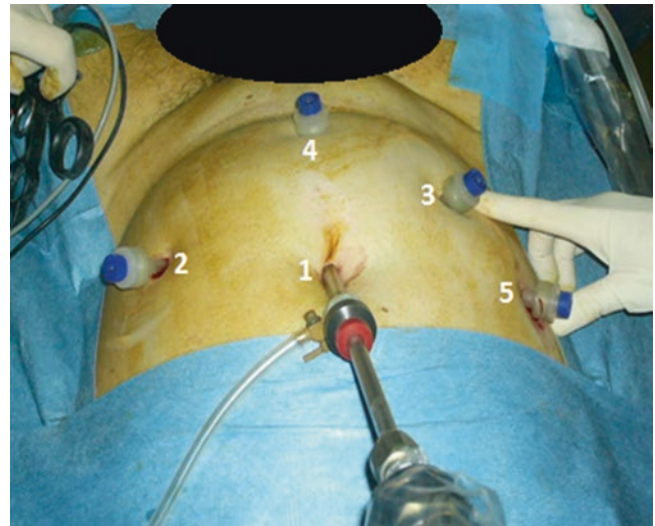


Fig. 52.3 Topography of the five ports

sigmoid colon from its parietal attachment and cautiously mobilizing it up, in order to free the true pelvis. Then the urachus is sectioned and the urinary bladder is progressively released from the anterior abdominal wall. The dissection is carried out laterally till the umbilical ligaments to develop the Retzius space. The pubic arch is clearly visualized and the anterior aspect of the prostate is identified along with the fascial tendinous arch of the pelvis. From this point, the two approaches (transperitoneal and extraperitoneal) are identical.

Step 1: Bladder neck approach and dissection (Fig. 52.4a–e). Three tricks can be used to identify the bladder neck:

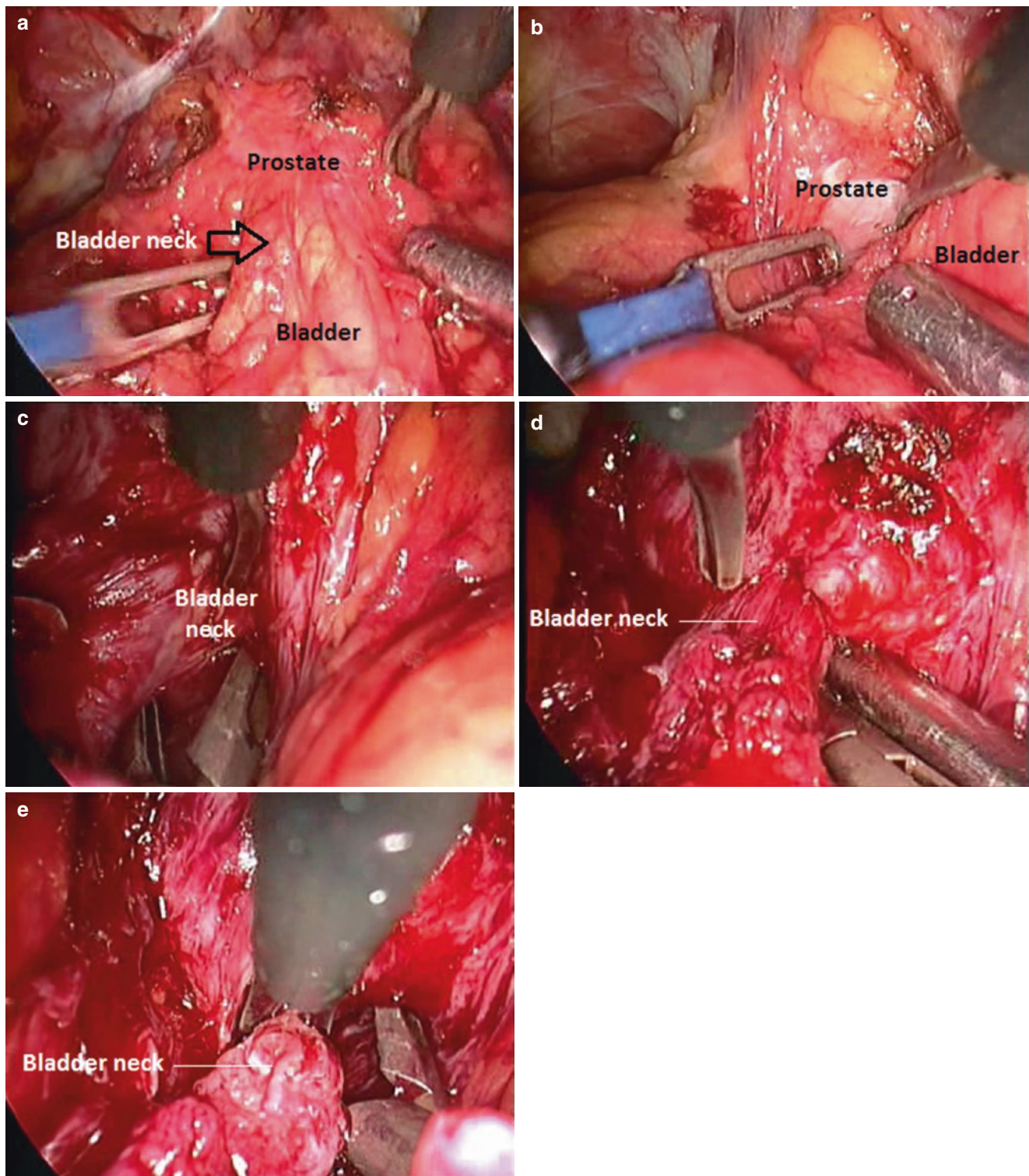


Fig 52.4 Bladder neck dissection. (a) The bladder neck is the last portion of the flabby bladder just above the firm prostate. (b) The dissection starts on the left side (c) Dissection continued on the right side and posteriorly. (c) The assistant opens the fenestrated forceps below the

bladder neck to show the demarcation between the prostate and the bladder. (d) The bladder neck is now fully skeletonized. (e) Division of the bladder neck

- (a) “Palpation” with the bipolar forceps and/or the suction cannula: The urinary bladder is flabby while the prostate is firm. The bladder neck corresponds to the last flabby cm just above the firm-feeling prostate.
- (b) Traction on the catheter: The balloon is blocked at the bladder neck.
- (c) Traction on the bladder dome: The angle between the stretched bladder and the fixed prostate becomes obvious.

Once the bladder neck is identified, the catheter balloon is emptied. Dissection starts anteriorly and continues on both sides and posteriorly until the vasa deferentia or the seminal vesicles are identified. Small blood vessels may be encountered, which are fulgurated using the bipolar

forceps. Urethra is skeletonized to clearly demarcate the bladder from the prostate, the bladder neck is opened and the catheter pulled back.

Step 2: Posterior dissection (Fig. 52.5a–c). The vasa deferentia and seminal vesicles are seen medially after opening the bladder neck and incising the vesico-prostatic muscle (VPM). The Denonvillier’s fascia is opened and the SVs are dissected off the pre-rectal fat. Titanium clips are applied on vessels supplying the SVs and the vasa deferentia. While an upward traction is made on the vasa deferentia, this dissection continues caudally in a plane between the rectum and the Denonvillier’s fascia until the posterior aspect of the prostatic apex is reached.

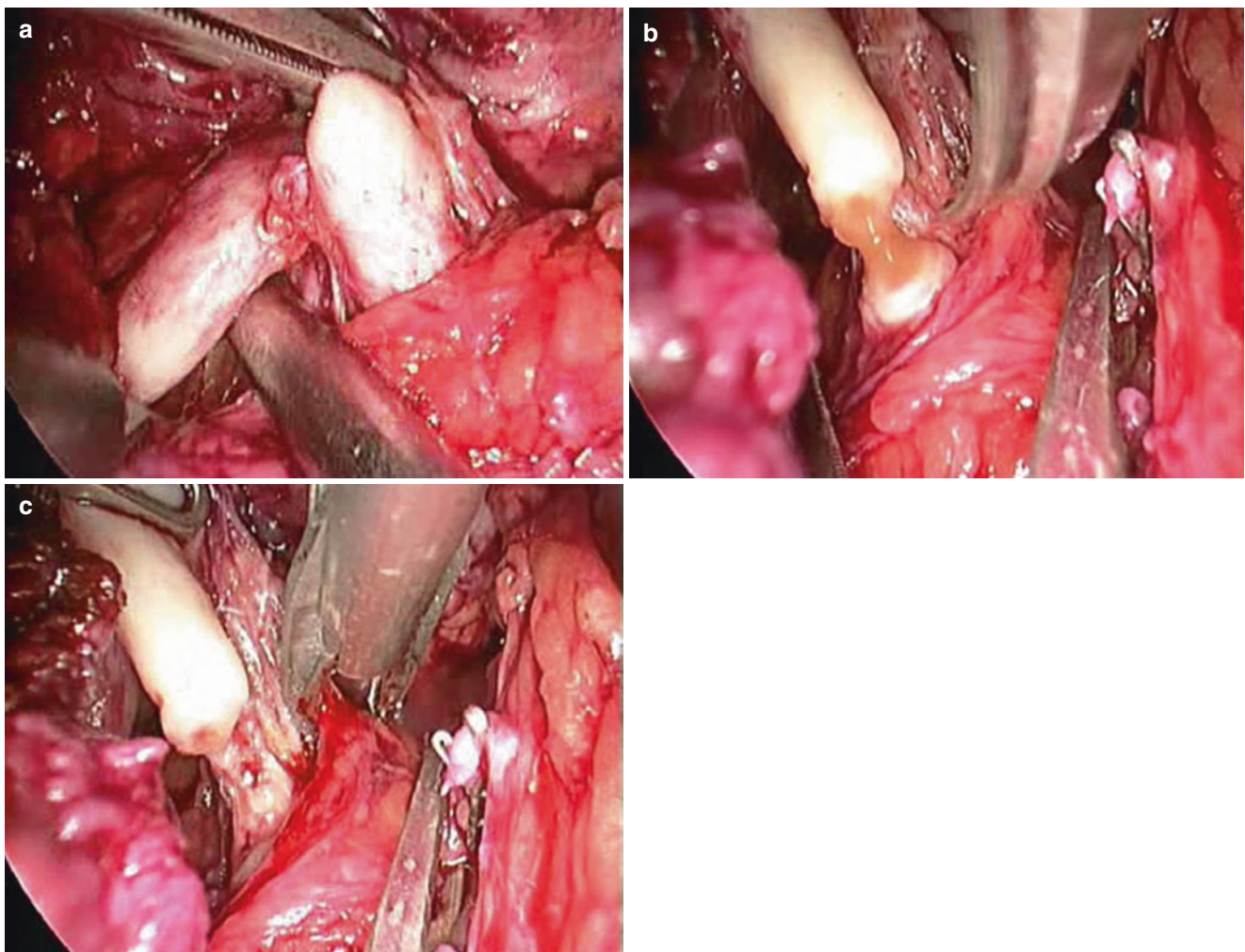


Fig. 52.5 Posterior dissection: (a) The vasa deferentia and SVs are dissected. (b) Section of a vas deferens. (c) A 5-mm titanium clip is applied on the vas vessels

Step 3: Postero-lateral dissection (Fig. 52.6a–c). Traction on the vasa deferentia is maintained to expose the plane between the prostate and the NVB. Here the prostatic pedicle is identified, clipped and sectioned. If the

nerve-sparing technique is an option, strict athermal dissection is performed and 5-mm titanium clips are used to control the many small vessels along the lateral aspect of the prostate.

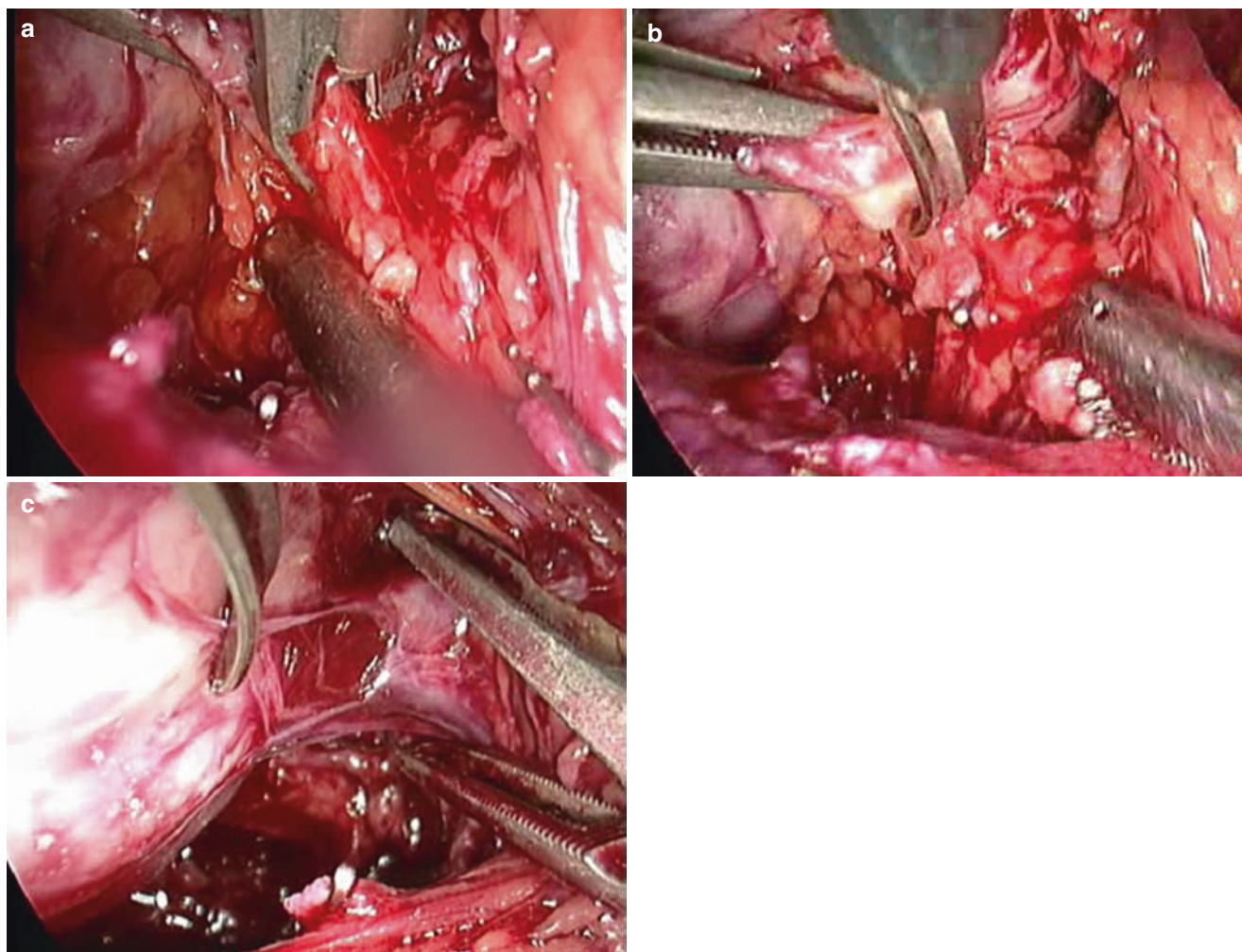


Fig 52.6 Postero-lateral dissection. (a) A 5-mm Titanium clip is applied on the prostate pedicle. (b) Athermal dissection is continued postero-laterally while traction is maintained on the VS. (c) The right

NVB is gently pushed laterally from within the LPF by the open fenestrated grasper and the intrafascial dissection plane is well demonstrated

Step 4: Anterior dissection and division of the urethra (Fig. 52.7a–e). Anteriorly the prostatic apex is approached from behind the puboprostic ligaments (PPLs) and the deep venous complex (DVC). These two structures are

rather dissected off the prostate and are not directly sectioned. Optionally the pneumoperitoneum pressure can be increased to 15-mmHg in order to minimize any bleeding from the DVC. Then the anterior aspect of the prostatic

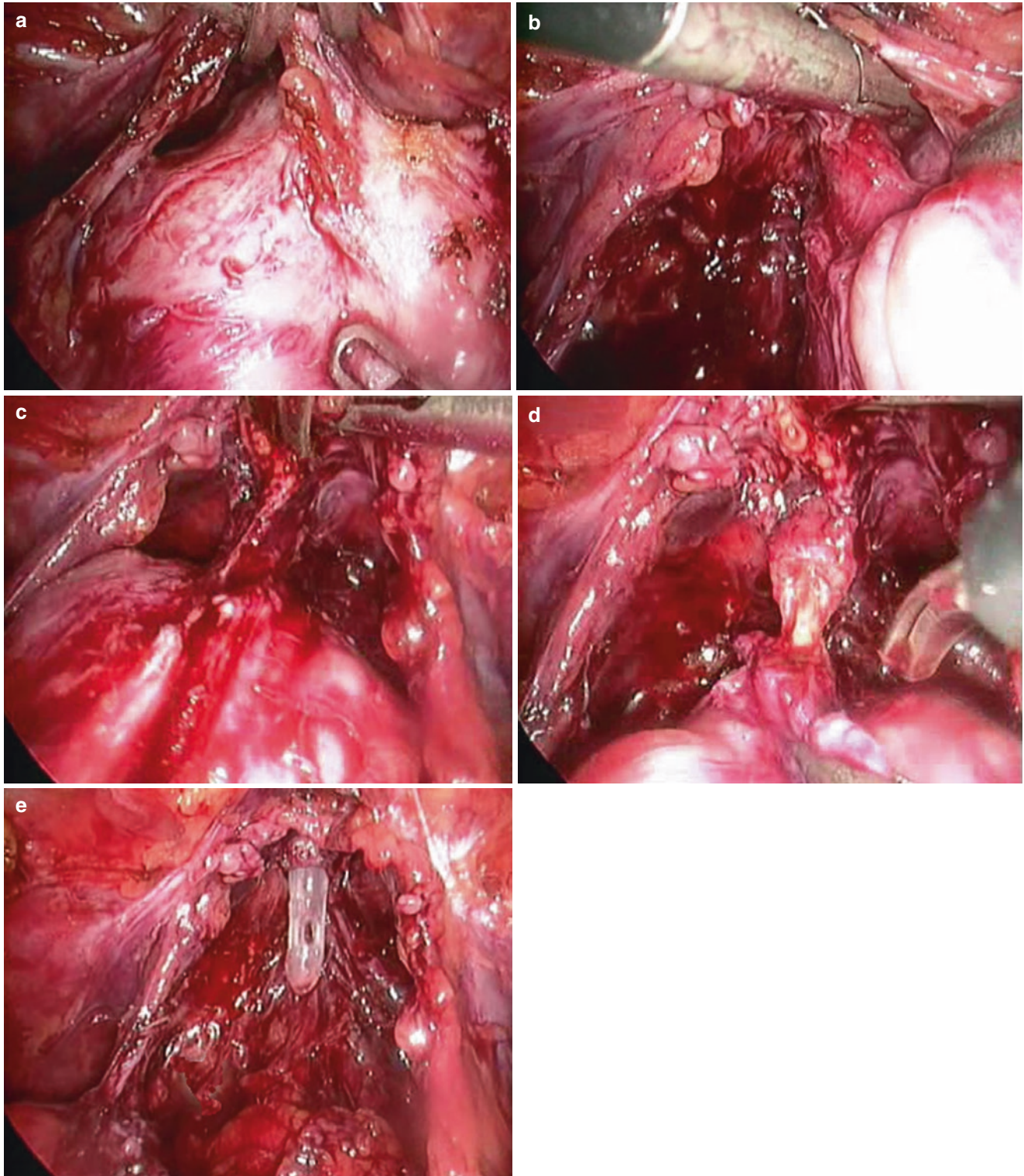


Fig. 52.7 Anterior dissection and division of the urethra. (a, b) The PPLs are dissected off the prostate from within the APF. The assistant pulls up the prostate using the fenestrated grasper. (c) Minimal bleeding

seen from the DVC. (d) The urethra is divided. (e) View after removal of the prostate. See the well preserved NVB

apex is dissected and the urethra divided near the prostate after pulling out the catheter without completely removing it. Now the prostate is completely free all around, and is entrapped in a tissue retrieval pouch. The DVC stump is secured by a continuous suture using a 3/0 Monocryl® (poliglecaprone 25) mounted on a 26-mm needle and the pneumoperitoneum is reduced to 12-mmHg.

Step 5: Vesico-urethral anastomosis (Fig. 52.8). This is performed using a continuous non-interlocking suture with a 26-cm long 3/0 V-Loc™ thread mounted on a 25-mm needle. This suture starts at 3 o'clock by an out-in way through the bladder neck and an in-out fashion in the urethra and continues so-forth posteriorly toward the left side. Once the posterior arch is completed, the catheter can be reinserted into the bladder and the anastomosis

continued anteriorly toward the right side until it reaches the starting point. With its good length, the 3/0 V-Loc™ is then used to attach the anterior prostatic fascia to the bladder neck, enhancing water tightness of the anastomosis, and restoring the tension of the PPLs. 120 ml sterile water is instilled inside the bladder. This serves the double purpose of checking the water tightness of the structure and washing out the bladder. If bloody fluid with clots is sucked back, the wash-out is repeated until fairly clear fluid is obtained and no clots are seen. The catheter balloon is then inflated with 10 cc fluid.

Step 6: Drainage, specimen retrieval and wound closures. Drain is placed on the discretion of the surgeon, specimen extracted by enlarging the camera port and port sites are closed.

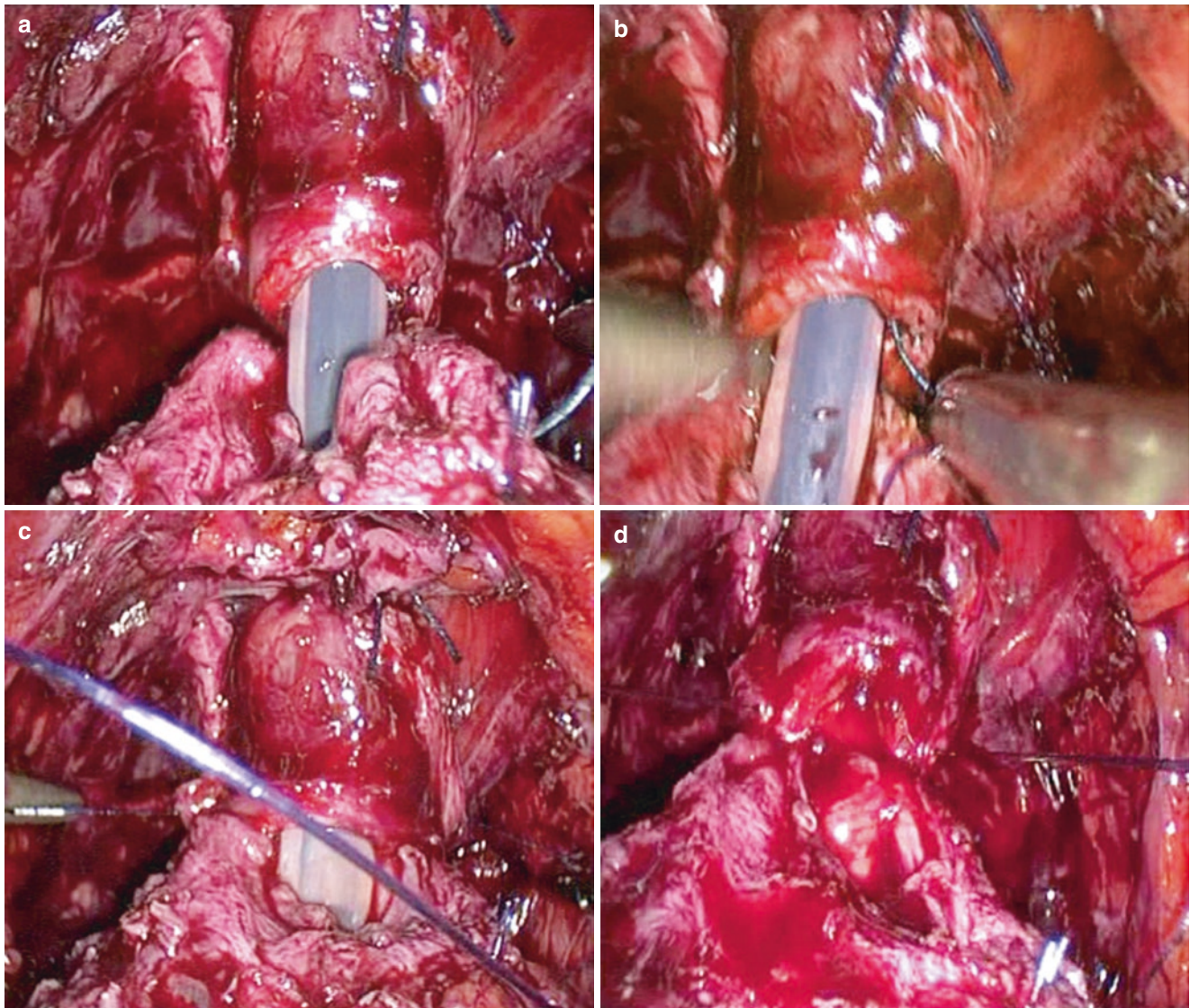


Fig. 52.8 Urethro-vesical anastomosis (anterior arch). (a) Urethrovesical anastomosis started with 3-0 monofilament polyglactin outside in through the bladder. (b) Corresponding suture inside out of urethra at 3 o'clock

position. (c) Posterior urethrovesical anastomosis as continuous suture. (d) Posterior urethrovesical anastomosis as continuous suture. (e) Anterior urethrovesical anastomosis. (f) Urethrovesical anastomosis completed

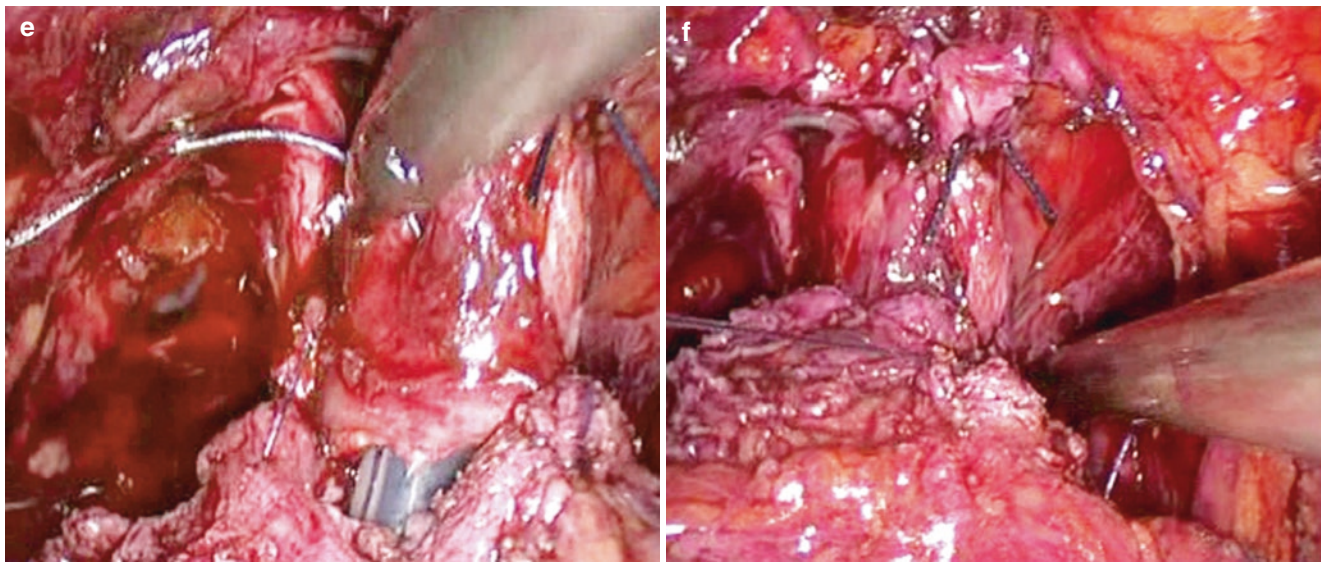


Fig. 52.8 (Continued)

Step 7: Post-operative course. Ambulation is started earlier from the first post-operative day (d1) and the patient receives a low molecular weight heparin such as the Enoxaparin (Lovenox®) 40 mg OD subcutaneously for 2–3 weeks. He is discharged on the third post-operative day and the catheter is removed by a home nurse on the tenth post operative day.

52.6 Conclusion

Our technique is easy to understand and to reproduce. It is now performed either extraperitoneally or transperitoneally and can be summarized by a rapid access and division of the bladder neck, a quick control of the prostatic pedicles and a descending posterior, lateral and anterior approach towards the prostatic apex with preservation of the pubo-prostatic ligaments.

References

- Guillonneau B, Vallancien G. Laparoscopic radical prostatectomy: initial experience and preliminary assessment after 65 operations. *Prostate*. 1999;39:71–5.
- Guillonneau B, Vallancien G. Laparoscopic radical prostatectomy: the Montsouris experience. *J Urol*. 2000;163:418–22.
- Curto F, Benijts J, Pansadoro A, Barmoshe S, Hoepffner JL, Mugnier C, Piechaud T, Gaston R. Nerve sparing laparoscopic radical prostatectomy: our technique. *Eur Urol*. 2006;49(2):344–52.
- Hruza M, Weiss HO, Pini G, Goezen AS, Schulze M, Teber D, Rassweiler JJ. Complications in 2200 consecutive laparoscopic radical prostatectomies: standardised evaluation and analysis of learning curves. *Eur Urol*. 2010;58(5):733–41.
- Caras RJ, Lustik MB, Kern SQ, Sterbis JR, McMann LP. Laparoscopic radical prostatectomy demonstrates less morbidity than open radical prostatectomy: an analysis of the American College of Surgeons-National Surgical Quality Improvement Program database with a focus on surgical trainee involvement. *J Endourol*. 2014;28(3):298–305.
- Sugihara T, Yasunaga H, Horiguchi H, Tsuru N, Ihara H, Fujimura T, Nishimatsu H, Ohe K, Fushimi K, Homma Y. Comparisons of perioperative outcomes and costs between open and laparoscopic radical prostatectomy: a propensity-score matching analysis based on the Japanese Diagnosis Procedure Combination database. *Int J Urol*. 2013;20(3):349–53.
- Grossi FS, Di Lena S, Barnaba D, Larocca L, Raguso M, Sallustio G, Raguso N. Laparoscopic versus open radical retropubic prostatectomy: a case-control study at a single institution. *Arch Ital Urol Androl*. 2010;82(2):109–12.
- Magheli A, Busch J, Leva N, Schrader M, Deger S, Miller K, Lein M. Comparison of surgical technique (open vs. laparoscopic) on pathological and long term functional outcomes following radical prostatectomy. *BMC Urol*. 2014;14:18.
- Cohen MS, Triaca V, Silverman ML, Tuerk IA. Progression of laparoscopic radical prostatectomy: improved outcomes with the extraperitoneal approach and a running anastomosis. *J Endourol*. 2006;20(8):574–9.
- Eden CG, King D, Kooiman GG, Adams TH, Sullivan ME, Vass JA. Transperitoneal or extraperitoneal laparoscopic radical prostatectomy: does the approach matter? *J Urol*. 2004;172(6 Pt 1):2218–23.
- Remzi M, Klingler HC, Tinzi MV, Fong YK, Lodde M, Kiss B, Marberger M. Morbidity of laparoscopic extraperitoneal versus transperitoneal radical prostatectomy versus open retropubic radical prostatectomy. *Eur Urol*. 2005;48(1):83–9; discussion 89. Epub 2005 Apr 12.
- Gil-Vernet S. *Pathologia urogenital: Biología y pathología de la prostata*. T.1. Madrid: Editorial Paz-Montalvo; 1953.
- McNeal JE. The zonal anatomy of the prostate. *Prostate*. 1981;2(1):35–49.
- Villers A et Devonec M. *Anatomie de la prostate*. EMC – Urologie 1993;1-0 [Article 18-500-A-10].

15. Walsh PC. Anatomic radical prostatectomy: evolution of the surgical technique. *J Urol*. 1998;160:2418–24.
16. Myers RP, Villers A. Anatomic considerations in radical prostatectomy. In: Kirby RS, Partin AW, Feneley M, editors. *Prostate cancer: principles and practice*. London: Taylor & Francis; 2006. p. 701–13.
17. Walz J, Burnett AL, Costello AJ, Eastham JA, Graefen M, Guillonneau B, Menon M, Montorsi F, Myers RP, Rocco B, Villers A. A critical analysis of the current knowledge of surgical anatomy related to optimization of cancer control and preservation of continence and erection in candidates for radical prostatectomy. *Eur Urol*. 2010;57:179–92.
18. Secin FP, Karanikolas N, Gopalan A, Bianco FJ, Shayegan B, Touijer K, Olgac S, Myers RP, Dalbagni G, Guillonneau B. The anterior layer of Denonvilliers' fascia: a common misconception in the laparoscopic prostatectomy literature. *J Urol*. 2007;177(2):521–5.
19. Buttet Y, Villers A, Delmas V, Piéchaud T. Bases anatomiques chirurgicales de la prostatectomie totale avec ou sans conservation nerveuse. EMC. *Techniques chirurgicales. Urologie*. 2012;5(1):1–9. Article 41 -304-A.
20. Stolzenburg JU, Schwalenberg T, Horn LC, Neuhaus J, Constantinides C, Liatsikos EN. Anatomical landmarks of radical prostatectomy. *Eur Urol*. 2007;52(3):629–39.
21. Al-Mamari SA, Quintens H, Mentine N, Burté C, Rouyer N, Jacob G, Amiel J. RALP: comparison of the oncological and functional outcomes of the intrafascial and the interfascial approaches. *Prog Urol*. 2015;25:54–61.
22. Cathelineau X, Sanchez-Salas R, Barret E, Rozet F, Galiano M, Benoist N, Stakhovsky O, Vallancien G, et al. Radical prostatectomy: evolution of surgical technique from the laparoscopic point of view. *Int Braz J Urol*. 2010;36(2):129–40 [online], [cited 2015-04-15].

Jens J. Rassweiler, Klein Jan, Fiedler Marcel,
and Goezen Ali Serdar

53.1 Introduction

Beside oncologic outcome, functional results following radical prostatectomy play an important role [1]. Long-term continence (12 months) data exceed 90 % in most laparoscopic and robotic series, however early continence data (3 months) are still in the range of 40–50 % [2–4]. Subsequently early continence represents an important aim for laparoscopic and robotic radical prostatectomy, particularly, since patients opting for a minimally invasive technique expect early functional recovery. Several concepts have been proposed to improve early continence (Table 1; [5–17]) including (i) preservation/reconstruction of puboprostatic ligaments [6, 17], (ii) suspension of DVC [13, 14], (iii) preservation of

bladder neck [12, 17–19], and (iv) posterior reconstruction of the rhabdosphincter [7–11, 20]. Takenaka introduced the concept of preservation of the puboprostatic collar [21]. Based on intensive studies of the current literature concerning pelvic anatomy (Table 2, [21–36]), we added the preservation of the levator fascia to this concept yielding significant improvement of short-term continence results in laparoscopic and robotic-assisted radical prostatectomy. In this article, we want to focus on the current terminology of the pelvic anatomy, describe the technical steps of extraperitoneal retrograde laparoscopic and robot-assisted radical prostatectomy improving early continence, and provide a comparative long-term analysis of our series using different techniques.

Jens J. Rassweiler (✉) • F. Marcel
Department of Urology, SLK Kliniken Heilbronn,
University of Heidelberg, Heilbronn 74078, Germany
e-mail: Jens.Rassweiler@slk-kliniken.de;
Marcel.Fiedler@slk-kliniken.de

K. Jan
Department of Urology Medical School Ulm,
University of Ulm, Ulm, Germany
e-mail: JTK171272@gmx.net

G.A. Serdar
Department of Urology SLK Kliniken Heilbronn,
University of Heidelberg, Heidelberg, Germany
e-mail: asgozen@yahoo.com

53.2 Patients and Methods

53.2.1 Patients

From March 1999 to March 2012, we performed 2502 laparoscopic (LRP) and 310 robotic assisted radical prostatectomies (RALP). From March 1999 to September 2007, we used the previously described technique (old technique) for

apical dissection including division of puboprostatic ligaments, distal ligation of dorsal vein complex, and incision of endopelvic and levator fascia ([37]; Fig. 53.1). In October 2007, we started with the posterior reconstruction according to Rocco (Fig. 53.2) and since September 2008, we applied our new technique including the preservation of puboprostatic collar and levator fascia (Fig. 53.3; Video; Table 3).

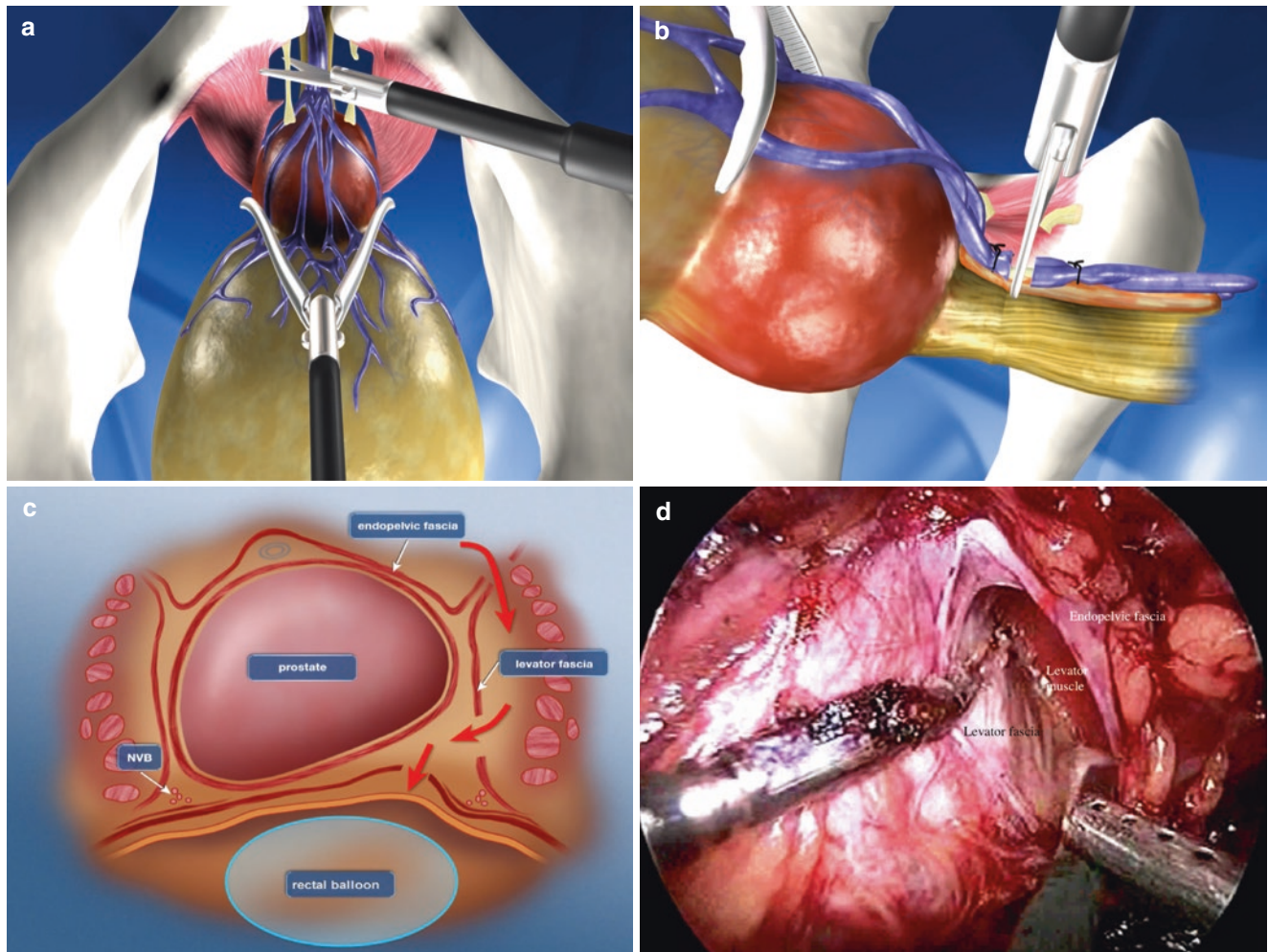


Fig. 53.1 Old Heilbronn technique. (a) Division of puboprostatic ligaments. (b) Distal stitch of dorsal vein complex. (c) Incision of endopelvic fascia and levator fascia (red arrows). (d) Dissection along the naked levator fascia

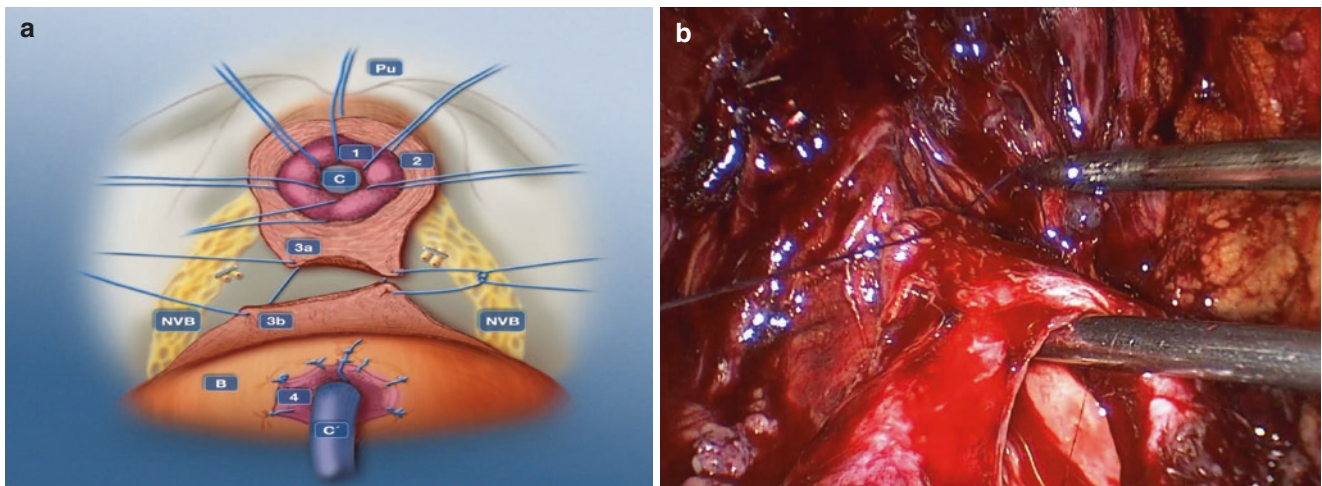


Fig. 53.2 Posterior reconstruction. (a) Schematic drawing according to Rocco et al. [8]: Suture between posterior raphe (rectourethralis muscle = 3a) and vesico-prostatic muscle (3b). Laparoscopic technique does not include everting sutures of bladder mucosa (=4) or pre-placed

stitches of urethral lissosphincter (=2). Posterior reconstruction reduces also tension on neurovascular bundles (NVB). (b) Endoscopic view of posterior reconstruction

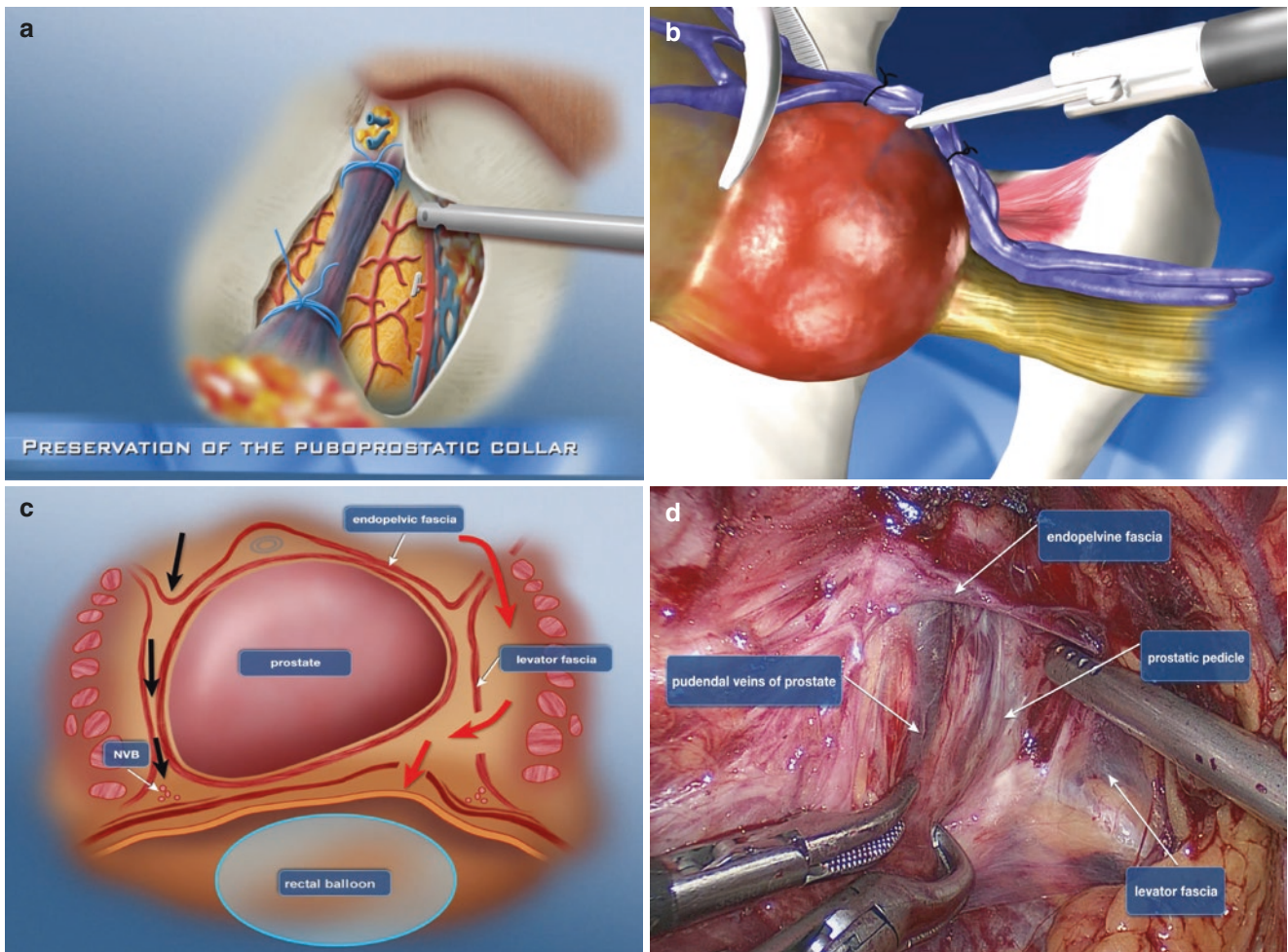


Fig. 53.3 New Heilbronn technique. (a) Preservation of pubo-prostatic collar. (b) Proximal stitch of dorsal vein complex (i.e. mid-portion of prostate). (c) Incision of endopelvic fascia and preservation of levator

fascia by blunt dissection (black arrows). (d) Endoscopic view of anatomic details during lateral and apical dissection with preservation of levator fascia

53.2.2 Anatomical and Physiological Considerations

As already pointed out by Walz et al. [29], the nomenclature and description of the pelvic anatomy differs in many articles. Basically anatomical and eponymical description can be distinguished, however, some authors also used different terminologies (Table 2). In the following we summarize the anatomical details described in the current literature.

53.2.2.1 Periprostatic Fascial Anatomy

Walsh described three layers covering the anterolateral surface of the prostate [22]: the prostatic fascia overlaying the prostatic capsule and levator fascia (fascia diaphragmatica pelvis superior). Both fascias fuse laterally to form the lateral pelvic fascia covered by the endopelvic fascia (fascia pelvis parietalis) reflecting off the transversalis fascia. This area also is described as tendinous arch of the pelvis. Posteriorly, there are two layers [23]: Denonvilliers' fascia (Prostato-seminal-vesicular fascia; septum retrovesicale) and the prostatic capsule (Fig. 53.4). The neurovascular bundles (NVB) run along the posterolateral part of the prostate between levator and prostatic fascia and contain branches from the inferior vesical arteries running medial to cavernosal nerve branches originating from the pelvic plexus. These vessels enter the capsule through the prostatic fascia [38]. Some authors describe the levator fascia also as periprostatic or parapelvic fascia [24, 25].

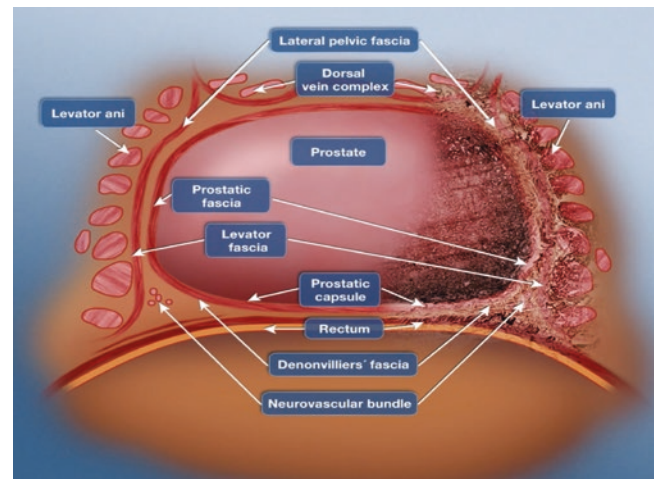


Fig. 53.4 Fascial anatomy of the Prostate according to Walsh 1999. Definition of levator fascia, prostatic fascia, Denonvilliers' fascia, and rectal serosa

53.2.2.2 Course and Branches of Pudendal Nerve

For preservation of continence, the course of intra-pelvic branches of the pudendal nerve is more relevant than the course of neurovascular bundles [5, 34]. The N. pudendus has three branches, (i) nervi rectales inferiores, (ii) nervi perinealis and (iii) nervus dorsalis penis. The perineal rami support the penile muscles (m. bulbospongiosus, m. ischiorectalis, m. ischiocavernosus) and the striated urethral sphincter. Lesions of the perineal branches lead to incontinence. Thus, the anatomical course of pudendal vessels and nerve is important regarding postoperative continence after radical prostatectomy. A., V. and N. pudendus enter the small pelvis through the Foramen ischiadicus minus then following the canalis pudendalis (Alcock's canal). Thereafter the nerve divides medially into its three branches. The perineal rami supporting the striated urethral sphincter run underneath the levator fascia (fascia diaphragmatica pelvis superior) as demonstrated by Hollabaugh et al. [34].

53.2.2.3 Anatomy of Urethral Sphincter Apparatus and the Bladder Neck

The urethral sphincter apparatus consists of the horse-shoe-shaped rhabdosphincter and the smooth-muscle longitudinal and circumferential lissosphincters [29]. Additionally, the prostate is connected laterally to the urethra by thickened fascial band components (Walsh's pillars, Müller's ischioprostatic ligaments). Anteriorly, puboprostatic (pubovesical) ligaments suspend the urethra. For preservation of the puboprostatic collar it is important to keep this part completely intact (Fig. 53.5). Posteriorly, the sphincter apparatus is supported by the median fibrous raphe respectively rectourethralis muscle [22, 23, 31]. Additionally, the striated sphincter is flanked by thickened anteriomedial edges of the anterior levator ani muscle (i.e. urogenital hiatus) forming an incomplete sling behind the urethra. On contraction they forcefully propel the prostate and prostatourethral junction upward and forward enabling quick stop of urination [23, 33, 34]. This movement is countered by the horse-shoe shaped striated sphincter contracting downwards and backwards.

The precise anatomy of the bladder neck and its effect on continence has proven difficult to clarify [16–18, 23]. In the transverse plane, the bladder neck (BN) is composed of two different muscles, the ventrolateral and dorsal longitudinal muscles, which are positioned in an oblique direction. When the BN is examined in a truly transverse direction, there is a distinct circular muscle called the musculus sphincter vesicae [23] possibly representing the rationale for bladder neck preservation.

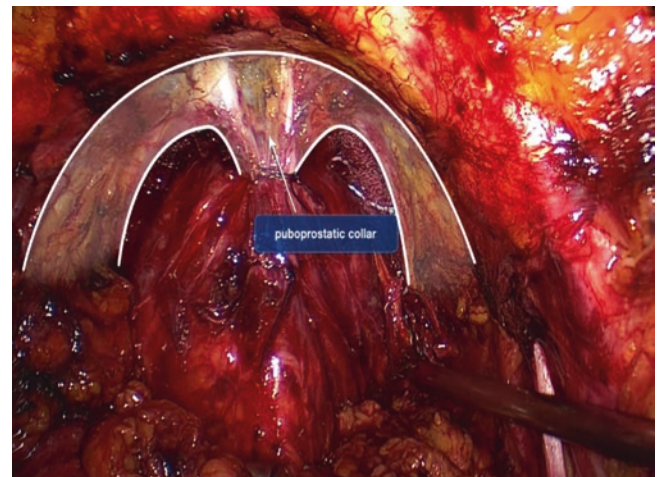


Fig. 53.5 Endoscopic view of pubo-prostatic collar

53.2.2.4 Neurologic Aspects of Urinary Continence Mechanism

Both, the somatic pudendal nerve and the autonomic branches of the pelvic plexus are involved in urinary continence mechanism. Somatic motor innervation passes from the anterior horn of S2-4 segments and travels to the external sphincter via an intra- and an extrapelvic branch of the pudendal nerve. Additional intrapelvic extrapudendal nerve fibres from S2-3 pass lateral to the pelvic plexus and then continue along the dorsolateral surface of the rectum until they disappear into the levator ani muscle and terminate in the urethral sphincter [34]. In addition to the efferent autonomic and somatic nerve fibres innervating the sphincteric musculature, intrapelvic afferents from the membranous urethra contribute to urinary continence. Intact afferents leads to a conscious sensation of urine entering the membranous urethra inducing either a spinal reflex or voluntary contraction of the rhabdosphincter. These afferent fibres run in branches of the pelvic plexus and the intrapelvic branch of the pudendal nerve.

53.2.3 Old Technique of Apical Dissection

Following lateral incision of endopelvic fascia including the levator fascia a dissection plane along the levator ani muscle was created (Fig. 53.2d). Subsequently, the levator fascia was incised secondarily to perform an interfascial nerve-sparing technique. This approach included complete division of puboprostatic ligaments and distal ligation of dorsal vein complex.

53.2.4 New Technique: Step by Step

53.2.4.1 Use of a Rectal Balloon

Prior to final positioning we place a balloon-catheter in the rectum and block it with 30 cc of air. After division of the DVC, the balloon is blocked with 50–60 cc (Fig. 53.6). This facilitates apical dissection by demonstrating the rectal fascia propria [23, 24] and is useful during identification of the apex of the prostate and the neurovascular bundle. Additionally, the risk of rectal injury can be minimized.

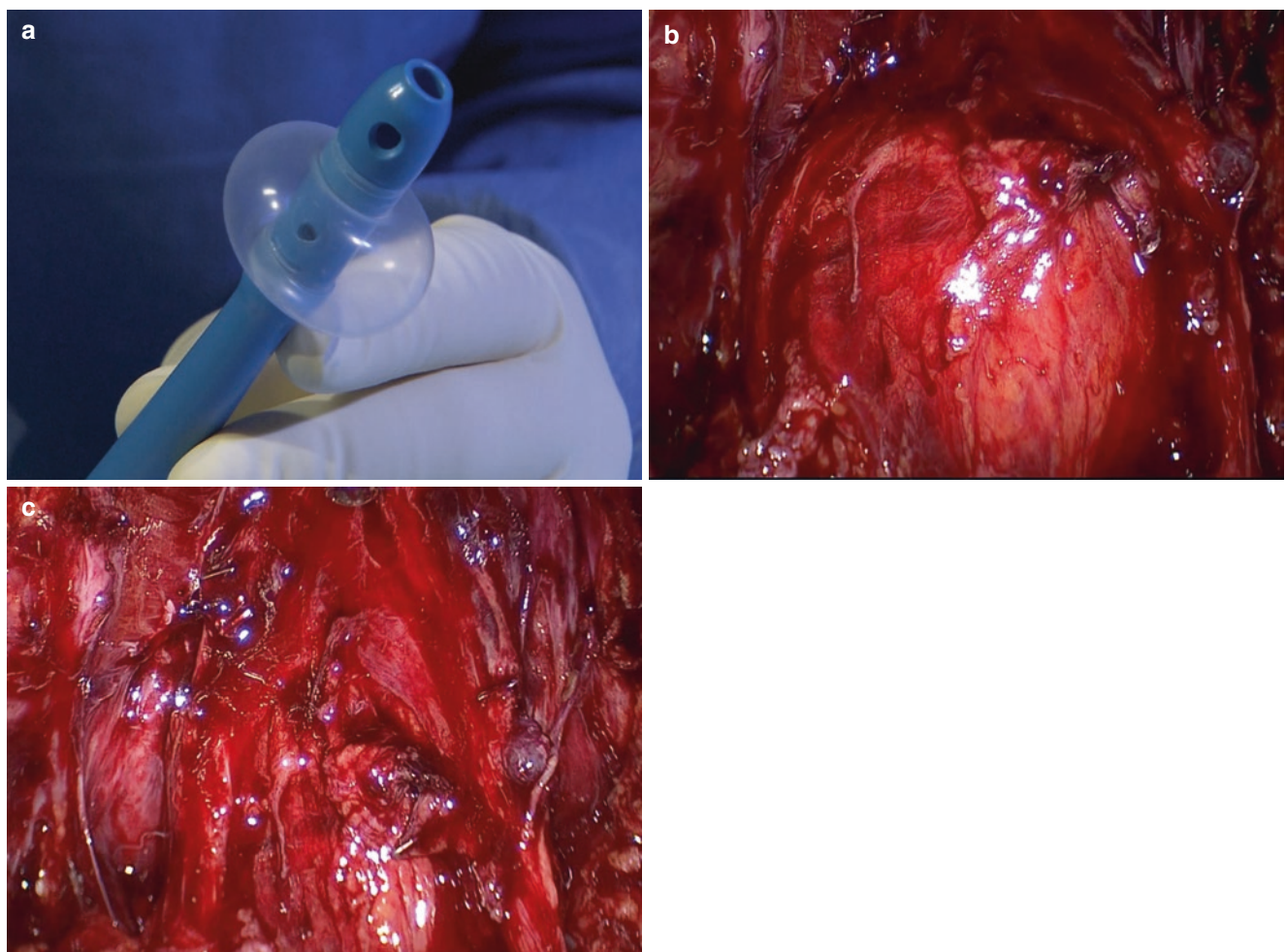


Fig. 53.6 Use of rectal balloon during retrograde dissection. (a) Rectal balloon mainly used for colonography. (b) Endoscopic view with inflated balloon. (c) Endoscopic view with deflated balloon and both preserved NVBs

53.2.4.2 Preservation of Puboprostatic Collar and Levator Fascia

The preservation of levator fascia requires a high medial incision of the endopelvic fascia just below the insertion of the puboprostatic ligaments. Subsequently the cleavage plane between the prostatic and levator fascia is developed bluntly using a right angle dissector (Video, Fig. 53.3d). Alternatively, this plane can be reached by careful incision of the endopelvic fascia lateral to the base of the prostate. During RALP, the same can be effectively carried out using the Metzenbaum scissors to bluntly sweep away the levator fascia. Thus, the perineal rami of the pudendal nerve running to the striated urethral sphincter remain untouched covered by levator fascia.

For preservation of puboprostatic collar DVC is sutured over the mid-part of the prostate. During division

of DVC we place a 120° endodissector at prostatovesical junction (Fig. 53.5) to provide counter-traction. The plane between DVC and anterior surface of prostate (McNeal's anterior fibromuscular stroma; [27]) is dissected by cold scissors (Fig. 53.7a). In case of RALP, we use monopolar scissors for this step. This results in rotation of prostate towards the surgeon to reach urethra and the anterior striated sphincteric complex (Fig. 53.7b), thus straightening the prostatourethral angulation varying from 35 to 90° [23, 27].

Retrograde dissection reproduces the open retropubic technique with earlier identification and release of NVB. For early release, the space between the urethra and the NVB is dissected bluntly until the fascia propria rectalis can be identified.

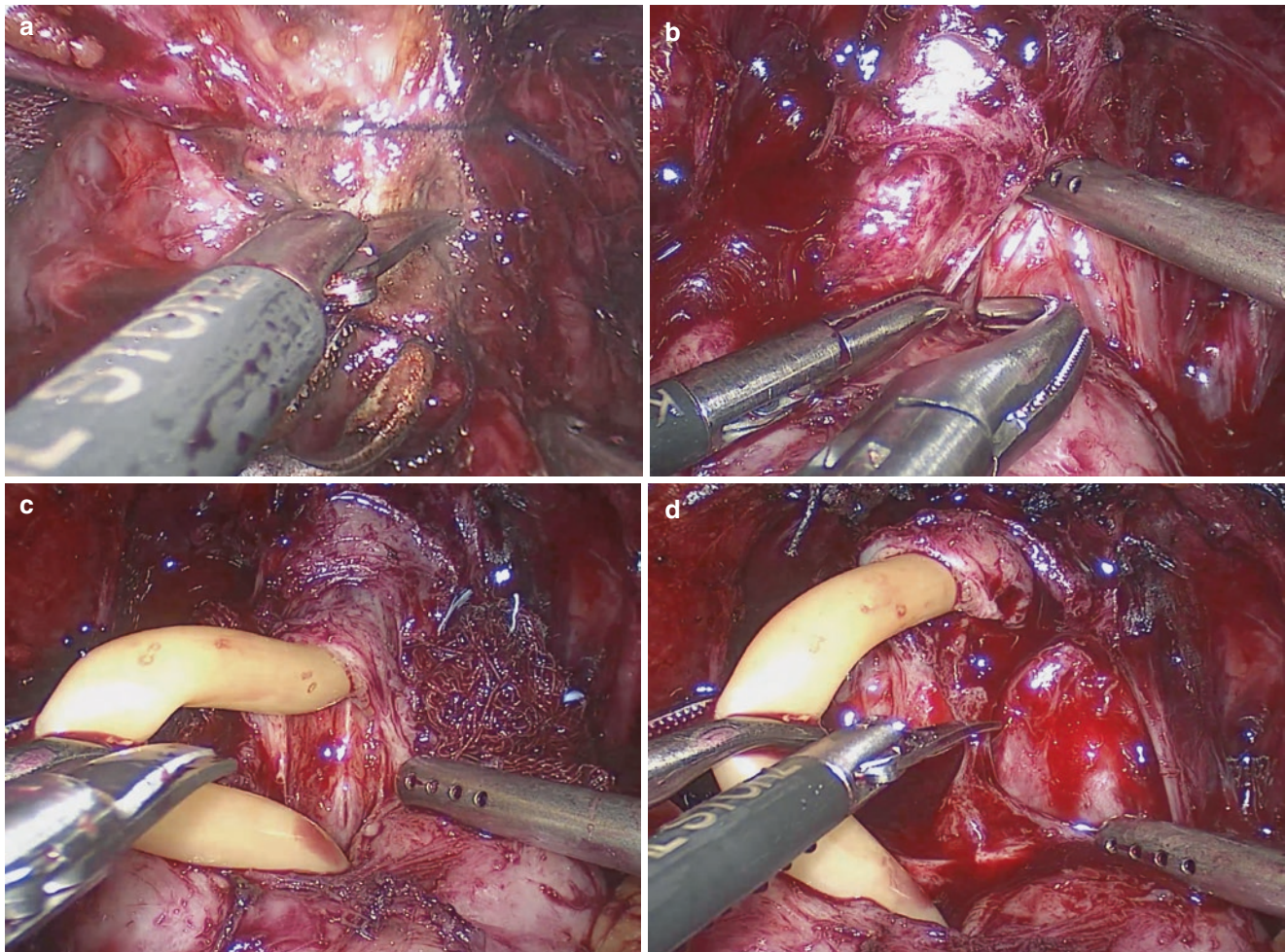


Fig. 53.7 Retrograde extraperitoneal technique of LRP and RALP (Heilbronn-technique) – apical dissection. (a) Division of dorsal vein complex after suturing and bipolar coagulation. (b) Dissection between

rectal serosa and Denonvilliers' fascia using right angle dissector. (c) Incision of urethra and lifting the anterior wall by use of Foley catheter. (d) Division of posterior raphe (i.e. rectourethralis muscle)

53.2.4.3 Division of the Urethra and Posterior Dissection

Following blunt dissection of a long urethral stump exposing the anterior isthmus of the prostate and dividing the ischio-prostatic ligaments, we incise the urethra wall anteriorly. Lifting of indwelling catheter enables optimal exposure of the posterior urethral wall, which is cut distal to the veru montanum considered as the beginning of distal continence zone by preserving the posterior raphe (Fig. 53.7c). The 30° telescope provides a lateral view to the apex minimizing the

risk of cutting tangentially through a prosterior lip of the prostate (Fig. 53.7d).

The distal end of the catheter is pulled with a grasper cranially to expose the posterior surface of the prostate. Posterior dissection is accomplished between the rectal fascia and posterior prostate visceral fascia (Prostato-seminal vesicular fascia, Denonvilliers' fascia). If necessary small branches to the NVB are controlled by 5 mm-Titanium-clips (Fig. 53.8). This leads to a stepwise release of the prostate from the rectum, which can be easily identified due to the inserted balloon.

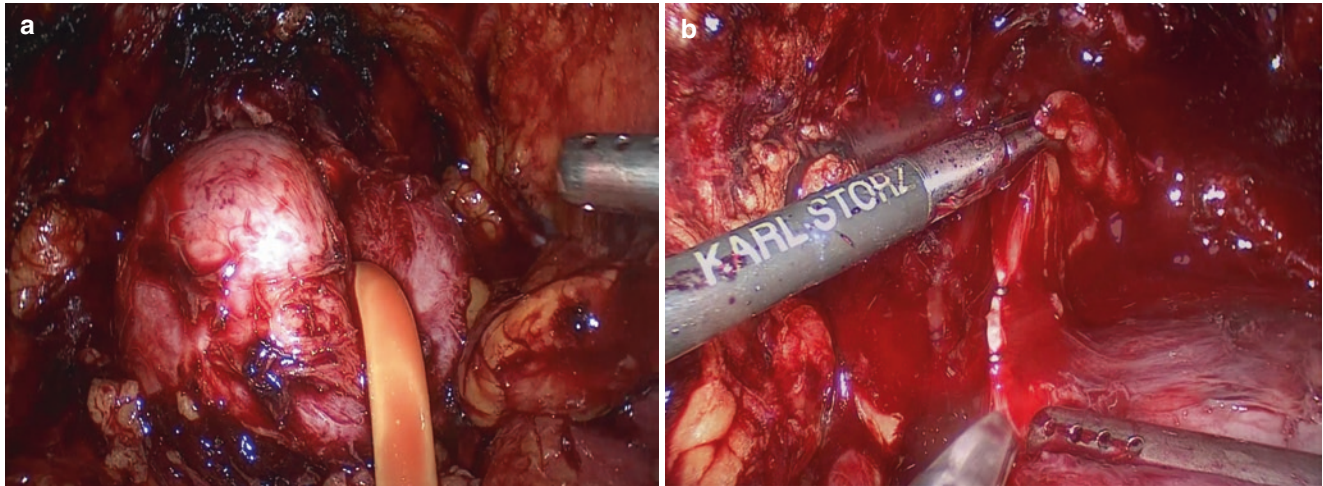


Fig. 53.8 Retrograde extraperitoneal technique of LRP and RALP (Heilbronn-technique) – posterior dissection. (a) Retraction of the prostate using the Foley catheter. (b) Control of vascular branches to the neuro-vascular bundle by 5 mm-Titanium-clips

53.2.4.4 Dissection of Bladder Neck, Seminal Vesicles and Prostatic Pedicles

Following posterior dissection, we pull the prostate anteriorly. The blocked Foley-balloon facilitates exposure of the bladder neck (Fig. 53.9a). The dissection of the bladder neck starts medially (Fig. 53.9b). Smaller detrusor vessels are controlled by bipolar or monopolar coagulation. In RALP we transect both layers of the detrusor muscle (outer longitudinal muscle and inner circumferential muscle) by use of monopolar scissors.

Once the bladder is opened (Fig. 53.9c), we deflate the Foley-balloon and use the catheter as a loop to expose the posterior wall of the bladder neck (Fig. 53.9d). After dividing the bladder neck, the prostato-vesicle muscle is incised close to the prostate to be used for posterior reconstruction of the anastomosis followed by blunt dissection of the spatium urogenitale (Fig. 53.10a). This anatomical space is

limited anteriorly by the prostato-vesicle muscle, laterally by the prostatic pedicle and posteriorly by vas and seminal vesicles (Fig. 53.10b). Now both vasa deferentes are clipped and divided followed by opening of the prostato-seminal vesicular fascia to reach the cleavage plane of posterior dissection.

The vascular supply of seminal vesicles is controlled by clips. Next step represents isolation of the prostatic pedicle. For this purpose the cleavage plane between seminal vesicle and the medial aspect of the pedicle can be dissected bluntly using a right angle dissector or the daVinci-scissors. Following division of the bladder neck, the course of NVB can be demonstrated clearly to determine the adequate position of the clips controlling the proximal pedicle (Fig. 53.10c, d) with adequate distance to the neurovascular bundles. Afterwards the specimen is entrapped in an organ-bag and parked at the left medial trocar (Fig. 53.11).

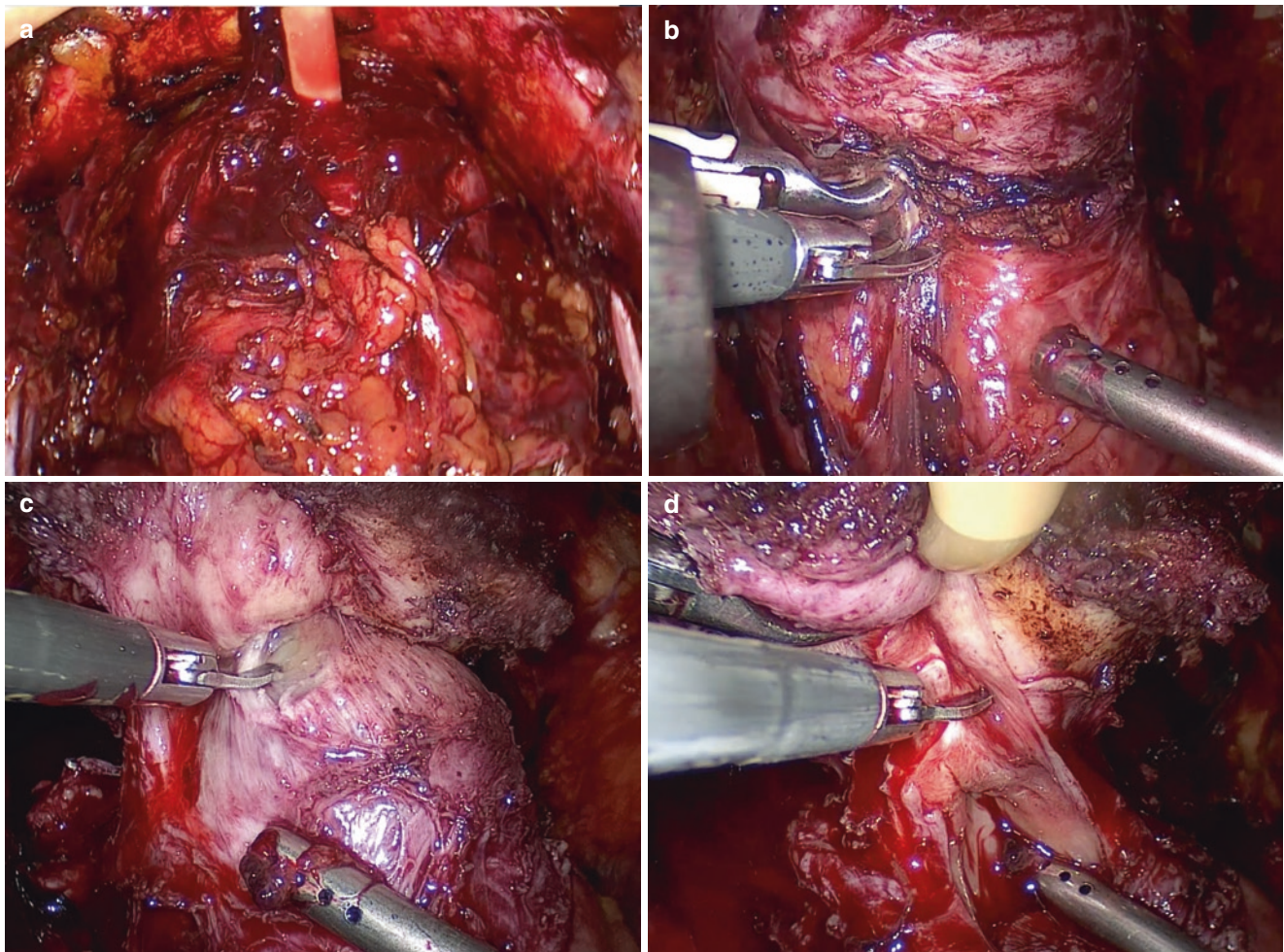


Fig. 53.9 Retrograde extraperitoneal technique of LRP and RALP (Heilbronn-technique) – Dissection of bladder neck. (a) Lifting the apex of the prostate by use of Foley catheter. (b) Incision of bladder neck. (c) Opening of the bladder (bladder neck-sparing). (d) Transection of bladder neck

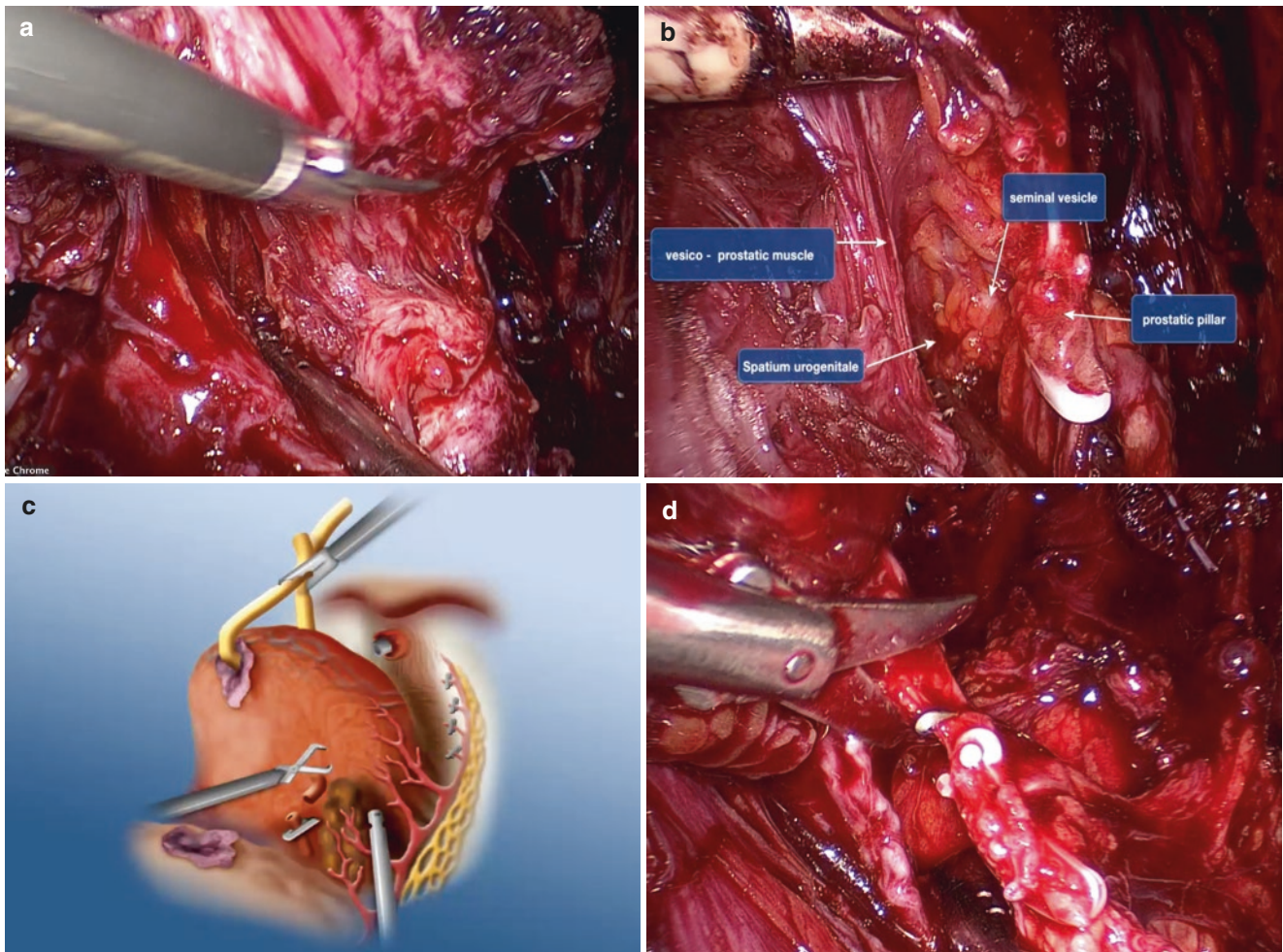


Fig. 53.10 Retrograde extraperitoneal technique of LRP and RALP (Heilbronn-technique) – Division of prostatic pedicles. (a) Incision of vesico-prostatic muscle to expose the spatium urogenitalis. (b) Division

of right prostatic pedicle with Hemo-lock-clips. (c) Schematic drawing to illustrate the division of prostatic pedicle. (d) Final cut of prostatic pedicle with preservation of NVB

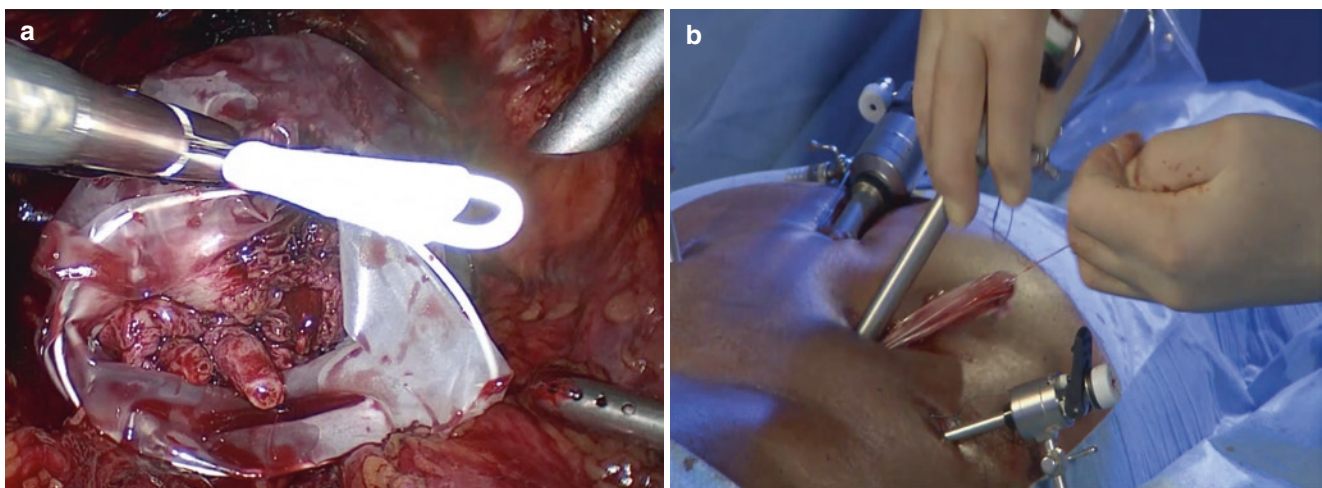


Fig. 53.11 Entrapment of specimen. (a) Use of self-opening bag (Extraction Bag, Karl Storz, Tuttlingen) for immediate entrapment of specimen. (b) Parking of the bag at the left medial port

53.2.4.5 Urethro-vesical Anastomosis

The peri-urethral anatomy is kept untouched including the preservation of the puboprostatic collar, the sphincter apparatus, endopelvic and levator fascia (Fig. 53.12). First step is the adaptation of the prostato-vesicle muscle to the rectourethralis muscle (central raphe) (Fig. 53.5; Table 1) as described by Rocco [8]. The anastomosis is performed using

the van Velthoven technique [40] with either two bi-coloured (17 cm PDS 3/0 and Biosyn; RB1-needle) or barbed (17 cm Quillan 3/0) sutures knotted together (Fig. 53.13). Once the posterior part of the anastomosis is accomplished, the sutures are pulled to adapt bladder neck and urethra using the winch-mechanism). Then we insert the F18-silicone catheter with central perforation and complete the anastomosis.

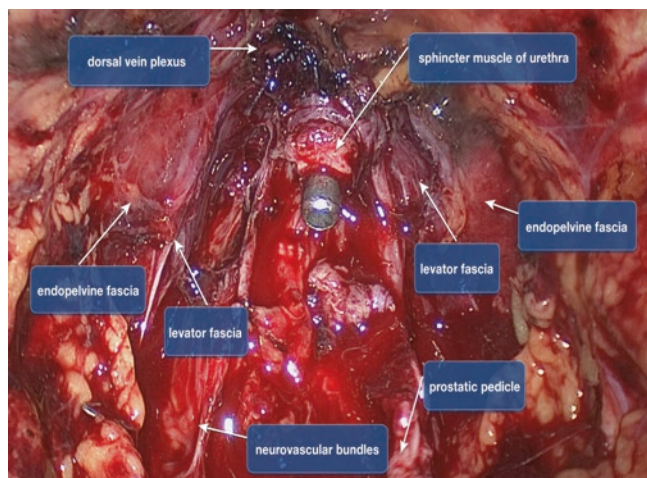


Fig. 53.12 Anatomy of the urethral stump and neurovascular bundles after nerve-sparing LRP with preservation of the levator fascia

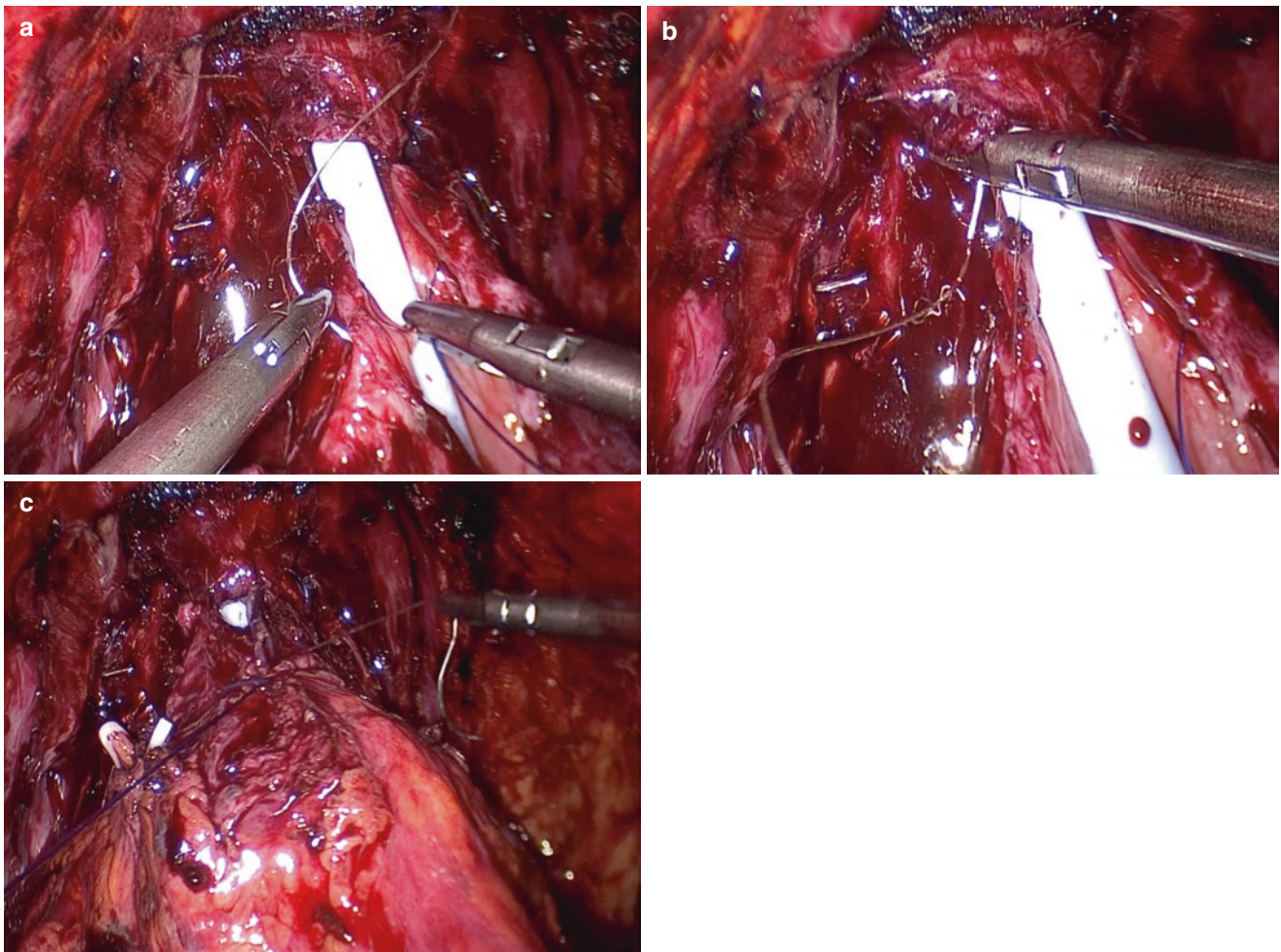


Fig. 53.13 Urethro-vesical anastomosis. (a) Single-knot technique according to van Velthoven using a bicolored suture. Suture through bladder outside-in. (b) Urethral stitch at 9 o'clock (inside-out). (c) Adaptation of the anterior part of anastomosis using the winch principle

53.2.5 Measurements

To determine early continence, we introduced the urine loss ratio (URL) based on a micturation protocol following catheter removal. For this purpose, every patient weighs his pads and records the micturation volume. If URL is below 0.05, the probability to become continent after 3 weeks is 89 % [39]. Additionally, all patients received a validated questionnaire focusing on postoperative continence and urinary symptoms (Appendix). To compare the impact of the operative technique, we did a matched-pair analysis taking 100 patients from each group (old LRP-technique, old LRP plus Rocco, new LRP-technique, new RALP technique) based on the estimated difference by calculating the overall results (Table 4).

53.2.6 Statistics

Category-specific times to continence were first compared based on the Kaplan-Meier method using SPSS, statistical

significance was quantified by log-rank tests. P-values less than 0.05 was defined statistically significant. Subsequently, univariate and multivariate Cox regression was used to assess possible relationships between clinical characteristics and postoperative course of incontinence. Statistical calculations were implemented using SAS version 9.2. Figures were plotted using Microsoft Excel and SPSS.

53.3 Results

53.3.1 Urine Loss Ratio

With our old technique 54 % of the patients who underwent a nerve-sparing procedure had 2 % or less urine loss, and 22 % maximal 5 % urine loss. This did not improve, when adding only posterior reconstruction. However, when using the new technique, the rate of favourable urine loss could be increased to 92 % and 8 % respectively (Table 4).

53.3.2 Continenence Data

Based on the analysis of our questionnaires, we found an significant improvement of early continence (Fig. 53.14). Whereas in univariate analysis, the new technique, the use of

posterior reconstruction, age, the use of the robot, and nerve-sparing technique were significant factors, in multivariate analysis only age, the new technique and a nerve-sparing approach remained significant (Table 4).

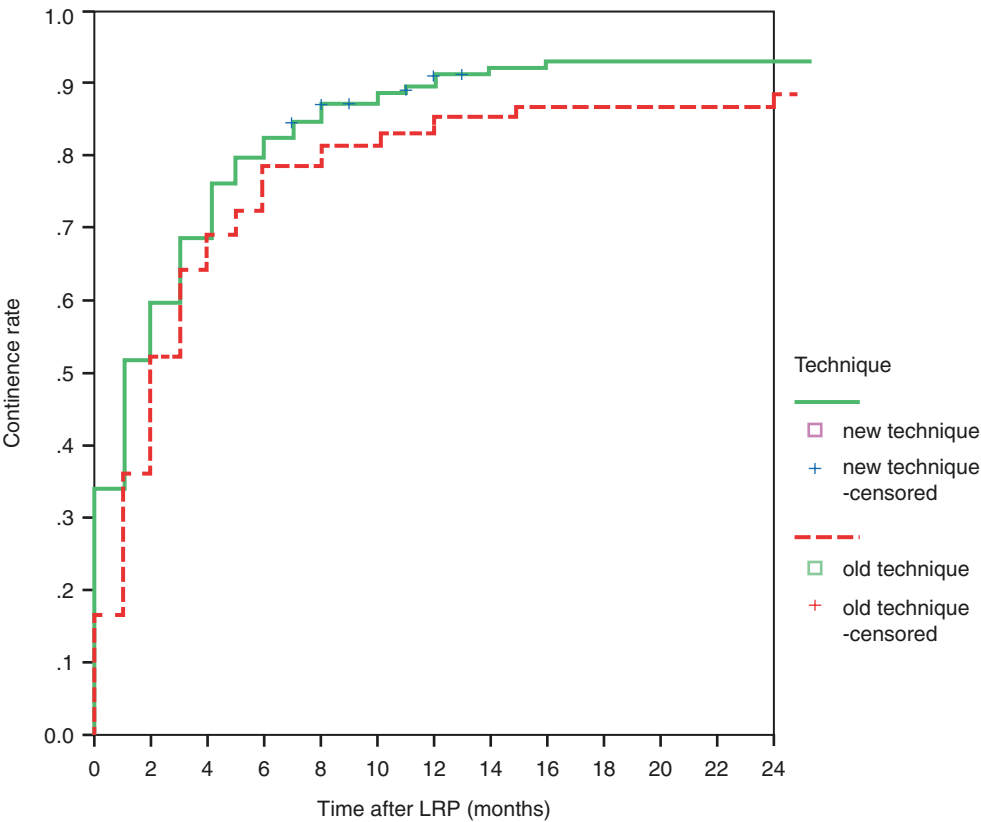


Fig. 53.14 Functional outcome after LRP and RALP – better early continence, when using the new technique

53.3.3 Oncologic Data

Our data revealed overall 10 year- PSA-r ecurrence free survival of 65 %, including 80 % for pT2 and 51 % for pT3-4 (Fig. 53.15a). Clinical progression-free 10-year-survival was

97 % for pT2 and 81 % for pT3 (Fig. 53.15b). We observed a local recurrence in 3 % of pT2- and 13 % of pT3/4-cases managed mostly by early adjuvant irradiation. Overall 10-year survival was 96.8 % for pT2 and 92.2 % for pT3 (Fig. 53.15c).

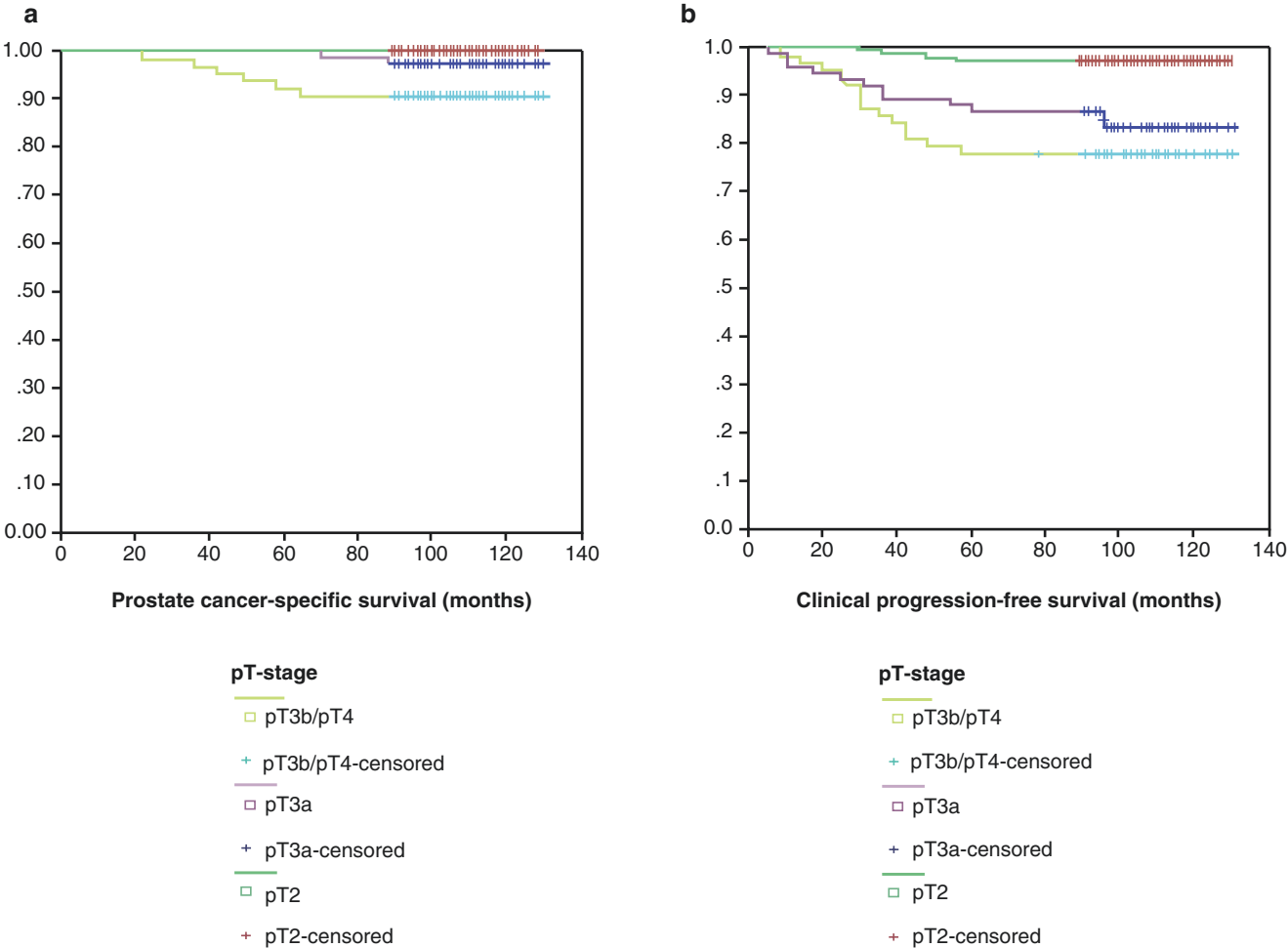
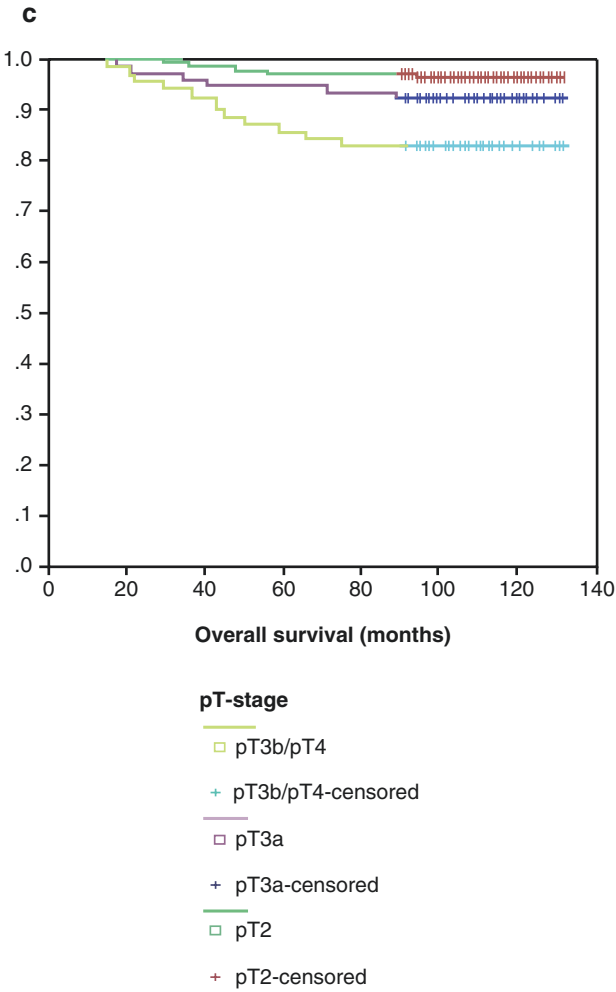


Fig. 53.15 Oncological outcome of LRP at 10 years follow-up (Heilbronn experience). (a) PSA-recurrence. (b) Clinical progression free survival. (c) Overall survival

Fig. 53.15 (continued)



53.4 Discussion

Independently of the approach RRP, LRP, and RALP achieve good long-term continence of more than 90 %. However, even at centres of expertise 3 months-continence rates may not exceed 40 % [3, 4]. Accordingly, several concepts have been presented to improve early continence, all based on functional and anatomical studies [5–21]. Since all of them are based on distinct aspects of the pelvic anatomy, it seems to be very useful to reach a consensus on the terminology describing all anatomical details, which we have tried to summarize (Table 2).

53.4.1 Preservation of Puboprostatic Ligaments and Suspension of Dorsal Vein Complex

The preservation of the puboprostatic ligaments has been already proposed for the open RRP. Recently Stolzenburg [6] advocated this for LRP. The concept is based on the urethral suspension similar to the management of female stress incontinence. In a prospective randomized study they increased 3 months-continence from 40 % to 75 %. The suspension of the dorsal vein by a suture to the pubic bone proposed by Patel [13] is based on the same principle of elevating the urethra. He reported 3 months-continence-rates in 93 % vs. 83 % of his patients and a shorter interval to recovery of continence (7 weeks vs 9 weeks). In contrast, in a randomized controlled study Stolzenburg [14] did not observe any advantage when suspending the urethra.

53.4.2 Long Urethral Stump

Independent from the approach, various authors emphasize the length of the urethral stump as a prognostic factor of early continence and describe an intra-prostatic dissection of the urethra. This is based on anatomical studies of the urethra describing the horse-shoe shaped rhabdosphincter with the transversal and longitudinal smooth muscle sphincters below. The theory is supported by urodynamic studies showing the correlation between functional length of the urethra and postoperative continence [41].

Moreover, Catarin et al. [42] found that after RRP significant autonomic afferent denervation of the membranous urethral mucosa was present in most patients. Impaired membranous urethral sensitivity seemed to be associated with urinary incontinence, particularly in patients with occasional urinary leakage. Thus, damage to the afferent autonomic innervation may have a role in the continence mechanism after nerve sparing RRP.

53.4.3 Preservation of the Bladder Neck

Theoretically, the preservation of the sphincter at the bladder neck should have a positive impact on early continence. Stolzenburg observed in a retrospective study a significant impact of bladder neck reconstruction on early continence (3 months: 73.3 vs 61.3 %), whereas long-term continence was equivalent [12]. However, the role of the detrusor-fibres close to the bladder is still unclear [23].

There are reports on the positive effect of bladder neck preservation or reconstruction on early continence. However, there is no consensus in the literature, and the risk of higher positive margin rates is also discussed [16–19]. Another problem represents the definition and quantification of BN preservation, since the definition of BN preservation is subjective and based on the absence of racket handle repair of the BN and the direct suturing of the BN on the urethra [43]. Evidently, some technical steps like the eversion of the bladder mucosa as proposed by Walsh [22] lost significant impact in the era of robot-assisted urethro-vesical anastomosis. On the other side, it seems to be important to preserve as much of the prostatic-vesical muscle for posterior reconstruction of the anastomosis [20].

53.4.4 Posterior Reconstruction

Studies of Rocco senior and junior proposed a technique of open respectively laparoscopic reconstruction of the posterior urethral plate by suturing the vesico-prostatic to the rectourethralis muscle [7, 8]. The authors were able to improve early continence from 30 respectively 40 % to 74 respectively 83.3 %. Apart from the effect on early continence, this technique may also reduce the tensions on the vesico-urethral anastomosis leading to a lower rate of extravasation respectively insufficiency of the anastomosis [20]. Woo et al. [44] found only a significant advantage of posterior reconstruction when continence was defined as the use of 0–1 pads per day. With a strict definition (pad free) the difference in time to achieve continence was not statistically significant. In the RALP-study of Coelho [9] using a modified two layer posterior reconstruction there was no difference at 3 months, but the interval to recovery of continence was shorter (4 vs 6 weeks). Using the old technique, we were not able to improve ULR by additional posterior reconstruction (Table 4). Accordingly, Rocco et al. [20] concluded in their recent review of the literature, that the role of reconstruction of the posterior musculofascial plate in terms of earlier recovery is encouraging but still controversial.

Additionally to posterior reconstruction, Takenaka et al. [21] proposed the anterior reconstruction (i.e. puboperineoplasty)

with significant improvement of 1 months continence to 77 %. However, the randomized trial of Menon [11] failed to demonstrate any short-term or long-term benefit. Thus, the use of both, posterior and anterior reconstruction, to improve continence remains unclear.

53.4.5 Preservation of the Pubo-Prostatic Collar and Levator Fascia

Takenaka and co-workers [21] presented this interesting concept. The pubo-prostatic collar includes the distal parts of pubo-prostatic ligaments, the dorsal vein complex and the lateral part of endopelvic fascia (tendinous arch; Fig. 53.5). We add to this concept the preservation of the levator fascia, which can be accomplished by blunt dissection between prostatic and levator fascia. Crossing muscle fibres to the prostate are divided. The created anatomical space extends laterally to the rectum, medially to the neurovascular bundles. In contrast to our old technique, we do not dissect directly on the levator muscle fibres, thus minimizing the injury of intraplevic branches of the pudendal nerve (Fig. 53.5). This is in accordance with earlier data of Hollabaugh presented after cadaver studies for RRP [5], who at that time focused on the misuse of a right angle clamp to develop the plane between posterior rhabdosphincter and anterior rectum damaging intrapelvic branches of pudendal nerves coursing to the external sphincter at the 5 and 7 o'clock position. With a modification of their technique they yielded a 3-months-continence-rate of 93 % versus 44.7 %.

Preservation of levator fascia and puboprostatic collar has significant impact on the technique to control of dorsal vein plexus. In the old technique the stitch of the dorsal vein complex was placed very distally after complete division of puboprostatic ligaments. The preservation of the levator fascia and puboprostatic collar does not allow this maneuver. In contrast, the Plexus Santorini is controlled at the middle of the prostate placing the stitch between the prostatic fascia and the dorsal vein complex (i.e. anterior fibromuscular stroma). Subsequently, the dorsal vein complex is stepwise divided to reach the urethra under simultaneous ante-rotation of the prostate [26]. This results in a long stump of the Plexus Santorini preserving the pubo-prostatic collar. In earlier studies [21, 45], the damage and subsequent repair of the striated external sphincter has been discussed mainly when using a right angle clamp to undermine the DVC. In our technique, the control of the DVC takes place far away from the striated external sphincter at the mid-part of the prostate (Fig. 53.3b). Therefore, it seems logical, that this is one of the most significant contributing factors to restore early continence.

53.4.6 The Impact of Nerve-Sparing Surgery on Early Continence

The preservation of bladder neck and neurovascular bundle significantly depend on the stage of the disease and is only indicated in clinical stage T1 and T2. Therefore, both cannot be a standard part of the concept of early continence. Presumably, the nerve-preservation improves early continence, mainly due to the fact, that it also contains sensoric fibres. This may allow the patient an earlier and better sensation of urine entering the posterior urethra. Moreover, most concepts of nerve-preservation (i.e. intra-fascial, inter-fascial) include at least the preservation of parts of the levator fascia [24–26, 36, 46]. However, it has to be mentioned, that in most descending techniques, the levator muscle fibres are initially exposed [4, 13, 15, 21, 44].

53.4.7 The Impact of the Vesico-urethral Anastomosis

Although, we did not see any advantage with the posterior reconstruction according to Rocco, when using our old technique, it is applied routinely in the new concept. The posterior reconstruction reduces the tension on the anastomosis. We adapt the prostatic-vesicle muscle with the musculofascial plate. The urethro-vesical anastomosis is accomplished by the van Velthoven-technique using a bi-coloured suture with two RB1-needles.

53.4.8 Assessment and Prediction of Return of Continence

Several concepts have been proposed recently to predict return of continence after radical prostatectomy including determination pad usage at 4–7 days [47, 48] or evaluation of urine loss ratio [39]. Our series confirmed the applicability of urine loss ratio determined during day 1–2 after catheter removal. A URL <0.02 indicated a 95 % chance of early continence within 3 months.

53.4.9 Non-surgical Factors Influencing Postoperative Continence

As already pointed out by Porena et al. [49], there are other reasons that may have significant impact on voiding dysfunction after radical prostatectomy, such as detrusor dysfunction, impaired bladder compliance or impaired detrusor contractility. However, in this study, we did not assess these factors, but as indicated by our questionnaires, only few patients suffered from such problems. On the other hand, associated morbidity and age still has a significant impact on restoration of early continence (Table 4).

53.4.10 Limitation of the Study

The major limitation of the study represents the fact, that we did not randomize our patients. However, after the pilot analysis showed such a significant difference, we did not want to move back to the old technique. On the other hand, the matched-pair analysis – like in other studies [13] should be scientifically adequate to demonstrate the benefit of our new approach. Based on this the type of operation (LRP or RALP) had no impact on our results.

53.5 Conclusion

Several concepts to improve early continence have been proposed for open, laparoscopic and robot-assisted radical

prostatectomy. Based on the review of the literature and the analysis of our own series, preservation of the levator fascia and the puboprostatic collar represent important steps to provide early continence. This includes preservation of the distal parts of the pubo-prostatic ligaments and proximal division of the DVC at the mid-part of the prostate. Thereby surgical trauma to anatomical integrity of the rhabdosphincter and its neurovascular supply is minimized. Other technical steps, such as suspension of DVC; bladder neck sparing; tennis-racket-suture with bladder mucosa eversion; posterior and anterior reconstruction play only a minor role. Nerve-sparing techniques mainly have a secondary effect on restitution of early continence by the preservation of levator fascia and puboprostatic collar, i.e. when using an intra-fascial technique.

Hariharan Palayapalayam Ganapathi,
Gabriel Ogaya-Pinies, Travis Rogers, and Vipul R. Patel

54.1 Introduction

Radical prostatectomy is one of the gold standard treatments for clinically localized prostate cancer. Since introduced in 2001 robotic assistance has significantly changed the surgical management of clinically localized prostate cancer. Within a decade, robot assisted laparoscopic radical prostatectomy (RALP) is being utilized worldwide. In the USA, more than 80 % of radical prostatectomies are performed with robot assistance [1]. Several technical modifications evolved with the principle of achieving trifecta. Our group introduced the concept of pentafecta with key components of local tumor control with negative surgical margins, less perioperative morbidity while preserving continence and sexual function [2].

Currently, RALP is performed with the da Vinci® system (Intuitive Surgical, Sunnyvale, CA). RALP has attracted the attention of urologists to take advantage of its superior three-dimensional (3-D) vision, 7° of freedom of movement truly mimicking the movements made during standard open surgery, lack of tremor, and superior ergonomics compared to standard laparoscopy. These advantages favor shorter learning curve for complex laparoscopic skills such as intracorporeal suturing and knot tying.

Multiple RALP series demonstrated safety, efficiency, and reproducibility of the procedure. Meta-analysis across multiple high volume centers demonstrated clear advantages in perioperative morbidity and functional outcomes [3, 4].

Our technique is based upon the open approach as described by Walsh and the standard laparoscopic approach. However, after having performed more than 9,000 cases, our technique has evolved significantly, including several

refinements to further improve surgical outcomes and reduce patient morbidity. In the present manuscript, we perform a detailed description of our surgical technique of RALP and provide practical recommendations based on available reports and personal experience. We herein describe the surgical technique we currently perform at our institution.

54.2 Preoperative Preparation

One hour prior to incision, the patient receives 1 g IV cephazolin (first-generation cephalosporin). Prior to induction of anesthesia, sequential compression devices are placed on the lower extremities and the patient receives 5,000 units of subcutaneous heparin. At this point the patient is positioned in low lithotomy, ensuring that thighs are not overextended to avoid neuropraxia. All pressure points including shoulders, elbows and wrists are carefully and thoroughly padded. The patient is placed within a bean bag which is fixed to the table aided by adhesive tape. Abdominal hair is trimmed and the patient is prepped and draped in a sterile fashion. An orogastric tube is inserted before insufflation along with an 18-French Foley catheter with 15 cc sterile water in the balloon.

54.3 Intra-abdominal Access and Trocar Placement (Figs. 54.1–54.6)

Most published RALP series follow the same basic principles with only subtle modifications. Positioning of the patient in extended lithotomy and steep Trendelenburg is the standard.

H.P. Ganapathi (✉) • G. Ogaya-Pinies • T. Rogers • V.R. Patel
University of Central Florida College of Medicine, Global
Robotics Institute, Florida Hospital Celebration Health,
410 Celebration Place, Orlando, FL 34747, USA
e-mail: Hari.Ganapathi@flhosp.org; Hari.uro@gmail.com;
Travis.Rogers.MD@flhosp.org

Likewise, most series utilize the transperitoneal approach as it provides a larger working space, particularly important during lymph-node dissection and urethrovesical anastomosis [5–7]. A six-trocar transperitoneal approach is utilized in all cases. Access to the abdominal cavity is obtained via a 1 cm supra-umbilical incision using a Veress needle insufflating up to 15 mmHg. Indicates our port placement.

Step 1: Incision of the Peritoneum and Entry into the Space of Retzius

Instruments

- Right arm: Monopolar scissors (Da Vinci Si setting: 25 W or Da Vinci Xi setting: 2)
- Left arm: Bipolar forceps (Da Vinci Si setting: 25 W or Da Vinci Xi setting: 2)
- Fourth arm: Prograsp forceps
- Assistant: Microfrance grasper and suction
- Scope: 0° lens

A transverse peritoneal incision is made through the median umbilical ligament and extended on both sides in an inverted U fashion to the level of the vasa deferens laterally. The fourth arm provides countertraction for this step. The peritoneum is dissected down to the pubic tubercle, which is the anatomical landmark used to follow the pubic rami lateral and horizontally so as to not produce inadvertent injury to epigastric vessels above the rami. It is important to dissect the peritoneum all the way up to the base of the vasa for optimum release of the bladder to allow a tension-free vesicourethral anastomosis.

Step 2: Incision of the Endopelvic Fascia (EPF) and Identification of the Dorsal Venous Complex (Figs. 54.7 and 54.8)

Instruments

- Right arm: Monopolar scissors (Da Vinci Si setting: 25 W, Da Vinci Xi setting: 2)
- Left arm: Bipolar forceps (Da Vinci Si setting: 25 W, Da Vinci Xi setting: 2)
- Fourth arm: Prograsp forceps
- Assistant: Microfrance grasper and suction
- Scope: 0° lens

The important landmarks are bladder neck, base of the prostate, levator ani muscles, and apex of the prostate. After defatting the prostate, the fourth arm is used to retract it contralaterally so as to provide adequate exposure and tension on the EPF. The EPF is opened (with blunt dissection) toward the base of the prostate and then followed toward the apex of the prostate to identify the dorsal venous complex (DVC) and the notch where the dorsal ligation and suspension stitch will be placed. This step is performed using cold scissors and taking extra caution in identifying any accessory pudendal arteries that may travel along the EPF. Proceeding from the base to the apex, the fibers of the levator ani are

dissected off the prostate with the round edge of the scissors until the DVC and urethra are visualized. Use caution when dissecting and cutting the pubo-prostatic ligaments because if carried out too medially it will definitely lead to injury of the DVC and unnecessary bleeding. Full dissection of the apex is best performed at the end of the procedure.

Step 3: Ligation of the DVC (Figs. 54.9–54.12)

Instruments

- Right arm: Large robotic needle driver
- Left arm: Large robotic needle driver
- Assistant: Laparoscopic scissors and needle driver
- Scope: 0° lens

We use Caprosyn 1 on a large CT1 needle. The needle is held two-third back at a 45° angle and placed in the notch between the urethra and DVC. The needle is pushed straight across at 90° and then the wrist is turned to curve around the apex of the prostate. At this point we prefer to use the slip knot to tie as it prevents the suture from loosening as it is tied. A second suture is then placed to suspend the urethra to the pubic bone and secondarily ligate the DVC. The DVC is encircled and then stabilized against the pubic bone along with the urethra (Fig) 22.

Step 4: Anterior Bladder Neck (BN) Dissection (Figs. 54.13 and 54.14)

Instruments

- Right arm: Monopolar scissors (Da Vinci Si setting: 25 W, Da Vinci Xi setting: 2)
- Left arm: Bipolar forceps (Da Vinci Si setting: 25 W, Da Vinci Xi setting: 2)
- Fourth arm: Prograsp forceps
- Assistant: Microfrance grasper and suction
- Scope: 30° lens directed downward

The scope is changed to a 30° down-facing lens for the BN dissection. Although some authors use 0° scope throughout the case, we believe that this angled lens is optimal to see inferiorly and to visualize the correct planes. Key points here to correctly identify the BN is identifying where the bladder fat ends on the prostate in the form of an inverted “U” (Fig. 14.4); another trick is to pull on the Foley catheter and visualize the balloon as it reaches the base of the prostate. However, although useful, this can be misleading in patients with prior transurethral resection of the prostate (TURP) or in the presence of median or anterior lobes. The robotic arms also provide a moderate amount of visual feedback to facilitate localization of the boundaries (double-pinch maneuver). This step is begun by cauterizing the superficial veins that are located in the midline with the bipolar forceps. Then the bladder is dissected off the prostate in the midline using a continuous sweeping motion of the monopolar scissors and traction with the bipolar forceps while visualizing the bladder

fibers. The key is to stay in the midline to avoid lateral venous sinuses until the anterior bladder neck is opened and the Foley catheter visualized. Once the anterior urethra is divided, the Foley catheter is retracted out of the bladder using the fourth arm, in an upward manner to expose the posterior bladder neck.

Step 5: Posterior Bladder Neck (Figs. 54.15 and 54.16)

Instruments

- Right arm: Monopolar scissors (Da Vinci Si setting: 25 W, Da Vinci Xi setting: 2)
- Left arm: Bipolar forceps (Da Vinci Si setting: 25 W, Da Vinci Xi setting: 2)
- Fourth arm: Prograsp forceps
- Assistant: Microfrance grasper and suction
- Scope: 30° lens directed downward

The posterior BN dissection is generally considered to be the most challenging step of the operation for the novice robotic surgeon. The difficulty is in appreciating the posterior tissue plane between the bladder and prostate and the direction and depth of dissection necessary to locate the seminal vesicles. After incising of the anterior BN, any remaining peripheral bladder attachments should be divided to attenuate the area of the posterior bladder neck and allow precise visualization and dissection of the posterior plane. The full thickness of the posterior bladder neck should be incised at the precise junction between the prostate and the bladder. The lip of the posterior BN is then grasped with the fourth arm and retracted upward. The bipolar forceps is then used for traction thus visualizing the correct plane between prostate and bladder. The dissection is directed posteriorly and slightly cephalad (toward the bladder) to expose the seminal vesicles. It is important to avoid dissecting caudally (toward the prostate) as there is a possibility of entering the prostate and missing the seminal vesicles completely.

Step 6: Seminal Vesicle (SV) Dissection (Fig. 54.17)

Instruments

- Right arm: Monopolar scissors (Da Vinci Si setting: 25 W, Da Vinci Xi setting: 2)
- Left arm: Bipolar forceps (Da Vinci Si setting: 25 W, Da Vinci Xi setting: 2)
- Fourth arm: Prograsp forceps
- Assistant: Microfrance grasper and suction
- Scope: 30° lens directed downward

Once the posterior BN dissection is complete, the vasa and SVs can be identified. The thin fascial layer over the SVs and vasa should be opened to free the structures for retraction. The fourth arm is used to retract the left vas superiorly and laterally. Dissection continues on the medial side of the vas due to the inexistence of vessels in this area, until the tip of the left SV is venous complex. (e) Second pass through the

dorsal venous complex and the periostium on the retropubis. (f) The final stitch is tied. (Reprinted with permission from Patel et al.) reached. When this occurs it is grasped and retracted with the fourth arm elevating it away from the neuro structures that lie beneath (hypogastric plexus). The vas is then clipped with a 10 mm hem-o-lock followed by clipping of the vessels of the tip of the SV. Then the SV is dissected completely to the base. This procedure is carried out similarly on the right side.

Step 7: Denonvilliers' Fascia and Posterior Dissection (Fig. 54.18)

Instruments

- Right arm: Monopolar scissors (Da Vinci Si setting: 25 W, Da Vinci Xi setting: 2)
- Left arm: Bipolar forceps (Da Vinci Si setting: 25 W, Da Vinci Xi setting: 2)
- Fourth arm: Prograsp forceps
- Assistant: Microfrance grasper and suction
- Scope: 30° lens directed downward

Once the SVs have been dissected completely to the base, the right SV is handed over to the assistant for upward traction; the left SV is retracted using the fourth arm. Downward traction of the undersurface of the prostate with the bipolar forceps is applied and blunt dissection using the monopolar scissors on the base of the SVs correctly identifies Denonvilliers' fascia (visualized as a bright pearly white plane). Denonvilliers' fascia is then entered and dissected laterally and caudally until reaching the apex of the prostate.

Step 8: Neurovascular Bundle (NVB) Preservation (Figs. 54.19–54.21,

Instruments

- Right arm: Monopolar scissors (Da Vinci Si setting: 25 W, Da Vinci Xi setting: 2)
- Left arm: Bipolar forceps (Da Vinci Si setting: 25 W, Da Vinci Xi setting: 2)
- Fourth arm: Prograsp forceps
- Assistant: Microfrance grasper and suction
- Scope: 30° lens directed upward

Athermal Early Retrograde Release: Our approach to nerve-sparing portion is unique as we perform it in a retrograde fashion, mirroring the open approach. It is based upon the philosophy of minimal traction, athermal, and early release of the neurovascular bundle with precise identification at the mid-prostate prior to ligating the prostatic pedicle.

Prior to performing this portion, it is essential to fully dissect the posterior plane up to the apex and laterally to the bundles. Prior DVC ligation is also key as this decompresses large periprostatic veins that can potentially be a frustrating source of bleeding.

For release of the left NVB, the assistant grasps the prostate and rotates it contralaterally (to the right). When dissecting the right NVB the fourth arm is used instead of the assistant to rotate and elevate the prostate, grasping the SVs and border of the prostate in an alternating manner. With the prostate rotated laterally, the lateral pelvic fascia is incised and peeled like an onion until the neurovascular bundle is identified. Once this is accomplished, early release of the neurovascular bundle can then be performed. The levator fascia is elevated with the bipolar forceps and incised along the lateral aspect of the prostate. At the level of the apex and mid-portion of the prostate, the avascular plane between the neurovascular bundle and prostatic fascia is developed with caution, using the bipolar forceps to maintain the neurovascular steady and the monopolar scissors used to peel the prostate off the bundle. The importance of the assistant in this step cannot be stressed enough as they are in charge of maintaining a bloodless operating field for clear visualization of the bundle as well as contralateral traction. Once the posterior plane is reached, the retrograde dissection begins toward the prostatic pedicle and then toward the apex of the prostate. No thermal energy is used during dissection of the bundle or ligation of the pedicle. The path of the bundle has now been clearly delineated and focus can now turn to controlling the prostatic vascular pedicle. The pedicle is controlled with hem-o-lock clips placed above the level of the already released bundle. This technique allows complete neurovascular bundle sparing without the use of any thermal energy, trauma, or inadvertent damage.

Step 9: Apical Dissection (Figs. 54.22–54.25)

Instruments

- Right arm: Monopolar scissors (Da Vinci Si setting: 25 W, Da Vinci Xi setting: 2)
- Left arm: Bipolar forceps (Da Vinci Si setting: 25 W, Da Vinci Xi setting: 2)
- Fourth arm: Prograsp forceps
- Assistant: Microfrance grasper and suction
- Scope: 30° lens directed downward

The landmarks are the ligated DVC, urethra, apex of the prostate, and NVB. Again, it is essential to have securely ligated DVC to prevent bleeding, which may interfere with the apical dissection and division of the urethra under direct vision. Cold scissors are used to carefully divide the DVC and create a long urethral stump facilitating the anastomosis. Complete dissection of the apex and urethra is facilitated by the 10× magnification that the robot provides. Once the urethra has been identified, the bipolar forceps is used to create a plane on the posterior surface of the urethra separating it from the musculofascial plate before incising with cold

scissors. The rhabdosphincter is then incised with caution, avoiding any posterior lip that the prostate may have at this location.

Step 10: Bladder Neck Reconstruction, Modified Posterior Reconstruction of the Rhabdosphincter and Urethrovvesical Anastomosis (Figs. 54.26–54.34)

Instruments

- Right arm: Large robotic needle driver
- Left arm: Large robotic needle driver

Before starting the bladder neck reconstruction it is essential to check the position of ureteral orifices and their distance from the edge of the bladder neck. Bilateral plication over the lateral aspect of the bladder is then performed using sutures of 3-0 Monocryl, with 6 in. length, in an RB-1 needle. The suture begins laterally and runs medially until the bladder neck size matches that of membranous urethra. The same suture subsequently runs laterally, back to the beginning of the suture in the lateral edge of the bladder neck; the suture is then tied.

Prior to performing the vesicourethral anastomosis, we perform a modified reconstruction of the pelvic floor, reattaching Denonvilliers' fascia to the rhabdosphincter as following the principles described by Francesco Rocco et al. 24 For this step, we use a 12 cm double arm 3-0 Monocryl suture on an RB1 needle attached together. We proceed to identify the free edge of Denonvilliers' fascia, which is approximated to the posterior aspect of the rhabdosphincter and posterior median raphe running one of the arms of the suture and tied. A second layer is then run with the second arm of the suture, approximating the posterior bladder neck to the posterior lip of the urethra 25.

A continuous modified van Velthoven vesicourethral anastomosis is then performed. Two 8 in. 3-0 Monocryl sutures on RB1 needles (dyed and undyed) are tied together with ten knots to provide a bolster for the anastomosis. The posterior urethral anastomosis is performed first with one arm of the suture starting at the 5 o'clock position until reaching the 10 o'clock position in a clock-wise fashion. This is followed by completion of the anterior anastomosis with the second arm of the suture in a counterclockwise fashion and then tying both sutures on the urethral stump 26. The key to performing an efficient rapid watertight anastomosis is to use both hands when suturing; that is, the left hand feeds the suture to the right and so forth. Having a long urethral stump, normalized bladder neck, clear operative field, and exerting perineal pressure (in some instances) contributes to this also. Once the anastomosis is completed, a new 18 Fr Foley catheter is placed and saline solution is used to irrigate and eliminate any clots and also to confirm a watertight anastomosis. A Jackson–Pratt drain is placed at the pelvic rim and then all trocars are removed under direct vision.

Fig. 54.1 Patient positioning for RALP

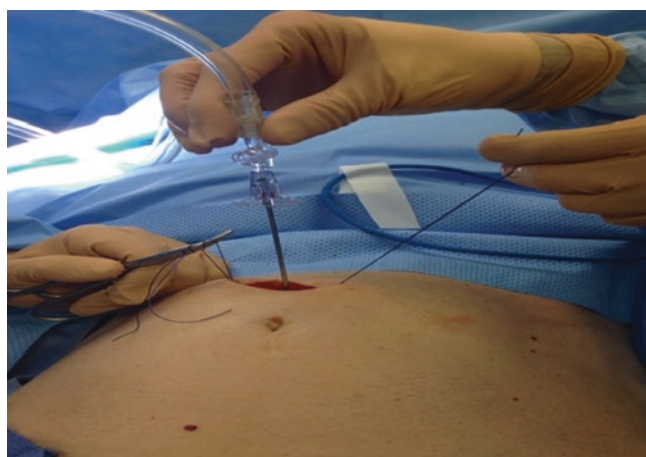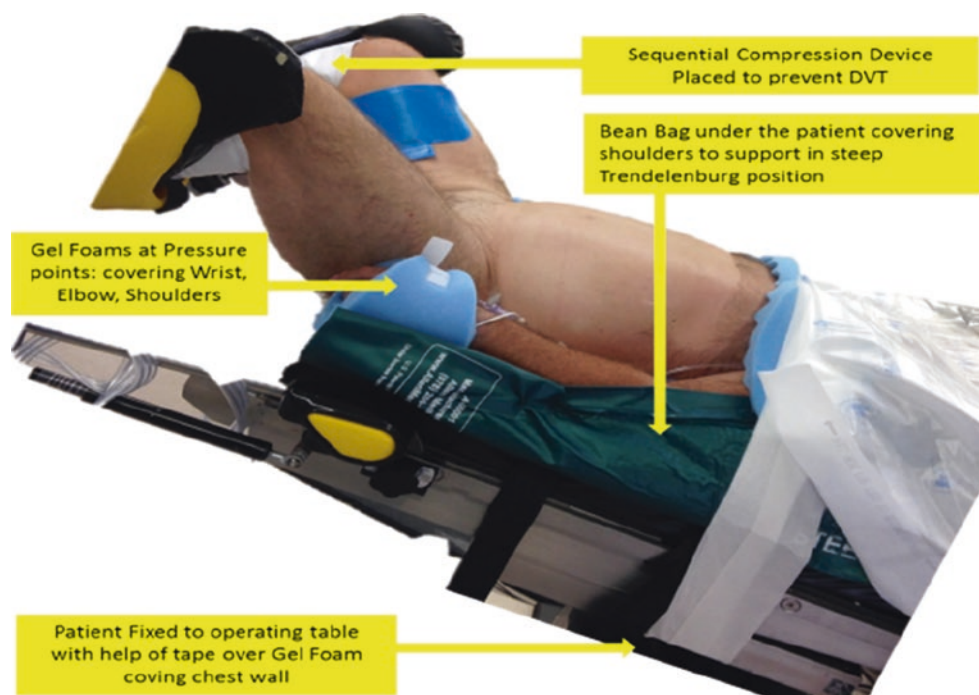


Fig. 54.2 Supra-umbilical incision, support stitches in the rectus sheath and Veress needle insufflation

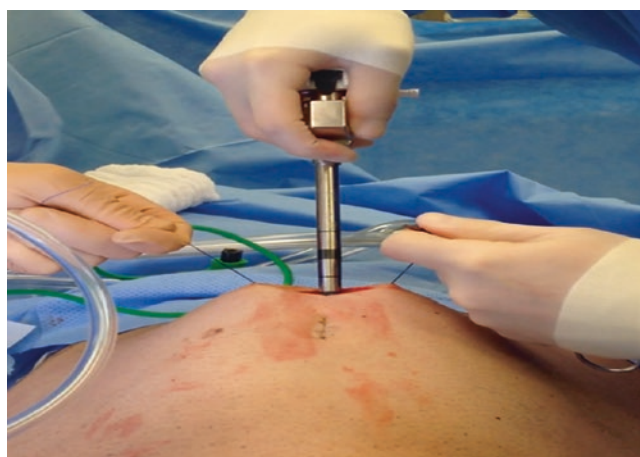

Fig. 54.3 Camera port placement (Da Vinci Xi 8 mm trocar)

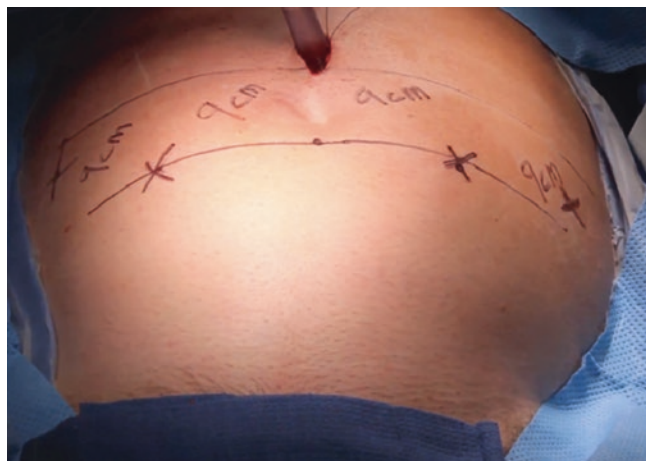

Fig. 54.4 Port position marking for Da Vinci Si surgical robot assisted radical prostatectomy

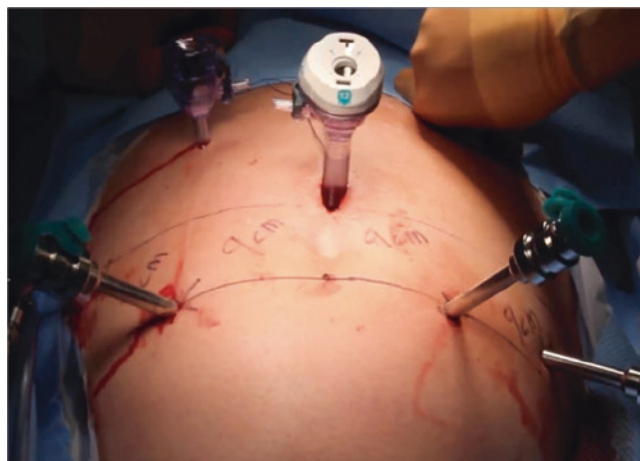

Fig. 54.5 Port in place for Da Vinci Si surgical robot assisted radical prostatectomy

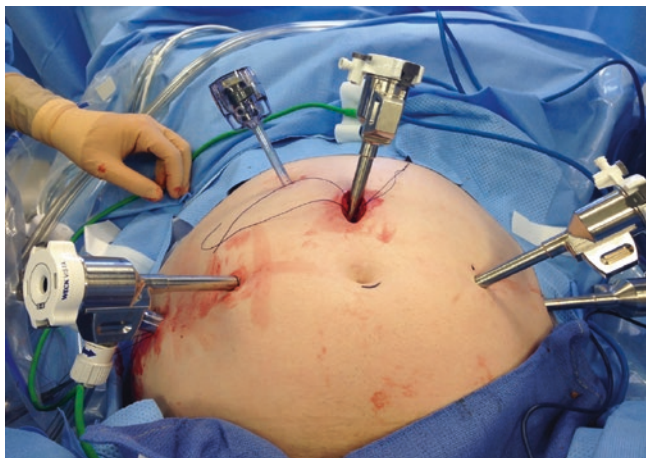


Fig. 54.6 Port in place for Da Vinci Xi surgical robot assisted radical prostatectomy

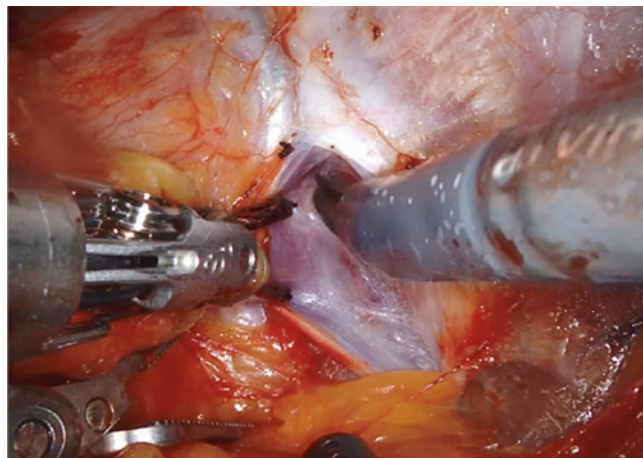


Fig. 54.7 Incision of endopelvic fascia

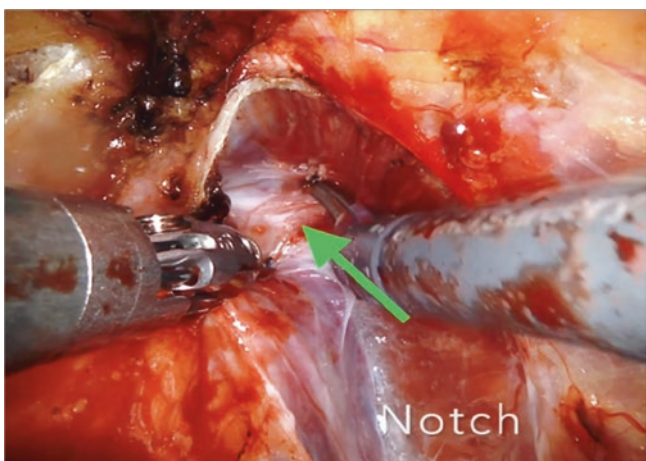


Fig. 54.8 Incision of endopelvic fascia and identification of notch between DVC and urethra

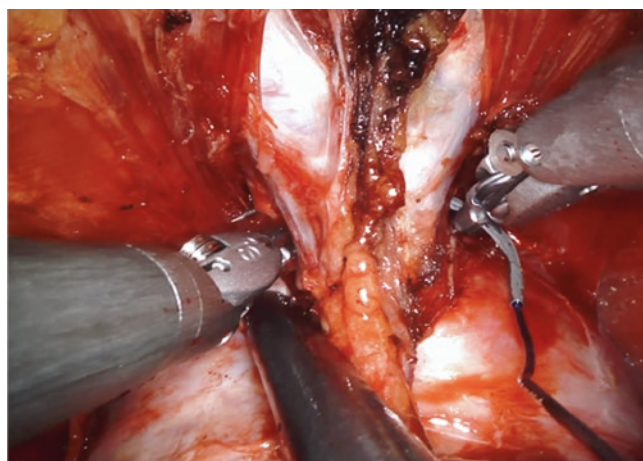


Fig. 54.9 Ligation of dorsal venous complex

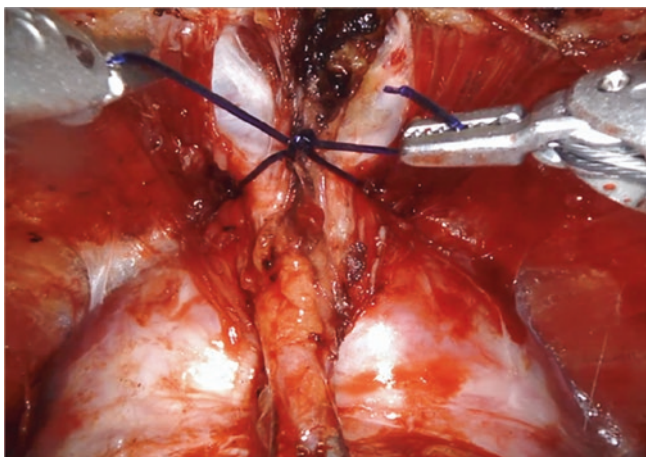


Fig. 54.10 Ligation of dorsal venous complex

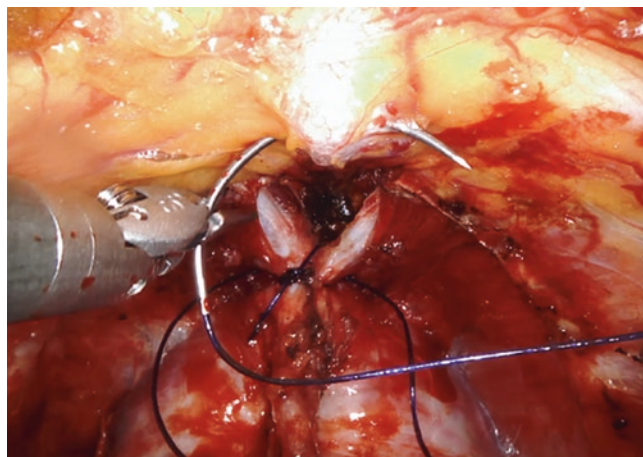


Fig. 54.11 Anterior suspension stitch

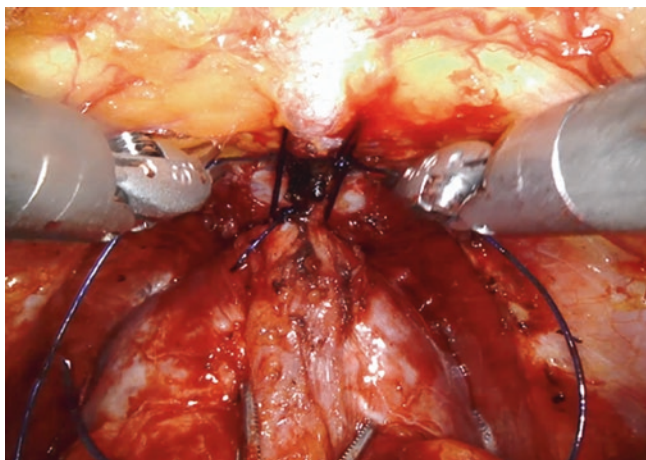


Fig. 54.12 Anterior suspension stitch

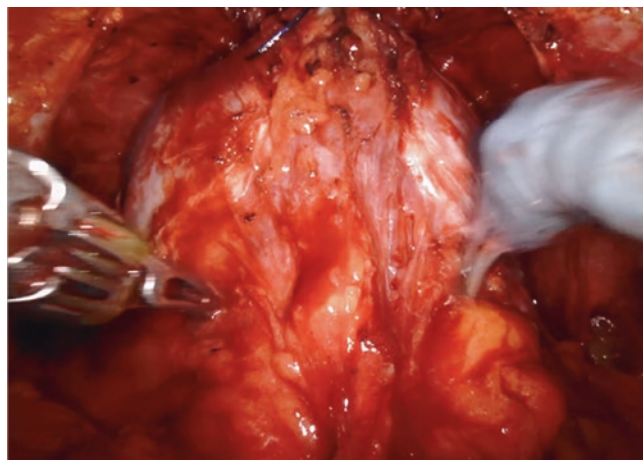


Fig. 54.13 Identifying anterior bladder neck by fat line and pinching with robotic arms

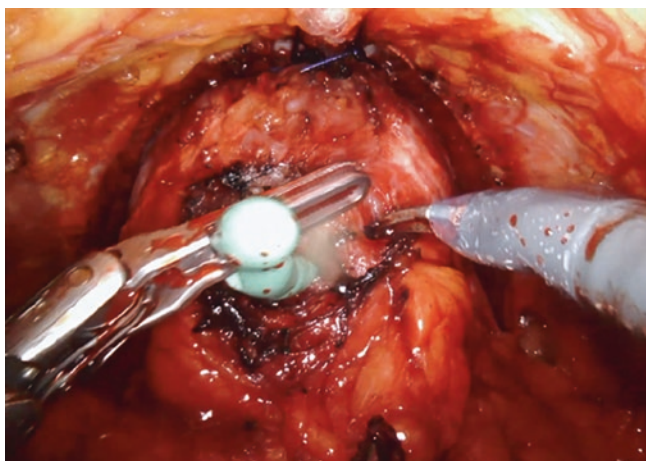


Fig. 54.14 Incision of anterior bladder neck and Foley catheter is retracted out of the bladder using the fourth arm, in an upward manner to expose the posterior bladder neck

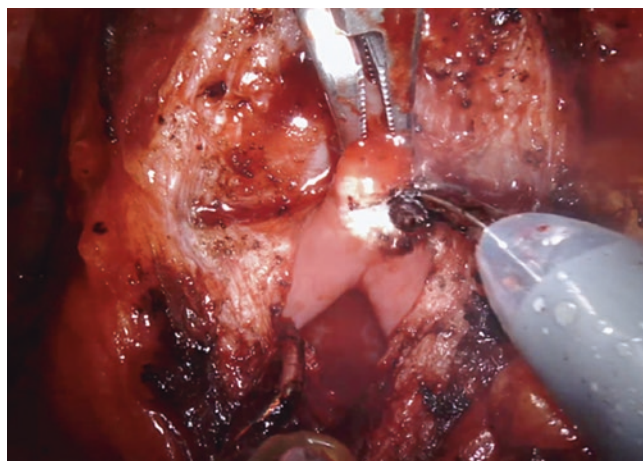


Fig. 54.15 Lip of the posterior BN is then grasped with the fourth arm and retracted upward

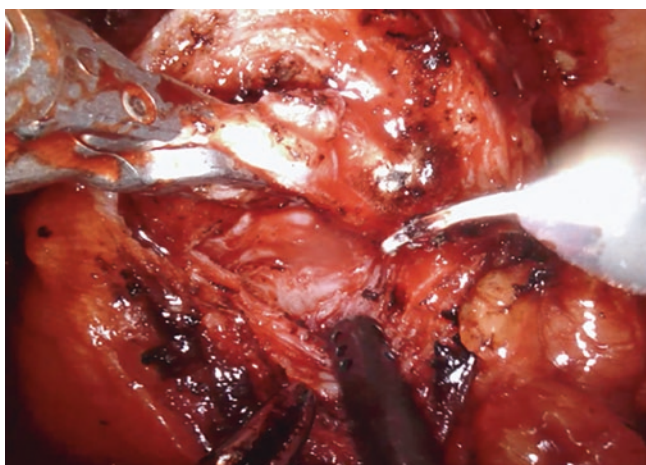


Fig. 54.16 Plane between prostate and bladder developed

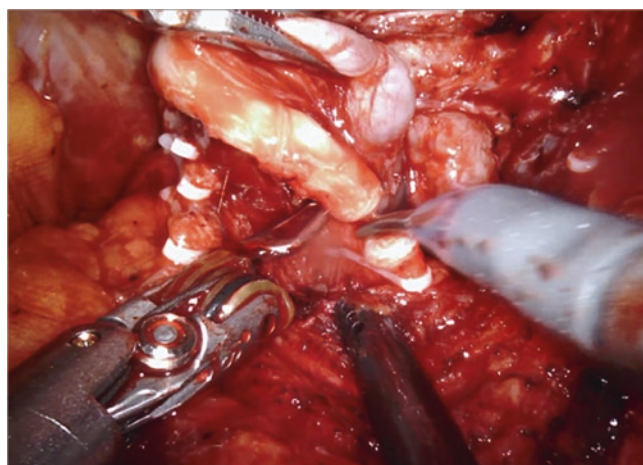


Fig. 54.17 The fourth arm is used to retract the left vas superiorly and laterally

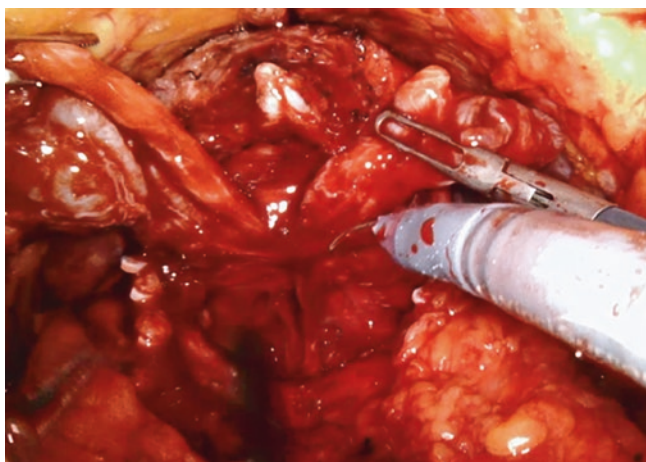


Fig. 54.18 Identification of Denonvilliers fascia

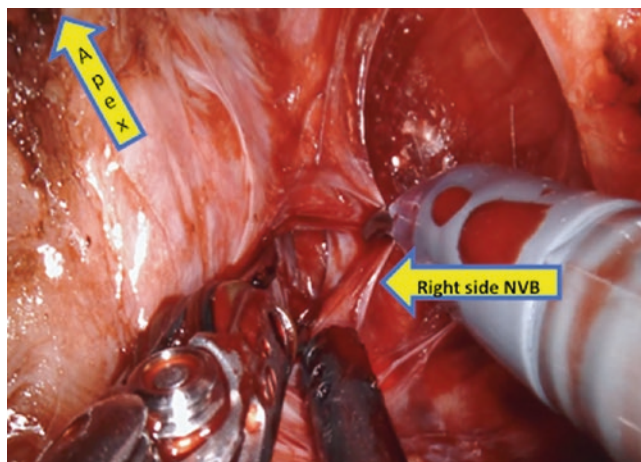


Fig. 54.19 Preservation of neuro-vascular bundle- right side

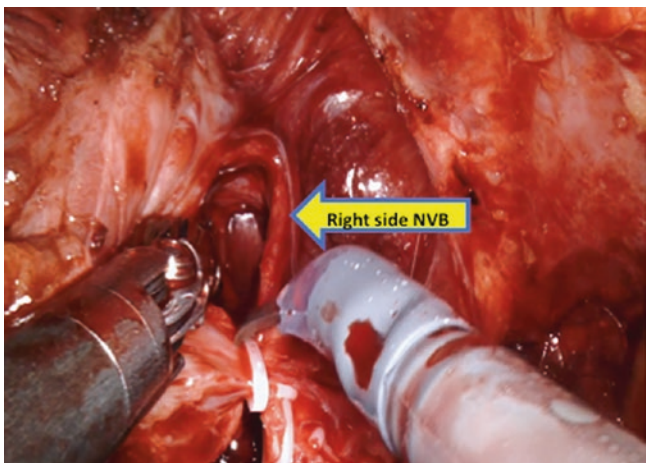


Fig. 54.20 Preservation of neuro-vascular bundle- right side

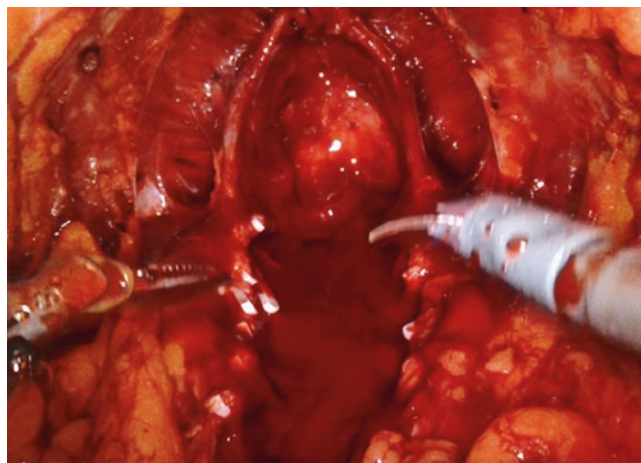


Fig. 54.21 Bilateral preserved neuro-vascular bundle

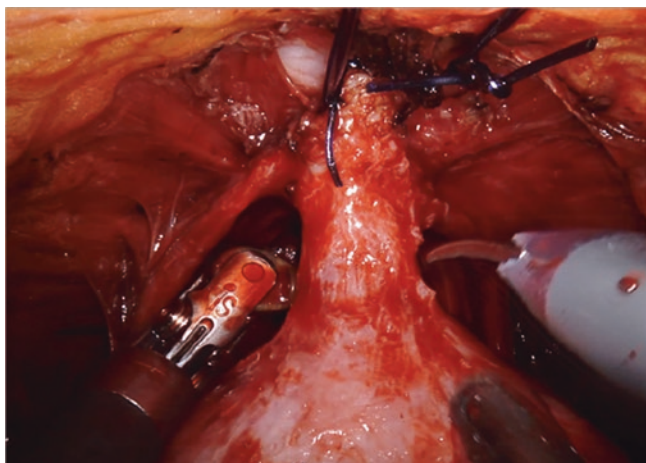


Fig. 54.22 Apical Dissection

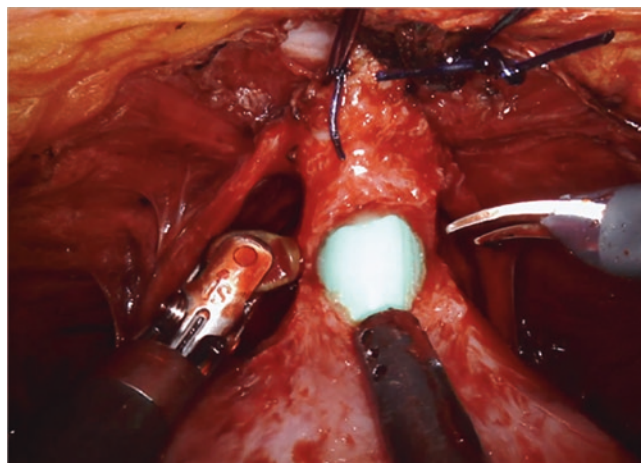


Fig. 54.23 Transection of urethra with adequate stump length

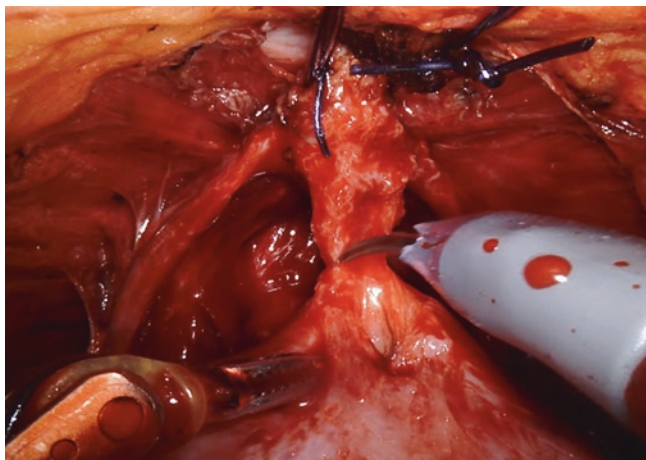


Fig. 54.24 Urethra division in progress

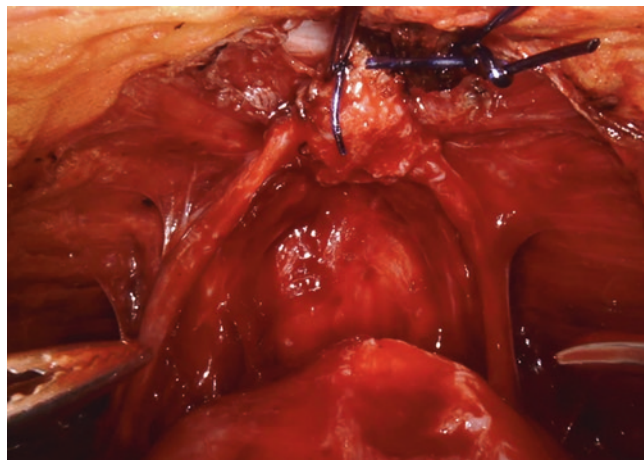


Fig. 54.25 Urethra divided at prostate apex

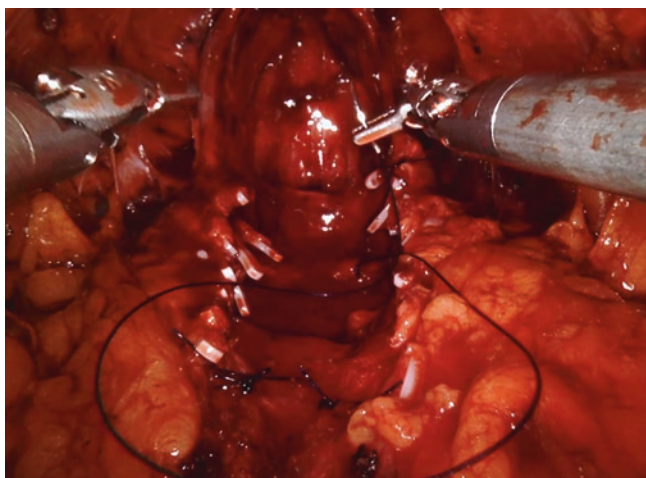


Fig. 54.26 Posterior layer reconstruction started

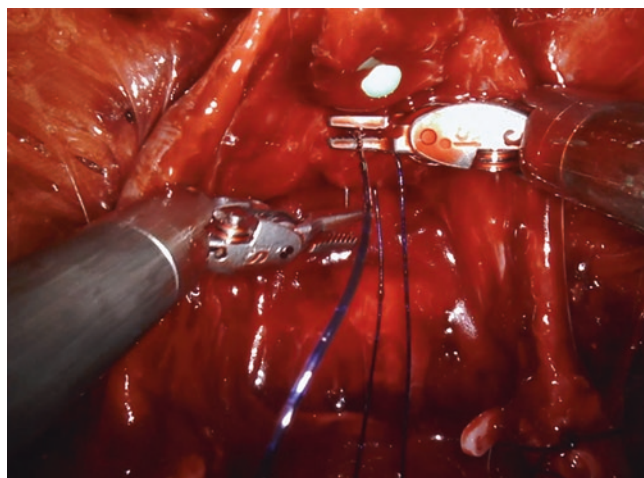


Fig. 54.27 Posterior layer reconstruction in progress

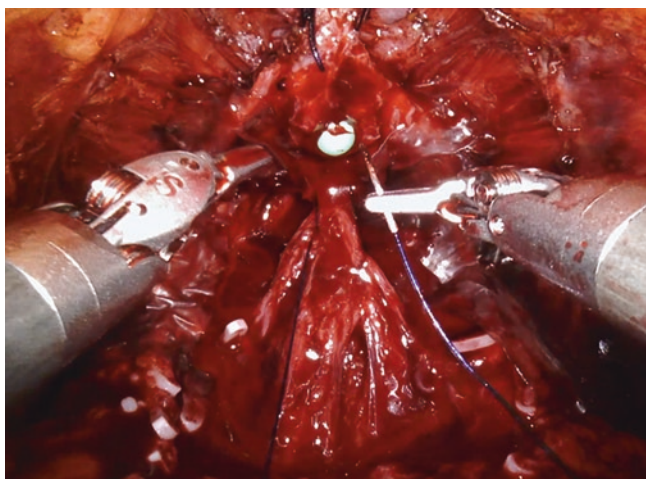


Fig. 54.28 Posterior layer reconstruction partially complete

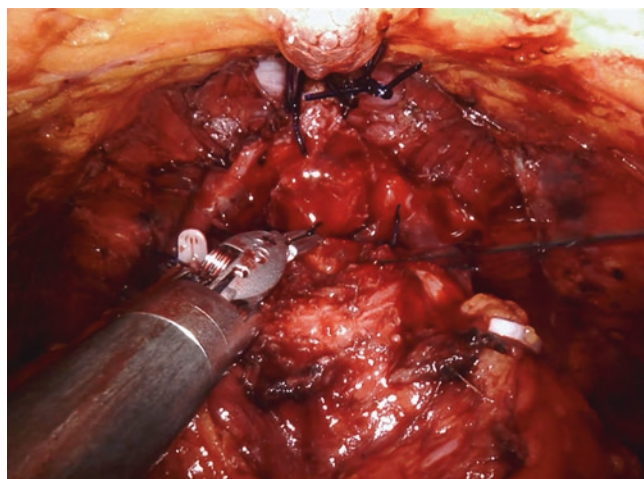


Fig. 54.29 Posterior layer reconstruction completed

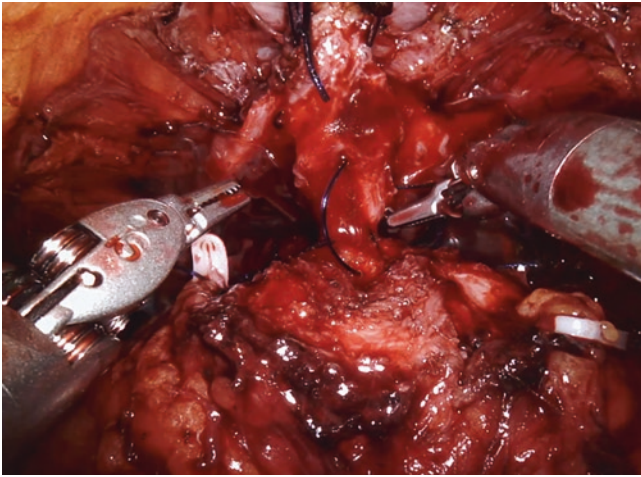


Fig. 54.30 Vesico urethral anastomosis in progress

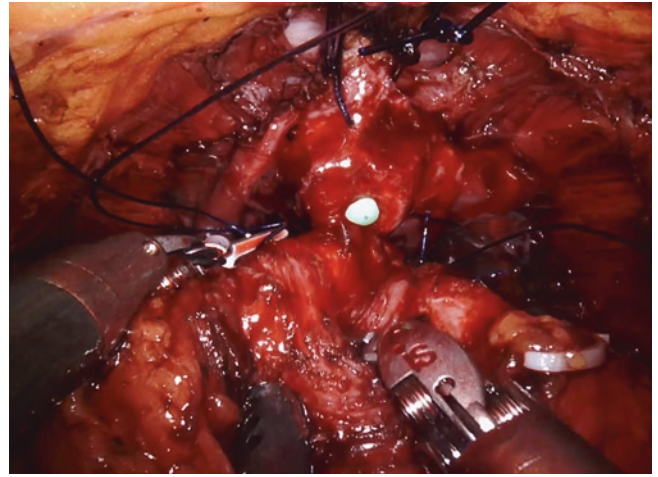


Fig. 54.31 Vesico urethral anastomosis in progress

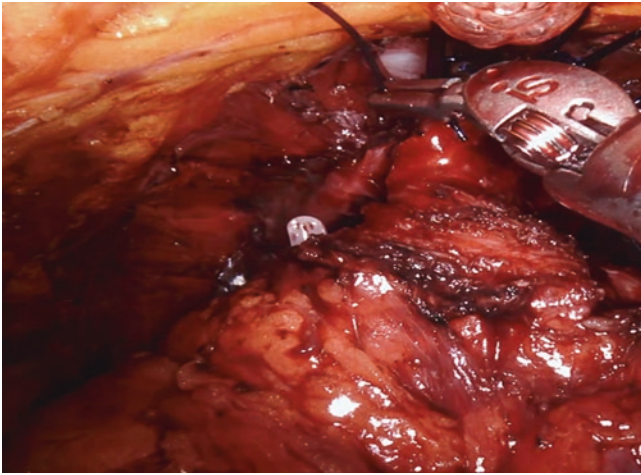


Fig. 54.32 Vesico urethral anastomosis in progress

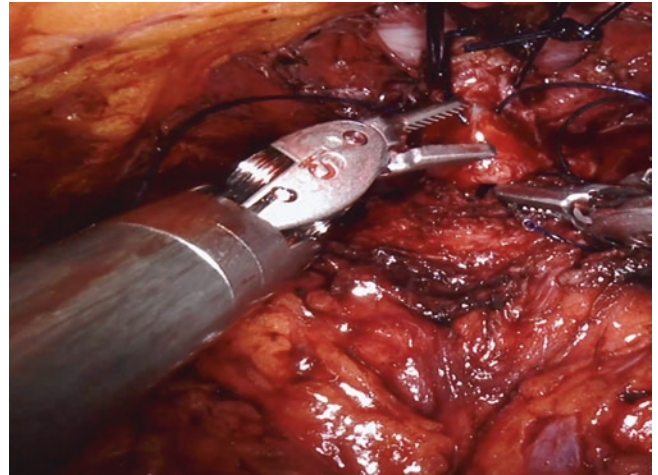


Fig. 54.33 Vesico urethral anastomosis in progress

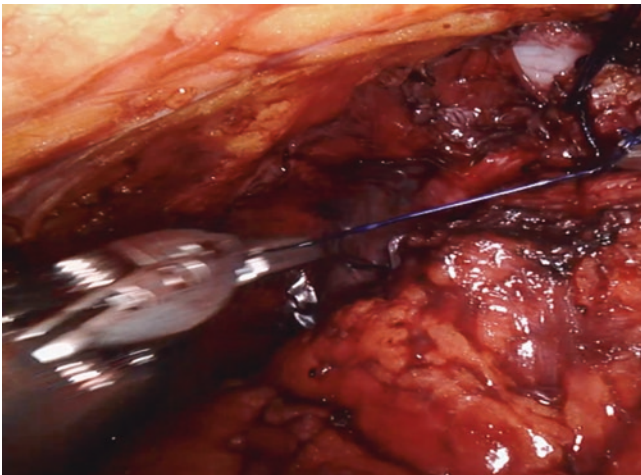


Fig. 54.34 Vesico urethral anastomosis completed

Conclusion

After one decade after the first RALP was performed, multiple large series are currently mature enough to demonstrate outcomes with at least comparable data to most experienced open centers.

It is clear that the evolution of minimally invasive surgery from standard laparoscopy to robotics has given the surgeon a great advantage over the latter, regarding magnification. However, these advantages provided rely solely on the expertise of the surgeon, team, and the manner in which he applies his surgical knowledge. As with any foray into new technology and surgical procedures, the development of technical modifications and surgical refinements are inevitable with increasing experience, explaining the role of surgical volume in ultimately improving the outcomes. During our learning experience, we developed several technical modifications that currently allow us to perform the procedure with shorter operative time, improved oncological and functional outcomes, and low overall complication rates.

References

1. Walsh PC, Donker PJ. Impotence following radical prostatectomy: insight into etiology and prevention. *J Urol.* 1982;128:492–7.
2. Gillitzer R, Thüroff JW. Technical advances in radical retropubic prostatectomy techniques for avoiding complications. Part II: vesico-urethral anastomosis and nerve-sparing prostatectomy. *BJU Int.* 2003;92:178–84.
3. Orvieto MA, Zorn KC, Gofrit ON, et al. Surgical modifications in bladder neck reconstruction and vesicourethral anastomosis during radical retropubic prostatectomy to reduce bladder neck contractures. *Can J Urol.* 2006;13:3353–7.
4. Steinberg PL, Merguerian PA, Bihrlé 3rd W, et al. The cost of learning robot-assisted prostatectomy. *Urology.* 2008;72:1068–72.
5. Binder J, Kramer W. Robotically assisted laparoscopic radical prostatectomy. *BJU Int.* 2001;87:408–10.
6. Villavicencio H, Esquena S, Palou Redorta J, et al. Robotic radical prostatectomy: overview of our learning curve. *Actas Urol Esp.* 2007;31:587–92.
7. Patel VR, Palmer KJ, Coughlin G, et al. Robot-assisted laparoscopic radical prostatectomy: perioperative outcomes of 1500 cases. *J Endourol.* 2008;22:2299–305.

Nian Zeng

55.1 Introduction

Open prostatectomy remains the technique of choice in the majority of patients with large prostate glands [1]. Advancements in laparoscopic urological expertise, especially in the management of prostatic carcinoma and the drive to apply the minimally invasive approach to treat large benign prostate glands, has led to the recent development of laparoscopic simple prostatectomy. However, there are some differences regarding surgical technique among different investigators.

Mariano et al. [2] reported their 6 year experience with laparoscopic transperitoneal prostatectomy for 60 cases with

large prostates. van Velthoven et al. [3] reported their initial experience using a laparoscopic extraperitoneal Millin's prostatectomy approach in 18 patients. As the experience of routine laparoscopic simple prostatectomy increased, robot and single port laparoscopic techniques have recently been applied to the field with promising results [4, 5]. Today, laparoscopic simple prostatectomy is considered an alternative to open surgery and this has been carried out by several groups, with encouraging initial results [3, 6–8] (Figs. 55.1, 55.2, 55.3, 55.4, 55.5, 55.6, 55.7, 55.8, 55.9, 55.10, 55.11, 55.12, 55.13, 55.14, 55.15, 55.16, 55.17, 55.18, 55.19, 55.20, 55.21, 55.22, 55.23).

N. Zeng
Chayoyang Hospital, Beijing, China
e-mail: nianzeng2006@vip.sina.com

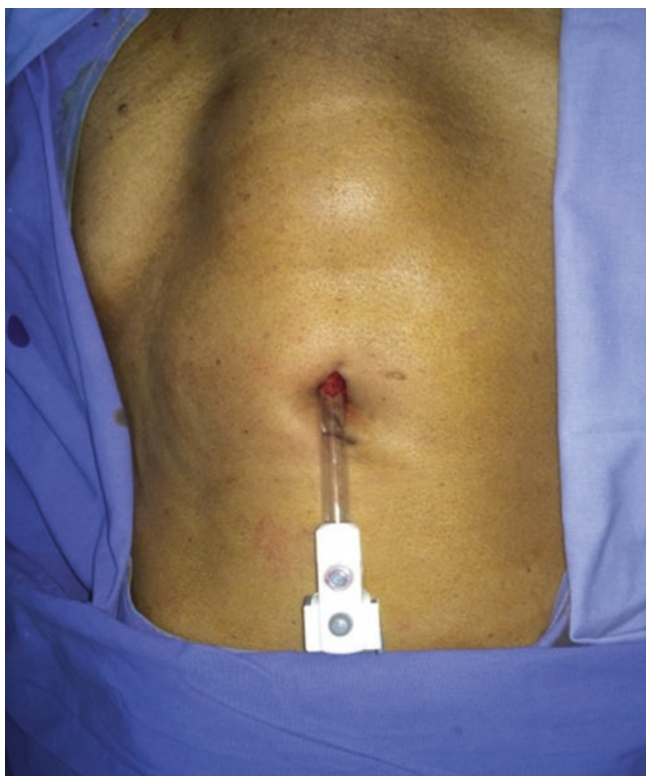

Fig. 55.1 Extraperitoneal space creation using balloon trocar

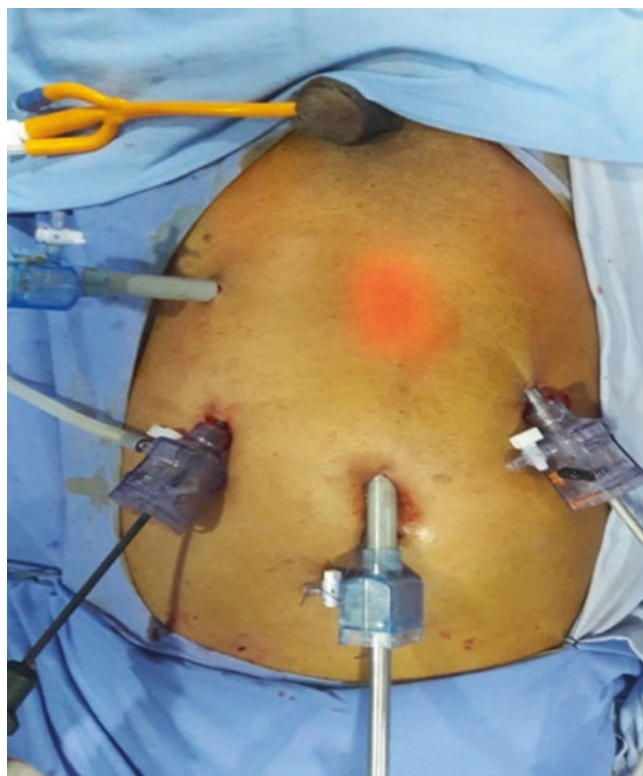

Fig. 55.2 Ports position

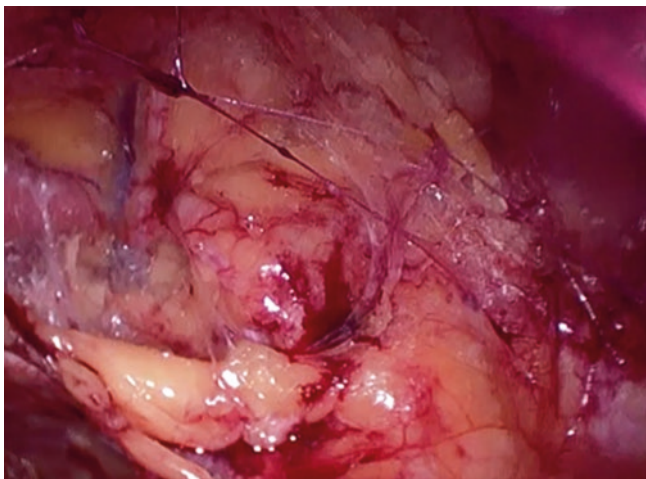


Fig. 55.3 Extraperitoneal space created by balloon inflation

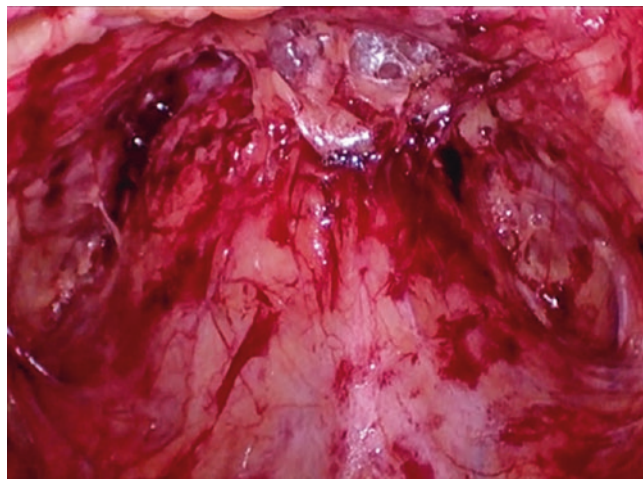


Fig. 55.4 Initial view of bladder and prostate from extraperitoneal space

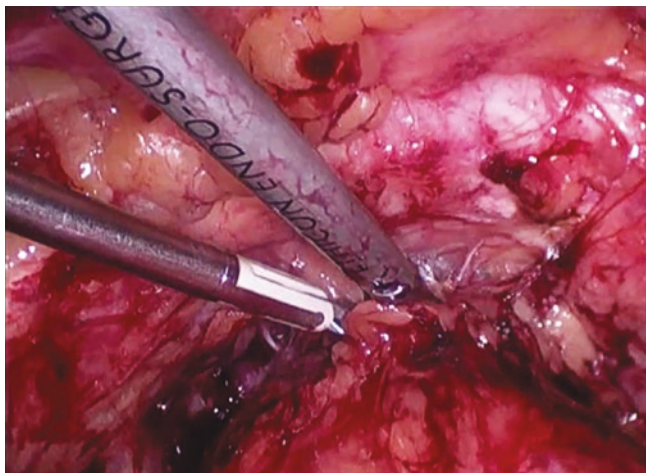


Fig. 55.5 Dorsal vein handled with ultrasonic shears

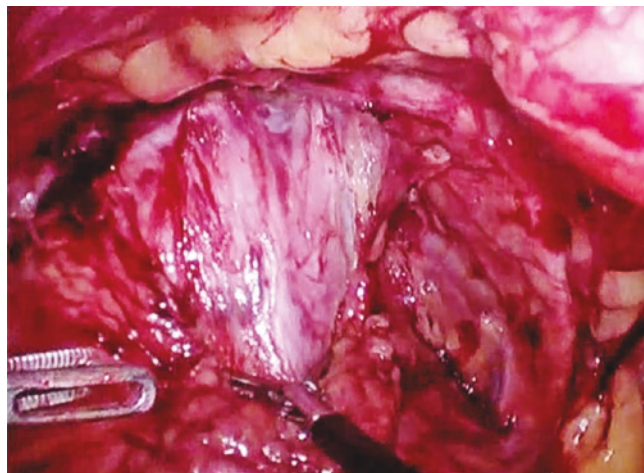


Fig. 55.6 Preprostatic fat cleared

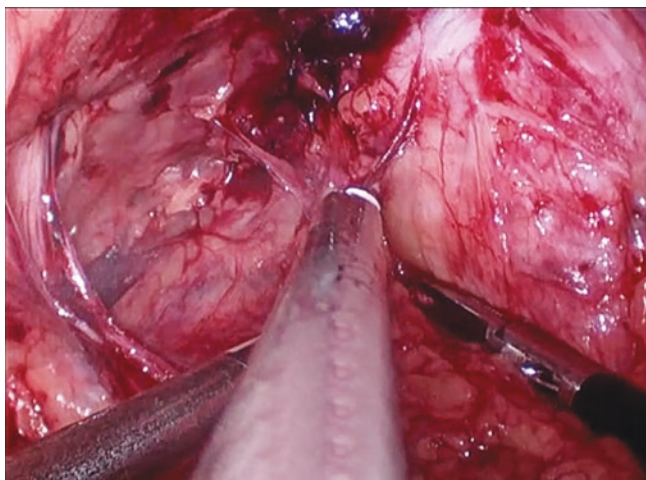


Fig. 55.7 Endopelvic fascia incised

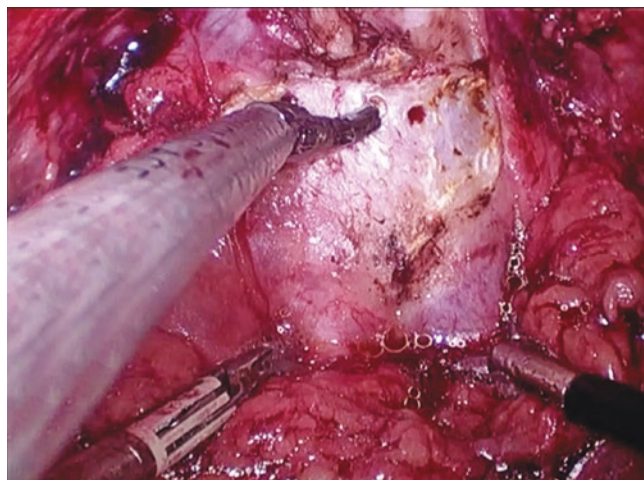


Fig. 55.8 Transverse capsulotomy with ultrasonic shears

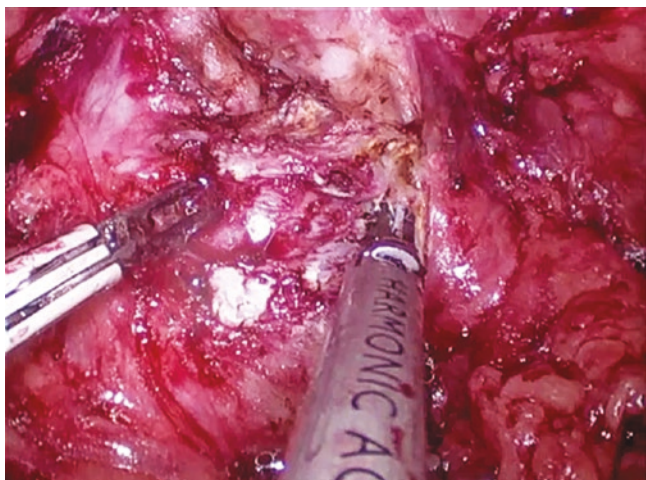


Fig. 55.9 Fascial plane developed just superficial to adenoma

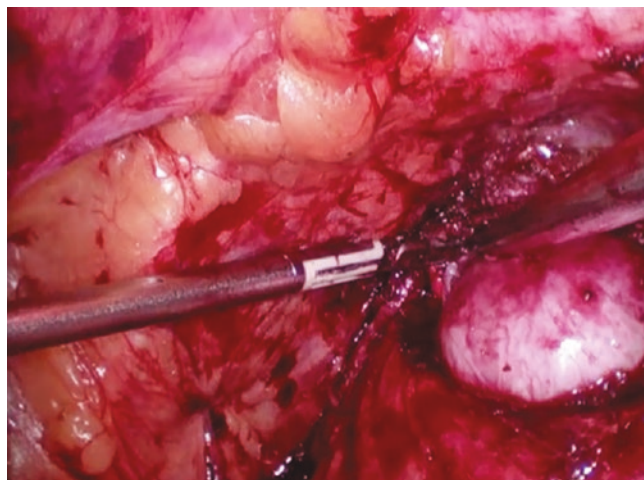


Fig. 55.10 Adenoma being cleared from the right lateral aspect of capsule

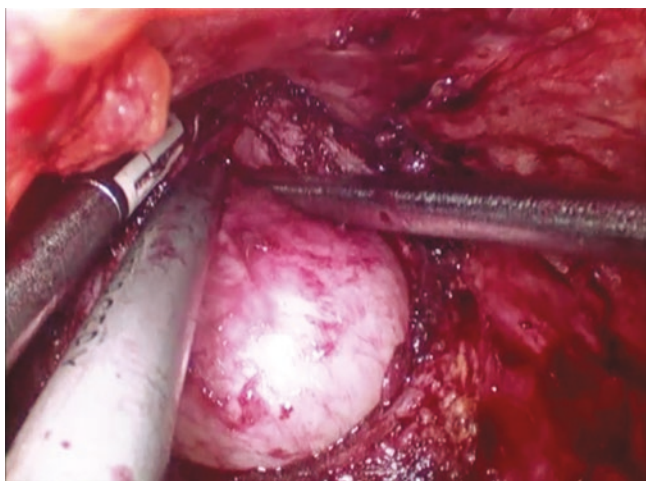


Fig. 55.11 Adenoma enucleated by blunt and sharp dissection

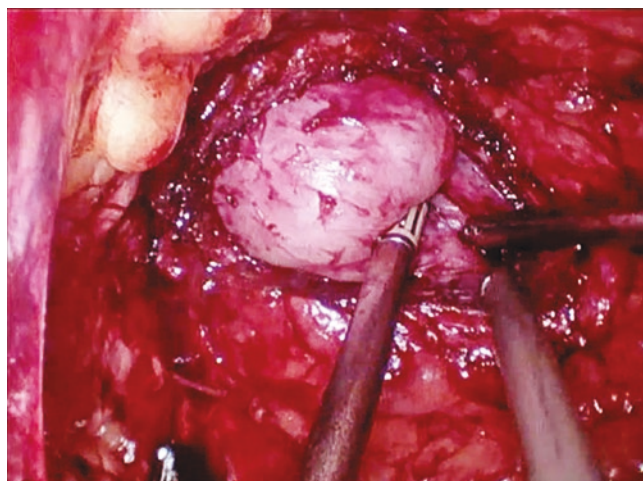


Fig. 55.12 Adenoma separated from urethra

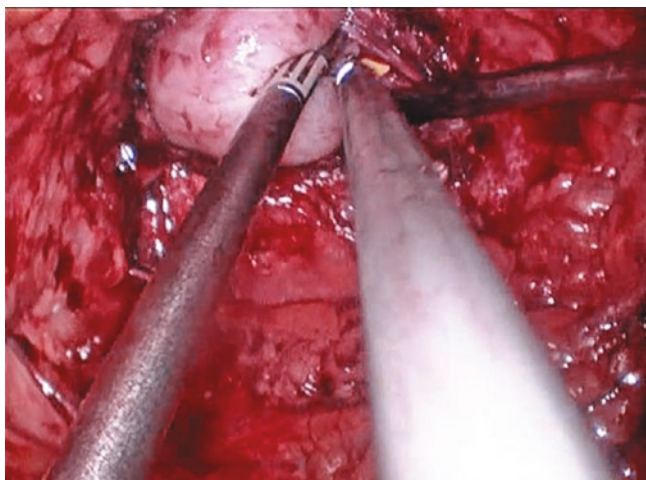


Fig. 55.13 Small rent in urethra during enucleation

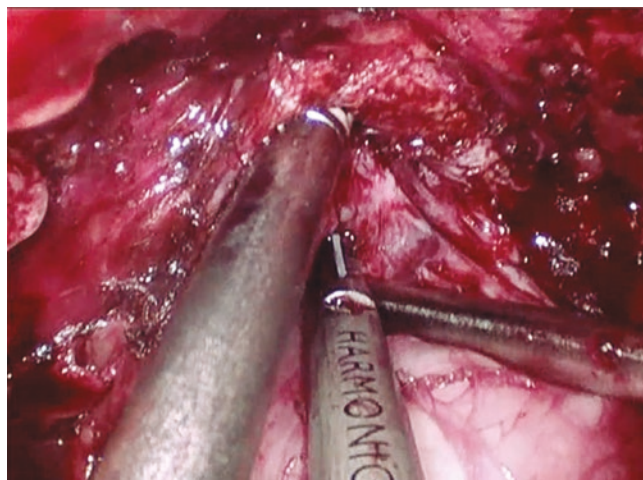


Fig. 55.14 Dissection near the prostatic apex

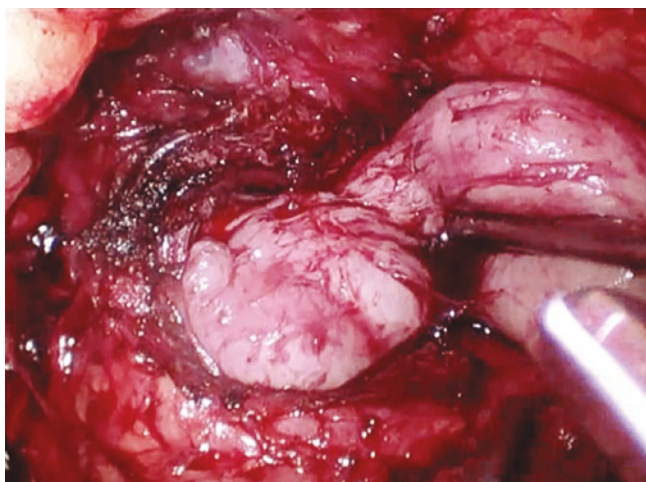


Fig. 55.15 Adenoma enucleated

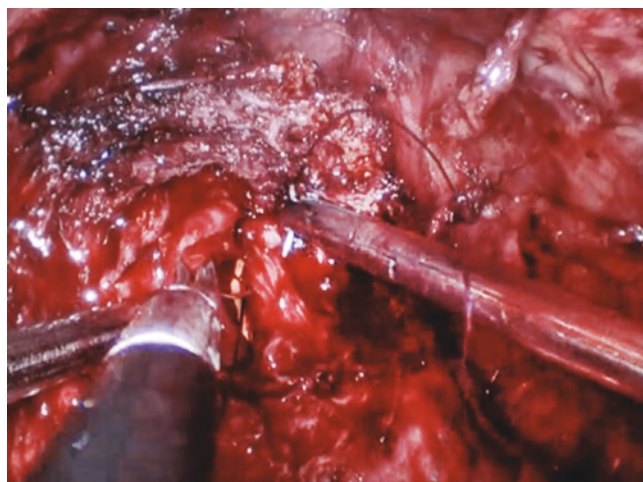


Fig. 55.16 Urethral rent being closed with 4-0 vicryl

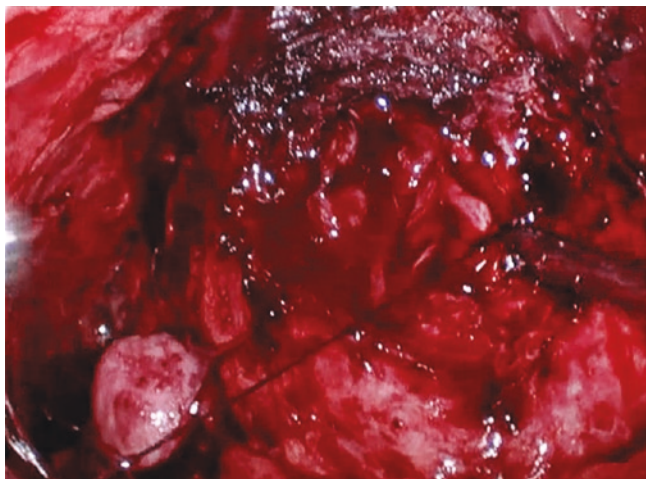


Fig. 55.17 Urethral rent closure complete

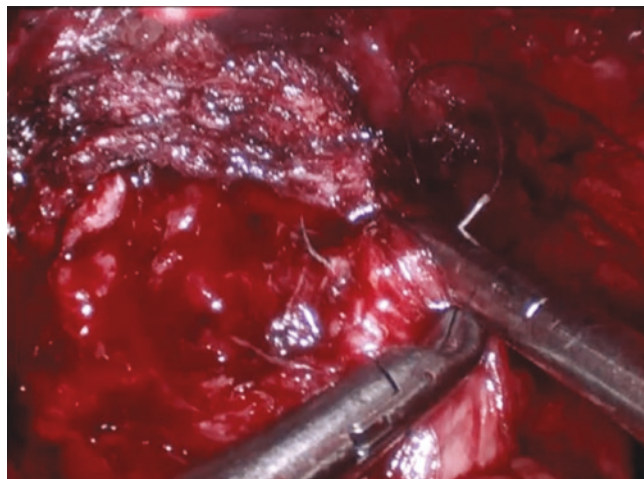


Fig. 55.18 Capsulotomy closure started on the right corner with 2-0 vicryl suture

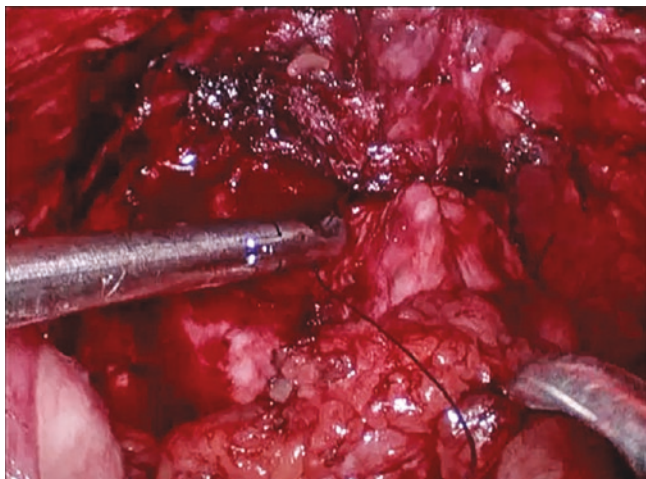


Fig. 55.19 Capsulotomy closure as continuous suture in progress

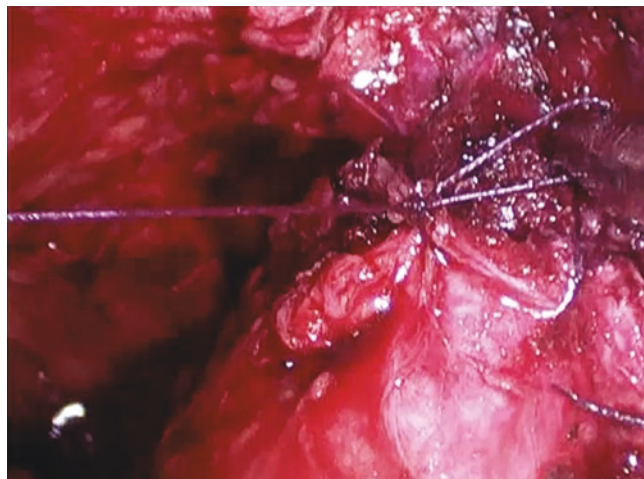


Fig. 55.20 Capsulotomy closure complete

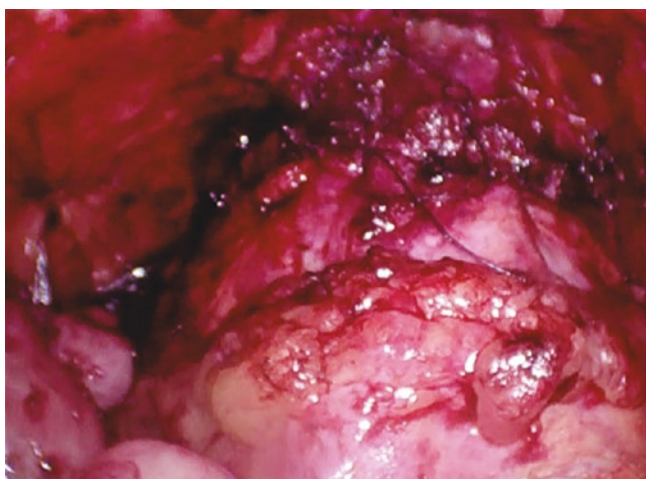


Fig. 55.21 Bladder distended (without foley balloon traction) to rule out any leak

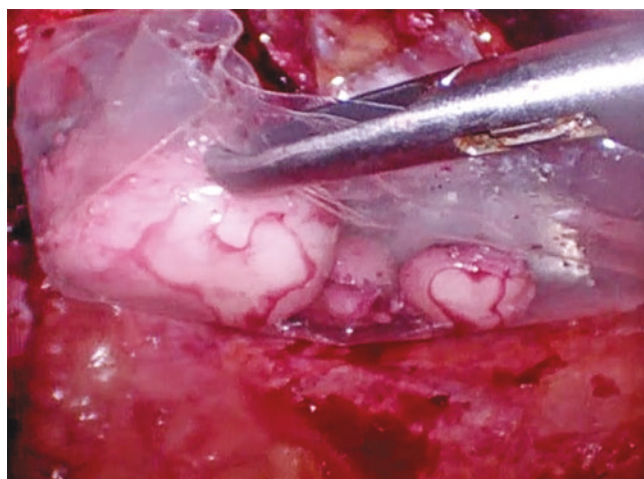


Fig. 55.22 Specimen bagged

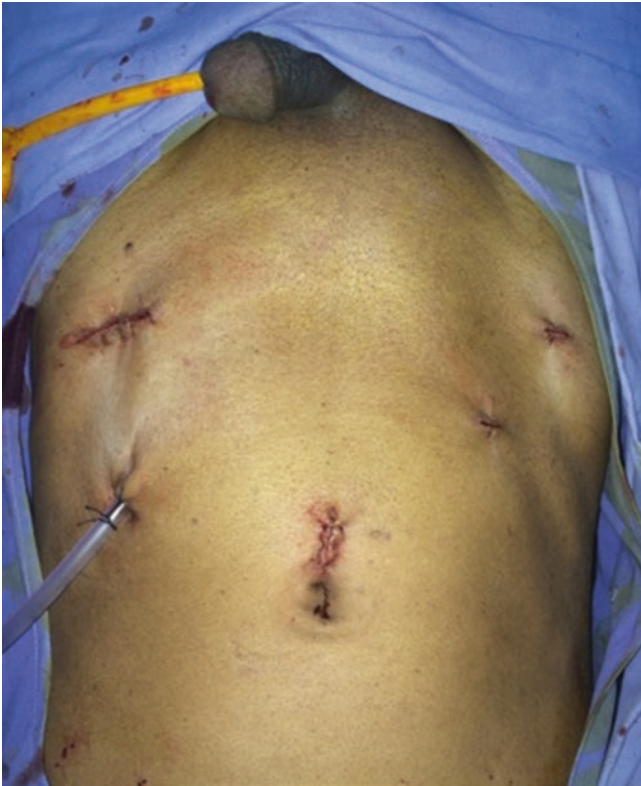

Fig. 55.23 Specimen retrieved by extending left iliac fossa port

55.2 Surgical Technique

Under general anesthesia patient is placed in a steep Trendelenburg position. A 1.5 cm midline incision just below the umbilicus is made. A balloon trocars is introduced into the extraperitoneal space and balloon is inflated to 500 ml. The inflated balloon is left in place for 3 min. Once the scope is placed through the first established trocar, the extraperitoneal space can be opened up with telescopic dissection. The other four trocars can be inserted under vision of the laparoscope. Thus, five trocars in a inverted U shape can be placed. Blunt dissection is used to clear the overlying fatty tissue. The anterior surface of the prostate capsule is then reached. The dosal vein complex is controlled by using the bipolar or vessel sealing device. A transverse incision is made over the prostatic capsule by L-hook electrocautery or harmonic scalpel. The plane of cleavage is defined between the adenoma and the capsule with careful blunt and sharp dissection using a harmonic scalpel. Having freed up the front and sides of each lateral lobe, the joined part of adenoma is incised and the anterior surface of the urethra can be seen clearly by moving the preplaced 18-Fr Foley catheter back and forth.

In turn, each lateral lobe is separated from the urethra by sharp scissors or harmonic scalpel dissection, while the rest of the adenoma is removed by either blunt or sharp dissection from the posterior aspect of the capsule. A swab is placed temporarily for haemostasis within the prostatic fossa. The integrity of the urethra is tested by bladder wash-out. If the urethra is opened inadvertently, it is closed with 3-0 polyglactin stitch. The prostatic capsule is closed with a 2-0 polyglactin running suture. A Jackson-Pratt drain is inserted, while the specimen is bagged and extracted from the suprapubic incision or by extending the portsites.

55.3 Discussion

The authors have used scissors or the harmonic scalpel to cut the connecting tissue along the plane between the adenoma and urethra, rather than blunt dissection, which might cause a tear in the urethra. A small opening could be easily closed with 3-0 polyglactin suture even if the urethra was incidentally cut. The prostatic capsule is not closed in the conventional Madigan technique. The prostatic capsule is closed in authors series using a running suture since this maneuver could not only help to prevent urinary leakage once the urethra was breached but also helps in hemostasis. Once the urethra is preserved, bladder irrigation is not needed. A haemostatic stitch may be necessary if the bleeding is

significant. It is easy to control the bleeding once the correct plane between the adenoma and capsule is identified.

Most often postoperative bladder irrigation is not required. A comparable significant improvement in the maximum urinary flow, IPSS symptom score and QOL were achieved in over 50 cases. There was no significant difference regarding erectile function before and after surgery, while all patients who regained sexual intercourse had antegrade ejaculation. The results are very encouraging, though more experience is needed.

The limitation for the mucosa preserving technique is that it is only indicated for prostates without a large median lobe. Hence cystoscopy is essential prior to this procedure, to identify the presence of a large median lobe. This is important as it may be difficult to enucleate the median lobe completely by this technique. Other modalities of treatment should be considered once a large median lobe is found.

55.4 Conclusion

Laparoscopic simple prostatectomy with prostatic urethral preservation is feasible in larger prostates without a median lobe. The advantage of the technique is that postoperative bladder irrigation can be avoided and antegrade ejaculation is preserved.

References

1. Oesterling JE. Retropubic and suprapubic prostatectomy. In: Walsh PC, Retik AB, Vaughan Jr ED, Wein AJ, editors. *Campbell's urology*, vol. 2. 7th ed. Philadelphia: W.B. Saunders Co.; 1998. p. 1529–40 [Chapter 50].
2. Mariano MB, Tefilli MV, Graziottin TM, et al. Laparoscopic prostatectomy for benign prostatic hyperplasia—a six-year experience. *Eur Urol*. 2006;49:127–32.
3. van Velthoven R, Peltier A, Laguna MP, Piechaud T. Laparoscopic extraperitoneal adenomectomy (Millin): pilot study on feasibility. *Eur Urol*. 2004;45:103–9.
4. Sotelo R, Clavijo R, Carmona O, et al. Robotic simple prostatectomy. *J Urol*. 2008;179:513–5.
5. Desai MM, Aron M, Canes D, et al. Single-port transvesical simple prostatectomy: initial clinical report. *Urology*. 2008;72:960–5.
6. Nadler RB, Blunt Jr LW, User HM, Vallancien G. Preperitoneal laparoscopic simple prostatectomy. *Urology*. 2004;63:778–9.
7. Rehman J, Khan SA, Sukkariéh T, et al. Extraperitoneal laparoscopic prostatectomy (Adenomectomy) for obstructing benign prostatic hyperplasia: transvesical and transcapsular (Millin) techniques. *J Endourol*. 2005;19:491–6.
8. Rey D, Ducarme G, Hoepffner JL, Staerman F. Laparoscopic adenectomy: a novel technique for managing benign prostatic hyperplasia. *BJU Int*. 2005;95:676–8.

Manickam Ramalingam and Kallappan Senthil

56.1 Introduction

Symptomatic benign conditions of seminal vesicle (lesions like cysts which need intervention) can be managed laparoscopically because the vision is better and the access is easier than in open surgery [1, 2].

56.2 Indications

Large seminal vesical cyst with voiding difficulty.

56.3 Surgical Technique

56.3.1 Patient Preparation

Bowel preparation is mandatory. Preliminary cystoscopy and ureteric catheterization is useful in case of large seminal vesicle cyst as it helps in avoiding injury to the ureter. Seminal vesicle is approached transperitoneally.

A supraumbilical camera port, two ports in the midclavicular line at the level of umbilicus for hand instruments and a flank port for retraction/suction are used. The bulge of the seminal vesicle cyst is easily seen through the peritoneum. The first step is to incise the peritoneum over the rectovesical pouch. The flank port can be used to retract the bowel cephalad. The ipsilateral vas is a good guide to locate the seminal vesicle. A blunt dissection of the seminal vesicle cyst is done and encountered small vessels can be tackled with either ultracision or bipolar cautery. If the cyst is very large it can be aspirated for an easier dissection. The cyst is disconnected from the ejaculatory duct and is retrieved using an endo-catch bag.

Thorough irrigation and suction is done at the end.

56.4 Comment

Non malignant seminal vesicle conditions can be dealt by laparoscopy with minimal morbidity.

M. Ramalingam (✉)
PSG Hospitals,
Coimbatore, India
e-mail: uroram@yahoo.com

K. Senthil, MCh (Urol, FRCS)
Urology Clinic, Gowtham Annexe, Coimbatore, India
e-mail: senthilsatya@hotmail.com

56.5 Laparoscopic Excision of Seminal Vesicle Cyst

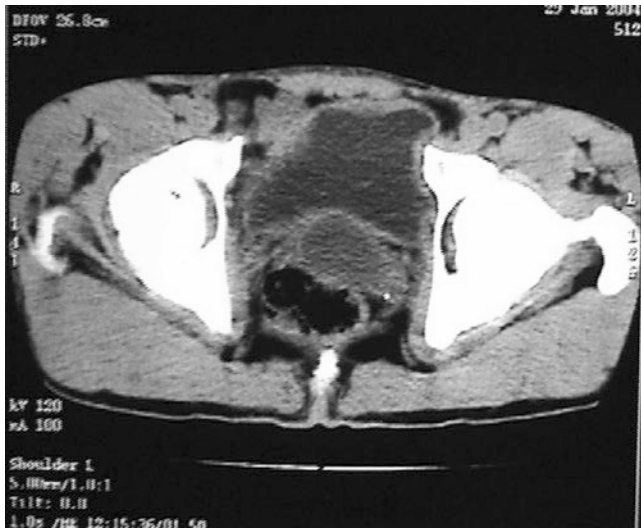

Fig. 56.1 Image showing seminal vesicle cyst

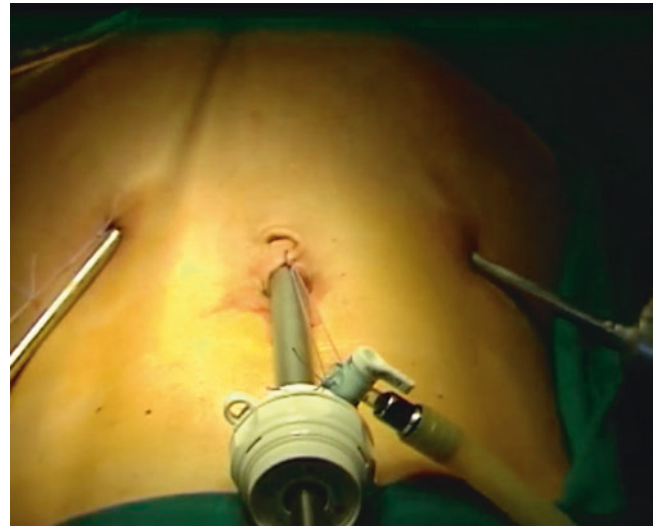


Fig. 56.2 Ports position

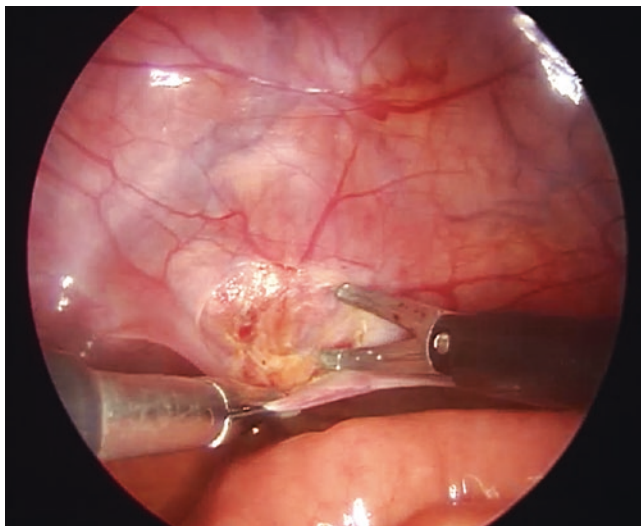


Fig. 56.3 Peritoneotomy and dissection posterior to bladder started

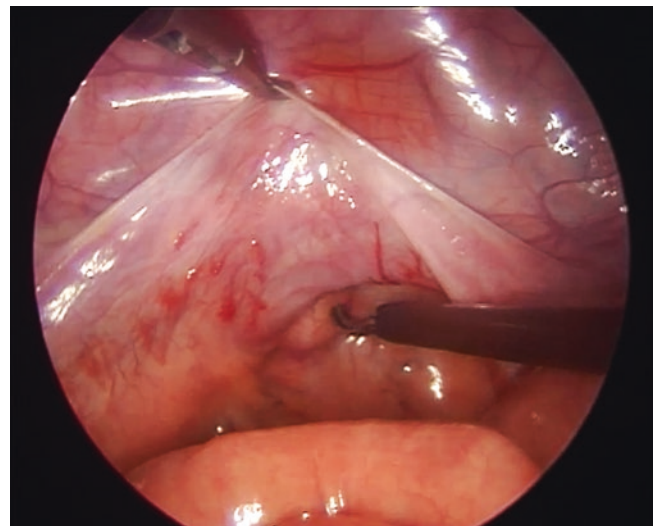


Fig. 56.4 Seminal vesicle cyst seen

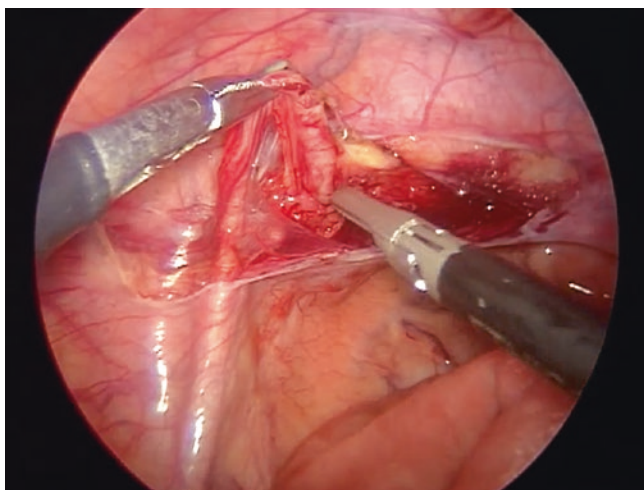


Fig. 56.5 Left vas being dissected towards the seminal vesicle

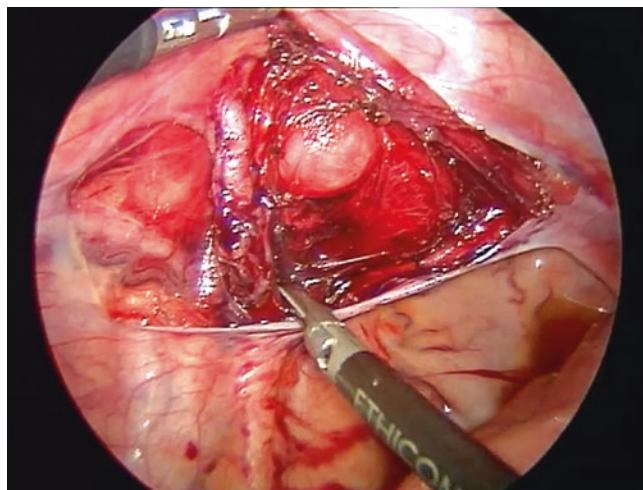


Fig. 56.6 Seminal vesicle with cyst being dissected

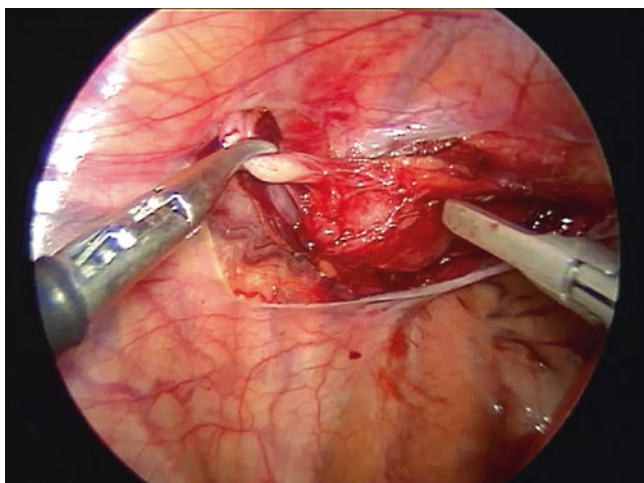


Fig. 56.7 Seminal vesicle with cyst being dissected along the vas

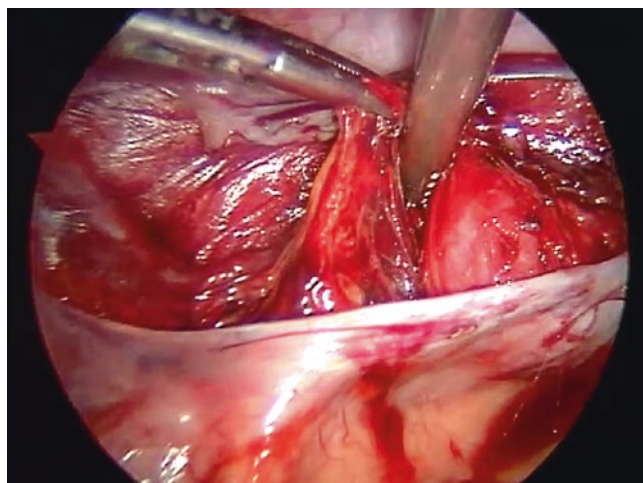


Fig. 56.8 Seminal vesicle pedicle being dissected

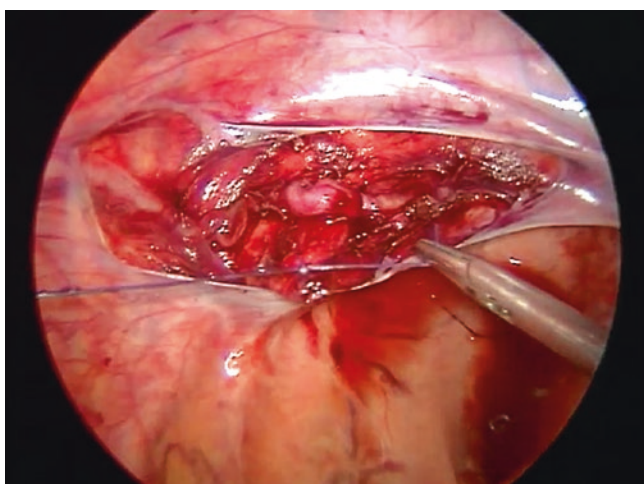


Fig. 56.9 Seminal vesicle pedicle ligated

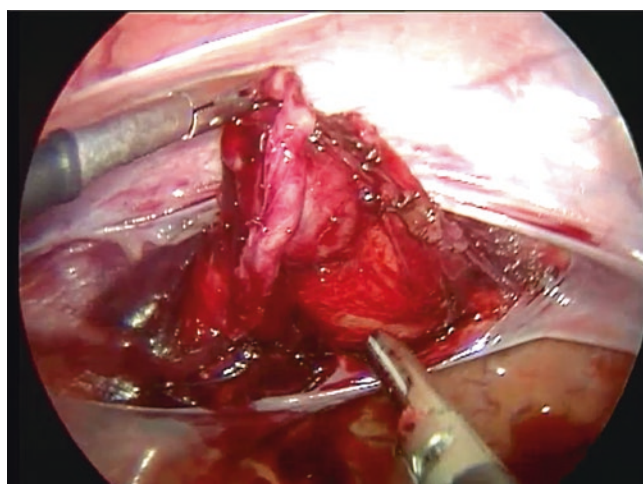


Fig. 56.10 Cyst being dissected all around

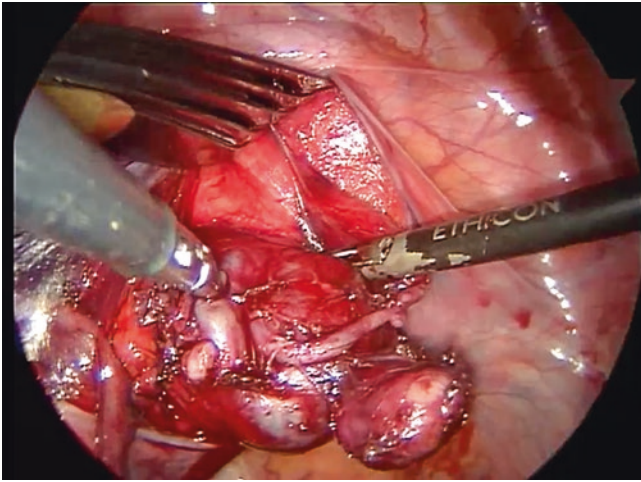


Fig. 56.11 Cyst being dissected anteriorly

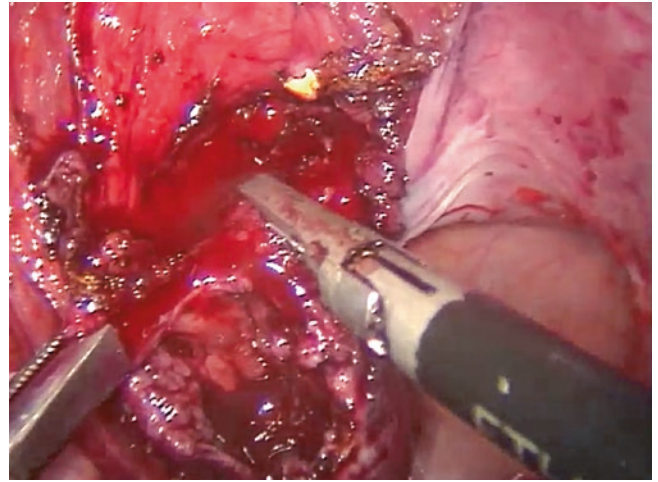


Fig. 56.12 Cyst wall being dissected from rectum

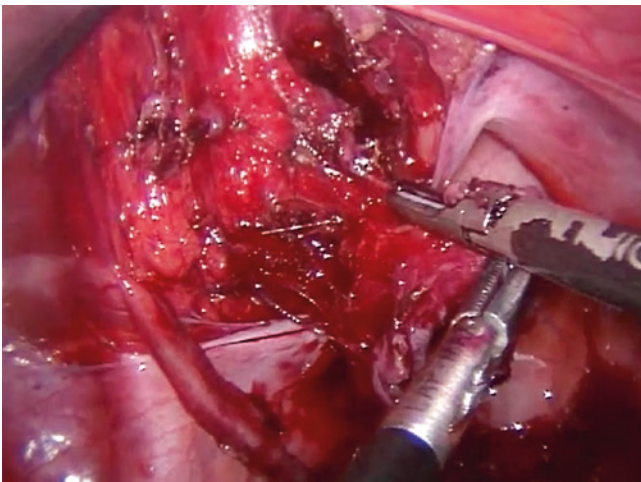


Fig. 56.13 Cyst wall detachment in progress

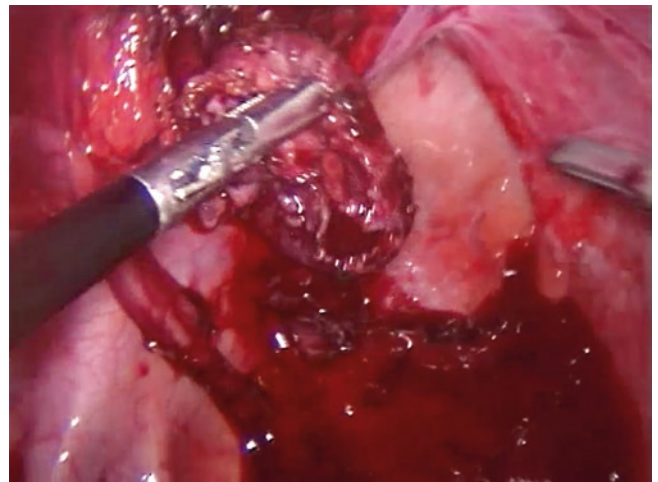


Fig. 56.14 Cyst wall separation complete

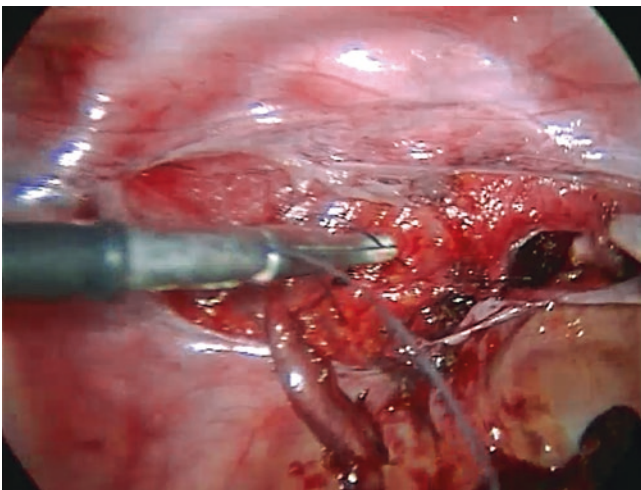


Fig. 56.15 Completed excision

References

1. Carmignani G, Gallucci M, Puppo P, et al. Video laparoscopic excision of a seminal vesicle cyst associated with ipsilateral renal agenesis. J Urol. 1995;153:439–439.
2. Ramalingam M, Senthil K, Selvarajan K, Pai MG. Laparoscopic excision of seminal vesicle cyst (Abstract). J Endourol. 2004; 18:A197.

Part VI

Reconsturive Procedure of the Undescended Testis

K. Selvarajan and Kallappan Senthil

57.1 Introduction

In a patient with undescended testis, a thorough clinical examination will reveal that the testis is either palpable or impalpable. In cases of clinically palpable testis at groin, though open orchiopexy is the choice, laparoscopic mobilization of gonadal vessels may be easier, due to better visibility in many instances. When testis is clinically impalpable, the choice of investigation is diagnostic laparoscopy [1, 2, 4]. Accuracy of laparoscopy in determining the site of intra abdominal testis is very good. Further it determines the next course of action as to how to proceed. The decision is taken based on the findings on laparoscopy [3, 5, 6].

- 2 For high intra abdominal testis
 - (a) Single stage orchiopexy.
or
 - (b) Two stage orchiopexy.
 - Ist stage – Ligation of gonadal vessels.
 - IInd stage – (8–12 weeks later) Division of gonadal vessels and mobilization based on artery to vas.
- 3 Excision of testis if it is very small.
- 4 Exploration of inguinal canal if gonadal vessels and vas are entering into internal ring.
- 5 For inguinal testis, either exploration of inguinal canal or laparoscopic mobilization can be done.

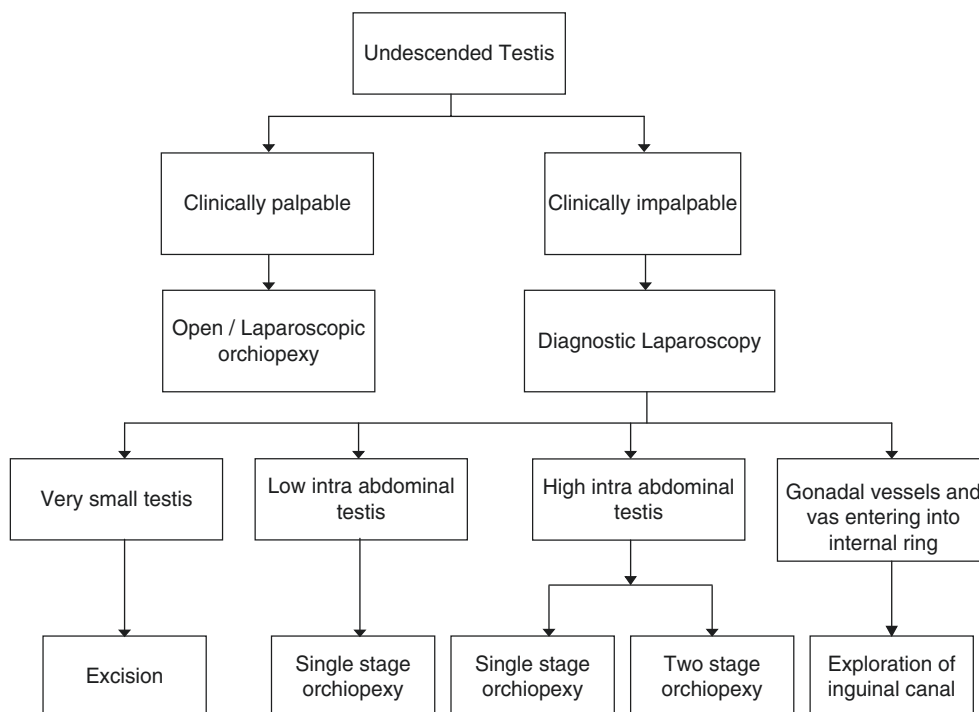
57.2 Surgical Technique

- 1 For low intra abdominal testis:
Single stage orchiopexy with mobilization of vas and gonadal vessels.

K. Selvarajan, MCh
Paediatric Surgery, K.G. Hospital and Postgraduate Institute,
Coimbatore, India

K. Senthil, MCh (Urol, FRCS) (✉)
Urology clinic, Gowtham annexe, Coimbatore, India
e-mail: senthilsatya@hotmail.com

Algorithm for management of undescended testis



Anesthesia – GA

Position of the patient – Head down

Operation Room set up (Fig. 57.1):

S Surgeon

A Assistant (Camera)

N Nurse

M Monitor

(b) Through the scrotal incision a haemostat is inserted.

(c) Under the guidance of laparoscope an instrument is introduced through the inguinal canal into the scrotum. An incision is made in the scrotum over the instrument. This instrument guides a clamp from below into the peritoneum to bring down the testis.

57.2.1 Ports Position

Figure 57.2 Left side orchiopexy

Figure 57.3 Right side orchiopexy

Figure 57.4 Bilateral orchiopexy

A Camera port

B and C Working ports

The mobilised testis is brought down through a tract which is created by one of the following methods.

Methods

(a) Through the scrotal incision a trocar (10 or 12 mm) is introduced and manipulated into the inguinal canal.

57.3 Conclusion

Laparoscopy is the first step in localizing a non palpable testis or proving its absence. The testis found in inguinal canal on laparoscopic examination needs inguinal exploration or laparoscopic mobilization based on the surgeons' choice. Single stage orchiopexy for low intra abdominal testis and two stage orchiopexy for high intra abdominal testis give good results. Bilateral undescended testes is also dealt laparoscopically on the same principles as unilateral undescended testis with distinct advantages of no additional incision or ports.

57.3.1 Single Stage Laparoscopic Orchiopexy

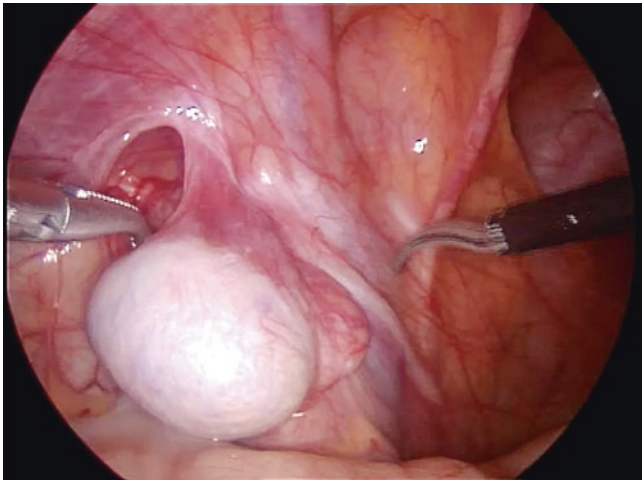


Fig 57.1 Initial view showing left testis at internal ring level. Gonadal vessels and vas seen

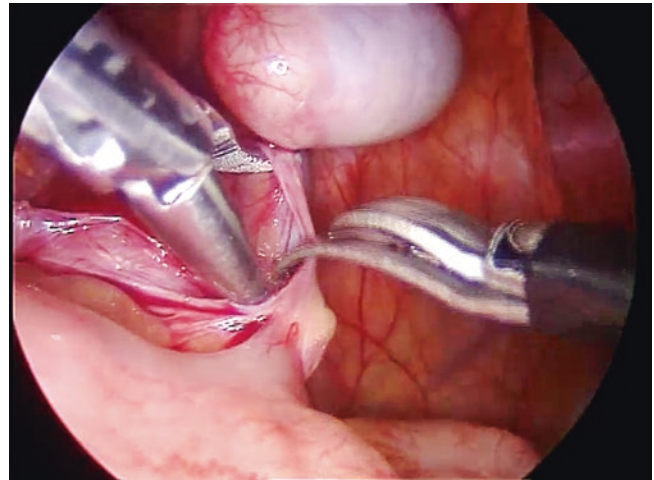


Fig 57.2 Sigmoid mobilised medially

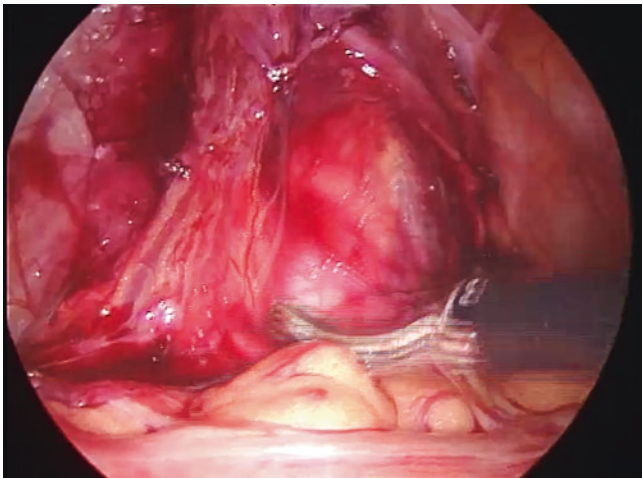


Fig 57.3 Peritoneum over gonadal vessels dissected

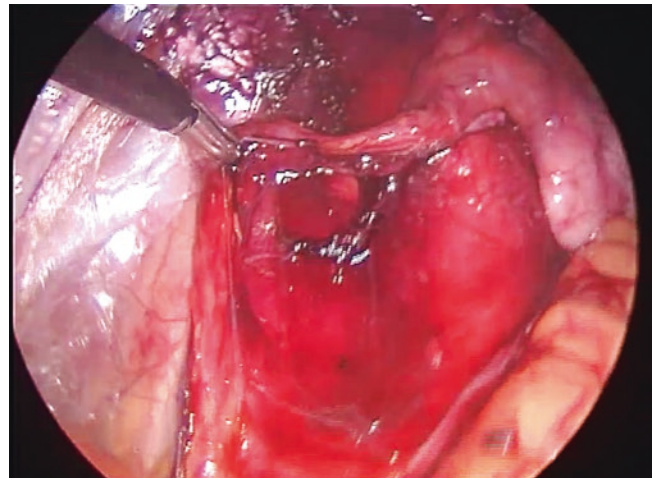


Fig 57.4 Gonadal vessels and vas mobilised

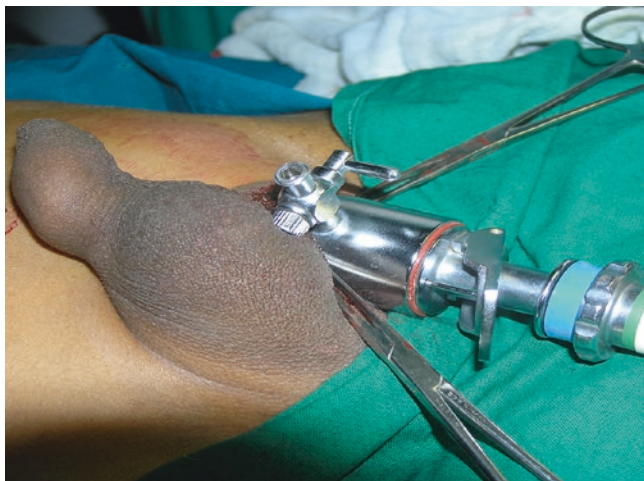


Fig 57.5 Port inserted through scrotum for delivering testis

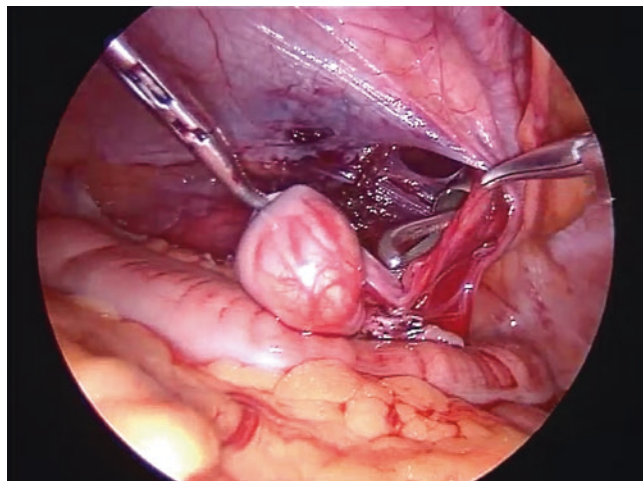


Fig 57.6 Testis grasped with right angled forceps passed up through scrotal port

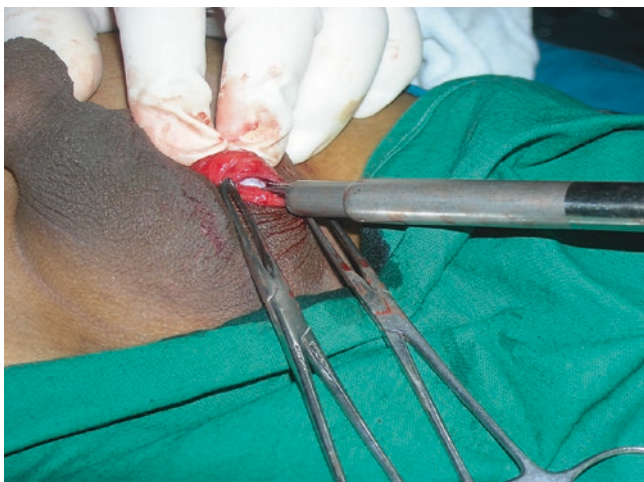

Fig 57.7 Testis delivered out through the scrotum with grasper

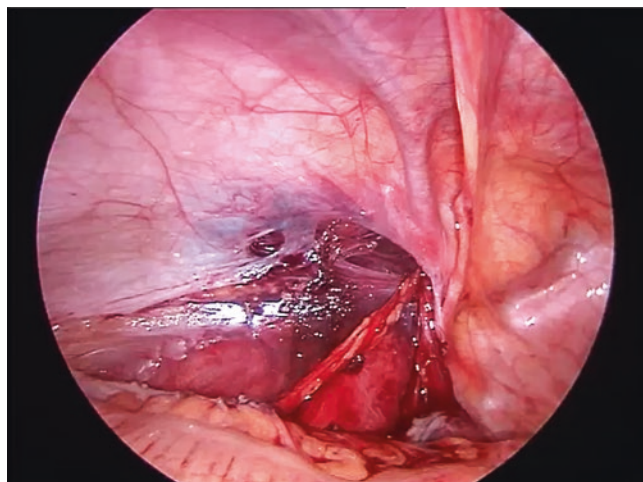


Fig 57.8 Intra peritoneal view after testis delivered out

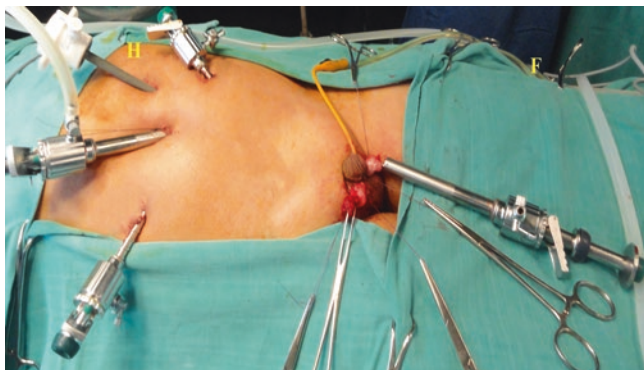

Fig. 57.9 Port position for bilateral orchidopexy. Both testes delivered out through the scrotum

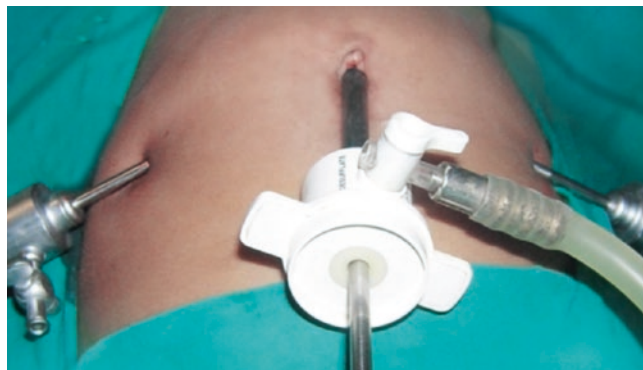

Fig. 57.10 Ports position

57.3.2 Stage 1 Fowlers

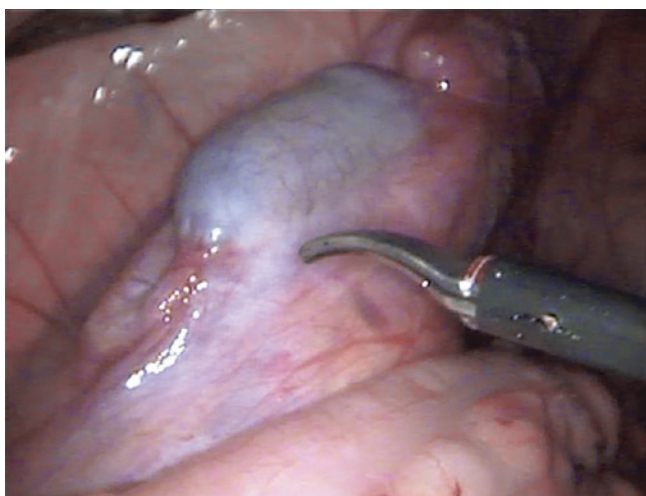

Fig. 57.11 Intraabdominal testis (*right*) seen at pelvic brim level

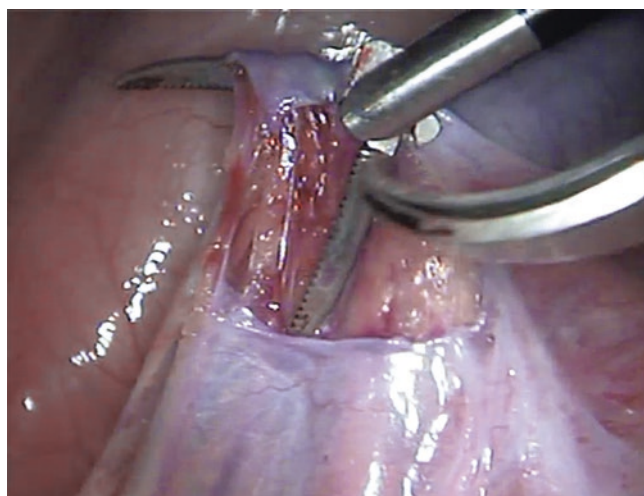


Fig. 57.12 Peritoneal incision proximal to testis, over the gonadal vessels

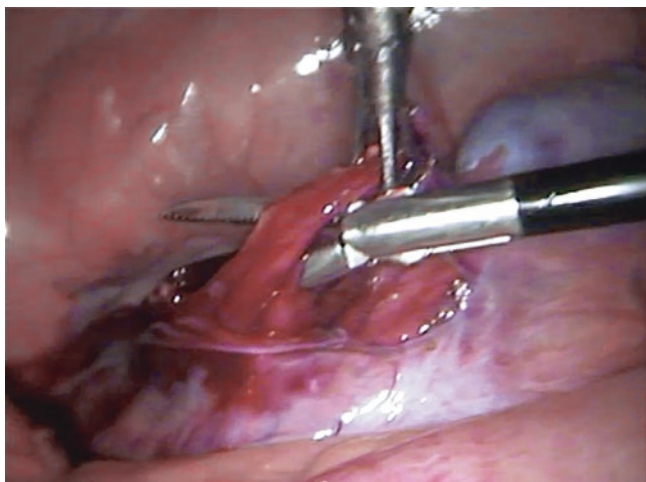


Fig. 57.13 Gonadal vessels being dissected

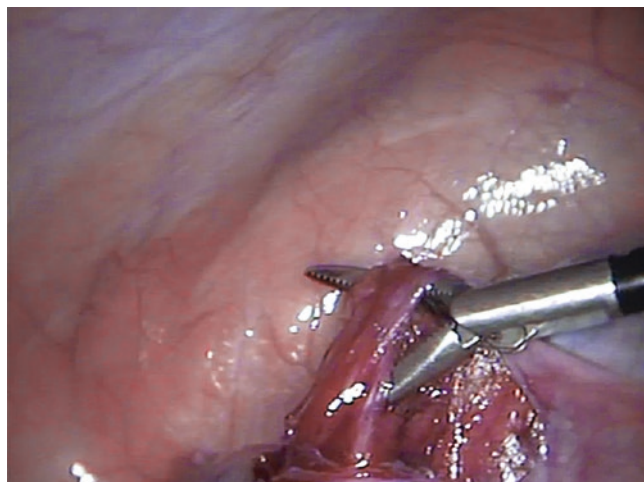


Fig 57.14 Gonadal vessels separated

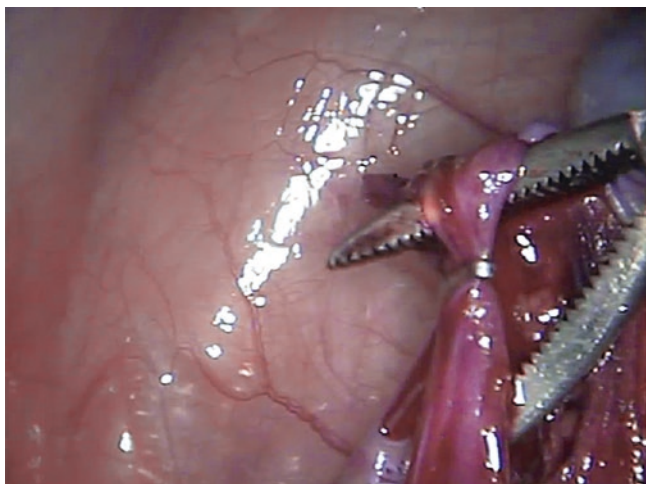

Fig. 57.15 Gonadal vessels clipped

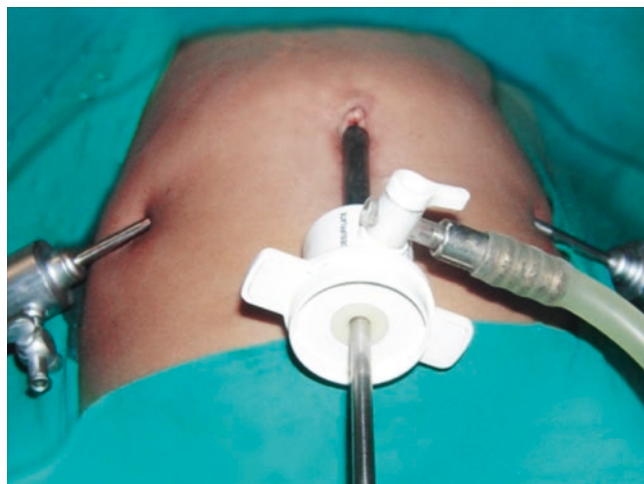


Fig. 57.16 Ports position

57.3.3 Laparoscopic Orchiopexy in Intracanalicular Testis

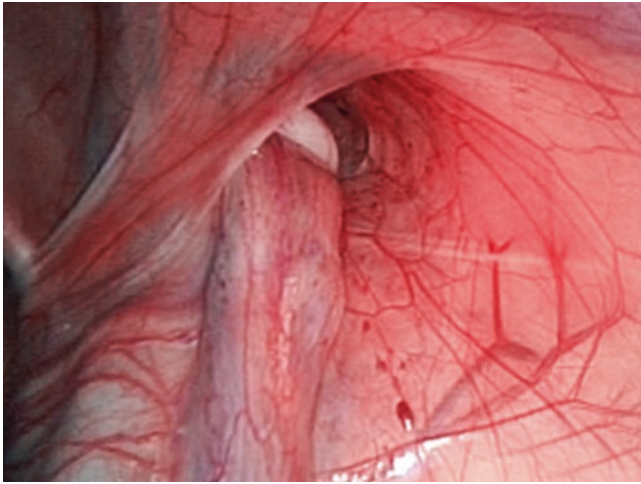


Fig. 57.17 Right testis seen below the internal ring level

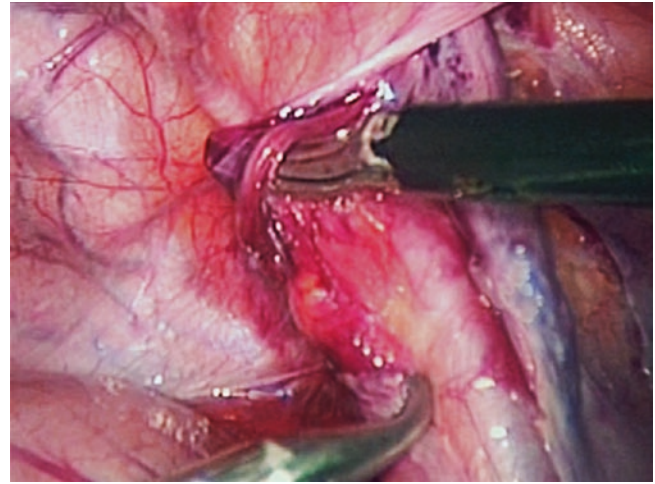


Fig. 57.18 Vas dissected

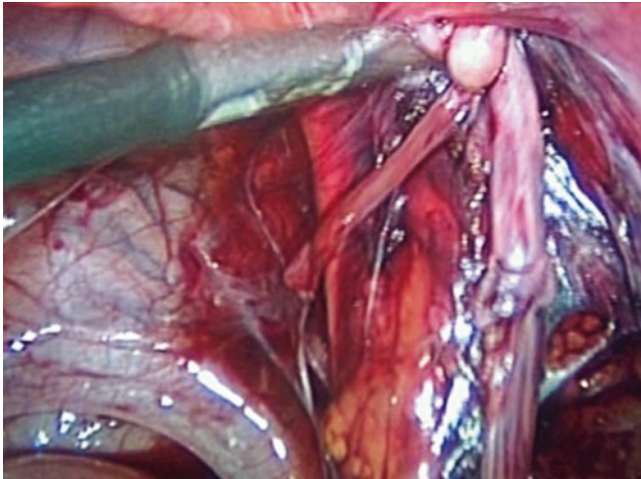


Fig. 57.19 Cord structures completely mobilised

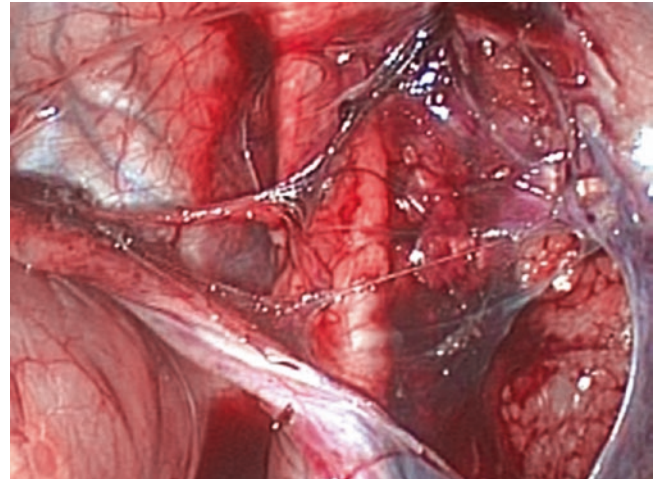


Fig. 57.20 Cord structures dissected all around to mobilise completely

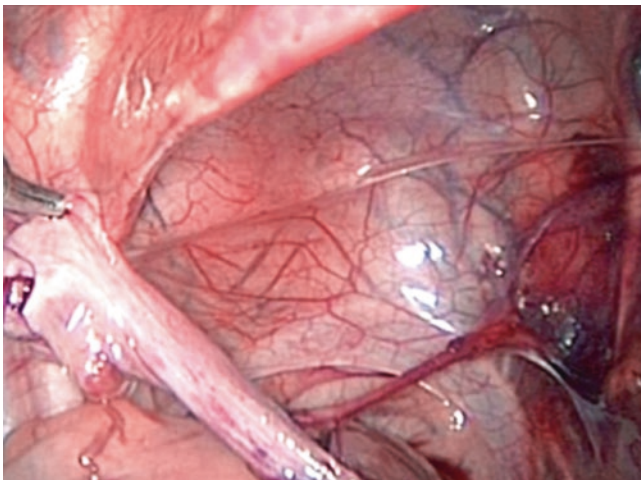


Fig. 57.21 Testis reaching opposite ring is a rough guide to adequacy of mobilisation

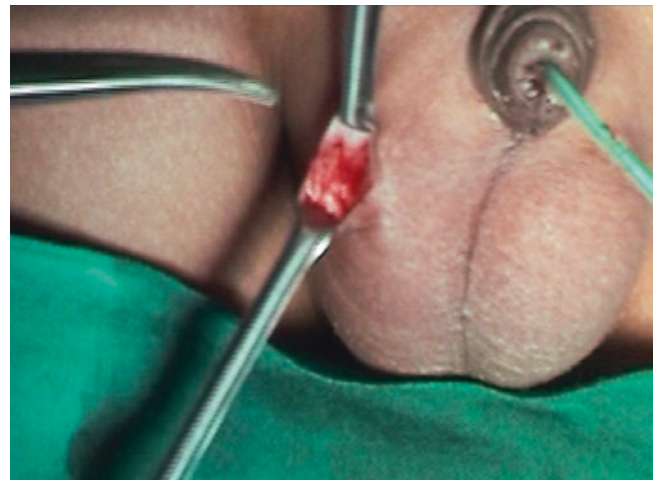


Fig. 57.22 Subdartos pouch creation

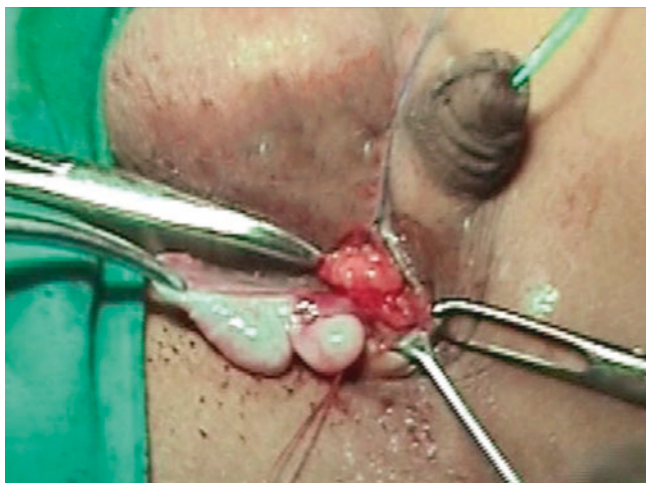


Fig. 57.23 Testis pulled through dartos pouch into scrotum

References

1. Ettayebi F, Benhammou M. The non-palpable testis: review of 35 cases. *Pediatr Endosurg Innov Tech*. 2001;5(3):335–8.
2. Wang KS, Shaul DB. Two stage laparoscopic orchiopexy with gubernacular preservations: preliminary approach report of a new approach to the intra abdominal testis. *Pediatr Endosurg Innov Tech*. 2004;8(3):250–3.
3. Stroedter L, Hoffmann K, Doede T, Waldschmidt J. Laparoscopic findings in children with cryptorchidism. *Pediatr Endosurg Innov Tech*. 1997;1(2):117–26.
4. Lima M, Domini M, Libri M, Pascotto R, Bertozzi M, Gentili A. Video laparoscopic evaluation of the nonpalpable testis: 36 consecutive explorations in 16 months. 1997;1(4): 211–6.
5. Ramalingam M, Selvarajan K, Senthil K. Cryptorchidism: facts and recent advances. contemporary trends in laparoscopic urology surgery. 1st edn. B.I. Churchill Livingstone Pvt Ltd. New york; 2002. p. 217–27.
6. Rozanski TA, Bloom DA. The undescended testis: theory and management. *Urol Clin N Am*. 1995;22(1):107–18.

Part VII

Single-Site Reconstructive Surgery

Abhay Rane and Sara L. Best

58.1 Introduction

As surgery continues to evolve, the desire to further minimize the invasiveness remains at the forefront of innovation. While it is the adoption of laparoscopy and subsequently, robotics in urology, resulted in a dramatic improvement in the morbidity of many urological procedures, talented surgeons have pushed the envelope even further with the development of laparoendoscopic single-site (LESS) surgery. Defined by the Laparoendoscopic Single Site Surgery Consortium for Assessment and Research (LESSCAR) in 2010 as any endoscopic/laparoscopic/robotic procedure using a single entry point [1], hundreds of publications detailing urologic procedures have appeared in the literature.

Reconstructive surgery, compared to extirpative operations, is often an ideal target for LESS approaches because typically there is no large surgical specimen that requires intact removal. Thus a pleasing cosmetic outcome can be maintained by keeping the surgical incisions small. Pyeloplasty is perhaps the best example of a LESS reconstructive operation for urologists to learn, as it is a common procedure, frequently occurring in younger patients who are less likely to have had multiple prior abdominal surgeries would and be more interested in cosmesis [2]. While some studies have reported improved convalescence measures in LESS patients compared to standard multi-port laparoscopy, the main advantage of LESS appears to be cosmetic outcomes, with reduced number of incisions and the ability to

conceal the scar within the umbilicus in many cases. Due to the technical challenges of LESS, described next, the best candidates for LESS may therefore be those patients who are particularly interested in “scarless” surgery or improved cosmetic outcomes.

LESS is associated with several ergonomic challenges that have their own learning curve, even in the hands of skilled laparoscopists. These challenges largely stem from the loss of instrument triangulation that occurs when all instruments are passed through a single site, as opposed to ports spaced out across the abdominal wall in standard laparoscopy. Triangulation of ports allows force to be applied in opposite directions, allowing the separation of tissues, while inserting the instruments next to each other in a single LESS incision causes a loss of instrument tip separation. LESS can also be associated with instruments clashing into each other as they compete for space within a small incision. Tactics for dealing with these ergonomic challenges are described below.

58.1.1 Preliminary Evaluation

As reviewed earlier in this book in the chapter on multi-port pyeloplasty, preoperative imaging with computerized tomography (CT) is helpful in the evaluation of UPJ obstruction as it can reveal the degree of dilatation of the renal pelvis, the presence of a crossing vessel (CT angiography is particularly helpful), and the presence of concurrent renal calculi. Diuretic renography can also clinch the diagnosis of obstruction and identify poorly functioning kidneys that are better suited for nephrectomy than reconstruction.

Axial imaging such as CT can also help identify patients who may be poorly suited for the technical challenges of LESS surgery. Obese patients, particularly those with extensive or fibrotic-appearing perinephric fat, and those with very small intra-renal pelvis may be better suited for a multi-port approach. Additionally, patients with a history of prior

A. Rane, OBE, MS, FRCS, FRCS(Urol) (✉)
East Surrey Hospital,
Canada Avenue, Redhill, Surrey RH1 1RH, UK
e-mail: a.rane@btinternet.com

S.L. Best, MD
Department of Urology, University of Wisconsin
School of Medicine and Public Health,
1685 Highland Ave, MFCB 3229, Madison, WI, USA
e-mail: best@urology.wisc.edu

ipsilateral renal surgery or other intra-abdominal operations that may lead to adhesions may be difficult to manage with a LESS technique.

As in all cases of suspected UPJ obstruction, retrograde pyelography can be very useful in the assessment of patients where the diagnosis is unclear or there is concern for possible ureteral pathology.

58.1.2 Surgical Technique

A transperitoneal approach through an umbilical incision is most commonly used in LESS pyeloplasty. While a single 2.5–3 cm umbilical incision is favored by the authors, use of three 5 mm laparoscopic ports placed through separate fascial incisions in the umbilicus has been reported [3]. Several commercially available LESS ports are available and these can be placed inside the 2.5–3 cm incision.

LESS pyeloplasty can be performed via either standard laparoscopy or using a robotic platform. Equipment utilized for LESS differs slightly between the two.

58.1.3 Standard LESS

Standard LESS typically uses three 5 mm laparoscopic ports placed through a LESS access device. “Low profile” ports with smaller than average heads can help reduce instrument conflict on the outside of the patient’s body. A 5 mm laparoscope is used and a variety of modifications and specialty scopes exist to facilitate LESS, including extra long endoscopes that allow the camera-holding assistant to be out of the way of the surgeon, right-angle light cord stem adapters, and flexible-tipped or deflecting laparoscopes; all designed to reduce the surgical conflict or “sword fighting” that is one of the greatest technical challenges of LESS. Similarly, modified laparoscopic instruments such as graspers, scissors, and needle drivers have been purpose-designed for LESS. These include rigid bent instruments as well as articulating devices, both of which seek to allow surgeons to restore the triangulation that is lost by passing all instruments through a single incision in LESS. These instruments can help accomplish the operation and reduce instrument conflict inside the abdominal cavity, but they do have a learning curve of their own that takes time to master. Many surgeons prefer using one bent or articulating instrument along with one standard straight laparoscopic instrument during LESS surgery.

Another technique used to reduce instrument conflict and restore triangulation is the crossing of instruments inside the abdominal cavity. This allows the tips of the instruments to be separated further from each other and allows better manipulation and separation of tissues. However this approach again has a learning curve, as the instrument on the left side of the screen is actually controlled by the right-hand and vice versa. Bent and articulating instruments were designed to particularly take advantage of crossing as their tips can be curved back towards the center of the screen (the surgical target area).

58.1.4 Robotic LESS

Just as robotic surgery replaced standard laparoscopic surgery in many centers for operations requiring suturing such as partial nephrectomy and prostatectomy, many surgeons have harnessed the Da Vinci® robotic platform (Intuitive Surgical, Sunnyvale, CA) to address some of the technical challenges of LESS. In robotic LESS pyeloplasty, an 8 mm robotic camera and 5 mm robotic instruments can be used. Endowristed 5 mm cautery scissors do not exist for this platform, so the surgeon can use either a 5 mm cautery hook device and cold shears or sacrifice some degree of instrument mobility and use an 8 mm robotic port that accommodates the cautery scissors. We have found that placing the ports in a diamond configuration through a GelPOINT® access device (Applied Medical, Rancho Santa Margarita, CA) reduces instrument and robotic arm conflict and permits an assistant port to be utilized (figure).

A 30° robotic camera set to the “up” position is often helpful in reducing instrument competition for space in the small incision. Just as in standard LESS, the right and left-handed instruments can be crossed just inside the fascia to restore triangulation. However, one advantage of the robotic platform in LESS is that the “masters” that control which joystick on the surgeon console controls which robotic arm/instrument can be changed on the console screen. This allows the instrument that is on the right side of the screen to be operated by the right hand and vice versa, reducing some of the physical challenge of learning LESS.

The steps of the operation after port placement are the same as described in the previous Chap. 5 on pyeloplasty, but there are several “tricks” that can be used to overcome the ergonomic challenges facing the LESS surgeon. These maneuvers are highlighted in the following images.

58.2 Follow Up

Follow up after LESS pyeloplasty mirrors that of standard laparoscopic pyeloplasty. A Foley catheter is left

draining the bladder during the hospitalization and removed before discharge if no urine leak is detected. Ureteral stents are typically left in place for 4 weeks postoperatively.

Fig. 58.1 Modified lateral decubitus positioning appropriate for minimally-invasive pyeloplasty of any approach. Placing the patients top arm at his/her side reduces external clashing with instruments

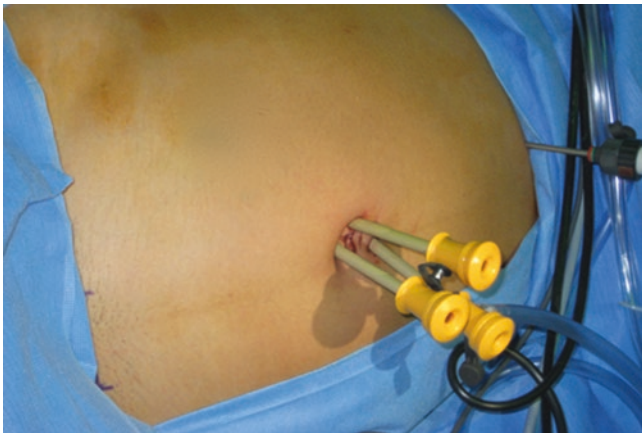
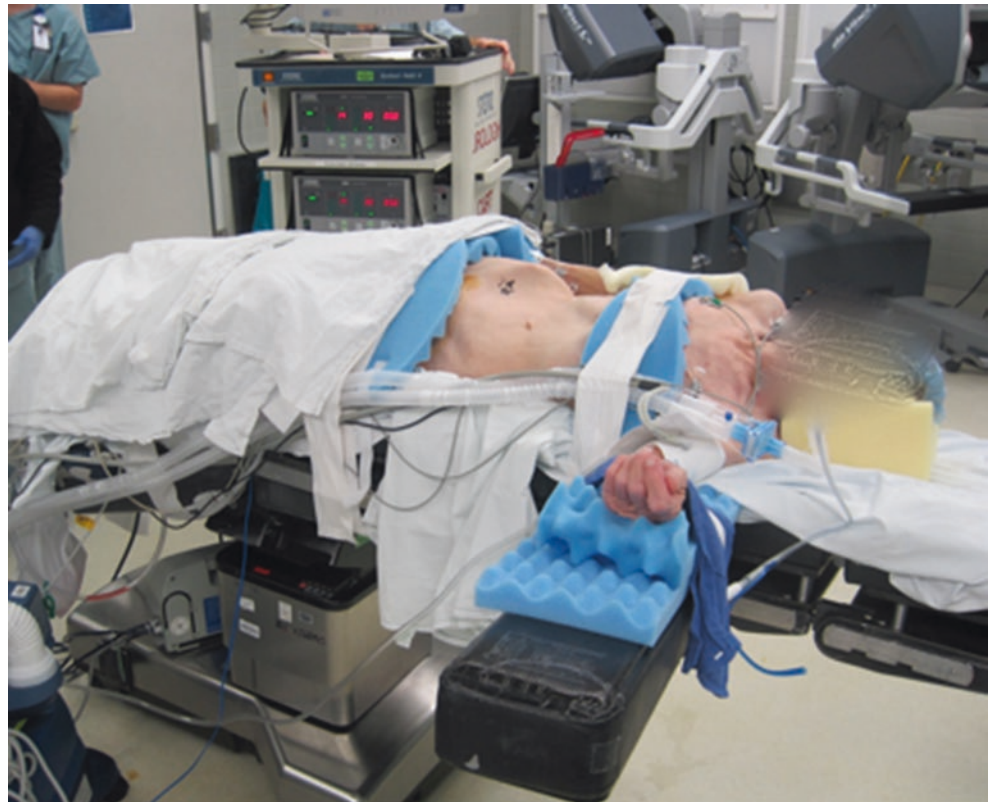

Fig. 58.2 Individual intraumbilical 5mm port placement suitable for LESS pyeloplasty. Low profile trocars with small heads allow the ports to be placed very close to each other while reducing external clashing of the ports themselves during surgery

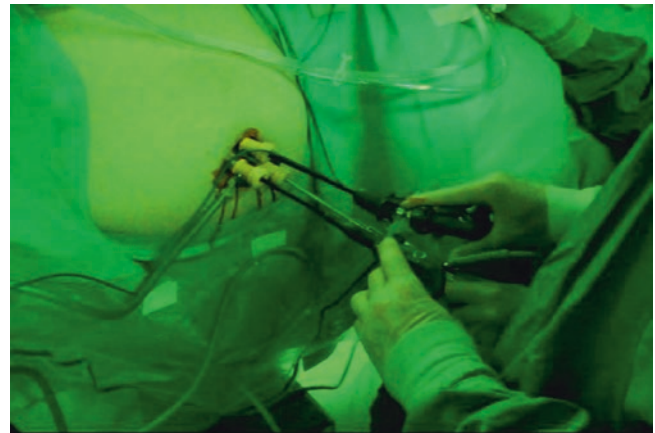


Fig. 58.3 External view of LESS renal surgery. Note how close the instruments and camera are to each other, which can produce significant ergonomic challenges for the surgeon and assistant

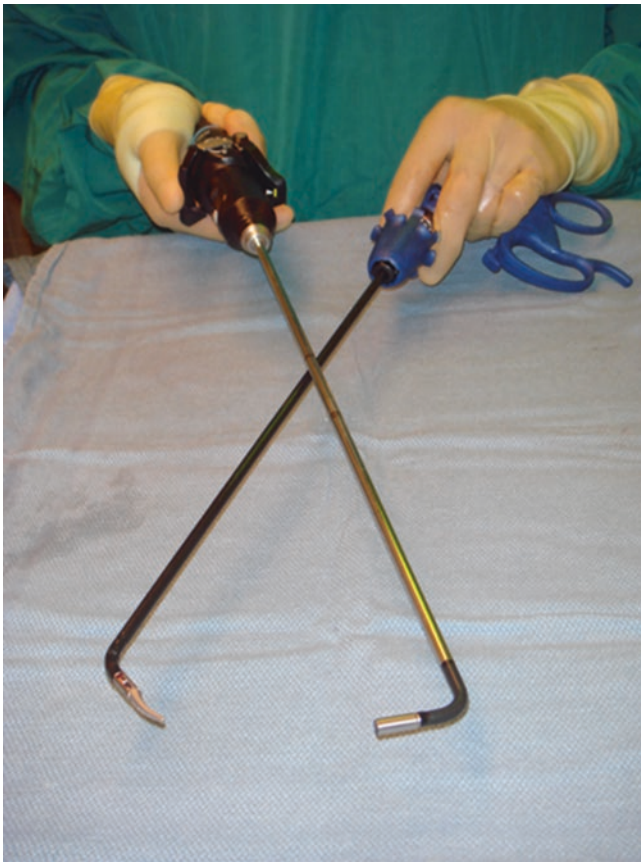

Fig. 58.4 Articulating laparoscopic grasper and endoscope used for LESS surgery. Also demonstrated is the proximal crossing of the instruments, which occurs inside the abdominal cavity

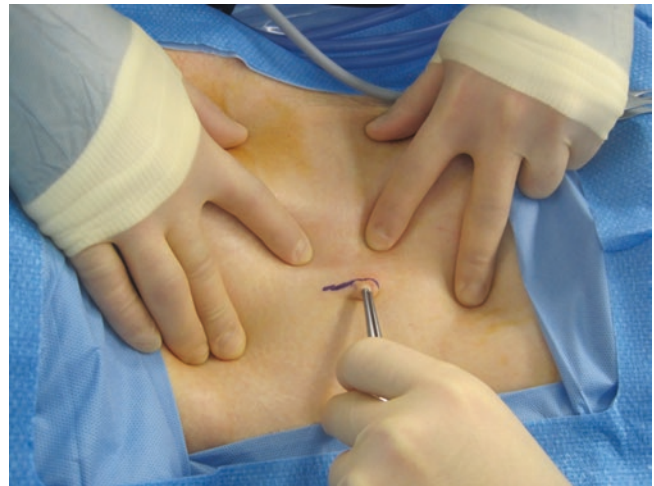

Fig. 58.5 Marking the 2-3cm incision site for the insertion of a purpose-built LESS port device. The umbilicus can be everted and the incision concealed within the folds of the umbilicus itself to maximize the cosmetic outcome

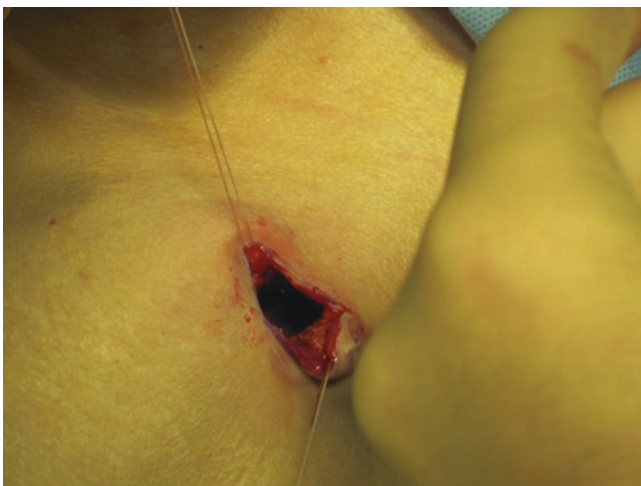

Fig. 58.6 Entering the abdomen with an open approach through the small incision. The fascia can be tagged with suture to help elevated the abdominal wall to insert the port and for ease of closure at the end of the case

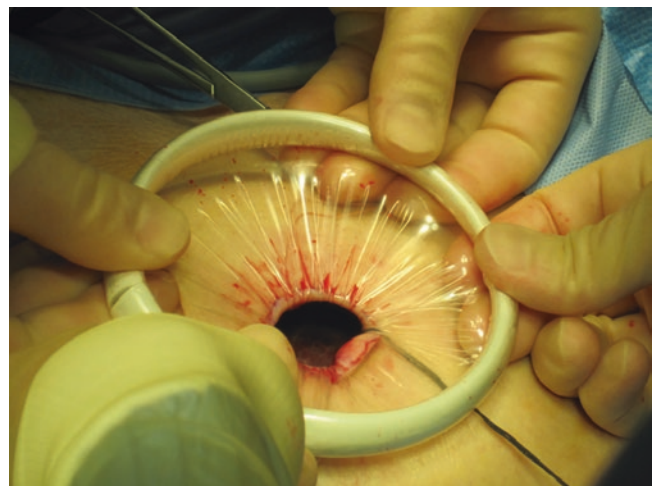


Fig. 58.7 Placement of the Alexis retractor portion of a GelPOINT® access device (Applied Medical, Rancho Santa Margarita, CA. One of the rings of the retractor has already been placed within the incision and the external ring is folded in on itself to tighten the device into place on the abdominal wall

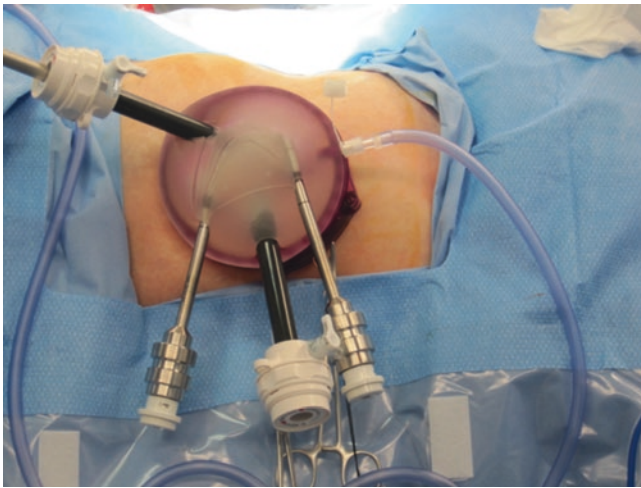


Fig. 58.8 The GelPOINT ® device locked into place in position for surgery. It is helpful to place the ports through the gel dome before attachment. We find that a diamond configuration of ports reduces instrument and robotic arm conflict. Here we have placed two 5mm robotic trocars at the sides of the “diamond shape,” while 10mm standard laparoscopic ports (one for the robotic camera and one for the assistant to pass suture through) are at the top and bottom

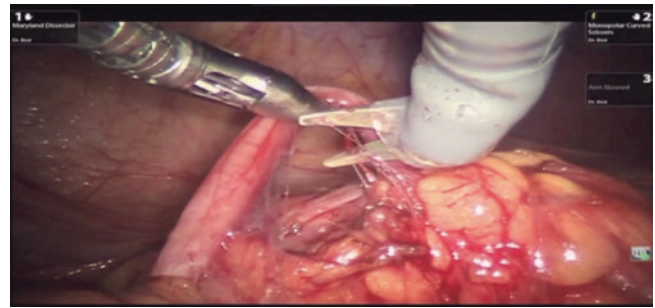


Fig. 58.9 The ureter is gently elevated with a grasper to allow dissection towards the UPJ. The robotic instruments are crossed at a fulcrum point off screen and the grasping instrument is put in position “on top” of the scissors since it is lifting the ureter up. This leaves more space for the scissors to be moved around the operative field. Caution must be exercised in R-LESS as the instruments can easily bump into each other and the camera. By making small moves at a time and moving the camera/instruments together as a unit, this conflict can be reduced

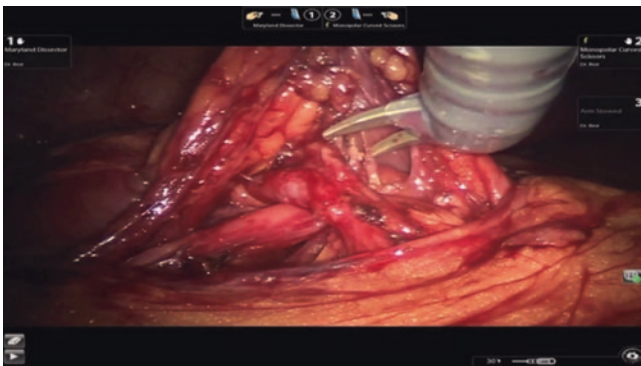

Fig. 58.10 Dissection of the UPJ reveals large crossing lower pole vessels that must be carefully freed from the surface of the UPJ such that the transected UPJ can be reconstructed anterior to them

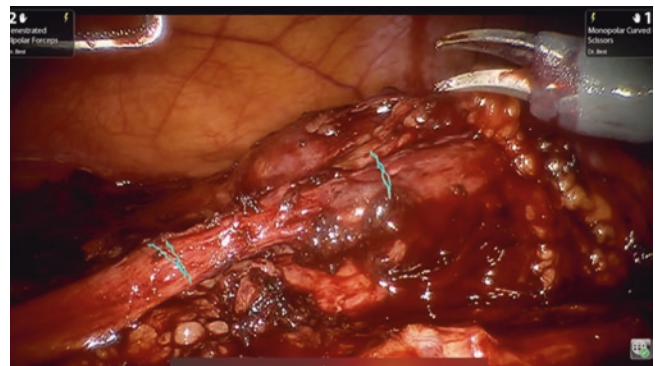


Fig. 58.11 This UPJ dissection revealed an unhealthy, stenotic proximal ureteral segment, rather than crossing vessels, as a source of obstruction. The segment between the blue lines was excised before reconstruction

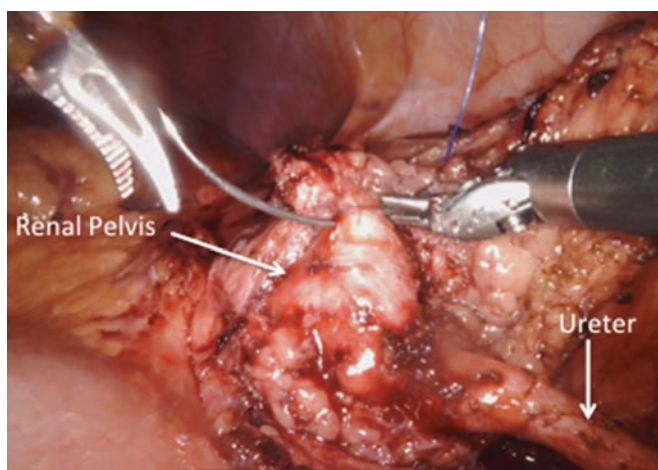
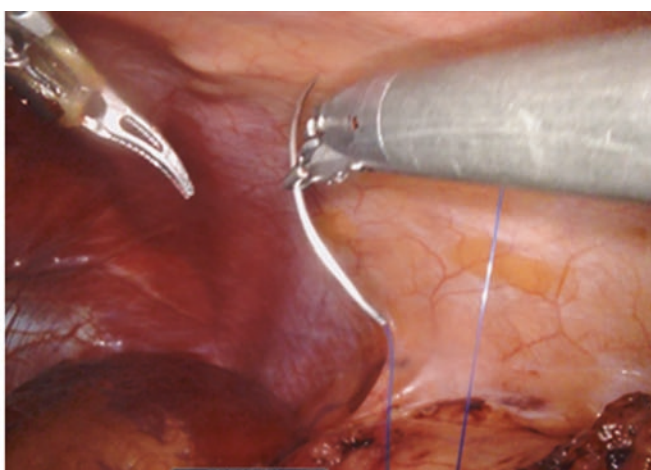


Fig. 58.12 Temporary percutaneous “hitch stitches” are particularly useful for elevating the renal pelvis or retracting other tissues during LESS. Here, a 2-0 polypropylene suture on a slightly straightened needle has been passed through the abdominal wall by the assistant,



allowing the console surgeon to pass it through the renal pelvis and back out the abdominal wall. The assistant can then adjust the suture tension to hoist the UPJ. Straight-type Keith needles can also be used for this purpose in patients with thicker abdominal walls

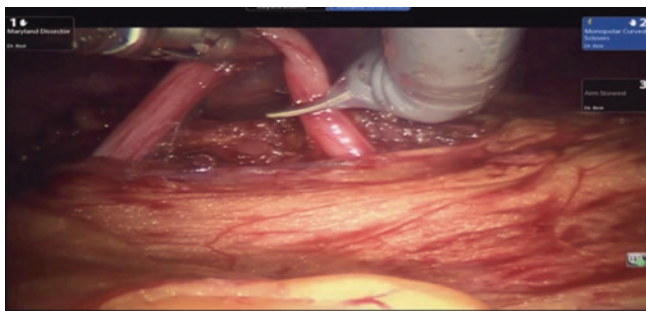


Fig. 58.13 Transection of the ureter at the UPJ

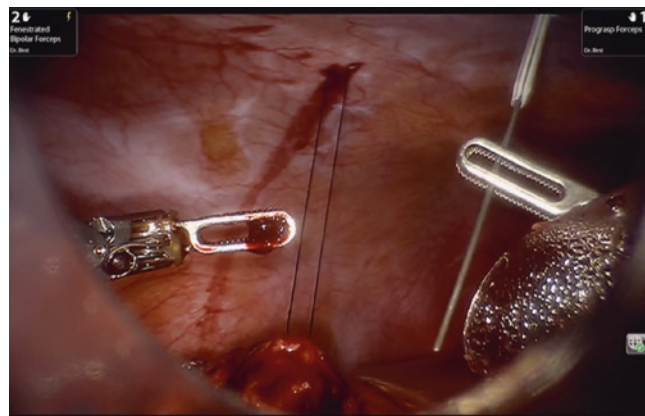


Fig. 58.14 Subcostal placement of a 14fr angiocatheter by the assistant allows a guidewire to be passed into the ureter at an ergonomically favorable angle. Once the wire has been successfully passed all the way down the ureter, the angiocatheter is removed and the small puncture created by it is typically sufficient in size to permit the passage of a 6Fr double J stent over the wire

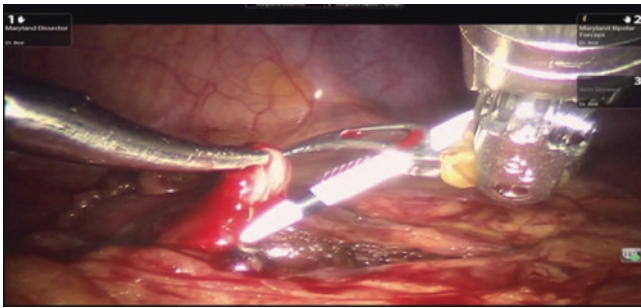


Fig. 58.15 Advancing the stent down the ureter over a wire, facilitated by the bedside assistant

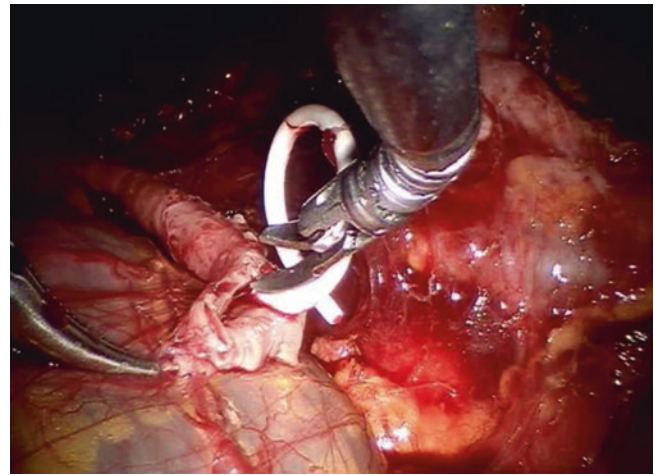


Fig. 58.16 Spatulation of the ureter

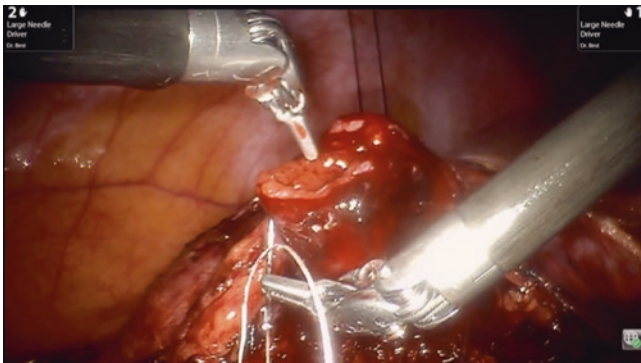


Fig. 58.17 Placing the anastomotic suture "outside to inside" at the most dependent portion of the renal pelvis. The pre-placed temporary hitch stitch helps greatly by suspending the UPJ for ease of suturing

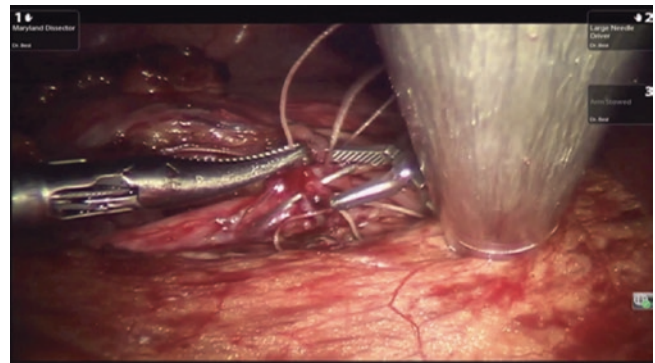


Fig. 58.18 Suturing the anterior UPJ anastomosis

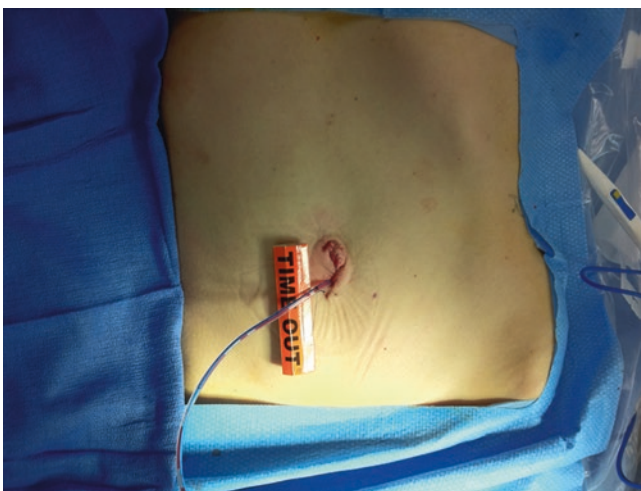


Fig. 58.19 Closure of the intraumbilical incision after LESS pyeloplasty. A small drain can be left exiting the wound if warranted

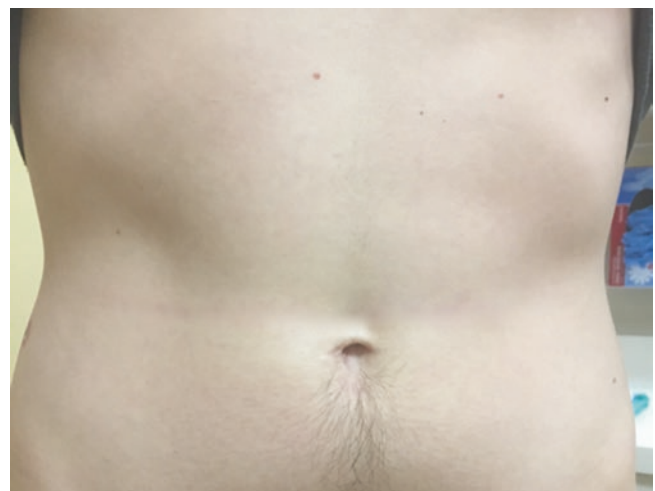

Fig. 58.20 Cosmetic outcome after robotic LESS pyeloplasty

References

1. Gill IS, Advincula AP, Aron M, Cadeddu J, Canes D, Curcillo 2nd PG, Desai MM, Evanko JC, Falcone T, Fazio V, Gettman M, Gumbs AA, Haber GP, Kaouk JH, Kim F, King SA, Ponsky J, Remzi F, Rivas H, Rosemurgy A, Ross S, Schauer P, Sotelo R, Speranza J, Sweeney J, Teixeira J. Consensus statement of the consortium for laparoendoscopic single-site surgery. *Surg Endosc*. 2010;24(4):762–8.
2. Park SK, Olweny EO, Best SL, Tracy CR, Mir SA, Cadeddu JA. Patient-reported body image and cosmesis outcomes following kidney surgery: comparison of laparoendoscopic single-site, laparoscopic, and open surgery. *Eur Urol*. 2011;60(5):1097–104.
3. Tracy CR, Raman JD, Bagrodia A, Cadeddu JA. Perioperative outcomes in patients undergoing conventional laparoscopic versus laparoendoscopic single - site pyeloplasty. *Urology*, 2009 Nov;74(5): 1029–34. doi: 10.1016/j.urology.2009.04.089. PMID: 19660793.

Part VIII

Kidney Transplantation

Pranjal Modi

59.1 Introduction

First laparoscopic living donor nephrectomy was published in 1995 [1], and it is a standard of care at many centers. In comparison to the open donor nephrectomy, the laparoscopic living donor nephrectomy is associated with less pain, early ambulation, rapid convalescence and better cosmetics appearance to the donor. With the development of better optics, laparoscopic suturing technique and instruments and training to the surgeons era of laparoscopic reconstructive surgery is started. Urologists master the technique of laparoscopic suturing and applied it for various operations like radical prostatectomy, pyeloplasty, ureteric reimplantation etc. Some urologists also published laparoscopic repair of injury to the blood vessels at the time of major pelvic surgery [1, 2]. Vascular surgeons started performing complex bypass surgery and repair of aortic aneurysm laparoscopically [3, 4]. Clearly, more complex operation like laparoscopic kidney transplantation is thought as a possibility and now is a reality at our center.

Advantages of laparoscopic kidney transplantation over conventional open kidney transplantation are less pain, early ambulation, no perigraft collection of fluid, rapid convalescence and better cosmetic appearance.

59.2 Indications and Contraindications

Indications of laparoscopic kidney transplantation are same as open kidney transplantation. In some patients, however, laparoscopic kidney transplantation is a relative contraindication; e.g. previous major abdominal or pelvic surgery, large pelvic mass like fibroid of uterus, extensive calcifica-

tion of external iliac vessels and large size native kidney occupying the whole abdomen leaving behind inadequate space to create for laparoscopic surgery. In addition, patient who has poor cardiovascular and pulmonary reservoir is a general contraindication for laparoscopic surgery. It is also not carried out in pediatric age group.

59.3 Operative Procedure

General anesthesia with placement of central venous line and radial arterial catheterization is carried out. Patient is placed in supine and 20° Trendelenbergh position. Foley catheter is placed. Pneumoperitoneum was achieved either using Verres needle or open access through umbilical scar. For right iliac fossa kidney transplantation, three ports are placed in to left iliac fossa (Fig. 59.1). The umbilical port is placed and an additional 5 mm port is placed to the right side about 6–8 cm away and a cm. inferior from the level of umbilical port. Initial pneumatic pressure would be 12 mmHg. The bowel loops are placed in to the upper abdomen to visualize the right iliac vessels and ureter. Posterior peritoneum is divided and external iliac vessels dissected out (Fig. 59.2).

The laparoscopic hand instruments are removed and a 6 cm long pfannensteil incision is made dividing the skin and the external sheath. Both recti muscles are separated in the midline and peritoneum is opened. The kidney prepared on the bench, is brought to the recipient wound and dropped into the peritoneal cavity. The external sheath is closed and pneumoperitoneum reestablished.

The kidney is positioned in such a way that the renal vessels are facing the external iliac vessels (Fig. 59.3). The external iliac vein is controlled either by vessel loops or by bulldog clamps and appropriate size venotomy carried out with endoshears. Renal vein to external iliac vein anastomosis was carried out in end to side fashion using polypropylene 5/0 suture material. Bulldog clamp is applied on to the renal vein and clamps on the external iliac veins

P. Modi
Institute of Kidney Diseases, Ahmadabad, India
e-mail: dr_pranjal@yahoo.com

removed to restore the lower limb circulation. Renal artery to external iliac artery is carried out in similar fashion. Clamps are removed and hemostasis secured. Graft perfusion is checked by its color and turgidity and urine output. The pneumoperitoneum pressure is reduced to 8–10 mmHg. A rectangular peritoneal flap is raised lateral to the external iliac vessels. Kidney is flipped on to the psoas muscle and covered by peritoneal flap to make it a retroperitoneal organ.

The laparoscope is shifted to the umbilical port and using right side 5 mm port and left side upper port ureteroneocystostomy was carried out without using double J stent. Fluid from peritoneal cavity especially under the surface of diaphragm is sucked out. Pneumoperitoneum is eliminated and port sites are closed. We routinely do not place the drain tube. Immediately in post operative period, doppler study is carried out to evaluate graft perfusion. Induction and maintenance immunosuppressants are used as per the institutional protocol. Foley catheter is typically removed on third or forth post operative day.

59.4 Outcome of Laparoscopic Kidney Transplantation

The operative time and warm ischemia time are usually more in laparoscopic kidney transplant and initial creatinine clearance is slower than open kidney transplantation [5, 6]. However, creatinine clearance at the end of 1 month and 1 year is not different in laparoscopic versus open kidney transplantation [6]. The average wound size in laparoscopic kidney transplantation was 5.5 cm vs. 17.5 cm in open

kidney transplantation. Less wound size was associated with less pain and requirement of less analgesic medication. Further, perigraft collection was not seen in any case of laparoscopic kidney transplantation possibly due to transperitoneal approach.

Laparoscopic en bloc kidney transplantation is carried out similar to conventional open kidney transplant for both kidneys [7]. The supra-renal aorta and vena cava are closed during bench surgery and the infra-renal part of aorta and vena-cava are sutured to the external iliac vessels. More recently, vaginal insertion of kidney followed by laparoscopic kidney transplantation is carried out in selected group of female recipients [8]. The kidney was brought closure to the external iliac vessels and laparoscopic kidney transplantation was carried out as described above. Vascular complications required conversion to open operation. The major vascular complications are bleeding from vascular anastomosis, thrombosis of the renal artery, and torsion of allograft. Urinary leak may occur later in the course of post-operative period and warrants redo procedure for reimplantation. Renal artery stenosis following laparoscopic kidney transplantation is not seen in our series.

59.5 Conclusion

Laparoscopic kidney transplantation is feasible and safe and associated with several advantages of laparoscopic surgery over open surgery. One year graft and patient survival is similar following laparoscopic and open kidney transplantation. High level of surgical skill for laparoscopic vascular suturing is required and has steep learning curve.

59.6 Laparoscopic Kidney Transplantation

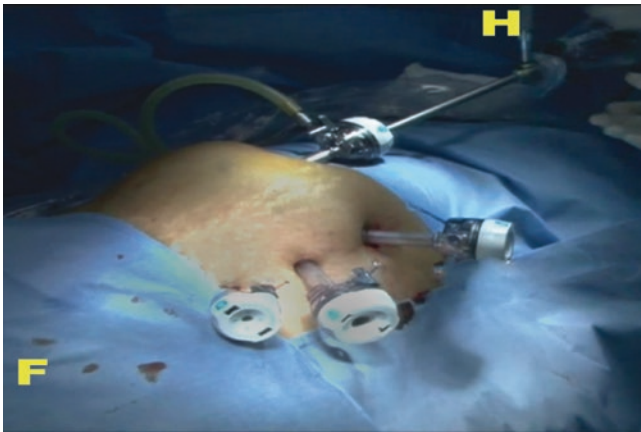


Fig. 59.1 Port position for laparoscopic renal transplantation

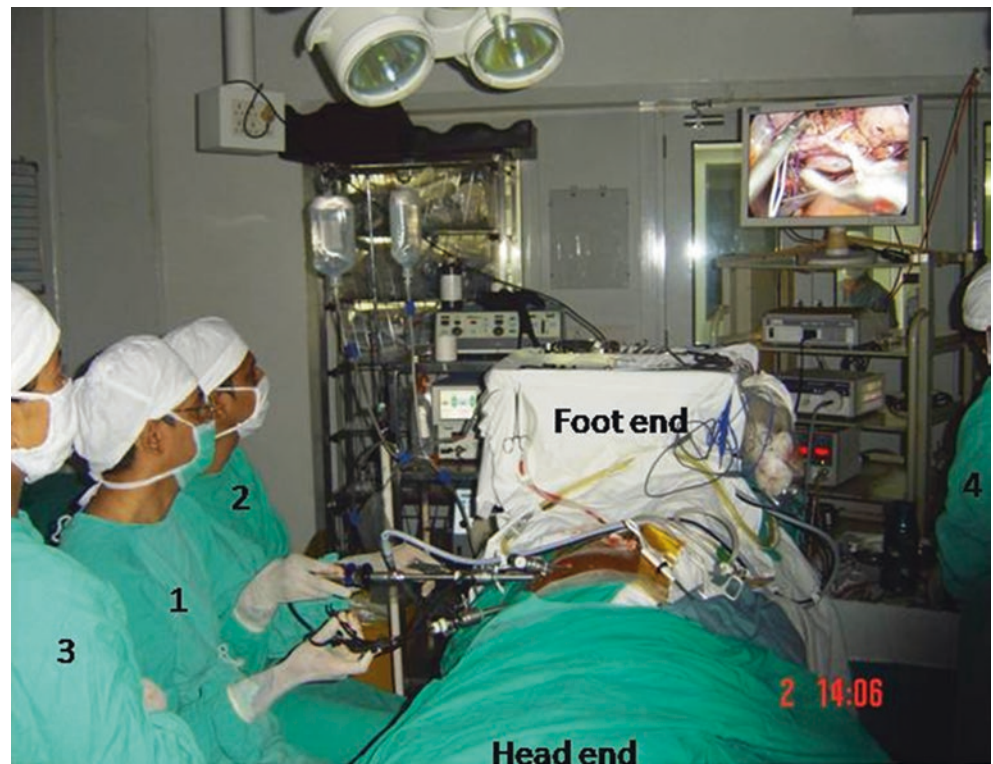

Fig. 59.2 Patient and surgeon position

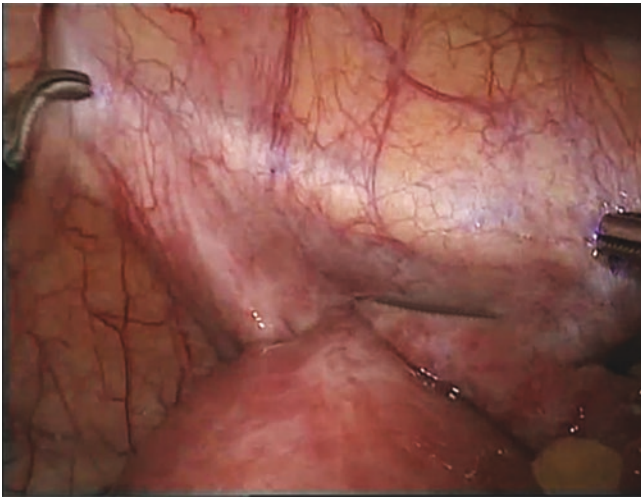

Fig. 59.3 Initial view of vessels in right iliac fossa

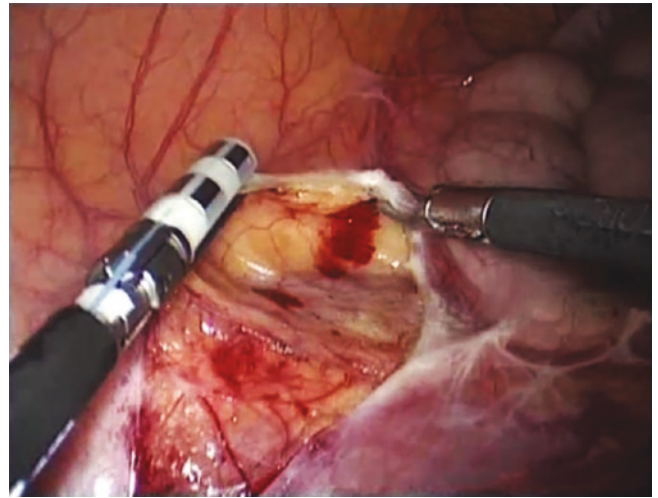


Fig. 59.4 Peritoneotomy with minimal bowel mobilisation

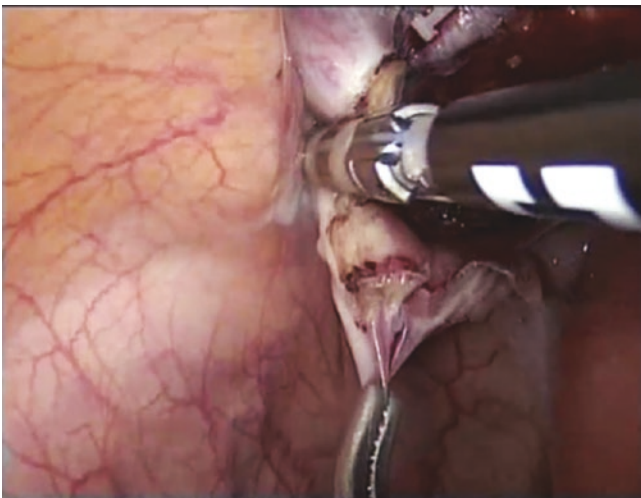


Fig. 59.5 Round ligament being divided

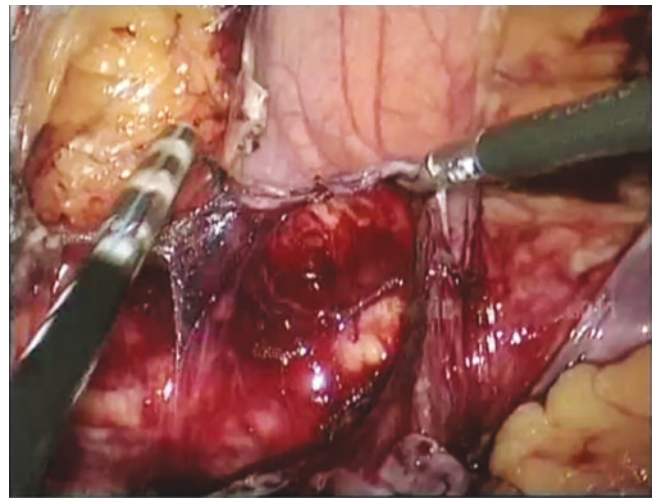


Fig. 59.6 Peritoneal flap created

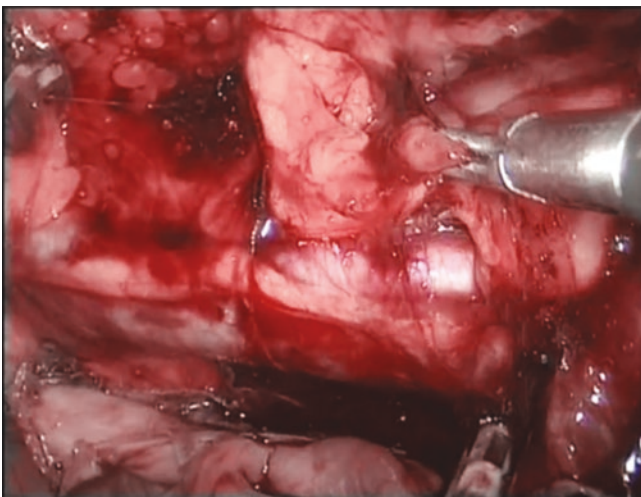


Fig. 59.7 Skeletonisation of external iliac artery and vein in progress

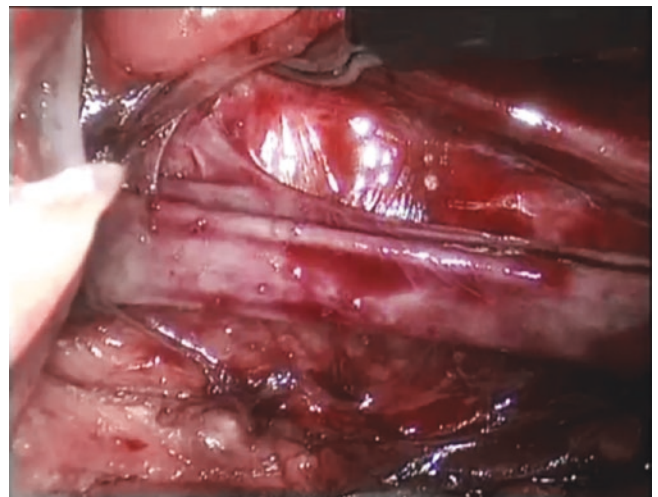


Fig. 59.8 External iliac vein dissection complete

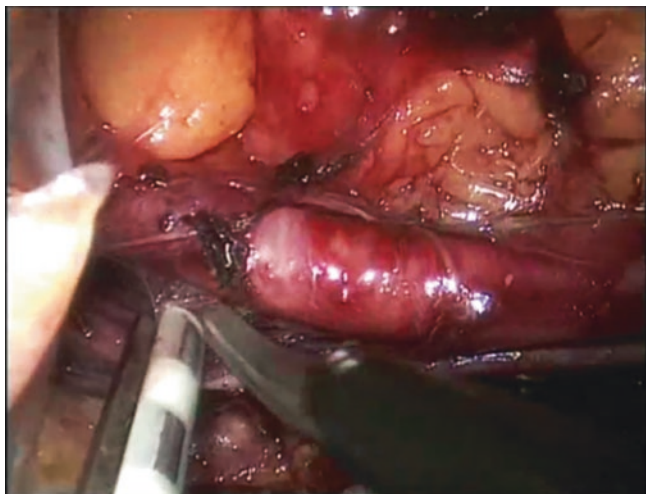


Fig. 59.9 External iliac artery dissection in progress

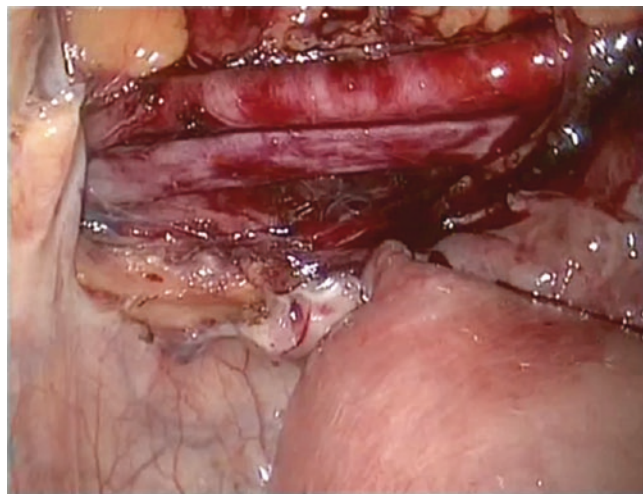


Fig. 59.10 Vessel dissection complete

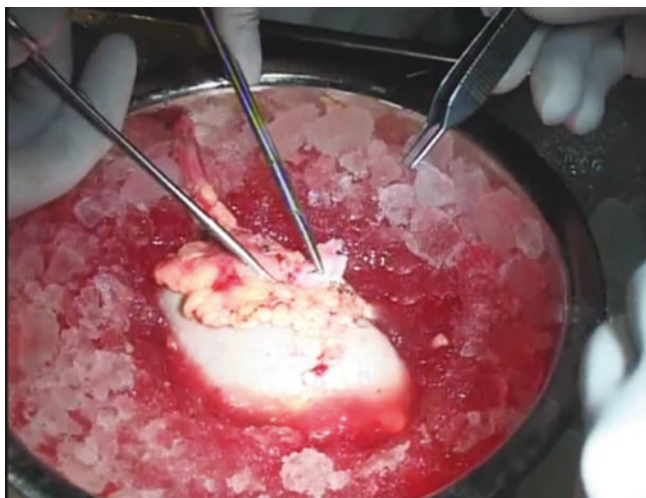

Fig. 59.11 Bench dissection of donor kidney



Fig. 59.12 Six centimeter Pfannensteil incision for placing the renal graft

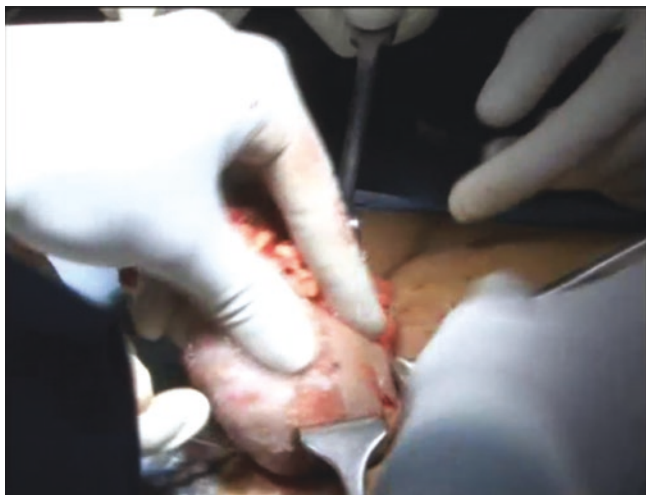

Fig. 59.13 Renal graft inserted through the incision

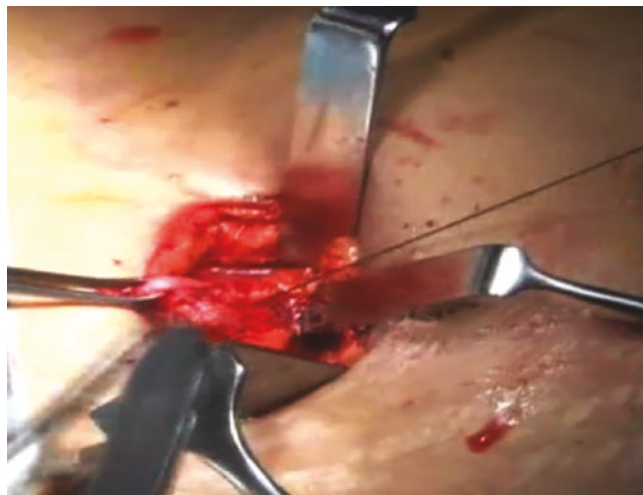

Fig. 59.14 Wound being closed

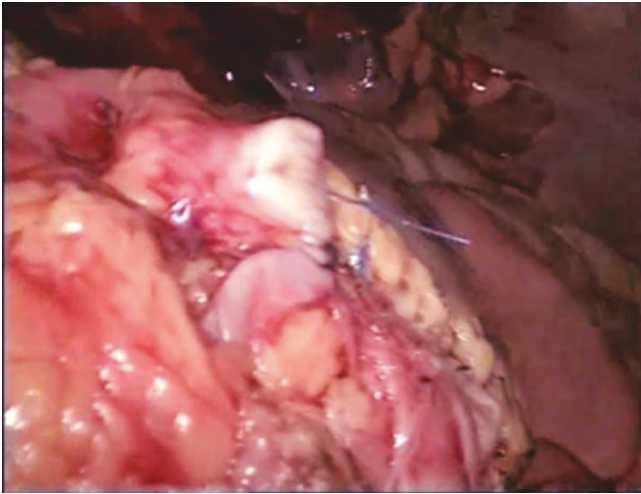


Fig. 59.15 Kidney in the peritoneal cavity

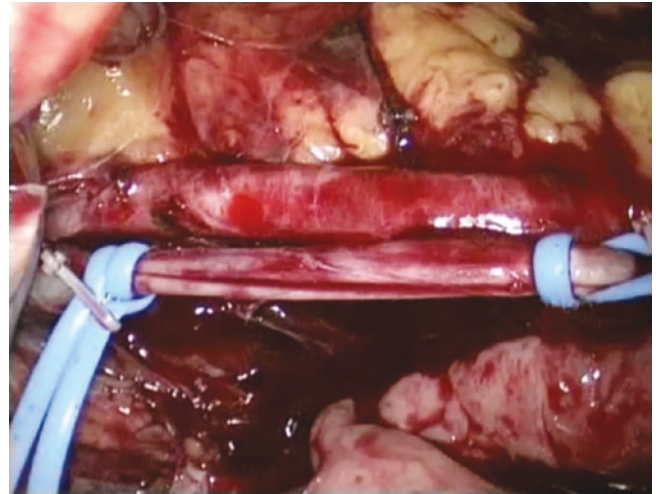


Fig. 59.16 Vein controlled in both ends with vessel loops

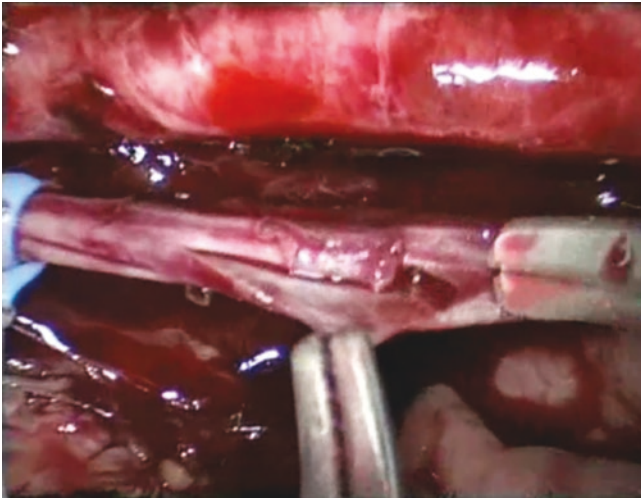


Fig. 59.17 Venotomy complete

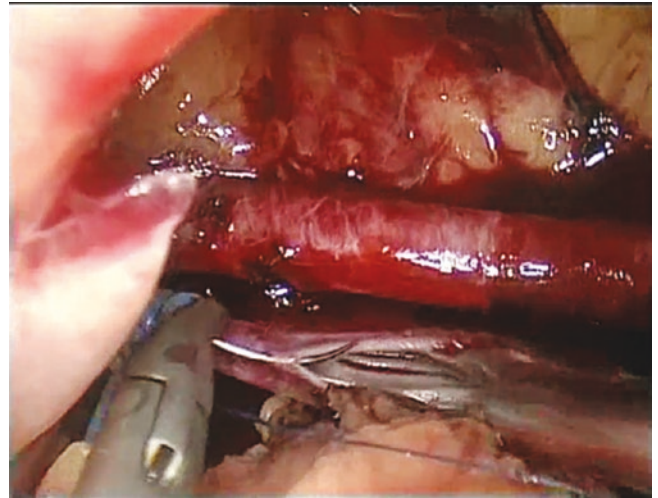


Fig. 59.18 Venous anastomosis started with 6-0 prolene suture

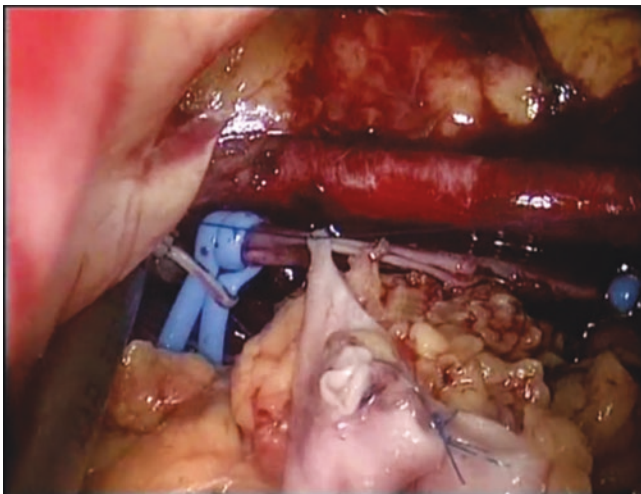

Fig. 59.19 Venous anastomosis in progress – first suture in place

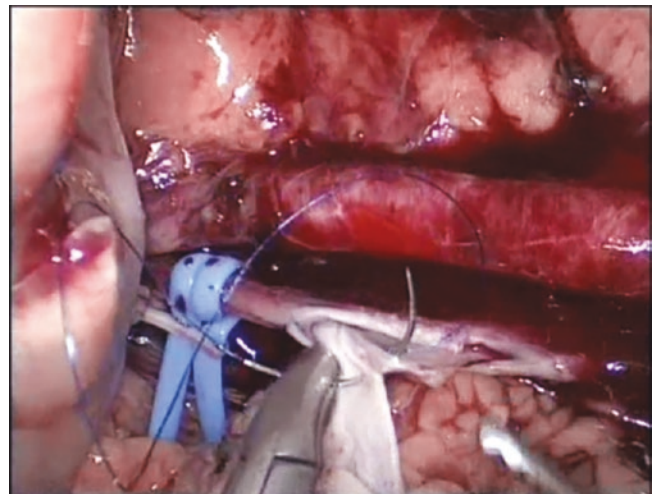


Fig. 59.20 Continuous suture of posterior wall anastomosis in progress

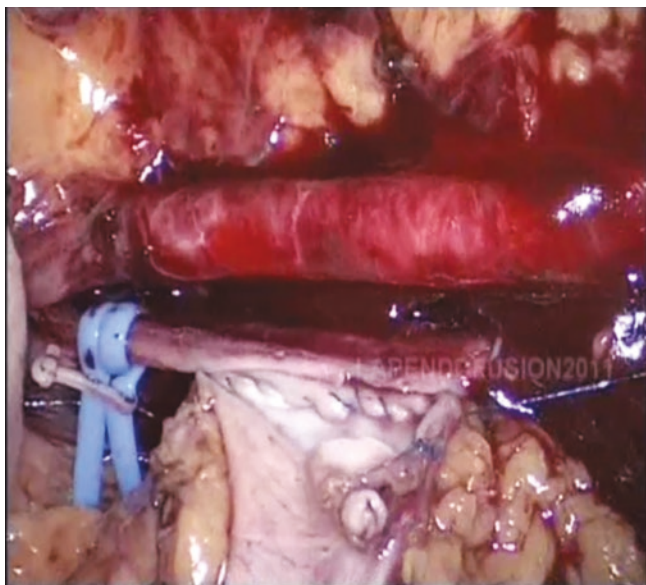


Fig. 59.21 Posterior wall venous anastomosis complete

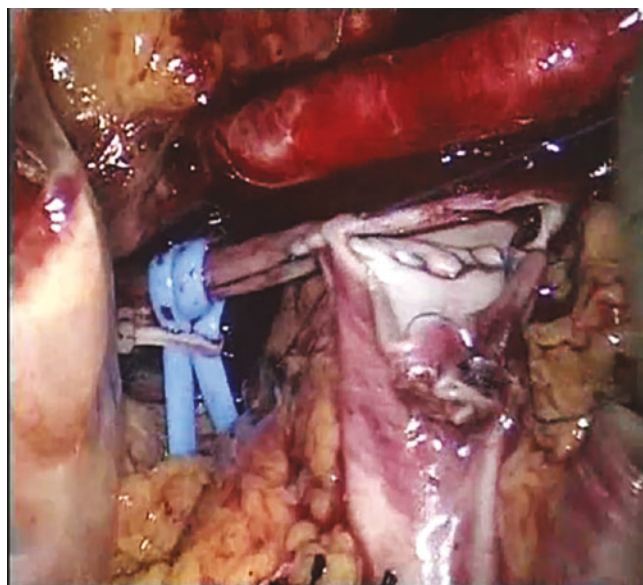


Fig. 59.22 Anterior wall venous anastomosis in progress

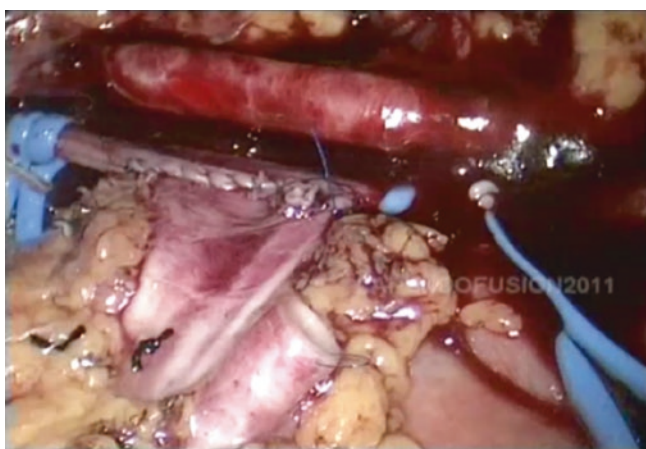

Fig. 59.23 Venous anastomosis complete

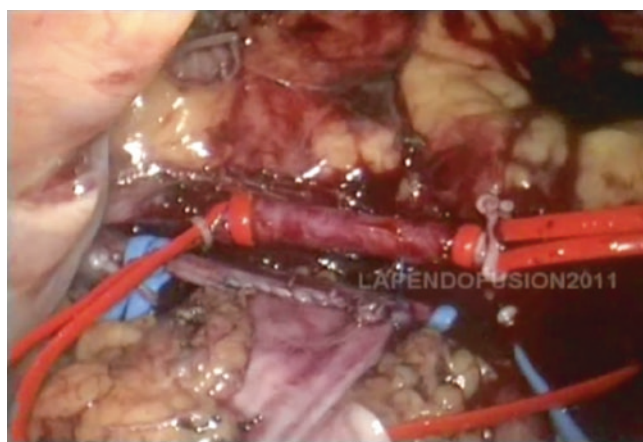


Fig. 59.24 Artery controlled at both ends with vessel loop

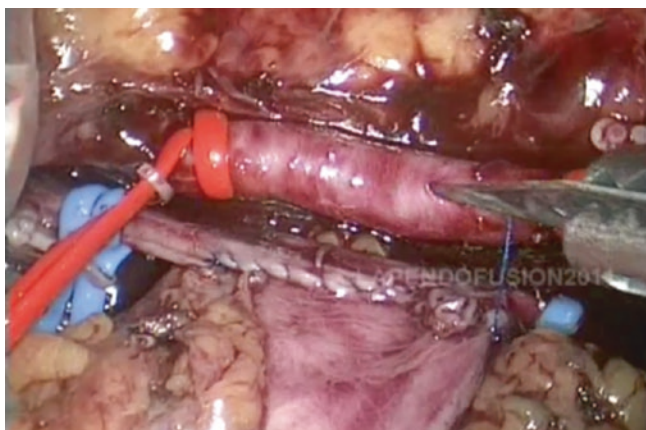


Fig. 59.25 Arteriotomy with knife

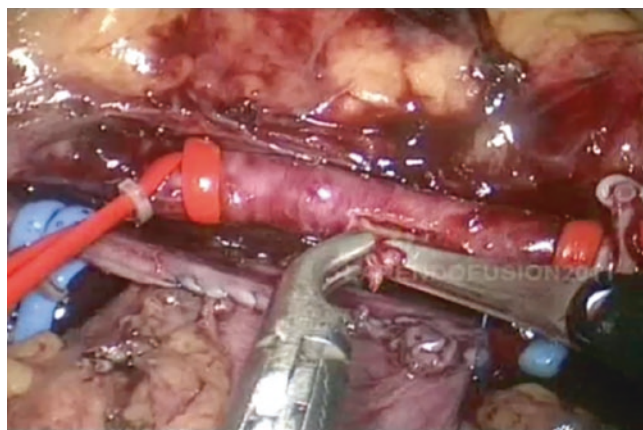


Fig. 59.26 Arteriotomy enlarged with scissors

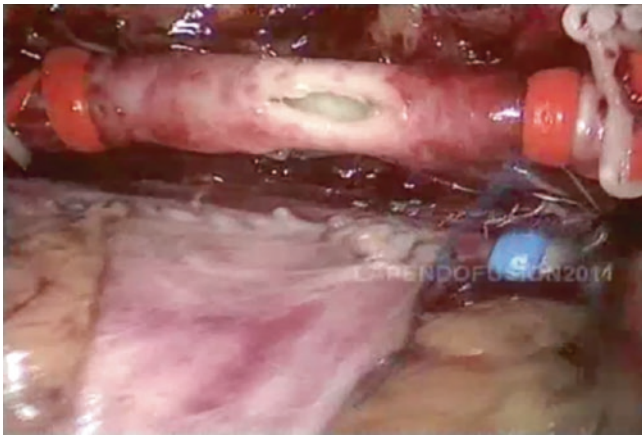


Fig. 59.27 Arteriotomy completed

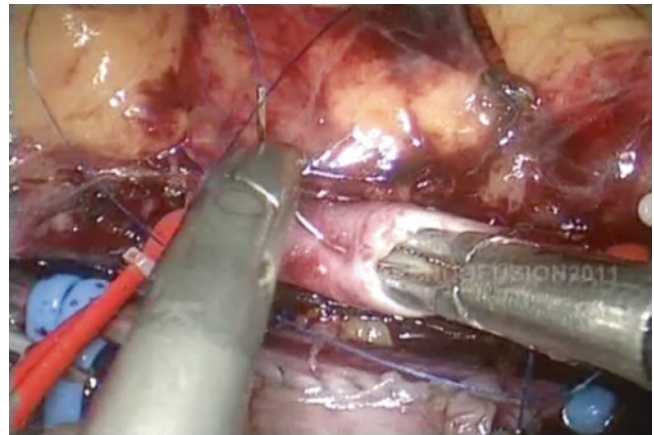


Fig. 59.28 Arterial anastomosis started with 6-0 prolene suture

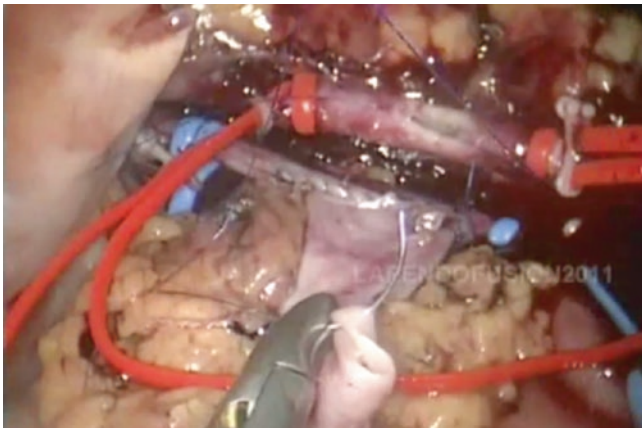


Fig. 59.29 Arterial anastomosis in progress

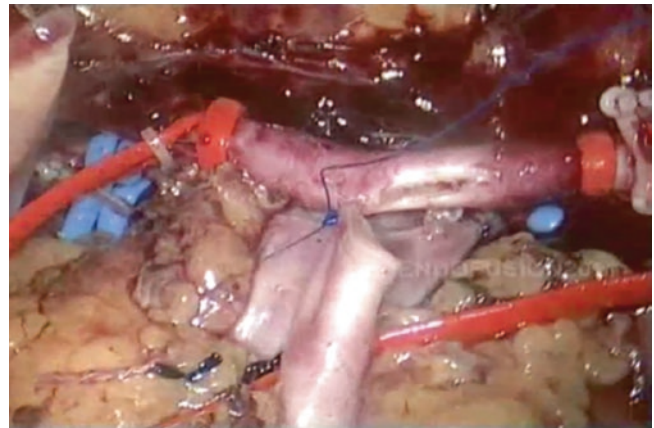


Fig. 59.30 Arterial anastomosis – first suture in place

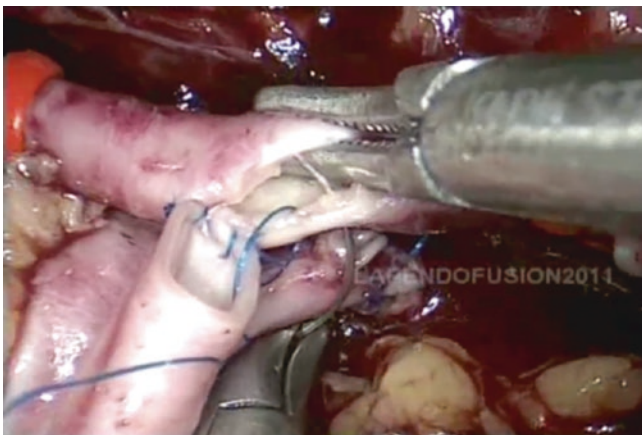


Fig. 59.31 Arterial anastomosis as continuous suture of posterior layer

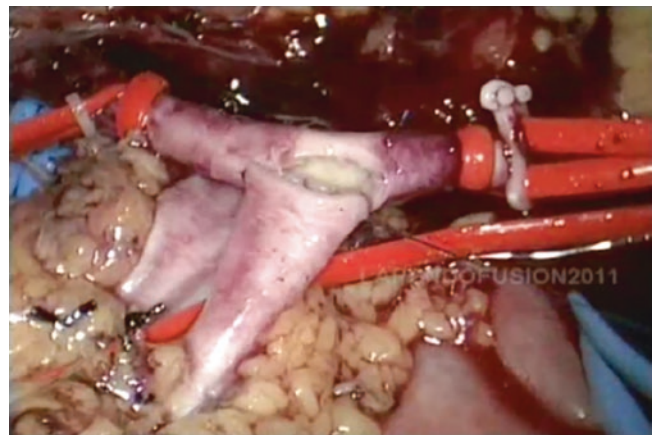


Fig. 59.32 Arterial anastomosis – posterior layer complete

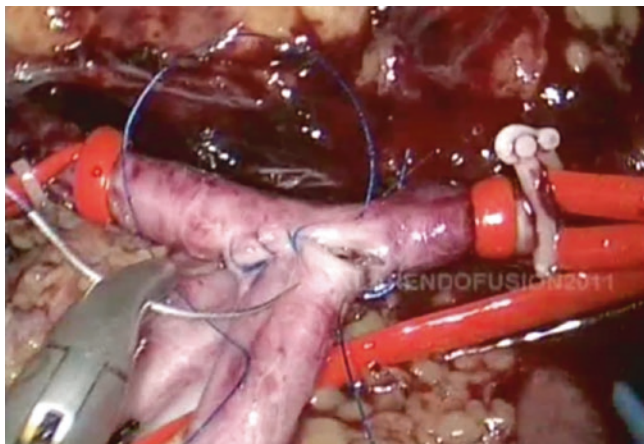


Fig. 59.33 Arterial anastomosis – anterior layer in progress

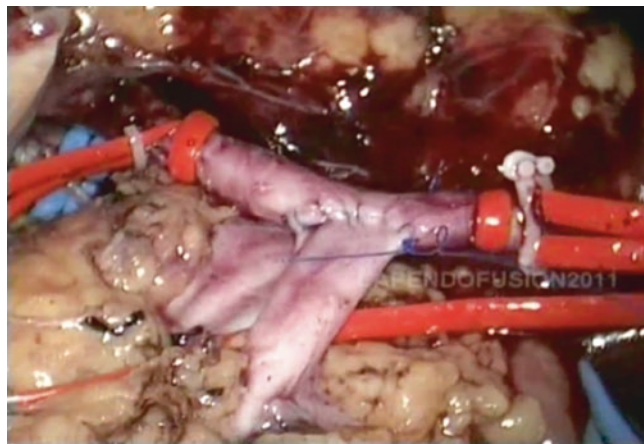


Fig. 59.34 Completed artery anastomosis

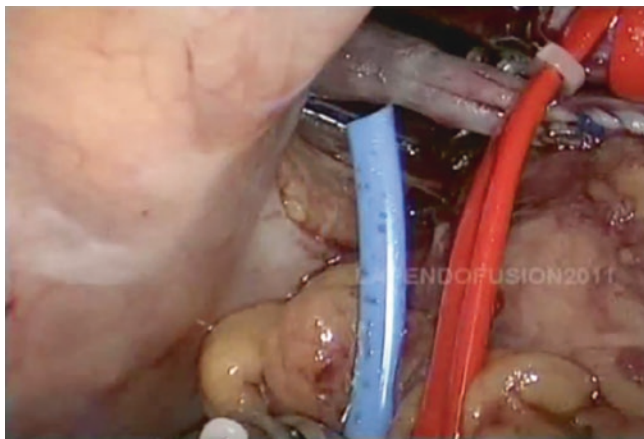


Fig. 59.35 Venous clamp released first

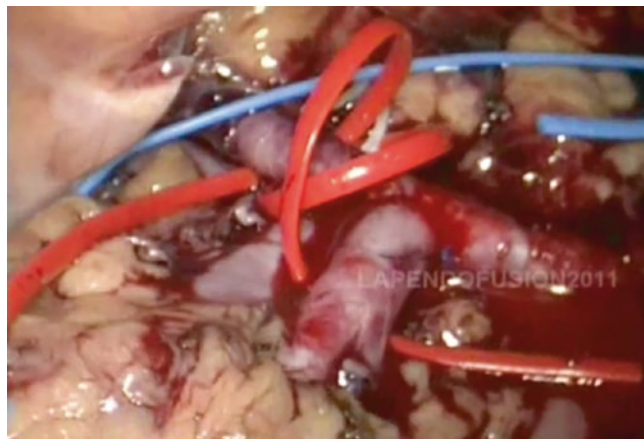


Fig. 59.36 Arterial and venous clamps released

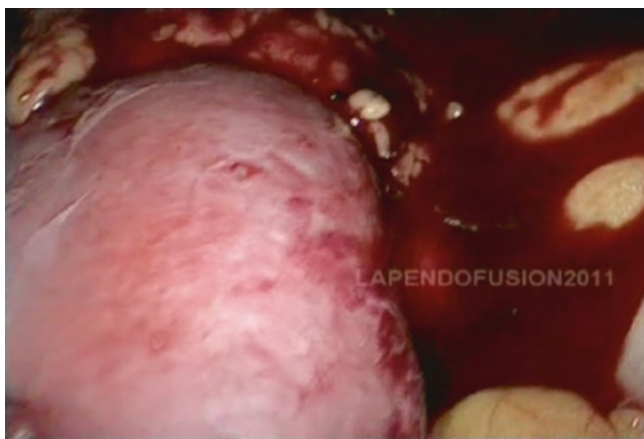

Fig. 59.37 Well perfused kidney after release of clamps

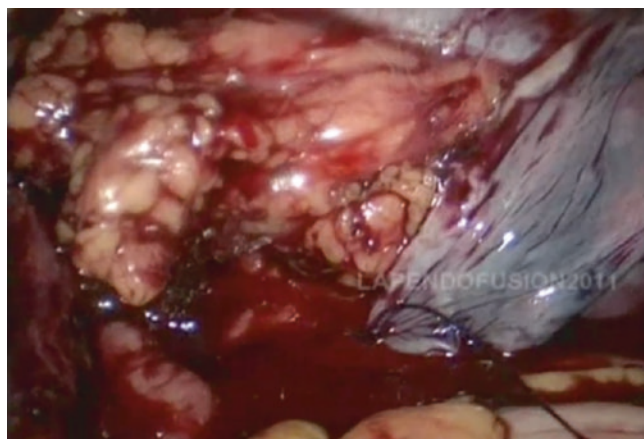

Fig. 59.38 Peritoneal flap cover for the kidney

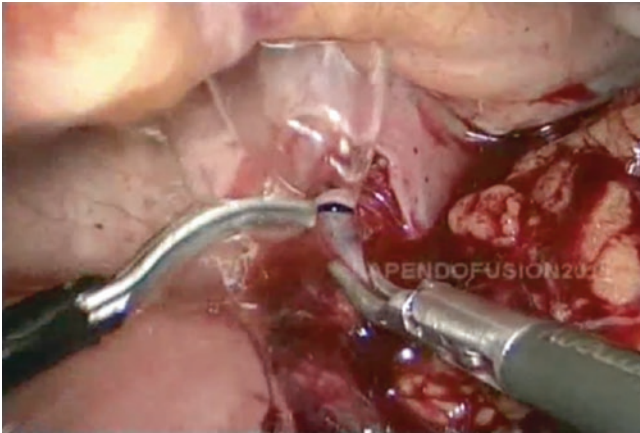


Fig. 59.39 Cystotomy for reimplantation

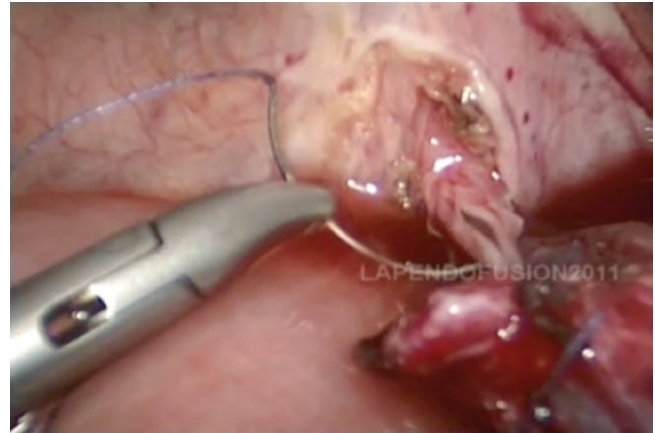

Fig. 59.40 Reimplantation with 4-0 vicryl in progress

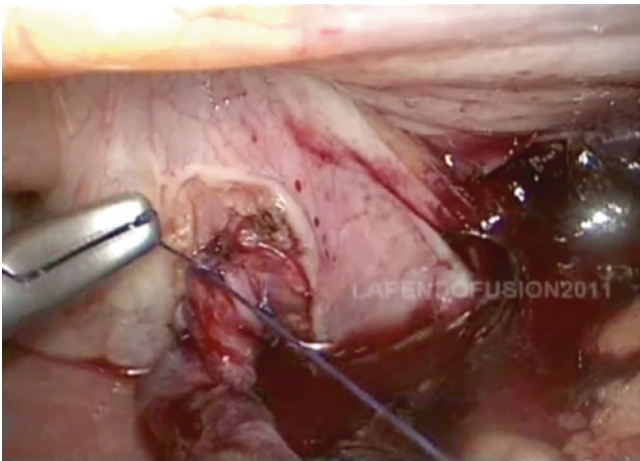


Fig. 59.41 Reimplantation in progress

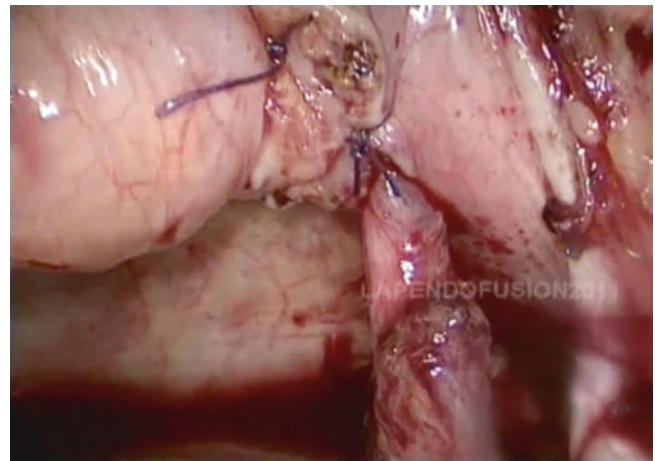


Fig. 59.42 Second layer of detrusor closure with 3-0 vicryl complete

References

1. Rosales A, Salvador JT, Urdaneta G, Patino D, Montlleo M, Esquena S, et al. Laparoscopic kidney transplantation. *Eur Urol*. 2010;57:164–7.
2. Castillo OA, Peacock L, Vitagliano G, Pinto I, Portalier P. Laparoscopic repair of an iliac artery injury during radical cystoprostatectomy. *Surg Laparosc Endosc Percutan Tech*. 2008;18(3):315–8.
3. Ferrari M, Adami D, Berchiolli R, Del Corso A, Pietrabissa A. Laparoscopic-assisted treatment of abdominal aortic aneurysm requiring suprarenal cross clamping. *J Vasc Surg*. 2009;50:1006–11.
4. Fournau I, Lerut P, Sabbe T, Houthoofd S, Daenens K, Nevelsteen A. The learning curve of totally laparoscopic aortofemoral bypass for occlusive disease. How many cases and how safe? *Eur J Vasc Endovasc Surg*. 2008;35:723–9.
5. Modi P, Rizvi J, Pal B, Bharadwaj R, Trivedi P, Trivedi A, et al. Laparoscopic kidney transplantation: an initial experience. *Am J Transplant*. 2011;11(6):1320–4.
6. Modi P, Pal B, Modi J, Singla S, Patel C, Patel R, Padhy S, et al. Retroperitoneoscopic living donor nephrectomy and laparoscopic kidney transplantation: experience of initial 72 cases. *Transplantation*. 2013;95(1):100–5.
7. Modi P, Thyagaraj K, Rizvi SJ, Vyas J, Padhi S, Shah K, et al. Laparoscopic en bloc kidney transplantation. *Indian J Urol*. 2012;28(2):230–1.
8. Modi P, Pal B, Kumar S, Modi J, Saifee Y, Nagaraj R, Qadri J, Sharmah A, Agrawal R, Modi M, Shah V, Kute V, Trivedi H. Laparoscopic transplantation following transvaginal insertion of the kidney: description of technique and outcome. *Am J Transplant*. 2015;15(7):1915–22.

60.1 Introduction

Minimally invasive approach in the field of renal transplantation has largely been restricted to laparoscopic donor nephrectomy. Wound related complications do occur in recipients and may compromise graft outcome [1]. Laparoscopic renal transplantation has not been taken up except in a very few centers. The inherent difficulty of laparoscopic vascular suturing, risk of increasing warm and cold ischemia, necessity of incision to place the graft and air tight closure prior to commencing anastomosis are the reasons behind it [2]. We describe our robot assisted approach side stepping most of these drawbacks, with results equivalent to open surgery, and benefits of minimally invasive surgery to the patients.

60.2 Indications

All the patients of end stage renal disease are potential robotic renal transplantation candidates. Patients with very poor cardio respiratory reserve may not tolerate the Trendelenberg position and pneumoperitoneum and hence are not ideal candidates. History of previous intraperitoneal surgeries is a relative contraindication.

A. Murugesan

Department of Urology, PSG Institute of Medical Sciences and Research, Peelamedu, Coimbatore, Tamil Nadu, India
e-mail: anandan79@gmail.com

P. Ghosh

Department of Urology and Renal Transplantation, Medanta Hospitals, Gurgaon, Haryana, India

R. Ahlawat (✉)

Division of Urology and Renal Transplant, Fortis Escorts Kidney and Urology Institute, Okhla Road, New Delhi, India
e-mail: rajesh.ahlawat@fortishealthcare.com

60.3 Procedure

Surgery is performed under general anesthesia. Patient is placed in low lithotomy position with 15–20° Trendelenberg tilt. After creating pneumoperitoneum, ports are placed as described in the picture. It is similar to that of prostatectomy. Robot is docked between the legs. Peritoneum is incised anterior to the iliac vessels on the right side and the external iliac artery and vein are dissected off the surrounding fibrous tissues. This step is similar to iliac lymphadenectomy. Vessels are completely mobilized, from the level of iliac bifurcation to superior pubic ramus. Internal iliac vein is clipped and cut as and when necessary.

Bladder is dropped and the Retzius space is developed anteriorly. Bladder is filled and a small incision is made in the dome for ureteric reimplantation. Submucosal plane is developed using sharp shears and a small tunnel is created proximally. Mucosa is incised and stay suture is taken in the distal end of the mucosal incision.

Peritoneal incision is extended lateral to the iliac vessels, and proximally the cecum is dissected and reflected superomedially. This creates a triangular flap for placing the graft in the retroperitoneum. The graft bed preparation is complete now and the robot is undocked.

Camera port is removed and a 5 cm circum umbilical incision is made and Gelpoint® port is placed. Fine ice slush is placed in the graft bed and over the bladder. Graft is placed and robot is docked.

Preparation of graft kidney after harvest is important in robotic renal transplantation. The graft is enclosed in ice slush and covered with gauze. A silk thread is placed at the upper pole for identification. Vessels are brought out through a hole in the gauze medially.

Graft is oriented and placed medial to the vessels. Bulldog clamps are placed for proximal and distal control on the vein around the selected anastomotic site. External iliac vein is incised at the selected site and flushed with saline to remove collected blood and clots. Renal vein is anastomosed to

external iliac vein using 6-0 PTFE sutures, end to side, in a continuous manner. PTFE is preferred to prolene due its easier handling. After anastomosis is complete, renal vein is clamped and iliac vein continuity restored.

Similar to the vein, the selected segment of the external iliac artery is isolated using bull dog clamps. A small incision is made using Snapfit® and desired opening created using aortic punch. The aortic punch is inserted through the Gelpoint®. The arterial segment is flushed and 6-0 PTFE continuous sutures are used for arterial anastomosis. After the completion of the anastomosis, clamps are released.

The gauze is cut and removed from the graft. Once the integrity of the anastomosis is confirmed, the graft is flipped laterally and the peritoneal flaps are used to cover it, using clips to keep them in place.

Ureter is brought out beneath the vas and the previously made detrusor tunnel. 4-0 PDS continuous sutures are used for uretero vesical anastomosis. Posterior layer is sutured first followed by anterior layer. Stent is placed after completion of the posterior layer. Detrusorraphy is done using braided sutures (3-0 V-loc®). Drain is placed over the graft through

the left lateral port site. Robot is undocked and port sites are closed.

60.4 Advantages

The main benefit of robot assisted renal transplantation is the smaller incision and as a result lesser chances of post operative infection. The additional benefit we have reported is the absence of post operative lymphocele [3]. In our series we have found no difference in the graft function compared to open renal transplantation.

60.5 Conclusion

Robotic renal transplantation is a relatively complex surgical procedure. The smaller incision in the immune compromised patients definitely decreases the chances of post operative wound infections while there is no deterioration in the overall graft function.

60.6 Robot Assisted Renal Transplantation

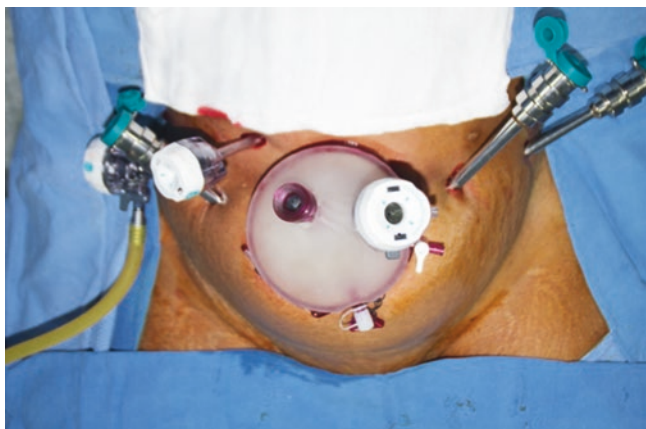


Fig. 60.1 Gelpoint in situ with ports inserted

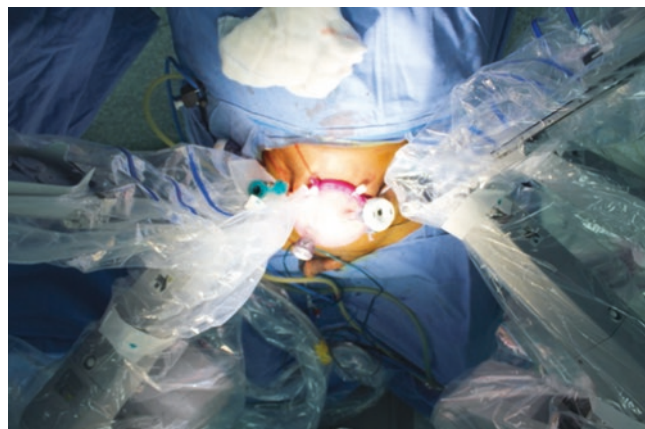


Fig. 60.2 Robot docked with Gelpoint in place

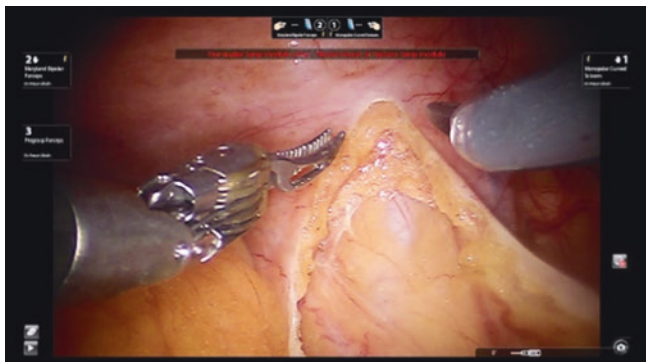

Fig. 60.3 Peritoneal incision over iliac vessels

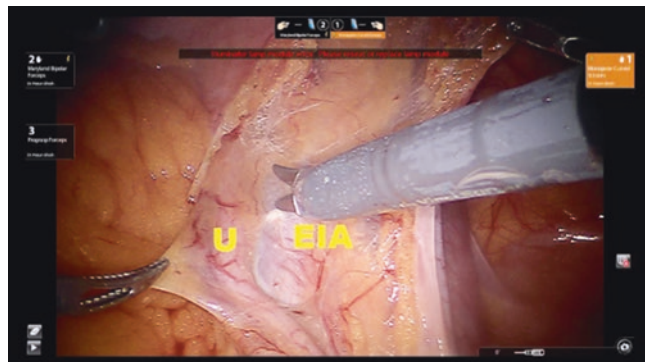


Fig. 60.4 Native ureter seen; *U* ureter

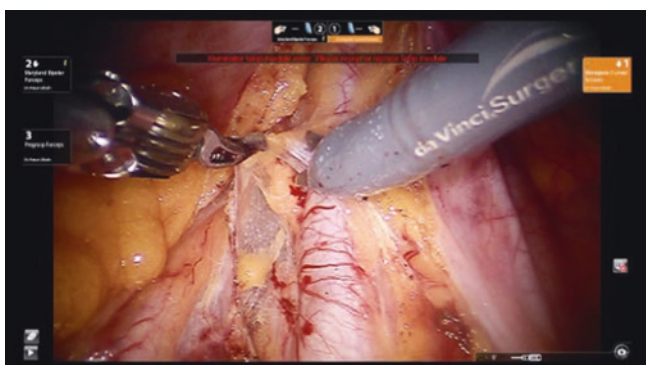


Fig. 60.5 External iliac artery dissection in progress

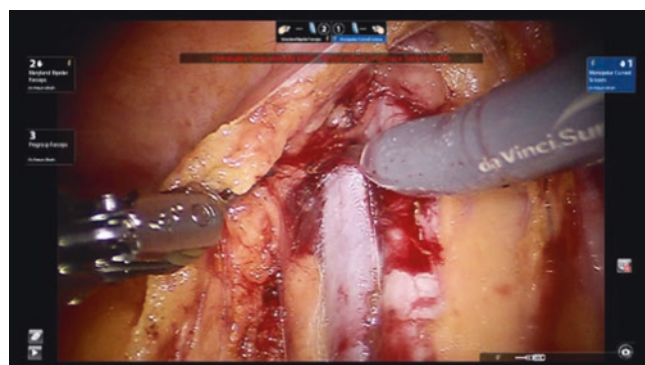


Fig. 60.6 External iliac vein dissection in progress

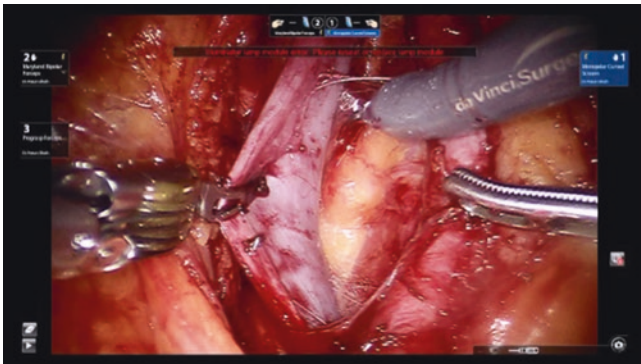


Fig. 60.7 External iliac vein dissection almost complete

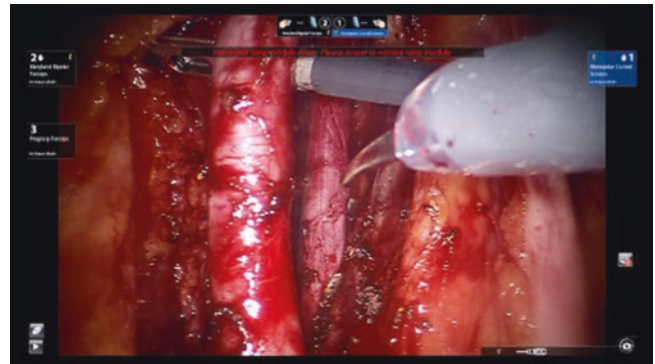


Fig. 60.8 External iliac artery completely mobilised

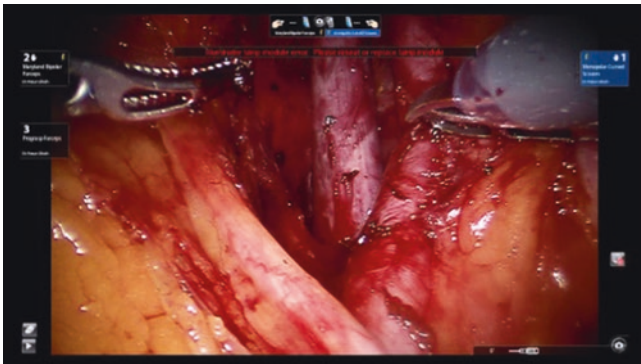


Fig. 60.9 External iliac vein completely mobilised

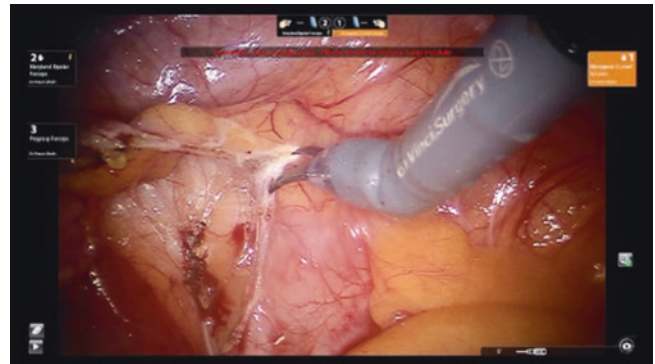


Fig. 60.10 Development of peritoneal flap in right iliac fossa started

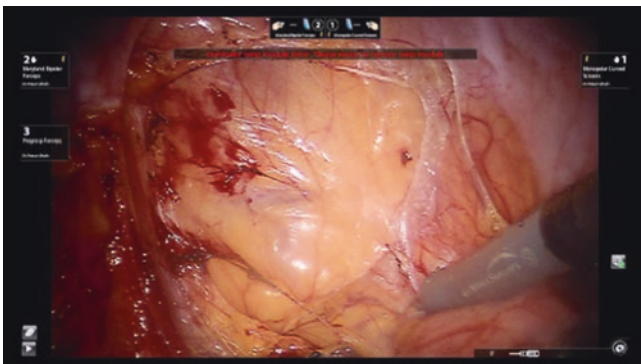


Fig. 60.11 Peritoneal flap fully developed

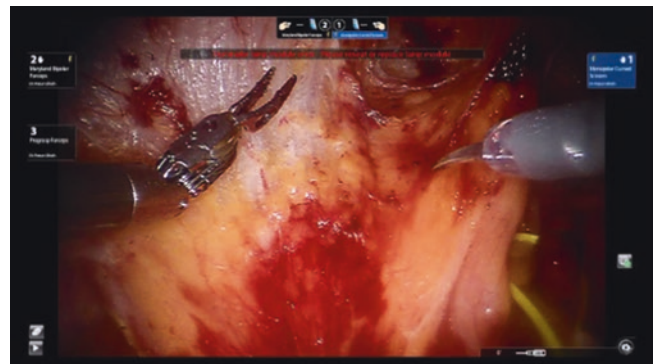


Fig. 60.12 Bladder drop in progress

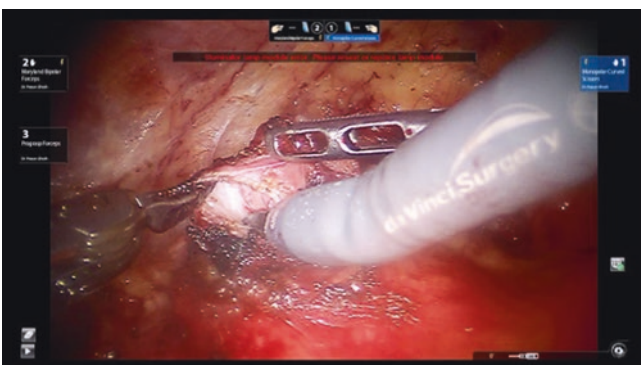


Fig. 60.13 Developing sub-mucosal plane in the bladder

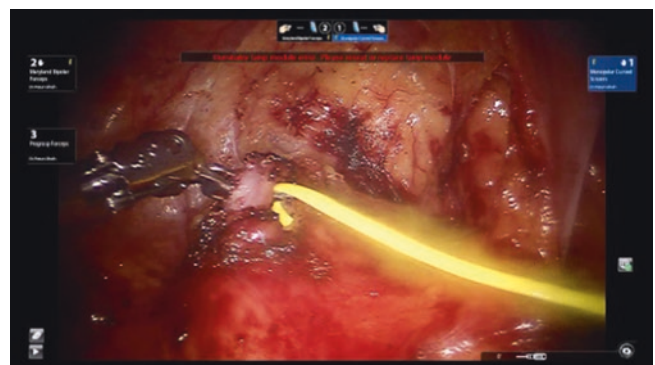


Fig. 60.14 Sub-mucosal tunnel developed

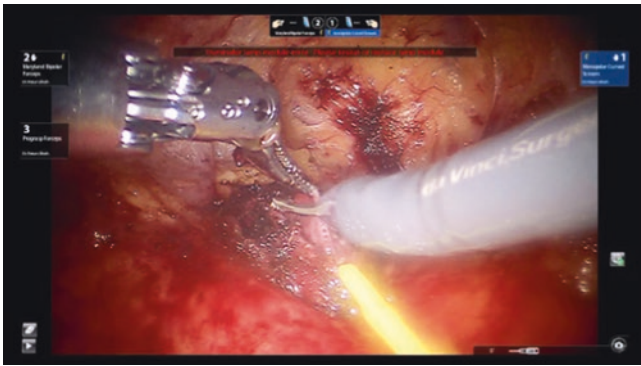


Fig. 60.15 Bladder mucosa incised

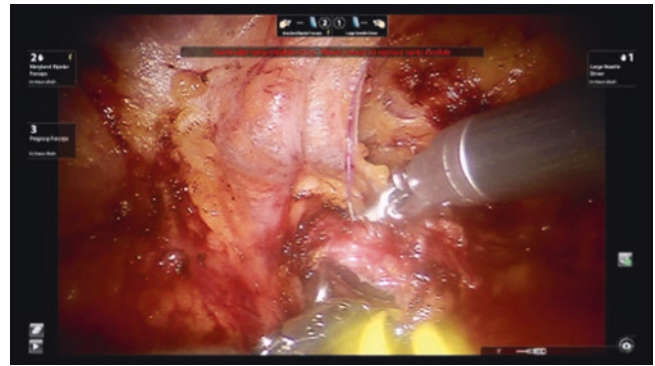


Fig. 60.16 Stay suture at the distal end of vesicotomy

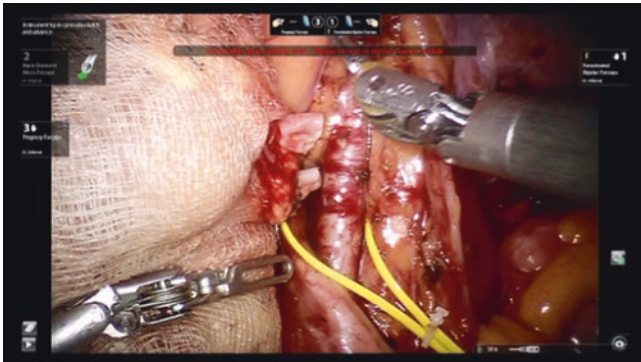


Fig. 60.17 Donor kidney placed medial to the iliac vessels

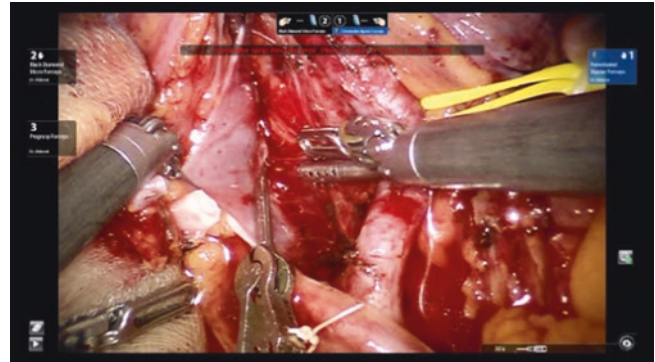


Fig. 60.18 External iliac vein clamped with bulldog clamps

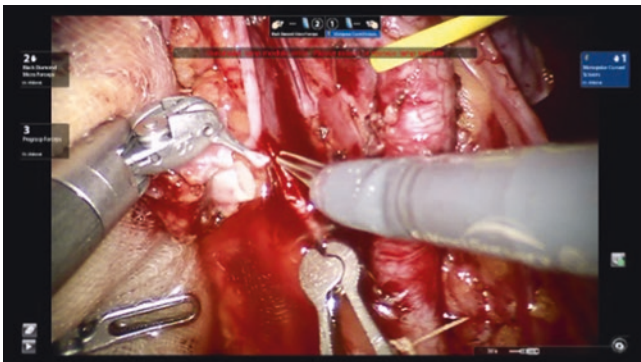


Fig. 60.19 Venotomy being done

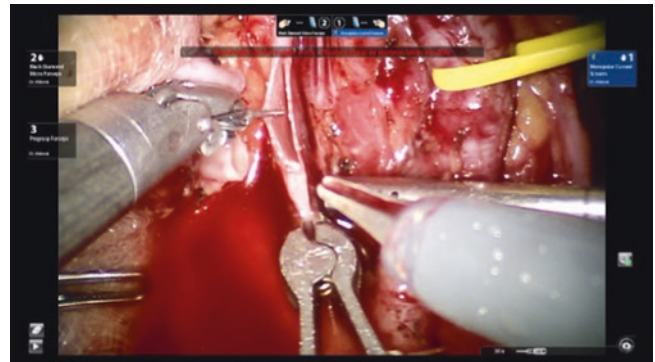


Fig. 60.20 Completed venotomy

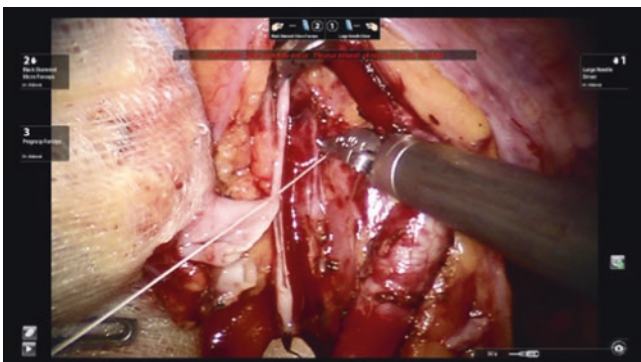


Fig. 60.21 Venous anastomosis started with 5-0 PTFE suture

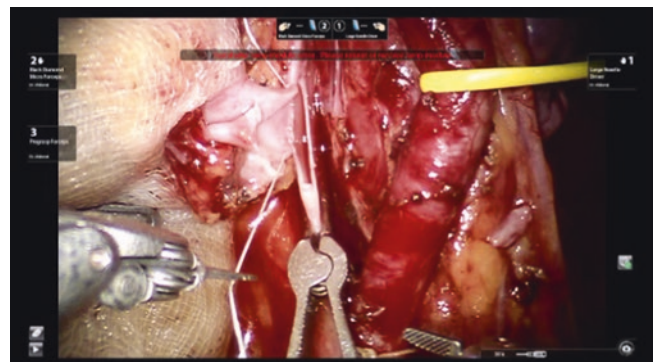


Fig. 60.22 Continuous suture of medial wall in progress

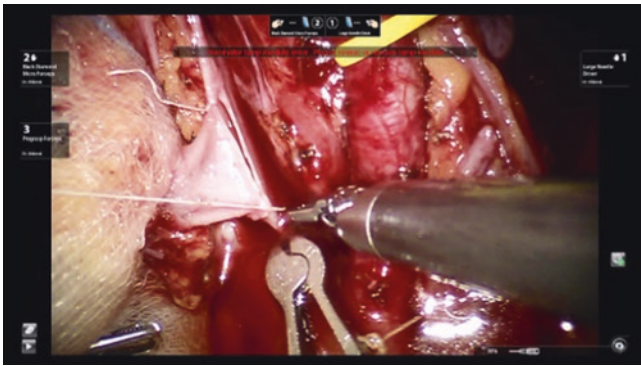


Fig. 60.23 Anastomosis of the medial wall of vein complete

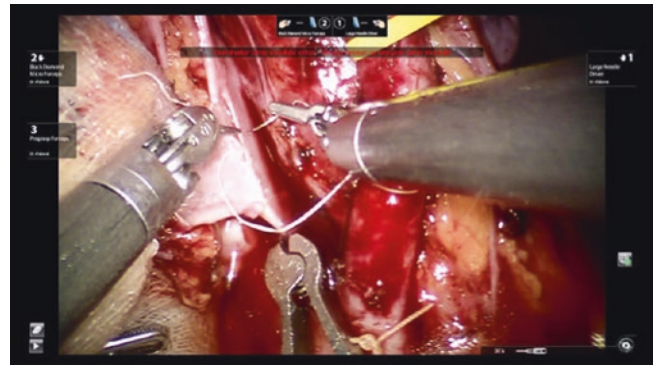


Fig. 60.24 Lateral wall anastomosis in progress

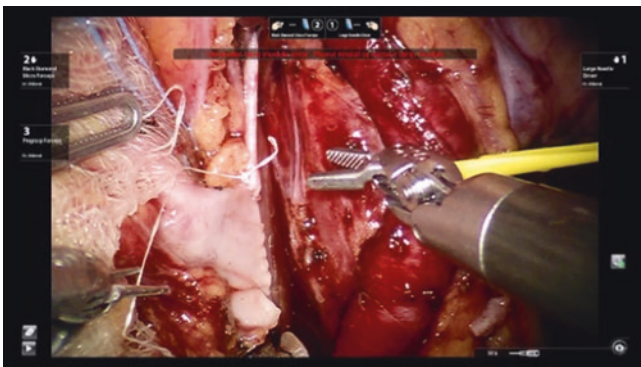


Fig. 60.25 Vein anastomosis complete

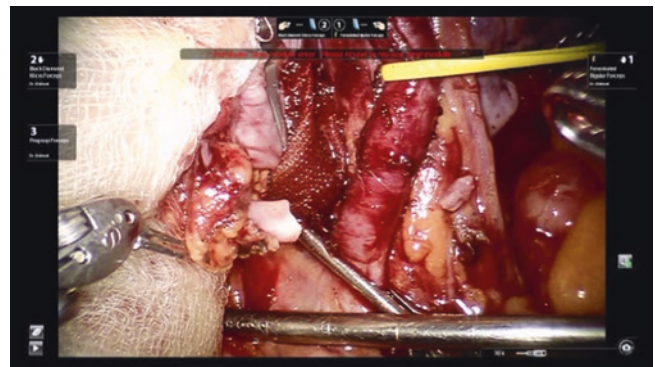


Fig. 60.26 External iliac artery clamped with bulldog clamp

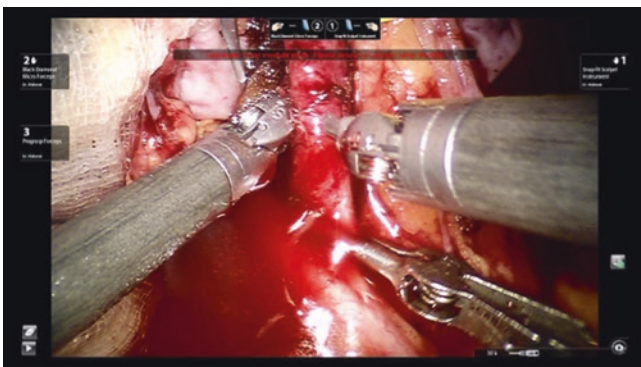


Fig. 60.27 Arteriotomy with knife

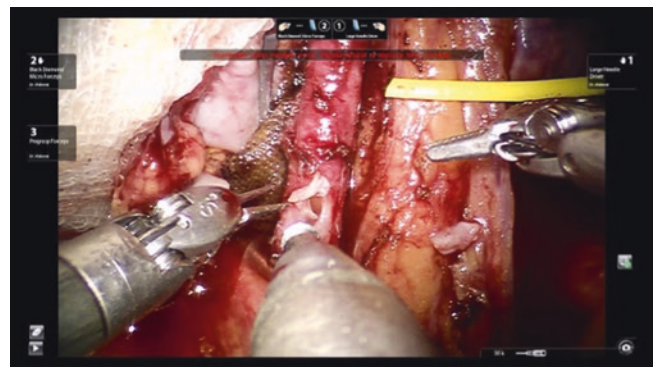


Fig. 60.28 Arteriotomy extended with vessel punch

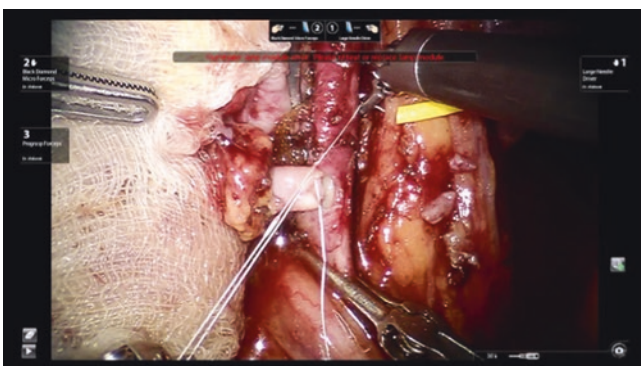


Fig. 60.29 Arterial anastomosis with 6-0 PTFE suture started

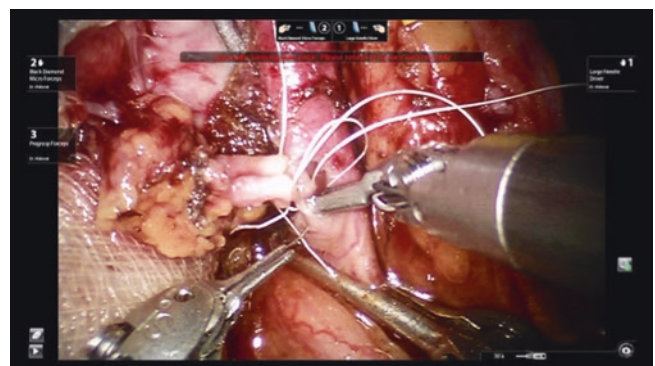


Fig. 60.30 Suturing of medial wall of artery in progress

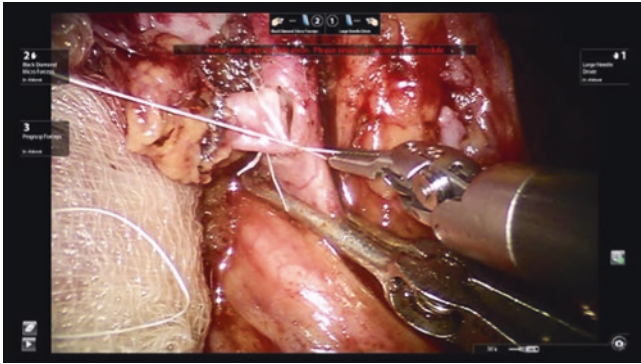


Fig. 60.31 Medial wall suturing complete

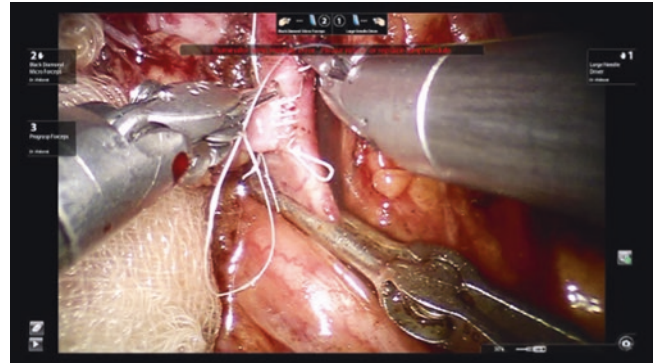


Fig. 60.32 Lateral wall suturing in progress

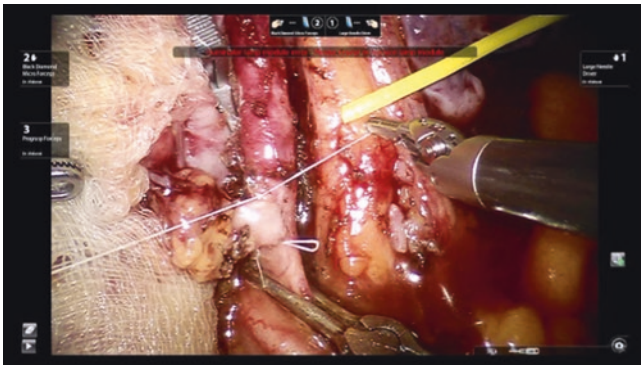


Fig. 60.33 Arterial anastomosis completed

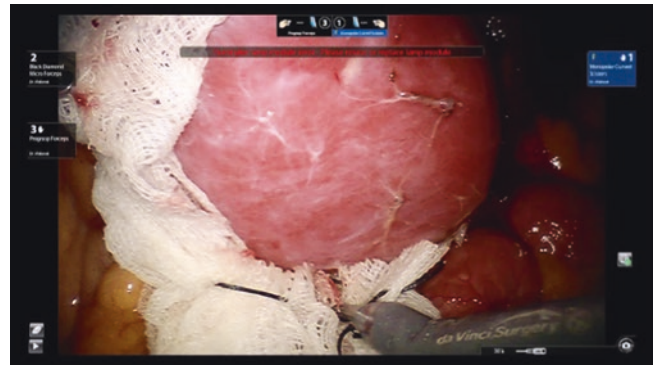


Fig. 60.34 Kidney well perfused after release of clamps

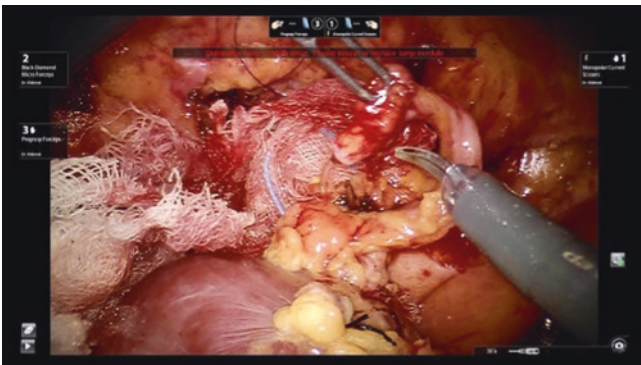


Fig. 60.35 Urine efflux seen

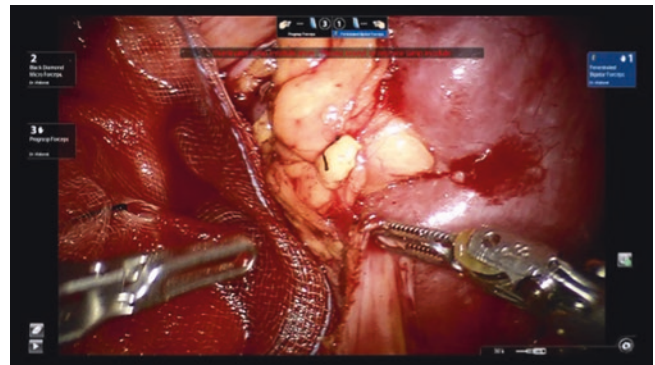


Fig. 60.36 Kidney flipped laterally

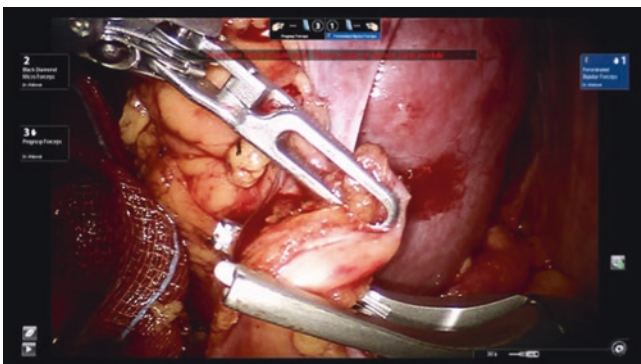


Fig. 60.37 Kidney being retroperitonealised by tacking already mobilised peritoneal flap

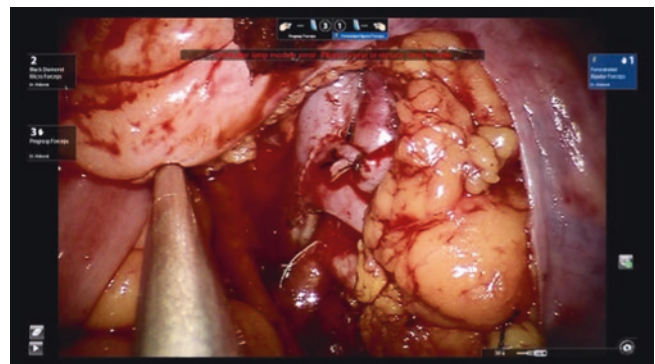


Fig. 60.38 Arterial and venous anastomosis seen

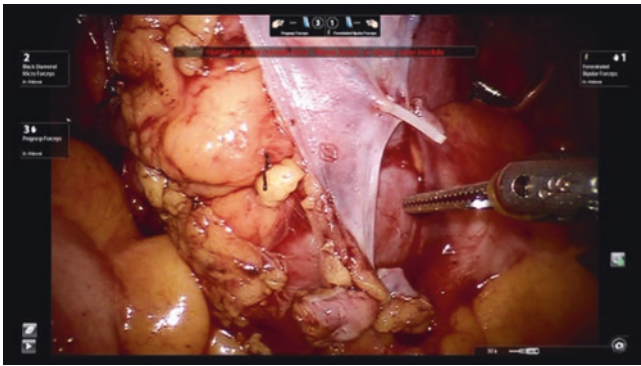


Fig. 60.39 Kidney retroperitonealised

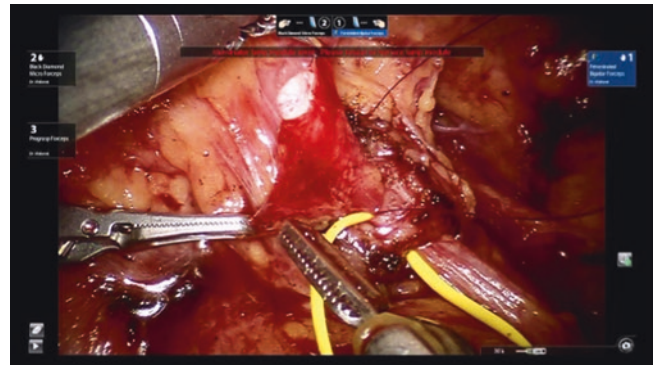


Fig. 60.40 Ureter pulled through submucosal tunnel

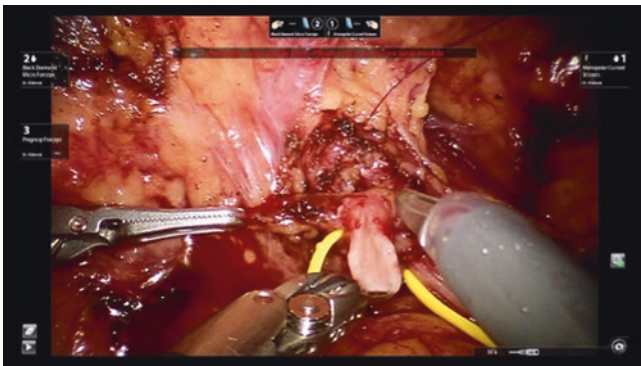


Fig. 60.41 Ureter spatulated

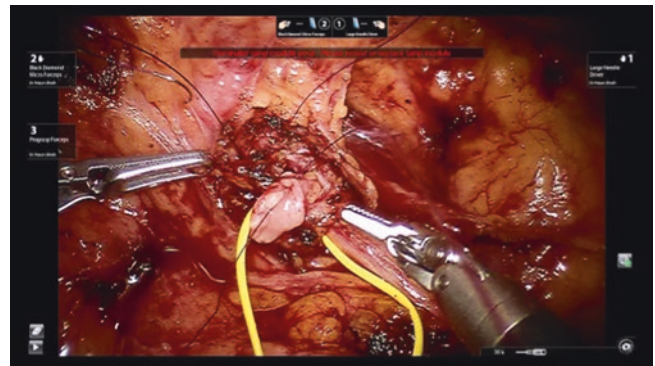


Fig. 60.42 Uretero vesical anastomosis started with 4-0 PDS suture

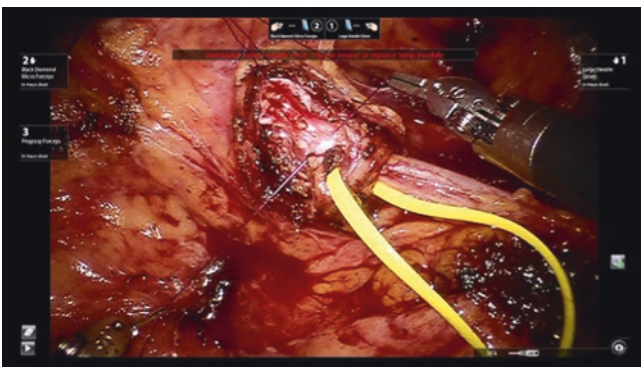


Fig. 60.43 Uretero-vesical anastomosis in progress

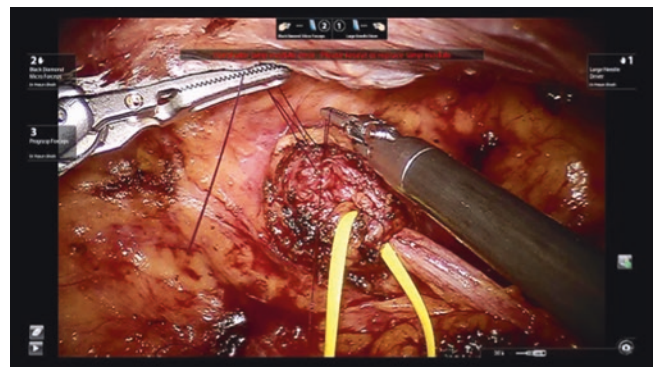


Fig. 60.44 Medial wall suturing completed

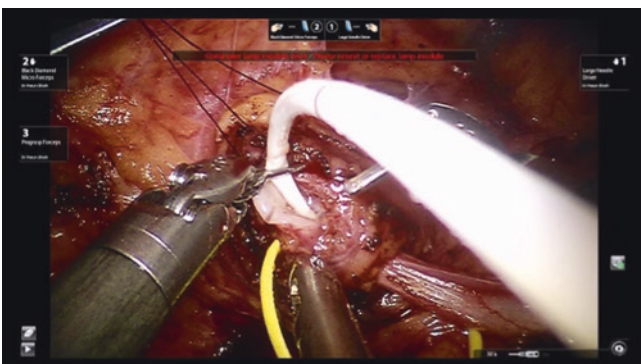


Fig. 60.45 Stent insertion

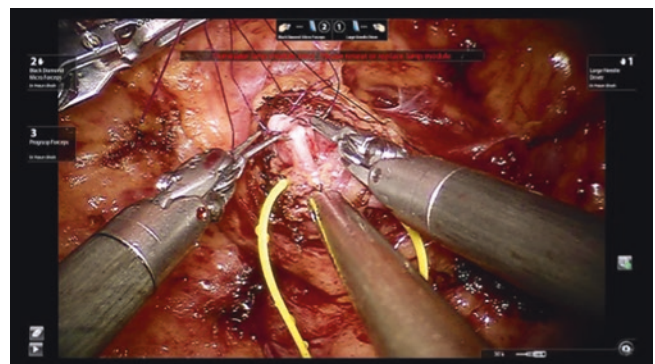


Fig. 60.46 Lateral wall suturing in progress

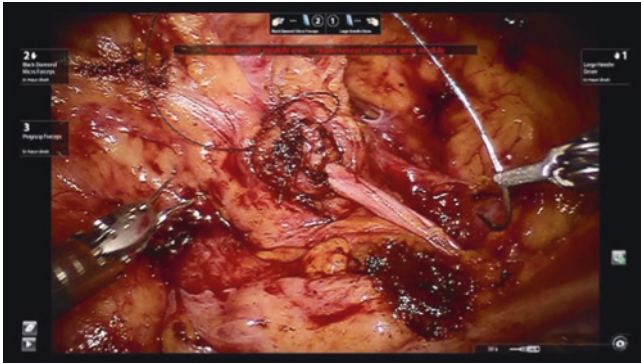


Fig. 60.47 Second layer of continuous suturing with 3-0 V Loc suture in progress

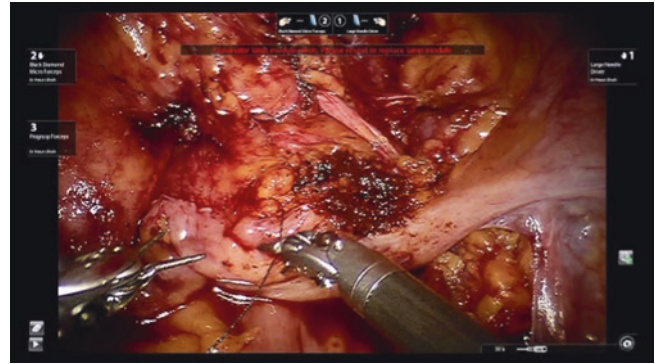


Fig. 60.48 Completed reimplantation

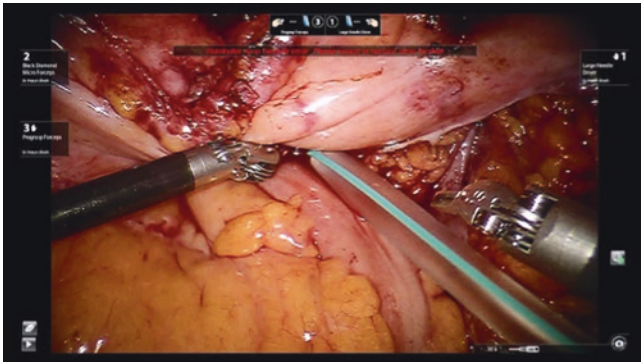


Fig. 60.49 Drain placed

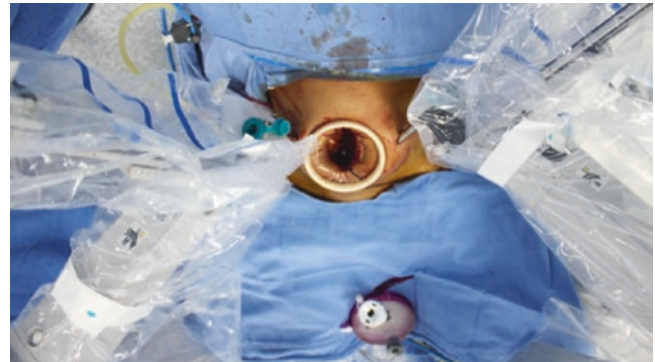


Fig. 60.50 Inner ring of Gelpoint in place

References

1. Kuo JH, Wong MS, Perez RV, Li CS, Lin TC, Troppmann C. Renal transplant wound complications in the modern era of obesity. *J Surg Res.* 2012;173(2):216–23.
2. Modi P, Rizvi J, Pal B, Bharadwaj R, Trivedi P, Trivedi A, Patel K, Shah K, Vyas J, Sharma S, Shah K, Chauhan R, Trivedi H. Laparoscopic kidney transplantation: an initial experience. *Am J Transplant.* 2011;11(6):1320–4.
3. Sood A, Ghosh P, Menon M, Jeong W, Bhandari M, Ahlawat R. Robotic renal transplantation: current status. *J Minim Access Surg.* 2015;11(1):35–9.

Part IX

Reconstructive Surgery for Uterine and Vaginal Prolapse

Laparoscopic Pelvic Floor Repair for Anterior Compartment Prolapse

61

Jean-Luc Hoepffner, Richard Gaston,
and Thierry Piechaud

61.1 Introduction

Symptomatic anterior compartment prolapse needs surgical intervention. Laparoscopic pelvic floor repair is a well accepted minimally invasive approach for this condition [1, 2].

61.2 Technique

61.2.1 Step I

The patient is placed in modified lithotomy position. The assistant uses a retractor from the vaginal end. Using four ports (subumbilical camera port, two ports in the midclavicular line on either side and a right flank port) the pelvis is inspected.

61.2.2 Step II

Initially the peritoneum over sacral promontory is incised and peritoneotomy extended down to pelvic floor. The uterosacral ligament, ischial spine (and arcus tendinus) are defined.

61.2.3 Step III

Strengthening of the posterior compartment of pelvic floor.

A ribbon of soft polypropylene mesh is tailored to the need. Caudally the mesh is fixed to posterior vaginal wall with 2 – 0 prolene to strengthen the uterosacral ligament. The lateral aspect of mesh is fixed to sacrospinous ligament just medial to ischial spine. All the time the assistant stabilises the posterior fornix.

61.2.4 Step IV

Dissection of anterior compartment.

The vesico uterine space is developed until bladder is adequately freed from anterior vaginal wall. Common limb of Y shaped soft prolene mesh ribbon is fixed to anterior vaginal wall. The two limbs of Y shaped mesh, are brought posteriorly through a rent made in the broad ligament on both sides.

61.2.5 Step V

Uterosacral ligament pexy.

The proximal ends of both mesh ribbons are fixed to presacral ligaments with 2 – 0 prolene suture, keeping the mesh at optimum tension [3].

61.2.6 Step VI

Peritoneal edges are sutured over the mesh. Ports are sutured.

J.-L. Hoepffner, MD (✉)
Surgeon, Lap and Robotic Oncological Urologic Surgery, Clinique
Saint-Augustin, 114 Avenue Dares, 33074 Bordeaux, France
e-mail: j.hoepffner@bordeaux.unicancer.fr

R. Gaston, MD • T. Piechaud, MD
Clinique Saint-Augustin, 114 Avenue Dares, 33074 Bordeaux,
France

Conclusion

Laparoscopic uterosacral ligament hysteropexy is an accepted less morbid option. In our experience of over

3,000 patients, the success rate has been very high. The mesh erosion is a rare complication. Laparoscopic approach is less morbid and appealing.

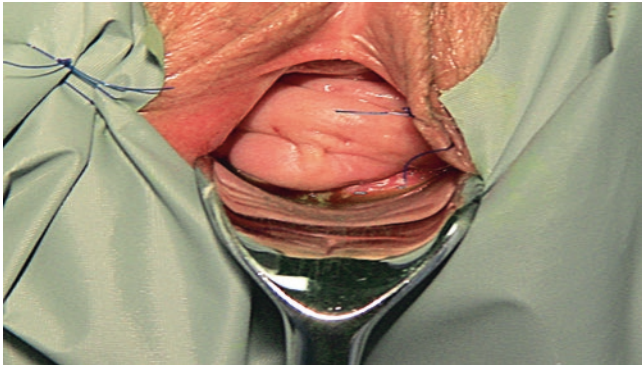

Fig. 61.1 Uterine prolapse with cystocele

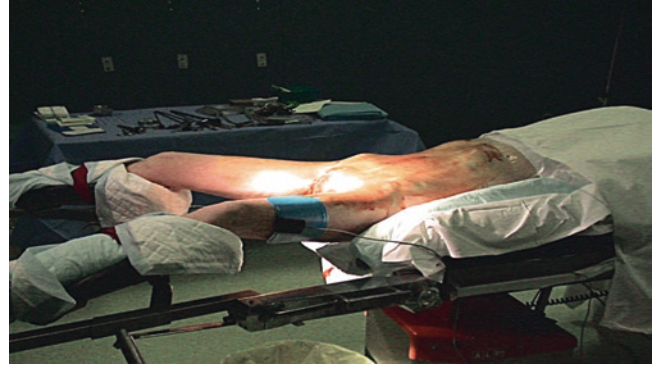

Fig. 61.2 Patient placed in modified lithotomy position

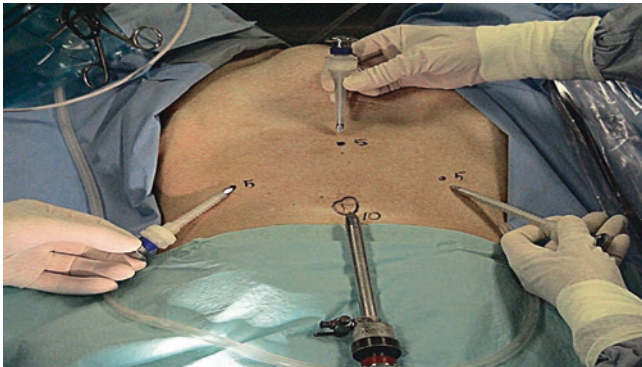


Fig. 61.3 Ports position

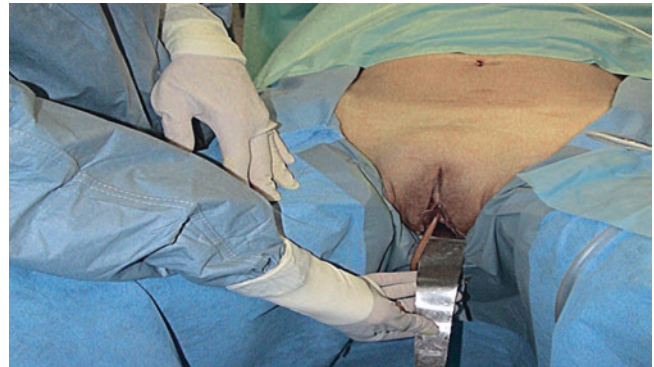

Fig. 61.4 Deaver retractor placed vaginally helps to angulate the fornix

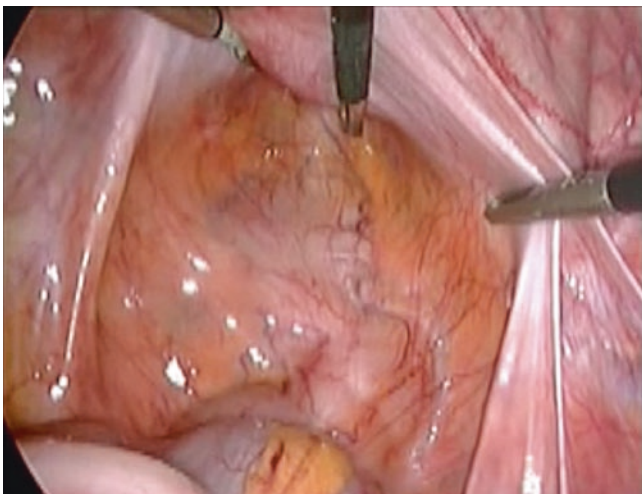


Fig. 61.5 Initial view of pelvis

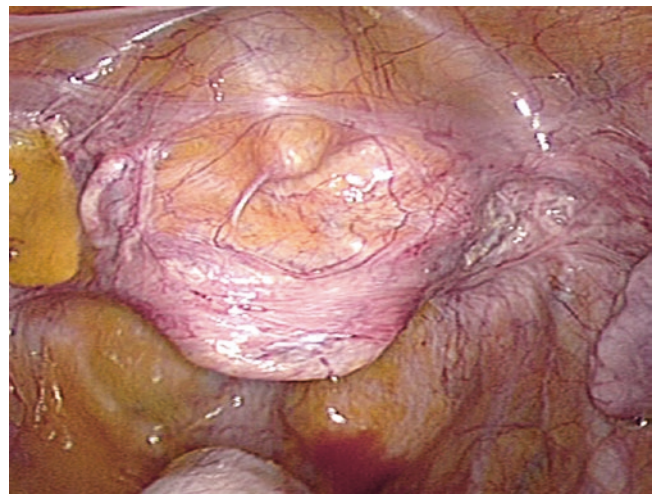


Fig. 61.6 Endo view showing the Deaver retractor helping to angulate the fornix

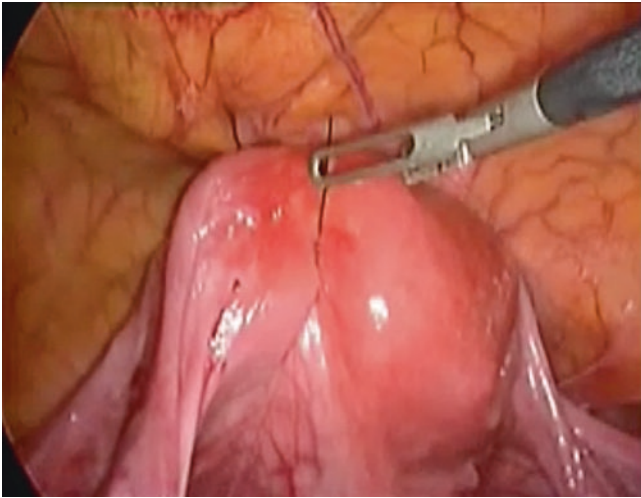


Fig. 61.7 Uterus is suspended anteriorly

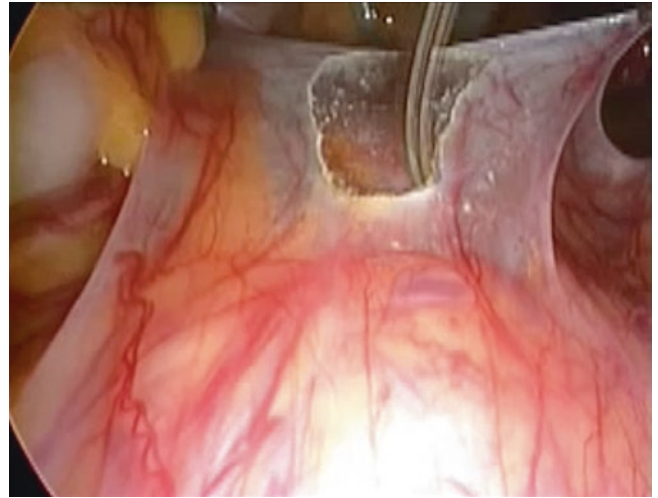


Fig. 61.8 Incision of peritoneum over sacral promontory

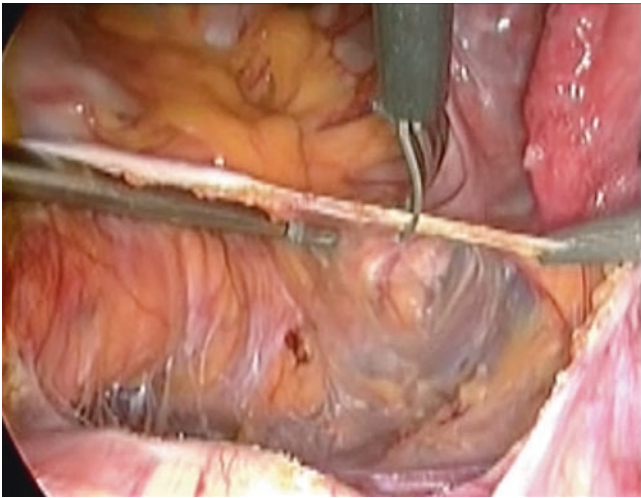


Fig. 61.9 Peritoneal incision extended inferiorly up to pelvic floor

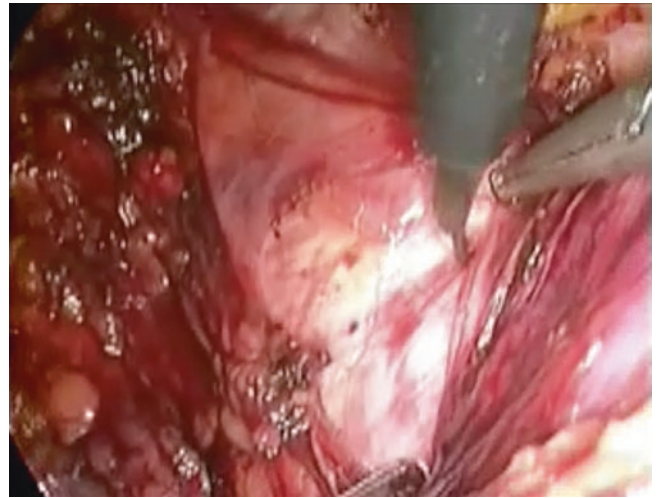


Fig. 61.10 Dissection along right levator ani

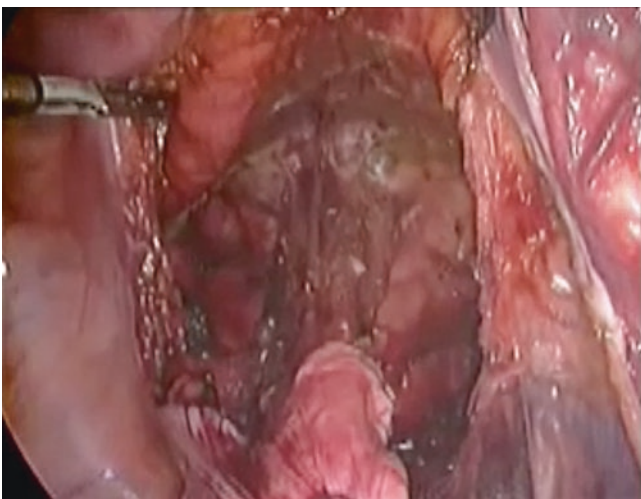


Fig. 61.11 Pararectal dissection completed on both sides

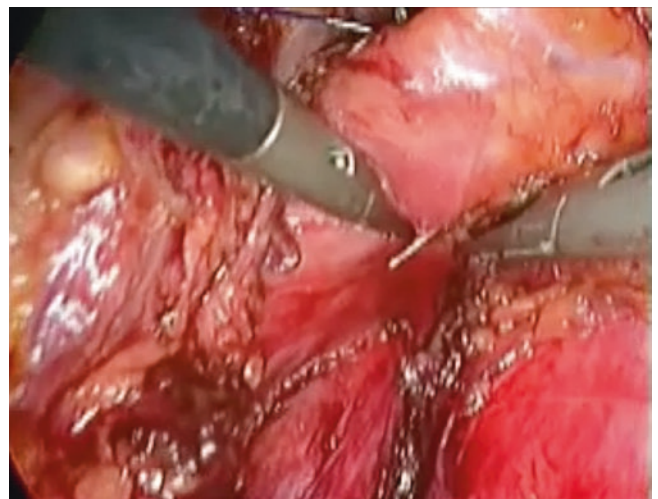


Fig. 61.12 Suture through right levator ani

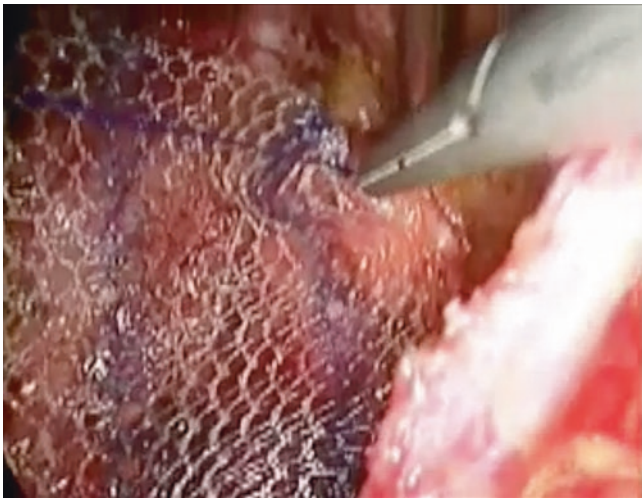


Fig. 61.13 One limb of mesh fixed to right levator ani using 2-0 prolene suture

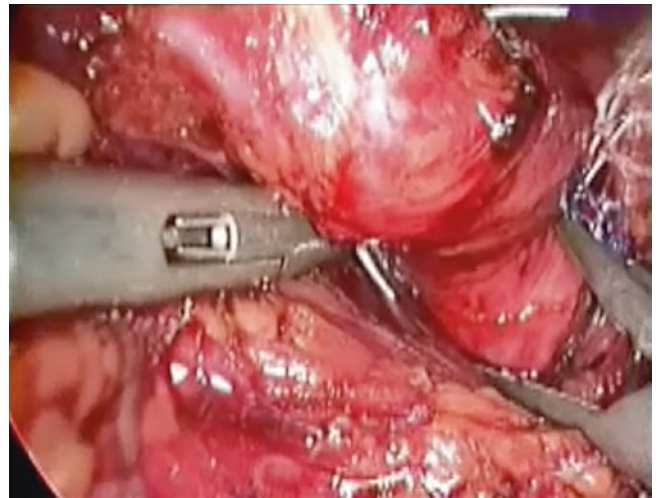


Fig. 61.14 Similar suture through left levator ani

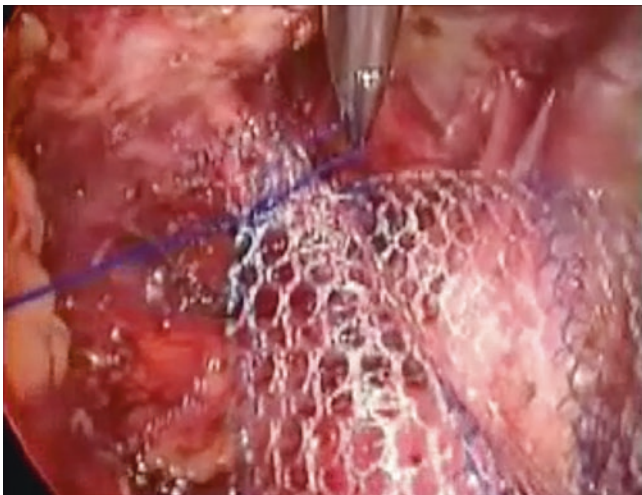


Fig. 61.15 Mesh fixed to left levator ani

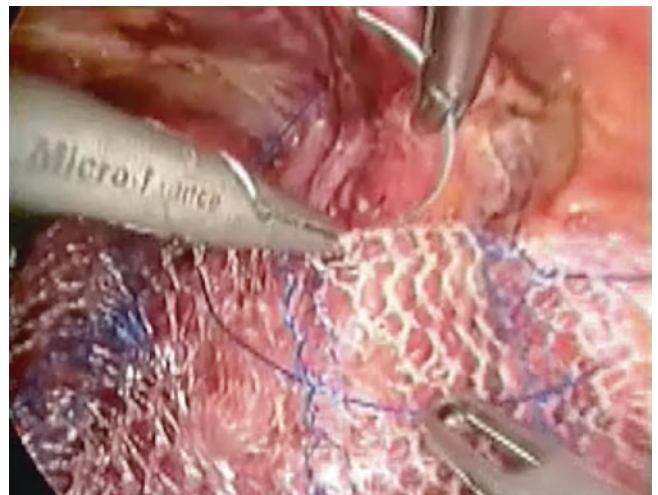


Fig. 61.16 Mesh fixed to uterosacral ligament

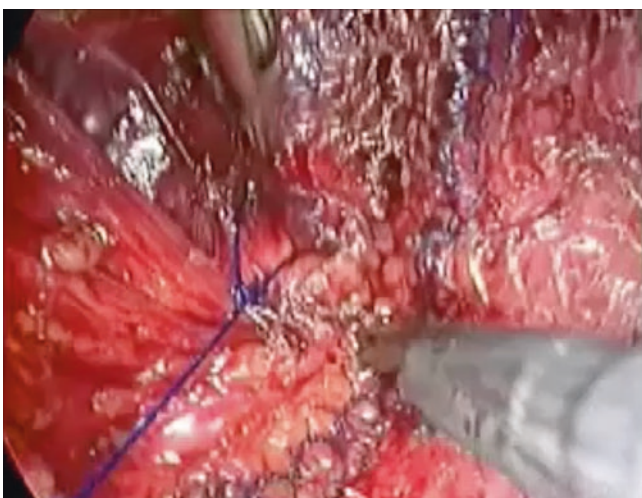


Fig. 61.17 Mesh anchored to lateral pelvic wall

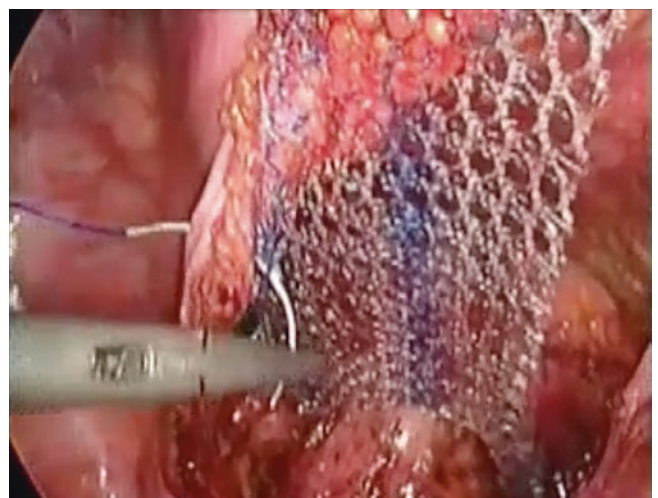


Fig. 61.18 Mesh fixed to left Meckenrodt ligament

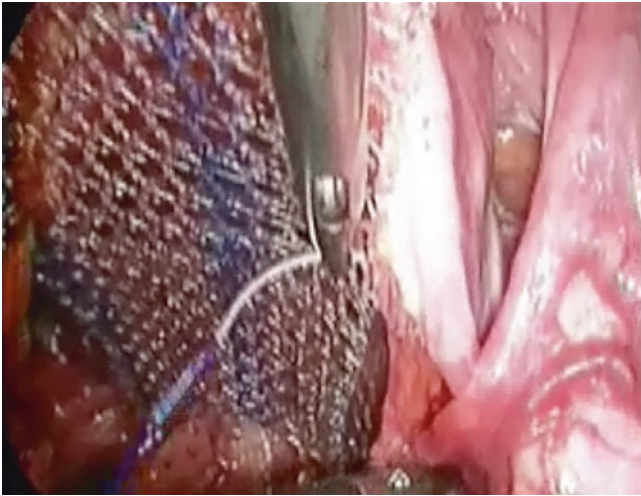


Fig. 61.19 Mesh fixed to right Mecklenrodt ligament

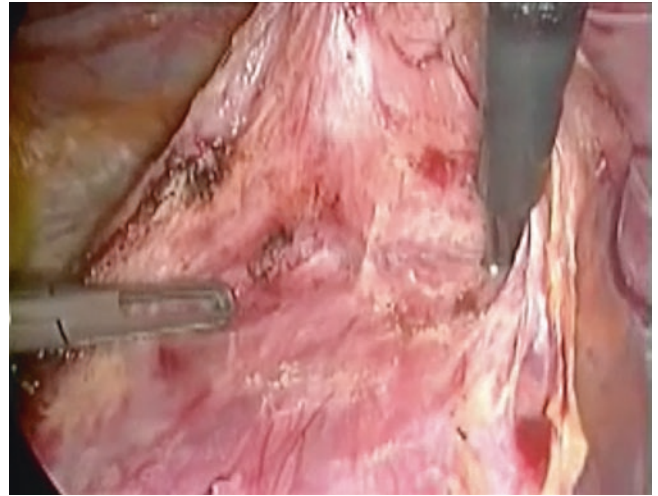


Fig. 61.20 After releasing uterine stitch, plane between bladder and anterior vaginal wall developed

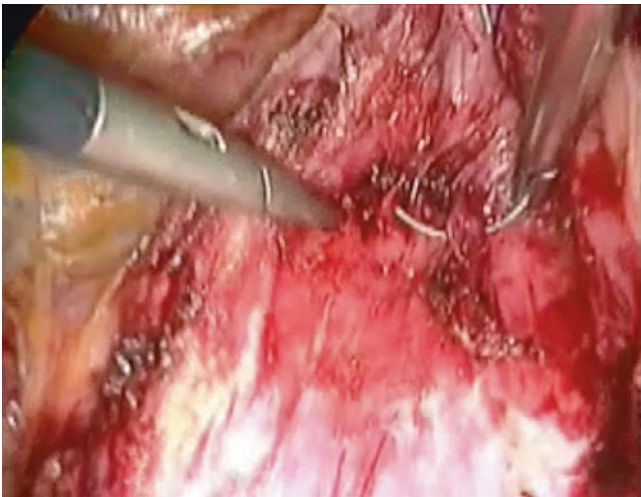


Fig. 61.21 Suture with 3-0 prolene through anterior vaginal wall

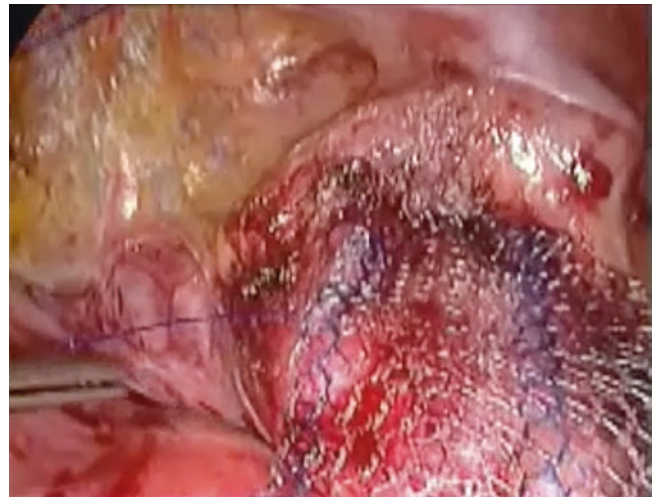

Fig. 61.22 Another limb of mesh fixed in the vesico uterine pouch

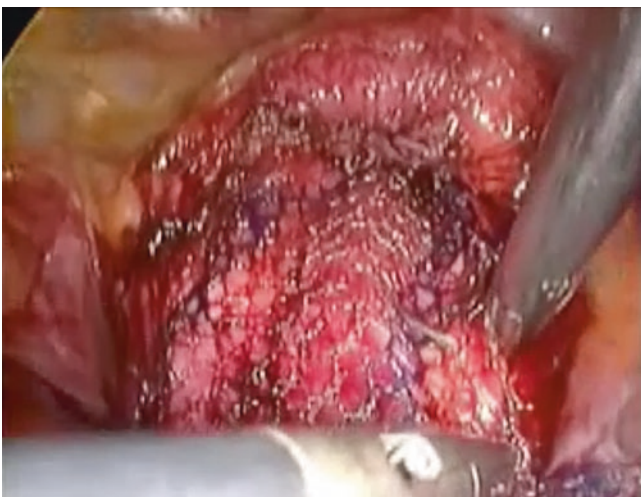


Fig. 61.23 Mesh anchored anteriorly

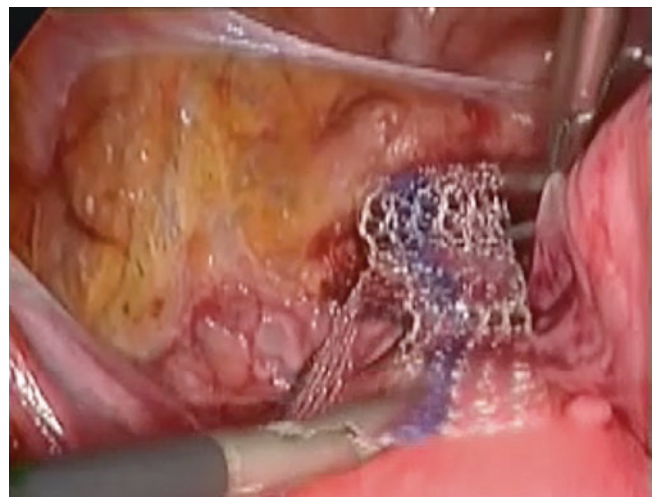


Fig. 61.24 Limbs of mesh tunneled through broad ligament

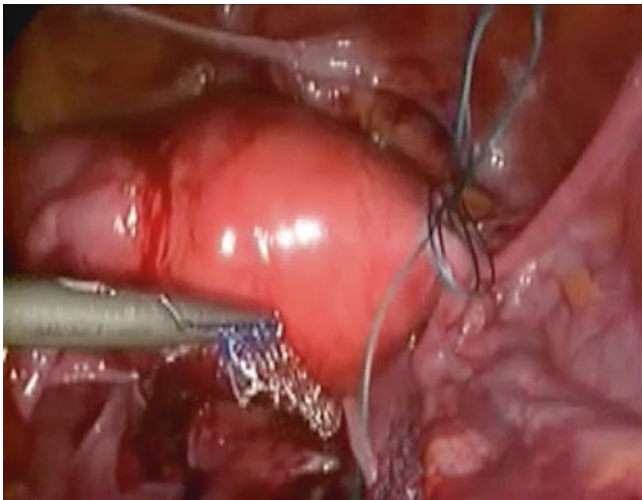


Fig. 61.25 Limbs of mesh tunneled through broad ligament

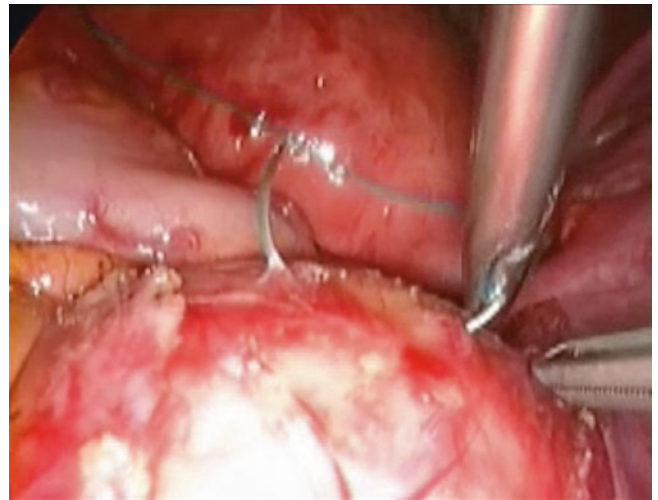


Fig. 61.26 Suture through sacral promontory

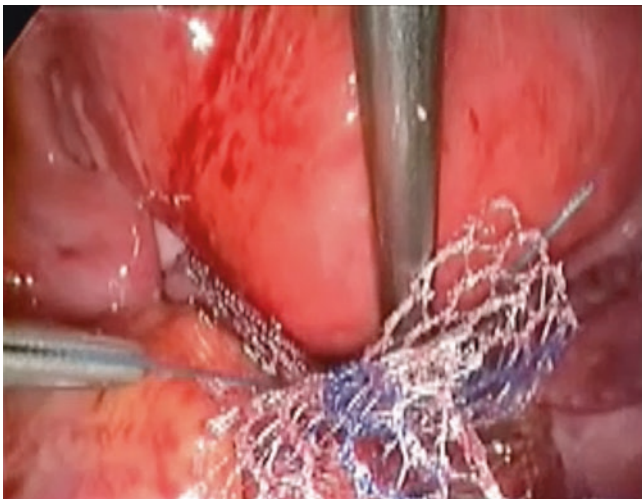


Fig. 61.27 Mesh fixed to sacral promontory using 1-0 prolene

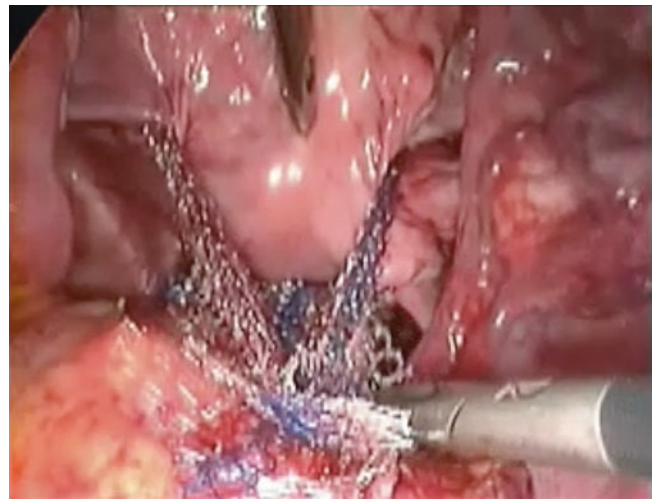


Fig. 61.28 Posterior repair completed

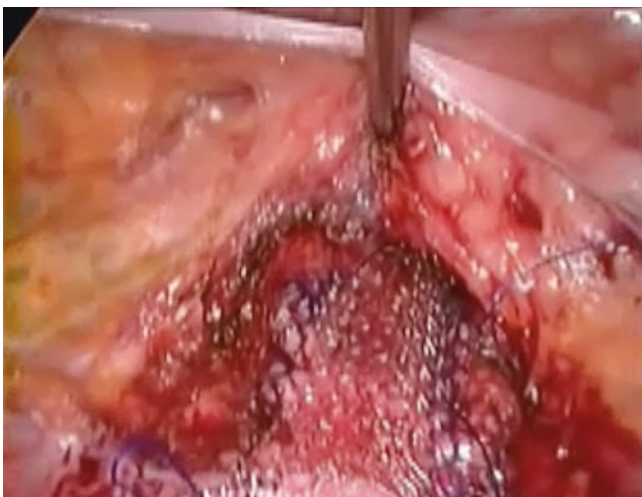


Fig. 61.29 Anterior compartment repair completed

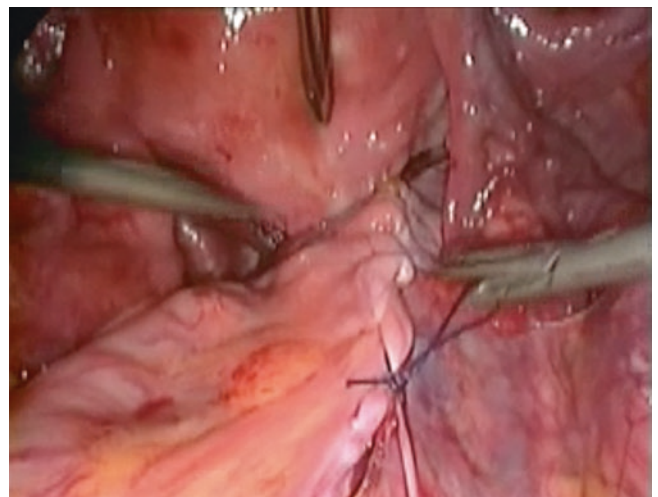


Fig. 61.30 Final view after retroperitonealising the mesh

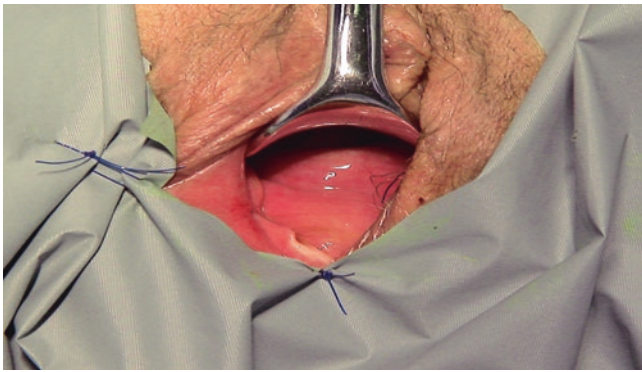


Fig. 61.31 Prolapse corrected- post procedure view

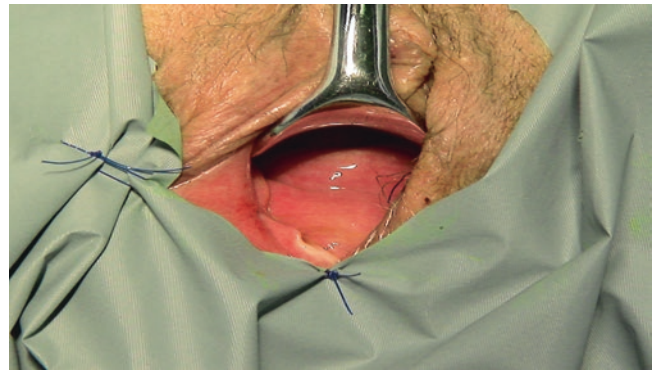


Fig. 61.32 External view after pelvic floor repair

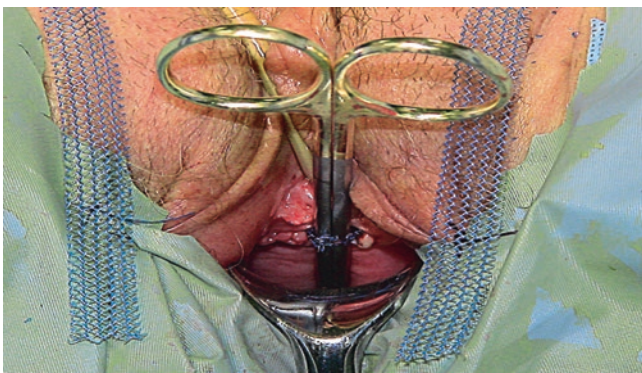


Fig. 61.33 Midurethral suspension (TVT) can be done if there is an associated stress urinary incontinence

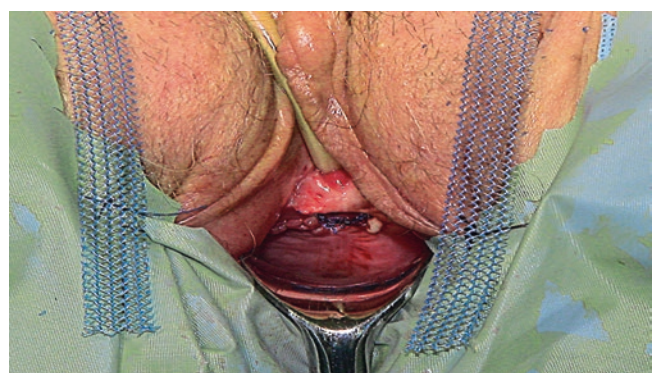


Fig. 61.34 Urethrovesical suspension (TVT) done

References

1. Miklos JR, Moore RD, Kohli N. Laparoscopic pelvic floor repair. *Obstet Gynecol Clin North Am.* 2004;31(3):551–65, viii–ix.
2. Miklos JR, Moore RD, Kohli N. Laparoscopic surgery for pelvic support defects. *Curr Opin Obstet Gynecol.* 2002;14(4):387–95.
3. Romero Sela E, Mugnier C, Piechaud PT, Gaston R, Hoepffner JL, Hanna S, Cusomano S. Laparoscopic promontofixation. *Actas Urol Esp.* 2010;34(10):837–44. Spanish. PMID: 21159278.

Ajay Rane, Jay Iyer, and Harsha Ananthram

62.1 Introduction

Laparoscopic sacrocolpopexy for Level 1 vaginal prolapse has demonstrated excellent anatomical and functional outcomes [1, 2]. Laparoscopy allows better exposure and surgical detail, reduces blood loss and the need for excessive abdominal packing and bowel manipulation, which all contributes to reduced morbidity.

62.2 Level I Defect

The support of the cervix, and in its absence, the apex of the vagina is provided by vertical and transverse fibres that have a broad origin at the sacrum and lateral pelvic wall (the uterosacral and cardinal ligaments), described by de Lancey as Level I supports. When these fail, uterine or vaginal vault prolapse occurs. Loss of apical support is associated with concomitant defects of the anterior or posterior wall in 67–100% of cases [3]. This is commonly caused by failure of adequate reattachment of the pericervical ring to the cuff at hysterectomy.

62.3 Technique

Patient is placed in a Lloyd Davies modified lithotomy position with port placement to suit the Surgeon's preference. The vagina is manipulated with a probe to define the vault and vaginal walls and to allow peritoneal dissection.

Anteriorly dissection of the parietal peritoneum exposes the apex of the pubovesical fascia; posteriorly, the apex of the rectovaginal septum.

Separation of the pubovesical and rectovaginal fascia exposes a coexisting cystocele or enterocele. On occasion, with a small enterocele, the sac can be plicated with permanent sutures to the vaginal apex or the lax anterior wall may need plication with the pubovesical fascia being attached to it. Larger enteroceles should be resected, with removal of excessive vaginal epithelium and a permanent Y-mesh applied to provide the necessary support. In women with diverticulosis, it is helpful to suture the appendices epiploicae to the anterior abdominal wall to help with retraction.

The next crucial step is identification of the sacral promontory and its relationship to the right ureter and the right common iliac vein. Deeper to the proposed peritoneal dissection lie the middle sacral vessels. A longitudinal incision of the peritoneum over the sacral promontory is carried out, extending to the cul-de-sac. The pneumoperitoneum helps expose underlying tissues – blunt dissection is then used to expose the anterior longitudinal ligament over the sacral promontory.

A Y shaped monofilament polypropylene mesh is then sutured in a tension-free manner to the vaginal vault using non absorbable sutures, with the vagina being placed in an anterior and cephalad direction. The free end of the Y-shaped mesh is then fixed to the anterior longitudinal ligament with non absorbable sutures, titanium tacks or staples. Complete peritoneal reapproximation helps cover the mesh internally.

A. Rane • J. Iyer (✉) • H. Ananthram
James Cook University, Townsville, QLD, Australia
e-mail: ajay.rane@jcu.edu.au; drsg2002@yahoo.co.uk;
harsha.ananthram@yahoo.com.au

62.4 Discussion

Tips to help achieve best outcome include:

1. Operate only on symptomatic vault prolapses, at least at stage II as per the Pelvic Organ Prolapse-Quantification system
2. Adequate bowel prep makes for better exposure of the promontory
3. Identify the border of L5-S1, the inferior limit of the left common iliac vein and the right ureter, to start dissection of the promontory. Maintain a view of the left ureter at all times whilst dissecting in the paravertebral space.
4. Carry out deep anterior and posterior dissection of the vaginal vault.
5. Avoid suturing the mesh to the enterocoele sac – this minimizes risk of surgical failure and mesh erosion.
6. Ensure full thickness suture attachment of the vagina (excluding vaginal epithelium).

62.5 Laparoscopic Sacrocolpopexy

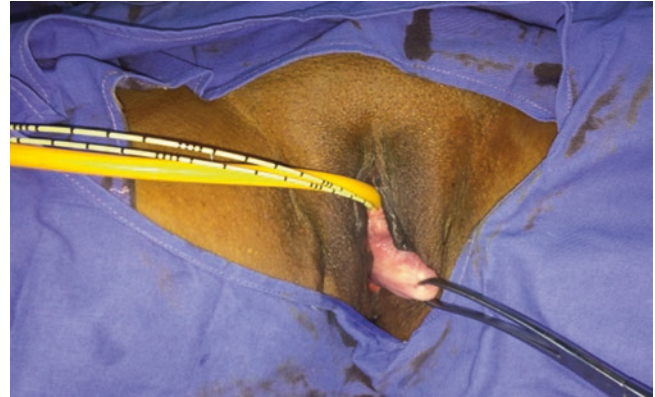


Fig. 62.1 Vault prolapse, post-vaginal hysterectomy. Note ureters catheterized

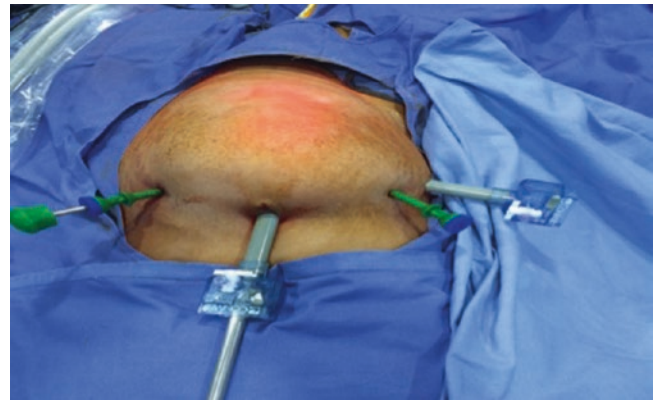


Fig. 62.2 Ports position

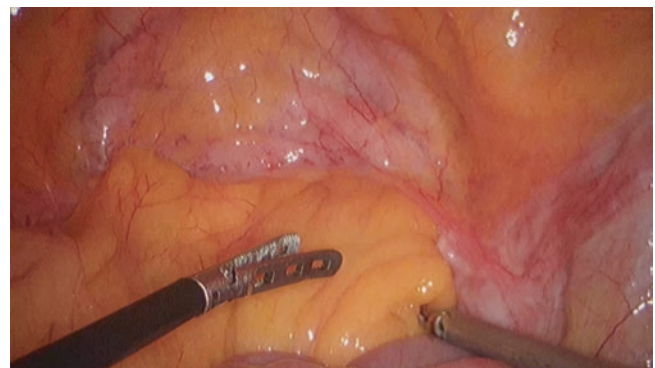


Fig. 62.3 Initial view of pelvic anatomy

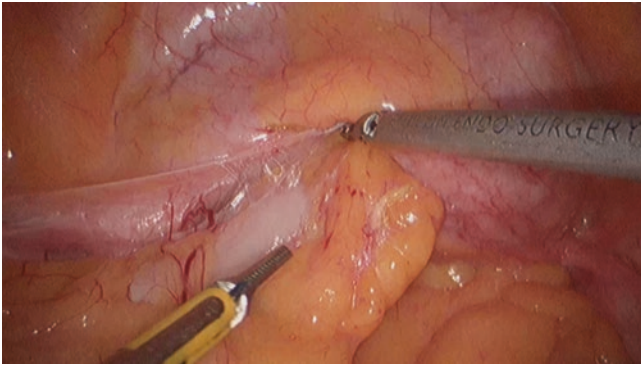


Fig. 62.4 Release of bowel adhesions

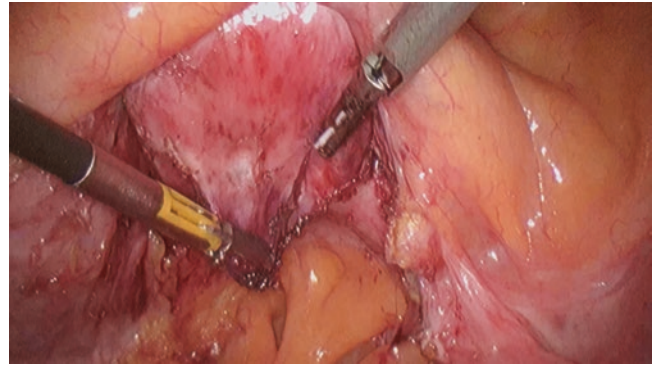


Fig. 62.5 Peritoneum dissected from posterior vaginal wall to create rectovaginal space

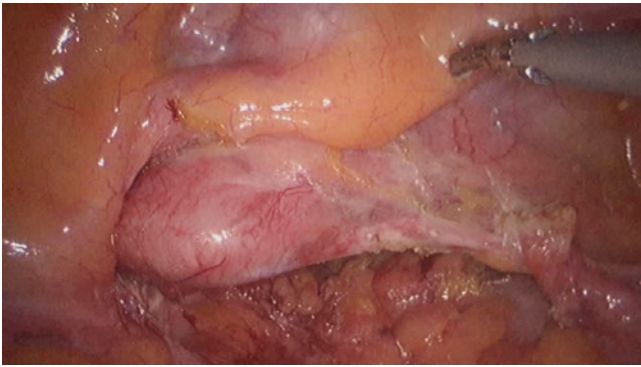


Fig. 62.6 Peritoneum released from the lateral vaginal wall. Deaver retractor used to manipulate vault

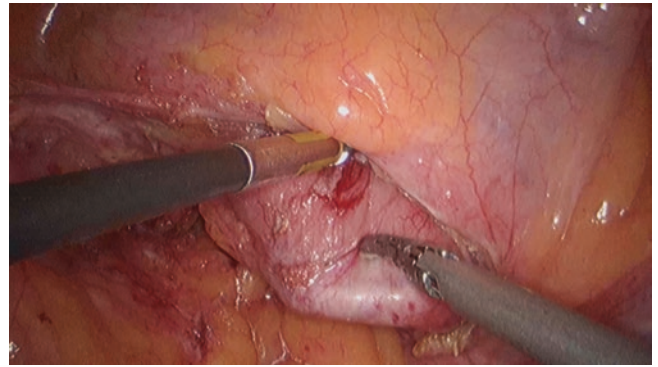


Fig. 62.7 Bladder mobilisation from anterior vaginal wall started

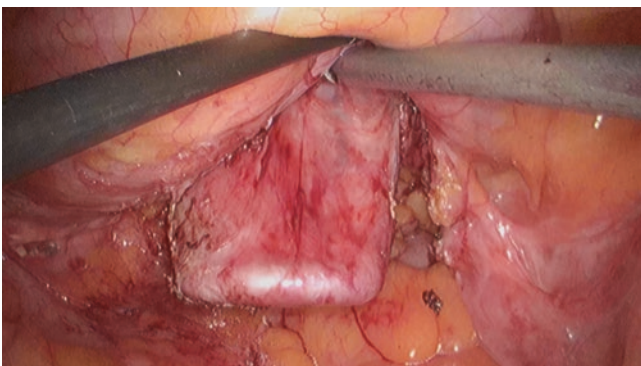


Fig. 62.8 Bladder mobilisation from anterior vaginal wall in progress

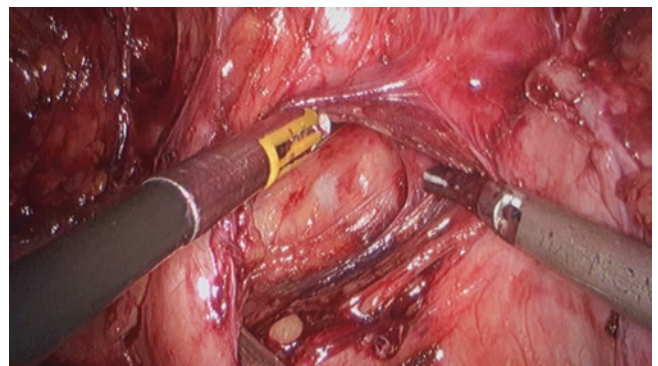


Fig. 62.9 Endopelvic fascia seen on the right side after dissection lateral to the rectum on the right side

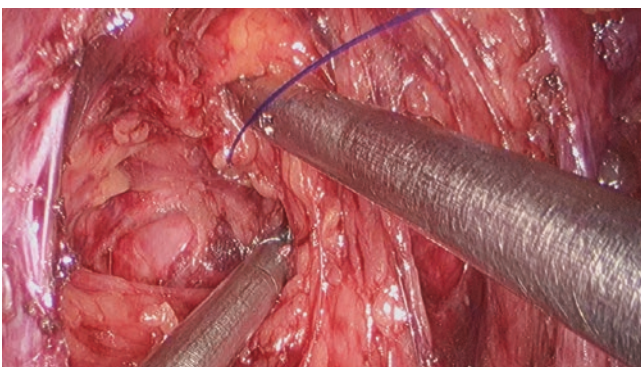


Fig. 62.10 Endopelvic fascia seen on the left side

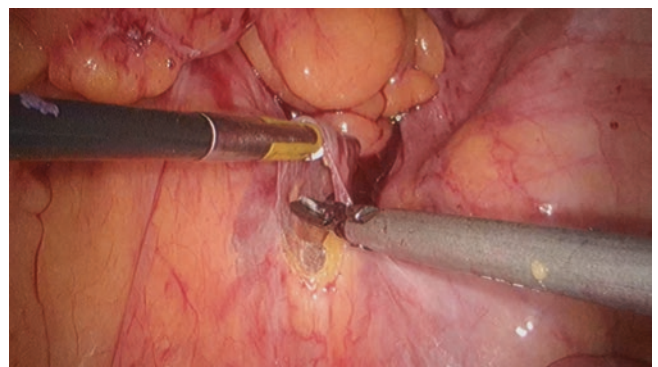


Fig. 62.11 Peritoneum incised anterior to the sacral promontory

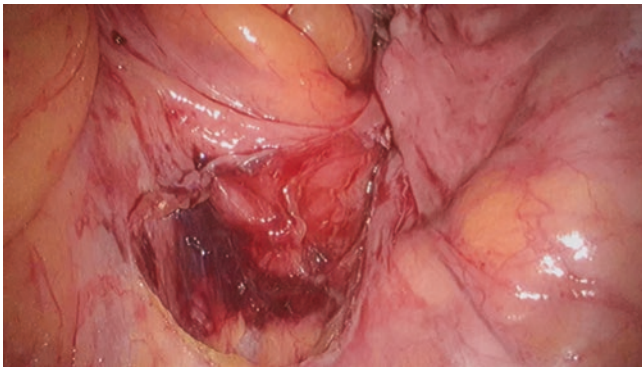


Fig. 62.12 Peritoneal incision extended inferiorly to join the recto vaginal space

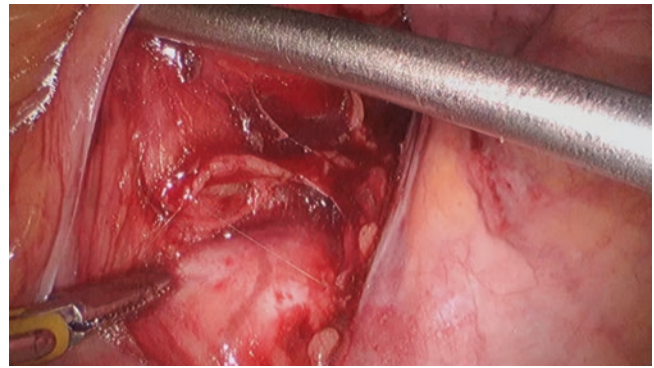


Fig. 62.13 Sacral promontory defined

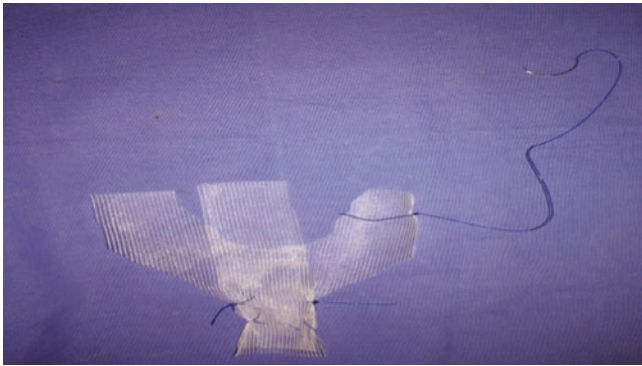


Fig. 62.14 Configured mesh

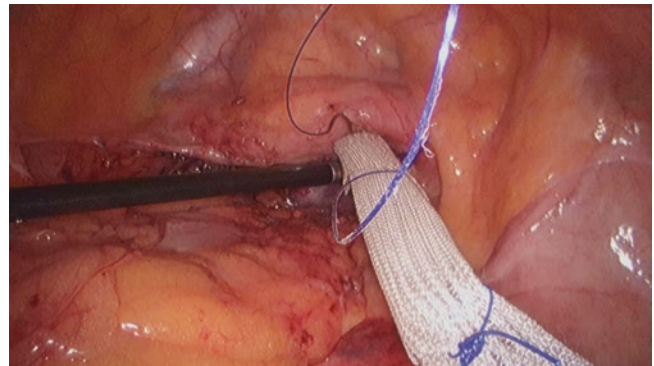


Fig. 62.15 Preconfigured mesh inserted into peritoneal cavity

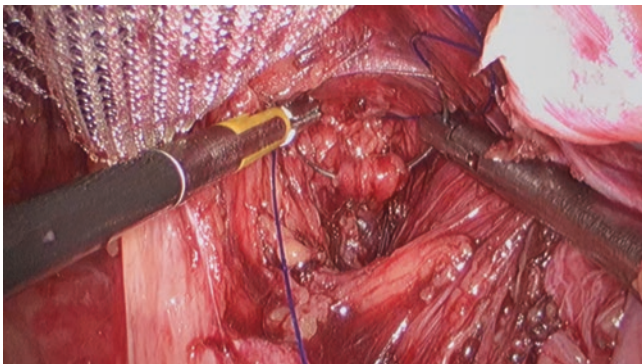


Fig. 62.16 Initial fixing suture through the levator ani on the right side

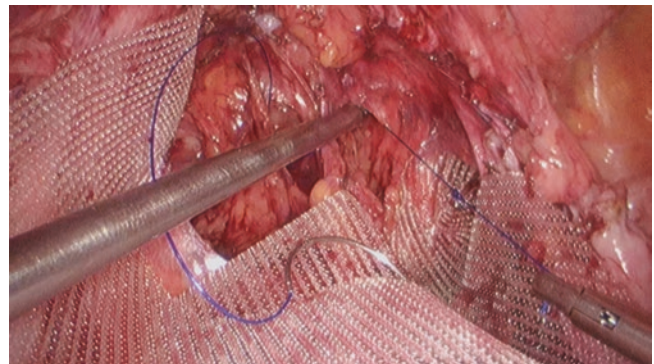


Fig. 62.17 Corresponding bite taken through the mesh and knot placed; fixing the mesh to levator ani

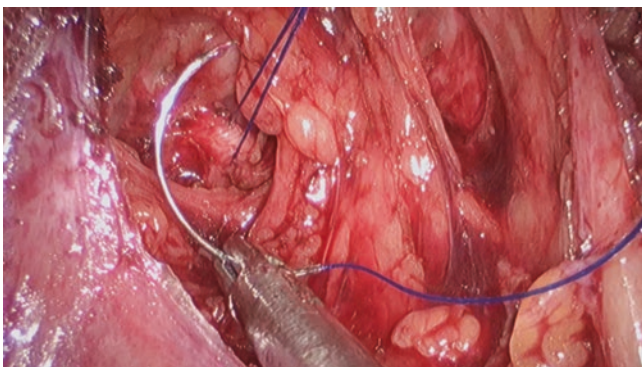


Fig. 62.18 Suture through the levator ani on the left side

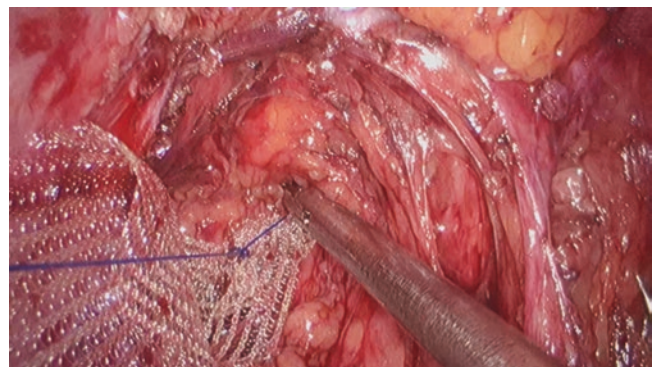


Fig. 62.19 Left limb of the mesh placed similarly

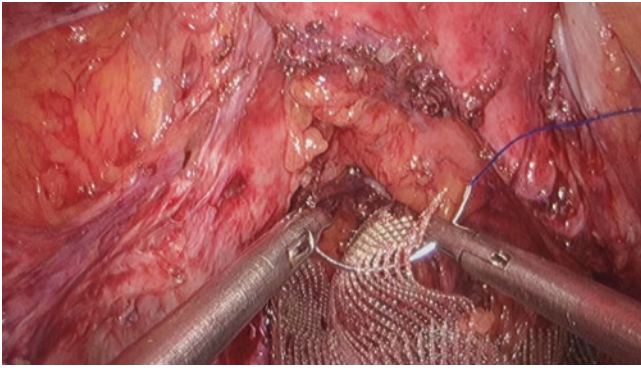


Fig. 62.20 Suture through central limb of mesh

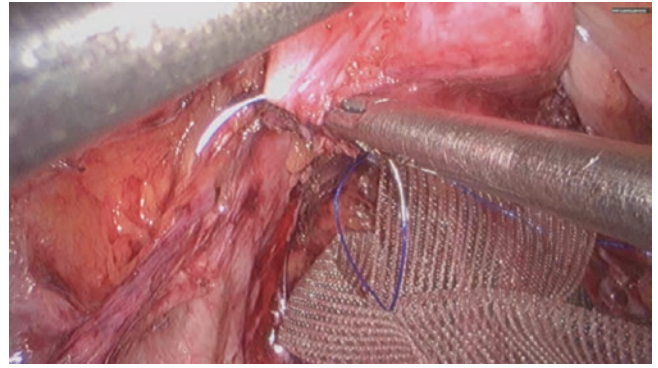


Fig. 62.21 Suture through the posterior wall of vagina

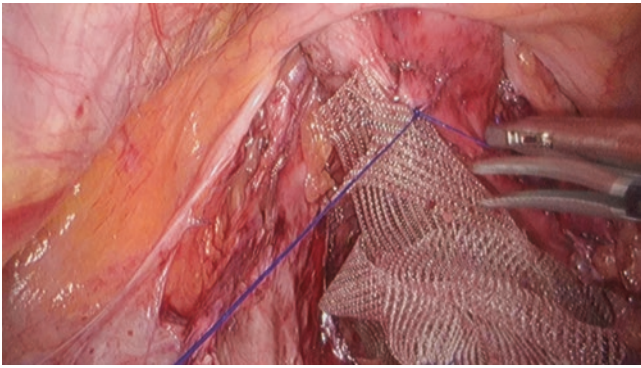


Fig. 62.22 Central limb of mesh fixed to posterior vaginal wall

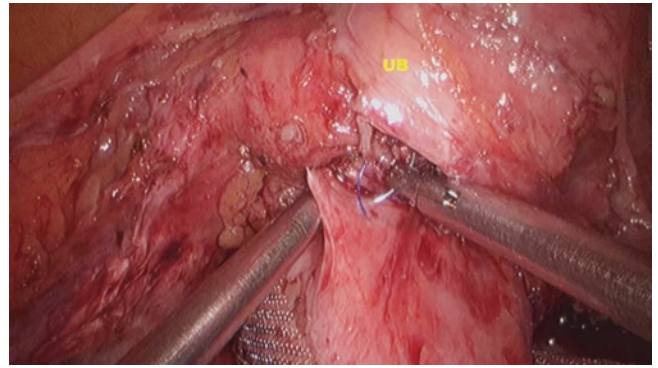


Fig. 62.23 Suture through anterior vaginal wall

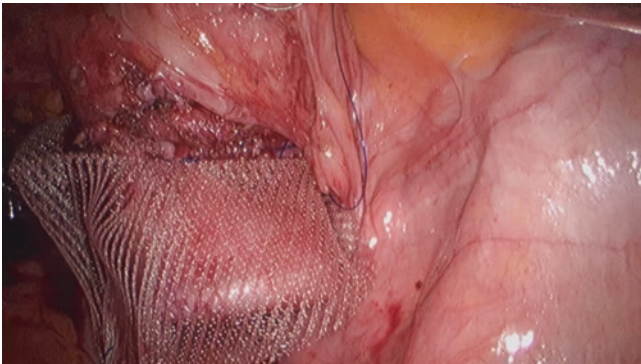


Fig. 62.24 Central part of mesh fixed to anterior vaginal wall

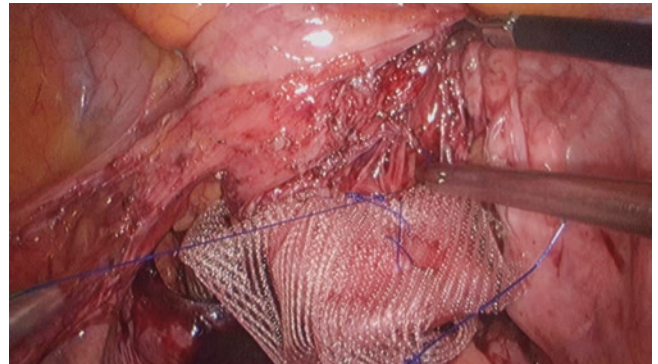


Fig. 62.25 Anterior fixation completed

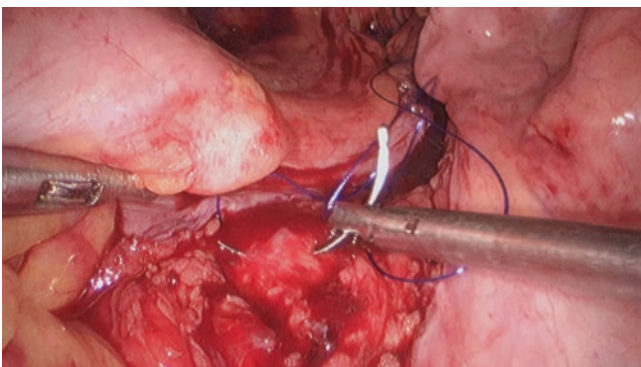


Fig. 62.26 Suture through sacral promontory

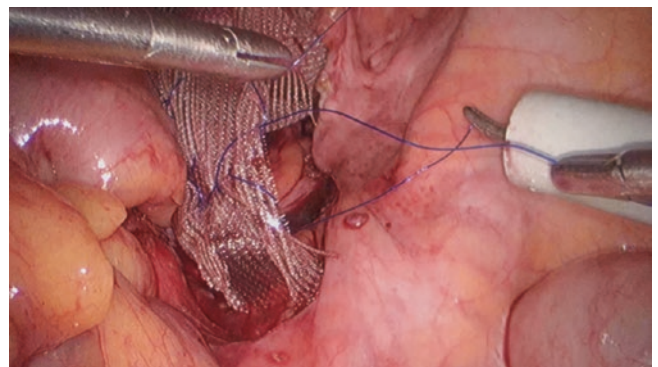


Fig. 62.27 Suture through mesh

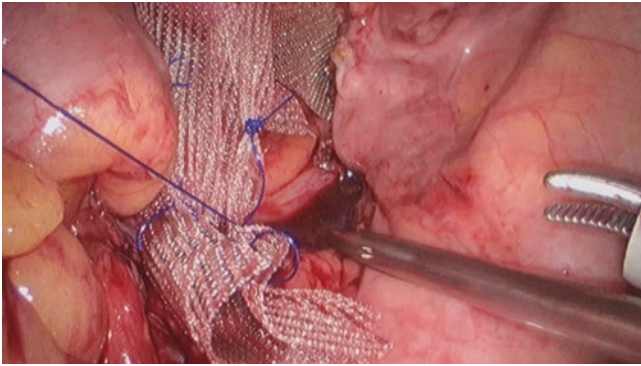


Fig. 62.28 Mesh fixed to promontory

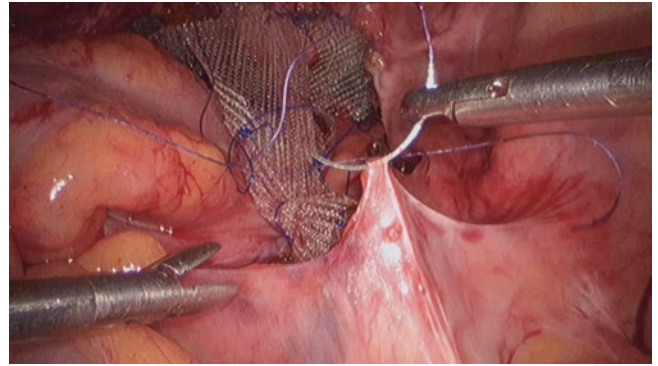


Fig. 62.29 View of mesh in situ and peritoneal closure started

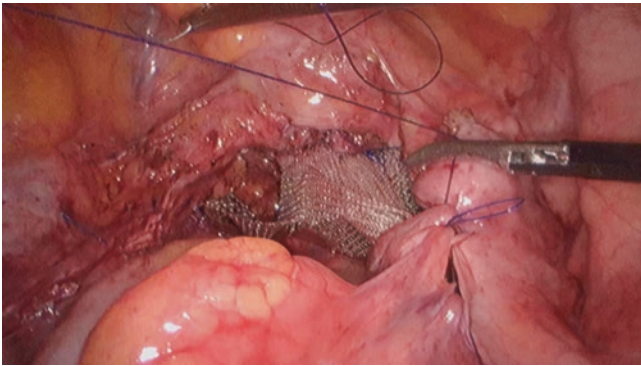


Fig. 62.30 Peritoneal closure in progress

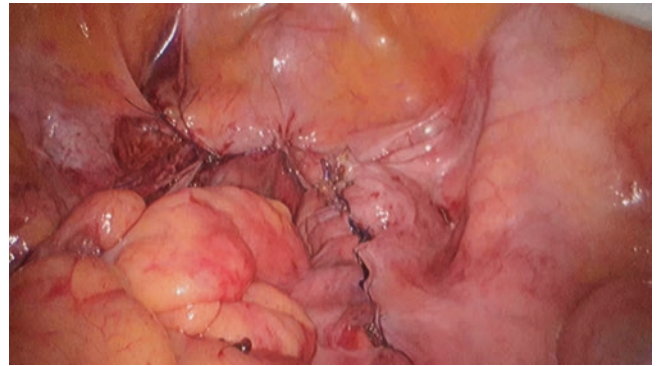


Fig. 62.31 Final view – mesh concealed by peritoneum

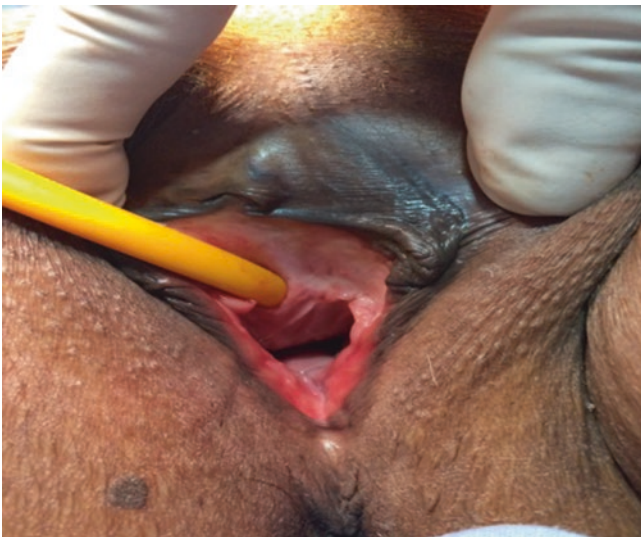

Fig. 62.32 Post op image – vault reduced

References

1. Sarlos D, Brandner S, Kots L, Gygax N, Schaer G. Laparoscopic sacrocolpopexy for uterine and post-hysterectomy prolapse: anatomical results, quality of life and perioperative outcome-a prospective study with 101 cases. *Int Urogynecol J Pelvic Floor Dysfunct*. 2008;19:1415–22.
2. Maher CF, Feiner B, DeCuyper EM, Nichlos CJ, Hickey KV, O'Rourke P. Laparoscopic sacral colpopexy versus total vaginal mesh for vaginal vault prolapse: a randomized trial. *Am J Obstet Gynecol*. 2011;204:360.e1–7.
3. DeLancey JO. Anatomic aspects of vaginal eversion after hysterectomy. *Am J Obstet Gynecol*. 1992;166:1717–28.

Robotic-Assisted Sacrocolpopexy for Comprehensive Repair of Multi-compartment Vaginal Vault Prolapse

63

Robert I. Carey, Jayapriya Jayakumaran, Celso Silva,
Sejal D. Patel, and Hariharan Palayapalayam Ganapathi

63.1 Robotic Sacrocolpopexy

Pelvic organ prolapse (POP) is a common female pelvic floor disorder that has significant impact on quality of life. A study predicted that by the year 2050, 43.8 million women, or nearly one-third of the adult female population in the US, would be affected by at least one troublesome pelvic floor disorder [1]. With the aging and increasing activity of the population, the demand for prolapse surgery is increasing. Prolapse surgery has historically been plagued with high rates of women requiring salvage repair after their initial attempts at surgical correction fail [2]. Decreasing the need for salvage procedures decreases the lifetime cost of the condition more than any other factor.

Whereas some patients with symptomatic POP can be managed by native tissue trans-vaginal repairs, correction of apical descent or multi-compartment prolapse (level I defect) is better treated by the abdominal approach [2]. However open laparotomy has higher morbidity, increased hospital stay, and often fails to achieve meticulous, thorough tissue dissection to enable a durable repair [2]. Robotic surgery is employed to achieve superior vision, superior dissection, and superior repair, particularly in cases made more difficult by severity of prolapsed, obesity, adhesions and salvage from previous attempts at repair.

Robot-assisted technology, with its stereoscopic vision, improved dexterity and use of wristed instruments simplifies complex laparoscopic tasks. Pelvic surgeons widely adopted this technology for dissection in narrow pelvis and intra-corporeal suturing [3]. A systematic review and meta-analysis reported objective and subjective cures ranging

from 84 % to 100 % and 92 % to 95 %, respectively [4]. Mesh erosion rate decreased to 2 %. The robotic technique was found to be safe and feasible with acceptable risk of complications. In this chapter we describe our technique of robotic-assisted sacrocolpopexy for vault prolapse, emphasizing details that result in durable repair and high patient satisfaction. Previous publications have outlined this technique in the salvage setting after previous failed attempts at open abdominal sacrocolpopexy [5] and in the setting of women who wish to have uterus preservation [6].

63.2 Preoperative Considerations

Although women with grade 4 prolapse descending far outside the introitus universally make appropriate request for repair, women with lesser degrees of herniation must be carefully screened for preoperative dysfunction and postoperative expectations. POP affects patients in terms of daily discomfort, urinary dysfunction, bowel dysfunction, sexual problems. Successful surgery should be measurable not only in a postoperative POP-Q score (which is rarely of importance to the patient), but also in terms of how her sex life, urination, bowel habits or daily life has improved. Women who are sexually active without dyspareunia, have no urinary or bowel complaints, nor any daily discomfort from their prolapse should be observed until correctable symptoms present. Many women have had previous trans-vaginal attempts at repair of their prolapse and their operative notes should be carefully examined for use of mesh and concomitant attempts at urethral suspension.

R.I. Carey (✉)
Florida State University College of Medicine, Sarasota, FL, USA
e-mail: ricareymd@gmail.com

J. Jayakumaran • C. Silva • S.D. Patel • H.P. Ganapathi
Florida Hospital, Orlando, FL, USA
e-mail: Hari.Ganapathi@flhosp.org

63.3 Patient Positioning and Port Placement

After appropriate antibiotic prophylaxis and general anesthesia is achieved, the patient is prepped and draped in the low lithotomy position and stabilized with all pressure points protected. Urinary bladder catheterization is done with aseptic precautions. Insufflation is achieved with a Veress needle and trocar positions are shown in Fig. 63.1. A supra-umbilical camera port, three 8 mm robotic ports (two on left side and one on right side) and an additional 12-mm assistant port are placed. The principal left and right working ports are placed as high as possible in the abdomen to assure optimal arm mobility for dissection of the sacral promontory which can be deceptively high in some patients. The patient is placed in the steep Trendelenburg position and the robot docked from the side or between legs. A self-retaining adjustable sacrocolpopexy retractor is placed inside the vagina and is controlled by the assistant during the case. It is imperative that all intraperitoneal adhesions to the retroperitoneal structures be released in order to create the space for repair.

63.4 Instruments

- Right arm: Monopolar scissors (Da Vinci Si setting: 25 W, Da Vinci Xi setting: 2)/Needle driver
- Left arm: Plasma-kinetic forceps/Needle driver
- Fourth arm: Prograsp forceps
- Scope: 30° down lens
- Intravaginal self-retaining, adjustable sacrocolpopexy retractor (Cooper Medical):

63.5 Surgical Steps

63.5.1 Identification of Sacral Promontory and Pre-placement of Suture

The sigmoid colon and retroperitoneum are retracted to left by fourth arm. The right ureter and iliac vessels are identified and protected (Fig. 63.2). Peritoneum overlying the sacral promontory is opened to expose anterior longitudinal ligament (ALL) of the sacrum (Fig. 63.3). Care is taken to avoid

injuring the iliac vessels and right ureter crossing iliac artery lateral to the sacral promontory. The middle sacral artery and the sacral plexus of veins must also be meticulously dissected to maintain a clean, bloodless field. Two Gore-Tex sutures, tied together to create a double arm suture of correct length, are placed through ALL (Fig. 63.4).

63.5.2 Creation of Peritoneal Flap/Tunnel

Right parietal peritoneum is superficially incised from the promontory to the vaginal vault without injuring the right ureter (Fig. 63.5). Alternatively a tunnel underneath the right parietal peritoneum can be made. This peritoneal flap/tunnel is used for retroperitonealization of the mesh later. The opening in the retroperitoneum should be ample to allow for a tension free closure. This step not only assures that no mesh is left exposed to bowel, but it also serves as a formal enterocele repair.

63.5.3 Dissection of Vaginal Vault

A self-retaining sacrocolpopexy retractor is inserted into the vagina, stretching it towards sacral promontory for easy identification and dissection (Fig. 63.6). Alternatively, an End-to-End anastomotic EEA sizer may be used. Peritoneum overlying the vaginal apex is dissected in pouch of Douglas (POD). The avascular plane between anterior vaginal wall and bladder is dissected until bladder trigone is reached (Fig. 63.7). To facilitate this surgical step, bladder can be filled with normal saline to identify its limits. Posteriorly, peritoneum and rectum is freed from the posterior vaginal wall (Fig. 63.8), avoiding damage to haemorrhoidal vessels or rectal nerves. The space should be sufficiently broad and long to accommodate the mesh placement and allow for ease of suturing (Fig. 63.9).

63.5.4 Fixation of Mesh

The length of the anterior and posterior sections is measured with the open width of the PK dissecting forceps. In general, 5–8 cm of anterior and posterior walls is dissected. A 23×4 cm wide pore polypropylene ‘Y’ shaped mesh is

selected and trimmed to size. This pre-tailored mesh is inserted through assistant port and placed in the dissected space. Fixation of mesh to anterior and posterior vagina is accomplished with double armed barbed suture in running fashion (Fig. 63.10a–c), with EEA sizer or sacrocolpopexy retractor in place. Generous but less than full thickness bites of vaginal wall are taken. Symmetrical fixation of mesh anteriorly and posteriorly on vaginal wall provides equal tension, while fixing it to sacrum. The Y limb of mesh is pulled to the level of ALL (Fig. 63.11). It is critically important at this point that the assistant has the prolapse reduced at the correct vaginal axis and to the desired tension. Any excess mesh is trimmed. The bottom end of the ‘Y’ mesh is anchored to the sacrum with the two preplaced Gore-Tex sutures (Fig. 63.12). It is customary to add several more sites of fixation to the ALL after the initial two sites are secured.

63.5.5 Retro-peritonealisation of Mesh

The parietal peritoneum over the vaginal vault and the sacral promontory is sutured with 2-0 vicryl in running fashion. The mesh is entirely retroperitonealized (Fig. 63.13a–c), thus preventing any future sites of enterocele formation or small bowel obstruction due to mesh adhesion. Care is taken

to make sure that no mesh is left exposed, no sites of herniation are left (Fig. 63.14), and complete hemostasis is achieved. A cystoscopy with vaginoscopy is performed at this point to evaluate for efflux from each ureter and to ensure that there was no occult bladder or vaginal injury during the case. The urinary catheter is placed again at the end of the case and removed the following morning.

63.6 Results

Robotic sacrocolpopexy when performed as described in this chapter leads to durable repair of pelvic floor prolapse both in salvage cases and in those with no previous attempts at repair. At 3 year follow up, a group of 152 patients who underwent salvage repair after failed transvaginal attempts has had no re-operations or representations secondary to recurrent prolapse. The estimated mean blood loss is less than 10 mL, a result obtained through diligent identification and dissection of the embryonic planes of tissue separation. The robotic operative times ranged from as low as 65 min to as high as 180 min with the discrepancy in time being the adherence of the vaginal wall to the perivesical and perirectal tissues as well as intraperitoneal adhesions.

63.7 Complications

Major complications are rare. In the 152 patients there has been one reoperation for small bowel obstruction caused by an unrecognized enterotomy during extensive lysis of adhesions in a patient with previous history of small bowel obstruction and numerous previous intra-abdominal operations. One patient has a small minor erosion at the vaginal apex. She is asymptomatic and has opted for non-intervention. There has

been one transfusion in a patient with severe pre-existing anemia unrelated to intraoperative blood loss. By far the most common issue after robotic sacrocolpopexy has been the emergence of symptomatic de novo stress urinary incontinence (SUI). Seven patients have required subsequent placement of autologous fascial slings. Risk factors associated with de novo SUI have been age of the patient (over 65) and previous history of a Burch colposuspension or Marshall-Marchetti-Krantz procedure as part of their initial failed attempts at repair.

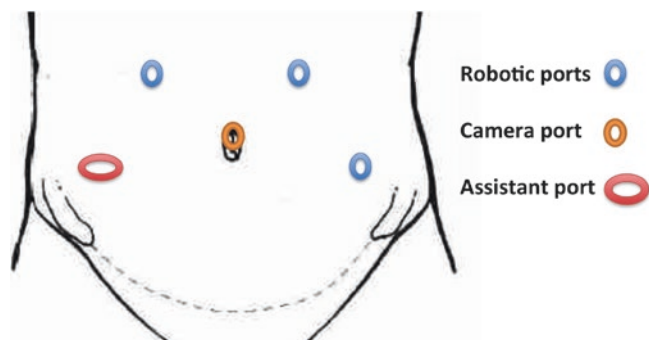


Fig. 63.1 Port position for robotic assisted sacrocolpopexy

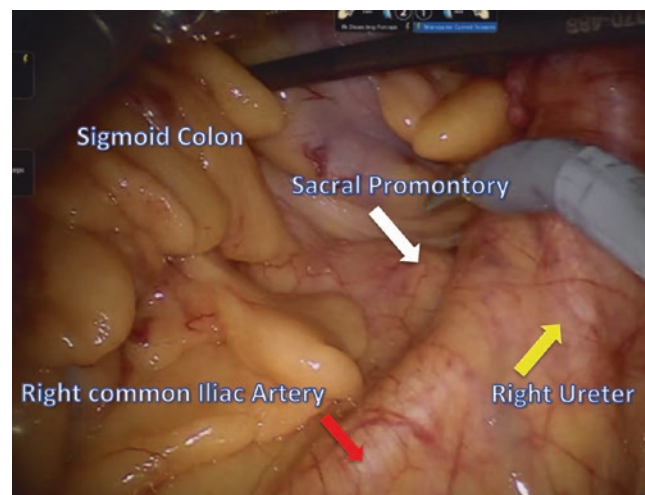


Fig. 63.2 Identification sacral promontory

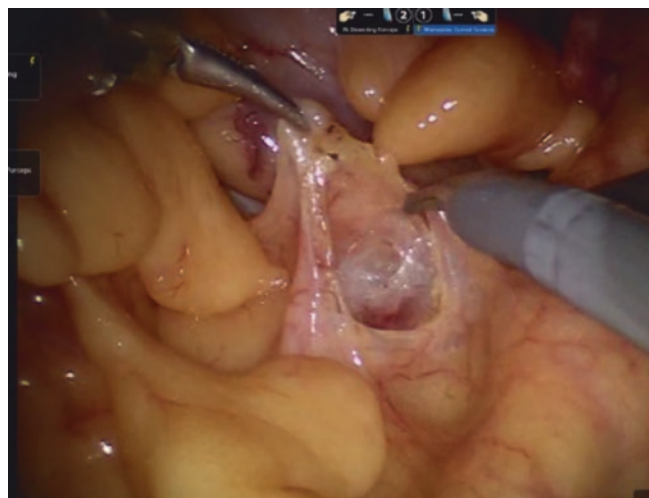

Fig. 63.3 Incision of peritoneum over the sacral promontory to expose the all

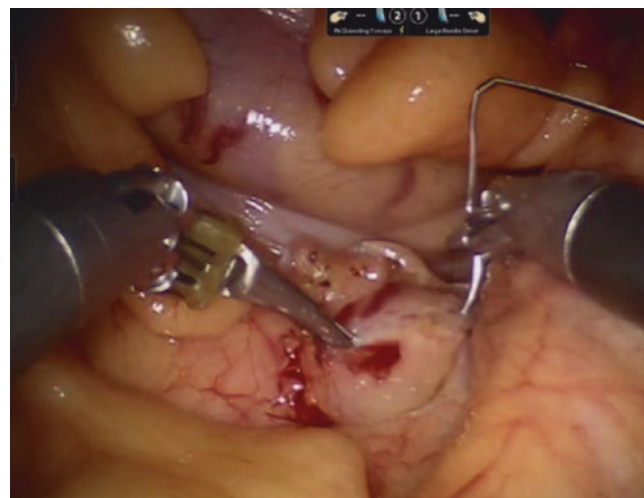


Fig. 63.4 Two Gore-tex sutures are pre-placed through anterior longitudinal ligament

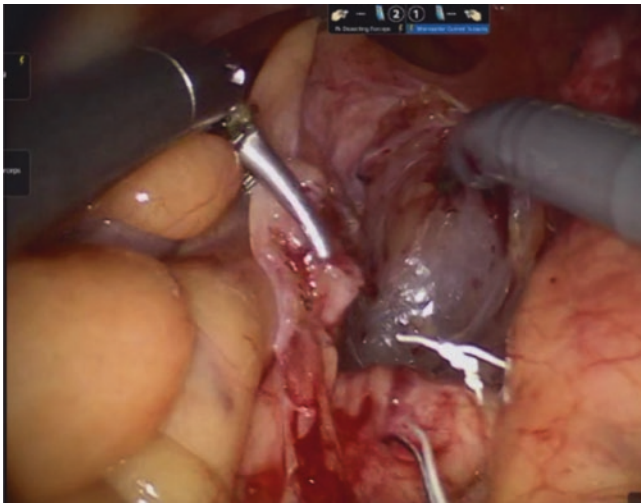


Fig. 63.5 Peritoneum incised from the promontory to the vaginal vault

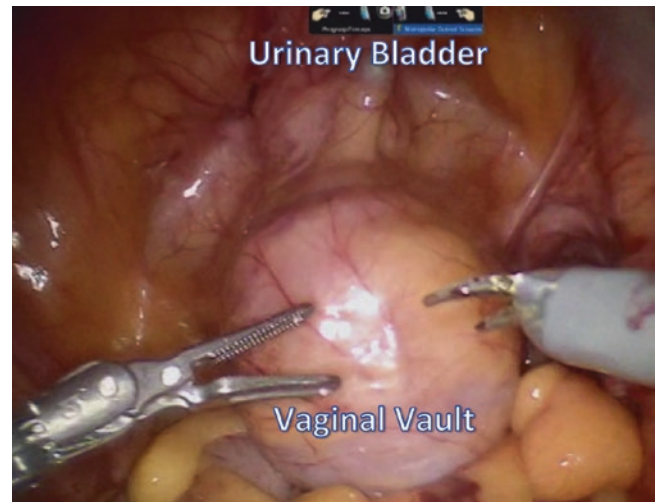


Fig. 63.6 Sacrocolpopexy retractor or EEA Sizer inserted into vagina to assist vault dissection

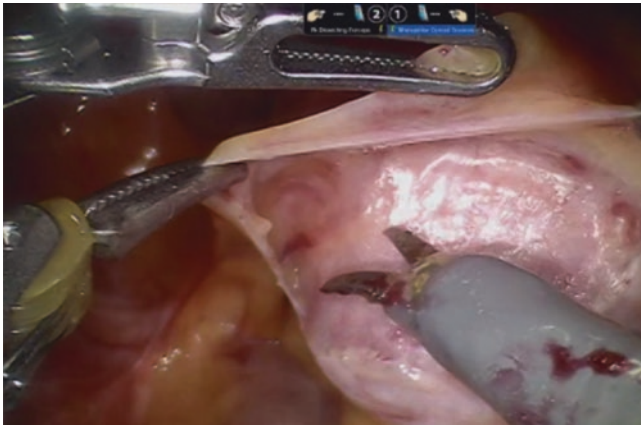


Fig. 63.7 Dissection of avascular plane between anterior vaginal wall and bladder

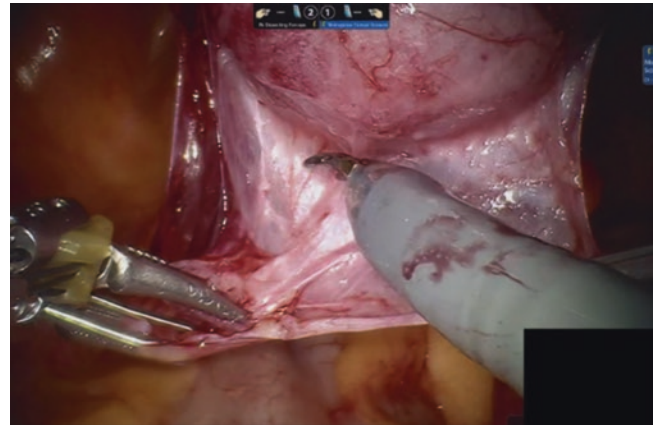


Fig. 63.8 Dissection of plane between posterior vaginal wall and rectum

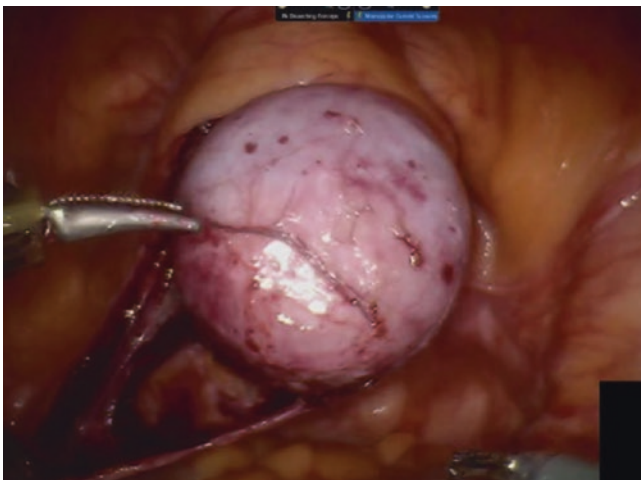


Fig. 63.9 Peritoneum dissected of vaginal vault for mesh placement

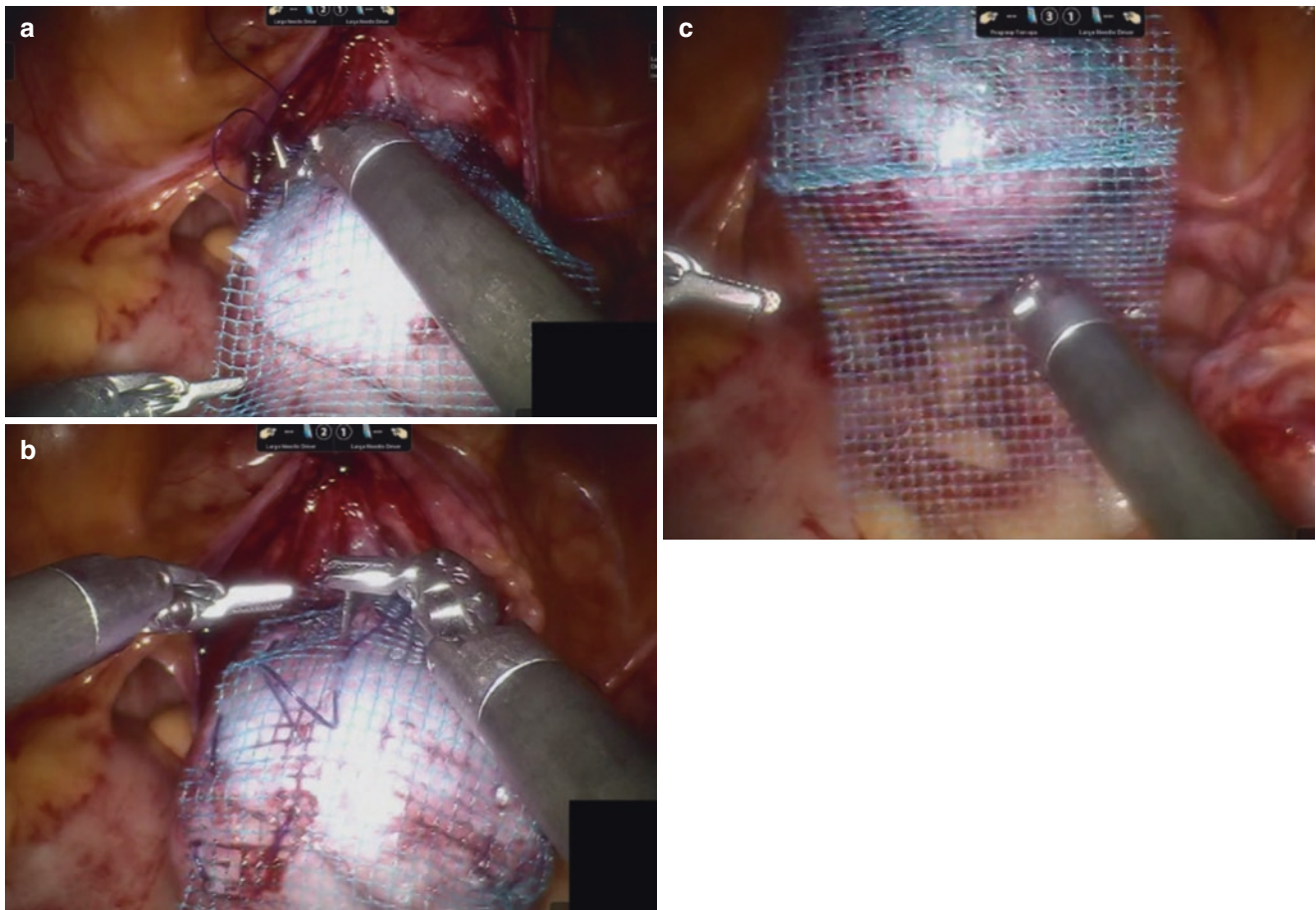


Fig. 63.10 (a) Fixation of mesh to anterior vagina less than full thickness bites. (b) Fixation of mesh to anterior vagina barbed running suture. (c) Fixation of mesh to posterior vagina in symmetrical fashion

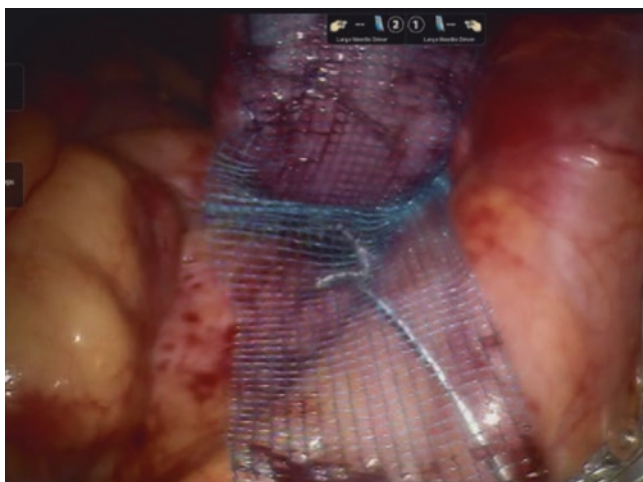


Fig. 63.11 Y limb of mesh is pulled to the level of anterior longitudinal ligament

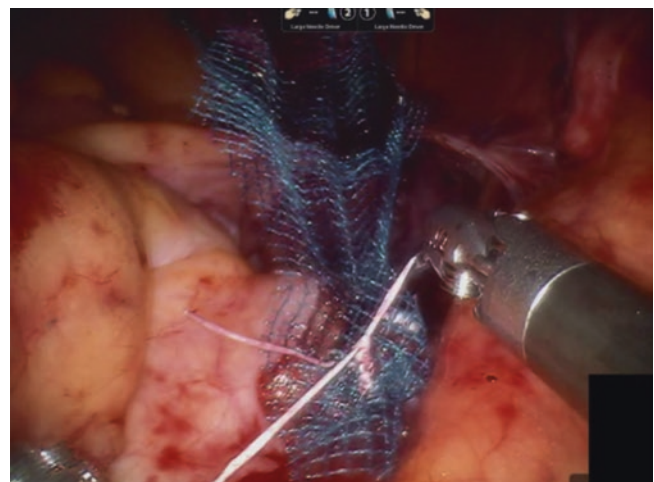


Fig. 63.12 Bottom end of the 'Y' mesh anchored to the sacrum with the two preplaced Gore-Tex sutures

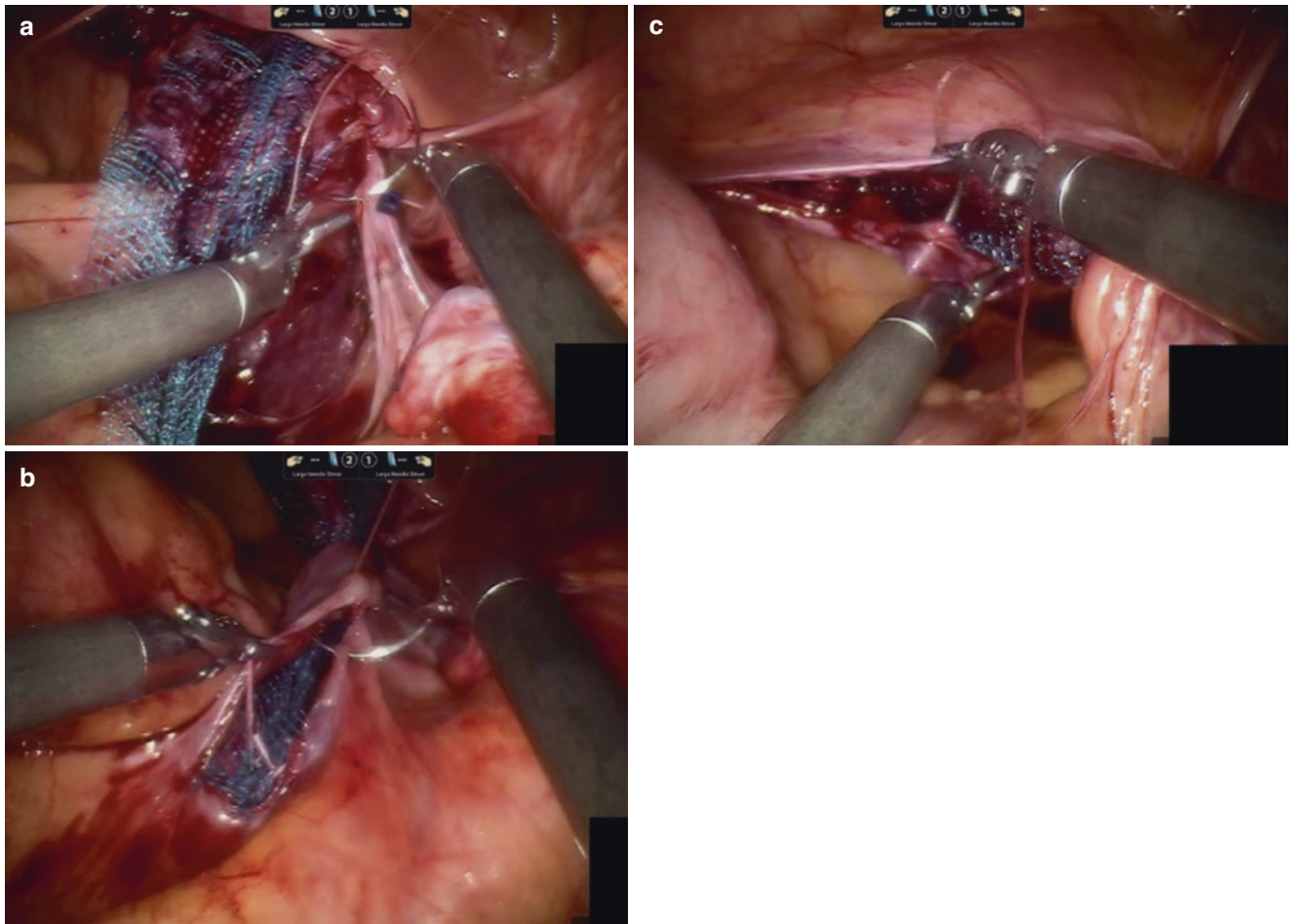


Fig. 63.13 (a) 'Y' limb of mesh covered with peritoneal flap. (b) 'Y' limb of mesh covered with peritoneal flap. (c) Mesh in vaginal vault covered with peritoneal flap

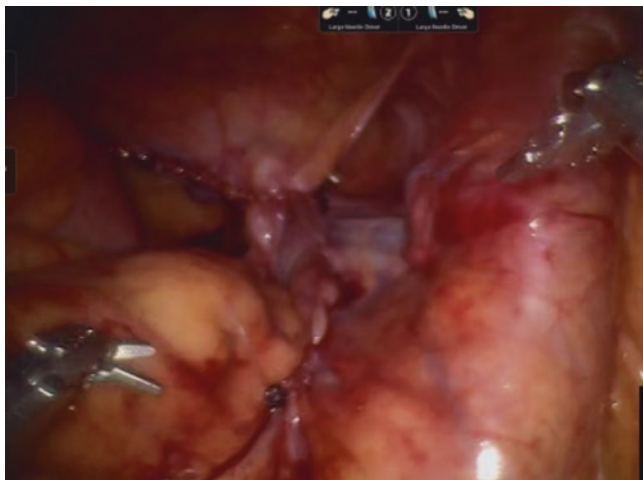


Fig. 63.14 Mesh completely retro-peritonealised

63.8 Conclusions

Robotic sacrocolpopexy as described above provides a comprehensive, complete pelvic floor repair, encompassing cystocele, rectocele, and enterocele repair all in one surgical procedure. In terms of durability of the vault suspension, robotic sacrocolpopexy provides results superior to open sacrocolpopexy procedures where only the apex of the vagina is dissected and attached to the ALL, leaving open the possibility of recurrent cystocele or rectocele formation [7]. Care must be taken in the preoperative planning stages to prevent de novo SUI through consideration of age, previous surgical procedures, pre-existing SUI or SUI elicited on urodynamic studies. Patients at risk should have a mid-urethral sling performed at the same time as the robotic sacrocolpopexy to avoid post-operative de novo SUI.

References

1. Wu JM, Hundley AF, Fulton RG, Myers ER. Forecasting the prevalence of pelvic floor disorders in U.S. Women: 2010 to 2050. *Obstet Gynecol.* 2009;114:1278–83.
2. Maher C, Feiner B, Baessler K, Schmid C. Surgical management of pelvic organ prolapse in women. *Cochrane Database Syst Rev.* 2013;(4):CD004014.
3. Callewaert G, Bosteels J, Housmans S, et al. Laparoscopic versus robotic-assisted sacrocolpopexy for pelvic organ prolapse: a systematic review. *Gynecol Surg.* 2016;13:115–23.
4. Serati M, Bogani G, Sorice P, et al. Robot-assisted sacrocolpopexy for pelvic organ prolapse: a systematic review and meta-analysis of comparative studies. *Eur Urol.* 2014;66(2):303–18.
5. Carey RI, Pilkington JE, Martin CJ, Blau EK. Robotic sacrocolpopexy: salvage procedure after failed open sacrocolpopexy. *J Endourol B Videourol.* 2014;28. doi:[10.1089/vid.2013.0090](https://doi.org/10.1089/vid.2013.0090).
6. Carey RI, Martin CJ, Pilkington JE, Folzenlogen ZA. Robot-assisted sacrocolpopexy with uterus preservation: trans-broad ligament anterior and posterior fixation. *J Endourol B Videourol.* 2013;27. doi:[10.1089/vid.2013.0044](https://doi.org/10.1089/vid.2013.0044).
7. Nygaard I, Brubaker L, Zykzynski C, et al. Long-term outcomes following abdominal sacrocolpopexy for pelvic organ prolapse. *JAMA.* 2013;309(19):2016–24.

Part X

Training in Laparoscopic and Robotic Reconstructive Surgery

Manickam Ramalingam, K. Selvarajan,
and Kallappan Senthil

64.1 Introduction

There is a definite role for laparoscopy in Urologic surgeries today for obvious advantages. There is a need for training with simplified modules. Several centres offer training in laparoscopic urology [1–4]. Nevertheless the training is not standardized and may involve the use of complex equipment. Here we present simplified training methods of our centre.

Training can be in a graded fashion

1. Dry lab exercises
2. Animal module exercises
3. Live Animal lab
4. Assisting Live Surgery

64.2 Dry Lab Exercises

- (a) Hand Eye Coordination
 - Cobra Drill
 - Bead transfer
- (b) Dissection – Using soft materials like orange, chicken tissues.
- (c) Knotting and Suturing Techniques – Step by Step teaching of different types of knotting and suturing.

M. Ramalingam (✉)
PSG Hospitals,
Coimbatore, India
e-mail: uroram@yahoo.com

K. Selvarajan, MCh
KG Hospital and Postgraduate Medical Institute, Coimbatore, India
Paediatric Surgery, K.G. Hospital and Postgraduate Institute,
Coimbatore, India

K. Senthil, MCh (Urol., FRCS) (✉)
Urology Clinic, Gowtham Annexe, Coimbatore, India
e-mail: senthilsatya@hotmail.com

64.3 Animal Module Exercise Like

- (a) Pyeloplasty
- (b) Ureterolithotomy
- (c) Urethrovessical suturing
- (d) IVC suturing

64.4 Live Animal Lab Training

64.4.1 Basic Training

- (a) Veress needle insertion
- (b) Trocar placement
- (c) Understanding triangulation concept
- (d) Dissection techniques
 - Transperitoneal
 - Nephrectomy
 - Retroperitoneoscopy

64.5 Advanced Animal Lab Training

- (a) Partial nephrectomy
- (b) Cystorrhaphy
- (c) Urethrovessical anastomosis
- (d) Pelvic lymphnode dissection
- (e) Para aortic lymphnode dissection

64.6 Comments

Indications for laparoscopic Urology are on the increase; more so in reconstructive procedures. Ultimately the skill transfer to the aspiring Urologists, will depend on

1. The intense desire to learn and keep learning
2. The commitment of the trainer or guide to impart the skills, discuss the problems he encountered over the years and their solutions.
3. Self evaluation.

64.7 Dry Laboratory Exercises



Fig. 64.1 Endotrainer with conventional camera needing an assistant




Fig. 64.2 Simple endotrainer with web camera. It does not need an assistant to hold the camera



Fig. 64.3 Dissection exercise using orange, chicken piece etc.




Fig. 64.4 Web camera mounted endotrainer-sideview

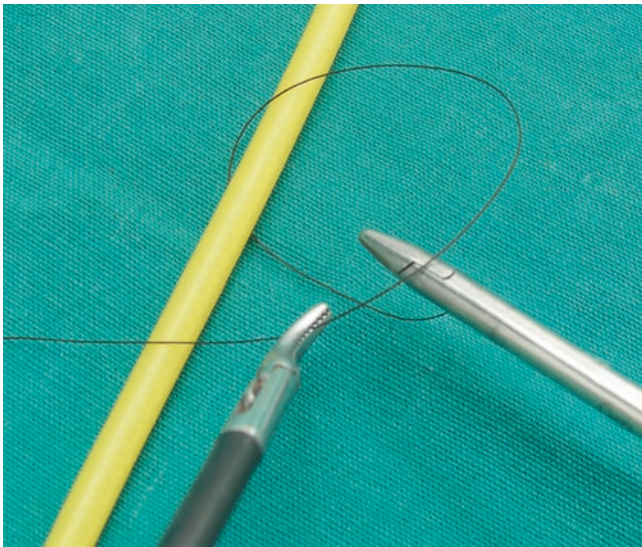


Fig. 64.5 Simple knot using c – loop technique

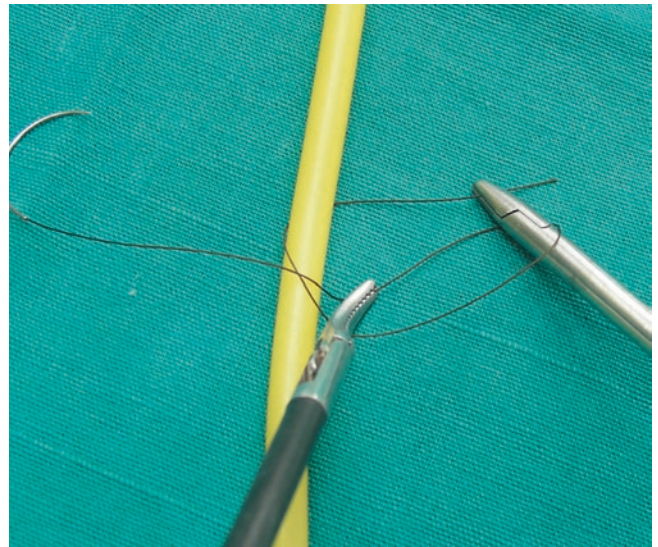


Fig. 64.6 Simple knot using c – loop technique

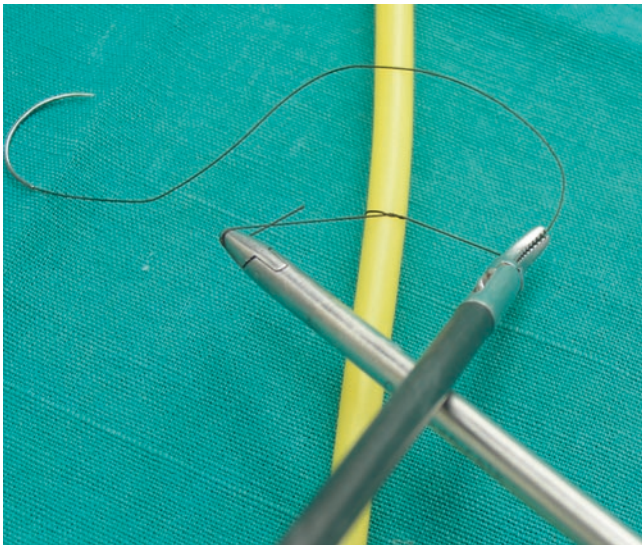


Fig. 64.7 Technique of tightening the knot (hand instruments moving at 180° to each other)

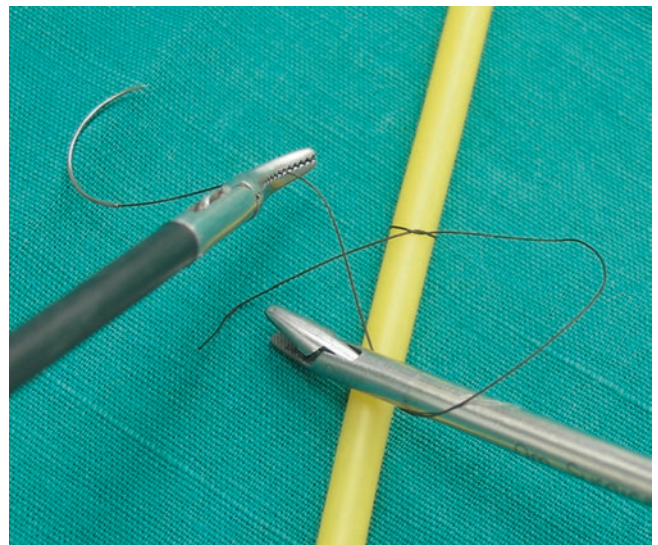


Fig. 64.8 Method of squaring the knot

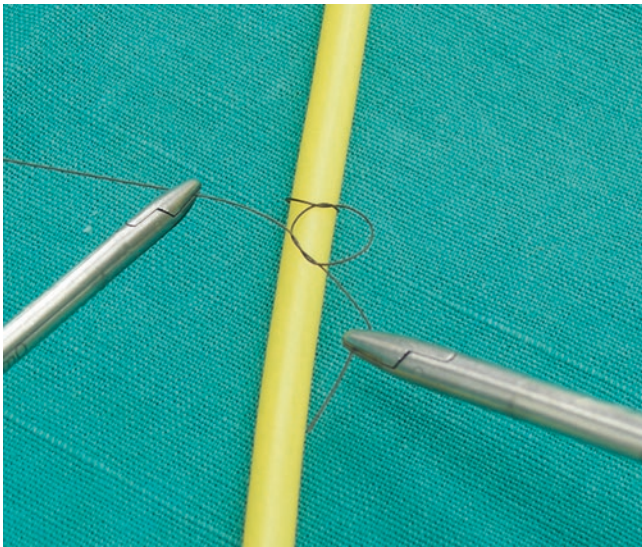


Fig. 64.9 Emphasis on ambidexterity (Note two needle holders)

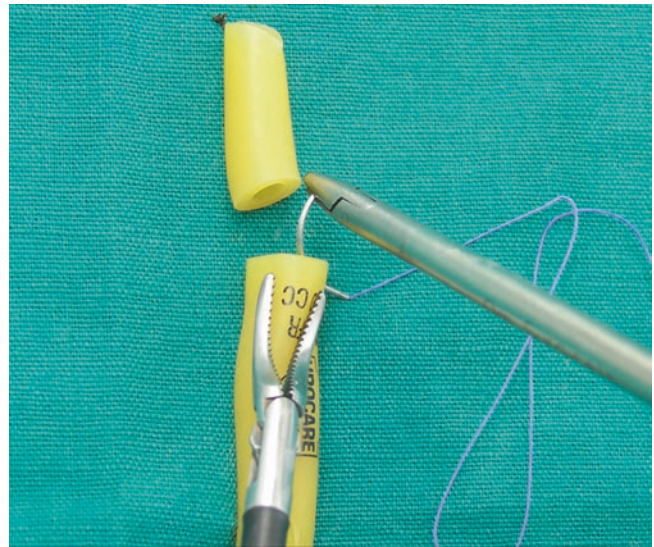

Fig. 64.10 Training using cut Foley catheter (Note the angle in which the needle holder drives the suture)

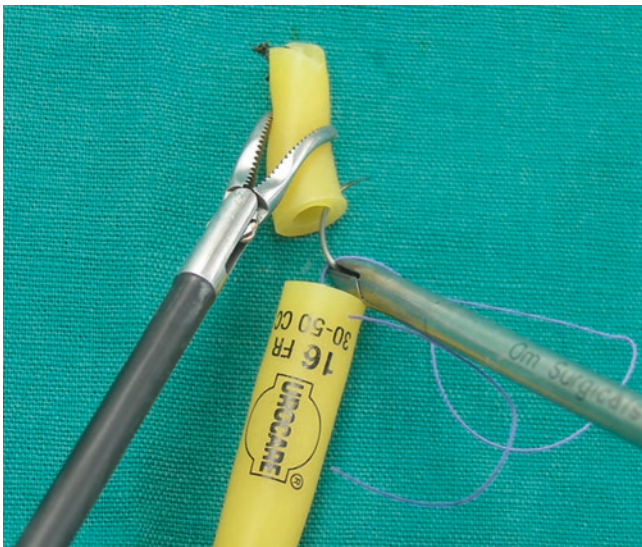

Fig. 64.11 Training using cut Foley catheter

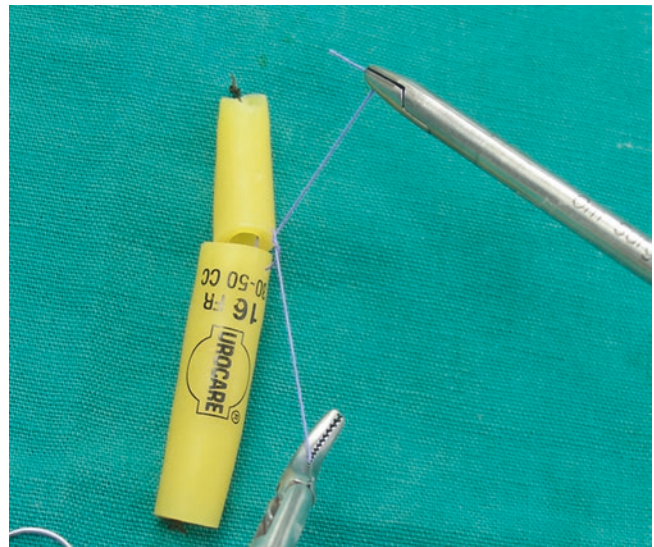

Fig. 64.12 Approximation akin to urethrovesical suturing

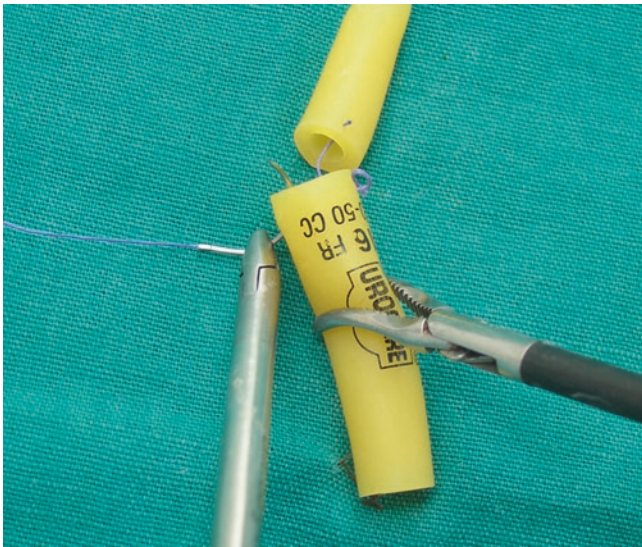


Fig. 64.13 Training with left hand suturing is emphasized

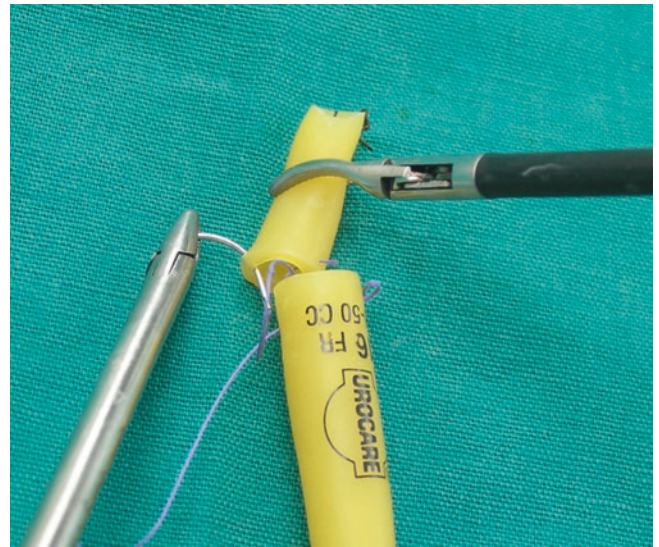


Fig. 64.14 Training with left hand suturing

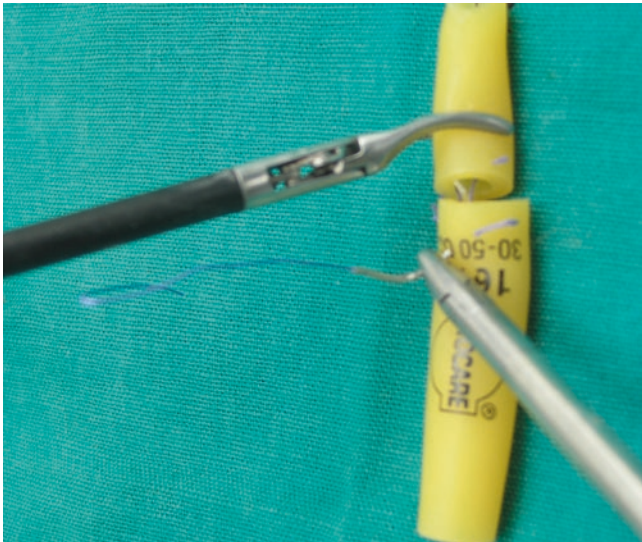


Fig. 64.15 Technique of back-hand suturing

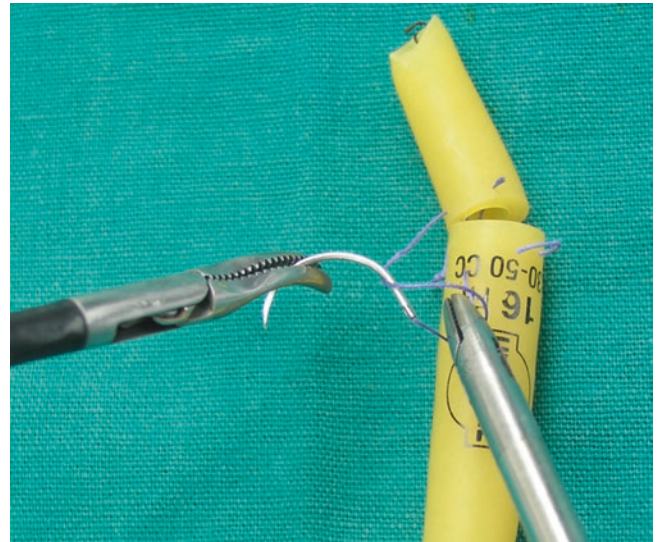

Fig. 64.16 Technique of throwing knot using needle

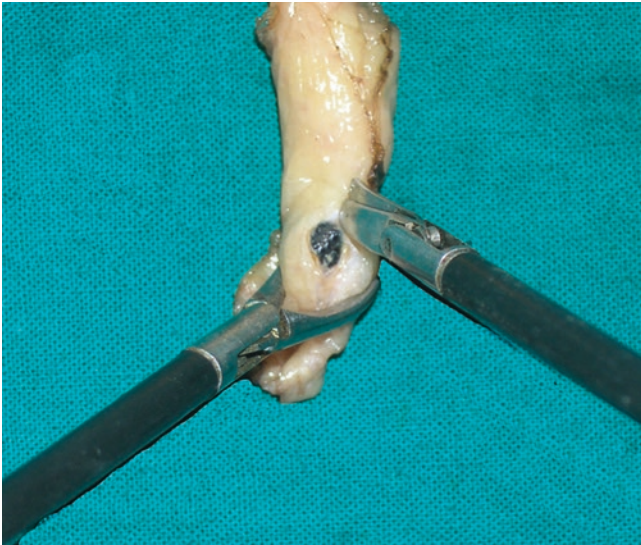


Fig. 64.17 Ureterolithotomy model with chicken skin

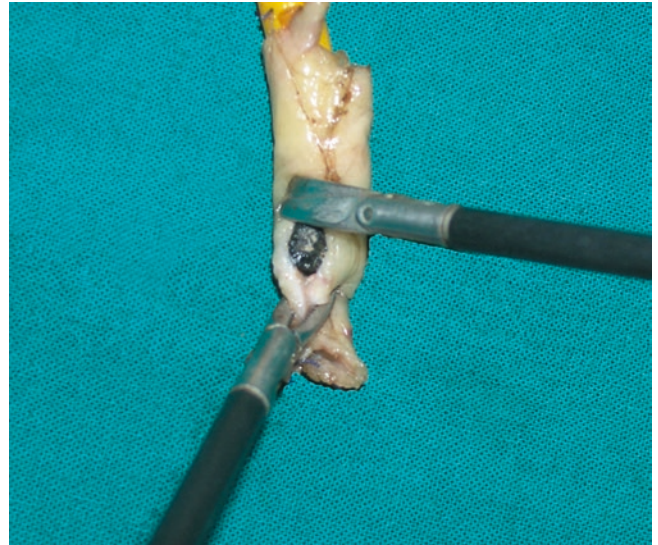


Fig. 64.18 Extending ureterotomy a little proximally

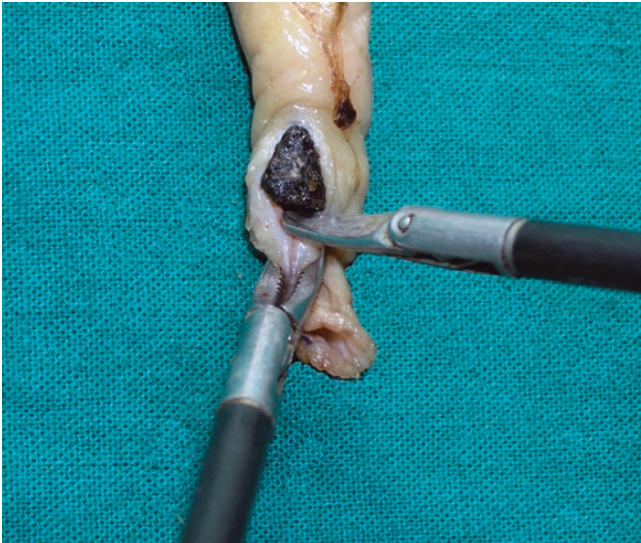


Fig. 64.19 Stone extraction practiced

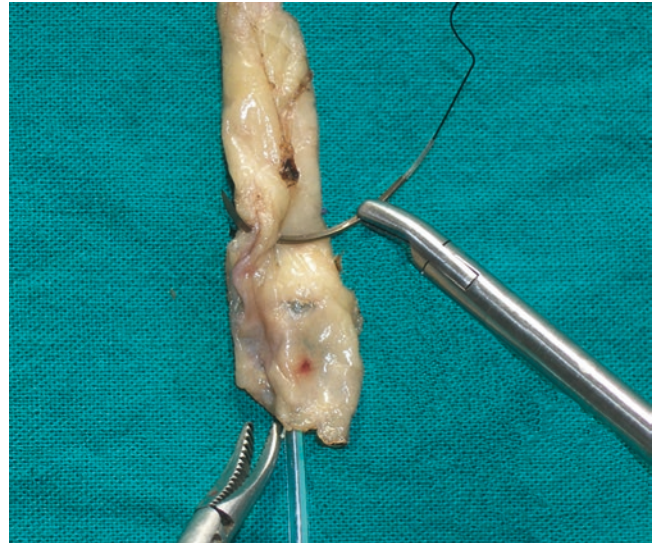


Fig. 64.20 Ureterotomy closure with interrupted suture

64.8 Model for Pyeloplasty

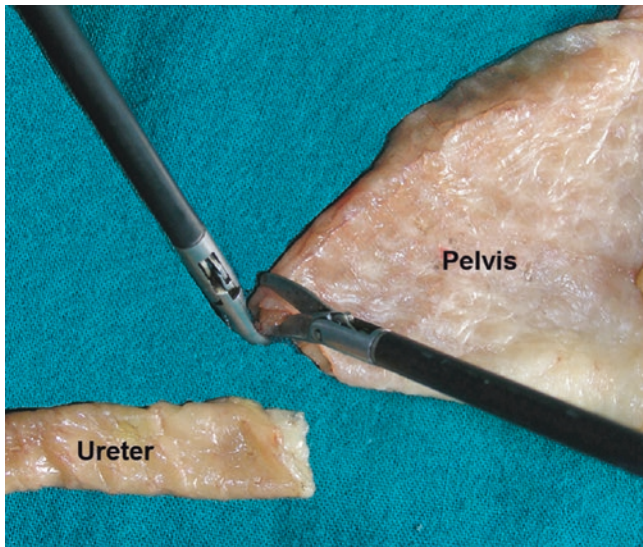


Fig. 64.21 Creating a module for pyeloplasty

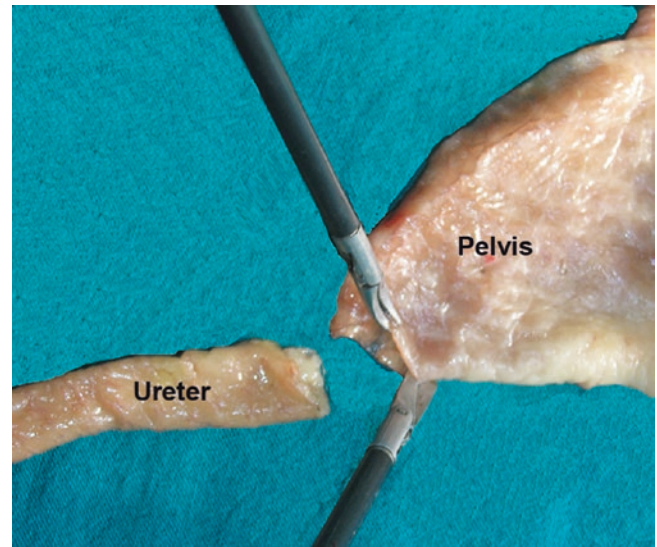


Fig. 64.22 Ureter spatulated laterally and pelvis spatulated medially

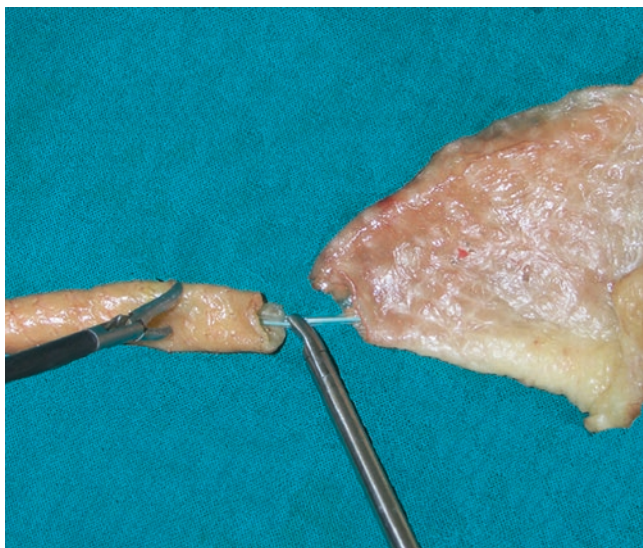


Fig. 64.23 Stenting technique

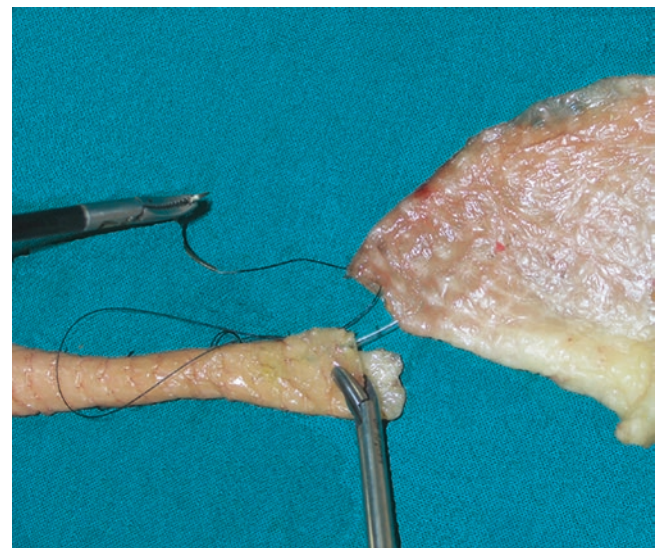


Fig. 64.24 Technique showing initial apical suture

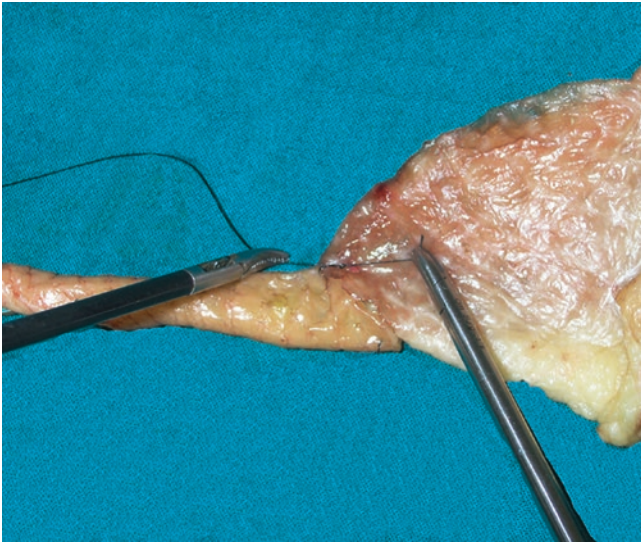


Fig. 64.25 Technique showing initial apical suture

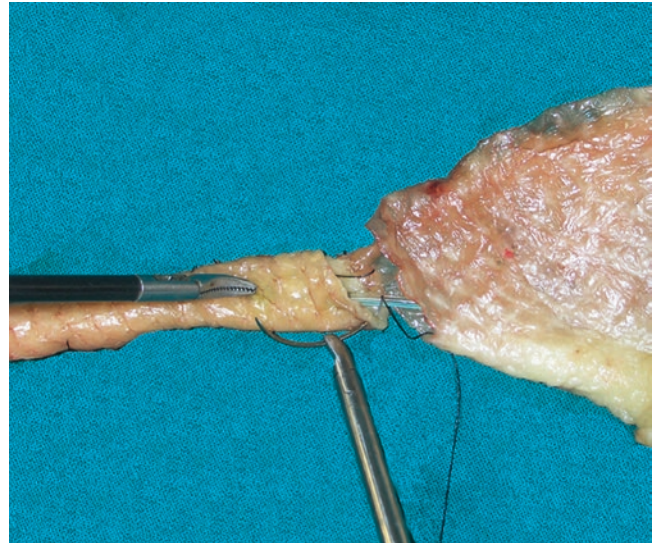


Fig. 64.26 Subsequent interrupted sutures of posterior layer

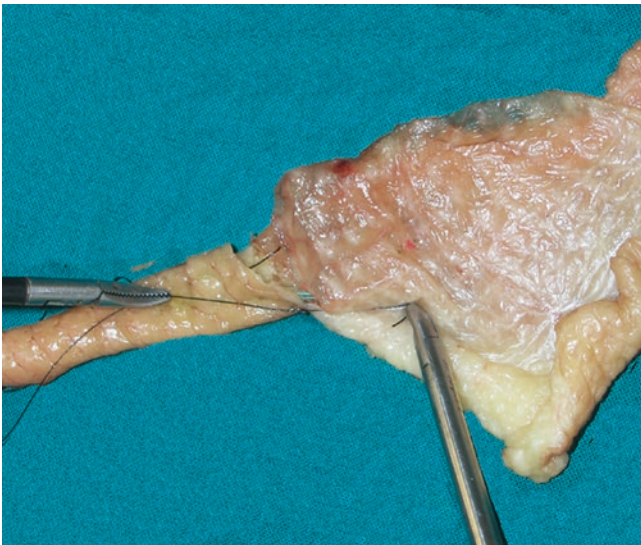


Fig. 64.27 Subsequent interrupted sutures of posterior layer

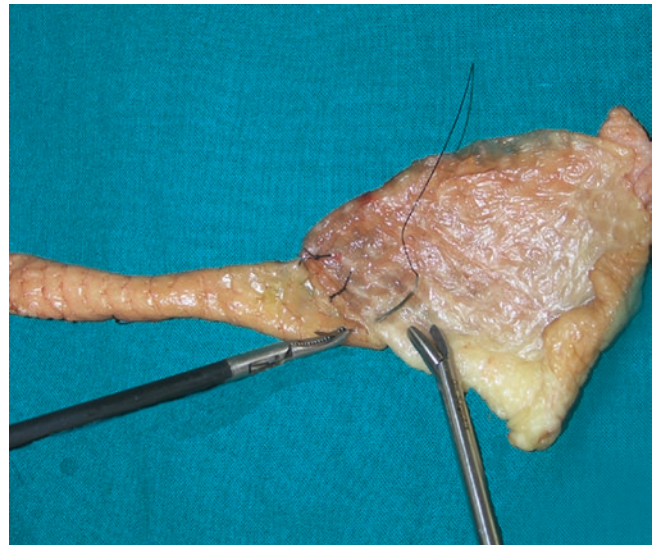


Fig. 64.28 Method of subsequent anterior layer suturing

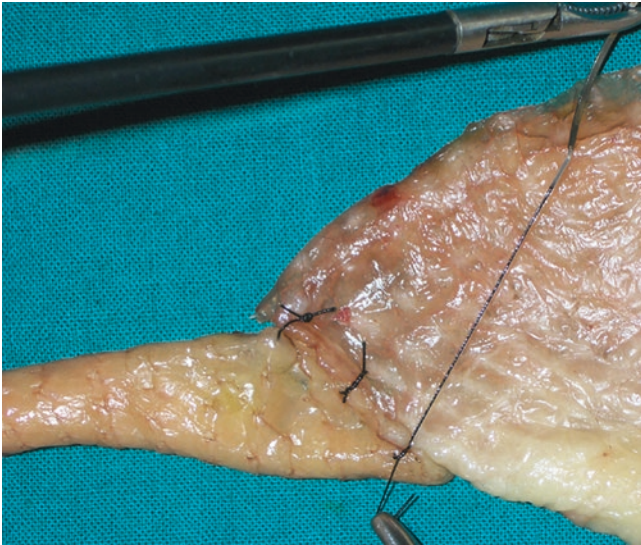


Fig. 64.29 Method of subsequent anterior layer suturing

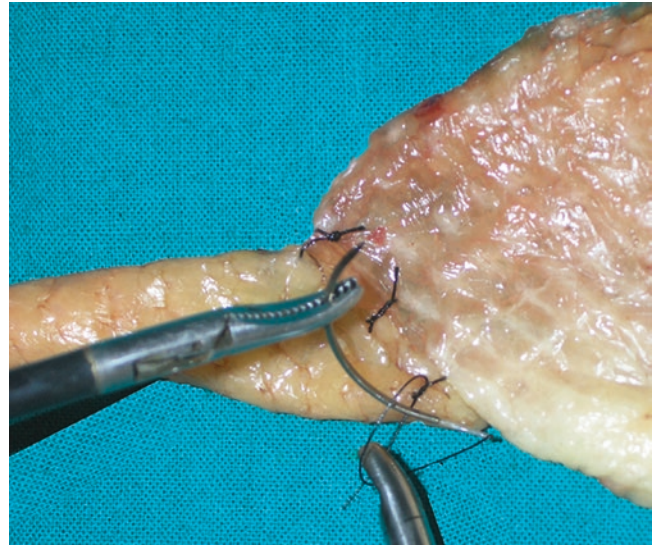


Fig. 64.30 If the suture is short, needle may be used to throw a knot

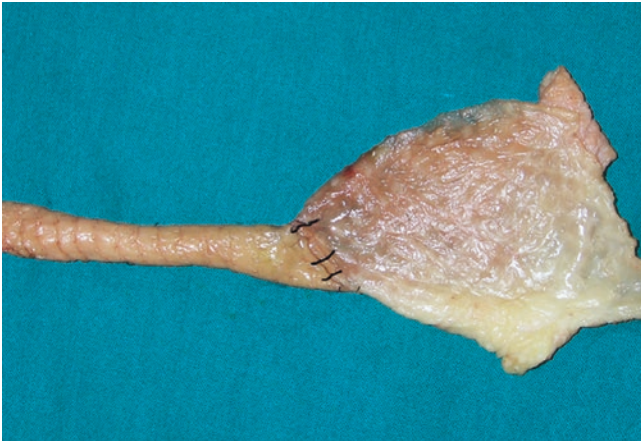

Fig. 64.31 Completed anterior layer suture

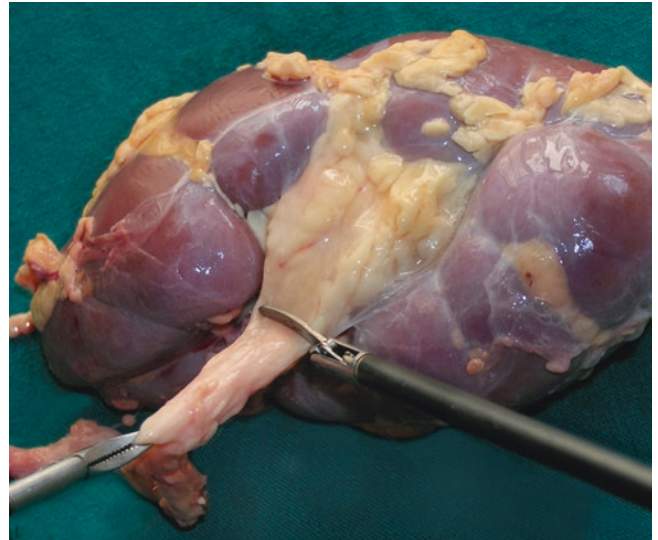

Fig. 64.32 Division of UPJ (Pyeloplasty model of animal kidney)

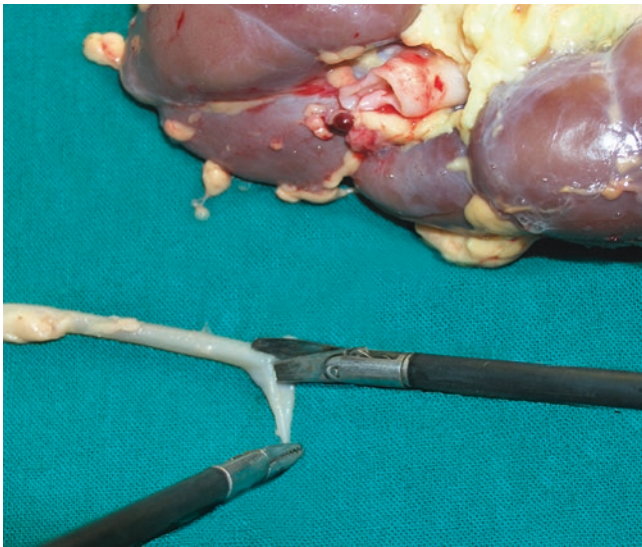


Fig. 64.33 Method of spatulation of upper ureter laterally

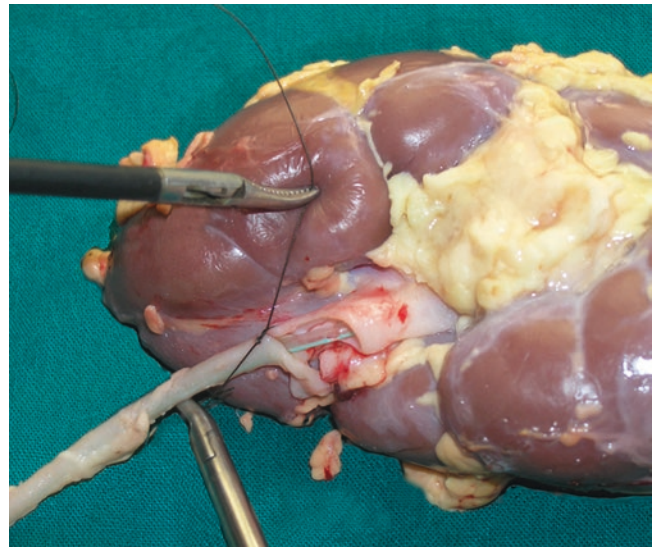


Fig. 64.34 Apical suture practiced

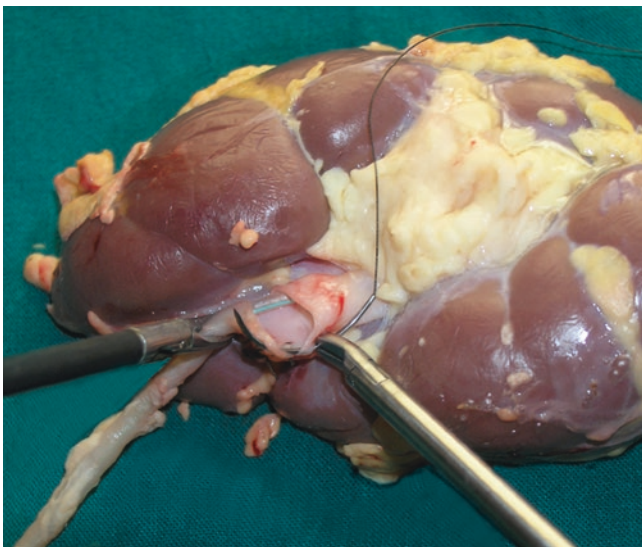


Fig. 64.35 Subsequent posterior layer suturing

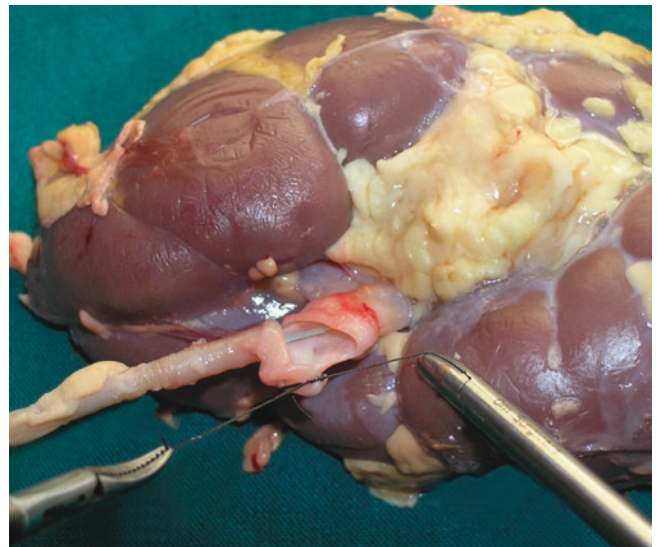


Fig. 64.36 Subsequent posterior layer suturing

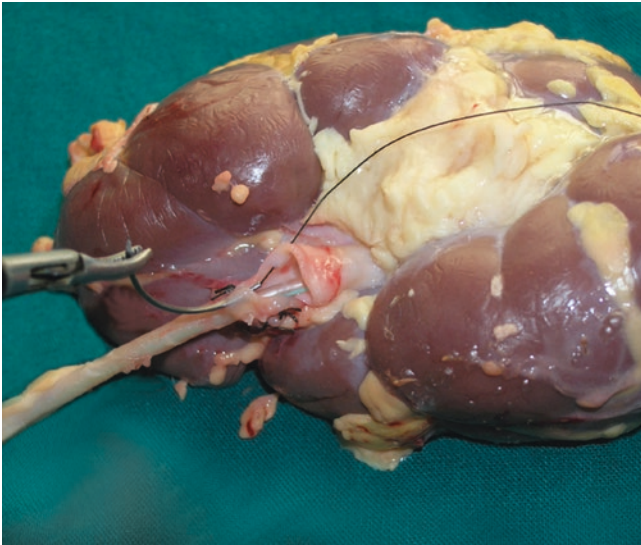


Fig. 64.37 Method of taking continuous suture

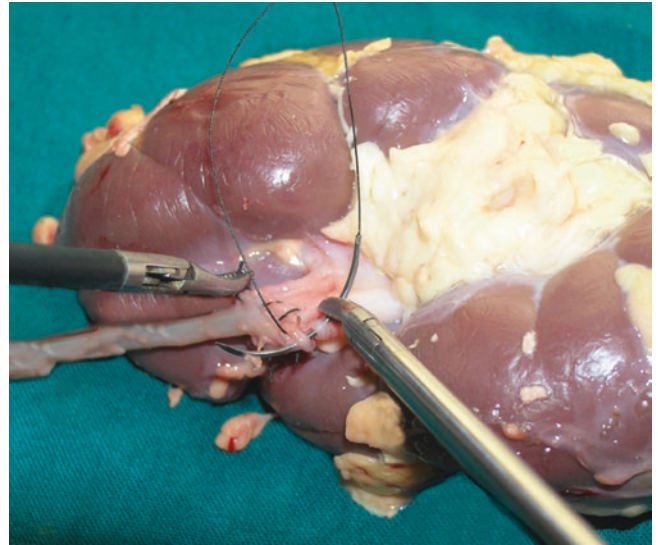


Fig. 64.38 Emphasis on equidistant bites

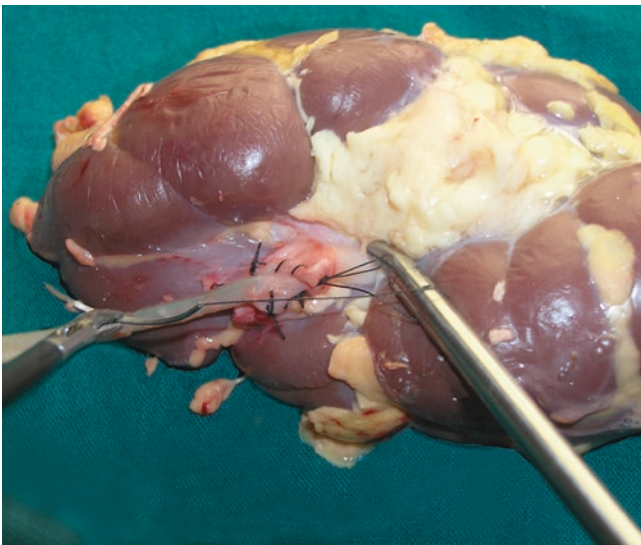


Fig. 64.39 Method of knotting

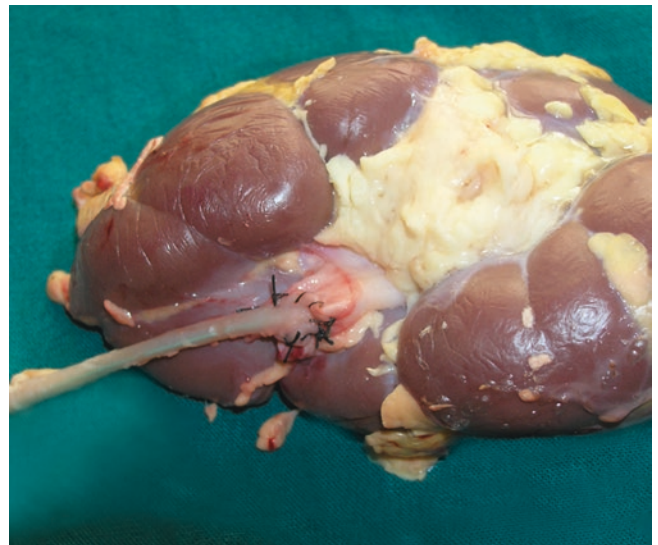


Fig. 64.40 View after dismembered pyeloplasty

64.9 Model for Vesico: Urethral Anastomosis (Chicken Skin)

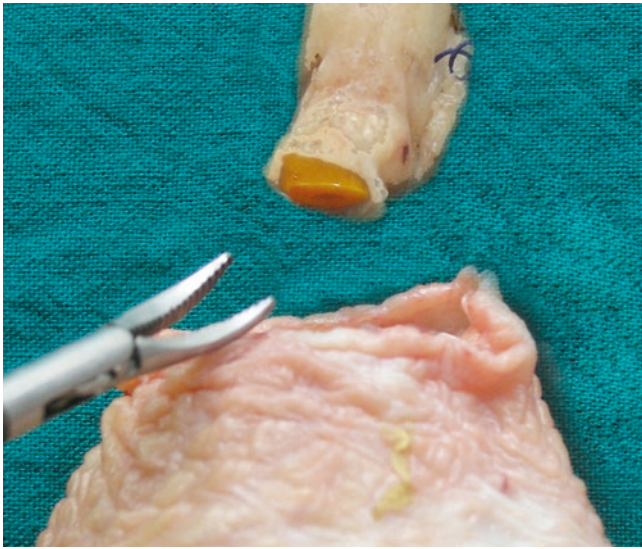


Fig. 64.41 Urethrovesical module made of chicken skin

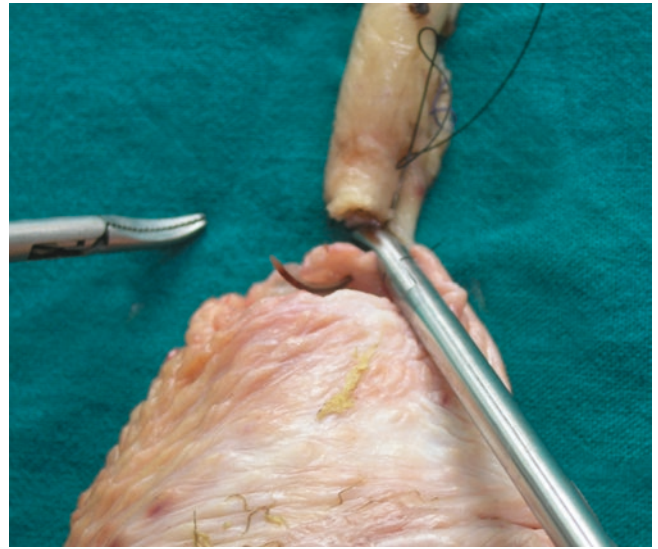


Fig. 64.42 Initial suture taken outside in through bladder neck

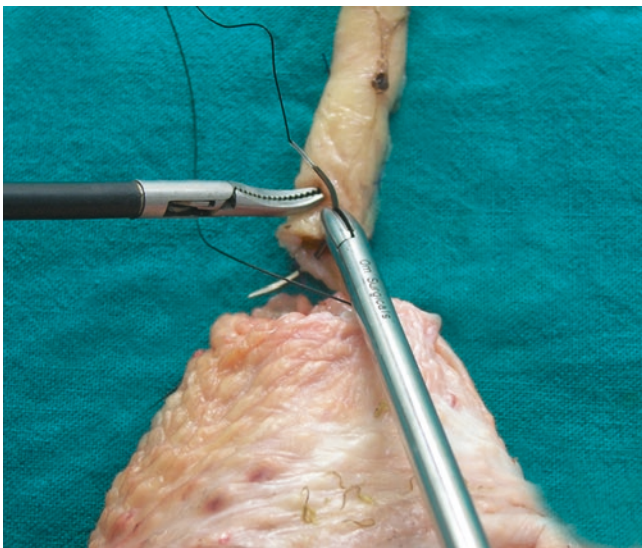


Fig. 64.43 Catheter is slightly withdrawn while taking suture through urethra

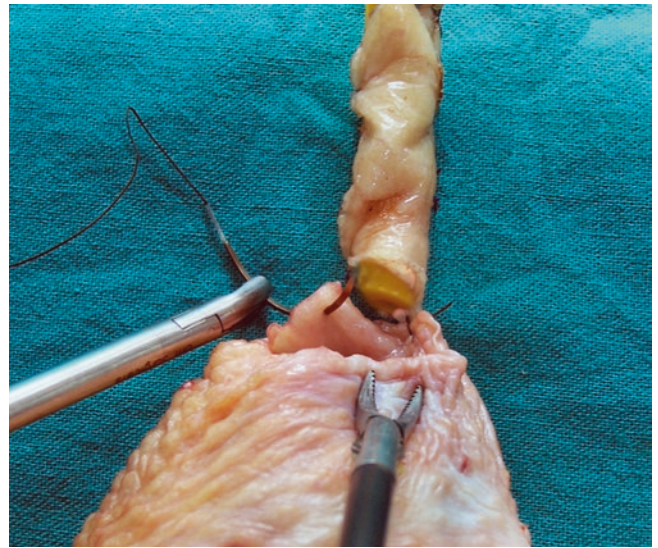


Fig. 64.44 Method of taking subsequent interrupted sutures

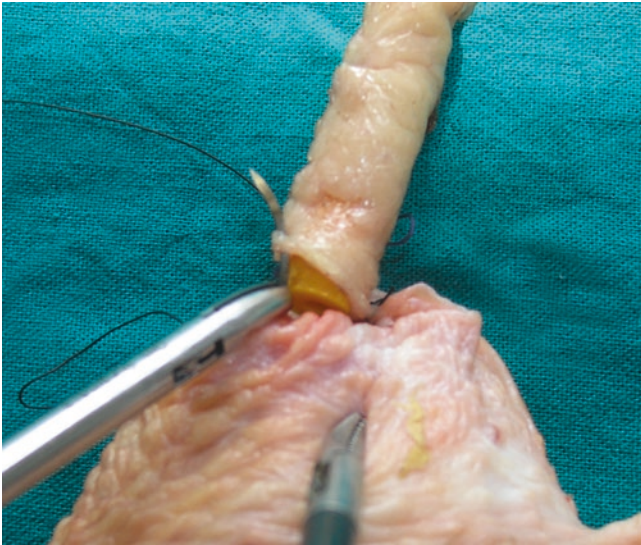

Fig. 64.45 Method of taking subsequent interrupted sutures

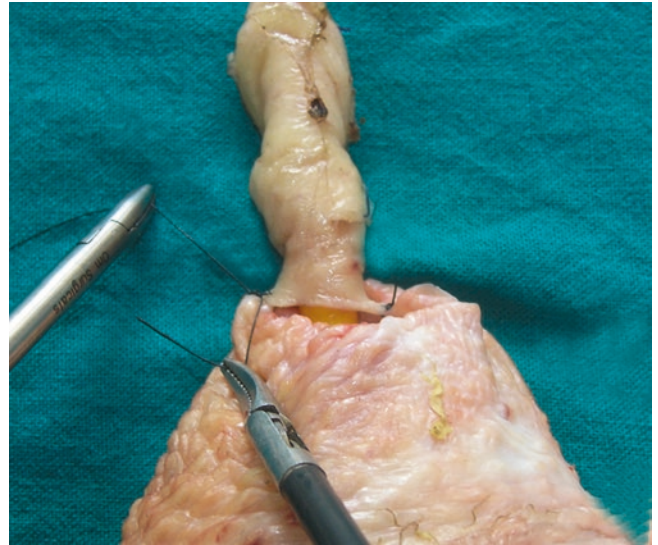


Fig. 64.46 View after posterior layer suture

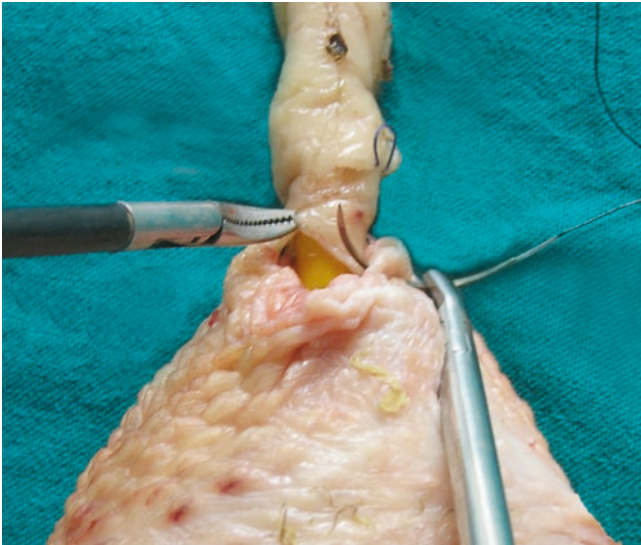


Fig. 64.47 Technique of suture taken in the anterior layer

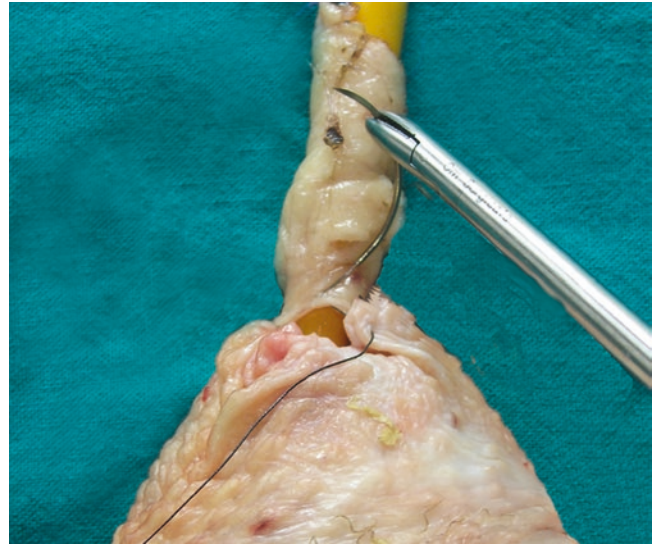


Fig. 64.48 Technique of suture taken in the anterior layer

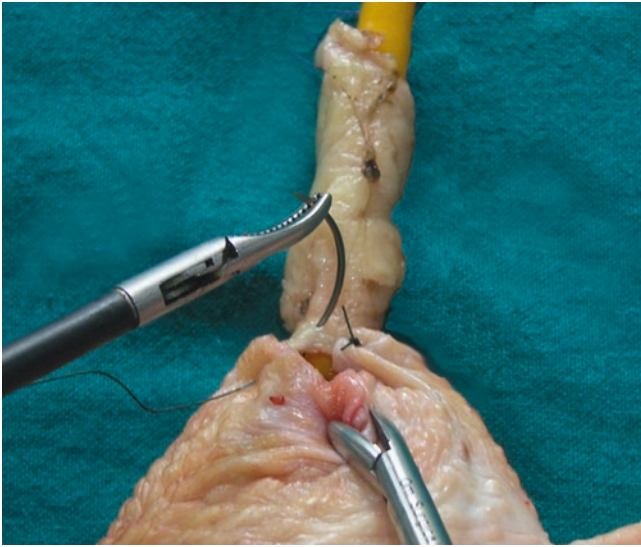


Fig. 64.49 Backhand suture for the anterior layer

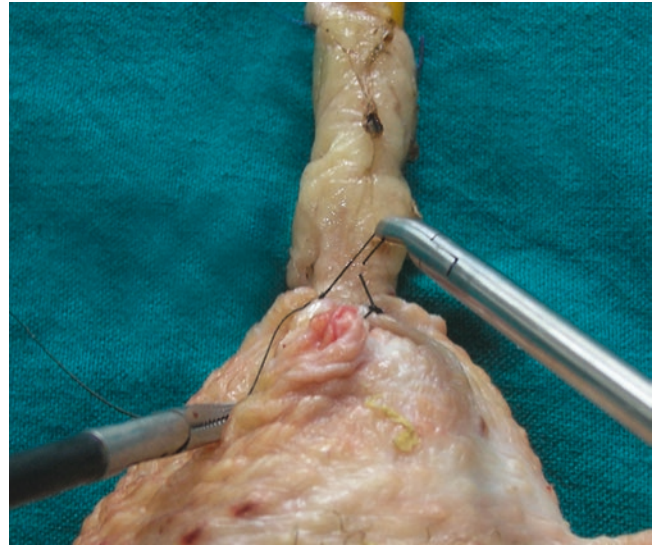


Fig. 64.50 Technique of completing the anterior layer suture

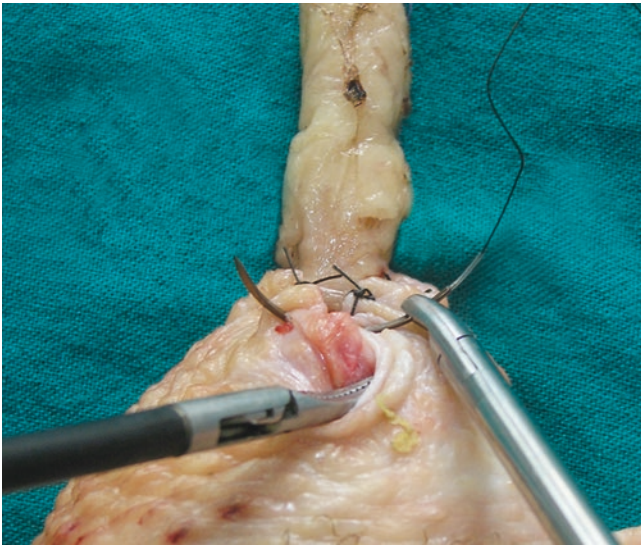


Fig. 64.51 Cystorrhaphy to complete the urethrovesical anastomosis

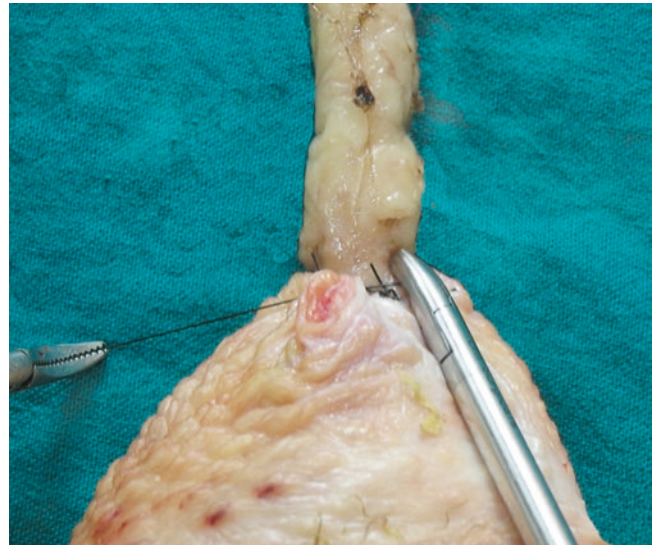


Fig. 64.52 Urethrovesical anastomosis completed

64.10 Porcine Model for Vesico: Urethral Anastomosis

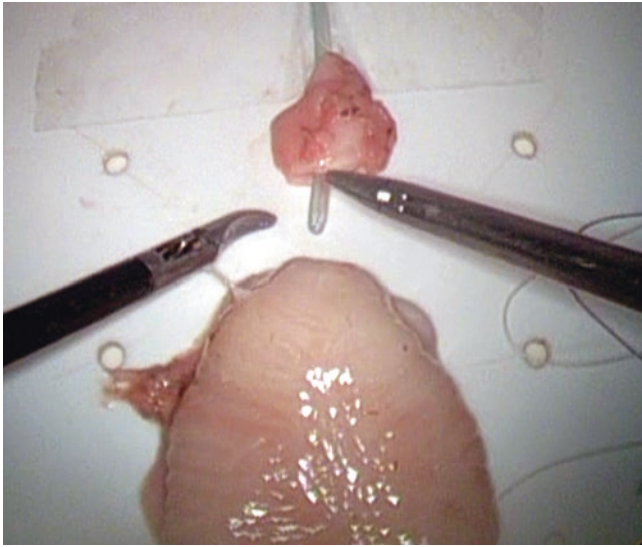


Fig. 64.53 Porcine model of bladder and urethra; Initial set up

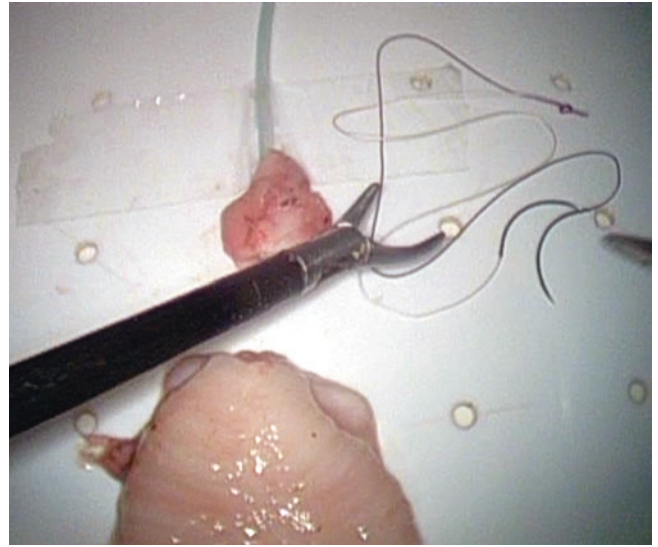


Fig. 64.54 Two Monocryl sutures (3-0) of enough length tied together (Von Velthoven technique)

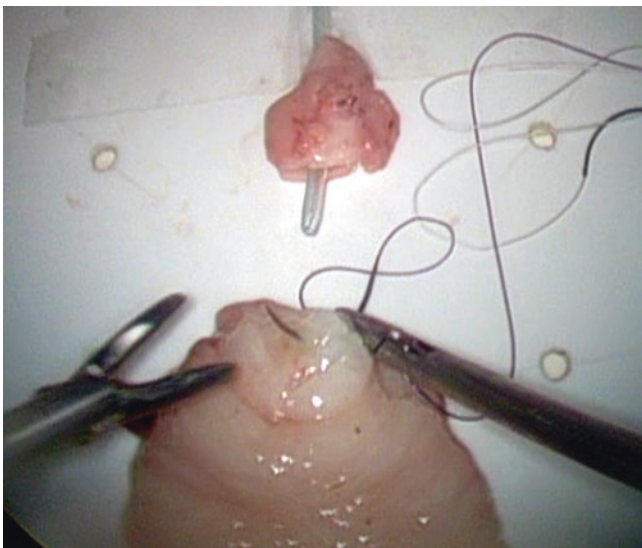


Fig. 64.55 Initial suture taken outside in through the bladder neck

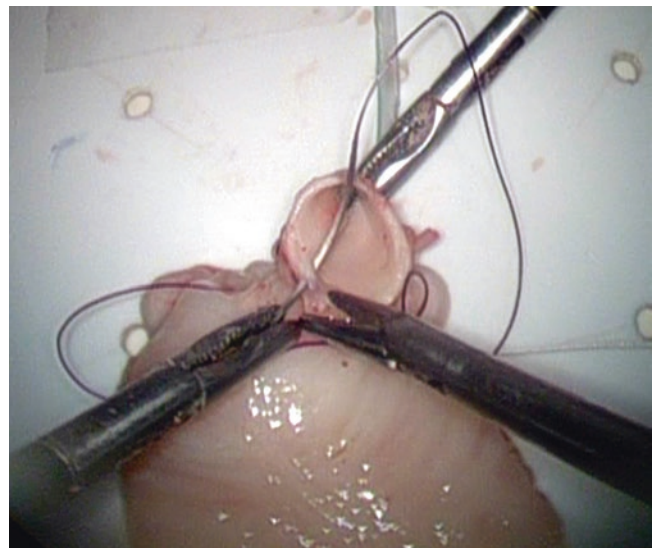


Fig. 64.56 Corresponding suture taken inside out through urethra

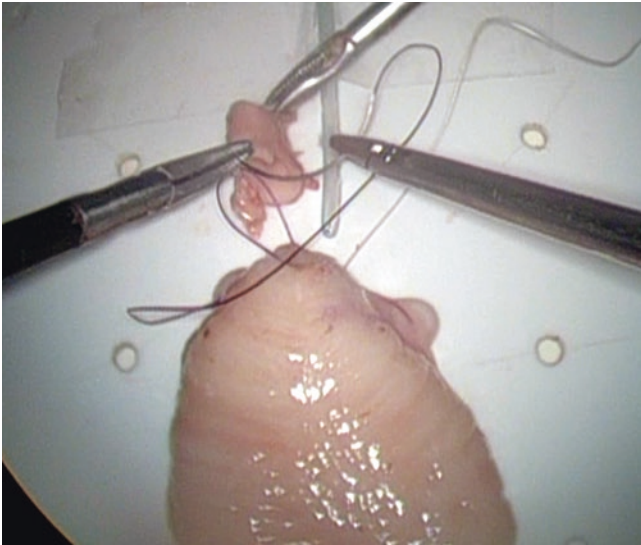


Fig. 64.57 Subsequent suture of posterior layer in clockwise direction

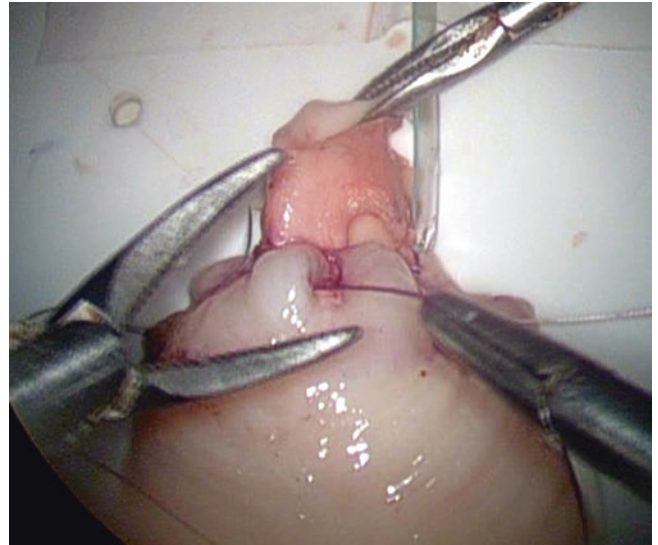


Fig. 64.58 Subsequent suture of posterior layer

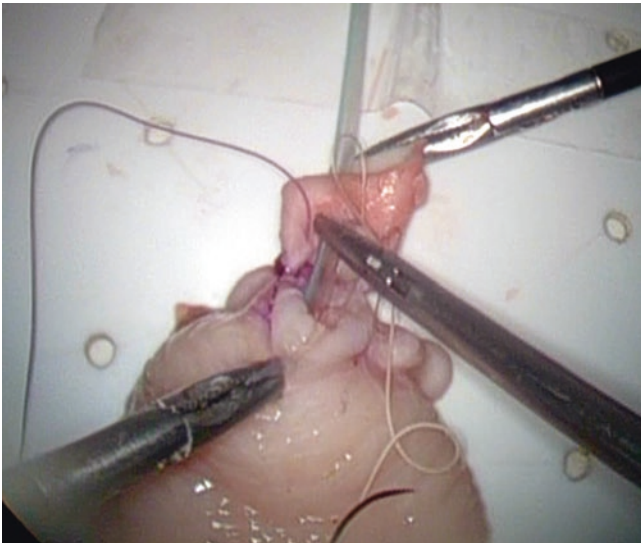


Fig. 64.59 Advancement of catheter

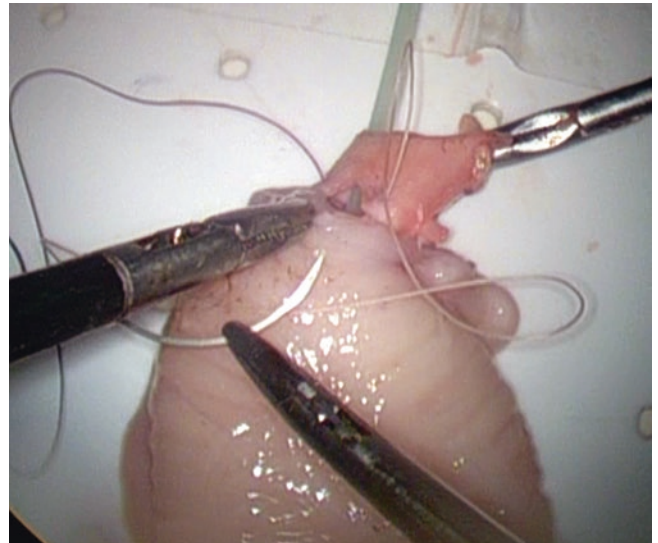


Fig. 64.60 Backhand suturing for anterior layer

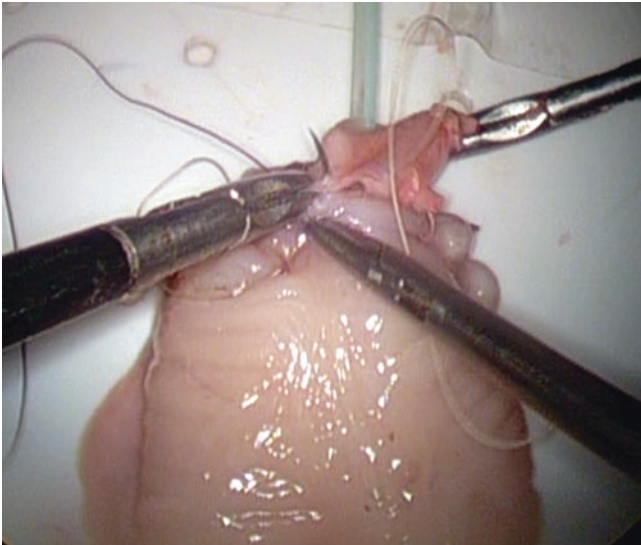


Fig. 64.61 Subsequently other half of the suture is used in anticlockwise direction

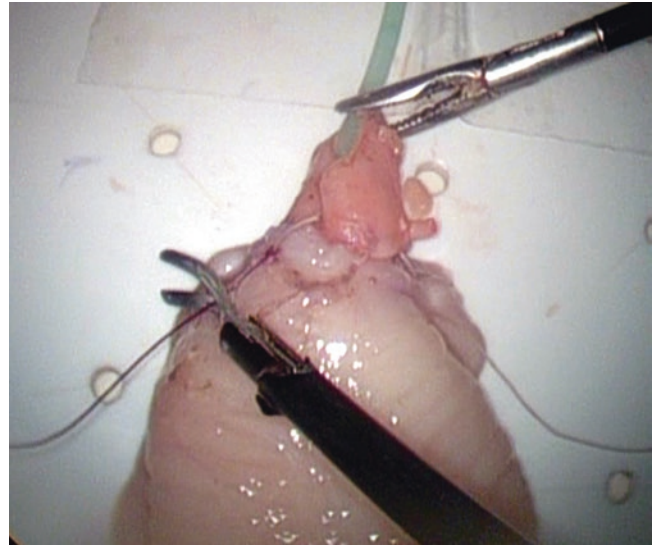


Fig. 64.62 Completed view of urethrovesical anastomosis

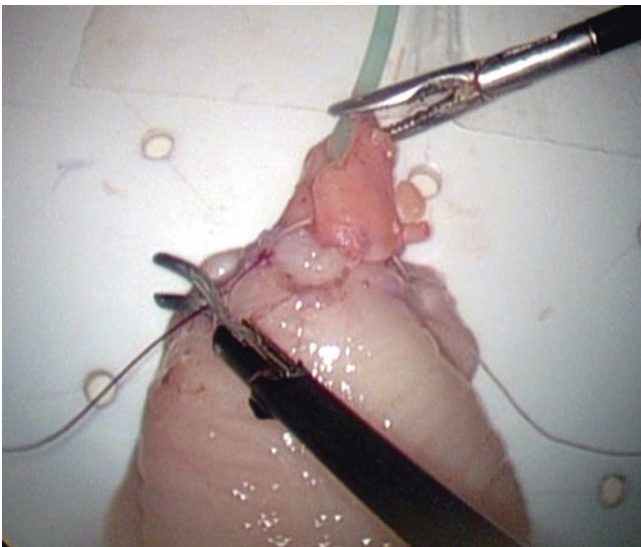


Fig. 64.64 Completed view of urethrovesical anastomosis

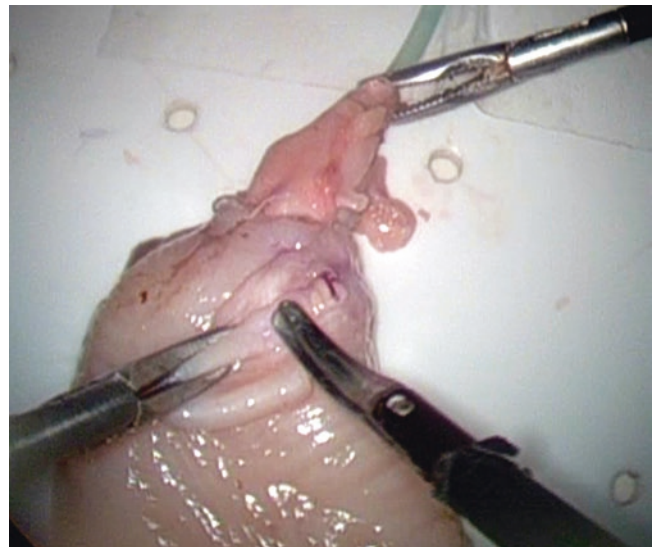


Fig. 64.64 Completed view of urethrovesical anastomosis

64.11 Chicken Gullet Model for Vesico: Urethral Anastomosis

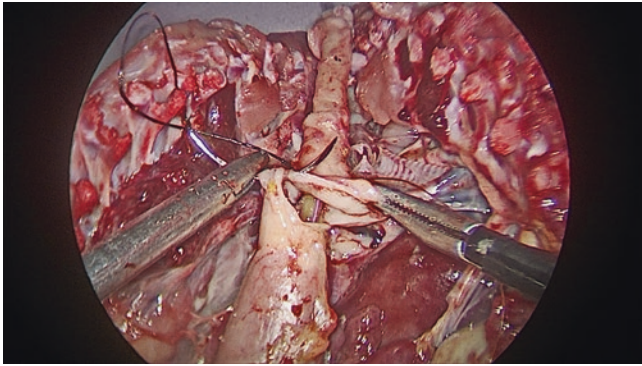


Fig. 64.65 Gullet of chicken improvised for urethrovesical anastomosis

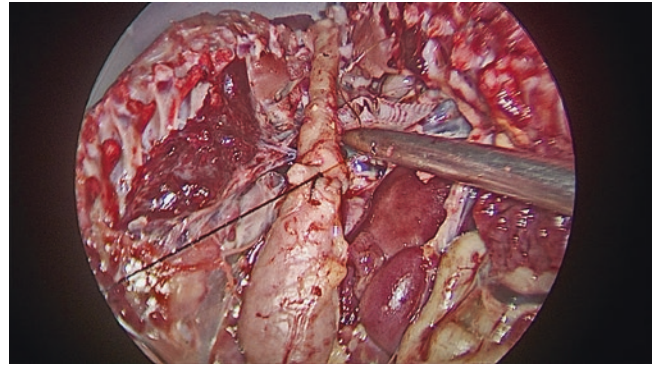


Fig. 64.66 Anastomosis as continuous suture practiced

64.12 IVC Model



Fig. 64.67 Flexible trocar with Satinsky clamp

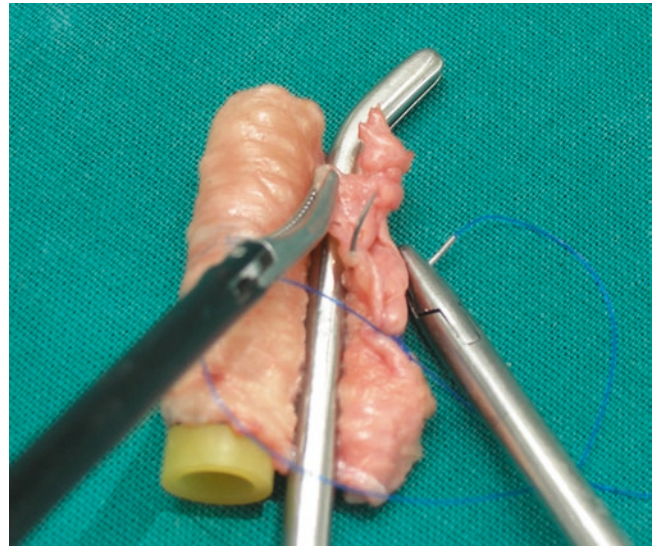


Fig. 64.68 Method of continuous vascular suturing in progress

64.13 Partial Nephrectomy Model

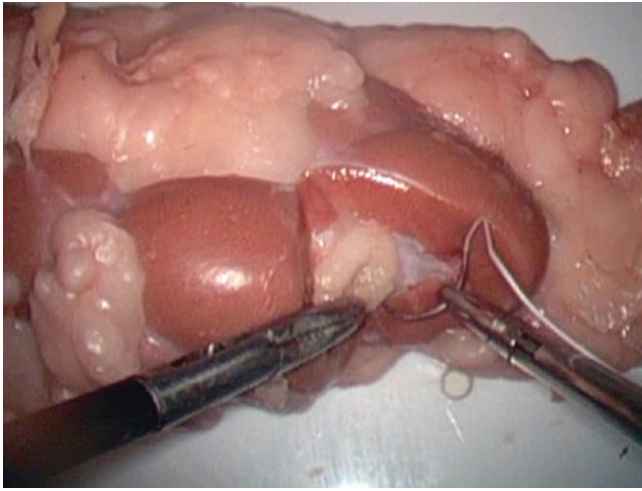


Fig. 64.69 Porcine model for partial nephrectomy

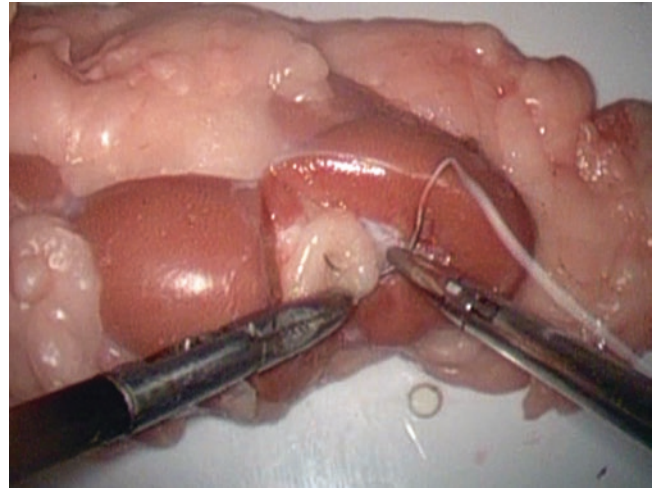


Fig. 64.70 Closure of collecting system with 4-0 vicryl

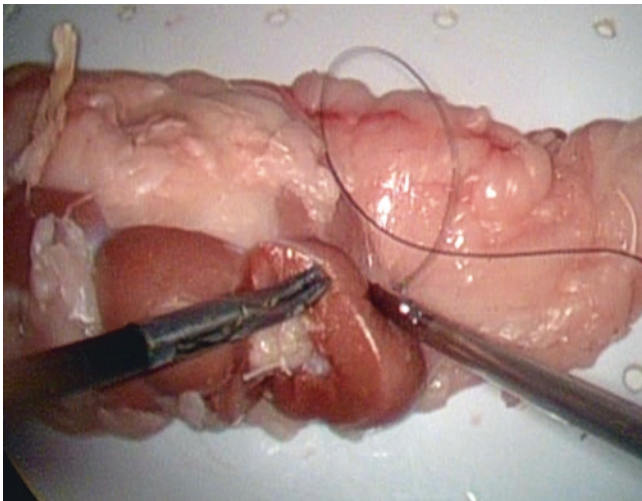


Fig. 64.71 Closure of collecting system with 4-0 vicryl

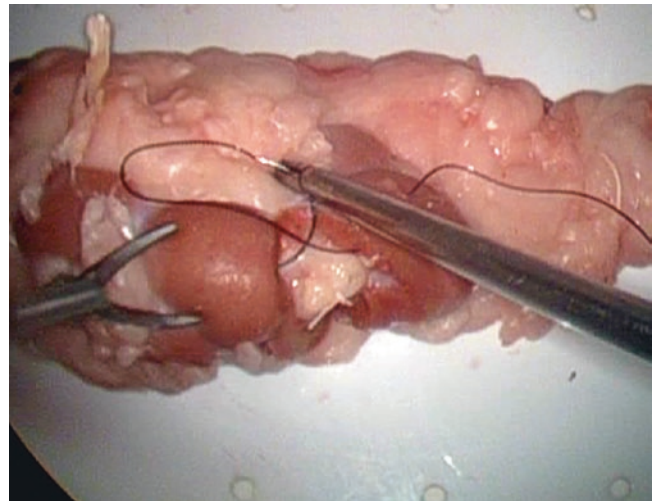


Fig. 64.72 Approximation of cut ends of renal parenchyma with 1-0 vicryl

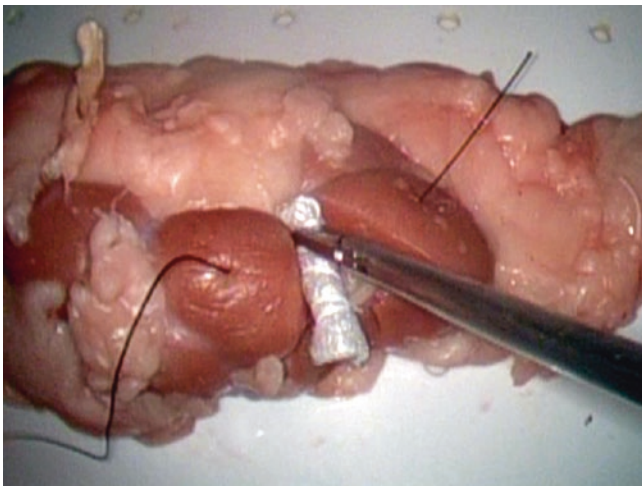


Fig. 64.73 Surgicel bolster interposition

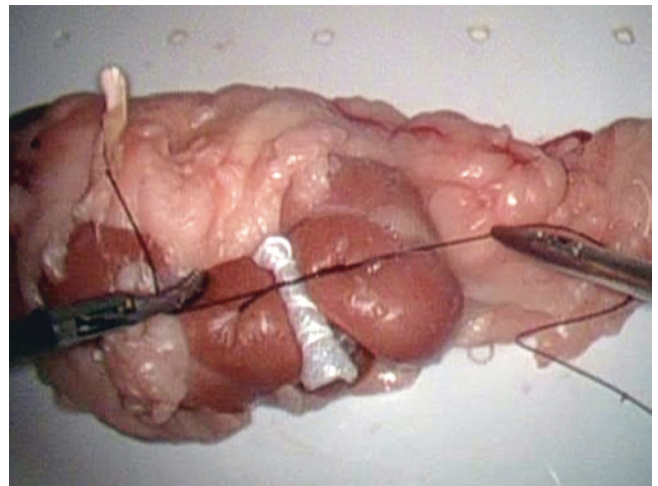


Fig. 64.74 Surgicel bolster interposition

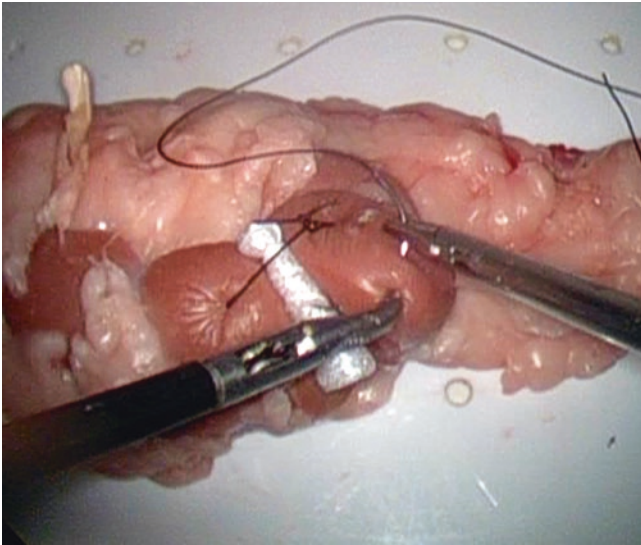


Fig. 64.75 Reinforcement suture

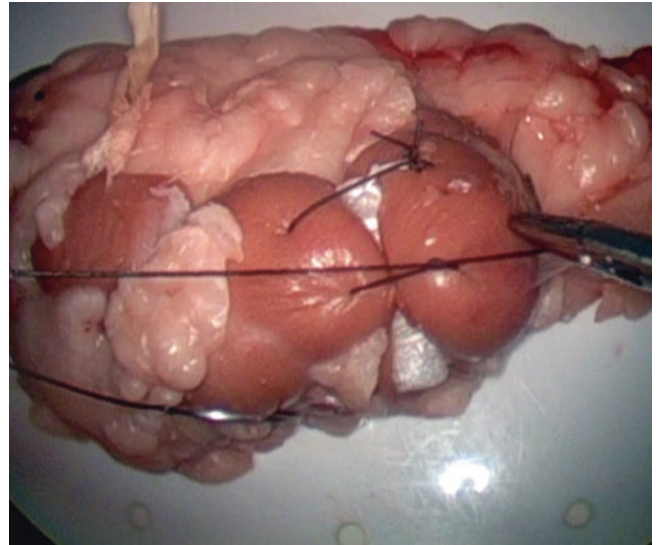


Fig. 64.76 Reinforcement suture

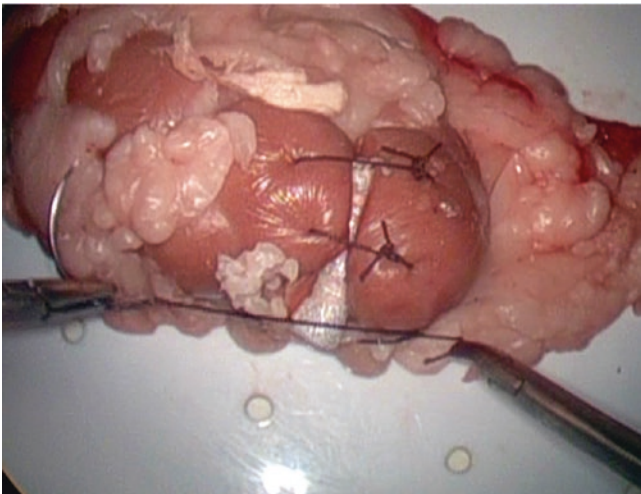


Fig. 64.77 Training with back-hand suture

64.14 Animal Lab Training

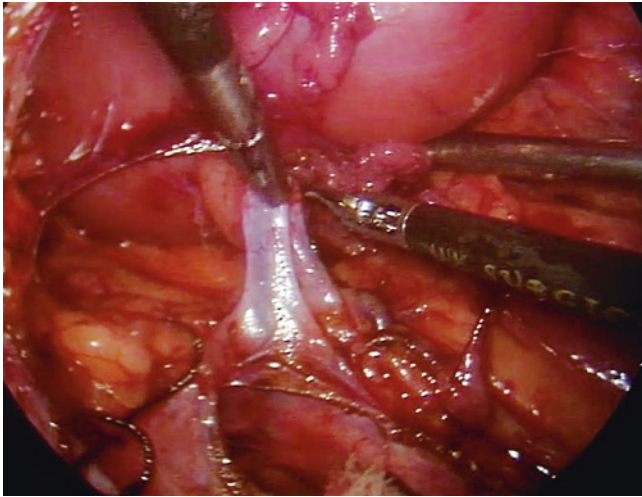


Fig. 64.78 Renal artery and vein dissected

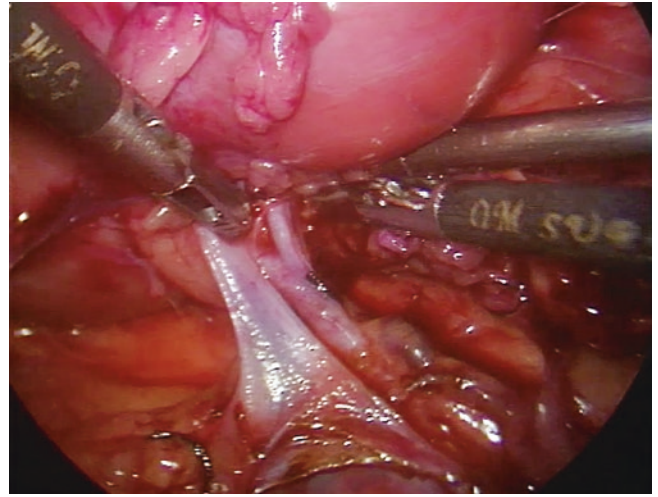


Fig. 64.79 Lower polar segmental artery dissected

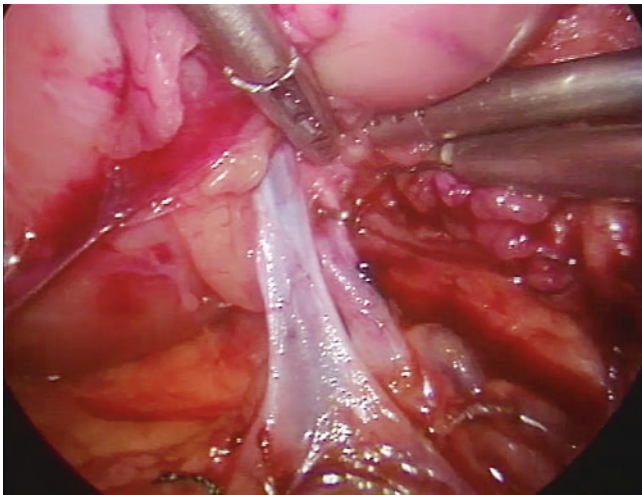


Fig. 64.80 Lower polar artery clipped

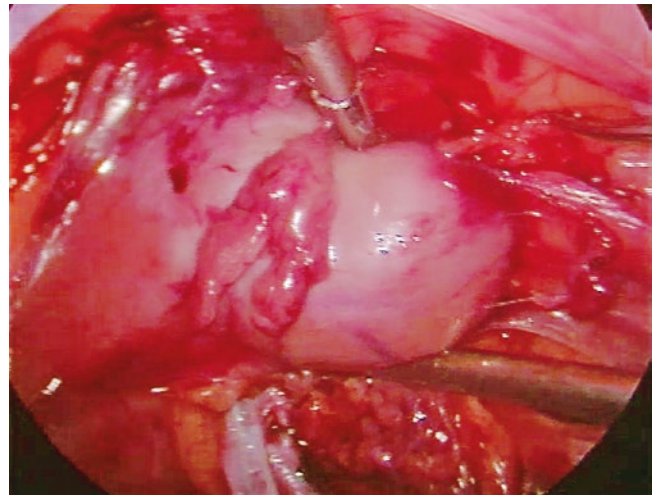


Fig. 64.81 Blanched lower pole after clipping

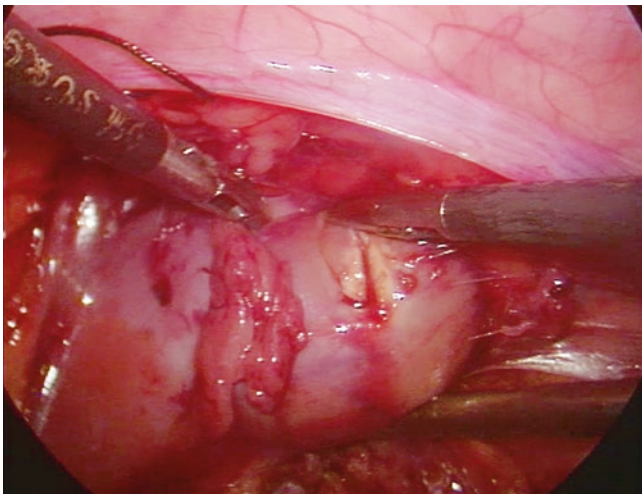


Fig. 64.82 Segment renal parenchyma excised

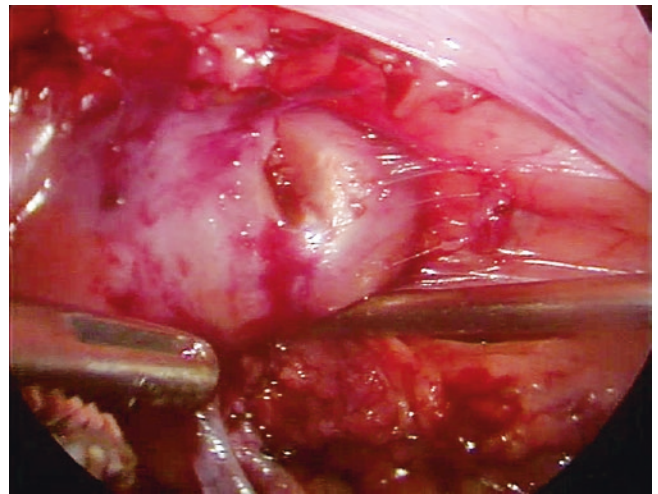


Fig. 64.83 Parenchymal bed after excision of parenchyma

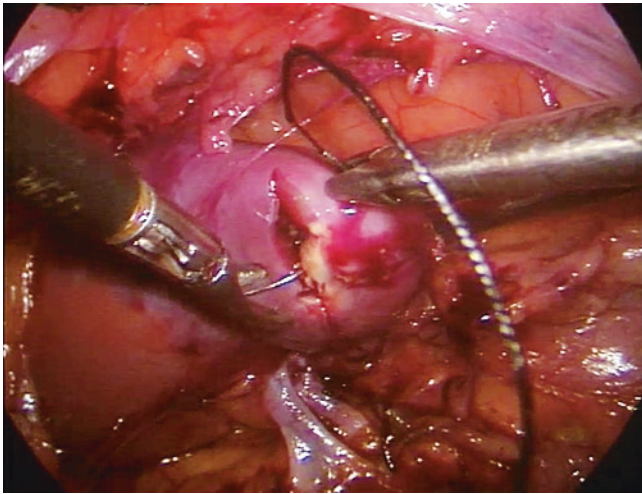


Fig. 64.84 Renal parenchymal suturing started

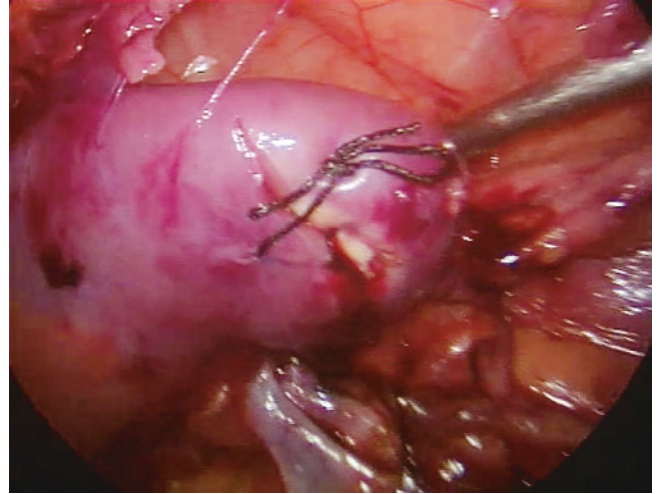


Fig. 64.85 Completed suture

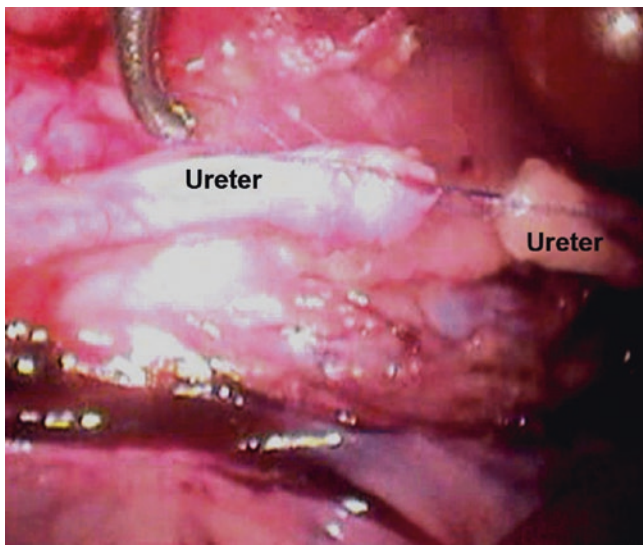


Fig. 64.86 Uretero-ureterostomy practiced

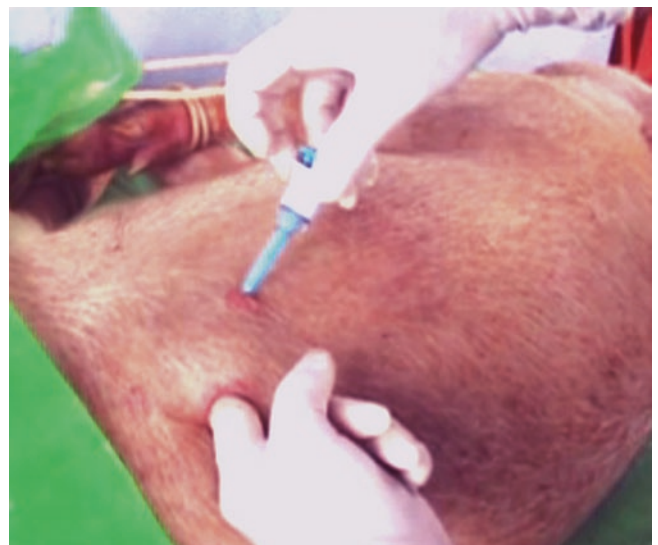

Fig. 64.87 Retroperitoneoscopic space creation and finger guided secondary trocar placement

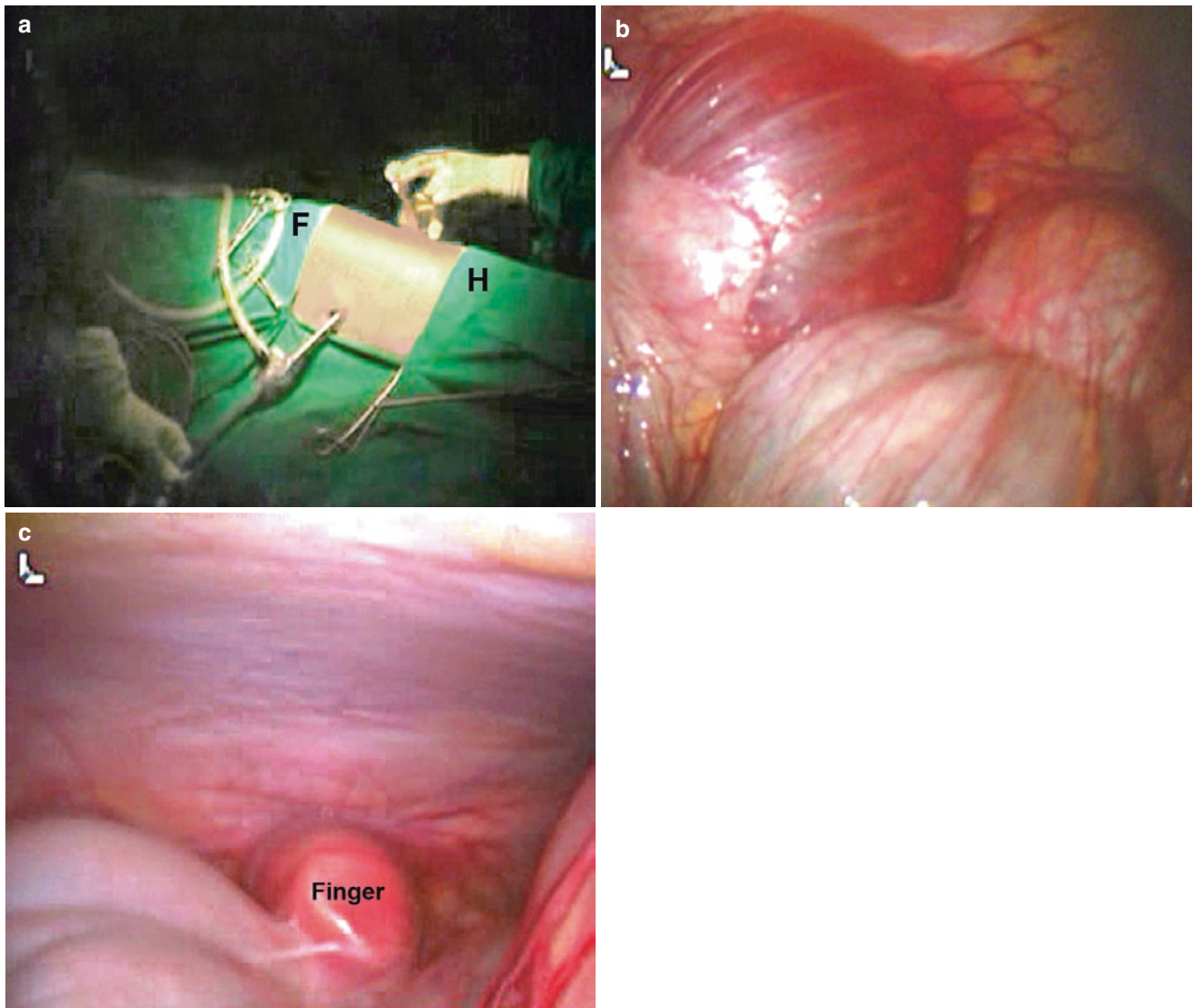


Fig. 64.88 (a) Retroperitoneal balloon inflation. Additional transperitoneal camera port to see transperitoneal view. (b) Retroperitoneal balloon inflated. Transperitoneal view. (c) Finger dissection in the retroperitoneum as seen with Transperitonela camera

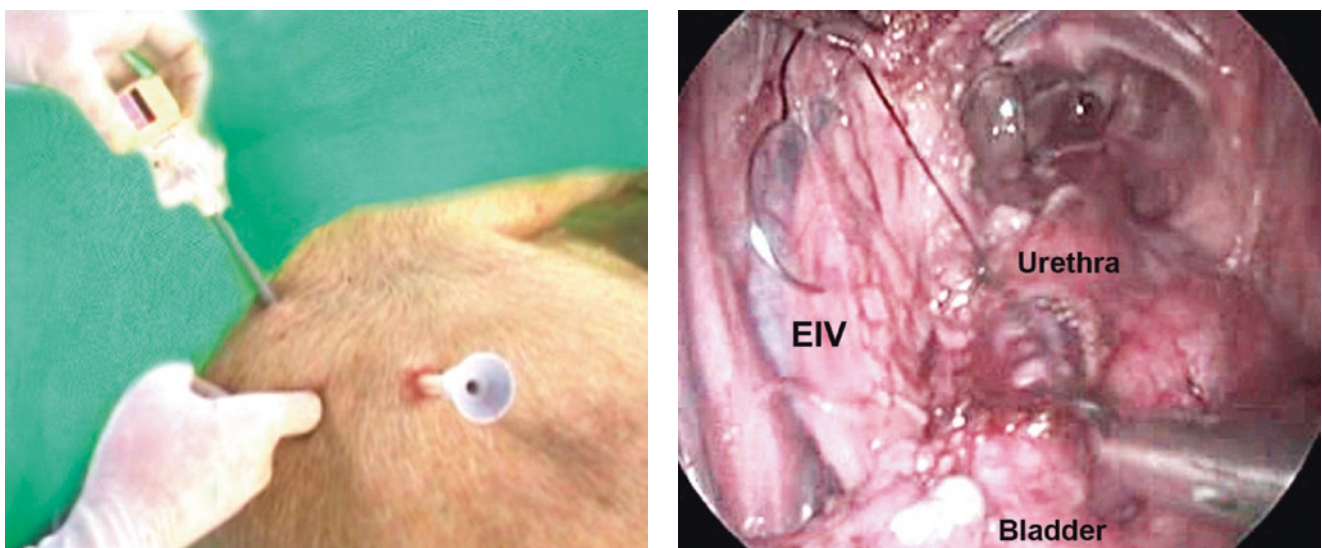


Fig. 64.89 Retroperitoneoscopic space creation and finger guided secondary trocar placement

Fig. 64.90 Learning urethro-vesical anastomosis in porcine model

64.15 Live Demonstration in Human

Fig. 64.91 Live demonstration in progress

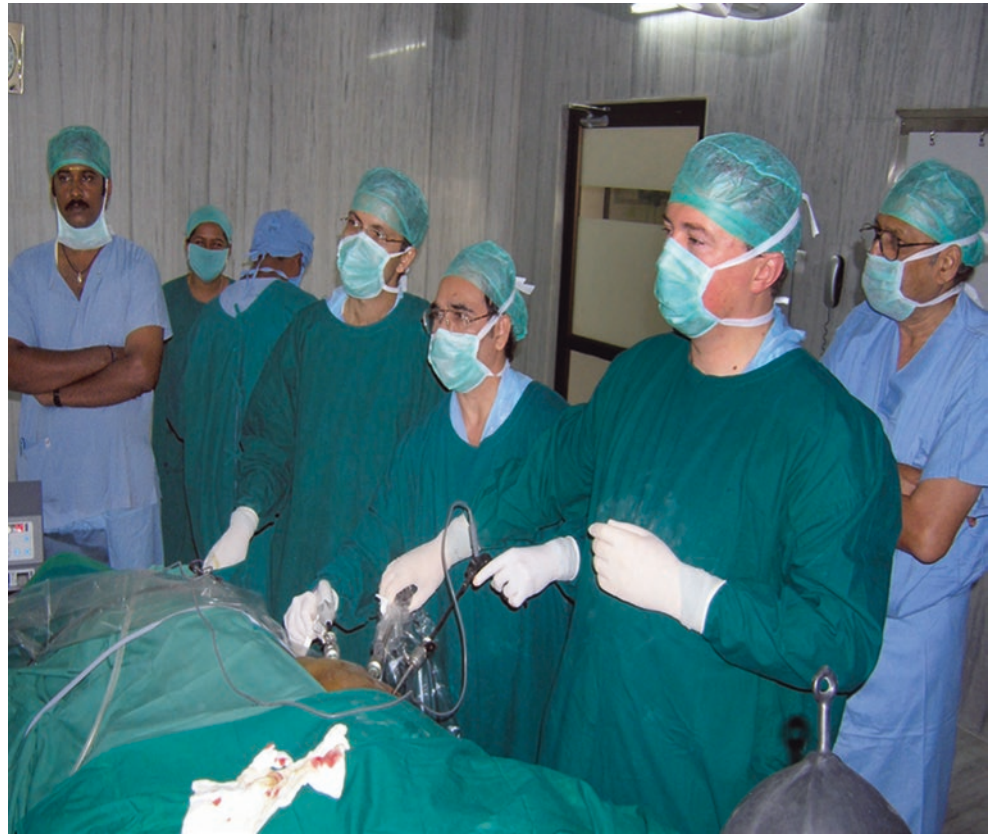
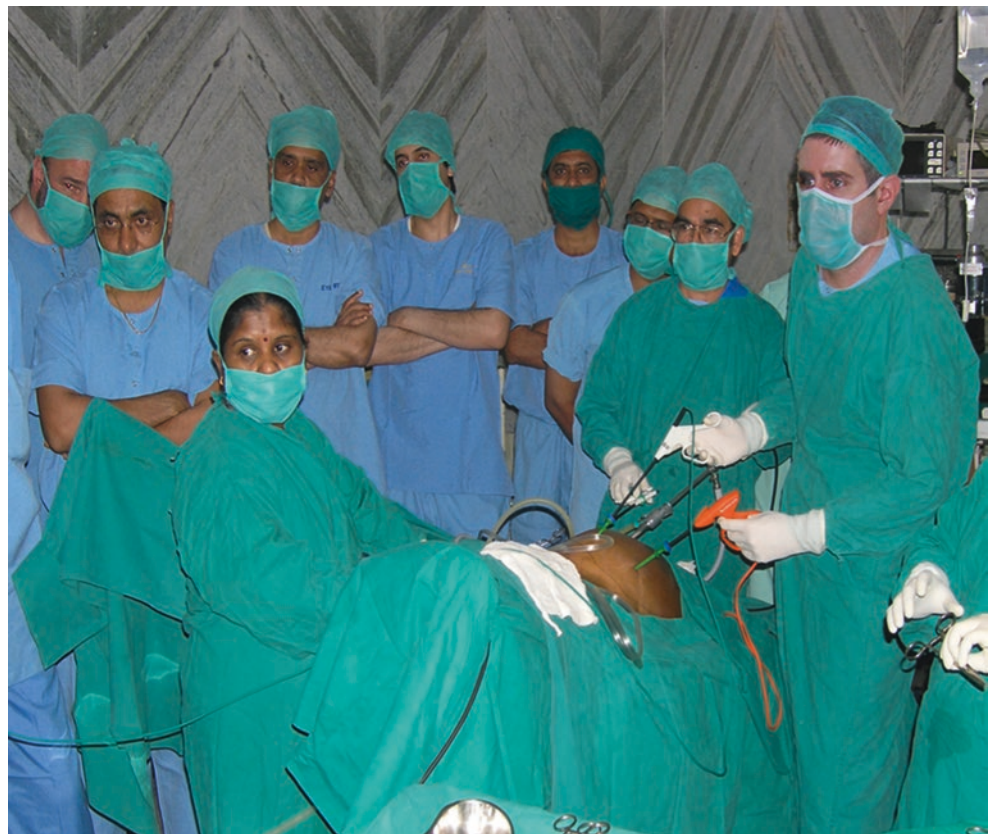
Fig. 64.92 Live demonstration in progress



References

1. Nadu A, Olsson LE, Abbou CC. Simple model for training in the laparoscopic vesicourethral running anastomosis. *J Endourol.* 2003;17:481–4.
2. Ramalingam M, Senthil K, Selvarajan K, Pai MG. Training in laparoscopic urology in developing countries – evolution of simple training modules and their evaluation (Abstract). *J Endourol.* 2006;20(1):A44.
3. Ramalingam M, Senthil K, Selvarajan K, Pai MG. Urolap training in India-developing country scenario (Abstract). *J Endourol.* 2004;18:A231.
4. Teber D, Dekel Y, Frede T, Klein J, Rassweiler J. The Heilbronn laparoscopic training program for laparoscopic suturing: concept and validation. *J Endourol.* 2005;19:230–8.

Nicholas Raison, Catherine Lovegrove, Kamran Ahmed,
and Prokar Dasgupta

Surgical training is undergoing sweeping changes. Having long followed the Halstedian master-apprentice model, new pressures and challenges are transforming the way in which surgeons are taught. Increasing training demands on ever more limited healthcare budgets are driving the need for efficiency. Additionally expectations for zero-complication surgery have led to the expansion of safeguards, and the standardisation of practices. As a result, the traditional model of “learning by doing” dependent on case volume is no longer feasible. Dedicated simulation-based training curricula are required to enable training in the necessary technical and on technical skills.

more advanced training however its effectiveness is yet to be formally established. Dry lab and basic animal tissue models also predominantly provide basic skills training but they do also allow more advanced techniques such as urethrovesical anastomosis to be practiced and refined. Live animal models and cadaveric models arguably provide the most realistic surgical simulation and enable advanced trainees to undertake full procedural training. However they are limited by cost, the need for specialised facilities and ethical concerns (operating on animal models is currently banned in the UK).

65.1 Simulation Training in Robotic Surgery

Robotic assisted surgery (RAS), as relatively new but rapidly evolving sub-speciality is well suited to simulation training. Virtual reality (VR) simulators comprise the majority of the available training tools and have undergone the most comprehensive validation. Recognition of the importance of structured training curricula is driving innovation in augmented reality, dry lab and wet lab models. The role of VR simulation in training novice robotic surgeons is increasingly being recognised. VR simulators enable training to be moved out of the operating room, allowing trainees to develop the necessary robotic skills in a safe environment and progress along the initial phase of the learning curve. Teaching sessions can be planned around rotas to allow more efficient and methodical training. Procedure specific VR simulation is being increasingly introduced to provide

65.1.1 E Learning Modules

Although the focus of robotic training is on the achievement of technical proficiency, it is important to have a thorough understanding of the theoretical basis to robotic surgery before undertaking practical training.

E-learning, a term used to describe all online, computer based teaching and education is now widely used in surgical education. Incorporating a range of teaching methods and technologies, it provides greater flexibility to both trainers and trainees, allowing teaching techniques to be tailored to the audiences. Particularly in postgraduate surgical training, having the ability to fit teaching around clinical schedules is key to a successful programme. Whilst e-learning is dependent on access to a computer with internet access, advances in online technology and data connection speeds allow more interactive learning platforms using videos and graphics to enrich the learning experience. The effectiveness of e-learning has now been demonstrated in comparison to traditional teaching in surgical trainees in a number of studies [3]. Consequently it has been integrated into a number of surgical curricula. American general surgical residents undergo training using the SCORE website. A modular curriculum covering the “care of diseases” and

N. Raison, MBBS, BSc, MRCS (✉) • C. Lovegrove • K. Ahmed
P. Dasgupta, MSc, MD, DLS, FRCS, FEBU
MRC Centre for Transplantation, Kings College, London, UK
e-mail: nicholas.raison@kcl.ac.uk; catherinelovegrove1@gmail.com;
kamran.ahmed@kcl.ac.uk

“performance of operations” is delivered using online resources. Similarly in Europe, e-learning forms the first step in the European Association of Urology Robotic Training Curriculum. All fellows have to complete e-modules developed an expert panel of robotic surgeons prior to commencing simulation training [9].

65.2 Virtual Reality Simulation

A wide variety of commercial virtual reality simulators are now available for robotic training. The majority have undergone extensive validation and are becoming increasingly ubiquitous in robotic training programmes.

Amongst the most widely validated are the da Vinci Skills Simulator (Intuitive Surgical, Sunnyvale, CA, USA) and the dV-Trainer™ (Mimic Technologies Inc., Seattle, WA, USA) (Picture 65.1). The da Vinci Skills Simulator (dVSS) is the only device to work directly with the da Vinci Robot. Attaching the dVSS “backpack” directly to the robot console allows the user to practice with the Da Vinci in a virtual environment. Whilst this comes at the disadvantage that the simulator can then only be used when the robot is free, it does provide the most realistic VR experience. Introduced in 2011, it now uses the “Msim” software (Mimic Technologies Inc., Seattle, WA, USA) with training modules in various basic robotic skills. Extensive studies have demonstrated face, content, construct and concurrent validity.

In contrast the dV Trainer is a stand-alone simulator with the hand controls connected via tension cables unlike the dVSS. It has also undergone extensive validation with mul-

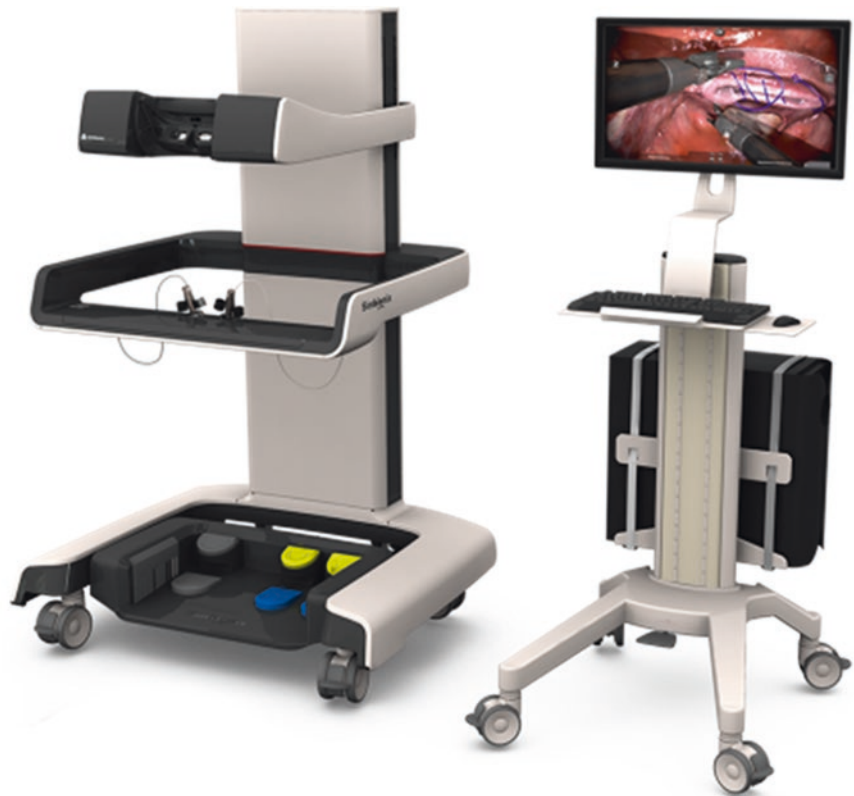iple studies showing face, content and construct validity. Furthermore predictive validity has also been proven whereby training on the dV-Trainer is shown to improve performance on the Da Vinci robot. In 2014 Mimic released a procedure specific “augmented reality” simulator. Called the Maestro system, it provides partial nephrectomy training through manipulation of a 3d video. Further training modules in prostatectomy and low anterior resection are in development.

Other validated standalone VR simulators include the Robotic Surgical Simulator (RoSS) (Simulated Surgical Systems, Buffalo, NY, USA), SimSurgery Educational Platform (SEP) Robot™ (SimSurgery®, Oslo, Norway) and RobotiX Mentor (Simbionix, Cleveland, OH, USA) (Picture 65.2). The RoSS simulator integrates the Fundamental Skills of Robotic Surgery (FSRS) curriculum allowing trainees to complete modules in basic console training, psychomotor Skills, basic surgical skills, and intermediate surgical Skills. It was also the first simulator offering procedure specific training in prostatectomy, cystectomy and lymph node dissection using its “Hands-on Surgical Training” (HoST). Although the SEP uses motion tracked hand controllers, contrasting to the Da Vinci controls, and a 2d video screen, it has still be shown to be useful in robotic skills training. Simbionix have developed the newest simulator to be released, the RobotiX Mentor. Again the hand controls differ with free floating controllers rather than fixed, but uniquely in addition to basic training modules, full procedural training is also available with incorporation of a laparoscopic simulator allowing an assistant to take part.

Picture 65.1 Mimic
dV-Trainer



Picture 65.2 Simbionix
RobotiX Mentor



65.3 Dry Lab Simulation

Compared to VR simulators, far fewer dry lab models have been validated for robotic surgery. Models for both basic skills and procedure specific training have been developed. Basic skill models, which provide training in fundamental robotic skills such as endowrist manipulation and camera control, have been shown to be effective compared to both VR and wet lab simulation. Dry lab models have now also been shown to be effective in more advanced training. SIMPLE (Simulated Inanimate Model for Physical Learning Experience) is a 3d printed replica of a kidney and tumour. Although it has only undergone limited validation, it does provide objective feedback on ischaemia time, estimated blood loss and positive margins. Other 3d models are available and their validation is eagerly awaited.

65.4 Wet Lab Simulation

Whilst live animal, cadaveric and animal tissue models have all been used in robotic surgical training, validation has been limited. Tissue models have been developed for both RARP and RAPN using porcine specimens. Animal models (porcine and chicken) are used as part of the EAU robotic training curriculum however specific data on their effectiveness has not been published. Likewise cadaveric models have undergone initial assessment showing face, content and construct validity however data is limited by low participant numbers.

65.5 The Role of Learning Curves

In 1936, T.P Wright described the practical application of learning curve theory to aeronautical manufacturing in the USA [10]. By comparing trainees' learning with productivity he identified a relationship with reduced production cost.

In surgery, historically the assumption has been that training-time and larger caseloads translate to improved surgical skill, eventually reaching a level of "competence" with improved outcomes. At this point the learning curve plateaus, indicating consistency in surgical practice [4]. The aim of improved training techniques, is to bring forward this point of plateau in the learning curve. Knowing when trainees can be expected to operate with the necessary level of proficiency is important for both planning surgical education programmes and for maintaining patient safety. Different parameters can be used in learning curve analysis. These can include surgical variables, patient variables or variables measured in a simulated environment (Table 65.1).

Through analysis of learning curves for a procedure or the sub-steps within an operation it becomes possible to subsequently plot the stage of a surgeon in their training. Trainees can be compared to experts, demonstrating construct validity for the learning curves. Consequently these can indicate when proficiency has been attained that the trainee is likely to be safe to move from operating in a simulated environment to operating on a patient in theatre. Furthermore this may allow accreditation at a given skill level to be awarded. It is also possible to utilise learning curves to indicate the minimum training hours or experience required prior to undertaking specific procedures.

Table 65.1 Variables for use in learning curve analysis

Surgical variables	Patient variables	Simulated variables
Operative time	Blood loss	Instrument clash
Conversion rate	Complications	Accuracy of movement
Resection margins	Length of hospital stay	Force exerted

65.6 Modular Training Pathways

Stolzenburg first proposed the use of modular training to shorten the learning curve associated with urological procedures [8]. This involves a defined sequence whereby surgeons progress through training in surgical steps requiring increasing levels of technical skill. A modular approach to training enables surgeons to participate in operations up to the level at which they are proficient with their seniors intervening for the more challenging steps where they are yet to attain competence.

Training pathways have been formulated incorporating this modular design. The European Association of Urology (EAU) Robotic Urology Section (ERUS) developed a robotic curriculum incorporating a modular design for robot assisted radical prostatectomy (RARP) [9]. This begins with theory-based training through online e-learning modules followed by virtual reality, dry-lab and wet-lab simulator experience. After establishing the foundations of training, a week of intensive lab-based training is undertaken including use of a dual console to facilitate mentoring of surgeons while operating in real-time. Trainees' technical and non-technical skills are assessed at baseline and after 28, 35 and 180 days to assess progression along the procedural learning curve. Finally, fellows submit a recorded case of RARP that they have performed independently. It is assessed by blinded reviewers using the Global Evaluative Assessment of Robotic Skills (GEARS) score and a generic dedicated scoring system. Successful completion of the curriculum results in certification as an ERUS Robotic Fellow.

At present there are few urological operations other than RARP with procedure-specific training and assessment tools available for use [5]. It is essential that these tools are evaluated in terms of content validity, inter-rater reliability, test-retest reliability, feasibility, acceptability, educational impact and cost effectiveness. Similar checklist-based tools are being developed for use with robot assisted partial nephrectomy (RAPN).

Checklist-based assessment can be used to support modular training pathways. They are an objective assessment of what processes have been performed in training and an evaluation of the skill with which they were enacted and can be applied to technical and non-technical skills. With a validated scoring system, assessments are standardised for use in a multitude of settings enabling objective comparison between trainees, training methods and institutions. Such information can guide future practice by distinguishing which skills surgeons need to practice more and by when they are proficient and ready to move to the next step in a modular training pathway.

65.7 Curricula and Fellowships

Several RAS curricula have been developed yet there exists significant variation in their implementation by national and international bodies owing to a lack of standardisation. Fundamentals of Robotic Surgery, Fundamental Skills of Robotic Surgery and Basic Skills Training Curriculum were identified in a review of robotic curricula in 2014 [2]. The only urology-specific curriculum in use at present is the ERUS Robotic Fellowship Curriculum though there exist many opportunities for fellowship and mini-fellowship programmes [6].

The American Association of Urology (AUA) recognised the lack of RAS curriculum and developed the Urologic Robotic Surgery Course [11]. This online, e-learning curriculum adopts a modular design incorporating "Fundamentals of Urologic Robotic Surgery", "Basic Procedures" and "Optional/Advanced Procedures" but does not progress to practical skills training.

The British Association of Urological Surgeons have published guidelines on training for their robotic surgery curriculum. The recommended curriculum entails a programme of e-learning modules, observation, simulation, mentorship/fellowship and non-technical skills team training before the final sign-off to indicate the completion of training. In time, as surgical trainees advance through this curriculum and it is validated, it will no doubt undergo revisions to ensure that it remains up to date, addressing training needs in the rapidly changing sphere of RAS.

65.8 Credentialing and Accreditation

Credentialing refers to the process of verifying the knowledge, skills and performance of clinicians "in a defined area of practice, at a level that provides confidence that the individual is fit to practice" [7]. Even though a trainee may successfully complete a validated curriculum programme or fellowship, prior to independent practice it is essential to ensure that trainee is proficient [1]. Currently there is no official credentialing in robot-assisted surgery and training in this area remains largely down to the enthusiasm and proactivity of individual trainees. BAUS have recommended a formal sign-off by mentors according to a specific quality standard however as yet these are not legally binding in medical practice. Included in recommendations is the maintenance of a logbook and videos of procedures undertaken which can be compared with evidence-based learning curves to ascertain the proficiency attained by trainee surgeons. Similar recommendations are required on a wider scale to incorporate international bodies and ensure competent incorporation of RAS in urology across the globe. It is important that safe

minimum-standards be established. These must be validated and measurable, either over time or at a one-off assessment for example on completing a given number of cases. There remain questions waiting to be answered regarding the most appropriate method of accrediting surgeons in robot-assisted surgery. Existing research is working towards establishing assessment of surgical competence through evidence-based practice and this must be applied in future.

Bibliography

1. Ahmed K, Jawad M, Dasgupta P, Darzi A, Athanasiou T, Khan MS. Assessment and maintenance of competence in urology. *Nat Rev Urol*. 2010;7(7):403–13. doi:10.1038/nrurol.2010.81.
2. Fisher RA, Dasgupta P, Mottrie A, et al. An over-view of robot assisted surgery curricula and the status of their validation. *Int J Surg*. 2015;13C:115–23. doi:10.1016/j.ijssu.2014.11.033.
3. Gold JP, Begg WB, Fullerton D, et al. Successful implementation of a novel internet hybrid surgery curriculum: the early phase outcome of thoracic surgery prerequisite curriculum e-learning project. *Ann Surg*. 2004;240(3):499.
4. Khan N, Abboudi H, Khan MS, Dasgupta P, Ahmed K. Measuring the surgical “learning curve”: methods, variables and competency. *BJU Int*. 2014;113(3):504–8. doi:10.1111/bju.12197.
5. Lovegrove C, Novara G, Mottrie A, et al. Structured and modular training pathway for Robot-assisted Radical Prostatectomy (RARP): validation of the RARP assessment score and learning curve assessment. *Eur Urol*. 2016;69(3):526–35. doi:10.1016/j.eururo.2015.10.048.
6. Lovegrove CE, Elhage O, Khan MS, et al. Training modalities in robot-assisted urologic surgery: a systematic review. *Eur Urol Focus*. 2016. doi:10.1016/j.euf.2016.01.006.
7. Report CSG. Postgraduate medical education and training board. 2010. Available at: http://www.gmc-uk.org/CSG_Report_April_2010.pdf_34123082.pdf.
8. Stolzenburg J-U, Schwaibold H, Bhanot SM, et al. Modular surgical training for endoscopic extraperitoneal radical prostatectomy. *BJU Int*. 2005;96(7):1022–7. doi:10.1111/j.1464-410X.2005.05803.x.
9. Volpe A, Ahmed K, Dasgupta P, et al. Pilot validation study of the European Association of Urology Robotic Training Curriculum. *Eur Urol*. 2014. doi:10.1016/j.eururo.2014.10.025.
10. Wright TP. Factors affecting the cost of airplanes. *J Aeronaut Sci*. 1936;3(4):122–8. doi:10.2514/8.155.
11. Urologic Robotic Surgery Course. Available at: <https://www.aaunet.org/education/modules/robotic-surgery/>. Accessed 2 Mar 2016.

Index

A

- Accreditation, robotic training, 709–710
- Adhesiolysis, 312, 333, 448
- AESOP. *See* Automated endoscopic system for optimal positioning (AESOP)
- American Association of Urology (AUA), 709
- Anatrophic nephrolithotomy. *See* Laparoscopic anatrophic nephrolithotomy (LAN)
- Animal lab training, laparoscopic urology surgery
 - anastomosis, 701
 - balloon inflation, 701
 - clipping, 699
 - dissection, renal artery and vein, 699
 - excision, 699
 - suture, 700
- Anterior compartment prolapse, pelvic floor repair
 - Deaver retractor position, 652
 - dissection, 653
 - fornix angle, 652
 - incision, 653
 - mesh placement, 654–656
 - midurethral suspension, 657
 - patient position, 652
 - ports position, 652
 - post procedure view, 657
 - step I, 651
 - step II, 651
 - step III, 651
 - step IV, 651
 - step V, 651
 - step VI, 651
 - suturing, 653–654
 - urethrovesical suspension, 657
 - uterine prolapse with cystocele, 652
- Appendicovesicostomy, 478–479
- Atraumatic graspers, 42
- Augmentation, 438–439, 479–481
 - bladder, 388–389, 444
 - cystoplasty, 467
 - cystoplasty, laparoscopic undiversion with, 408–412
 - indications and evaluation, 407
 - methods, 407
- Autoaugmentation, 387
- Automated endoscopic system for optimal positioning (AESOP), 5–6
- Automatons, 3
 - humanoid, 3, 4

B

- Babcock grasper, 42
- Balloon dilator, inflated, 41
- Balloon tip trocar, 35
- Bipolar cautery, 297
- Bipolar coagulation, 41
- Bipolar forceps, 45
- Bladder
 - augmentation, 444
 - bite
 - initial bite through, 269
 - for psoas hitch, 268
 - diverticulum, 318
 - flap, 282
 - initial view of, 393
 - injuries, laparoscopic repair of, 312–314
 - contraindication, 311
 - indications, 311
 - surgical technique, 311
 - laparoscopic autoaugmentation of, 388–389
 - indication, 387
 - preliminary evaluation, 387
 - surgical technique, 387
 - mass, MRI image of, 361
 - mobilisation, 312
 - mucosa, 282, 462, 478
 - mucosal incision, 333, 477
 - rent, 351
 - ruptures, isolated, 311
- Bladder diverticulectomy, laparoscopic, 318–322
 - diverticulum, 317
 - indication, 317
 - postoperative followup, 317
 - surgical technique, 317
- Bladeless trocar, 40
- Blunt dissection, 293
- Blunt tip trocar, 40
- Boari flap, 273, 277
 - reconstruction, bladder, 281
 - reimplantation, 248–249
 - robot assisted, ureteric reimplantation, 283–286
 - benefits, 282
 - indications, 281
 - procedure, 281–282
 - ureteric reimplantation
 - laparoscopic, 273–279
- Bosniak renal cyst
 - type I and type II, 141
 - type III and IV (complex cyst), 141–142
- Bowel
 - adhesions, 408–409
 - anastomosis, 475
 - detubularisation of, 403
 - isolation, 299
 - segment, 305, 395, 474
 - segment isolation, 488–489

Bricker method, 483
 British Association of Urological Surgeons, 709
 Buccal mucosal graft ureteroplasty
 transperitoneal, 196
 for ureteric stricture, 209–212

C

Cadiere forceps, 44
 Calculi, 287, 288
 secondary
 PUJ obstruction with, 93
 UPJ obstruction with, 53
 Cefazolin, 469
 Claw graspers, 42
 Clean self intermittent catheterization (CSIC), 453
 Clip applicators, 46
 Coagulation devices, 45
 Cobra grasper, 44
 Colonic rent closure, 451
 Colovesical fistula, laparoscopic repair of, 448–452
 surgical technique, 447
 Conduit, 407, 409, 456, 489
 Conventional laparoscopy, 297
 Conventional trocars, 35
 Covidien, 298
 Credentialing, robotic training, 709–710
 CSIC. *See* Clean self intermittent catheterization (CSIC)
 Curricula robotic training, 709
 Curved bipolar dissectors (Intuitive surgical®), 43
 Curved scissor, 42
 Cystectomy, 487
 partial (*see* Partial cystectomy)
 radical (*see* Radical cystectomy (RC))
 Cystogram, 303, 317, 344, 351, 407, 448, 460
 Cystometrogram, 416
 Cystometry, 422, 427
 Cystoplasty, 411, 412, 435
 Cystorrhaphy, 336–339
 Cystoscopy, 273, 317, 343, 352, 361, 383
 light, 327
 Cystotomy, 301, 333, 341, 354, 359, 362–366, 370, 375, 381–382,
 394, 403, 410, 420, 423, 429–431, 438, 462, 464, 476
 oblique, 423, 464
 transverse, 340–342, 402, 407, 410, 420, 435, 438
 vertical, 333, 353, 443

D

da-Vinci surgical system, 6, 8–10, 45
 DeBakey forceps, 44
 Deflux, 471
 Detrusor myotomy, 388, 389
 Detrusorotomy, 470
 Detrusorrhaphy, 265
 Detubularisation, 396, 410
 of bowel, 403
 Dismembered pyeloplasty, 52, 53
 reteroperitoneoscopic, 85–88
 transperitoneal, 55–58
 Dissectors, 42
 Distended bladder, 418, 448, 450
 Diverticular dissection, 319
 Diverticulectomy
 laparoscopic, 325
 robot assisted laparoscopic, 326–329

Diverticulocystoplasty
 laparoscopic, 436–439
 Diverticulum, 317, 318, 320, 325–329, 437–438
 dissection, 319
 Dolphin nose dissector, 42
 Double armed PDS suture, 269
 Dry laboratory exercises
 simulation, robotic training and validation, 708
 urology surgery training
 dissection exercise, 677, 679
 endotrainer, 679
 hand eye coordination, 677
 knotting techniques, 677, 680
 suturing techniques, 681–682
 ureterotomy, 683
 web camera mounted endotrainer-sideview, 679

E

Eco Sac (EMT Healthcare), 47
 Ectopic kidney, pyeloplasty in, 72–76
 Ectopic ureter, ureteric reimplantation in, 254–255
 E learning modules, robotic training, 705–706
 Electrocautery, 359, 360, 367
 EndoGIA stapler, 297–298, 391
 Endometriosis, 361–363
 Endopelvic fascia, 485, 486
 Endo Stitch (Covidien), 298
 ENSEAL® (Ethicon, Somerville, New Jersey), 41
 European Association of Urology (EAU) Robotic Urology Section
 (ERUS), 709
 Excretory urography, 343
 Extracorporeal bowel isolation, 403
 Extravesical reimplant (tailored), 240–245

F

Fellowships, robotic training, 709
 Fenestrated bipolar forceps (Intuitive surgical®), 43
 Fibrin-based haemostatic agents, 46
 Fistula
 colovesical, laparoscopic repair of, 448–452
 iatrogenic, 344
 urachal, 383–386
 vesicouterine, laparoscopic repair of, 351–356
 vesicovaginal
 laparoscopic repair of, 336–339
 robotic-assisted repair, 343–348
 Flap tubularisation, 278–279
 Fluorophores, 7

G

Gastrocystoplasty, laparoscopic, 441–446
 Gaur balloon, 34
 Gerota's fascia, 36, 53, 159, 168
 Global Evaluative Assessment of Robotic Skills (GEARS) score, 709
 Grasper. *See specific types of graspers*

H

Haemostatic agents, fibrin-based, 46
 Hands-on Surgical Training (HoST), 706
 HARMONIC SCALPEL®, 41
 Harmonic ultrasonic device®, 45
 Harvested bowel segment, 396

Hasson cannula, 17
 Hasson technique, 19
 Head-mounted display (HMD), 4–5
 Heilbronn technique, 562, 563
 Heminephrectomy, 125, 133
 lower moiety, 125–128
 upper moiety, 129–131
 Heminephroureterectomy, robot assisted laparoscopic upper pole
 followup, 134
 indications, 133
 outcomes, 134
 patient position, 135
 surgical technique, 133–139
 Hem-o-lok® clips, 46, 159
 HMD. *See* Head-mounted display (HMD)
 Hood electrode, 45
 Hook cautery (Intuitive surgical®), 43
 Hook scissor, 42
 Horse shoe kidney, UPJ obstruction in, 53, 68–71
 Humanoid robot, 3, 4
 Hutch diverticulum, 435
 Hysterectomy, 363

I

Iatrogenic fistula, 344
 Ileal conduit, 407
 laparoscopy assisted
 dissection, 495
 final external view, 497
 loop, 496, 497
 ports position, 494
 surgical technique, 493
 uretero ileal anastomosis, 497
 robot assisted laparoscopic
 anastomosis, 508–510
 bladder drop, 505
 dissection, 502, 503
 ports positions, 502
 staple lines, 505
 stapler, 507
 Ileal detubularisation, 479
 Ileal neobladder, laparoscopy assisted
 anastomosis, 532
 dissection, 528–530
 drain, 532
 method, 527
 ports position, 528
 reimplantation, 531
 suturing, 530
 Ileal stoma edges, 407
 Ileal ureter, laparoscopy assisted, 304–308
 surgical technique, 303
 Ileocystoplasty
 laparoscopic, 392–399
 indications, 391
 surgical technique, 391
 laparoscopy assisted, 402–405
 surgical technique, 401
 total laparoscopic, 391–399
 Ileovesical anastomosis, 298, 398, 404
 Iliac lymphadenectomy, 487–488
 Inferior vena cava (IVC), 196, 219
 Inflated balloon dilator, 41
 Interpolar renal mass, 174–176
 Intracavitary ultrasound scan, 368

Intracorporeal ileal conduit, laparoscopic radical cystectomy with, 483–491
 Intracorporeal ileal neobladder
 anastomosis, 522, 525
 clipped ureter, 518–521
 detubularisation, 523
 dissection, 515–516
 exteriorised stent, 526
 lymphadenectomy, 517
 ports position, 514
 reconstruction, 524
 reimplantation, 525
 surgical technique, 513–514
 tips and tricks, 514
 Intracorporeal ileal ureter, laparoscopic, 299–301
 indications, 297
 surgical techniques, 297–298
 tips and tricks, 298
 Intracorporeal neobladder reconstruction, robotic assisted
 management, drainage catheters, 537
 patient re-positioning, 536–537
 post-operative care, drainage catheters, 537
 pre-operative preparation, 535
 trocar placement, 535
 Intra reanal pelvis, 304

J

Jackson-Pratt drain, 344

K

Kidney
 ectopic, pyeloplasty in, 72–76
 functioning, ureterocystoplasty in, 415
 and hilar dissection, 185 (*see also* Robotic partial nephrectomy (RPN))
 horse shoe, UPJ obstruction in, 53, 68–71
 transplantation
 laparoscopic, 633 (*see also* Laparoscopic kidney transplantation)
 robot assisted (*see* Robot assisted renal transplantation)

L

Lahey bags, 46
 LAN. *See* Laparoscopic anastrophic nephrolithotomy (LAN)
 Laparoendoscopic single-site (LESS) reconstructive surgery
 Alexis retractor portion, 622
 articulating laparoscopic grasper and endoscope, 622
 cosmetic outcome, 625
 follow up, 621
 GelPOINT® device, 623
 hitch stitches, 624
 intraumbilical incision, 625
 patient position, 621
 port placement, 621
 preliminary evaluation, 619–620
 robotic technique, 620
 spatulation, 625
 standard technique, 620
 surgical technique, 620
 suturing, 625
 Laparoendoscopic single-site (LESS) surgery, 39, 41
 Laparoendoscopic Single Site Surgery Consortium for Assessment and Research (LESSCAR), 619

- Laparoscopic anastrophic nephrolithotomy (LAN)
 - indication, 159
 - preliminary evaluation, 159
 - surgical technique, 159–162
 - Laparoscopic kidney transplantation
 - anastomosis, 637
 - arteriotomy, 635
 - clamps, 637
 - contraindications, 629
 - dissection, 633
 - indications, 629
 - operative procedure, 629–630
 - outcome, 630
 - patient and surgeon position, 631
 - peritoneotomy, 632
 - Pfannensteil incision, 633
 - port position, 631
 - reimplantation, 638
 - renal graft, 633
 - skeletonisation, external iliac artery and vein, 632
 - venotomy, 634
 - venous anastomosis, 634–635
 - wound closure, 633
 - Laparoscopic partial nephrectomy (LPN), 165
 - interpol renal mass, 174–176
 - large upper pole/hilar tumour, 169–173
 - nephrometry scoring system, 166
 - patient positioning, 166–168
 - postoperative management, 169
 - preoperative imaging, 166
 - Laparoscopic radical prostatectomy (LRP)
 - anterior dissection and urethra division, 557–558
 - bladder neck approach, 554–555
 - contraindications, 551
 - drainage, 558
 - indications, 551
 - instruments requirement, 551–552
 - patient's skin preparation, 553
 - ports placement, 553
 - posterior dissection, 555
 - postero-lateral dissection, 556
 - post-operative course, 559
 - surgical anatomy, 549–550
 - surgical steps, 554
 - vesico-urethral anastomosis, 558
 - Laparoscopic undiversion with augmentation cystoplasty, 408–412
 - indications and evaluation, 407
 - methods, 407
 - Laparoscopy assisted ileocystoplasty with Mitrofanoff procedure (Yang Monti technique), 459–468
 - LapSac, 47
 - Large clip applier, 44
 - Learning curves analysis, robotic training, 708
 - LESS. *See* laparoendoscopic single-site (LESS) surgery
 - Long atraumatic graspers, 42
 - Long curved dissectors (Intuitive surgical®), 44
 - Long Johan graspers, 42
 - Long tip forceps, 44
 - Lower moiety heminephrectomy, 125–128
 - Lower moiety UPJ obstruction, 107
 - LPN. *See* Laparoscopic partial nephrectomy (LPN)
 - Lymph node dissection, 373
 - balloon inflation, 594
 - bladder distended, 597
 - capsulotomy, 597
 - dissection, 596
 - endopelvic fascia incision, 595
 - enucleation, 596
 - extraperitoneal space creation, 594
 - mucosa preserving technique, 599
 - ports position, 594
 - preprostatic fat, 595
 - specimen retrieval, 598
 - surgical technique, 599
 - ultrasonic shears, 595
 - Marsupialisation, renal cyst, 141–144
 - Maryland bipolar forceps (Intuitive surgical®), 43
 - Maryland dissector, 42
 - MEMS. *See* Microelectromechanical systems devices (MEMS)
 - Mesentery, 303
 - Mesoappendix, 455, 456
 - Mesosigmoid, 488
 - Micro bipolar forceps (Intuitive surgical®), 44
 - Microelectromechanical systems devices (MEMS), 8
 - Mimic dV-Trainer, 707
 - Mitrofanoff procedure
 - laparoscopic, 469
 - complications, 454
 - indication, 453
 - laparoscopy assisted ileocystoplasty with, 459–468
 - preparation, 453
 - procedure, 453–454
 - using appendix, 455–457
 - laparoscopy assisted ileocystoplasty with, 460–468
 - RALMA (*see* Robotic-assisted laparoscopic Mitrofanoff appendicovesicostomy (RALMA))
 - Modular training pathways, robotic training, 709
 - Monopolar curved scissors (Intuitive surgical®), 43
 - Mucosal anastomosis, 463
- N**
- Needle holder, 43
 - Nelaton catheter, 454
 - NeoSurgical's Neoclose Laparoscopic Access site closure device, 24
 - Nephrectomy, 35, 415
 - for complex renal cyst, 145–149
 - Nephrolithotomy, anastrophic
 - indication, 159
 - preliminary evaluation, 159
 - surgical technique, 159–162
 - Nephron-sparing surgery (NSS), 165
 - Nephrostogram, 442
 - Neurogenic bladder, 388, 402, 469
 - Nipple valve ureteric reimplantation, 226, 251–253
 - Non dismembered pyeloplasty, 52, 53
 - retroperitoneoscopic, 89–91
 - transperitoneal, 59–62
 - NSS. *See* Nephron-sparing surgery (NSS)
- O**
- Oblique tunnel, 470
 - O' Connor's technique, 332–335
 - Omental adhesions, 292, 361, 374, 384
 - Omental wrapping, 291
 - of anastomosis, 308
 - Omentum, 291, 294, 312, 313, 351, 404, 442, 445, 467
 - Open partial nephrectomy (OPN), 165
- M**
- Madigan prostatectomy, laparoscopic
 - adenoma, 595–596

Open pyeloplasty (OP), 95
 vs. RLP, 96–100
 OPN. *See* Open partial nephrectomy (OPN)
 Orchiopexy, laparoscopic, 614–615

P

Partial cystectomy
 laparoscopic
 endometriosis, 361–363
 for solitary TCC, 360
 in TCC, 364–366
 in urachal tumour, 367
 robotic, urachal tumours, 373–376
 Partial nephrectomy (PN), 165
 laparoscopic, 165–176 (*see also* Laparoscopic partial nephrectomy (LPN))
 retroperitoneoscopic, 177–183
 robotic, 165, 185–191 (*see also* Robotic partial nephrectomy (RPN))
 Patent urachus, laparoscopic excision of
 surgical technique, 379
 with urachal fistula, 383–386
 PCNL. *See* Percutaneous nephrolithotomy (PCNL)
 Pelvic floor repair. anterior compartment prolapse
 Deaver retractor position, 652
 dissection, 653
 fornix angle, 652
 incision, 653
 mesh placement, 654–656
 midurethral suspension, 657
 patient position, 652
 ports position, 652
 post procedure view, 657
 step I, 651
 step II, 651
 step III, 651
 step IV, 651
 step V, 651
 step VI, 651
 suturing, 653–654
 urethrovesical suspension, 657
 uterine prolapse with cystocele, 652
 Pelvic organ prolapse (POP). *See* Sacrocolpopexy
 Pelvi ureteric anastomosis, 56, 58
 Pelvi ureteric junction, 56, 59
 Penelope robot, 10
 Percutaneous nephrolithotomy (PCNL), 159
 Perinephric fat, 307
 Peritoneotomy, 262, 483
 Peritoneum, 260, 281, 318, 388, 423
 Perivesical fat, 260, 263, 269
 Pfannenstiel incision, 483
 PN. *See* Partial nephrectomy (PN)
 Pneumoperitoneum, 14, 18, 19, 260
 Pneumoretroperitoneum, 287
 Port closure needle, 24
 Postoperative urinary drainage, 470
 Pott's scissors, 44
 Preliminary cystogram, 317
 Preoperative ureteric stenting, 291
 PROBOT. *See* Prostate robot (PROBOT)
 Programmable Universal Manipulation Arm (PUMA) 200, 4
 ProGrasp TM forceps, 44
 Prostate apical dissection, 487
 Prostate robot (PROBOT), 4, 5
 Prostatic lateral pedicles, 486

Proximal ureter, 117
 Psoas hitch
 bladder bite for, 268
 in place, 269
 ureteric reimplantation, 226
 for ureterovaginal fistula, 246–247
 urteric reimplantation
 robotic, 266
 Psoas muscle, 36
 PUMA 200. *See* Programmable Universal Manipulation Arm (PUMA) 200
 Pyeloileal anastomosis, 298, 301, 306
 Pyelolithotomy
 retroperitoneoscopic, 151, 156–157
 transperitoneal, 151–155
 Pyeloplasty
 laparoscopic, 54
 complications, 52
 contraindication, 51
 culp flap lap, 80–84
 dismembered, 52, 53, 55–58, 85–88
 in ectopic kidney, 72–76
 indications, 51
 non dismembered, 52, 53, 59–62, 89–91
 patient preparation, 51
 planning of approach, 51
 PUJ obstruction with secondary calculus, 93
 redo lap., 77–79
 redopyeloplasty, 53
 retroperitoneoscopic approach, 52–53
 stent insertion, difficulty in, 92
 transmesocolic, 52, 63–67
 transperitoneal approach, 52
 in model, laparoscopic surgery training
 emphasis, 688
 knotting method, 688
 module, 684
 spatulation, 687
 stenting technique, 684
 sutures, 684–686
 robotic (*see* Robotic laparoscopic pyeloplasty (RLP))
 robotic vs. conventional laparoscopic vs. open, 96–100
 transperitoneal dismembered, 55–58
 transperitoneal non dismembered, 59–62
 Pyelotomy, 300–301
 linear, 306
 Pyelo ureteric anastomosis, 66

R

Radical cystectomy (RC)
 anastomosis, 522, 525
 clipped ureter, 518–521
 detubularisation, 523
 dissection, 515–516
 exteriorised stent, 526
 with intracorporeal ileal neobladder, laparoscopic (*see* Intracorporeal ileal neobladder)
 with intracorporeal ileal conduit, laparoscopic, 483–491
 lymphadenectomy, 517
 ports position, 514
 reconstruction, 524
 reimplantation, 525
 robot assisted (*see* Robot assisted radical cystectomy (RARC))
 surgical technique, 513–514
 tips and tricks, 514
 Radical nephrectomy (RN), 165

- Radical prostatectomy
 - laparoscopic (*see* Laparoscopic radical prostatectomy (LRP))
 - robotic assisted
 - anastomosis, 590
 - Denonvilliers' fascia, 583, 588
 - dissection, 582–593
 - incision, 582, 586
 - intra-abdominal access and trocar placement, 582–590
 - ligation, 582, 586
 - neurovascular bundle (NVB) preservation, 583–584
 - patient positioning, 585
 - port position, 585
 - preoperative preparation, 581
 - seminal vesicle (SV) dissection, 583
 - transperitoneal ascending laparoscopic (*see* Transperitoneal ascending laparoscopic radical prostatectomy)
- RALMA. *See* Robotic-assisted laparoscopic Mitrofanoff appendicovesicostomy (RALMA)
- RALS. *See* Robot assisted laparoscopic surgery (RALS)
- RALUR. *See* Robotic-assisted laparoscopic ureteral reimplantation (RALUR)
- RCC. *See* Renal cell carcinoma (RCC)
- Reconstructive urology
 - access, 39–41
 - clip appliers and clamps, 46
 - dissectors, 42
 - fibrin-based haemostatic agents, 46–47
 - graspers, 42
 - hemostasis, 41, 43
 - manipulative instruments, 41–46
 - scissors, 42
 - suturing and knot tying instrument, 43
- Redopyeloplasty, 53, 77–79
- Redundant urteric margin, 271
- Reimplantation
 - transvesical, in VUR, 236–239
 - ureteric (*see* Ureteric reimplantation)
- Renal cell carcinoma (RCC), 165
- Renal cyst
 - Bosniak Type I and II, 141
 - Bosniak Type III and IV, 141–142
 - marsupialisation of, 141–144
 - partial nephrectomy for, 145–149
- Renal mass, interpolar, 174–176
- Renal pelvis, 297
- Renal transplantation. *See* Kidney, transplantation
- Renorrhaphy technique, 168
- Reteropitoneoscopic dismembered pyeloplasty, 85–88
- Reteropitoneoscopic non dismembered pyeloplasty, 89–91
- Retrocaval ureter
 - retroperitoneal ureteroureterostomy for, 196, 202–206
 - robot assisted ureteroureterostomy for, 219–222
 - transperitoneal ureteroureterostomy for, 196, 198–201
- Retrograde cystourethrography, 343
- Retrograde pyelogram (RGP), 51, 196, 273, 281
- Retroperitoneal dissection, 266, 292
- Retroperitoneal space (RPS), 31
- Retroperitoneal ureteroureterostomy, 196
 - for retrocaval ureter, 202–206
- Retroperitoneoscopic partial nephrectomy, 177–183
- Retroperitoneoscopic pyelolithotomy, 151, 156–157
- Retroperitoneoscopic ureterolithotomy, 287–289
 - indication, 287
- Retroperitoneoscopy, 33
 - contraindication, 31
 - indications, 31
 - port placement, 32–36
 - position of patient, 31
 - techniques, 31
- Retroperitoneum, 31, 36
- Retroverted uterus, 353
- Retzius space, 260, 485
 - being developed, 263
 - fully developed, 268
- RGP. *See* Retrograde pyelogram (RGP)
- Right angle dissector, 42
- Right uretero enteric anastomosis, 491
- Rigid/Flexible cystoscopy, 260
- Rip-stop nylon, 46–47
- RLP. *See* Robotic laparoscopic pyeloplasty (RLP)
- RN. *See* Radical nephrectomy (RN)
- ROBODOC robot, 5
- Robot assisted laparoscopic surgery (RALS), 259
- Robot assisted radical cystectomy (RARC)
 - ileal conduit diversion, 500
 - indications, 499
 - procedure, 499–500
- Robot assisted renal transplantation
 - advantages, 640
 - anastomosis, 644
 - arteriotomy, 644
 - dissection, 641–642
 - gelpoint in situ, 641
 - indications, 639
 - kidney retroperitonealised, 646
 - procedure, 639–640
 - stent insertion, 646
 - suturing, 643, 647
 - ureter spatulated, 646
- Robotic-assisted laparoscopic Mitrofanoff appendicovesicostomy (RALMA), 472–482
 - follow-up, 471
 - indications, 469
 - patient selection, 469
 - postoperative care, 471
 - surgical technique, 469–470
- Robotic-assisted laparoscopic ureteral reimplantation (RALUR), 260
- Robotic assisted ureteroneocystostomy (RUNC), 260
- Robotic laparoscopic pyeloplasty (RLP), 95, 100–105
 - indications, 95
 - vs. LP, 96–100
 - vs. OP, 96–100
 - patient positioning, 96
 - port placement, 96
 - surgical tips, 96
- Robotic partial nephrectomy (RPN), 165, 186–191
 - excision of tumor and renorrhaphy, 185
 - exiting the abdomen, 186
 - kidney and hilar dissection, 185
 - peritumor fat removal and sonography, 185
 - reflection of the colon, 185
 - trocar placement, 185
- Robotic Surgical Simulator (RoSS), 706
- Robotic training and validation
 - accreditation, 709–710
 - credentialing, 709–710
 - curricula and fellowships, 709
 - dry lab simulation, 708
 - E learning modules, 705–706
 - learning curves role, 708
 - modular training pathways, 709
 - simulation training, 705–706
 - virtual reality simulation, 706–707
 - wet lab simulation, 708

RobotiX Mentor, 706
 Robot position, between the thighs, 261
 Robot, surgical
 arms, 4
 automation in, 8–9
 challenges and future trends in
 advancement in vision, 8
 haptics, 7
 image integrated surgery, 8
 independent/autonomous robotic surgery, 8–9
 latency in signal transmission, 11
 miniaturization, 8
 mobility improvement, 8
 operating room integration, 10
 signal security, 11
 surgical team robotic augmentees, 10
 visual feedback, 7
 defined, 4
 evolution of, 3–5
 history, 3–4
 Round tip scissors, 44
 RUNC. *See* Robotic assisted ureteroneocystostomy (RUNC)

S

Sacrocolpopexy
 blood loss, 669
 complications, 670
 dissection, 671
 identification sacral promontory, 670
 instruments, 668
 laparoscopic, vault prolapse
 bladder mobilisation, 661
 bowel adhesions, release of, 661
 endopelvic fascia, 661
 level I defect, 659
 mesh placement, 662
 pelvic anatomy, initial view of, 660
 peritoneal closure, 664
 peritoneal incision, 662
 ports position, 660
 sacral promontory, 662
 suturing, 663
 technique, 659
 patient positioning, 668
 port placement, 668, 670
 preoperative considerations, 667
 surgical steps
 mesh fixation, 668–669, 672
 peritoneal flap/tunnel creation, 668
 retro-peritonealisation of mesh, 669
 sacral promontory and suture pre-placement, 668
 vaginal vault dissection, 668
 ‘Y’ mesh, 672–673
 SARP. *See* Surgeon-assistant robot for prostatectomy (SARP)
 Satinsky clamp, 167
 Scissors, 42. *See also specific types of scissor*
 Seminal vesicle cyst, laparoscopic excision of
 dissection, 602, 604
 excision, 604
 image of, 602
 indications, 601
 patient preparation, 601
 peritoneotomy, 602
 ports position, 602
 Shock wave lithotripsy (SWL), 159
 Short Johan graspers, 42

Side to side ureterocystoplasty, 428–433
 in-situ, 422–427
 Sigmoid colon, 449, 484, 488
 Sigmoid, medialisation of, 266
 Simbionix RobotiX Mentor, 707
 SIMPLE (Simulated Inanimate Model for Physical Learning Experience), 708
 SimSurgery Educational Platform (SEP) Robot™, 706
 Simulation training, robotic training, 705–706
 Single-site reconstructive surgery. *See* Laparoendoscopic single-site (LESS) reconstructive surgery
 Single stage laparoscopic orchiopexy, undescended testis
 algorithm for management, 610
 dissection, 611
 port position, 612
 ports position, 610
 stage 1 fowlers, 613
 surgical technique, 609
 Sliding renorrhaphy technique, 168
 Small clip applier (Intuitive surgical®), 44
 Small curved scissor, 42
 Small renal masses (SRM), 165
 Sonography, 185
 Spatula cautery (Intuitive surgical®), 43
 Spatula electrode, 45
 Spigots, 471
 Spiral Monti, 461
 catheterization channels, 470
 Stapled bowel anastomosis, 489
 Staplers, 443
 Stomal incontinence, 471
 Stratafix, 298
 Stump, 456
 Surgeon-assistant robot for prostatectomy (SARP), 4
 Surgeon's Operating Force-feedback Interface Eindhoven (SOFIE)
 robot, 7
 SWL. *See* Shock wave lithotripsy (SWL)
 Symptomatic urachal cyst, 379

T

Telesurgery, robotic, 4–5
 Testis
 intracanalicular, laparoscopic orchiopexy, 614–615
 undescended, single stage laparoscopic orchiopexy
 algorithm for management, 610
 dissection, 611
 port position, 612
 ports position, 610
 stage 1 fowlers, 613
 surgical technique, 609
 Transmesocolic pyeloplasty, 52, 63–67
 Transperitoneal ascending laparoscopic radical prostatectomy
 apical dissection, 566
 bladder neck dissection, 569
 bladder neck preservation, 577
 continence data, 574
 continence, return, 578
 entrapment of specimen, 570
 limitations, 579
 long urethral stump, 577
 measurements, 573
 nerve-sparing surgery, 578
 new Heilbronn technique, 563
 non-surgical factors, 578
 old Heilbronn technique, 562
 oncologic data, 575–576

Transperitoneal ascending laparoscopic radical prostatectomy (*cont.*)

- patients position, 562
 - periprostatic fascial anatomy, 564
 - posterior reconstruction, 563, 577–578
 - prostatic pedicles dissection, 569
 - puboprostatic collar and levator fascia, 567
 - pube-prostatic collar and levator fascia preservation, 578
 - puboprostatic ligaments preservation, 577
 - pudendal nerve, course and branches, 565
 - rectal balloon usage, 566
 - retrograde extraperitoneal technique, 569, 570
 - seminal vesicles dissection, 569
 - statistics, 573
 - urethra and posterior dissection, 568
 - urethral sphincter apparatus and bladder neck, 565
 - urethro-vesical anastomosis, 571–572
 - urinary continence mechanism, 566
 - urine loss ratio, 573
 - vesico-urethral anastomosis, 578
- Transperitoneal buccal mucosal graft ureteroplasty, 196
- Transperitoneal laparoscopic and robotic approach, 13
- contraindication, 14
 - exiting the abdomen, 23–24
 - indication, 13
 - pneumoperitoneum, technique of creation of, 18–19
 - preparation for surgery, 14
 - robotic surgery, 25–30
 - safe trocar insertion technique, 14–19
 - technological advancements, 20–22
- Transpyloric plane (TPP), 166
- Transureteroureterostomy, 433
- Transvesical reimplantation, VUR, 236–239
- Trans vesicoscopic cohen reimplantation
- ureteroceles, 227–232
- Trauma-pod (TP) project, 6
- Trocar, 411. *See also specific types of trocar*
- with locking device, 40
 - with shielded blade, 40
- SPC, 465

U

- Ultracision, 359, 360, 367
- Umbilical sinus, 383
- Undescended testis, laparoscopic surgery
- algorithm for management, 610
 - dissection, 611
 - port position, 612
 - ports position, 610
 - stage 1 fowlers, 613
 - surgical technique, 609
- Unimate PUMA 200, 4
- Upper moiety heminephrectomy, 129–131
- Urachal cyst, 381
- Urachal fistula, excision of patent urachus with, 383–386
- Urachal tumour, 374
- partial cystectomy in, 367
 - robotic partial cystectomy for, 373–376
- Ureter, 260, 266–269, 277, 293, 294, 299, 305, 318, 327, 415, 418–419, 428–429, 437, 443–444, 484
- dissection, 262, 293
 - divided proximal to obstruction, 262
 - ligated close to bladder, 276
 - looped, 262
 - second needle passed through, 269
 - seen lateral to bladder, 275
 - spatulated, 263
 - substitution of, 297
- Ureteric anastomosis
- pelvi, 56, 58
 - pyelo, 66
- Ureteric reimplantation, 256
- Boari flap reimplantation, 248–249
 - in ectopic ureter, 254–255
 - extravesical reimplant (tailored), 240–245
 - indications, 225
 - nipple valve reimplantation, 226, 251–253
 - psoas hitch, 226, 246–247
- robotic
- indications, 259
 - outcomes, 260–261
 - RALS, 259
 - technique, 259–260
- surgical techniques, 225–226
- transperitoneal approach, 226
- transvesical laparoscopic surgery problems, 233–235
- transvesical reimplantation in VUR, 236–239
- trans vesicoscopic cohen reimplantation, ureteroceles, 227–232
- Ureteric stricture
- buccal mucosal graft ureteroplasty for, 209–212
 - ureteroureterostomy in, 196, 207–208
- Ureterocalicostomy, 117–123
- Ureterocystoplasty, 421, 427
- in functioning kidney, 415
 - laparoscopic, 416–421
 - indication, 415
 - side to side in-situ ureterocystoplasty, 422–427
 - side to side ureterocystoplasty, 428–433
 - surgical technique, 415
 - ureterocystoplasty in functioning kidney, 415
- Ureteroenteric anastomosis, 407
- Ureterogastric anastomosis, 444
- Ureterolysis, 291
- laparoscopic, 292–294
 - indication, 291
 - surgical technique, 291
- Ureteropelvic junction (UPJ) obstruction, 95
- CT image, 55, 72
 - in horse shoe kidney, 53, 68–71
 - with secondary calculi, 53
 - ureteropyelostomy, 107
- Ureteroplasty
- for stricture ureter, 209–212
 - transperitoneal buccal mucosal graft, 196
- Ureteropyelostomy
- for complete duplex system, 107–115
 - for incomplete duplication, 107
- Ureterotomy, 288, 289, 424, 426, 430
- longitudinal, 430
- Ureteroureterostomy, 197
- evaluation, 195
 - indications for surgery, 195
 - for retrocaval ureter, 219–222
 - retroperitoneal, 196, 202–206
 - robot assisted, for retrocaval ureter, 219–222
 - trans, 197, 213–217
 - transperitoneal, 196, 198–201
 - for retrocaval ureter, 196, 198–201
 - in ureteric stricture, 196, 207–208
- Ureterovaginal fistula, psoas hitch ureteric reimplantation, 246–247
- Ureterovesical anastomosis, 420, 425
- Urethral anastomosis (chicken skin), laparoscopic urology surgery
- training
 - chicken gullet model, 695
 - model for, 689–691
 - porcine model, 692–694

Ureterocele, trans vesicoscopic cohen reimplantation, 227–232
 Urinary undiversion, 407
 UROBOT, 4
 Urology surgery training
 advanced animal lab training, 677
 animal lab training
 anastomosis, 701
 balloon inflation, 701
 clipping, 699
 dissection, renal artery and vein, 699
 excision, 699
 suture, 700
 animal module exercise like, 677
 comments on, 678
 dry laboratory exercises
 dissection, 677, 679
 endotrainer, 679
 hand eye coordination, 677
 knotting and suturing techniques, 677, 680–683
 web camera mounted endotrainer-sideview, 679
 IVC model, 696
 laparoscopic training, 677
 live animal lab training, 677
 live demonstration in human, 702
 partial nephrectomy model, 697–698
 pyeloplasty model
 emphasis, 688
 knotting method, 688
 module, 684
 spatulation, 687
 stenting technique, 684
 sutures, 684–686
 urethral anastomosis (chicken skin)
 chicken gullet model, 695
 model for, 689–691
 porcine model, 692–694

V

Vector X™ Closure, 24
 Veress needle technique, 14, 15, 18

Vertical detrusor myotomy, 389
 Vesicoappendicular anastomosis, 453
 Vesico ileal anastomosis, 301, 307
 Vesicotomy, 269
 for reimplantation, 263
 Vesicoureteric reflux (VUR), transvesical reimplantation in, 236–239
 Vesicovaginal fistula (VVF), 332
 laparoscopic repair of, 351–356
 cystorrhaphy, 336–339
 laparoscopic VVF repair, 332–335
 surgical technique, 331–332
 transverse cystotomy approach, 340–342
 tube drain, 332
 repair, 343
 robotic-assisted repair, 343–348
 small supra-trigonal, 347
 supra-trigonal, 332, 345
 Vessel sealer (Intuitive surgical®), 43
 Virtual reality (VR) simulation, robotic training, 706–707
 V-Lock, 298
 VVF. *See* Vesicovaginal fistula (VVF)

W

Warm ischaemia time (WIT), 166
 Wave graspers, 42
 Weck EFX™ Endo Fascial Closure System, 24
 Wet lab simulation, robotic training, 708

Y

Yang Monti technique, 459–468

Z

ZEUS robotic surgical system (ZRSS), 5–7