

Autopsy Report

for

Michael Jackson

STATE OF CALIFORNIA
CERTIFICATION OF VITAL RECORD

COUNTY OF LOS ANGELES

DEPARTMENT OF HEALTH SERVICES

3052009085414

CERTIFICATE OF DEATH

CITY OF LOS ANGELES
USE BLACK INK ONLY. NO ERASURES. ACCEPTANCE OF SIGNATURE
DATE OF DEATH

SOCIAL REGISTRATION NUMBER

1. NAME OF DECEDENT - FIRST (Given)		2. MIDDLE		3. LAST (Family)	
MICHAEL		JOSEPH		JACKSON	
4. DATE OF BIRTH (month/day/year)					
08/29/1958					
5. AGE (in years)					
50					
6. SEX					
M					
7. DATE OF DEATH (month/day/year)					
06/25/2009					
8. HOURS (24 hours)					
1428					
9. BIRTH STATE/COUNTRY					
IN					
10. MARRITAL STATUS (at Time of Death)					
DIVORCED					
11. OCCUPATION - (Type of work for most of life. Do NOT USE RETIRED)					
MUSICIAN					
12. KIND OF BUSINESS OR INDUSTRY (e.g., grocery store, meat construction, employment agency, etc.)					
ENTERTAINMENT					
13. YEARS IN OCCUPATION					
45					

14. DECEDENT'S RESIDENCE (Street and number or PO box)					
[REDACTED]					
15. CITY					
ENCINO					
16. COUNTY/RESIDENCE					
LOS ANGELES					
17. ZIP CODE					
[REDACTED]					
18. YEARS IN COUNTY					
35					
19. STATE/COUNTRY					
CA					

20. DECEASED'S RESIDENCE (Street and number or PO box)					
[REDACTED]					

21. NAME OF FATHER - FIRST					
JOSEPH					
22. MIDDLE					
WALTER					
23. LAST					
JACKSON					
24. BIRTH STATE					
AR					
25. NAME OF MOTHER - FIRST					
KATHERINE					
26. MIDDLE					
ESTHER					
27. LAST					
SCRUSE					
28. BIRTH STATE					
AL					

29. DATE OF DEATH					
07/07/2009					
30. PLACE OF FINAL DISPOSITION					
FOREST LAWN MEMORIAL PARK 6300 FOREST LAWN DRIVE, LOS ANGELES, CA 90068					
31. TYPE OF DISPOSITION					
TEMP					
32. NAME OF FUNERAL ESTABLISHMENT					
FOREST LAWN MEMR PRKS & MTYS					
33. LICENSE NUMBER					
FD 904					
34. DATE (month/day/year)					
07/07/2009					

35. PLACE OF DEATH					
RONALD REAGAN/UCLA MEDICAL CENTER					
36. COUNTY					
LOS ANGELES					
37. CITY					
LOS ANGELES					

38. CAUSE OF DEATH					
INVESTIGATIVE CAUSE IN DEFERRED					
39. ICD-10 CODE					
[REDACTED]					
40. ICD-9 CODE					
[REDACTED]					
41. SEARCH REPORTED TO CORONER					
[X] YES [] NO					
42. SEARCH NUMBER					
2009-04415					
43. AUTOPSY PERFORMED					
[X] YES [] NO					
44. AUTOPSY REPORT COMPLETED					
[X] YES [] NO					
45. ICD-10 CODE					
[REDACTED]					
46. ICD-9 CODE					
[REDACTED]					

47. OTHER SIGNIFICANT CONDITIONS CONTRIBUTING TO DEATH (Do NOT list details such as the underlying cause given in 38)					
[REDACTED]					
48. WERE OPERATIONS PERFORMED FOR ANY CONDITION IN ITEM 47? (Do NOT list if not applicable and date.)					
[] YES [] NO [] UNK					

49. SIGNATURE OF PHYSICIAN WHO KNOWS DEATH OCCURRED AT THE HOUR, DATE, AND PLACE STATED FROM THE CAUSE STATED					
[REDACTED]					
50. SIGNATURE OF PHYSICIAN WHO ISSUED THE CERTIFICATE					
[REDACTED]					
51. TYPE, ATTENDING PHYSICIAN'S NAME, MAILING ADDRESS, ZIP CODE					
[REDACTED]					

52. LOCATION THAT DEATH OCCURRED AT THE HOUR, DATE, AND PLACE STATED FROM THE CAUSE STATED					
53. NUMBER OF DEATHS					
[] Natural [] Accidental [] Suicide [] Pending Investigation [] Could not be determined					
54. PLACE OF INJURY (e.g., home, construction site, vehicle, etc.)					
55. DECEDENT FROM INJURY (e.g., gunshot wound, stab wound, etc.)					
56. LOCATION OF INJURY (Street and number, or location, and city, and ZIP)					
57. DATE (month/day/year)					
07/07/2009					
58. TYPE NAME, TITLE OF CORONER/DEPUTY CORONER					
CHERYL MACWILLIE, DEPUTY CORONER					

59. STATE REGISTRAR					
[REDACTED]					
60. DATE					
07/07/2009					
61. TYPE NAME, TITLE OF CORONER/DEPUTY CORONER					
CHERYL MACWILLIE, DEPUTY CORONER					
62. STATE REGISTRAR					
[REDACTED]					
63. DATE					
07/07/2009					
64. TYPE NAME, TITLE OF CORONER/DEPUTY CORONER					
CHERYL MACWILLIE, DEPUTY CORONER					

65. STATE REGISTRAR					
[REDACTED]					
66. DATE					
07/07/2009					
67. TYPE NAME, TITLE OF CORONER/DEPUTY CORONER					
CHERYL MACWILLIE, DEPUTY CORONER					

68. STATE REGISTRAR					
[REDACTED]					
69. DATE					
07/07/2009					
70. TYPE NAME, TITLE OF CORONER/DEPUTY CORONER					
CHERYL MACWILLIE, DEPUTY CORONER					

71. STATE REGISTRAR					
[REDACTED]					
72. DATE					
07/07/2009					
73. TYPE NAME, TITLE OF CORONER/DEPUTY CORONER					
CHERYL MACWILLIE, DEPUTY CORONER					

74. STATE REGISTRAR					
[REDACTED]					
75. DATE					
07/07/2009					
76. TYPE NAME, TITLE OF CORONER/DEPUTY CORONER					
CHERYL MACWILLIE, DEPUTY CORONER					

This is a true certified copy of the record filed in the County of Los Angeles Department of Health Services if it bears the Registrar's signature in purple ink.

Jana Marie Fielding MD
VD

DATE ISSUED

SEP - 1 2009

Director of Health Services and Registrar

This copy not valid unless prepared on engraved border displaying seal and signature of Registrar.

http://www.autopsyfiles.org



STATE OF CALIFORNIA
CERTIFICATION OF VITAL RECORDCOUNTY OF LOS ANGELES
DEPARTMENT OF HEALTH SERVICES

3052009085414

STATE FILE NUMBER

PHYSICIAN/CORONER'S AMENDMENT

NO ERASURES, WHITEOUTS, PHOTOCOPIES,
OR ALTERATIONS

3200919027107

LOCAL REGISTRATION NUMBER

1.1

 BIRTH DEATH FETAL DEATH

TYPE OR PRINT CLEARLY IN BLACK INK ONLY - THIS AMENDMENT BECOMES AN ACTUAL PART OF THE OFFICIAL RECORD

PART I INFORMATION TO LOCATE RECORD

INFORMATION AS IT APPEARS ON ORIGINAL RECORD	1A NAME - FIRST MICHAEL	1B MIDDLE JOSEPH	1C LAST JACKSON	2 SEX M
	3 DATE OF EVENT - MM/DD/CCYY 06/25/2009	4 CITY OF EVENT LOS ANGELES	5 COUNTY OF EVENT LOS ANGELES	

PART II STATEMENT OF CORRECTIONS

6 CERTIFICATE ITEM NUMBER	7 INFORMATION AS IT APPEARS ON ORIGINAL RECORD	8 INFORMATION AS IT SHOULD APPEAR
107A	DEFERRED	ACUTE PROPOFOL INTOXICATION
107AT	-	UNKNOWN
112	-	BENZODIAZEPINE EFFECT
119	-	HOMICIDE
120	-	NO
121	-	06/25/2009
122	-	UNK
123	-	RESIDENCE
124	-	INTRAVENOUS INJECTION BY ANOTHER
125	-	100 NORTH CAROLWOOD DRIVE, LOS ANGELES, CA 90077

2 OF 2

INFORMATIONAL DOCUMENT
NOT A VALID DOCUMENT TO ESTABLISH IDENTITY

I HEREBY DECLARE UNDER PENALTY OF PERJURY THAT THE ABOVE INFORMATION IS TRUE AND CORRECT TO THE BEST OF MY KNOWLEDGE.

DECLARATION OF CERTIFYING PHYSICIAN OR CORONER	9 SIGNATURE OF CERTIFYING PHYSICIAN OR CORONER	10 DATE SIGNED - MM/DD/CCYY 08/31/2009	11 TYPED OR PRINTED NAME AND TITLE/DEGREE OF CERTIFIER DME	
	12 ADDRESS - STREET AND NUMBER	13 CITY LOS ANGELES	14 STATE CA	15 ZIP CODE
STATE/LOCAL REGISTRAR USE ONLY	16 OFFICE OF VITAL RECORDS OR LOCAL REGISTRAR		17 DATE ACCEPTED FOR REGISTRATION - MM/DD/CCYY 08/31/2009	



109007159

This is a true certified copy of the record filed in the County of Los Angeles Department of Health Services if it bears the Registrar's signature in purple ink.

Jonathan E. Fielding MD
VB

Director of Health Services and Registrar

DATE ISSUED
SEP - 1 2009

This copy not valid unless prepared on engraved border displaying seal and signature of Registrar.

<http://www.autopsyfiles.org>

COUNTY OF LOS ANGELES

CASE REPORT

DEPARTMENT OF CORONER

1

APPARENT MODE **ACCIDENT/ NATURAL**

CASE NO
2009-04415

SPECIAL CIRCUMSTANCES
Celebrity, Media Interest

CRYPT
S.C.

LAST FIRST MIDDLE

AKA

#

JACKSON, MICHAEL JOSEPH

ADDRESS
100 NORTH CAROLWOOD DRIVE

CITY
LOS ANGELES

STATE ZIP
CA 90077

SEX	RACE APPEARS	DOB	AGE	HGT	WGT	EYES	HAIR	TEETH	FACIAL HAIR	ID VIEW	CONDITION
MALE	BLACK	8/29/1958	50	69 in	136 lbs	BROWN	BROWN	ALL NATURAL TEETH	UNSHAVEN	Yes	FAIR

MARK TYPE MARK LOCATION MARK DESCRIPTION

NOTIFIED BY DATE TIME
6/25/2009

SSN DL ID STATE
N8685798 CA

PENDING BY

ID METHOD
CALIFORNIA DRIVER'S LICENSE

LA # MAIN # CII # FBI # MILITARY # POB
INDIANA

IDENTIFIED BY NAME (PRINT) RELATIONSHIP PHONE DATE TIME

CDI. 6/25/2009

PLACE OF DEATH / PLACE FOUND ADDRESS OR LOCATION CITY ZIP
HOSPITAL 757 WESTWOOD PLAZA DRIVE LOS ANGELES 90095

RONALD REAGAN/UCLA MEDICAL CENTER

PLACE OF INJURY AT WORK DATE TIME LOCATION OR ADDRESS ZIP
RESIDENCE No 100 NORTH CAROLWOOD DRIVE, LOS ANGELES, CA 90077

DOD TIME FOUND OR PRONOUNCED BY
6/25/2009 14:26 DR COOPER

OTHER AGENCY INV. OFFICER PHONE REPORT NO. NOTIFIED BY NO
LAPD ROBBERY HOMICIDE DIVISION - DET. SCO (213) 485-2167

TRANSPORTED BY TO DATE TIME
ALEXANDER P PEREZ LOS ANGELES FSC 6/25/2009 18:50

FINGERPRINTS?	Yes	CLOTHING	No	PARPT	No	MORTUARY	
MED EV	Yes	INVEST PHOTO #	30	SEAL TYPE	NOT SEALED	HOSP RPT	Yes
PHYS EV	No	EVIDENCE LOG	Yes	PROPERTY?	Yes	HOSP CHART	Yes
SUICIDE NOTE	No	GSR NO		RCPT NO	231940	PF NO	397-5944

SYNOPSIS
THE DECEDENT IS A 50-YEAR-OLD BLACK MALE WHO SUFFERED RESPIRATORY ARREST WHILE AT HOME UNDER THE CARE OF HIS PRIMARY PHYSICIAN. ON THE DAY OF HIS DEATH, THE DECEDENT COMPLAINED OF DEHYDRATION AND NOT BEING ABLE TO SLEEP. SEVERAL HOURS LATER, THE DECEDENT STOPPED BREATHING AND COULD NOT BE RESUSCITATED. PARAMEDICS TRANSPORTED HIM TO UCLA MEDICAL CENTER, WHERE HE WAS PRONOUNCED DEAD. THE DECEDENT WAS TAKING SEVERAL PRESCRIPTION MEDICATIONS INCLUDING CLONAZEPAM, TRAZODONE, DIAZEPAM, LORAZEPAM AND FLOMAX. IT IS UNKNOWN IF HE WAS COMPLIANT WITH HIS MEDICATIONS. THE DECEDENT SUFFERED FROM VITILIGO AND HAD NO HISTORY OF HEART PROBLEMS.

ELISSA FLEAK
497061 *E. Fleak*

DATE 6/26/2009 REVIEWED BY *J. [Signature]* DATE 6-26-09
TIME 04:33 TIME 0700

INVESTIGATOR FORM #3 NARRATIVE TO FOLLOW?



**County of Los Angeles, Department of Coroner
Investigator's Narrative**



Case Number: 2009-04415

Decedent: JACKSON, MICHAEL

Information Sources:

1. Detective W. Porche, LAPD- West Los Angeles Division
2. Detective S. Smith, LAPD- Robbery Homicide Division
3. UCLA Medical Center, medical record #397-5944

Investigation:

On 6/25/09 at 1538 hours, Detective W. Porche from the Los Angeles Police Department (LAPD) reported this case as an accidental vs. natural death to the Los Angeles County Department of Coroner. Lieutenant F. Corral assigned this death investigation to me at 1615 hours. I arrived at UCLA Medical Center at 1720 hours, along with Assistant Chief E. Winter and Forensic Attendant A. Perez. Upon my completion of the body examination at the hospital, the decedent was transported by the Los Angeles Sheriffs Department-Air Bureau to the Coroner's Forensic Science Center (FSC). Forensic Attendant Perez escorted the decedent's body during transport.

Assistant Chief E. Winter and I left the hospital and went to the decedent's residence. We arrived at the residence at 1910 hours and I performed a scene investigation. We departed the scene 2020 hours and returned to the FSC.

Location:

Place of death: UCLA Medical Center, 757 Westwood Plaza Drive, Los Angeles, CA 90095

Informant/Witness Statements:

The following information is preliminary and subject to change pending further investigation by the appropriate law enforcement agency. I spoke with Detective S. Smith from the LAPD and he reported that on the early morning of 6/25/09 at approximately 0100 hours, the decedent placed a call to his primary physician, cardiologist, Dr. Conrad Murray. The decedent complained of being dehydrated and not being able to sleep. Dr. Murray went to the decedent's residence and administered medical care. The details and extent of this medical care are currently unknown; though the decedent slept for several hours and Dr. Murray was at the bedside. Around 1200 hours, Dr. Murray found that the decedent was not breathing and he pulled the decedent onto the bedroom floor and began CPR. 911 was called and paramedics responded to the house.

According to the medical record (listed above), the paramedics arrived at the home at 1226 hours and found the decedent asystolic. Paramedics continued CPR and ACLS protocol including two rounds of epinephrine and atropine. The decedent was then intubated and CPR efforts continued. The decedent remained unresponsive; his pupils were fixed and dilated. Under advisement of Dr. Murray, the decedent was placed in the ambulance and transported to UCLA Medical Center. Throughout the transport, all medical orders were given by Dr. Murray.

The decedent presented asystolic to the hospital. Central lines and an intra-aortic balloon pump were placed but the decedent remained without vital signs. Dr. Cooper pronounced death at 1426 hours on 6/25/09.

According to Detective S. Smith, the decedent had been undergoing daily strenuous exercise in preparation for an upcoming planned music tour, in which it would have been necessary for the decedent to be in strong physical condition. The decedent did not have a history of heart problems. He was taking several prescription medications including clonazepam, trazodone, diazepam, lorazepam and Flomax but it is unknown if he was compliant.



County of Los Angeles, Department of Coroner
Investigator's Narrative



Case Number: 2009-04415

Decedent: JACKSON, MICHAEL

Scene Description:

The decedent's residence is a two-story mansion located in Bel-Air on a quiet residential street. The home is clean and well-groomed. I observed the bedroom on the second floor of the home, to the right of the top of the staircase. Reportedly, this is the bedroom where the decedent had been resting and entered cardiac arrest. His usual bedroom was down the hall.

The bedroom to the right of the staircase contained a queen size bed, numerous tables and chairs, a dresser and a television. There was also a large attached walk-in closet. The bedding was disheveled and appeared as though someone had been lying on the left side of the bed. There was a blue plastic pad lined with cotton on the left side of the fitted sheet near the center of the bed. Near the left foot of the bed, there was a string of wooden beads and a tube of toothpaste. Miscellaneous items remained on the right side of the bed including a book, laptop computer and eyeglasses. Also near the foot of the bed, there was a closed bottle of urine atop a chair.

Next to the left side of the bed, there were two tables and a tan colored sofa chair. Reportedly, the decedent's doctor sat here. A green oxygen tank was also on this side of the bed. The decedent's prescription medication bottles were seen on the tables with various medical supplies including a box of catheters, disposable needles and alcohol pads. Several empty orange juice bottles, a telephone and lamp were on the tables as well. An ambu-bag and latex gloves lay on the floor next to the bed.

Evidence:

I collected medical evidence from the decedent's residence on 6/25/09; see form 3A for details.

Body Examination:

I performed an external body examination at the hospital on 6/25/09. The decedent was wearing a hospital gown. The body is that of an adult Black male who appears to be approximately 50-years-old. He has brown colored eyes, natural teeth and brown hair. The decedent's head hair is sparse and is connected to a wig. The decedent's overall skin has patches of light and dark pigmented areas.

The ambient temperature in the hospital room was 68 degrees F at 1815 hours. At 1811 hours, rigor mortis was not present throughout the body and lividity blanched with light pressure. Lividity was consistent with a supine position.

There was a dark black discoloration on the decedent's upper forehead near his hair line. Dark coloration was present on the decedent's eyebrows, eyelashes and lips. A small piece of gauze was found on the tip of his nose and an ETT, held in place with medical tape, was seen in his mouth. A red discoloration is prominent on the center of his chest.

Gauze covering a puncture wound was taped to his right neck and IV catheters were present in his left neck and bilaterally in the inguinal area. There was also an external urine catheter present. Additional puncture wounds were seen on his right shoulder, both arms and both ankles. There is a bruise on his left inner leg, below his knee and 4 discolored indentations were found on his lower backside.

Identification:

The body was positively identified as Michael Joseph Jackson by visual comparison to his California Drivers License on 6/25/09.



County of Los Angeles, Department of Coroner
Investigator's Narrative



Case Number: 2009-04415

Decedent: JACKSON, MICHAEL

Next of Kin Notification:

The decedent was not married and his children are under 18 years of age. His mother, is the legal next-of-kin and was notified of the death on 6/25/09.

Tissue Donation:

The hospital record does not indicate if the decedent's family was approached regarding donation.

Autopsy Notification:

Detective S. Smith from the LAPD-Robbery Homicide Division requests notification of autopsy. See file for contact information.

E. Fleak

ELISSA FLEAK, Investigator

6/26/09

6/26/2009

John P. ...

Supervisor

COUNTY OF LOS ANGELES

MEDICAL EVIDENCE

DEPARTMENT OF CORONER

3A

CASE # 2009-04415
 DECEDENT'S NAME: JACKSON, MICHAEL JOSEPH
 DOD: 6/25/2009
 INCOMING MODE:

Page 1 of 2

Drug Name	Rx Number	Date of Issue	Number Issued	Number Remaining	Form	Dosage	Rx Directions	Physician	Pharmacy Phone/Comments
BENOCQUIN					LIQUID	20%	LOTION IN TUBE		APPLIED PHARMACY SERVICES NO SCRIPT INFO
CLONAZEPAM	1793217	4/18/2009	30	8	TABLET	1MG	1 AT BEDTIME	METZGER	RITE AID 310-273-3561
DIAZEPAM	C0222066	6/20/2009	60	57	TABLET	10MG	1/2 TO 1 EVERY 6 HRS	MURRAY	CVS 310-273-5252
FLOMAX	567153	6/3/2009	30	24	CAPSULE	0.4MG	ONCE DAILY	MURRAY	CVS 310-474-2152
HYDROQUINONE					LIQUID	8%	LOTION IN TUBE		APPLIED PHARMACY SERVICES NO SCRIPT INFO
LIDOCANE	6636823	5/14/2009	60		LIQUID	4%PLO	LOTION IN TUBE	MURRAY	APPLIED PHARMACY SERVICES 702-304-0770 PRESCRIBED TO DR. MURRAY
LORAZEPAM	C567154	4/28/2009	30	9	TABLET	2MG	ONCE AT BEDTIME	MURRAY	CVS 310-474-2152
TEMAZEPAM	C541756	12/22/2008	30	3	CAPSULE	30MG	ONCE AT BEDTIME AS N	MURRAY	CVS 310-474-2152

Paraphernalia Description
 ONE GREEN OXYGEN TANK; A BROKEN SYRINGE; AN OPEN BOX OF HYPODERMIC DISPOSABLE NEEDLES; AN OPEN BOX OF IV CATHETERS; UVA ANTHELLOS XL LOTION; OPEN BOTTLE OF BAYER ASPIRIN; EMPTY GLASS VIAL OF PROPOFOL INJECTABLE EMULSION 1%; AND EMPTY GLASS VIAL OF FLUMAZENIL INJECTION 0.5MG/ML

Investigator:
 ELISSA J. FLEAK (497061)
Date:
 6/26/2009

COUNTY OF LOS ANGELES

MEDICAL EVIDENCE

DEPARTMENT OF CORONER

3A

CASE # 2009-04415
 DECEDENT'S NAME: JACKSON, MICHAEL JOSEPH
 DOD: 6/25/2009
 INCOMING MODE:

Page 2 of 2

Drug Name	Rx Number	Date of Issue	Number Issued	Number Remaining	Form	Dosage	Rx Directions	Physician	Pharmacy Phone/Comments
TEST									
TIZANIDINE	1612056	6/7/2009	10	8	TABLET	4MG	HALF TABLET AT BEDTI	KLEIN	RITE AID 310-273-3561 PRESCRIBED TO OMAR ARNOLD
TRAZADONE	1793218	4/18/2009	60	38	TABLET	50MG	2 AT BEDTIME AS NEED	METZGER	RITE AID 310-273-3561

Paraphernalia Description
 ONE GREEN OXYGEN TANK; A BROKEN SYRINGE; AN OPEN BOX OF HYPODERMIC DISPOSABLE NEEDLES; AN OPEN BOX OF IV-CATHETERS;
 UVA ANTHELIOS XL LOTION; OPEN BOTTLE OF BAYER ASPIRIN; EMPTY GLASS VIAL OF PROPOFOL INJECTABLE EMULSION 1%; AND EMPTY
 GLASS VILE OF FLUMAZENIL INJECTION 0.5MG/ML

Investigator:
 ELISSA J. FLEAK (4970611)
Date:
 6/26/2009

*** 2ND FORM 3A ***
 Initiated on 6/29/2009 for evidence collected from second scene visit

COUNTY OF LOS ANGELES

MEDICAL EVIDENCE

DEPARTMENT OF CORONER

3A

CASE # 2009-04415
 DECEDENT'S NAME JACKSON, MICHAEL JOSEPH
 DOD 6/25/2009
 INCOMING MODE Accident vs. Natural

Page 1 of 3

Drug Name	Rx Number	Date of Issue	Number Issued	Number Remaining	Form	Dosage	Rx Directions	Physician	Pharmacy Phone/ Comments
Propofol 1% injectable emulsion					liquid		no prescription directions		3 - 100 mL vials no patient or doctor names
Propofol 1% injectable emulsion					liquid		no prescription directions		8 - 20 mL vials no patient or doctor names
Lidocaine HCl injectable					liquid		no prescription directions		6 - 30 mL vials no patient or doctor names
Midazolam injectable					liquid		no prescription directions		5 - 10 mL vials no patient or doctor names

Paraphernalia Description

2 blue plastic/canvas bags, 1 square black bag, 5 business cards for Dr. Conrad Murray, 1 IV side clamp, 1 blue rubber strip, 1 Starline aneroid sphygmomanometer (blood pressure cuff), 1 red stained piece of gauze, 1 pulse finger monitor (Nonin-Onyx), and 1 bag of medical supplies including crumpled packaging

Investigator:

ELISSA J. FLEAK (437051)

Date:

6/29/2009

*** 2ND FORM 3A ***
 Initiated on 6/29/2009 for evidence collected from second scene visit

COUNTY OF LOS ANGELES

MEDICAL EVIDENCE

DEPARTMENT OF CORONER

3A

CASE # 2009-04415
 DECEDENT'S NAME JACKSON, MICHAEL JOSEPH
 DOD 6/25/2009
 INCOMING MODE Accident vs. Natural

Page 2 of 3

Drug Name	Rx Number	Date of Issue	Number Issued	Number Remaining	Form	Dosage	Rx Directions	Physician	Pharmacy Phone/ Comments
Flumazenil injectable			liquid				no prescription directions		4 - 5 mL vials no patient or doctor names
Lorazepam injectable			liquid				no prescription directions		2 - 4 mL vials no patient or doctor names
Lorazepam injectable			liquid				no prescription directions		1 - 10 mL vial no patient or doctor names
Ephedrine, Caffeine, Aspirin				14	black and red capsules				red plastic pill bottle with no prescription directions and no patient or doctor names
Paraphernalia Description									
									Investigator: ELISSA J FLEAK (69735-1)
									Date: 6/29/2009

*** 2ND FORM 3A ***
 Initiated on 6/29/2009 for evidence collected from second scene visit

COUNTY OF LOS ANGELES

MEDICAL EVIDENCE

DEPARTMENT OF CORONER

3A

CASE # 2009-04415
 DECEDENT'S NAME JACKSON, MICHAEL JOSEPH
 DOD 6/25/2009
 INCOMING MODE Accident vs. Natural

Page 3 of 3

Drug Name	Rx Number	Date of Issue	Number Issued	Number Remaining	Form	Dosage	Rx Directions	Physician	Pharmacy Phone/ Comments
BOKARA white tube of lotion					liquid				Applied Pharmacy Services no prescription directions and no patient or doctor names over the counter
Bausch&Lomb eye drops					liquid				
Paraphernalia Description									

Investigator:
 ELISSA J FLEAK (49705-1)
 Date: 6/29/2009

*** 3rd FORM 3A ***
 Initiated on 7/9/2009 for evidence brought to FSC by family

COUNTY OF LOS ANGELES

MEDICAL EVIDENCE

DEPARTMENT OF CORONER

3A

CASE # 2009-04415
 DECEASED'S NAME: JACKSON, MICHAEL JOSEPH
 DOD 6/25/2009
 RECEIVING MODE Accident vs. Natural

Page 1 of 1

Drug Name	Rx Number	Date of Issue	Number Issued	Number Remaining	Form	Dosage	Rx Directions	Physician	Pharmacy Phone/ Comments
Zanaflex	7018879	11/6/08	4	0	tablet	4mg	1/2 to 1 tab at bedtime	Klein, Arnold	Mickey Fine Pharm 310-271-6128
Prednisone	1795927	4/25/09	10	0	tablet	10mg	6 tab now, 4 tomorrow	Klein, Arnold	Rite Aid 310-273-3561
Amoxicillin	53380	2/2/09	28	21	caps	500mg	4 times daily	Dwight James/ Cherlyn Lee	Patient name blacked out on label
Azithromycin	54729	3/9/2009	6	2	tablet	250mg	2 tabs first day then 1 for 4 days	Dwight James/ Cherlyn Lee	patient name: Kathryn Hursey

Paraphernalia Description
 OTC- Bausch and Lomb eye drops, small tube of "Ultravate" ointment

Investigator:
 ELISSA J FLEAK (497057)
 Date: 7/9/2009

COUNTY OF LOS ANGELES

DEPARTMENT OF CORONER

12**AUTOPSY REPORT**

No.

2009-04415

JACKSON, MICHAEL

I performed an autopsy on the body of



at the DEPARTMENT OF CORONER

Los Angeles, California

on JUNE 26, 2009 @ 1000 HOURS

(Date)

(Time)

From the anatomic findings and pertinent history I ascribe the death to:

(A) ACUTE PROPOFOL INTOXICATION

DUE TO OR AS A CONSEQUENCE OF

(B)

DUE TO OR AS A CONSEQUENCE OF

(C)

DUE TO OR AS A CONSEQUENCE OF

(D)

OTHER CONDITIONS CONTRIBUTING BUT NOT RELATED TO THE IMMEDIATE CAUSE OF DEATH:

BENZODIAZEPINE EFFECT

Anatomical Summary:

1. Toxicology findings (see separate report).
 - A) Propofol, lorazepam, midazolam, lidocaine, diazepam and nordiazepam, identified in blood samples (see toxicology report for details).
 - B) Propofol, midazolam, lidocaine and ephedrine identified in urine.
 - C) Propofol and lidocaine identified in liver tissue.
 - D) Propofol identified in vitreous humor.
 - E) Lidocaine and propofol identified in stomach contents.
2. Nodular prostatic hyperplasia.
 - A) Prominent intravesical median lobe enlargement.
 - B) Urinary retention.
3. Vitiligo.
4. Tubular adenoma of colon.
5. Evidence of therapy.
 - A) Endotracheal tube.
 - B) Intravascular catheters of left neck, and both femoral regions.

COUNTY OF LOS ANGELES

AUTOPSY REPORT**12**

No.

2009-04415

JACKSON, MICHAEL

Page 2

- C) Intra-aortic balloon pump, inserted through left femoral artery.
- D) Punctures and contusions of right neck, both arms, left calf, and right ankle.
- E) Condom catheter.
- F) Resuscitative abrasion-contusion of central chest.
- G) Resuscitative fractures of sternum, right 4th and 5th ribs, and left 3rd through 5th ribs.
- H) Resuscitative alveolar hemorrhage of lungs.
- I) Resuscitative transmural hemorrhage of stomach.
6. See separate consultation reports:
- A) Neuropathology.
1. Mild cerebral vascular congestion.
 2. Mild diffuse brain swelling without herniation syndrome.
 3. Mild basal ganglia calcification.
- B) Pulmonary pathology.
1. Marked diffuse congestion and patchy hemorrhage of right and left lungs.
 2. Marked respiratory bronchiolitis, histiocytic desquamation, and multifocal chronic interstitial pneumonitis.
 3. Multifocal fibrocollagenous scars.
 4. Organizing and recanalizing thromboemboli of two small arteries.
 5. Intravascular eosinophilia with occasional interstitial eosinophilic infiltrate.
 6. Suggestive focal desquamation of respiratory lining cells with squamous metaplasia.
- C) Radiology.
1. Minimal degenerative spondylosis of the lower thoracic spine.
 2. Right C7 cervical rib.
 3. Degenerative osteoarthritis of lower lumbar spine facet joints, distal interphalangeal joints of the right index and long fingers, and distal interphalangeal joint of left little finger.

12**AUTOPSY REPORT**

No.

2009-04415

JACKSON, MICHAEL

Page 3

4. Mild calcified arterial atherosclerosis of both legs.

D) Odontology.

1. Root canal therapy, tooth #13.
2. Endosseal implants, teeth #18 and #19.
3. Metallic/ceramic restorations of lower right quadrant.
4. Multiple all-ceramic restorations of maxillary teeth.

E) Anesthesiology.

CIRCUMSTANCES:

The decedent is a 50 year old man who was found unresponsive in his residence on June 25, 2009. He was taken to UCLA Medical Center, where he was pronounced dead.

EXTERNAL EXAMINATION:

The body is identified by toe tags and is that of an unembalmed refrigerated adult Black male who appears the stated age of 50 years. The body weighs 136 pounds, measures 69 inches in length, and is thin. Over the lower back are several 1/4-1/2 inch perimortem abrasions. (Comment: Scene photographs show beads on the bed).

EVIDENCE OF RECENT THERAPY:

An endotracheal tube is appropriately positioned in the trachea. Intravascular catheters enter the left jugular vein and both femoral vessels. An intraaortic balloon pump enters the left femoral artery and is appropriately positioned within the aorta. A condom catheter is present. There are numerous punctures over both arms. Additional punctures are present on the medial left knee and the medial right ankle. Gauze pads are present on the right neck, left antecubital fossa, left forearm, and right antecubital fossa.

The central chest shows a 1-1/2 x 1-1/4 inch irregular abrasion with a surrounding 3 x 3 inch bruise. The soft tissue of the left anterior chest shows a 3-1/2 x 2 inch bruise and the soft tissue of the right anterior chest shows a 5 x 3-1/2 inch bruise. The sternum is fractured at the level of the 3rd rib.

12**AUTOPSY REPORT**

No.

2009-04415

JACKSON, MICHAEL

Page 4

The right 4th and 5th ribs are fractured at the chondrocostal junction. The left 3rd, 4th and 5th ribs are fractured at the chondrosternal junction.

The following scars are present:

1. There is a 3/4 inch scar behind the left ear and a scar-like area behind the right ear.
2. There are scars at the lateral border of the alae nasi, 3/5 inch in length on the right and 5/8 inch in length on the left.
3. On the top of the right shoulder is an irregular scar-like area approximately 4 inches in diameter.
4. At the posterior base of the neck are two downsloping scar-like areas measuring 3-1/4 inch on the left and 3 inches on the right. (See microscopic examination, slide U).
5. The left arm shows a 1/4 inch scar on its anterior surface just proximal to the antecubital region. The left wrist shows a 1/8 inch scar.
6. There is a 7/8 inch scar on the right thenar eminence, and a 1/8 inch scar of the right wrist.
7. There is a 2 inch surgical scar in the right lower quadrant of the abdomen.
8. There is a 5/8 inch scar around the area of the umbilicus.
9. There is a 2 x 1/8 inch semicircular scar of the right knee, with several smaller scars distal to it measuring 1/2 to 1/4 inch in length.
10. On the anterior right shin is a 5 x 2-1/2 inch area of hyperpigmentation.

The following tattoos are present:

There is a dark skin discoloration resembling a tattoo on the anterior half of the scalp. There are dark tattoos in the areas of both eyebrows and at the superior and inferior borders of the palpebral fissures. There is a pink tattoo in the region of the lips.

There is focal depigmentation of the skin, particularly over the anterior chest and abdomen, face and arms.

Rigor mortis is present in the limbs and jaw. Livor mortis is fixed and distributed posteriorly.

The head is normocephalic and is partly covered by black hair. There is frontal balding and the hair can be described as short and tightly curled. A mustache and beard are absent.

COUNTY OF LOS ANGELES

DEPARTMENT OF CORONER

12**AUTOPSY REPORT**

No.

2009-04415

JACKSON, MICHAEL

Page 5

Examination of the eyes reveals irides that are brown and sclerae that show no injection or jaundice. There are no petechial hemorrhages of the conjunctivae of the lids or the sclerae. The oronasal passages are unobstructed. A bandage is present on the tip of the nose. Upper and lower teeth are present and in good repair (see odontology consultation). The neck is unremarkable. There is no chest deformity. There is no increase in the anterior-posterior diameter of the chest. The abdomen is flat. The genitalia are those of an adult male. The penis appears uncircumcised. The extremities show no edema, joint deformity, or abnormal mobility.

CLOTHING:

The body was not clothed and no clothing is available for review.

INITIAL INCISION:

The head and body cavities are entered through the standard coronal incision and the standard Y-shaped incision, respectively. No foreign material is present in the mouth, upper airway and trachea.

NECK:

The neck organs are removed en bloc with the tongue. There are small contusions inside the lips as well as in the central area of the tongue. On the mucosa of the left pyriform recess are three slightly raised nodules measuring 0.2 cm in diameter each. There is no edema of the larynx. Both hyoid bone and larynx are intact without fractures. No hemorrhage is present in the adjacent throat organs, investing fascia, strap muscles, thyroid or visceral fascia. There are no prevertebral fascial hemorrhages.

CHEST AND ABDOMINAL CAVITIES:

The pleural cavities contain minimal fluid and no adhesions. No pneumothorax is demonstrated. The parietal pleurae are intact. The lungs are well expanded. Soft tissues of the thoracic and abdominal walls are well-preserved. The organs of the abdominal

12**AUTOPSY REPORT**

No.

2009-04415

JACKSON, MICHAEL

Page 6

cavity have a normal arrangement and none is absent. There is no fluid collection in the abdomen. The peritoneal cavity is without evidence of peritonitis. There are no adhesions.

SYSTEMIC AND ORGAN REVIEW

CARDIOVASCULAR SYSTEM:

The aorta is fairly elastic and of even caliber throughout with vessels distributed normally from it. It shows lipid streaking. There is no tortuosity, widening or aneurysm of the aorta. The major branches of the aorta show no abnormality. Within the pericardial sac there is a minimal amount of serous fluid. The heart weighs 290 grams. It has a normal configuration. The right ventricle is 0.2 cm thick and the left ventricle is 1.4 cm thick. The chambers are normally developed and are without mural thrombosis. The valves are thin, leafy and competent. Circumferences of valve rings are: Tricuspid valve 12.8 cm, pulmonic valve 7.0 cm, mitral valve 8.8 cm, and aortic valve 7.2 cm. There is no endocardial discoloration. There are no focal lesions of the myocardium. There is no abnormality of the apices of the papillary muscles. There are no defects of the septum. The great vessels enter and leave in a normal fashion. The ductus arteriosus is obliterated. The coronary ostia are widely patent. The right coronary artery is the dominant vessel. There is no coronary artery atherosclerosis. No focal endocardial, valvular or myocardial lesions are seen. The blood within the heart and large blood vessels is liquid.

RESPIRATORY SYSTEM:

Scant secretions are found in the upper respiratory passages. The mucosa of the larynx is focally hemorrhagic. The lungs are subcrepitant and there is dependent congestion. The left lung weighs 1060 grams (see Special Procedures below) and the right lung weighs 940 grams. The visceral pleurae are smooth and intact. The parenchyma is moderately congested. The pulmonary vasculature is without thromboembolism.

12**AUTOPSY REPORT**

No.

2009-04415

JACKSON, MICHAEL

Page 7

GASTROINTESTINAL SYSTEM:

The esophagus is intact throughout. The stomach is not distended. It contains 70 grams of dark fluid. There are a few mucosal hemorrhages, but no ulceration. Portions of tablets and capsules cannot be discerned in the stomach. The external and in situ appearance of the small intestine and colon are unremarkable. The small intestine and colon are opened along the antimesenteric border, revealing a 2 mm pedunculated polyp of the sigmoid colon. The colonic mucosa is purple. The appendix is present. The pancreas occupies a normal position. There is no pancreatic necrosis. The parenchyma is lobular and firm. The pancreatic ducts are not ectatic and there is no parenchymal calcification.

HEPATOBIILIARY SYSTEM:

The liver weighs 1480 grams. It is red-brown and the capsule is thin. The consistency is soft and the cut surface is smooth. There is a normal lobular arrangement. The gallbladder is present and its wall is thin and pliable. It contains 10 grams of bile and no stones. There is no obstruction or dilatation of the extrahepatic ducts. The periportal lymph nodes are not enlarged.

URINARY SYSTEM:

The left kidney weighs 120 grams and the right kidney weighs 140 grams. The kidneys are normally situated and the capsules strip easily revealing a surface that is smooth and dark purple. The corticomedullary demarcation is preserved. The right kidney shows a 0.2 cm off-white well circumscribed medullary mass. The pyramids are not remarkable. The peripelvic fat is not increased. The ureters are without dilatation or obstruction and pursue their normal course. The urinary bladder is distended and trabeculated. It contains 550 grams of clear yellow-orange urine.

GENITAL SYSTEM:

The prostate is moderately enlarged, with a prominent intravesical middle (median) lobe. The prostatic parenchyma is nodular. Both testes are in the scrotum and are unremarkable and without trauma.

12**AUTOPSY REPORT**

No.

2009-04415

JACKSON, MICHAEL

Page 8

HEMOLYMPHATIC SYSTEM:

The spleen weighs 110 grams. The capsule is thin and the parenchyma is dark red. There is no increase in the follicular pattern. Lymph nodes throughout the body are small and inconspicuous in general. However, there is a 1.5 cm well circumscribed off-white lobulated mass located in the periaortic region just medial to the left adrenal gland. The mass is not remarkable. The bone marrow of the vertebra is red and moist.

ENDOCRINE SYSTEM:

The thyroid gland is unremarkable and weighs 24 grams. Tissue from the parathyroid area is submitted for microscopic evaluation. The adrenals are intact without necrosis or hemorrhage and weigh 5 grams each. The thymus is not identified. The pituitary gland is of normal size.

HEAD AND CENTRAL NERVOUS SYSTEM:

There is no subcutaneous or subgaleal hemorrhage in the scalp. The external periosteum and dura mater are stripped showing no fractures of the calvarium or base of the skull. There are no tears of the dura mater. There is no epidural, subdural or subarachnoid hemorrhage. The brain weighs 1380 grams.

SPINAL CORD:

The spinal cord is not dissected.

NEUROPATHOLOGY:

The brain is placed in formalin solution for further fixation and later neuropathology consultation. Note: Following neuropathological examination, residual brain tissue is released to the mortuary on 7-8-09.

HISTOLOGIC SECTIONS:

Representative specimens from various organs are preserved in two storage jars in 10% formalin. A separate storage jar of

12**AUTOPSY REPORT**

No.

2009-04415

JACKSON, MICHAEL

Page 9

selected areas of brain tissue is preserved by the neuropathologist on 7-8-09. Sections are submitted at autopsy for slides. The slide key is as follows:

- A - adrenal glands
- B - left pyriform recess
- C - parathyroid area
- D - thyroid gland
- E - left periaortic mass
- F - bone marrow
- G - aorta, right ventricle
- H - pituitary
- I - cardiac interventricular septum
- J - left ventricle
- K - right lung
- L - right testis
- M - left testis
- N - stomach and gallbladder
- O - pancreas
- P - spleen
- Q - liver
- R - right kidney
- S - left kidney
- T - bowel
- U - scar-like area from right posterior neck
- V - prostate

TOXICOLOGY:

Blood, bile, liver tissue, stomach, urine and vitreous humor have been submitted to the laboratory. A comprehensive screen is requested.

SPECIAL PROCEDURES:

The left lung is referred to pulmonary pathology for examination (see separate report). Note: Following pulmonary pathology examination, residual left lung tissue is released to the mortuary on 7-8-09, after selected sections of the perfused inflated lung are preserved in one of the original storage jars.

12**AUTOPSY REPORT**

No.

2009-04415

JACKSON, MICHAEL

Page 10

PHOTOGRAPHY:

Photographs have been taken prior to and during the course of the autopsy. The following photographs taken by the coroner are reviewed prior to signing the autopsy report:

1. 17 photographs taken at the hospital on 6-25-09.
2. 13 photographs taken at the scene on 6-25-09 showing the bedroom where paramedics treated the decedent.
3. One intake photograph taken at the Forensic Science Center on 6-25-09.
4. 61 photographs taken on 6-26-09 before and during autopsy (documenting resuscitative injury and intravesical prostatic enlargement).
5. 3 photographs of a silver BMW 645 Ci taken on 6-29-09.
6. 13 photographs taken at the scene on 6-29-09 showing the dressing room with closets where additional medical evidence was collected.
7. Three contact sheets showing 108 photographs (items 1 to 6 above).
8. Four photographs taken on 7-23-09 of the Stokes litter from Sheriff's Air 5 helicopter used in transporting decedent.
9. Five enlarged scene photographs taken by the police are reviewed with Dr. Calmes, in addition to some of the other police photographs pertaining to medical evidence.

RADIOLOGY:

Sixteen x-rays are obtained.

WITNESS:

Detective Scott Smith of LAPD witnessed the autopsy.

DIAGRAMS USED:

Diagram Forms 20 and 22 were used during the performance of the autopsy. The diagrams are not intended to be a facsimile.

12**AUTOPSY REPORT**

No.

2009-04415

JACKSON, MICHAEL

Page 11

OPINION:

Toxicology studies show a high blood concentration of propofol, as well as the presence of benzodiazepines as listed in the toxicology report. The autopsy did not show any trauma or natural disease which would cause death.

The cause of death is acute propofol intoxication. A contributory factor in the death is benzodiazepine effect.

The manner of death is homicide, based on the following:


1. Circumstances indicate that propofol and the benzodiazepines were administered by another.
2. The propofol was administered in a non-hospital setting without any appropriate medical indication.
3. The standard of care for administering propofol was not met (see anesthesiology consultation). Recommended equipment for patient monitoring, precision dosing, and resuscitation was not present.
4. The circumstances do not support self-administration of propofol.



CHRISTOPHER ROGERS, MD, MBA
CHIEF FORENSIC MEDICINE DIVISION

DATE

8-19-09



LAKSHMANAN SATHYAVAGISWARAN, MD
FRCP (C), FCAP, FACP
CHIEF MEDICAL EXAMINER-CORONER

DATE

8-19-09

CR:mtm:c
D-06/26/09
T-06/30/09

13**2009-04415
Jackson, Michael**

July 31, 2009

This consultation is provided at the request of the Chief Medical Examiner-Coroner, Dr. Lakshmanan Sathyavagiswaran.

Gross Description:

The weights of the left and right lung are provided in the Autopsy Protocol.

On 6/26/09, the bronchus of the left lung was cannulated with a plastic tube that was slightly smaller in diameter than that of the bronchus. The tube was attached to a perfusion-inflation apparatus containing ~40 gallons of 10% buffered (monobasic and dibasic phosphate) formalin. Perfusion was maintained for ~72 hrs at 30cm water pressure, following which the formalin was replaced with tap water and perfusion continued for ~24 hours.

The formalin-fixed and washed lung was then placed in an electrical rotary slicer and five sagittal slices of whole lung tissue were obtained beginning at the hilum. The inflated left lung measured 25.0 cm in sagittal height, 12.0 cm in coronal width, and 12.0 cm in sagittal depth. The visceral pleural surfaces were generally thin and transparent with the exception that the lateral surface of a large portion of the lower lobe was slightly thickened and had a milky appearance. There was also a patchy anthracotic pigment deposition that involved primarily the superior and lateral portions of the upper and lower lung lobes, with band-like distributions along the rib cage. There were no pleural adhesions or areas of consolidation other than several poorly defined small nodules in the apical portion of the upper lobe in association with a few whitish streaks having an apparent lymphatic distribution. The anterior margin of the upper lobe showed a patchy film-like opacification. The main stem bronchus of the left lung measured 2.5 cm in length and was grossly unremarkable. A few hilar lymph nodes were noted that were grossly unremarkable except for slight anthracotic pigmentation.

Gross examination of the sliced section at the base of the Left Lower Lobe showed three relatively firm and nodular masses of tissue immediately below the pleura surface. On cut section, the largest of the nodular masses was irregular and measured 0.6 cm x 0.8 cm x 0.5 cm. Two other masses, each measuring 0.5 cm x 0.5cm and 0.7 cm, were moderately firm in consistency and, in large part, associated with congestion and hemorrhage. An area of brownish discoloration of the apical pleura overlying the Left Upper Lobe measured 0.5cm x 0.6cm, with superficial involvement (~1.0mm) of the subpleural tissue. Additional small areas of subpleural brownish discolorations were nearby. At the base of the Left Upper Lobe, a reddish-brown and hemorrhagic mass was found that measured 0.6 cm x 0.6cm x 0.4 cm. Five sections of the formalin-perfused lung tissue were excised for microscopic study.

Sections taken for paraffin embedding and processing:

Cassette B - apex, Left Lower Lobe; Cassette D - base, Left Lower Lobe
Cassette A - base, Left Upper Lobe; Cassette E - base, Left Lower Lobe
Cassette C- Main stem bronchus, transverse section

Histopathologic Findings

On examination of the base of the Left Lower Lobe, four roughly rectangular scar areas were found that measured approximately 3.5mm x 1.4mm, 7.6mm x 4.2mm, 4.8mm x 0.9mm, and 1.4mm x 0.6mm. All shared in common acellular fibrocollagenous tissue, derangement of bronchioloalveolar structures, hemorrhage, proteinaceous-fibrinous deposits, and aggregates of heavily pigmented macrophages. In some scar areas there was a fibrous thickening of bronchioloalveolar walls with round cell infiltrates and aggregates of pigmented histiocytes. There is slight to moderate thickening of the pleura that overlies fibro-inflammatory lesions. Several foci of round cells aggregates are noted, including periarteriolar and pericapillary sites.

13

July 31, 2009

**2009-04415
Jackson, Michael**

Page 2

Histopathologic Findings (Cont.)

There is widespread bronchioloalveolar histiocytic infiltration and patchy histiocytic desquamation. Centriacinar derangement is noted with and without chronic inflammation. Two small arteries are observed that contain organizing/recanalizing thromboemboli. One of the vessels with a thromboembolus (base of upper lobe) is associated with a localized, subpleural area of hemorrhage. Eosinophils are often noted within capillaries and other vascular channels, and are also seen occasionally within interstitial tissues of the lung. In two instances, an air space was observed that contained cells consistent with respiratory lining cells that have undergone squamous metaplasia. Histiocytes often contained birefringent particulates in association with anthracotic pigment. Birefringent particles were absent elsewhere in the lung. Slight chronic inflammation was seen in the bronchial section. The foregoing findings were in part observed in the "K" section of the uninflated lung (H&E stained section). PAS and iron stains of Slides D and K were reviewed.

DIAGNOSIS:

Marked diffuse congestion and patchy hemorrhage of right and left lungs.
Marked respiratory bronchiolitis, histiocytic desquamation, and multifocal chronic interstitial pneumonitis.
Multifocal fibrocollagenous scars with and without congestion and hemorrhage.
Organizing and recanalizing thromboemboli of two small arteries.
Intravascular eosinophilia with occasional interstitial eosinophilic infiltrate.
Suggestive focal desquamation of respiratory lining cells with squamous metaplasia.

OPINION

The above findings reflect a depletion of structural and functional reserves of the lung. Reserve depletion is the result of widespread respiratory bronchiolitis and chronic lung inflammation in association with fibrocollagenous scars and organizing/recanalizing thromboemboli of small arteries.

It should be noted that the above lung injury with reserve loss is not considered to be a direct or contributing cause of death. However, such an individual would be especially susceptible to adverse health effects.

Respectfully submitted,



Russell P. Sherwin, M.D.
Deputized Consultant in Pulmonary Pathology
Professor of Pathology
Keck School of Medicine
University of Southern California

RPS/vr

13CC #2009-04415
JACKSON, Michael Joseph**ODONTOLOGY CONSULT****REQUEST:**

The decedent is a 50 year old black man who died unexpectedly. Please examine for dental contribution to cause of death.

FILMS:

Post Mortem AP and lateral skull

FINDINGS:

Review of the two films reveal history of routine restorative dentistry. There were incomplete dental records from two Las Vegas dentists who performed restorative and surgical treatment for this decedent. There is root canal therapy completed on tooth #13. There are endosseal dental implants in the positions of teeth #18 and #19. There are also metallic/ceramic restorations present in the lower right quadrant. There are multiple all ceramic restorations present in the maxillary teeth. There is no gross pathology seen on these two radiographic views, even though these are not the standard views for a dental exam.



Cathy Law, D.D.S.
DENTAL CONSULTANT

7-10-09

Date

cl:ECL
hw 7/10/09

COUNTY OF LOS ANGELES

FORENSIC CONSULTANT'S REPORT

DEPARTMENT OF CORONER

13NEUROPATHOLOGY

2009-04415

JACKSON, MICHAEL J.

July 8, 2009

AGE: 50 years

DATE OF DEATH: June 25, 2009

REFERRING DME: Christopher Rogers, M.D.

CIRCUMSTANCES:

The following information is taken from the Investigator Report, preliminary autopsy notes, and records from UCLA Ronald Reagan Medical Center currently in the file.

This 50-year-old man was reportedly found unresponsive in his residence at approximately 1200 hours on 6/25/09, and arriving paramedics found him to be in cardiopulmonary arrest. He was transported to UCLA Ronald Reagan Medical Center, but did not respond to resuscitative efforts and was pronounced at 1426 hours on 6/25/09. Available records reveal no remarkable prior neurological symptoms or findings, and no history of trauma of seizures preceding the cardiopulmonary arrest.

At the time of postmortem examination on 6/26/09 the findings included evidence of therapy, and no scalp, skull or intracranial abnormalities were described. Brain weight at removal was 1380 grams.

GROSS DESCRIPTION:

Specimens available for examination are cranial dura mater and brain. The specimens are identified as to source by the identification tag indicating specimen number and decedent name on the specimen container, and separately on a plastic card within the specimen container, within the green surgical cap surrounding the brain.

The cranial dura mater submitted includes dorsal convexities with falx cerebri, posterior fossa with tentorium cerebelli, and the bulk of the middle and anterior fossae bilaterally. External and internal surfaces of the dura mater are smooth and shiny, without evidence of discoloration, hemorrhage, subdural neomembranes, mass lesions, or other significant

13NEUROPATHOLOGY

2009-04415

JACKSON, MICHAEL J.

Page 2

finding. No calcific plaques are palpated within the dura. Dural venous sinuses are normal in pattern.

The cerebral leptomeninges show a very mild degree of increased opacity over the dorsal convexities, well within normal limits for age group, and are otherwise thin and delicate. There is a mild degree of leptomeningeal vascular congestion. The hemispheres are approximately symmetrical, with a midline and closely apposed interhemispheric fissure. There is mild diffuse cerebral swelling, with mild flattening of gyral crowns and narrowing of sulci, but no evidence of herniation at the uncus, cerebellar tonsillar/biventer lobule region, superior cerebellar vermis or cingulate gyrus. The convolitional pattern is unremarkable. No recent or remote cerebral or cerebellar cortical contusions are identified. No focal areas of softening, increased firmness, or focal discoloration are present.

Rectus-orbital and basitemporal areas are intact. Cranial nerves, I through XII, are present and unremarkable except for avulsion of the olfactory bulbs bilaterally. Major basal arteries are as follows: the left vertebral artery is slightly larger than the right vertebral artery, as they fuse to join the basilar artery. The anterior communicating artery is duplicated. Major basal arteries are otherwise unremarkable, without major anomalies, aneurysms, or significant occlusive vascular disease. Belly of the pons and medulla have a normal configuration, discounting some minor brain removal artifact consisting of a superficial incision in the anterolateral left medulla which crosses the inferior olivary nucleus. Cerebellar hemispheres are approximately symmetrical, with mild swelling of the folia. Basal cisterns are minimally narrowed, consistent with the mild degree of brain swelling previously described.

The brain is sectioned in a coronal plane, and the brainstem and cerebellum in a transverse plane. The cortical ribbon is normal in thickness and color, and gray/white demarcation is distinct. Underlying white matter is homogeneous and clear, discounting a somewhat softer consistency of parenchyma in deep hemisphere areas (which is not infrequently encountered in formalin-fixed tissue). Corpus callosum is normal in thickness, color and symmetry. Lateral ventricles are normal in size, with only a trace asymmetry noted, consisting of a

13NEUROPATHOLOGY

2009-04415

JACKSON, MICHAEL J.

Page 3

trace rounding of the superior angle of the left lateral ventricle compared to the right, which is sharp. Septum pellucidum is non-fenestrated, and there is a small cavum septi pellucidi. Third ventricle is midline and does not exceed 0.3 to 0.4 cm in maximum transverse diameter. Cerebral aqueduct and fourth ventricle are normal in size and configuration, and choroid plexus is unremarkable bilaterally. Basal ganglia are normal in size, symmetry, contour and color. Substantia nigra is normally pigmented. Hippocampal formation, amygdaloid complex of nuclei, mamillary bodies and pineal body are all grossly unremarkable. Multiple transverse sections of the brainstem and cerebellum reveal no abnormality.

Selected areas are retained in storage. Representative sections are submitted for microscopic examination.

GROSS IMPRESSIONS:

- A. Mild cerebral vascular congestion.
- B. Mild diffuse brain swelling without herniation syndrome.
- C. Otherwise grossly unremarkable adult brain and coverings.

John M. Andrews, M.D.
JOHN M. ANDREWS, M.D.
DEPUTY MEDICAL EXAMINER
NEUROPATHOLOGY CONSULTANT

DATE

7/30/09

JMA:mtm:c
T-07/08/09

13NEUROPATHOLOGY

2009-04415

JACKSON, MICHAEL J.

July 14, 2009

MICROSCOPIC DESCRIPTION:

Sections of brain (8) stained by H&E method include the right frontal lobe (slide A), right basal ganglia (slide B), left and right hippocampi (slides C and D, respectively), right thalamus (slide E), right parietal lobe (slide F), medulla (slide G), and cerebellum (slide H).

A few vessels in the sections (e.g. slide B), demonstrate sparse small lymphocytes in perivascular spaces, considered within the normal range. Very sparse extravasated blood is seen around rare parenchymal vessels (e.g. slide C). Rare leptomeningeal vessels show mild intimal thickening and fibrosis, without significant lumen compromise (e.g. slide G).

A minority of neurons in some sections (e.g. slides B, C, D and E) shows slightly more shrinkage than the majority of neurons, at times with a mild magenta tint to the cytoplasm, considered mildly suspicious for, but insufficient for the diagnosis of, acute neuronal hypoxic/ischemic injury. The majority of neurons are unremarkable. Patchy dark neuron change is also present in the sections.

Relatively mild, patchy fine granular black to purplish concretions are seen in globus pallidus, in vessel walls of some of the larger vessels and in neuropil. The smaller, generally separate granules in the neuropil are also mainly vessel-centered. The appearance of these black to purplish concretions is consistent with mild mineralization (e.g. calcification).

There is no evidence of meningitis, encephalitis, abnormal neuronal inclusions, developmental anomalies, or neoplasia.

FINAL NEUROPATHOLOGIC DIAGNOSIS:

- A. Mild cerebral vascular congestion.
- B. Mild diffuse brain swelling without herniation syndrome.
- C. Mild basal ganglia calcification (see comment).

COUNTY OF LOS ANGELES

FORENSIC CONSULTANT'S REPORT

DEPARTMENT OF CORONER

13NEUROPATHOLOGY

2009-04415

JACKSON, MICHAEL J.

Page 2

Comment: The type of mild basal ganglia mineralization present in the globus pallidus in this case is not unusual in this age group. In the absence of any clinical evidence of endocrine or metabolic disorder, it is interpreted as an incidental finding unrelated to the cause or manner of death.

John M. Andrews, M.D.
JOHN M. ANDREWS, M.D.
DEPUTY MEDICAL EXAMINER
NEUROPATHOLOGY CONSULTANT

7/30/09
DATE

JMA:mtm:c
T-07/16/09

13**ANESTHESIOLOGY CONSULTATION****JACKSON, Michael Joseph
2009-04415**

Pg. 1 of 2

This special consult is at the request of the Los Angeles County Chief Medical Examiner Coroner, Dr. Lakshmanan, for a 50 year old decedent who was found with physical evidence of the anesthetic drug propofol in his home.

RELEVANT INFORMATION ON PROPOFOL AND ITS ADMINISTRATION:

Propofol is an intravenous anesthetic with highly favorable properties: rapid onset of sedation and/or unconsciousness, predictable dose response (usually) and duration of action, rapid return of consciousness, little post-anesthesia "hang-over" and little postoperative nausea and vomiting. Unfavorable properties include respiratory and cardiovascular depression, especially on induction or if the IV bolus is rapid. Respiratory and cardiovascular depression is usually dose dependent and is accentuated if other sedatives, such as benzodiazepines, are present. There is also a narrow margin between mere sedation and full general anesthesia, with possible loss of the patient's ability to breathe and maintain their airway. (These properties are the most relevant to this case; other properties of propofol are not listed.)

Since its introduction into clinical practice in 1989, propofol has been widely used for induction and maintenance of anesthesia for surgery and to supplement regional and local anesthesia. It is widely used for sedation during uncomfortable diagnostic procedures and is also used in ICUs for sedating critically ill patients. It is reported to be used to relieve the pain of acute migraine headaches, in pain clinic settings. There are NO reports of its use for insomnia relief, to my knowledge. The only reports of its use in homes are cases of fatal abuse (first reported in 1992), suicide, murder and accident.

Propofol must be given intravenously. Administration techniques include single IV bolus (for induction of general anesthesia, going on to additional anesthesia drugs), repeat IV boluses (when there is a short-term need for sedation in a quick painful procedure) and IV bolus followed by continuous infusion (used for both general anesthesia with the addition of other drugs or for lengthy diagnostic procedures). The infusion technique requires precision control of the dose by way of a controllable infusion pump, because of the narrow margin between mere sedation and full general anesthesia and build-up of the drug as it is administered long-term. Because propofol is painful on injection, lidocaine (1 cc of 1%) is usually given, either immediately before injection or mixed into the amount to be infused. Propofol solutions easily support bacterial growth, and attention to antisepsis is required as well as discarding vials and syringes within 6 hours of use.

Full patient monitoring is required any time propofol is given. The most essential monitor is a person trained in anesthesia and in resuscitation who is continuously present and not involved in the on-going surgical/diagnostic procedure. Other monitors expected would be a continuous pulse oximeter, EKG and blood pressure cuff, preferably one that automatically inflates. An end-tidal CO₂ monitor would be used for fully anesthetized patients and is also highly desirable in sedated patients. Although the measurement of CO₂ would not be accurate in sedated patients, who have a loose mask or nasal cannula for supplemental oxygen, the presence of CO₂ documents that the patient is breathing and that the airway is open. If CO₂ stops being present, for whatever reason, the monitor will alarm (audible and visual signals), which calls attention to the possible apnea and/or airway obstruction, so action can be taken promptly. Of course, airway devices and drugs for resuscitation must always be present. Supplemental O₂ should always be delivered to patients receiving propofol, and they should always have a recovery period with monitoring and observation by trained recovery nurses.

13

ANESTHESIOLOGY CONSULTATION

JACKSON, Michael, Joseph
2009-04415

Pg. 2 of 2

Because of the risk of sudden onset of full general anesthesia, propofol should be given only by anesthesiologists or other supervised anesthesia providers, who are fully trained to recognize and treat the possible respiratory and cardiac depression. In the ICU setting, propofol should be given by ACLS certified critical care level nurses, following physician orders. (These patients are intubated and ventilated, decreasing the need to deal with respiratory depression or airway problems from propofol.) In procedure rooms such as endoscopy suites, propofol is sometimes given by nurses (hopefully ACLS certified) under the supervision of the physician doing the procedure. This is not ideal and is the subject of conflict between gastroenterologists and anesthesiologists at the national level.

THIS PARTICULAR CASE:

Questions to be answered include was the standard of care for administering propofol met, could the decedent have administered the propofol to himself and what is an anesthesiologist's point of view on the toxicology screen results.

Was the standard of care for giving propofol met? It is not known whether trained medical personnel were continuously observing the decedent while propofol given. There was no evidence of an infusion pump for control of an IV infusion. No monitors were found at the scene; a blood pressure cuff and portable pulse oximeter were recovered from a closet in the next room. A tank of oxygen with some kind of non-rebreathing bag with a clear plastic mask (for positive pressure ventilation) was near where the patient was found by the paramedics. This tank was empty when examined on 7/13/09. A non-rebreathing bag was not attached when the tank was examined. Multiple opened bottles of propofol were found, with small amounts of remaining drug. A used bottle should be discarded 6 hours after opening, to avoid possible bacterial growth. The standard of care for administering propofol was not met.

Could the decedent have given propofol to himself? It is unknown where the propofol physically came from. It would have been difficult for the patient to administer the drugs (others besides propofol were administered) to himself, given the configuration of the IV set-up. The IV catheter was in the left leg. The injection port of the IV tubing was 13.5 cm from the tip in the catheter. He would have had to bend his knee sharply or sit up to reach the injection port and push the syringe barrel, an awkward situation, especially if sleep was the goal. If only bolus injections via a syringe were used, sleep would not have been maintained, due to the short action of propofol. Someone with medical knowledge or experience would have started the IV. Anyone could have drawn up and administered the medications after the IV was started.

What is an anesthesiologist's view point on the toxicology screen results? The levels of propofol found on toxicology exam are similar to those found during general anesthesia for major surgery (intra-abdominal) with propofol infusions, after a bolus induction. During major surgery, a patient with these blood levels of propofol would be intubated and ventilated by an anesthesiologist, and any cardiovascular depression would be noted and treated.

Anesthesiologists would also comment on the presence of other sedative drugs in the toxicology screen. Lorazepam, a long-acting benzodiazepine, is present at a pharmacologically significant level and would have accentuated the respiratory and cardiovascular depression from propofol.

Selma Calmes MD
Selma Calmes MD
Anesthesiology Consultant

Date

08/03/2009

13CC #2009-04415
JACKSON, Michael Joseph**RADIOLOGY CONSULT****REQUEST:**

The decedent is a 50 year old black man who died unexpectedly. Please examine for trauma or natural disease.

FILMS:

Whole body radiographic survey—Adult

FINDINGS:

The two views of the skull demonstrate metallic dental “caps” of several right mandibular teeth (pre-molar/molar) with appropriate post operative dental changes, and at least 2 implanted left mandibular dental prostheses (pre-molar/molar). The nasal bones are obscured by overlying cranial and facial structures. The remainder of the craniofacial skeletal structures are unremarkable. An endotracheal tube is in place.

There are no visible significant thoracic skeletal abnormalities other than minimal degenerative spondylosis at T11/12. A small right C7 cervical rib is present. An iatrogenic device with a linear metallic marker is present overlying the left thoracic parasagittal region consistent with a known aortic balloon pump, with the tip located at T6. The superficial soft tissues are unremarkable.

The abdomen and pelvis are unremarkable except for the presence of iatrogenic catheters consistent with femoral vascular catheters as well as the abdominopelvic portion of the aortic balloon pump and what appears to be mild degenerative osteoarthritis of the lumbar spine facet joints at L4/5 and L5-S1.

The right upper extremity is unremarkable, except for probable mild degenerative osteoarthritis of the DIP joints of the index and long fingers. A small portion of the mid right upper extremity (including the proximal third of the forearm) is not included on the films.

The left upper extremity is unremarkable except for moderate degenerative osteoarthritis of the DIP joint of the little finger.

The skeletal and articular structures of the right lower extremity are unremarkable. Incidentally noted is a thin 5 cm. long calcific collection in the posterior mid to distal leg consistent with atherosclerotic arterial calcification.

13**RADIOLOGY CONSULT**CC #2009-04415
JACKSON, Michael Joseph

Page 2 of 2

The skeletal structures of the left lower extremity are unremarkable. Incidentally noted is a thin 2 cm. long calcific density in the posterior distal leg consistent with calcified arterial atherosclerosis (found at the same level as the ID marker band placed about the lower left leg). There is additional minimal calcified arterial atherosclerotic calcification approximately 1.5 cm distal to the larger calcification.

IMPRESSION:

1. Right mandibular pre-molar/molar metallic "caps" with appropriate post-operative changes.
2. Two (2) mandibular pre-molar/molar implanted dental prostheses.
3. Minimal degenerative spondylosis of the lower thoracic spine.
4. Right C7 cervical rib
5. Vascular iatrogenic devices are in place.
6. Mild degenerative osteoarthritis of the lower lumbar spine facet joints.
7. Probable mild degenerative osteoarthritis of the DIP joints of the right index and long fingers.
8. Moderate degenerative osteoarthritis of the DIP joint of the left little finger.
9. Mild calcified arterial atherosclerosis of both legs.

Donald C. Boger M.D.
DONALD C. BOGER, M.D.
RADIOLOGY CONSULTANT

7/2/09
Date

DCB/ecl
7/2/09

14

I performed a microscopic examination on →

July 20, 2009

2009-04415

at THE DEPARTMENT OF CORONER

JACKSON, MICHAEL J.

Los Angeles, California

MICROSCOPIC DESCRIPTION

The adrenal glands (slide A) are normal in size and structure. No significant inflammation is present.

A section of left pyriform recess (slide B) shows several submucosal nodules of lymphoid tissue with keratin material and neutrophils, consistent with tonsillar tissue (Waldeyer's ring). The mucosa is unremarkable.

Sections from the parathyroid region (slide C) show several small lymph nodes and a portion of ectopic salivary gland. A cystic area shows a thin rim of parathyroid tissue.

A section of thyroid gland (slide D) shows follicles of roughly uniform size with abundant colloid and low cuboidal epithelium. There is no significant inflammation. Special stains show the usual PAS-positive colloid. Iron is absent.

A section of periaortic mass just medial to the left adrenal gland (slide E) appears to be a sympathetic ganglion with normal ganglion cells.

The bone marrow (slide F) shows normal cellularity for age. All cell lines are present. A small lymphoid aggregate is noted.

Sections of heart (right ventricle, slide G; interventricular septum, slide I; left ventricle, slide J) show normal myocardial structure without significant inflammation. Coronary arteries show minimal atherosclerosis. Red cells do not show sickling.

The aorta (slide G) is without significant atherosclerosis or inflammation.

The pituitary gland (slide H) is unremarkable.

The right lung (slide K) shows scattered alveolar hemorrhage. See Dr. Sherwin's report.

14

2009-04415

JACKSON, MICHAEL J.

Page 2

The right (slide L) and left (slide M) testes show active spermatogenesis with the usual number of Leydig cells. There is no significant fibrosis or inflammation. The epididymides are unremarkable.

The stomach (slide N) shows recent hemorrhage into the mucosa, submucosa and muscularis. The mucosa is without ulceration or inflammation.

The gallbladder (slide N) is autolyzed.

The pancreas (slide O) shows a normal glandular structure without significant inflammation or fibrosis. Islets of Langerhans are normal in size and number.

A section of spleen (slide P) shows the usual follicular structure.

The liver (slide Q) is normal in structure. Hepatocytes show no inclusions or lipid droplets. There is no significant parenchymal necrosis or inflammation.

The right (slide R) and left (slide S) kidneys show glomeruli which are normal in number and structure. Tubular cells are unremarkable. There is no significant inflammation. The right pyramidal apex (slide R) shows focal interstitial fibrosis.

Sections of colon (slide T) show a pedunculated polyp consisting of benign colonic glands in a fibrous stroma. Abundant eosinophils are present. The adjacent colon is unremarkable.

Sections of skin (slide U) show no melanocytic pigment. Melanocytes, although present, are reduced in number. The skin is otherwise unremarkable. No scar or suture material is present.

The prostate gland (slide V) shows hyperplastic glands in a nodular configuration. Minimal lymphoid infiltrate is present. There is no malignancy.

14

2009-04415

JACKSON, MICHAEL J.

Page 3


Consultation is obtained with Dr. Chandrasoma, Professor of Pathology at USC Keck School of Medicine.

Diagnosis:

1. Colon, tubular adenoma
2. Vitiligo
3. Nodular prostatic hyperplasia
4. Evidence of resuscitation
 - A) Lung, alveolar hemorrhage
 - B) Stomach, transmural hemorrhage


CHRISTOPHER ROGERS, MD, MBA
CHIEF FORENSIC MEDICINE DIVISION

8-19-09
DATE


LAKSHMANAN SATHYAVAGISWARAN, MD
FRCP (C), FCAP, FACP
CHIEF MEDICAL EXAMINER-CORONER

8-19-09
DATE

CR:LS:mtm:f
T-7/29/09

15

AUTOPSY CLASS: A B C Examination Only D

FAMILY OBJECTION TO AUTOPSY

Date: 6-26-01 Time: 1000 Dr. Rogers/Lakshminarayanan
(Print)

FINAL ON: 8-7-01 By: Rogers/Lakshminarayanan
(Print)

APPROXIMATE
INTERVAL
BETWEEN
ONSET
AND
DEATH

DEATH WAS CAUSED BY: (Enter only one cause per line for A, B, C, and D)

IMMEDIATE CAUSE:

(A) Acute propofol intoxication

DUE TO, OR AS A CONSEQUENCE OF:

(B)

DUE TO, OR AS A CONSEQUENCE OF:

(C)

DUE TO, OR AS A CONSEQUENCE OF:

(D)

OTHER CONDITIONS CONTRIBUTING BUT NOT RELATED TO THE IMMEDIATE CAUSE OF DEATH:

Benzodiazepine effect

- NATURAL
- SUICIDE
- HOMICIDE
- ACCIDENT
- COULD NOT BE DETERMINED

If other than natural causes,
HOW DID INJURY OCCUR?

Intravenous injection by another

WAS OPERATION PERFORMED FOR ANY CONDITION STATED ABOVE: YES NO

TYPE OF SURGERY: _____ DATE: _____

ORGAN PROCUREMENT TECHNICIAN: Sanchez / Delacorte

PREGNANCY IN LAST YEAR YES NO UNK NOT APPLICABLE

WITNESS TO AUTOPSY EVIDENCE RECOVERED AT AUTOPSY
Item Description:

Det Smith, LAPD
Photo memory
card given to
Capt. Keadles

RESIDENT

DME

Age: 30 Gender: Male / Female

PRIOR EXAMINATION REVIEW BY DME

- BODY TAGS CLOTHING
- X-RAY (No. _____) FLUORO
- SPECIAL PROCESSING TAG MED. RECORDS
- AT SCENE PHOTOS (No. _____)

CASE CIRCUMSTANCES

- EMBALMED
- DECOMPOSED
- >24 HRS IN HOSPITAL
- OTHER: _____ (Reason)

TYPING SPECIMEN

TYPING SPECIMEN TAKEN BY: CR
SOURCE: Femoral

TOXICOLOGY SPECIMEN

- COLLECTED BY: CR
- HEART BLOOD STOMACH CONTENTS
 - FEMORAL BLOOD Keim VITREOUS
 - TECHNIQUE Ant. punct.
 - _____ BLOOD SPLEEN
 - _____ BLOOD KIDNEY
 - BILE _____
 - LIVER _____
 - URINE (3) _____

URINE GLUCOSE DIPSTICK RESULT: 4+ 3+ 2+ 1+ 0

TOX SPECIMEN RECONCILIATION BY: CR

HISTOLOGY

Regular (No. 2) Oversize (No. 1)
Histopath Cut: Autopsy Lab (L. H. H.)

TOXICOLOGY REQUESTS

- FORM 3A: YES NO
- NO TOXICOLOGY REQUESTED
 - SCREEN C H T S D
 - ALCOHOL ONLY
 - CARBON MONOXIDE
 - OTHER (Specify drug and tissue)

REQUESTED MATERIAL ON PENDING CASES

- POLICE REPORT MED HISTORY
- TOX FOR COD HISTOLOGY
- TOX FOR R/O INVESTIGATIONS
- MICROBIOLOGY EYE PATH. CONS.
- RADIOLOGY CONS.
- CONSULT ON _____
- BRAIN SUBMITTED
- NEURO CONSULT DME TO CUT
- CRIMINALISTICS
- GSR SEXUAL ASSAULT OTHER

[Handwritten signatures]

AUTOPSY CHECK SHEET

16

EXTERNAL EXAM

Sex Male
Race Black
Age 40
Height 6'9"
Weight 136
Hair Brown
Eyes Brown
Sclera
Teeth
Mouth
Tongue
Nose
Chest - Central abrasion
Breasts
Abdomen
Scar - See findings
Genital
Edema
Skin
Decub
HEART Wt. 290
Pericard
Hypert
Dilat
Muscle
Valves
Coronar

RV 0.2
LV 1.4
Septum
RV 12.8
PV 7.0
AV 3.8
AV 7.2

AORTA

VESSELS

LUNGS Wt

R 940
L 1060 - sent to pulmonary path
Adhes
Fluid
Atelectasis
Oedema
Congest
Consol
Bronchi
Nodes

PHARYNX

TRACHEA

THYROID

THYMUS

LARYNX

HYOID

ABDOMINAL WALL FAT

PERITONEUM

Fluid
Adhes

LIVER Wt 480

Caps
Lobul
Fibros
G B 10 gm bile
Calc
Bile ducts

SPLEEN Wt 110

Color
Consist
Caps
Malpig

PANCREAS

ADRENALS

KIDNEYS Wt

R 140 - 0.2 cm nodular mass
L 120
Caps
Cortex
Vessels
Pelvis
Ureter

BLADDER

GENITALIA

Prost - prominent
Testes - normal
Uterus
Tubes
Ovar

OESOPHAGUS

STOMACH

Contents 70g. n. cl. fluid

DUOD & SM INT

APPENDIX

LARGE INT

ABDOM NODES

SKELETON

Spine
Marrow
Rib Cage
Long bones
Pelvis
Fracture of sternum, 4th rib, L 3, 4, 5, 6, 7, 8, 9, 10, 11, 12, 13, 14, 15, 16, 17, 18, 19, 20, 21, 22, 23, 24, 25, 26, 27, 28, 29, 30, 31, 32, 33, 34, 35, 36, 37, 38, 39, 40, 41, 42, 43, 44, 45, 46, 47, 48, 49, 50, 51, 52, 53, 54, 55, 56, 57, 58, 59, 60, 61, 62, 63, 64, 65, 66, 67, 68, 69, 70, 71, 72, 73, 74, 75, 76, 77, 78, 79, 80, 81, 82, 83, 84, 85, 86, 87, 88, 89, 90, 91, 92, 93, 94, 95, 96, 97, 98, 99, 100

SCALP

CALVARIUM

BRAIN Wt 1380

Dura
Fluid
Ventric
Vessels
Middle ears
Other

PITUITARY

SPINAL CORD

TOXICOLOGY SPECIMENS

Blood, urine, bile, liver, vitreous, stomach contents

SECTIONS FOR HISTOPATHOLOGY

2 skull base, see slide box

MICROBIOLOGY

DIAGRAMS 20, 22

X-RAYS full body

OTHER PROCEDURES

1. Lung to pulmonary pathology

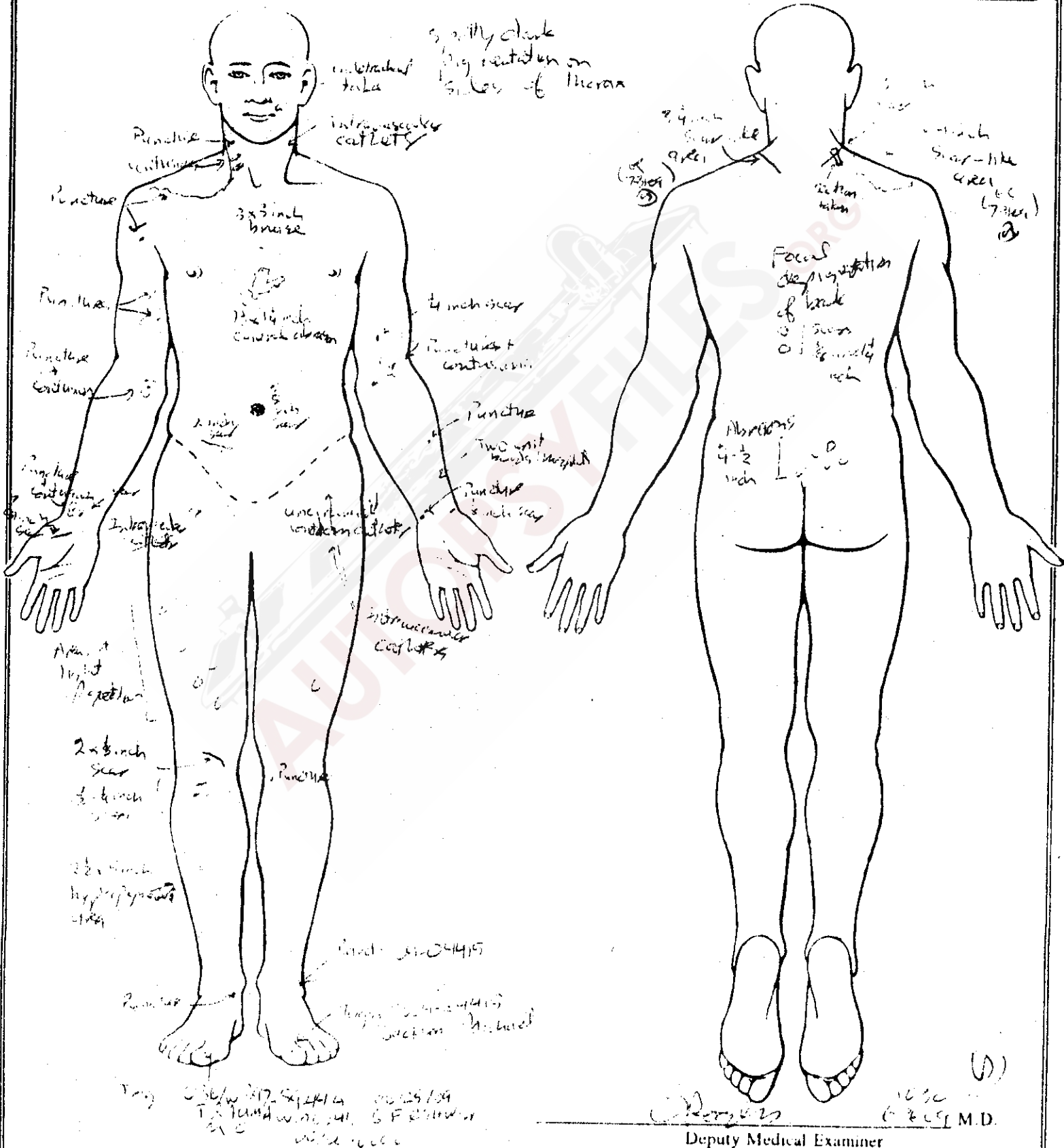
GROSS IMPRESSIONS

1. Normal heart & lungs
2. Normal brain
3. Normal stomach & intestines
4. Normal kidneys
5. Normal liver & spleen
6. Normal testes & ovaries
7. Normal bones & joints
8. Normal skin & soft tissue
9. Normal thyroid & parathyroids
10. Normal thymus & lymph nodes

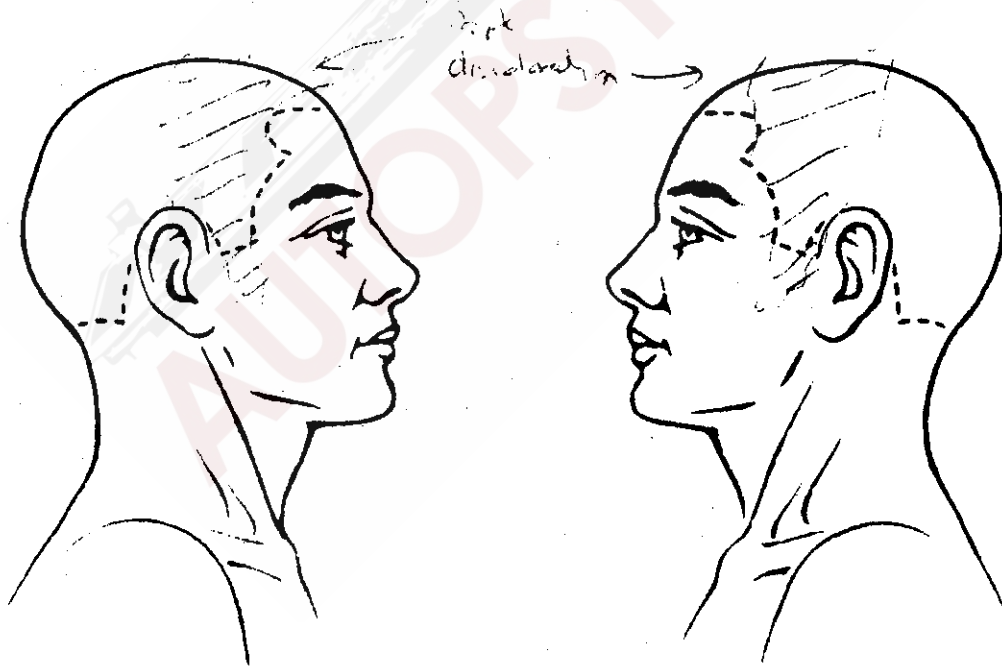
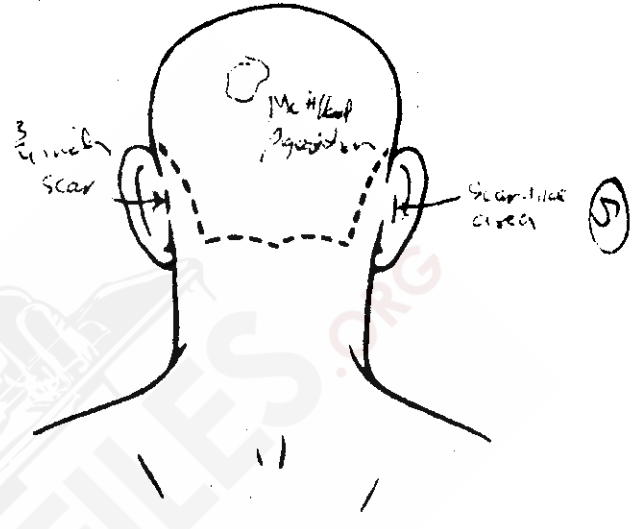
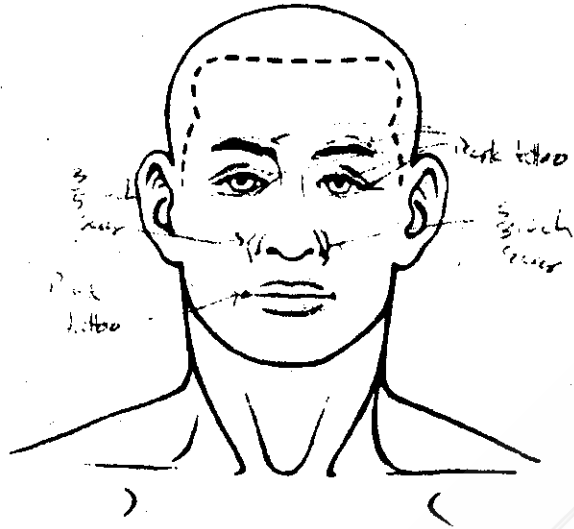
Date: 6-26-09 Time: 1300 Deputy Medical Examiner: [Signature]

20

S.C



22



1030
 6-26-09 [Signature] M.D.
 Deputy Medical Examiner



Department of Coroner, County of Los Angeles
FORENSIC SCIENCE LABORATORIES
 Laboratory Analysis Summary Report



Wednesday, July 15, 2009

To: Dr. Rogers
 Deputy Medical Examiner

✓ Pending Tox

Subject: Coroner Case Number 2009-04415 JACKSON, MICHAEL JOSEPH

The following results have been technically and administratively reviewed and are the opinions and interpretations of the Analyst:

<u>SPECIMEN</u>	<u>SERVICE</u>	<u>DRUG</u>	<u>LEVEL</u> <u>UNITS</u>	<u>ANALYST</u>
Blood, Femoral				
	Bases	Lidocaine	0.84 ug/ml	E. Fu
	Benzodiazepines	Lorazepam	169 ng/ml	S. DeQuintana
	Propofol	Propofol	2.6 ug/ml	J. Lintemoot
Blood, Heart				
	Acetaminophen	Acetaminophen	ND	J. Lintemoot
	Alcohol	Ethanol	Negative	M. Schuchardt
	Barbiturate	Barbiturates	ND	D. Anderson
	Bases	Lidocaine	0.68 ug/ml	E. Fu
	Bases	Meperidine	ND	E. Fu
	Bases	Normeperidine	ND	E. Fu
	Bases	Norsertaline	ND	E. Fu
	Bases	Sertraline	ND	E. Fu
	Bases	Trazodone	ND	E. Fu
	Benzodiazepines	Alprazolam	ND	R. Budd
	Benzodiazepines	Diazepam	<0.10 ug/ml	S. DeQuintana
	Benzodiazepines	Lorazepam	162 ng/ml	S. DeQuintana
	Benzodiazepines	Midazolam	4.6 ng/ml	R. Budd

NOTE: Hospital, Blood: Tube labeled "Trauma, Gershwin" drawn on 06/25/09 @ 1330 hours.

Urine*: Approximately 450 mls of urine collected from scene by Inv. E. Fleak.

*Done: See Form 13, Medical Evidence Analysis Summary Report.

Legend:

ug/g	Microgram per Gram
ug/ml	Microgram per Milliliter

%	of total Hgb
% Saturation	
Done	
mg	Milligram
ND	Not Detected
Negative	
ng/ml	Nanogram per Milliliter
Present	

Administratively reviewed by: Daniel T. Anderson
 Supervising Criminalist II
 FORENSIC LABORATORIES

Page 1 of 8



Department of Coroner, County of Los Angeles
FORENSIC SCIENCE LABORATORIES
 Laboratory Analysis Summary Report



Wednesday, July 15, 2009

To: Dr. Rogers
 Deputy Medical Examiner

Pending Tox

Subject: Coroner Case Number 2009-04415 JACKSON, MICHAEL JOSEPH

The following results have been technically and administratively reviewed and are the opinions and interpretations of the Analyst:

<u>SPECIMEN</u>	<u>SERVICE</u>	<u>DRUG</u>	<u>LEVEL</u>	<u>UNITS</u>	<u>ANALYST</u>
	Benzodiazepines	Nordiazepam	<0.05	ug/ml	S. DeQuintana
	Benzodiazepines	Zaleplon	ND		R. Budd
	Carbon Monoxide	Carbon Monoxide	<10	% Saturation	D. Anderson
	Cocaine	Cocaine and Metabolites	ND		D. Anderson
	Cyanide	Cyanide	ND		M. Schuchardt
	Fentanyl	Fentanyl	ND		D. Anderson
	GC/MS	Tizanidine	ND		S. DeQuintana
	Halogenated Hydrocarbons	Ethchlorvynol	ND		R. Budd
	Halogenated Hydrocarbons	Trichlorethanol	ND		R. Budd
	LC/MS	7-Aminoclonazepam	ND		J. Lintemoot
	LC/MS	Clonazepam	ND		J. Lintemoot
	LC/MS	Oxazepam	ND		J. Lintemoot
	LC/MS	Temazepam	ND		J. Lintemoot
	Marijuana	Carboxy-THC	ND		D. Anderson
	Methamphetamine	Amphetamine	ND		O. Pleitez
	Methamphetamine	Ephedrine	ND		O. Pleitez
	Methamphetamine	Methamphetamine	ND		O. Pleitez
	Neutrals	Propofol	Present		D. Anderson

NOTE: Hospital, Blood: Tube labeled "Trauma, Gershwin" drawn on 06/25/09 @ 1330 hours.

Urine*: Approximately 450 mls of urine collected from scene by Inv. E. Fleak.

*Done: See Form 13, Medical Evidence Analysis Summary Report.

Legend:

ug/g	Microgram per Gram
ug/ml	Microgram per Milliliter

%	of total Hgb
% Saturation	
Done	
mg	Milligram
ND	Not Detected
Negative	
ng/ml	Nanogram per Milliliter
Present	

Administratively reviewed by: Daniel T. Anderson
 Supervising Criminalist II
 FORENSIC LABORATORIES



Department of Coroner, County of Los Angeles
FORENSIC SCIENCE LABORATORIES
 Laboratory Analysis Summary Report



Wednesday, July 15, 2009

✓ Pending Tox

To: Dr. Rogers
 Deputy Medical Examiner

Subject: Coroner Case Number 2009-04415 JACKSON, MICHAEL JOSEPH

The following results have been technically and administratively reviewed and are the opinions and interpretations of the Analyst:

<u>SPECIMEN</u>	<u>SERVICE</u>	<u>DRUG</u>	<u>LEVEL</u>	<u>UNITS</u>	<u>ANALYST</u>
	Opiates	Codeine		ND	D. Anderson
	Opiates	Hydrocodone		ND	D. Anderson
	Opiates	Hydromorphone		ND	D. Anderson
	Opiates	Morphine		ND	D. Anderson
	Outside Test	Hemoglobin A1C	5.1	%	Quest Diagnostics
	Oxycodone	Oxycodone		ND	S. DeQuintana
	Phencyclidine	Phencyclidine		ND	D. Anderson
	Propofol	Propofol	3.2	ug/ml	J. Lintemoot
	Salicylate	Salicylate		ND	J. Lintemoot

Blood, Hospital

	Acetaminophen	Acetaminophen		ND	J. Lintemoot
	Barbiturate	Barbiturates		ND	J. Lintemoot
	Bases	Diazepam		Present	E. Fu
	Bases	Lidocaine	0.51	ug/ml	E. Fu
	Bases	Meperidine		ND	E. Fu
	Bases	Norperidine		ND	E. Fu
	Bases	Norsertaline		ND	E. Fu
	Bases	Sertraline		ND	E. Fu

NOTE: Hospital, Blood: Tube labeled "Trauma, Gershwin" drawn on 06/25/09 @ 1330 hours.

Urine*: Approximately 450 mls of urine collected from scene by Inv. E. Fleak.

*Done: See Form 13, Medical Evidence Analysis Summary Report.

Legend:

ug/g	Microgram per Gram
ug/ml	Microgram per Milliliter

%	of total Hgb
% Saturation	
Done	
mg	Milligram
ND	Not Detected
Negative	
ng/ml	Nanogram per Milliliter
Present	

Administratively reviewed by: *D. Anderson*
 Daniel T. Anderson
 Supervising Criminalist II
 FORENSIC LABORATORIES



Department of Coroner, County of Los Angeles
FORENSIC SCIENCE LABORATORIES
 Laboratory Analysis Summary Report



Wednesday, July 15, 2009

To: Dr. Rogers
 Deputy Medical Examiner

 Pending Tox

Subject: Coroner Case Number 2009-04415 JACKSON, MICHAEL JOSEPH

The following results have been technically and administratively reviewed and are the opinions and interpretations of the Analyst:

<u>SPECIMEN</u>	<u>SERVICE</u>	<u>DRUG</u>	<u>LEVEL</u>	<u>UNITS</u>	<u>ANALYST</u>
	Bases	Trazodone		ND	E. Fu
	Cocaine	Cocaine and Metabolites		ND	J. Lintemoot
	Fentanyl	Fentanyl		ND	J. Lintemoot
	LC/MS	7-Aminoclonazepam		ND	J. Lintemoot
	LC/MS	Clonazepam		ND	J. Lintemoot
	LC/MS	Oxazepam		ND	J. Lintemoot
	LC/MS	Temazepam		ND	J. Lintemoot
	Marijuana	Carboxy-THC		ND	J. Lintemoot
	Methamphetamine	Methamphetamine		ND	J. Lintemoot
	Opiates	Codeine		ND	J. Lintemoot
	Opiates	Hydrocodone		ND	J. Lintemoot
	Opiates	Hydromorphone		ND	J. Lintemoot
	Opiates	Morphine		ND	J. Lintemoot
	Phencyclidine	Phencyclidine		ND	J. Lintemoot
	Propofol	Propofol	4.1	ug/ml	J. Lintemoot
	Salicylate	Salicylate		ND	J. Lintemoot
Liver	Bases	Lidocaine	0.45	ug/g	E. Fu

NOTE: Hospital, Blood: Tube labeled "Trauma, Gershwin" drawn on 06/25/09 @ 1330 hours.

Urine*: Approximately 450 mls of urine collected from scene by Inv. E. Fleak.

*Done: See Form 13, Medical Evidence Analysis Summary Report.

Legend:

.....	ug/g	Microgram per Gram
.....	ug/ml	Microgram per Milliliter
%		of total Hgb
% Saturation		
Done		
mg		Milligram
ND		Not Detected
Negative		
ng/ml		Nanogram per Milliliter
Present		

Administratively reviewed by: Daniel T. Anderson
 Supervising Criminalist II
 FORENSIC LABORATORIES



Department of Coroner, County of Los Angeles
FORENSIC SCIENCE LABORATORIES
 Laboratory Analysis Summary Report



Wednesday, July 15, 2009

To: Dr. Rogers
 Deputy Medical Examiner

✓ Pending Tox

Subject: Coroner Case Number 2009-04415 JACKSON, MICHAEL JOSEPH

The following results have been technically and administratively reviewed and are the opinions and interpretations of the Analyst:

<u>SPECIMEN</u>	<u>SERVICE</u>	<u>DRUG</u>	<u>LEVEL</u>	<u>UNITS</u>	<u>ANALYST</u>
	Propofol	Propofol	6.2	ug/g	J. Lintemoot
Medical Evidence					
	Medical Evidence	-----	* Done		J. Lintemoot
Stomach Contents					
	Bases	Lidocaine	1.6	mg	E. Fu
	Propofol	Propofol	0.13	mg	J. Lintemoot
Urine					
	"Dipstick"	Glucose	Negative		J. Muto
	Acetaminophen	Acetaminophen	ND		J. Lintemoot
	Alcohol	Ethanol	Negative		M. Schuchardt
	Barbiturate	Barbiturates	ND		D. Anderson
	Bases	Lidocaine	Present		E. Fu
	Bases	Meperidine	ND		E. Fu
	Bases	Normeperidine	ND		E. Fu
	Bases	Norsertaline	ND		E. Fu
	Bases	Sertraline	ND		E. Fu
	Bases	Trazodone	ND		E. Fu
	Benzodiazepines	Alprazolam	ND		R. Budd

NOTE: Hospital, Blood: Tube labeled "Trauma, Gershwin" drawn on 06/25/09 @ 1330 hours.

Urine*: Approximately 450 mls of urine collected from scene by Inv. E. Fleak.

*Done: See Form 13, Medical Evidence Analysis Summary Report.

Legend:

ug/g	Microgram per Gram
ug/ml	Microgram per Milliliter

%	of total High
% Saturation	
Done	
mg	Milligram
ND	Not Detected
Negative	
ng/ml	Nanogram per Milliliter
Present	

Administratively reviewed by: Daniel T. Anderson
 Supervising Criminalist II
 FORENSIC LABORATORIES



Department of Coroner, County of Los Angeles
FORENSIC SCIENCE LABORATORIES
 Laboratory Analysis Summary Report



Wednesday, July 15, 2009

To: Dr. Rogers
 Deputy Medical Examiner

PendingTox

Subject: Coroner Case Number 2009-04415 JACKSON, MICHAEL JOSEPH

The following results have been technically and administratively reviewed and are the opinions and interpretations of the Analyst:

<u>SPECIMEN</u>	<u>SERVICE</u>	<u>DRUG</u>	<u>LEVEL</u>	<u>UNITS</u>	<u>ANALYST</u>
	Benzodiazepines	Midazolam	6.8	ng/ml	R. Budd
	Benzodiazepines	Zaleplon	ND		R. Budd
	Cocaine	Cocaine and Metabolites	ND		D. Anderson
	Fentanyl	Fentanyl	ND		D. Anderson
	Halogenated Hydrocarbons	Ethchlorvynol	ND		R. Budd
	Halogenated Hydrocarbons	Trichlorethanol	ND		R. Budd
	Marijuana	Carboxy-THC	ND		B. Waters
	Marijuana	Tetrahydrocannabinol (THC)	ND		B. Waters
	Methamphetamine	Amphetamine	ND		O. Pleitez
	Methamphetamine	Ephedrine	Present		O. Pleitez
	Methamphetamine	Methamphetamine	ND		O. Pleitez
	Neutrals	Propofol	Present		D. Anderson
	Opiates	Codeine	ND		D. Anderson
	Opiates	Hydrocodone	ND		D. Anderson
	Opiates	Hydromorphone	ND		D. Anderson
	Opiates	Morphine	ND		D. Anderson
	Oxycodone	Oxycodone	ND		S. DeQuintana
	Phencyclidine	Phencyclidine	ND		D. Anderson

NOTE: Hospital, Blood: Tube labeled "Trauma, Gershwin" drawn on 06/25/09 @ 1330 hours.

Urine*: Approximately 450 mls of urine collected from scene by Inv. E. Fleak.

*Done: See Form 13, Medical Evidence Analysis Summary Report.

Legend: ug/g Microgram per Gram
 ug/ml Microgram per Milliliter

.....
 % of total Hgb

% Saturation

Done

mg Milligram

ND Not Detected

Negative

ng/ml Nanogram per Milliliter

Present

Administratively reviewed by: Daniel T. Anderson
 Supervising Criminalist II

FORENSIC LABORATORIES

Page 6 of 8



Department of Coroner, County of Los Angeles
FORENSIC SCIENCE LABORATORIES
 Laboratory Analysis Summary Report



Wednesday, July 15, 2009

To: Dr. Rogers
 Deputy Medical Examiner

 Pending Tox

Subject: Coroner Case Number 2009-04415 JACKSON, MICHAEL JOSEPH

The following results have been technically and administratively reviewed and are the opinions and interpretations of the Analyst:

<u>SPECIMEN</u>	<u>SERVICE</u>	<u>DRUG</u>	<u>LEVEL</u>	<u>UNITS</u>	<u>ANALYST</u>
	Propofol	Propofol	0.15	ug/ml	J. Lintemoot
	Salicylate	Salicylate		ND	J. Lintemoot
Urine*	"Dipstick"	Glucose		Negative	J. Muto
	Acetaminophen	Acetaminophen		ND	J. Lintemoot
	Alcohol	Ethanol		Negative	M. Schuchardt
	Barbiturate	Barbiturates		ND	D. Anderson
	Bases	Lidocaine		Present	E. Fu
	Bases	Meperidine		ND	E. Fu
	Bases	Normeperidine		ND	E. Fu
	Bases	Norsertaline		ND	E. Fu
	Bases	Sertraline		ND	E. Fu
	Bases	Trazodone		ND	E. Fu
	Benzodiazepines	Alprazolam		ND	R. Budd
	Benzodiazepines	Midazolam	25	ng/ml	R. Budd
	Benzodiazepines	Zaleplon		ND	R. Budd
	Cocaine	Cocaine and Metabolites		ND	D. Anderson
	Fentanyl	Fentanyl		ND	D. Anderson

NOTE: Hospital, Blood: Tube labeled "Trauma, Gershwin" drawn on 06/25/09 @ 1330 hours.

Urine*: Approximately 450 mls of urine collected from scene by Inv. E. Fleak.

*Done: See Form 13, Medical Evidence Analysis Summary Report.

Legend:

-----		ug/g	Microgram per Gram
		ug/ml	Microgram per Milliliter
%	of total Hgb		
% Saturation			
Done			
mg	Milligram		
ND	Not Detected		
Negative			
ng/ml	Nanogram per Milliliter		
Present			

Administratively reviewed by: Daniel T. Anderson
 Supervising Criminalist II
 FORENSIC LABORATORIES

Page 7 of 8



Department of Coroner, County of Los Angeles
FORENSIC SCIENCE LABORATORIES
 Laboratory Analysis Summary Report



Wednesday, July 15, 2009

✓ Pending Tox

To: Dr. Rogers
 Deputy Medical Examiner

Subject: Coroner Case Number 2009-04415 JACKSON, MICHAEL JOSEPH

The following results have been technically and administratively reviewed and are the opinions and interpretations of the Analyst:

<u>SPECIMEN</u>	<u>SERVICE</u>	<u>DRUG</u>	<u>LEVEL</u>	<u>UNITS</u>	<u>ANALYST</u>
	Marijuana	Carboxy-THC		ND	B. Waters
	Marijuana	Tetrahydrocannabinol (THC)		ND	B. Waters
	Methamphetamine	Amphetamine		ND	O. Pleitez
	Methamphetamine	Ephedrine		Present	O. Pleitez
	Methamphetamine	Methamphetamine		ND	O. Pleitez
	Opiates	Codeine		ND	D. Anderson
	Opiates	Hydrocodone		ND	D. Anderson
	Opiates	Hydromorphone		ND	D. Anderson
	Opiates	Morphine		ND	D. Anderson
	Oxycodone	Oxycodone		ND	S. DeQuintana
	Phencyclidine	Phencyclidine		ND	D. Anderson
	Propofol	Propofol	<0.10	ug/ml	J. Lintemoot
	Salicylate	Salicylate		ND	O. Pleitez
Vitreous	Propofol	Propofol	<0.40	ug/ml	J. Lintemoot

NOTE: Hospital, Blood: Tube labeled "Trauma, Gershwin" drawn on 06/25/09 @ 1330 hours.
 Urine*: Approximately 450 mls of urine collected from scene by Inv. E. Fleak.
 *Done: See Form 13, Medical Evidence Analysis Summary Report.

Legend:

ug/g	Microgram per Gram
ug/ml	Microgram per Milliliter

 % of total Hgb
 % Saturation
 Done
 mg Milligram
 ND Not Detected
 Negative
 ng/ml Nanogram per Milliliter
 Present

Administratively reviewed by: Daniel T. Anderson
 Supervising Criminalist II
 FORENSIC LABORATORIES

13

2009-04415
Jackson, Michael

**Los Angeles County Department of Coroner
Forensic Science Laboratories
Medical Evidence Analysis Summary Report**

Medical Evidence #1 (collected by Coroner Investigator E. Fleak on 6/26/09)

- Propofol and Lidocaine were detected in approximately 0.19g of white fluid from a 10cc syringe barrel with plunger.

Medical Evidence #2 (collected by Coroner Investigator E. Fleak on 6/29/09)

- 4 components of an IV system tested.
 - Propofol, Lidocaine, and Flumazenil were detected in approximately 0.17g of white tinted fluid from a 10cc syringe.
 - Propofol, Lidocaine, and Flumazenil were detected in approximately 0.47g of yellow tinted fluid from a short section of IV tubing attached to a Y connector.
 - No drugs were detected in approximately 17g of clear liquid from a long section of IV tubing attached to an IV bag plug.
 - No drugs were detected in approximately 0.38g of clear fluid from a 1000cc IV bag.

Jaime Lintemoot
Jaime Lintemoot
Senior Criminalist

7/15/09
Date



SUMMARY of POSITIVE TOXICOLOGICAL FINDINGS
2009-04415 - Jackson, Michael Joseph



Drug	Specimen (ug/ml or ug/g)							
	Heart Blood	Hospital Blood	Femoral Blood	Vitreous	Liver	Gastric Contents	Urine	Urine-Scene
Propofol	3.2	4.1	2.6	<0.40	6.2	0.13 mg	0.15	<0.10
Lidocaine	0.68	0.51	0.84	---	0.45	1.6 mg	Present	Present
Diazepam	<0.10	Present	---	---	---	---	---	---
Nordiazepam	<0.05	---	---	---	---	---	---	---
Lorazepam	0.162	---	0.169	---	---	---	---	---
Midazolam	0.0046	---	---	---	---	---	0.0068	0.025
Ephedrine	ND	---	---	---	---	---	Present	Present

D. Anderson
 Supervising Criminalist II
 7/15/09

UJ
 02-2-09

13

2009-04415
Jackson, Michael

**Forensic Science Laboratories
Los Angeles County Department of Coroner
Criminalist Report**

Investigating Agency: Los Angeles Police Department
Investigating Officer: Detectives Orlando Martinez, Dan Myers, and Scott Smith

On August 6, 2009 at approximately 1300 hours, I was notified by Chief of Laboratories Joseph Muto that a Coroner Criminalist was requested to collect hair samples from the above listed decedent for potential toxicology testing. The decedent had been to the hospital, autopsied on two separate occasions, and handled by mortuary staff prior to my involvement. The decedent would be under the jurisdiction of the decedent's family and the mortuary during evidence collection.

Coroner Chief of Operations Craig Harvey, Forensic Technician II Jose Hernandez, and I arrived at the Glendale branch of Forest Lawn Memorial Park, Glendale at 1745 hours. Forest Lawn personnel, Darryl Drabing, escorted us to a waiting room while preparations were made for viewing the decedent. At 1835 hours we were permitted to view the decedent in a secured lobby area. Those present included Forest Lawn personnel D. Drabing and Scott Drolet, family member La Toya Jackson and her male companion, and the above mentioned coroner personnel.

At approximately 1840 hours I conducted a limited examination of a decedent supine in a yellow casket with blue lining. The majority of the decedent was covered with multiple white towels/sheets leaving only the hands and top of the head exposed. The top of the decedent's head was covered in a wig with long, dark apparent hair. Moving the wig revealed short, dark, curly, natural hair in the temporal regions measuring approximately one and a half inches in length. An unknown dark residue was present on the natural hair. The hair in the parietal region was sparse and covered in an unknown clear adhesive material. Hair samples were collected by plucking with gloved hands. Hernandez took photographs of the hair collection process.

The following items of evidence were collected at the mortuary:

Physical Evidence (PE)

- Hair Samples (packaged in small PE envelope)
 - Hair Samples from Left Temporal Region (packaged in aluminum foil and paper bindle)
 - Hair Samples from Right Temporal Region (packaged in aluminum foil and paper bindle)

Evidence Collection was completed at the mortuary on August 6, 2009 at 1920 hours.

Evidence was sealed at the Forensic Science Center (FSC) on August 6, 2009 at 1950 hours and placed in a secured storage locker.

Jaime Linternoot
Jaime Linternoot
Senior Criminalist

8/13/09
Date Written

9/9/09
Date Finalized