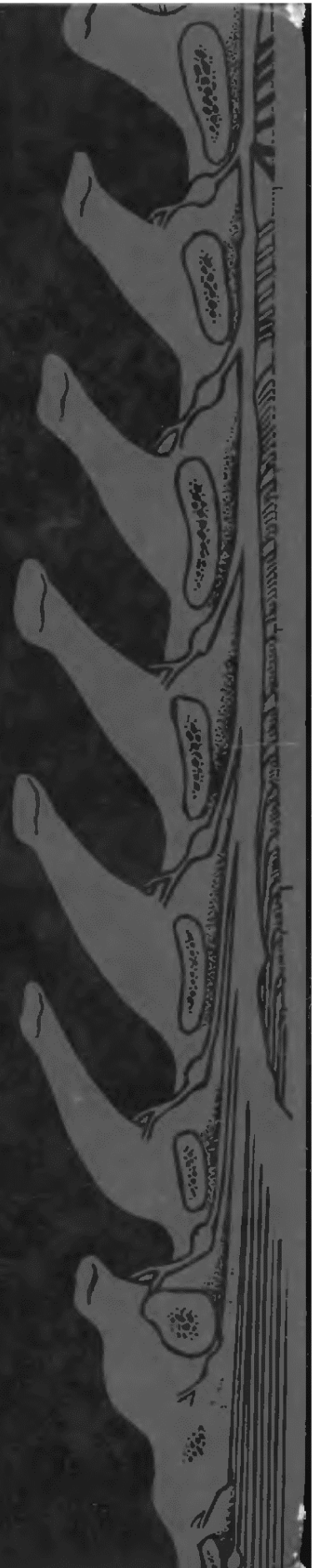


Handbook of Small Animal Spinal Surgery

N. D. Jeffery



Handbook of Small Animal Spinal Surgery

N.D. Jeffery

*Animal Health
Trust,
Newmarket, UK*

Present address:
*University of Cambridge,
Cambridge, UK*

**with a contribution from
T.G. Yarrow
*Citivet, London, UK***

W.B. Saunders Company Ltd

LONDON PHILADELPHIA TORONTO SYDNEY TOKYO

W.B. Saunders 24-28 Oval Road
Company Ltd London NW1 7DX, UK
Baillière Tindall

The Curtis Center
Independence Square West
Philadelphia, PA 19106-3399, USA

55 Horner Avenue
Toronto, Ontario M8Z 4X6, Canada

Harcourt Brace & Company
(Australia) Pty Ltd
30-52 Smidmore Street
Marrickville, NSW 2204, Australia

Harcourt Brace Japan
Ichibancho Central Building
22-1 Ichibancho
Chiyoda-ku, Tokyo 102, Japan

© 1995 W.B. Saunders Company Ltd

All rights reserved. No part of this publication may be reproduced, stored in a retrieval system or transmitted, in any form or by any means, electronic, mechanical, photocopying or otherwise, without the prior permission of W.B. Saunders Company Ltd, 24-28 Oval Road, London NW1 7DX, UK

A catalogue record for this book is available from the British Library

ISBN 0-7020-1688-8

This book is printed on acid-free paper

Typeset by J&L Composition Ltd, Filey, North Yorkshire
Printed and bound in Great Britain by Butler and Tanner, Frome

Contents

Preface	ix
Acknowledgements	xi
Chapter 1: Instrumentation	
Guest chapter by T.G. Yarrow	
Introduction	1
Diagnostic equipment	1
Operating room	3
Haemostatic agents	6
Orthopaedic instrumentation	7
Chapter 2: Anatomy	
^ Introduction	9
Vertebral column	10
Intervertebral joints	14
Ligaments of the vertebral column	16
Anatomy of the spinal cord	18
Associated reading	23
Chapter 3: Investigation of Spinal Disease	
Introduction	24
History	24
Physical examination	26
Neurological examination	27
Localization of lesions	41
Associated reading	43
Chapter 4: Ancillary Aids	
Introduction	45
Blood sampling	45
Radiography	46
Other imaging techniques	57
Cerebrospinal fluid (CSF) analysis	60
Electrodiagnostics	61
Associated reading	61
Chapter 5: Pathophysiology of Spinal Cord Injury	
Introduction	64

Pathophysiology of acute spinal cord injury	64
Secondary injury mechanisms	65
Pathophysiology of chronic (compressive) cord injury	69
Associated reading	70
Chapter 6: Anatomical Anomalies and Congenital Lesions	
Introduction	72
Disorders of the vertebral column	72
Anomalies of the spinal cord	80
Associated reading	83
Chapter 7: Degenerative Conditions	
Degenerative disorders of the vertebral column	85
Degenerative conditions of the spinal cord	105
Associated reading	108
Chapter 8: Fractures, Luxations and External Trauma to the Vertebral column	
Introduction	111
Reduction methods	114
Methods of surgical fixation of spinal fracture/luxations	115
Bullets/pellets	123
Hyperextension, 'traumatic discs' and cord concussion	124
Conservative management of spinal fracture/luxations	126
Associated reading	127
Chapter 9: Tumours	
Introduction	128
Classification by location	129
Modes of therapy	136
Associated reading	136
Chapter 10: Inflammatory, Infectious and Vascular Disease	
Introduction	138
Vascular disease	138
Inflammatory and infectious disease	140
Associated reading	145
Chapter 11: Cervical Spinal Surgery	
Introduction	148
Cervical disc surgery	148
Fractures/subluxations	155
Neoplasia	163
Associated reading	166
Chapter 12: The 'Wobbler' Syndrome	
Introduction	169
Diagnosis	171

Differential diagnosis	176
Treatment	176
Prognosis	183
Associated reading	184
Chapter 13: Surgery of the Thoracolumbar Spine	
Introduction	187
Decompressive surgery	188
Prophylactic techniques	194
Fractures and luxations of the thoracolumbar segment	197
Other conditions of the thoracolumbar segment (T3–L3)	197
Neoplasia in the thoracolumbar segment	198
Associated reading	199
Chapter 14: Surgery of the Lumbosacral and Sacrocaudal Regions	
Introduction	202
Type I disc extrusions in the caudal lumbar region	203
Lumbosacral stenosis	204
Fractures and luxations	209
Neoplasia	212
Miscellaneous conditions	212
Associated reading	213
Chapter 15: Medical and Conservative Therapy	
Introduction	215
Antibiotic treatment of spinal disease	215
Corticosteroid therapy of spinal disease	217
Other treatments	219
Conservative therapy of mild disc-associated symptoms	220
Associated reading	221
Chapter 16: Postoperative Care and Physical Therapy	
Introduction	223
Pain	223
Recumbency	224
Management of incontinent animals	227
Physiotherapy	228
Associated reading	230
Index	231

Preface

In the past, small animal spinal surgery has often been regarded as a subsection of orthopaedics. This classification is unsatisfactory because the approach to diagnosis and treatment of a vertebral or spinal cord lesion must be different to the approach to a disorder of the appendicular skeleton. This difference arises because the most important structure to be treated in spinal disease is the neural tissue, i.e. the spinal cord and nerve roots; other considerations such as bone healing are secondary in importance. The consequence is that neurological examination is essential to determine diagnosis and prognosis. The response of the nervous system to injury differs markedly to that of the musculoskeletal system and must be considered when discussing prognosis.

Over the last 10 to 15 years there has been a vast expansion in the veterinary literature dealing with small animal spinal surgery. This book aims to provide an overview of this work, as well as information on diagnostic approaches and recent studies of the pathophysiology of spinal cord injury.

Two recent developments have been associated with the increased veterinary interest in spinal surgery: (i) newer non-ionic contrast media have rendered myelography (an essential prerequisite for most spinal surgery) a relatively safe procedure with good diagnostic yield, and, (ii) increased access to suitable surgical instrumentation.

Although these developments have meant that an increasing number of veterinarians are now inclined to carry out surgery on the vertebral column, many feel unsure of themselves when dealing with neurological problems. It is hoped that this book can serve as a general practitioner's guide to investigation of animals with spinal lesions, interpretation of myelography and description of the types of surgery available, regardless of whether such surgery is to be performed by the practitioner or at a referral centre.

The book has been set out into several parts to try to avoid repetition of comments regarding the various surgical lesions that occur throughout the vertebral column; the general principles of investigation and treatment are similar in all areas.

Acknowledgements

I wish to extend thanks to many people who have encouraged my interest in neurology and neurosurgery and therefore contributed indirectly to this book. In particular I greatly appreciate having worked with and learnt from Simon Perry, Tom Yarrow and Joe Mayhew. John Fuller deserves special thanks for his excellent drawings and I would also like to thank those at the Animal Health Trust and Department of Clinical Veterinary Medicine, Cambridge who supplied some of the other illustrations. Grateful thanks to Jill Jeffery for correcting grammar and style of the text, Sandra Tatum and Lorraine Leonard, for their assistance at the AHT and Cambridge Veterinary School libraries and to all those at WB Saunders, especially Katharine Hinton and Suzanne Haydon.

CHAPTER 1

Instrumentation

T. G. Yarrow

Contents

<i>Introduction</i>	1
<i>Diagnostic equipment</i>	1
<i>Operating room</i>	3
<i>Haemostatic agents</i>	6
<i>Orthopaedic instrumentation</i>	7

'For it is impossible, or at least not easy to play a noble part unless furnished with the necessary equipment' Aristotle, *The Nichomachean Ethics*.

Neurosurgical procedures require certain specialized equipment and instrumentation in addition to the standard surgical pack. Although some of the items discussed in this chapter are not essential to carry out surgery on the spine they all are helpful during certain procedures. It is hoped that this chapter may serve as a guide to those considering purchasing equipment for spinal surgery.

Diagnostic equipment

Neurological examination

Certain instruments are required to carry out the neurological examination. These include a reflex hammer, artery forceps (mosquito type), penlight, ophthalmoscope, rat tooth forceps and a pair of pliers. It is easier to acquire familiarity with the responses of normal animals if a specified set of implements is used for every case. A reflex hammer is not essential; the handle end of a heavy pair of scissors will suffice to stimulate tendon reflexes and is often preferable for examination of small breeds of dog or cats.

Imaging

RADIOGRAPHY

X-ray generators are designated by the current (mA) and the maximum voltage (kV) they can produce. For the production of diagnostic films of the vertebral column in large breeds of dogs, instruments capable of 300 mA and 120 kV are desirable. Less-powerful generators may be satisfactory but should have a minimum of 100 mA through the range of kV required (up to about 100 kV). Small

2 HANDBOOK OF SMALL ANIMAL SPINAL SURGERY

portable generators are not suitable as it is not possible to obtain enough mA at the higher kV settings. This means that long exposures are needed, which may produce movement artefact even in anaesthetized patients.

A grid will be required to reduce the effects of X-ray scatter when radiographing parts of the body greater than 10 cm thick. Bucky grids are preferable (to eliminate grid lines) but not essential.

It should be possible to tilt the table on which the animal is positioned for radiography. During cisternal myelography the flow of the contrast medium relies on gravity; it is customary to tilt the table to about 10–15° from horizontal. For small dogs and cats a short piece of wood can be used to maintain the animal in a tilted position. For lumbar myelography it is not necessary to tilt the table.

Radiolucent foam pads are very useful to ensure proper positioning of the patient. Only certain types of foam are suitable because it must not produce artefacts on radiographs. Suitable foam can be purchased in large blocks and cut into the required shapes using an electric carving knife. Radiolucent cradles and calving ropes are other useful positioning aids. Animals subjected to spinal radiography should be anaesthetized almost without exception, there should never be a need for the patient to be restrained manually during radiography.

Spinal needles are used for CSF sampling and introduction of myelographic contrast agents. Regular hypodermic needles can be used for the same purpose but are more likely to become blocked. Spinal needles (with a stylet) must be used for lumbar puncture. Useful sizes of needle are 20 gauge 2 inch and 3.5 inch, and 22 gauge 1.5 and 3.5 inch.

It is very helpful to have automatic X-ray film processing available because during myelography the contrast agent often moves rapidly down the subarachnoid space and films may be required at many sites in quick succession. Wet processing also has the drawback that it is difficult to read subtle changes on wet films.

ADVANCED IMAGING

Access to computed tomography (CT) and magnetic resonance imaging (MRI) is not essential for diagnosis of most surgical conditions of the spine, but both can be useful and are likely to become more widely used by veterinarians in the future.

CT is capable of producing cross-sectional images of areas of interest. For improved definition of the spinal cord it can be combined with myelography. Alterations in contrast scales can be made during the scan allowing excellent definition of bone detail.

MRI can produce superb images of the spine – it provides most benefit in evaluation of soft tissue structures and the spinal cord itself. The small size of veterinary patients (compared with humans) means that great care must be taken to attain accurate positioning for optimal sagittal images. In the human medical field MR scanning is rapidly replacing all other forms of spinal imaging (except for use of CT and conventional radiographs for fractures).

Ultrasound may be useful in the future, although experience with spinal cord ultrasound is currently limited.

ELECTRODIAGNOSTIC INSTRUMENTS

Electromyography (EMG) and nerve conduction studies can be useful in certain cases. EMG studies can help in the diagnosis of lumbosacral disorders and can also help in establishing if a lower motor neurone disorder is generalized or local.

CSF EXAMINATION

It is recommended that cell counts on CSF be carried out within 20–30 min of collection, alternatively the CSF can be mixed with an equal volume of formal saline which will preserve the cells. If the cell count is to be carried out in a practice laboratory a standard haemocytometer can be used. Differential cell counts can be problematical because without centrifugation of the sample it is often difficult to find sufficient number of cells to count.

Cell sedimentation chambers can be made and used in practice – instructions are given in several publications. Sedimentation allows sufficient cells to be concentrated for differential counts. Estimation of protein concentrations, including immunoglobulins, can be carried out by outside laboratories; there is not a requirement for immediate analysis.

Operating room

Table

It is important that the operating table is of solid construction and that there is little or no instability – there is a tendency to lean against the table while carrying out surgery on the spine and it could be catastrophic for the table to wobble or move during delicate procedures. It is helpful to have the capability to tilt the table both along and across its long axis. Lateral tilt is helpful for lateral approaches to the thoracolumbar spine and axial tilt is useful during approaches to the caudal cervical spine. Positioning aids such as sandbags, cradles, ties and deflatable bags filled with polystyrene beads may all be required.

Lighting

It should be possible to move the light into a variety of positions so as to allow good lighting even into the deep cavities which are required to reach the spinal cord in some approaches. It is preferable that the light has handles that can be sterilized so that it can be moved by the surgeon or a scrubbed assistant. Also available are head-mounted lights which can be fibre-optic or bulb types. Coaxial lighting is available and preferable as the light will always be directed at the site of interest.

Magnification

Magnification is often useful, especially for removal of intradural lesions. Either operating microscopes or loupes can be appropriate.

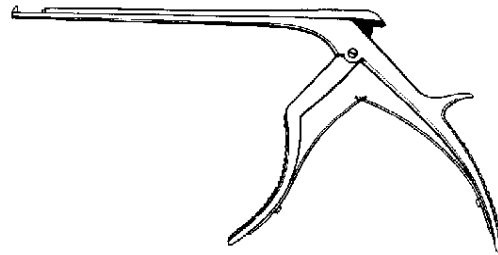


Figure 1.1 *Kerrison rongeurs. Footplate is small and thin allowing its use to remove lamina during thoracolumbar 'mini hemilaminectomy' or cervical continuous dorsal laminectomy.*

Surgical instruments

Retractors of several sorts are required; self-retaining types are most useful. Each surgeon has individual preferences but the Gelpi is probably the most widely used and versatile. Hand-held retractors are useful at certain stages in many operations; the best types are Langenbecks and those made from malleable stainless steel. For nerve retraction, a small blunt and rounded hook, such as the Graham nerve retractor, is required.

Rongeurs of several types are required, although if a powered drill is available a more limited selection is satisfactory. Large double-action rongeurs are used to remove large portions of bone such as the spinous process. Kerrison type rongeurs (Figure 1.1) can be used for rapid removal of the dorsal lamina in dorsal laminectomy (especially in the cervical spine) or to remove portions of the pedicle in the mini hemilaminectomy. Lempert rongeurs (Figure 1.2), which have very fine tips, are used in the inverted cone decompression (modified slot) technique.

A selection of microdissectors or picks is required for estimating the depth of bone to be penetrated and for removal of the inner layer of cortex during laminectomies (Figure 1.3). They are also used for dislodging pieces of extruded disc which lie in the vertebral canal and for lifting the anulus and dorsal longitudinal ligament, allowing these structures to be excised. There are many types of microdissectors: blunt, sharp, curved angled or straight. A large selection is useful, blunt types are required for exploration of intervertebral foramina and ones with a 90° tip are required for retrieval of extruded disc material in the ventral slot procedure.

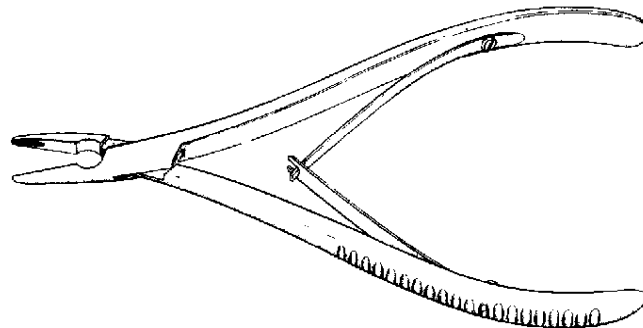


Figure 1.2 *Lempert rongeurs. The tips are narrow allowing good access to remove fragments of dorsal anulus during inverted cone slotting.*

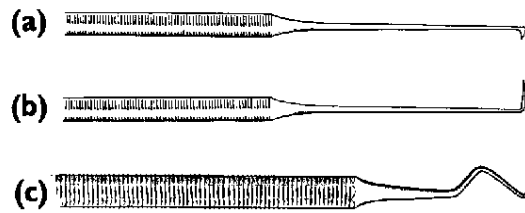


Figure 1.3 Selection of some suitable disc instruments. (a) can be useful during inverted cone slotting. (b) and (c) are useful shapes for general purpose extruded disc retrieval.

Instruments for microsurgery, such as are used in intraocular surgery, can be helpful when operating inside the dura. Iris scissors, lens vectis and small needle holders are particularly useful. Jewellers forceps may be preferable to ophthalmological needle holders as they are cheaper and do not have a catch which can cause unnecessary jarring of the operation site.

Dural hooks, which are used to grasp and retract the cut dura, are available but are rather large for small patients. Fine hypodermic needles with bent tips can be used instead. These can also be used to carry out durotomy incisions. Myelotomy is best carried out using a broken razor blade in a holder.

Suction and irrigation

Both suction and irrigation of the surgical field are required. It should be possible to alter the amount of vacuum generated because high-powered suction can cause damage to the neural tissue (especially when operating inside the dura). Irrigation can be carried out by pouring or by bulb syringe. Suction/irrigation devices (Hydroflow, Portex) are particularly useful and time saving. Small metal suction probes are usually best but in confined areas intravenous cannulae may also work well.

Diathermy

Unipolar diathermy is useful during the initial dissection. Bipolar output allows the surgeon to carry out very discrete coagulation close to vital structures. If forceps are used attached directly to the diathermy then the bayonet type are probably best as they allow the surgeon an unobstructed view of the surgical field. Some bipolar diathermy units have the capability to coagulate in a wet or bloody field, which is desirable. Wet fields reduce the adherence of tissue to activated diathermy forceps. If tissue adheres during coagulation then during subsequent removal the tissue will tear and often causes haemorrhage to recommence. When not in use the tips of diathermy forceps should be kept wet to reduce this occurrence.

Powered instruments

While there are many descriptions of standard neurosurgical procedures carried out with hand instruments, the proper use of powered drills and burrs will allow operations to be carried out more quickly with less chance of iatrogenic damage. Certain procedures can only be carried out using these instruments.

There is a vast selection of power instruments. Most are driven by compressed gas (air or nitrogen) but some are electric. Different brands and types have varying

speeds and torques. Experience shows that high-speed drills, 50–100 000 r.p.m., are preferable. Below 50 000 r.p.m. the torque is higher but the burr will not cut without some pressure, which potentially is a source of danger in animals that have very thin bone. At burr speeds of 50 000 or above the bone can be 'painted' away without pressure being required. These drills are supplied with burr guards which must allow sufficient working length to allow a ventral slot to be prepared. Angled burr guards are available, although expensive, and can help during surgery of the caudal cervical spine and other areas.

There are a large number of burr sizes and shapes including pineapple, barrel, cone and spherical. All procedures can be carried out using spherical burrs. There are also different types of material used to make burrs, such as steel, tungsten carbide and diamond: steel does not appear to cut well and blunts quickly; carbide cuts well and has a long life; diamond does not cut but abrades somewhat like sandpaper and can be used for polishing and final removal of bone over delicate structures.

Inexperienced users should acquaint themselves with the capability of a powered drill by practice on cadavers. In use the soft tissue should be meticulously removed because if it is encountered by the rotating burr it will wrap around it and pull the burr sideways. The first bone to be encountered is the outer cortex, which is white and hard. It is usually quite thick and can be removed quickly. Under this is a layer of cancellous bone which is reddish in colour and soft. This second layer is cautiously thinned until the white inner cortex is exposed. This layer is often thin and must be painted away until it is transparent and gives under pressure, it can then be removed using picks or rongeurs.

Use of a large rather than a small burr is often advantageous even in very small patients. Using a large burr (4–6 mm) it is possible to perforate the lamina quickly and safely. The burr is set at 90° to the lamina and with circular motions a round cavity is developed. With experience, perforation of the inner cortex can be appreciated and the periosteum is often left intact. The procedure is safe as the large burr is unlikely suddenly to penetrate all the bone layers (unlike a small burr).

Alternatively, during the modified Funquist dorsal laminectomy, the inner cortex may be cut through with a small burr and the entire lamina removed in one piece.

Haemostatic agents

Bone wax

This product is used to control bleeding from cut bone surfaces. It is warmed and moulded in the hand and then pressed into the cut surface. It is easiest to apply using fingers but in deep, narrow cavities metal instruments must be used – those with flat, broad surfaces are the best. Similar products which are impregnated with haemostatic chemicals appear not to work any better and can be more difficult to apply to the bone.

Bleeding from cancellous bone which arises during drilling can sometimes also be arrested by continued drilling; the bone dust will be distributed centrifugally into the bone surface and appears to aid haemostasis.

Surgical cellulose and similar material

Surgical cellulose is produced as a fine soft mesh and is impregnated with thrombin. It has a very large available surface area which encourages clot formation and, following application, it expands greatly in volume as it absorbs blood. Surgical cellulose is used mostly to assist in arresting haemorrhage from venous sinuses or occasionally from cut cancellous bone. It is ultimately absorbed but, as always with large foreign bodies, it is preferable not to leave it *in situ* if possible.

There are a number of collagen-based haemostatic agents available. These are alternatives to surgical cellulose. They have the drawback of being less easy to pack into confined spaces. Gelatin sponge (Gelfoam) is widely used in the USA for haemostasis and to fill gaps left in bone following surgical excision. It is difficult to obtain in the UK and some studies have suggested that it is associated with an unacceptable amount of postoperative scarring.

Patties

These are made from compressed rayon, cotton or polyester. They are used to absorb blood or other fluids and are designed to be used on delicate neural tissues in place of standard gauze swabs. (They absorb blood rather than promoting haemostasis.) Before use they are moistened with saline and placed on a flat metal surface. Putting them on metal helps to prevent them from picking up lint from the drapes. In use they are laid on the tissues and when they fill up with fluid they can be sucked dry without having to be removed. They are most useful when operating inside the dura.

Orthopaedic instrumentation

Much standard orthopaedic instrumentation can be required for neurosurgery. A/O (ASIF) instruments and implants are certainly preferred but are not essential in situations in which plates and screws are used. These implants are used for vertebral body plating for fracture/luxation fixation and fixation across intervertebral diarthrodial joints; screws can also be used instead of pins for the pins/methylmethacrylate style of fracture/luxation fixation. Pins and wires are used for many types of fixation; positive threaded pins have great advantages in that migration is reduced and positive threading reduces the likelihood of pin breakage at the threaded/non-threaded interface. A slow-speed powered drill is very useful to drive pins and drill pilot holes for screw fixation. Goniometers are occasionally useful; plastic protractors can be used as an alternative but require gas sterilization (they will melt in an autoclave).

Polymethylmethacrylate (PMMA) bone cement should be available. This versatile material can be used for fixation of many spinal fracture/luxations and also for replacement of bone defects. Care must be taken in its use because of the exothermic reaction which takes place as it cures; saline lavage is required to encourage heat dissipation. PMMA is a large foreign body and can encourage infection – strict aseptic technique is mandatory during its use.

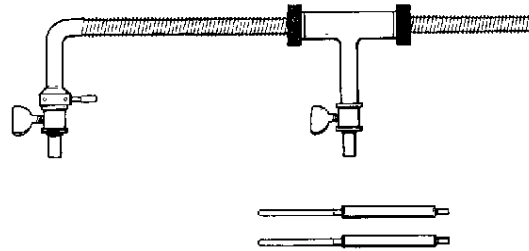


Figure 1.4 Distractor instrument useful in fracture/luxation reduction. Variable sized pins can be used.

External fixator systems are occasionally useful, they can be applied either internally or externally.

Distraction devices

In cases of fracture/luxation in the vertebral column it may be useful to use a distractor. Distraction can often be achieved manually but it can be difficult to carry out in a controlled manner. At some time the surgeon will almost certainly need to transfer the distraction instruments to an assistant, which can result in loss of alignment and can be associated with additional trauma to the delicate neural structures. The problem is solved by use of the distractor (Figure 1.4).

A suitable sized pin is inserted at right angles through the spinous processes cranial and caudal to the fracture/luxation site (alternatively they can be driven across the vertebral bodies themselves). These transfixion pins do not need to be close to the injured area, thereby allowing room to work. The distraction instrument is attached to the pins and controlled axial distraction can be applied and maintained. During distraction the fracture/luxation will often realign satisfactorily or it can be manipulated and temporarily fixed while the definitive fixation is applied. The distractor can be left in place until completion of reduction and fixation.

CHAPTER 2

Anatomy

Contents

<i>Introduction</i>	9
<i>Vertebral column</i>	10
<i>Intervertebral joints</i>	14
<i>Ligaments of the vertebral column</i>	16
<i>Anatomy of the spinal cord</i>	18
<i>Associated reading</i>	23

Introduction

Accurate diagnosis and effective treatment of spinal disease in small animals is dependent on an understanding of the anatomy and physiology of both the spinal cord and the vertebral column. Disease of the vertebral column will frequently cause abnormalities in function of the neural tissue which lies within it.

To understand the forces acting through the vertebral column, analogies with engineered constructions have been made. The normal kyphotic curve of the thoracolumbar region can be compared to a bow, and the abdominal musculature (in particular the rectus abdominis) is analogous to the string of the bow (Figure 2.1). The cervical portion of the vertebral column can be compared to a crane which supports the weight of the head (Figure 2.2).

The forces applied to each part of the vertebral column can be inferred from this structure and suggest concentration of stresses around the thoracolumbar junction and cranial and caudal parts of the cervical vertebral column. Disruption of the

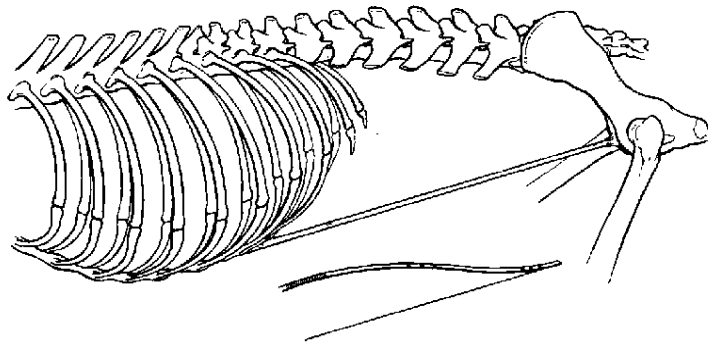


Figure 2.1 The thoracolumbar vertebral column and rectus abdominis muscles form a structure analogous to a bow and string.

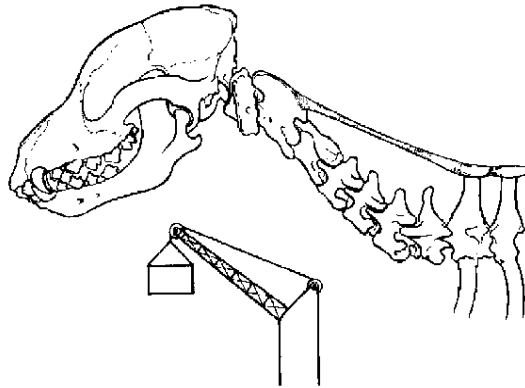


Figure 2.2 The head and cervical vertebral column form a weight which is counterbalanced by the epaxial musculature and ligaments. The structure is analogous to a crane.

continuity of the vertebral column at these regions may therefore be inferred to be more likely, and the clinical consequences of degenerative disc disease are most commonly observed at these sites. Owing to a differential growth between the spinal cord and the vertebral column, the spinal cord segments are not enclosed within the vertebral column segments of the same name. The spinal cord segments are located somewhat cranially in relation to their relevant vertebral column segments. This shift in location is most marked in the caudal lumbar area but can also be observed to a lesser extent in the caudal cervical region (Figures 2.3 and 2.4). A neurological examination will determine which spinal cord (not vertebral) segment is affected; care must therefore be taken to ensure that the relevant area of the vertebral column is examined radiographically.

Vertebral column

The vertebral column consists of a series of irregular bones, plus ligaments, in which lies the spinal cord. A 'typical' vertebra consists of: (i) body; (ii) vertebral arch – which can be subdivided into right and left pedicles plus the dorsal lamina; and (iii) various processes to which attach muscles and components of joints. The constituent parts are variable in size and shape but within each region of the spine, the vertebrae show a number of common features. Five regions are recognized in the canine vertebral column: cervical, thoracic, lumbar, sacral and caudal.

Cervical spine – seven vertebrae

The first two vertebrae are the most atypical in the spine. The first cervical vertebra, the atlas, is unusual in that it has no vertebral body. During embryonic development, the body becomes attached to the cranial aspect of the second cervical vertebra (the axis), to form the dens. The atlas has no dorsal spinous process either, but the transverse processes are the well-developed wings of the atlas (Figure 2.5). The axis has a very well-developed dorsal spinous process, the most cranial aspect of which, in life, overhangs the arch of the atlas (Figure 2.6). The dens

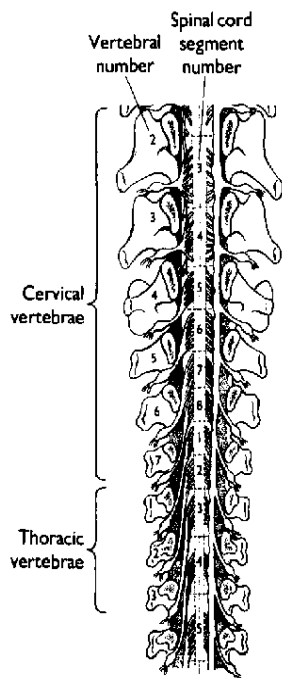


Figure 2.3 Relationship of spinal cord with cervical vertebrae. Note that there are eight spinal cord segments but only seven vertebrae.

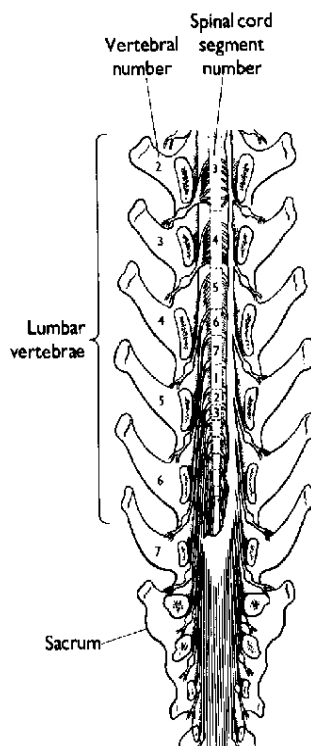


Figure 2.4 Relationship of spinal cord and nerve roots with lumbar vertebrae.

of the axis lies in the ventral part of the vertebral canal of the atlas and is maintained in this position by the transverse atlantal ligament and the apical ligaments. Articulation of the atlas with the occipital region of the skull allows movement in the sagittal plane; articulation of the atlas with the axis allows rotatory movement about the central axis of the vertebral column.

The remaining cervical vertebrae possess small spinous processes, which increase in size from C3 to C7, and ventrolaterally projecting transverse processes, which reach greatest size on C6. The large transverse processes on C6 are useful landmarks during ventral surgical approaches to the cervical spine. All cervical

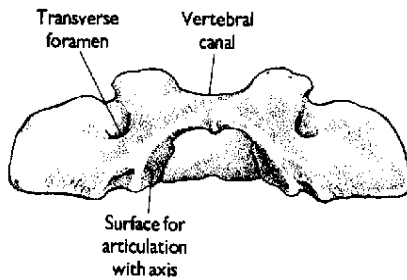


Figure 2.5 Atlas, caudoventral aspect.



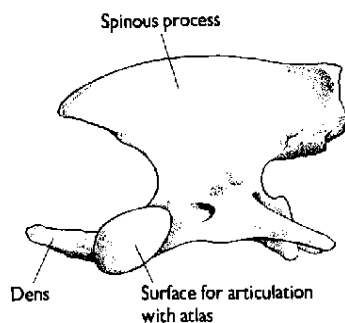


Figure 2.6 Axis, lateral aspect.

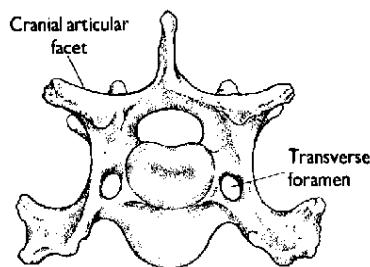


Figure 2.7 C5, cranial aspect.

vertebrae except C7 possess transverse foramina, through which the vertebral artery courses. This lies at the lateral aspect of the margins of the body, close to the base of the transverse processes (Figure 2.7). The cervical vertebral canal is more capacious in relation to the spinal cord than that of other segments of the spine.

The cranial articular facets of the cervical vertebrae face almost directly ventrally on the dorsolateral margins of the vertebral canal and the caudal articular facets face dorsally. This allows movement between vertebrae both laterally and to a lesser extent dorsoventrally, while rotatory movement is very limited. The greatest movement in the cervical spine takes place in the cranial part of this segment.

Thoracic spine – 13 vertebrae

Typical features of thoracic vertebrae are the well-developed spinous processes, small transverse processes and articulation with the ribs. The spinous process is largest on T1 and then becomes progressively smaller on the remaining thoracic vertebrae. The first 10 thoracic vertebrae possess caudally directed spinous processes but on T11 the spinous process is relatively small and projects vertically from the body. This is known as the anticlinal vertebrae and can be a useful landmark on thoracolumbar radiographs. The spinous processes on the remaining thoracic vertebrae have a slight cranial inclination (Figure 2.8).

The bodies of the thoracic vertebrae are short. Articulation with the rib takes place at the cranial aspect of the vertebra and with the costal fovea of the short transverse process. The articulation of the rib on each vertebrae is located further

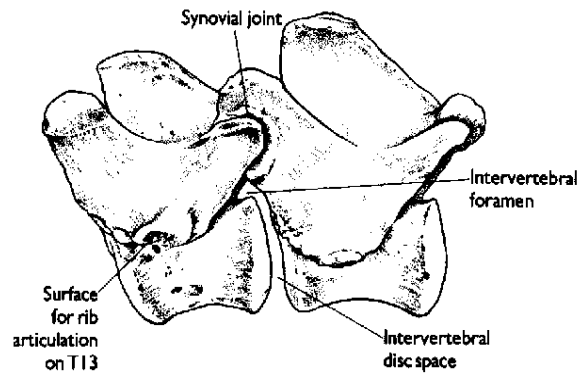


Figure 2.8 Articulation of T13 with L1, lateral view (with ribs removed).

caudally on the more caudal thoracic vertebrae. The articular facets on the first 10 thoracic vertebrae are orientated similarly to those of the cervical vertebrae, whereas those of T11, 12 and 13 form joints parallel to the sagittal plane. Movement of the spine in the cranial thoracic region is rather limited, partly because of the large muscle masses around the vertebrae plus the ligaments and musculature associated with the ribs. In the caudal thoracic region, greater movement between vertebrae is permitted. Movement in the caudal thoracic spine is limited almost exclusively to flexion and extension within the sagittal plane; a lesser degree of movement is permitted in the lateral plane.

Lumbar spine – seven vertebrae

The vertebral bodies in this area are long and wide, particularly in the cat. There is a general increase in size of the lumbar vertebrae progressing caudally; however, L7 vertebra is somewhat smaller than L6 and the spinous process is also shorter. This feature can be of use in determining the site of needle introduction for lumbar myelography. The transverse processes are well developed and directed cranioventrally; the spinous processes are directed cranially. Articular facets are orientated similarly to those in the caudal thoracic region, with the cranial facets of one vertebra lateral to the caudal facets of that preceding it (Figures 2.9 and 2.10).

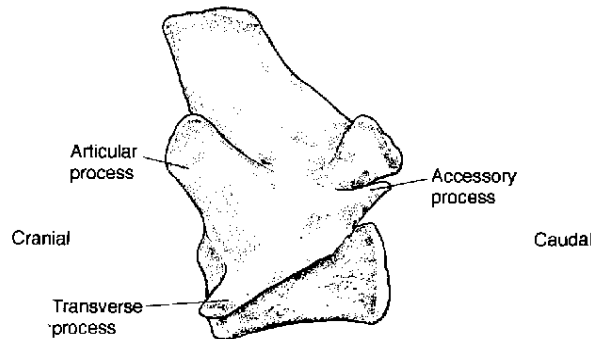


Figure 2.9 L1, lateral view.

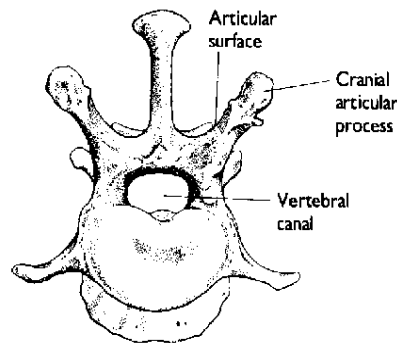


Figure 2.10 L1, cranial view.

Movement in the lumbar spine is limited almost exclusively to flexion and extension within the sagittal plane but the area is relatively mobile, especially in the more cranial part.

Sacrum – three vertebrae

The sacral vertebrae are fused in the adult dog to form the sacrum which articulates laterally with the ilia. The sacroiliac articulation is a cartilaginous joint allowing little movement. The three parts of the sacrum are apparent, both grossly and radiographically. There are three small spinous processes, and two pairs of dorsal and pelvic (ventral) foramina, which transmit the first two sacral nerve roots. The third pair of sacral nerves leaves the vertebral canal between the sacrum and the first caudal vertebra.

Caudal vertebrae – approximately 20 vertebrae

The bodies of the caudal vertebrae are elongated and present throughout the length of this segment of the vertebral column. Ventral to the body of the first few vertebrae there is a haemal arch through which the median coccygeal artery runs. Dorsally, there is a neural arch that contains the caudal nerves. Progressing caudally, the caudal vertebrae gradually lose the typical features of vertebrae, the last few being almost featureless cylinders of bone.

Intervertebral joints

Intervertebral discs (IVD)

These consist of two main portions, an inner nucleus pulposus and an outer anulus fibrosus (Figure 2.11). The two associated cartilaginous end plates which are adherent to the neighbouring vertebral bodies are often also included in descriptions of the structure of the IVD. The intervertebral discs lie between adjacent vertebral bodies and conform to their shape. There is an intervertebral disc at each intervertebral space, except between the atlas and the axis, and between the

fused vertebrae of the sacrum. There is some variability in the width of the discs; the largest are in the caudal cervical and caudal lumbar regions.

The outer anulus fibrosus is a fibrocartilaginous tissue consisting of concentric lamellae of collagenous fibres. Bundles of fibres run obliquely between adjacent vertebrae crossing each other at angles of 100–120°. The fibres of the anulus are well attached at their periphery. The inner layers attach to the cartilaginous endplates, whereas the outer layers attach to the vertebral endplates. The inner layer of the anulus is more cartilaginous and less fibrous than the outer layers.

The inner portion of the intervertebral disc, the nucleus pulposus, is a semifluid gelatinous tissue and is contiguous with the central portion of the cartilaginous endplates. The nucleus is oval-shaped and eccentrically placed between the middle and dorsal one-third of the disc. The eccentric position of the nucleus is important, as it is presumed to be the reason for the greater observed incidence of dorsally directed disc extrusions versus those directed ventrally. The dorsally directed extrusions and protrusions are those responsible for the signs of back pain, ataxia and paresis which are so frequently observed in the dog. The nucleus contains large amounts of glycoprotein and proteoglycans, the exact amount being dependent on the age and breed of dog. These constituents confer gel-like properties to the nucleus pulposus and are responsible for the non-compressible nature of the IVD in a healthy animal. The degenerative processes occurring in intervertebral discs will be considered elsewhere.

The IVD in the adult is avascular. Consequently, its nutrition is dependent on passive diffusion pathways. There are two nearby sources of metabolites for the IVD, the peripheral vascular plexus of the anulus and the vessels adjacent to the hyaline cartilage of the bone/disc interface. The 'pumping' action of normal vertebral movement may assist in the delivery of large molecules to the central portions of the disc. The central disc tissues have low oxygen tensions and high concentrations of lactic acid, suggesting that respiration is primarily anaerobic.

Nerve supply to the IVD is limited to sparse fibres detectable in the outer layers of the anulus fibrosus, the nucleus being devoid of nerve supply. The dorsal longitudinal ligament of the dog has been found to be profusely supplied with nerve fibres and is in intimate contact with the dorsal part of the anulus fibrosus. This nerve supply is derived from spinal nerves originating from up to two segments either cranially or caudally. This diffuse innervation could account for the poor localization of back pain noted in both animals and people. Stimulation of

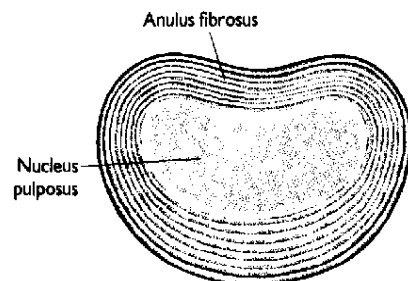


Figure 2.11 *Transverse section of intervertebral disc. Note concentric orientation of fibres of anulus fibrosus and eccentric position of nucleus.*

nerves in the outer layers of the anulus fibrosus and dorsal longitudinal ligament could be responsible for the phenomenon of 'discogenic pain' which sometimes appears to occur in dogs.

Intervertebral synovial joints

In addition to the IVD, there are synovial joints between neighbouring vertebrae, except for the fused bones of the sacrum. The atlanto-occipital and atlanto-axial joints are somewhat different from those between other vertebrae. The synovial joints of the remaining vertebrae lie between the facets. These synovial joints are most voluminous between those vertebrae where the most movement is permitted – the cervical region.

ATLANTO-OCCIPITAL JOINT

The atlanto-occipital articulation is formed between the occipital condyles and the cranial articular foveae of the atlas. It is a synovial joint. A lateral atlanto-occipital ligament runs from each lateral aspect of the dorsal arch of the atlas to the jugular process of the occipital bone.

ATLANTO-AXIAL JOINT

The atlantoaxial articulation is supported by several ligaments.

- (1) The alar ligaments consist of three parts, all originating from the dens. Two lateral parts run craniolaterally to attach to the medial aspect of the caudal parts of the occipital condyles; the middle portion runs directly cranially to attach to the intercondyloid incisure on the caudal aspect of the ventral skull
- (2) The transverse ligament of the atlas is a strong band connecting one side of the ventral arch of the atlas to the other. It runs dorsal to the dens thereby maintaining its position relative to the atlas
- (3) The dorsal atlanto axial ligament runs between the dorsal arch of the atlas and the neural arch of the axis.

There is a synovial joint between the cranial articular facets of the axis and the caudal articular foveae of the atlas. The joint capsule extends to include both sides of this articulation and extends dorsally to incorporate the dorsal atlanto-axial ligament.

Ligaments of the vertebral column

There are both long and short ligaments of the vertebral column. Long ligaments run along or between a series of vertebrae, whereas short ligaments run between adjacent vertebrae only.

Long ligaments

NUCHAL LIGAMENT

This ligament runs between the caudal part of the spinous process of the axis to the dorsal tip of the first thoracic vertebra. It is composed of elastic fibres and is pale yellow in appearance. This ligament is probably of little functional importance in the dog and cat but is a useful landmark during surgery. A portion of the nuchal ligament can be used in one surgical technique for stabilization of atlanto-axial subluxation.

SUPRASPINOUS LIGAMENT

This ligament runs along the dorsal tips of all vertebrae caudal to T1. It is relatively larger in the thoracic region, and may be difficult to identify in other regions of the spine.

DORSAL LONGITUDINAL LIGAMENT

This ligament lies on the floor of the vertebral canal from the dens to the caudal end of the vertebral canal. It is firmly attached to both the vertebral bodies and to the dorsal anulus of each intervertebral disc. The dorsal longitudinal ligament is widest over the intervertebral discs and narrowest in the middle of each vertebral body. This is a large and important spinal ligament which assists in maintaining stability (Figure 2.12). It is also important surgically as an obstacle to be overcome during ventral approaches to decompress the spinal cord.

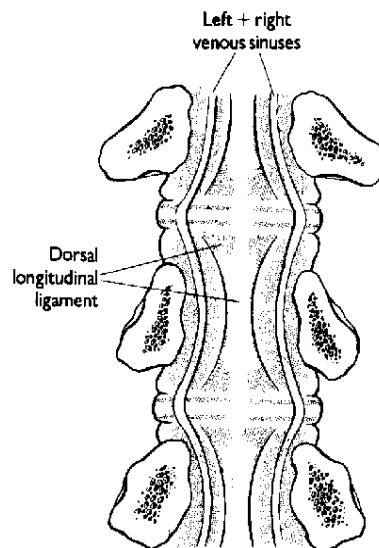


Figure 2.12 Dorsal view of dorsal longitudinal ligament and venous sinuses. Note divergence of venous sinuses as they pass over the disc.

VENTRAL LONGITUDINAL LIGAMENT

This attaches along the ventral aspect of the vertebral bodies along the midline. It runs from the axis to the sacrum and is far less strong than the dorsal longitudinal ligament. It may be difficult to identify in some regions of the spine.

Short ligaments

INTERSPINOUS LIGAMENTS

These ligaments connect adjacent spinous processes. The fibres run at oblique angles relative to these processes. The interspinous ligaments are most obvious in the thoracic region, where the vertebrae have long spinous processes.

FLAVAL LIGAMENTS

These are pale yellow elastic ligaments connecting adjacent vertebral arches. The dimensions of this ligament vary but it can be several millimetres thick in the cervical region. Laterally, this ligament often merges with the joint capsule of the facet joints. The flaval ligaments can be a source of spinal cord or nerve root compression in some disorders.

INTERCAPITAL LIGAMENTS

This ligament runs between the heads of the ribs articulating with one thoracic vertebra. It runs dorsal to the dorsal anulus fibrosus of the intervertebral disc but ventral to the dorsal longitudinal ligament. There is no intercapital ligament between the first pair of ribs or between the last two pairs of ribs; the intercapital ligament between the eleventh pair of ribs is considerably smaller than the others. This ligament is thought to be important in preventing disc extrusion in the T2-T10 region of the spine.

Anatomy of the spinal cord

The spinal cord is the nerve tissue that extends from the caudal part of the brain to its termination, as the conus medullaris, in the caudal lumbar region. There is a canal running through the centre of the spinal cord, which contains cerebrospinal fluid (CSF) and is known as the central canal. It is continuous with the ventricular system of the brain.

A pair of spinal nerves emerge between each pair of adjacent vertebrae. The first pair of cervical nerves emerges between the atlas and occipital bone; thus there are eight pairs of cervical nerves, then 13 thoracic, seven lumbar and three sacral. The spinal cord is enveloped in three membranes, termed meninges: the pia mater, arachnoid mater and the dura mater. The innermost is the pia mater which is intimately associated with the spinal cord parenchyma. A double leaf of the pia mater extends dorsally from the ventral midline and invests the ventral spinal artery as it courses into the parenchyma. In close association with the outer aspect of the pia is the delicate arachnoid mater; the two membranes are associated closely

enough to be frequently referred to together as the pia-arachnoid. There is a space on the outer aspect of the arachnoid, which also contains CSF, and is referred to as the subarachnoid space. Many fine thread-like extensions of the arachnoid project across this space to contact the outermost membrane, the dura mater. The subarachnoid space is important clinically as it can be opacified with radiographic contrast agents during myelography. The dura mater is a tough and inelastic membrane which functions to protect the spinal cord. The spinal cord is suspended within the dura mater by the denticulate ligaments, which attach to the inner aspect of the dura and to the pia mater.

The spinal nerve roots which enter and leave the spinal cord parenchyma are invested in layers of the meninges. The distribution of dura mater covering is variable at different sites within the vertebral column. For the cervical nerve roots C1 to C6, both the dorsal and ventral roots are invested in dura together; elsewhere in the spine there is a separate covering for each of the two root divisions.

There are two main components identified in cross-sections taken at any level: the central grey matter and the more peripheral white matter. The grey matter is more or less butterfly-shaped at most levels. It contains the cell bodies of the spinal cord neurones, plus a quantity of supporting cells (glia) and connecting nerve fibres. The white matter contains the axons which make connections with more rostral or more caudal parts of the nervous system, together with the glial cells which produce myelin and support and maintain the axons themselves. Groups of axons with similar connections (and therefore subserving similar functions) are grouped together to form tracts, which are reasonably well defined. The location of the various spinal cord tracts running to and from the brain are known with reasonable accuracy in the dog and cat (Figure 2.13).

The spinal cord is not of uniform diameter. There are areas where it widens; these are in the caudal cervical/cranial thoracic region and in the lumbar region and are referred to as the cervical and lumbar intumescences, respectively. At these regions there are a greater number of cell bodies, which supply the thoracic and pelvic limbs, respectively, and therefore the cord diameter is increased. The mid-thoracic/cranial lumbar region of the spinal cord is comparatively narrow in diameter. Knowledge of the normal appearance of the cord at these sites is particularly important when evaluating myelograms.

The spinal cord does not extend throughout the length of the vertebral column. In dogs, the cord ends at approximately the caudal end of L5, although the exact site is

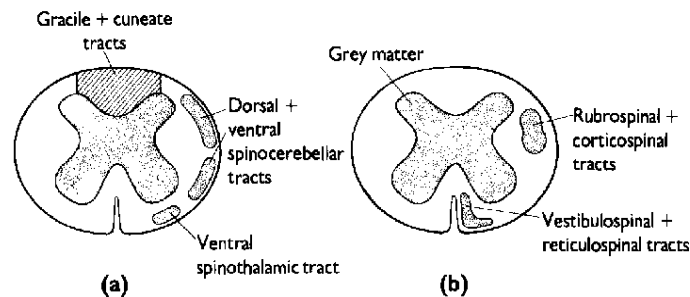


Figure 2.13 Diagram of transverse sections of spinal cord to show position of major ascending (a) and descending (b) tracts.

variable with the size and breed. In smaller dogs the cord extends further caudally in relation to the vertebral column. In cats, the cord ends at about the caudal end of L6. The termination of the spinal cord is termed the conus medullaris.

Spinal nerves destined to leave the vertebral canal at sites more distal to this end point continue to run caudally for some distance in the vertebral canal. They form a collection of nerves running almost parallel to each other, and are referred to as the cauda equina.

Cross-sectional anatomy of the spinal cord

Ventrally, the centrally located reflection of the pia mater containing the ventral spinal artery divides the ventral white matter into two halves. The exiting ventral roots and the pathway for the dorsal roots serve to subdivide further the white matter into other less well-defined fasciculi: i.e. the dorsal and lateral fasciculi.

Both ascending (i.e. transmitting impulses cranially) and descending (i.e. transmitting impulses caudally) tracts are mixed together in most fasciculi but the dorsal fasciculi contain only ascending fibres (in the dog and cat). Ascending pathways contain sensory fibres transmitting the modalities of pain, temperature sensation and proprioception (i.e. position sense) to the medulla, thalamus, cerebellum and cerebral cortices. Descending pathways contain fibres transmitting impulses caudally from cranial structures (the upper motor neurone, UMN) to influence the lower motor neurones (LMN) in the ventral horn, usually via interneurons.

Important sensory pathways include:

- (1) The gracile and cuneate tracts in the dorsal columns which carry proprioceptive information (plus fine touch and vibratory sensation) first to centres in the medulla (the gracile and cuneate nuclei) from where it is then relayed to the thalamus and cerebral cortices. This information forms the basis for 'conscious proprioception', which is frequently tested during neurological examination. The nerve fibres are large and heavily myelinated. This feature renders them more sensitive to insult; in particular they are sensitive to the effects of compression. Deficits in conscious proprioception are therefore commonly the first abnormalities to be observed in animals with spinal cord compression.
- (2) Spinocerebellar pathways which contain fibres carrying information regarding the state of contraction of the muscles (i.e. information from the Golgi tendon organs and the muscle spindles). This information is transmitted to the cerebellum for use in integrating and finely regulating the motor responses of the animal. Lesions in this pathway cause abnormalities to be observed in postural reactions during the neurological examination.
- (3) The spinothalamic tract which carries the modality of deep pain (i.e. aching pain). This pathway contains lightly or nonmyelinated fibres and contains many synapses. The pathway is distributed on both sides of the cord and a stimulus to one side of the body will elicit a response in the spinothalamic tract bilaterally. Because of these anatomical features and the lesser degree of myelination of its constituent fibres, this pathway is very difficult to disrupt completely. For this reason the loss of deep pain response has great significance, as it must result from severe disorders which cause more or less complete functional transection of the cord.

Descending pathways of importance include:

- (1) The rubrospinal tract, which is the most important motor pathway in the domestic species. Constituent fibres originate from the red nucleus in the midbrain and descend after immediate decussation. The locomotor patterns of walking and running are, in part at least, controlled from this site. The red nucleus itself is subject to influence from the cerebral cortex and the cerebellum. The rubrospinal tract is influential in increasing flexor tone.
- (2) The vestibulospinal tract originates from the medulla and contains axons which have the effect of stimulation of the lower motor neurones to increase extensor tone on the ipsilateral side and increase flexor tone on the contralateral side.
- (3) The reticulospinal tract originates in the pons and is influential in increasing extensor tone.
- (4) The corticospinal tract originates in the motor cortex of the cerebral hemispheres and descends to influence the ventral horn cell (alpha motoneurone) of the spinal cord via an interneurone. The important difference from human spinal cord anatomy is that the corticospinal axons do not act directly on the ventral horn cells but act via an intermediary. In humans, the interruption of the corticospinal tract, as occurs in strokes, is very serious, with loss of much motor power and control. In dogs and cats the loss of control is rather transient and animals can cope well with this interruption.

Overall, there is a balance between the influences increasing the extensor muscle tone (i.e. antigravity muscles) and those increasing the flexor tone (i.e. encouraging locomotor activity). This balance is responsible for the tone of the muscles observed during neurological examination. Increase or decrease in these influences is able to set the pattern for expression of the nature and velocity of the gait.

Blood supply to the spinal cord

Arterial supply to the spinal cord is organized segmentally. Between each pair of adjacent vertebrae a radicular artery enters the vertebral canal alongside the exiting spinal nerve. Radicular arteries are derived from the aorta or, in the cervical region, from the vertebral artery. There are both dorsal and ventral radicular arteries. In the cervical region the dorsal vessels are branches of the ventral radicular arteries. The radicular arteries form one ventral and two dorsal spinal arteries which run uninterrupted on the surface of the cord. The ventral spinal artery lies in the ventral median fissure and each dorsal spinal artery lies within a dorsolateral sulcus. There are contributions to the dorsal and ventral spinal arteries at most interspaces, although the number is variable at different levels of the cord; the highest proportion of contributions is present in the cervical region and the least in the thoracic region. A pial arterial plexus is formed by anastomosis of branches of the dorsal and ventral spinal arteries. The cord parenchyma is supplied by blood from both sources, the central one-third by the ventral spinal artery, the outer half by the pial plexus and the remainder by a combination of both (Figure 2.14). The capillary network is considerably more dense in the grey than in the white matter. Flow of blood to the spinal cord is responsive to variations in arterial $p\text{CO}_2$ and can be maintained at a constant level over a wide range of systemic perfusion pressures. This autoregulation is similar to that acting in the brain.

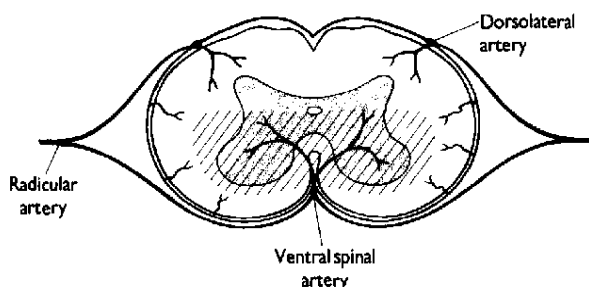


Figure 2.14 Diagrammatic representation of blood supply to spinal cord. Shaded area is supplied by ventral spinal artery, clear area is supplied by dorsolateral arteries and pial plexus.

Venous drainage of the cord is via veins in the dorsal and ventral median fissures and veins in the dorsolateral and ventrolateral sulci into the radicular veins and eventually into the epidural venous sinuses. The venous sinuses lie on the lateral part of the floor of the vertebral canal and have no valves, enabling blood within them to flow both cranially and caudally. There are numerous connections between the right and left vessels and they also receive blood from the vertebral bodies. The paired venous sinuses deviate from each other over the intervertebral discs and approach each other in the centre of the vertebral bodies. They drain into the extra-vertebral circulation via intervertebral veins. The venous sinuses are very important structures in surgery of the vertebral column, owing to the profuse and hazardous haemorrhage which may result should they be damaged. The rate of blood flow within the venous sinuses is largely dependent on obstructions to flow in anastomosing pathways. For example, flow of blood in the lumbar venous sinuses will be greater if there is compression of the abdomen, which slows the passage of blood to the caudal vena cava.

Cerebrospinal fluid (CSF)

The spinal cord is surrounded by the CSF, which is contained in the subarachnoid space; there is also CSF within the central canal. The CSF is produced in the choroid plexuses in the brain and tends to flow caudally from the head towards the tail. Movement of the CSF is encouraged by the pulsation of blood within the arteries of the spinal cord. CSF leaks out at the cuffs where the nerve roots are surrounded by the dura and is reabsorbed into the circulation. CSF is also reabsorbed by the arachnoid villi in the cerebral veins or venous sinuses of the head. The central canal of the spinal cord is continuous with the ventricular system of the brain and is lined with the same type of ependymal cells. CSF reaches the subarachnoid space of the spinal cord by flowing through the lateral apertures of the fourth ventricle.

The fluid-filled subarachnoid space is commonly used for radiographic studies of the spinal cord following its opacification with contrast agents. Contrast material is not normally introduced into the central canal, although this can occasionally be done in order to demonstrate abnormalities such as syringomyelia.

Associated reading

- Braund K.G. (1993) Intervertebral disc disease. In: Bojrab M.J. (ed.) *Disease Mechanisms in Small Animal Surgery*, 2nd edn. Philadelphia, Lea and Febiger, p. 960.
- Burke M.J., Banks W.J. (1986) Histochemical study of the anulus fibrosus in normal canine caudal cervical intervertebral discs. *Res. Vet. Sci.* **40**, 18.
- Burke M.J., Colter S.B. (1990) A practical review of canine spinal cord anatomy. *Prog. Vet. Neurol.* **1**, 358.
- Caulkins S.E., Purinton P.T., Oliver J.E. (1989) Arterial supply to the spinal cord of the dog. *Am. J. Vet. Res.* **50**, 425.
- Crock H.V. (1960) The arterial supply and venous drainage of the vertebral column of the dog. *J. Anat.* **94**, 88.
- Evans H.E., Christensen G.C. (1979) The skeleton. In: Evans H.E., Christensen G.C. (eds), *Miller's Anatomy of the Dog*, 2nd edn. Philadelphia, W.B. Saunders, p. 107.
- Fletcher T.F. (1979) Spinal cord and meninges. In: Evans H.E., Christensen G.C. (eds) *Miller's Anatomy of the Dog*, 2nd edn. Philadelphia, W.B. Saunders, p. 935.
- Forsythe W.B., Ghoshal N.G. (1984) Innervation of the canine thoracolumbar vertebral column. *Anat. Rec.* **208**, 57.
- Hansen H.J. (1952) A pathologic-anatomical study on disc degeneration in dog. *Acta Ortho. Scand. Suppl.* **XI**.

CHAPTER 3

Investigation of Spinal Disease

Contents

<i>Introduction</i>	24
<i>History</i>	24
<i>Physical examination</i>	26
<i>Neurological examination</i>	27
<i>Localization of lesions</i>	41
<i>Associated reading</i>	43

Introduction

The investigation of an animal with a suspected spinal lesion can be divided into several parts, which are carried out sequentially, prior to carrying out a plan of treatment. In common with investigation of disease elsewhere in the body, the SOAP format of case recording can be a very useful means of ensuring that diagnostic efforts proceed logically: S, subjective information (i.e. the history obtained from the owner); O, objective findings of the veterinarian; A, assessment, i.e. possible diagnoses/differential diagnosis; P, plan of action to confirm diagnosis and/or initiate treatment.

The initial part of the investigation for animals with suspected spinal lesions includes the following means of diagnosis: history, physical examination, neurological examination, and ancillary aids (see Chapter 4).

History

A detailed history may suggest an aetiology for any symptoms exhibited by the animal and therefore care should be taken with this part of the investigation. Important information to elicit from the owner in such cases includes:

- Signalment—age, breed, sex
- Rapidity of onset and duration of symptoms
- Is/was the condition progressive?
- Are/were the symptoms predominantly unilateral?
- Has there been any response to previous treatment?
- Is there a history of intercurrent or recent other disease?
- Family history of any particular disease?
- Has the animal been treated at any time for neoplastic disease?

Signalment

Many neurological diseases are associated with specific breed, age or sex of the patient. This information can be used to help increase the 'index of suspicion' for certain conditions, which may usefully help to guide diagnostic efforts in the correct direction. However, care must be taken not to rely too heavily on this type of information, as there may be a possibility of overlooking a more unusual or unexpected diagnosis. Signalment information, therefore, should not be used as a short cut in the logical progression from history-taking to establishment of the diagnosis.

Rapidity of onset of symptoms

Again, this information can be invaluable as a means of establishing a likely differential diagnosis list. The rapidity of onset can be used as a means of ruling out certain aetiologies, for instance, some conditions typically present peracutely, such as fibrocartilaginous embolization. An abnormality with insidious onset can therefore not be a result of this aetiology. However, not all conditions will be associated with such clear-cut temporal onset and some disorders have a very variable speed of onset of symptoms, such as neoplasia.

Progression of symptoms

Whether the symptoms are progressive must be established prior to further work up. In many instances, a decision as to whether surgical or medical treatment would be most appropriate will be based on this information. Many spinal disorders are self limiting (as they are caused by disc extrusions) and so the nature of the individual's symptoms is the most important factor in determining the appropriate therapy.

Lateralization

This question is useful to pose in order to correlate findings on radiography, in particular myelography, with the clinical findings. Often the owner will notice that one or more limbs were affected before the others, even in animals in which clinical signs appear to be symmetrical at the time of neurological examination.

Response to previous treatment

This is important partly as a means of determining the potential value of surgery (as opposed to medical therapy), and may also give a clue as to the type of lesion which is present. This is particularly important with regard to previous response to corticosteroids.

Intercurrent/recent disease

As systemic disease can be a cause for lesions of the spinal cord or vertebral column, questioning of the owner regarding the animal's recent health can help

in identifying symptoms that may be related. Two main categories of such disease are recognized; tumour which can metastasize (which would include any sarcoma, and some carcinomas) and systemic infectious or inflammatory disease (especially canine distemper). Furthermore, it is important to identify presence of unrelated systemic disease, such as chronic renal failure, which would contraindicate surgery.

Physical examination

A complete physical examination should, of course, be performed on all animals. Neurological deficits can often be the result of disease of one of the other body systems. Particular items of interest when investigating for possible spinal disease include: attitude, temperature, cardiovascular system, orthopaedic disorders, urinary tract and endocrine system.

Attitude

The general attitude of the animal is significant because some very depressed animals which have non-neurological primary disease will exhibit neurological deficits, e.g. those which have profound hypovolaemia due to shock or haemorrhage. Pain responses may be altered in these cases. Animals exhibiting changed temperament may be in severe pain (which is often spinal or radicular in origin) or be suffering from a primary brain disease.

Temperature

Change in the animal's body temperature is occasionally significant, such as pyrexia associated with infection, or hypothermia as one sign associated with ascending myelomalacia.

Cardiovascular disease

Cardiovascular (CV) disorders are important for a variety of reasons: (i) the symptoms associated with CV disease may mimic those of primary neurological disease, e.g. cardiomyopathy may cause apparent weakness; (ii) CV disease may itself be an aetiology for nervous system disease, e.g. aortic thromboembolism in cats; (iii) CV disease may be present as a result of a common aetiology e.g. endocarditis associated with bacteraemia and discospondylitis; (iv) severe CV disease may be a relative or absolute contraindication to spinal surgery.

Musculoskeletal system

An orthopaedic examination must be carried out and is especially important in animals exhibiting pelvic limb weakness or pain. Several orthopaedic conditions may be confused initially with spinal disease, in particular bilaterally ruptured anterior cruciate ligaments, and hip dysplasia/coxofemoral degenerative joint disease. Animals with bilateral carpal injuries may also initially appear to be

suffering from a spinal disorder. Some neurological diseases will also mimic orthopaedic conditions, notably brachial plexus disorders.

Urinary tract

Examination of the urinary system may help in identifying abnormalities, such as altered continence, which may help in identification of the type and site of spinal lesion. Urinary tract infection is a common sequela to incontinence arising from spinal injury and must be identified so as to allow appropriate management.

Endocrine system

Abnormal endocrine function can lead to secondary disorders of the nervous system. This usually takes the form of deficits in the function of lower motor neurones or muscle, often in association with diabetes mellitus, insulin-secreting tumours or hyperadrenocorticism. The lesions of the spine that may be most likely to be confused with such diseases would be those in which lower motor neurone deficits are apparent, such as lumbosacral disorders.

Neurological examination

The neurological examination is the most important part of the assessment of an animal thought to be suffering from a spinal disorder. The neurological examination can determine whether or not neurological disease is present (unless there is an episodic problem), locate lesions, and in some cases can provide invaluable prognostic information. The precision in localization can be very variable, depending on the nature of the disease process; for example, a diffuse, mild, non-painful lesion of the T3–L3 segment of the spinal cord can be only poorly localized but a painful, severe lesion affecting lower motor neurone pathways to part of a limb can be very precisely localized. Other investigations may be required to determine the nature of the disease process but the type of further investigation is often dictated by the findings on neurological examination.

Although this book is concerned with spinal disorders, it is important that the whole nervous system is evaluated, as certain diseases can cause multifocal lesions, some of which will also involve cranial structures.

The neurological examination is aimed initially at localizing a lesion to one or more of the following broad categories: (i) 'head', (ii) C1–C5, (iii) C6–T2, (iv) T3–L3, (v) L4–caudal, (vi) peripheral nerve, neuromuscular junction or muscle. (NB, The spinal locations refer to spinal cord, not vertebral, segments (Figure 3.1).

A lesion is categorized into one or more of these locations by examination of both the 'local' spinal or cranial nerve reflexes, and more complex responses.

The neurological examination should be carried out in the same sequence on each patient. This will enable the examination to be carried out more quickly and with fewer omissions. Furthermore, a routine sequence of examination will ensure familiarity with the responses of normal animals at each stage.

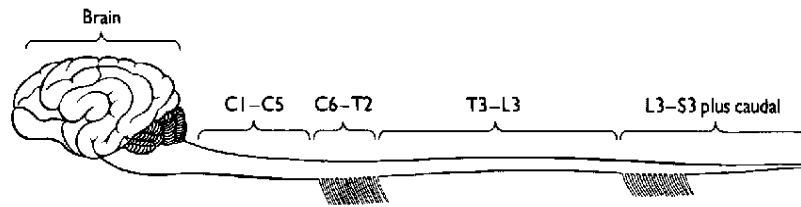


Figure 3.1 Diagrammatic representation of CNS.

Gait

The first part of neurological assessment consists of observing the animal as it walks, or attempts to, and its response to its surroundings. This is best carried out in a large space and preferably on a non-slip surface. Certain animals, such as those suspected of suffering fracture or luxation of the vertebral column, should not be allowed to attempt to walk because of the risk of incurring further injury to the spinal cord. Abnormalities in the gait can be tentatively designated orthopaedic or neurological in origin.

Muscle mass and tone

Muscle tone can be conveniently assessed while the animal is in lateral recumbency for testing of the myotatic reflexes and is often carried out before those tests. The temperament and anxiety level of the animal can render evaluation of muscle tone difficult. Muscle tone is usually depressed by lesions of the reflex arcs but may be increased by lesions of the higher centres or their pathways (upper motor neurone lesion). Muscle mass can be assessed subjectively by palpation, particularly by comparing one side of the animal with the other. It can be helpful to assess each limb by palpation with both left and right hands in order to detect subtle changes. Experience of normal muscle mass in animals of different ages and breeds is invaluable.

Spinal reflexes

These reflexes are tested with the animal in lateral recumbency. It is important to relate the character of the responses to the temperament and anxiety level of each individual animal. Two types of spinal reflex are tested: the myotatic (stretch) reflexes and the withdrawal reflexes.

MYOTATIC REFLEXES

These are assessed by sharply tapping the muscle or its tendon with a patellar hammer (plexor) or alternative implement and observing the reflex contraction of that muscle. The leg to be tested is usually the upper leg (i.e. away from the table) but it can be of value to test each limb in both positions. The myotatic reflex is monosynaptic and dependent on intact sensory mechanisms (muscle spindles), afferent neuronal pathways, efferent pathways, neuromuscular junction and muscle function. The presence of an intact reflex indicates that the entire arc is



Figure 3.2 Testing the patellar reflex using a patellar hammer.

functional but gives little indication of the state of pathways to and from the higher centres (Figures 3.2 and 3.3).

Myotatic reflexes can be graded as absent, reduced, normal, hyperactive, or showing clonus (repeated contraction of muscle in response to a single stimulus). These are often scored from 0 to 4. An increased response is often observed if there is a lesion cranial to the arc under assessment (upper motor neurone lesion) and

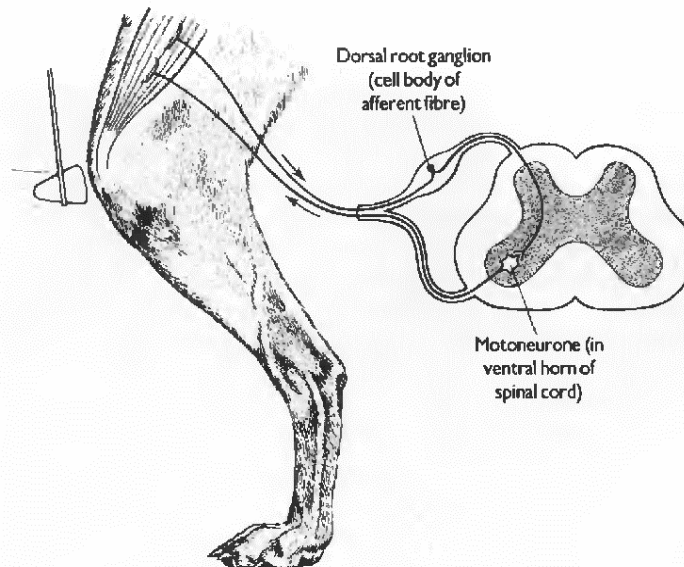


Figure 3.3 Diagram of quadriceps tendon reflex. Sensory impulses are conveyed through afferent fibres entering via the dorsal root; motor impulses are conveyed through the efferent fibres leaving via the ventral root.

Table 3.1 Commonly assessed muscles and their nerves

<i>Muscle</i>	<i>Nerve</i>	<i>Cord segment*</i>
Quadriceps (patellar reflex)	Femoral	L4–L6
Cranial tibial	Peroneal	L6–7
Gastrocnemius	Tibial	L7–S1
Triceps	Radial	C7–T1
Extensor carpi radialis	Radial	C7–T1
Biceps	Musculocutaneous	C6–8

* There is some variation in contribution by various nerve roots to the brachial and lumbosacral plexuses and their respective peripheral nerves between individual animals.

also occasionally if there is weakness in opposing muscle groups – this is most commonly observed in animals with weakness in the hamstring muscles as a consequence of lumbosacral disorders, which often demonstrate apparently hyperactive patellar reflexes. A decreased response indicates a lesion in part of the arc under assessment (this part cannot usually be determined by physical examination alone).

Many myotatic reflexes are available for examination in the small animal patient. However, the patellar reflex is the only one that can be obtained consistently in all animals and its absence is always abnormal. Absence of other myotatic reflexes may be suggestive of a reflex arc disorder, especially when the reflex differs from that on the contralateral limb, but cannot be regarded as definitely abnormal.

The commonly assessed muscles and their respective nerves are shown in Table 3.1.

Flexor reflexes

These reflexes are also 'local' but because they involve activation of several muscles are dependent on the integrity of a slightly larger area of the spinal cord. The receptor organs in this reflex are mainly free nerve endings in the skin which are responsive to various stimuli such as pressure, heat and cold. The flexor reflex is assessed in each limb in turn by pinching the skin of the foot with fingers or forceps; the ability of the animal to withdraw the foot from the stimulus is evaluated. It is important to assess the strength and degree of flexion at each joint in the leg, i.e. the hip, stifle and hock in the pelvic limb and the shoulder, elbow and carpus in the thoracic limb. At the same time as this reflex is examined the conscious response to pain and the presence or absence of the crossed extensor reflex (see below) can be evaluated.

The flexor reflex in the pelvic limb allows evaluation of the sciatic nerve and relevant spinal cord segments; that in the thoracic limb allows evaluation of spinal cord segments C6–T2 and the nerves originating there.

ANAL REFLEX

This reflex is elicited by stimulation of the perineal region by light touch, or by digital pressure on the bulb of the penis or vulva. The normal response is contraction of the anal sphincter muscle and flexion of the tail. The S1–S3 spinal

cord and associated nerve roots and nerve (pudendal) are involved in this reflex. Evaluation of the tone of the muscle of the anal sphincter (by rectal palpation) can aid in recognition of subtle changes.

Postural reactions

Postural reactions are complex responses that maintain the animal in a normal upright position. Abnormalities in these tests may result from lesions 'locally' (i.e. within the reflex arcs at that level – the lower motor neurone lesion), or lesions in the ascending or descending pathways running between the spinal neurones and centres within the brain (upper motor neurone lesion).

Several methods are used in assessment of postural reactions; it is preferable to perform these tests on a non-slip surface, especially when dealing with large-breed dogs.

CONSCIOUS PROPRIOCEPTIVE POSITIONING REACTIONS

The term 'conscious' is used because the pathways involved in this response eventually reach the sensory cortex of the contralateral cerebrum.

One method of testing proprioceptive (position sense) function is simply to turn the toes of the foot over onto their dorsal surfaces. A normal animal will react by turning the paw immediately to take weight in a normal position. Any delay in this response can be considered abnormal (Figure 3.4). (This response could arguably be due to tactile stimulation of the paw dorsum rather than true proprioceptive information.)

A second method to test proprioceptive function is to place the foot onto a piece of paper or card and slide it slowly laterally. Normal animals will tolerate only very



Figure 3.4 Dog exhibiting 'knuckling' of the digits – an abnormal response owing to depression of conscious proprioception.

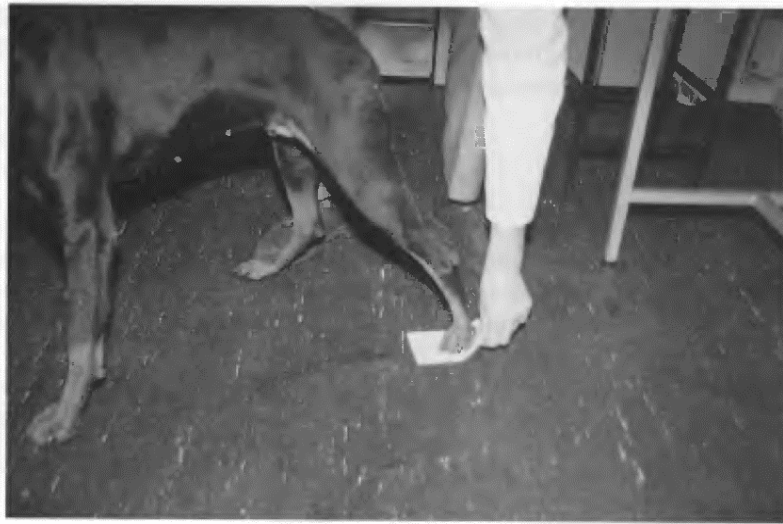

Figure 3.5 Sliding paper test. The normal animal will very quickly lift foot as paper moves laterally.

slight abduction of the limb before lifting and replacing the foot in a normal position (Figure 3.5).

In larger dogs, the 'sway response' can also be useful. The examiner attempts to push the dog to one side and, as the animal resists, the sideways pressure is suddenly released. The normal individual will quickly replace the feet into positions appropriate for the animal to remain standing and abnormal animals will sway or stumble to the side.

Nerve fibres involved in these responses include the large-diameter heavily myelinated fibres of the dorsal and dorsolateral columns which are very sensitive to compressive (and some other) injuries. Consequently, abnormalities of conscious proprioception are commonly observed in even relatively mild compressive lesions of the spinal cord.

WHEELBARROWING (THORACIC LIMBS), EXTENSOR POSTURAL THRUST (PELVIC LIMBS), HOPPING, HEMISTANDING AND HEMIWALKING

These tests evaluate the ability of the animal to initiate and coordinate movement of various combinations of limbs. Subtle deficits in coordination may be more easily detected during these tests than during simple observation of ambulation. Furthermore, an estimate of limb strength is possible when the animal is made to bear all the weight on a limited number of limbs. Deficits in these responses may be a result of either sensory or motor dysfunction, which may be due to abnormality in either local reflexes or central pathways (Figures 3.6 and 3.7).

Sensory tests

Tests of sensory function in animals are limited to modalities of proprioception and pain; unfortunately, the tests described also rely on intact motor pathways and do not evaluate the sensory pathways alone. Proprioceptive responses are included in



Figure 3.6 *Wheelbarrowing.*



Figure 3.7 *Extensor postural thrust response.*

the preceding section on postural reactions. Tests of pain sensation are very important in evaluating the severity of a spinal cord lesion.

SUPERFICIAL SENSATION

This can be assessed by pinching the skin or by light pin-pricking on various areas of the body. For the animal to demonstrate intact sensation, there needs to be objective evidence of conscious perception of the stimulus, that is a cranial response such as crying, or attempting to bite the examiner. The presence of a withdrawal reflex in response to skin stimulation merely demonstrates that the local reflex arc is intact. The pathways to the brain involved in conscious perception of superficial skin sensation consist of large-diameter myelinated fibres which are relatively sensitive to compression injury.

DEEP PAIN RESPONSE

In testing this response a strong, painful stimulus, such as artery forceps compression, is applied to an area of the foot, toe or tail; the normal response is to attempt to avoid the stimulus, vocalizing or attempts to bite (Figure 3.8). *A flexor reflex in response to this stimulation does not indicate intact pain sensation.* Should intact superficial sensation be present it is not necessary to carry out this test, as it is implied that the pathway involved in the deep pain response will also be intact. A lesion in either the peripheral or central pathways can be responsible for failure of normal response. If the local reflex arc has been determined to be intact (i.e. flexor reflex is intact) and there is absence of deep pain response, then failure of the central pathways is implied. The neuronal pathway thought to be responsible for transmission of this modality (spinothalamic tract) is the most resilient to be assessed;



Figure 3.8 Assessment of deep pain with artery forceps. The animal is closely observed for evidence of a response at the head. Deep pain can also be assessed using more severe compression (see text).

consequently, abnormalities in central conduction of deep pain stimuli are associated with severe, and thus prognostically grave, lesions.

Bladder function

Abnormality in bladder function is encountered in association with many spinal lesions (Figure 3.9). Much information regarding abnormalities can be obtained by close questioning of the owner, such as the ability of the animal to urinate properly, the quality of the urine stream and its frequency, and whether the animal will urinate in a correct environmental location. During a neurological examination the bladder tone and resistance to emptying can be evaluated by palpation. Lesions causing depression in anal reflex or tone are often associated with depression in bladder sphincter tone.

Neurogenic disorders of bladder function can be divided into lower and upper motor neurone types. Lesions of the sacral spinal cord, cauda equina or related nerves produce a lower motor neurone bladder. Detrusor contraction is abolished which allows accumulation of large volumes of urine. In severe lesions the external bladder sphincter will also be paralysed. However, the internal sphincter, which is innervated via the hypogastric nerve originating in the lumbar spinal cord, is not affected (unless that area of the cord is also injured). Therefore the bladder may be either easily expressed or show resistance to emptying. Overflow incontinence will usually result.

Lesions affecting any part of the nervous system between the pons and the sacral spinal cord can result in production of an upper motor neurone bladder. In this condition the urethral sphincters will usually become hypertonic, thereby rendering the bladder difficult to express. Furthermore there is a loss of coordination between the relaxation of the sphincter and contraction of the detrusor which is required for normal micturition to take place. Over a period of time, usually several days, an upper motor neurone bladder will usually exhibit reflex emptying in response to bladder distention. This reflex is mediated via the sacral spinal cord segments and is usually not well developed enough to cause complete bladder emptying.

Long-term bladder distention from any cause can lead to damage to the detrusor muscle and result in detrusor atony. Affected animals will have huge, flaccid bladders which are full of urine; overflow will also occur.

Other responses

CUTANEOUS TRUNCI MUSCLE (PANNICULUS) REFLEX

This reflex is used primarily as an aid to localization of a lesion. The reflex is initiated by pin-prick or pinch of the skin on the flank, cranial to the wings of the ilia. A normal response is a twitch of the cutaneous trunci (panniculus) muscle on both sides of the animal, and sometimes a cranial response. The reflex pathway includes skin receptors, whose axons enter the related segment of the spinal cord via the dorsal roots. The impulses are relayed cranially through the spinal cord white matter to synapses on lower motor neurones at the C8-T1 region, from which originates the lateral thoracic nerve, which is responsible for innervating the

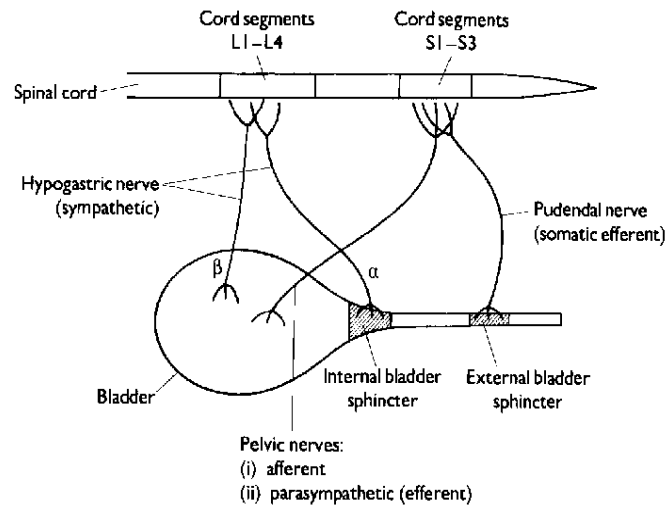


Figure 3.9 Diagram of nerve supply to the bladder (simplified). This local circuitry is also under control from centres in the brain. The pelvic nerves contain both afferent (sensory) and parasympathetic (efferent) fibres. The sympathetic supply to body of bladder (β) is inhibitory but sympathetic supply to 'sphincter' (α) is stimulatory.

cutaneous trunci muscle (Figure 3.10). A 'cut-off' of this response is commonly observed in thoracolumbar lesions, i.e. caudal to a certain point on the lumbar or thoracic skin the response is absent. Absence of this reflex at a certain level can be helpful in determining the level of transverse thoracolumbar spinal cord lesions. It must be remembered that the afferent nerves course cranially before entering the spinal canal; consequently, the location of the 'cut off' of the response on the skin will be somewhat caudal to level of the spinal lesion. The cutaneous trunci muscle reflex is normal in animals that have lesions caudal to the L1 spinal cord segment.

The efferent arc can sometimes be affected if there is a lesion in the caudal part of the cervical intumescence or its associated nerve roots (i.e. lesion of C8/T1 or lateral thoracic nerve).

BABINSKI (EXTENSOR TOE) REFLEX

With the animal in lateral recumbency, the caudolateral aspect of the distal limb (hock or carpus to digits) is stroked with a firm implement. Normal animals will either not respond, or will slightly flex the digits. An abnormal response is extension of the digits. The pathway involved in this reflex is not known but abnormalities are observed if there is a lesion of spinal cord tracts. An abnormal Babinski response is commonly observed in dogs which have degenerative myelopathy.

CROSSED EXTENSOR REFLEX

The crossed extensor reflex is an abnormal response in which there is a concurrent extension of the contralateral limb while the tested limb flexes during flexor reflex testing. This reflex is not observed in normal animals in lateral recumbency. There

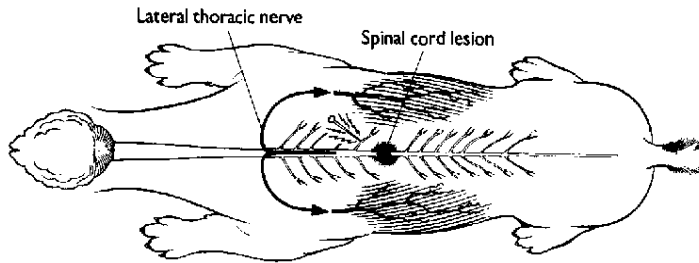


Figure 3.10 Diagram of cutaneous trunci muscle reflex. The afferent arm of the reflex is transmitted via the spinal cord. A response to stimulation will occur cranial to the lesion (illustrated) but not caudally.

can be difficulties in interpretation of this test owing to possible confusion with voluntary efforts made by the animal in attempts to resist restraint. The presence of a crossed extensor reflex is considered to be evidence of a lesion of central pathways and is most commonly found in association with long-standing lesions.

SCHIFF-SHERRINGTON PHENOMENON

Following acute injury to the thoracolumbar spinal cord, this specific syndrome of paraplegia with concurrent thoracic limb hypertonia can occur. The pelvic limbs are frequently hypotonic. Postural reaction testing of the thoracic limbs will reveal normal responses, although there may be hypertonia. The syndrome results from the interruption of inhibitory pathways ascending from the lumbar spinal cord to terminate in the area of the cervical intumescence. This syndrome is usually associated with severe cord lesions but does not necessarily imply a hopeless prognosis.

Palpation of the spine

Following examination of the reflexes and responses it is useful systematically to palpate the entire spine. This is usually best carried out from caudal to cranial. Deep palpation of the transverse and spinous processes and ventrally directed pressure are helpful in most areas of the spine. Manipulation of the spine in flexion, extension and laterally can also be carried out and is most useful in assessment of the cervical region. During careful examination it is often possible to locate accurately areas of increased sensitivity (hyperaesthesia). Localization by this means is more likely to be inaccurate in animals of nervous disposition.

Examination of the head

Following the systematic examination of the spine and reflexes described above, the cranial responses should also be examined. This consists of evaluation of the cranial nerve reflexes, plus assessment of mentation and other neurological responses. A detailed description of evaluation of the cranial responses is beyond the scope of this text but some major features are summarized in Table 3.2.

Table 3.2 Cranial nerve reflexes and other head-related responses.

<i>Brain Region</i>	<i>Symptoms</i>	<i>Test</i>	<i>Abnormal response</i>
Forebrain (thalamocortex)	Seizures	-	-
	Mood change	History	-
	Dementia	Observation	
	Circling	Observation	
	Paresis/ataxia	Postural reactions	Poorly initiated limb movement, misplacement of feet knuckling of toes
	Visual dysfunction	Menace response Obstacle course	No eye blink Bumps into obstacles
	Auditory dysfunction	Fixation response Response to noise	Fails to fixate moving objects Fails to localize source of sound (but does respond)
Brain stem (midbrain, hindbrain) ^a	Depression	Observation	May be severely depressed/comatose
	Paresis/ataxia	Postural reactions	As above
	Cranial nerve deficits	See below	See below
Cerebellum	Dysmetria	Postural reactions	Poor hopping, hemiwalking but CP tests usually normal
	Head bobbing	Observation	
	Intention tremor Ataxia	Observation	

<i>Cranial nerve</i>	<i>Symptoms</i>	<i>Test</i>	<i>Abnormal response</i>
I (olfactory)	Anosmia ?Depressed appetite	Observe response to smell of food while blindfolded	Fails to respond (sense of smell is difficult to test objectively)
II (optic)	Blindness Dilated pupil(s)	Menace response Obstacle course Fixation response Pupillary light reflexes (PLR)	No blink Bumps into obstacles Failure to fixate gaze on moving objects In abnormal eye, pupil fails to constrict in response to light
III (oculomotor)	Dilated pupil Ventrolateral strabismus	PLR Observation Head movement	Failure of affected pupil to constrict in response to light Abnormal eye movements
IV (trochlear)	Dogs – none Cats – slanted pupil	Observation of pupil +/- or retinal vessels Head movement	Dorsal aspect of pupil (or superior retinal vein) deviated laterally Poor rotatory eye movements
V (trigeminal) Motor	Muscle loss in temporal region ?Corneal ulceration	Palpation, observation Resistance to mouth opening Light touch around face – medial + lateral eyelids – ear – corneal aesthesiometry	Muscle wasting (masticatory muscles only) Reduced jaw muscle tone Absent blink response (or other avoidance) Depressed corneal sensitivity
Sensory			
VI (abducens)	Medial strabismus	Observation Vestibular eye movements	Poor laterally directed eye movement
VII (facial)	Facial drooping Enlarged palpebral fissure (acute)	Assess tension in lip commissure Touch face Brush ear	Weakness Absent blink response Absent ear flick response

Table 3.2 (continued)

<i>Cranial nerve</i>	<i>Symptoms</i>	<i>Test</i>	<i>Abnormal response</i>
VIII Cochlear	Deafness	Response to noise BAER	No response if bilateral (unilateral difficult to detect) Absence of components of waveform
Vestibular	Head tilt Nystagmus Strabismus	Observation Observation Response to various head positions or movement	More likely to be exhibited in darkened room Spontaneous drifting of eye position, rapid correction Non-conjugate eye movement or position
IX (glossopharyngeal)	Dysphagia	Gag reflex	Absent/reduced retching
X (vagus)	Dysphagia Dysphonia	Gag reflex Listen to breathing Observe larynx under GA	Reduced response Increased stridor Poor abduction of vocal folds/arytenoids
XI (spinal accessory)	Wasting of trapezius plus sterno cleidomastoid muscles	Palpation	Very rarely detected/detectable clinically
XII (hypoglossal)	Weakness or drooping of tongue	Observe licking + other tongue movements	Tongue deviates to affected side, muscle atrophy
Sympathetic nerve supply to eye (Note b)	Horner's syndrome: - pupil constriction (miosis) - enophthalmous - drooping of upper lid - erythema of conjunctiva	Observation Pharmacological testing	In darkened room, anisocoria is more pronounced May help in localizing site of lesion

^a Cranial nerve signs may be found together with depression or paresis and ataxia in cases of brain stem disease.

^b Sympathetic nerve supply to eye is not a true cranial nerve. Horner's syndrome may arise due to lesions which do not affect the head.

Examination of the pupils is of particular importance in evaluation of animals with spinal disease, especially if involvement of the cervical and cranial thoracic levels is suspected. This is because of the possibility of damage to the long pathway involved in supplying sympathetic function to the eye. Axons from the brain run caudally within the spinal cord to synapse at T1–T3 in the intermediate grey matter; subsequently fibres return cranially via the sympathetic trunk and, via a second synapse in the cranial cervical ganglion, are distributed to the eye. Lesions at any of these levels can cause Horner's syndrome, which characteristically consists of miosis, ptosis, globe retraction and subsequent prolapse of the third eyelid, although all features are not equally prominent in every case. Pharmacological testing with 10% phenylephrine, or the finding of other neurological deficits can aid in identifying the affected level.

Localization of lesions

Following neurological examination it should be possible to determine in which of the major functional divisions of the nervous system the lesion or lesions could be located. Depression of any of the normal responses or reflexes indicates disease in some part of the nervous system. If the abnormality is in the postural reactions, localization is not possible without knowledge of the state of the local reflexes. If these are intact, the lesion is in the central pathways, i.e. cranial to that spinal cord segment. If the local reflexes are depressed then there is a lesion in that reflex arc. By assessment of both thoracic and pelvic limbs the location of the lesion to one of the categories can be deduced. Difficulties can arise in multifocal disease in which a reflex arc abnormality can mask a concomitant central pathway lesion, as absence of the local reflex will also cause abnormality of the postural reactions (see Figure 8.1). It is particularly important to be aware of this possibility in cases of spinal trauma or infectious disease because multiple lesions are likely. In general, attempts are made to explain all abnormalities by a single lesion, if this is not possible then a multifocal disease process must be assumed.

The following signs are associated with lesions at defined spinal segments (not all signs will be exhibited by each affected animal):

- (1) C1–C5. Tetraparesis/tetraplegia or hemiparesis/hemiplegia; ataxia; no 'head' signs; Horner's syndrome; limb reflexes intact or hyperactive.

Summary: UMN lesion to all four legs, with normal head.

The absence of 'head' signs is particularly important to determine if a lesion in this segment is suspected, as the signs associated with certain brain lesions can be very similar.

- (2) C6–T2. Tetraparesis/tetraplegia or hemiparesis/hemiplegia; ataxia; thoracic limb reflexes depressed or absent; pelvic limb reflexes intact or hyperactive; Horner's syndrome; depressed/absent cutaneous trunci reflex (efferent portion).

Summary: UMN to pelvic limbs, LMN to thoracic limbs.

Some animals, in particular 'wobbler' Dobermann pinschers, may exhibit an unexpected increase in tone of the thoracic limb extensors with lesions at this level. This is thought to be the result of the reduction of flexor muscle tone

which occurs in association with lesions of the more cranial parts of the cervical intumescence.

- (3) **T3–L3.** Paraparesis/paraplegia or monoparesis/monoplegia; pelvic limb ataxia; thoracic limb reflexes normal; pelvic limb reflexes normal or hyperactive; loss of part of cutaneous trunci reflex (afferent); sensory loss of varying degree in hindquarters; abnormalities of micturition (dyssynergia); Schiff–Sherington phenomenon.

Summary: UMN to pelvic limbs, normal thoracic limbs.

Localization within this level is carried out by examination for evidence of pain, or by evaluation of the cutaneous trunci muscle reflex.

- (4) **L4–caudal.** Pelvic limb ataxia; paraparesis/paraplegia or monoparesis/monoplegia; depressed/absent pelvic limb reflexes; sensory loss of varying degrees and areas; abnormalities of micturition (atony of bladder); weak tail; anal tone depression.

Summary: LMN to hindquarters, normal thoracic limbs.

Localization within each of the C1–C5 and T3–L3 categories is carried out by careful palpation to examine for areas of hyperaesthesia. However, this is not a feature of all disease processes, and greater specificity of localization may not be possible. In the large T3–L3 segment, the cutaneous trunci reflex may be helpful in determining the exact level affected. However, in some mild lesions this reflex is not affected at any level, and lesions caudal to L1 do not interfere with the reflex. Within the C6–T2 and L4–caudal segments, more precise localization of the lesion may be possible by ascertaining which of the reflexes are abnormal. In dealing with the L4–caudal segment, it must be remembered that the cell bodies of these spinal nerves are located a long way cranial to their eventual exit from the vertebral canal; therefore, there is a large area in the vertebral column in which these nerves can be damaged.

Surgical spinal disease

In general, spinal surgery is concerned with the elimination or reduction of compression of neural tissue. Certain features of spinal cord compressive disease may be apparent on neurological examination, which can help to indicate the presence of a lesion likely to be amenable to surgical therapy:

- (1) Location/signalment – because of the high frequency of certain disorders in certain areas of the vertebral column and the high frequency in certain breeds, a surgical lesion may be expected, e.g. acute thoracolumbar (T3–L3) lesion in a middle-aged Dachshund suggests acute disc extrusion.
- (2) Localization to a very limited area of the cord (i.e. transverse myelopathy) – compressive lesions are not usually extensive in the cranial–caudal dimension.
- (3) Pain – many compressive lesions are painful; this applies to epidural lesions in particular, in which pain is often a major feature. However, inflammatory lesions may also be painful.

Conversely, lesions which are widespread, or multifocal, are more likely to be caused by inflammatory or infectious processes and are less likely to be amenable to surgical treatment.

Following the assessment of history, physical and neurological examinations, it should then be possible to make a tentative diagnosis, or to formulate a list of different diagnoses. This should include the location(s) of any spinal disease and possible aetiologies for such signs at each location. The plan is formulated at this stage and consideration is given to the means of attaining the diagnosis, and/or definitive therapy for the lesion – the diagnostic tests likely to be of most value should be carried out first. The finding of clinical signs consistent with surgical disease should prompt the use of imaging techniques to define clearly the exact site of such a lesion. If clinical findings suggest that inflammatory disease is a more likely problem, then blood sampling or CSF analysis would be a more appropriate first step.

A further consideration should be the wishes of the owner, such as whether they would wish for surgical (or other) treatment of the condition to be carried out. If surgery is not to be an option, the need to make a precise diagnosis must be carefully weighed up in relation to the possible hazards of the necessary diagnostic work. A consideration from the surgeon's point of view is, if a surgical lesion is discovered, whether the condition and its history of progression/regression, would warrant surgical intervention in any case. A large number of spinal disorders are self-limiting and do not necessarily need surgical intervention. There is no purpose in pursuing a diagnosis that will not alter the treatment offered to the patient.

Associated reading

- Braund K.G. (1985) Localizing lesions using neurologic syndromes – 2. spinal cord syndromes. *Vet. Med.* **80**, 54.
- Braund K.G., Shores A., Brawner W.R. (1990) Localizing spinal cord lesions through recognition of neurologic syndromes. *Vet. Med.* **85**, 692.
- Chrisman C.L. (1991) The neurologic history/The physical and neurologic examinations. In: Chrisman C.L. (ed.) *Problems in Small Animal Neurology*. Philadelphia, Lea and Febiger, pp. 25–72.
- Gilmore D.G. (1983) Cervical pain in small animals: differential diagnosis. *Comp. Cont. Educ. Pract. Vet.* **5**, 953.
- Griffiths I.R. (1982) Spinal disease in the dog. *In Practice* **4**, 44.
- Hackner S.G. (1992) Paresis and paralysis. *Comp. Cont. Ed. Pract. Vet.* **14**, 1179.
- Moore M.P. (1992) Approach to the patient with spinal disease. *Vet. Clin. N. Am.* **22**, 751.
- Moreau P.M. (1982) Neurogenic disorders of micturition in the dog and cat. *Comp. Cont. Ed. Pract. Vet.* **4**, 12.
- O'Brien D. (1988) Neurogenic disorders of micturition. *Vet. Clin. N. Am.* **18**, 529.
- Oliver J.E., Lorenz M.D. (1983) Neurologic examination Chapter 3. In: Oliver J.E., Lorenz M.D. (eds) *Handbook on Veterinary Neurologic Diagnosis* 1st edn. Philadelphia, W.B. Saunders, p. 19.
- Oliver J.E., Osborne C.A. (1980) Neurogenic urinary incontinence. In: Kirk R.W. (ed.) *Current Veterinary Therapy VII*. Philadelphia, W.B. Saunders, p. 1122.
- Parker A.J. (1990) Principles of neurologic diagnosis. *Prog. Vet. Neurol.* **1**, 11.
- Pollock R.V.H. (1985) Anatomy of a diagnosis. *Comp. Cont. Educ. Pract. Vet.* **7**, 621.
- Pollock R.V.H. (1985) Diagnosis by calculation. *Comp. Cont. Educ. Pract. Vet.* **7**, 1019.

- Saidla J.E. (1978) Problem oriented medicine for the veterinarian. *J. Am. Anim. Hosp. Assoc.* **14**, 307.
- Shores A. (1984) The differential diagnosis of ataxia, paresis or paralysis in large breed dogs. *J. Am. Anim. Hosp. Assoc.* **20**, 265.
- Steinberg H.S. (1982) Myotatic reflexes. *Comp. Cont. Ed. Pract. Vet.* **4**, 895.
- Wheeler S.L. (1985) The approach to spinal disease in dogs. *Brit. Vet. J.* **141**, 222.
- Wheeler S.L. (1989) Diagnosis of spinal disease in dogs. *J. Small Anim. Pract.* **30**, 81.
-

CHAPTER 4

Ancillary Aids

Contents

<i>Introduction</i>	45
<i>Blood sampling</i>	45
<i>Radiography</i>	46
<i>Other imaging techniques</i>	57
<i>Cerebrospinal fluid (CSF) analysis</i>	60
<i>Electrodiagnostics</i>	61
<i>Associated reading</i>	61

Introduction

The preceding chapter dealt with the means of diagnosing the approximate site or sites of disease within the nervous system. The next stage in investigation and treatment of a spinal disorder is to attempt to diagnose the nature of the lesion responsible for the clinical signs. In order to define the exact site and/or nature of a lesion, ancillary aids are required. Definitive diagnosis most often relies on surgical exploration, histopathological examination of biopsy material, or both.

Blood sampling

Blood samples may be required for several reasons, either in order to try to make a definite diagnosis of a cause of a spinal disorder, or as a preoperative assessment of the animal's fitness for surgery.

Routine haematology and blood chemistry analysis are indicated before carrying out spinal surgery on aged animals in order to ascertain the state of the major organ systems. In certain breeds blood coagulation studies may be required before surgery is contemplated as there is a high incidence of clotting disorders, such as von Willebrand's disease in the Dobermann pinscher. The buccal mucosa bleeding time is generally the most useful parameter to measure and can be carried out during anaesthesia for radiography.

Specific tests on animals which have spinal lesions may include serology, such as measurement of canine distemper virus (CDV) or protozoal (*Toxoplasma* and *Neospora*) neutralizing antibody titres. In certain parts of the world, it may be necessary to measure antibody titres against a variety of other infectious agents including rickettsia and mycoses. When confusion with peripheral nervous system disease is a possibility, blood electrolytes, glucose concentrations and creatinine phosphokinase (CPK) activity should also be measured.

Radiography

Obtaining diagnostic images of a lesion is essential prior to decompressive spinal surgery. Furthermore, spinal imaging is an integral part of the diagnostic investigation of any animal in which a focal spinal lesion is suspected. Prophylactic surgery, such as fenestration of thoracolumbar discs, may be carried out without knowledge of which disc has been responsible for the animal's previous symptoms. However, diagnostic images of the area may be required in order to eliminate other causes of spinal dysfunction from consideration.

Certain specifications for X-ray machines are required in order to obtain good quality radiographs of the spine; these requirements are dealt with in Chapter 1. The ability to obtain high kV and mAs and the need for a grid (preferably Bucky) to minimize scatter are important factors.

Plain radiography

Plain radiographs may be sufficient to reach a 'working' diagnosis in some spinal conditions. An exact diagnosis is not always essential to enable appropriate treatment to be applied. In its place a working diagnosis, which provisionally rules out some of the possible differential diagnoses, is sufficient. For example, in ambulatory dogs with disease of T3-L3 segment, plain radiographs can help to rule out, provisionally, a diagnosis of discospondylitis or destructive tumour of the vertebral bodies. Many dogs presenting with this symptomatology have mild disc lesions that will respond to conservative therapy alone; further diagnostic efforts are not warranted unless more severe clinical signs are exhibited by the dog.

After localization of the lesion to within a certain spinal cord segment has been accomplished by neurological examination, that entire segment should be radiographed. This is best carried out by both survey and local views of this area. There is some difficulty in accurate assessment of a large area of the vertebral column on one view, owing to divergence of the X-ray beam which can cause loss of detail at the margins; therefore local views of only a few vertebrae are also required (Figure 4.1).

In general, survey views include about six vertebrae, whereas the local views will show only three. The detail on the local views is also enhanced owing to reduction of radiographic scatter. Local views of only one area may be required if the location of the lesion has already been deduced from the neurological examination, or of many areas if the neurological localization cannot be precisely made.

For radiography of any region, the vertebral column must be accurately aligned parallel to the X-ray film. In all but the most severely depressed patients, general anaesthesia is essential to enable good quality radiographs to be obtained. Both lateral and ventrodorsal views of the relevant area should be obtained. During lateral radiography, padding is required under the mid-cervical spine, under the ventral chest margin, between the hindlimbs, and often under the mid-lumbar spine (in thin individuals). For radiography of the cervical spine, the wings of the atlas should be carefully positioned perpendicular to the table. For radiographs of the caudal cervical spine, it is usually helpful to pull the thoracic limbs caudally, so as to minimize the overlay of the scapulae and their associated muscles. For

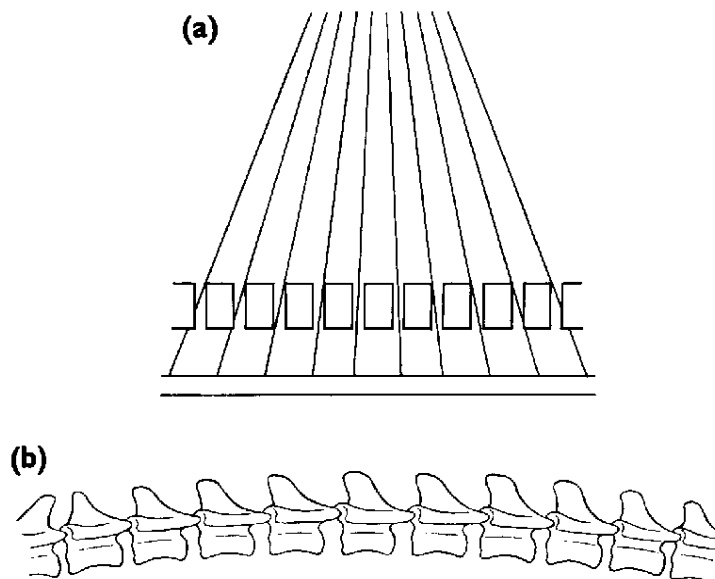


Figure 4.1 Divergence of X-ray beam (a) causes intervertebral spaces in the centre of the field to appear larger than those at the periphery (b).

lateral radiographs of the cranial thoracic spine the thoracic limbs are generally best pulled cranially and maintained in this position by use of calving ropes. When positioning for lateral radiographs of the thoracolumbar region, it is usually helpful to draw the thoracic limbs cranially and the pelvic limbs caudally. This minimizes the natural kyphosis of the region, which is especially marked in small breed dogs and in cats, and which can render interpretation more difficult. Lateral radiographs of the lumbosacral region should include flexed, neutral and extended views; care is required to avoid introducing rotation into these views.

For ventrodorsal views (preferred over dorsoventral views, as less distortion is introduced) a radiolucent cradle is useful. For ventrodorsal views of the cervical spine the endotracheal tube should be withdrawn to a position cranial to the point of interest to avoid introducing extraneous radiodense lines (Figure 4.2).

There are some special plain radiographic views which may be helpful in certain cases. For dogs in which a very lateralized disc extrusion is suspected, 45° oblique views will help to delineate extruded disc material in the foramen. Lateralized disc extrusions are most commonly observed in the cervical region and a 'cloud' of calcified disc material will be seen obscuring the margins of the foramen.

Rotated views of the cranial cervical spine can be helpful in diagnosing abnormalities in the size or shape of the dens of the axis. With the atlas rotated, its wings will not be superimposed on the dens allowing a clearer view (Figure 4.3). Care may be needed in placing an animal in this position if there is reduced stability at this site.

Observations to be made on plain radiographs

- Vertebrae number and shape
- Intervertebral disc space: width, shape, opacity

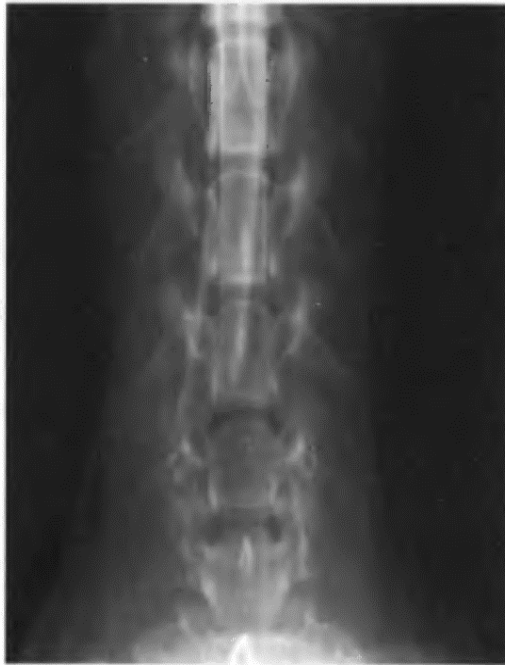

Figure 4.2 *Superimposed endotracheal tube renders myelogram difficult to interpret accurately.*

- Intervertebral foramen: size, shape
- Vertebral canal: alignment, width
- Vertebral body: size, shape, density
- Lysis or proliferation of bone
- Presence of fracture lines
- Presence of foreign bodies

Diagnosis of many spinal disorders can be made from plain radiographs alone, for example discospondylitis, congenital malformations and most fractures and




Figure 4.3 *Rotation of the head and atlas enables the dens of the axis to be clearly seen.*

luxations. Often, however, the significance of abnormalities detected on plain radiographs is uncertain and therefore contrast radiographs are indicated.

Myelography

Myelography is required in most animals for which surgical treatment is considered in order to demonstrate unequivocally the presence of a mass lesion. Previously, myelography has been considered hazardous, partly owing to the potential toxic effects of the contrast medium on neural tissue. Modern nonionic contrast media have greatly reduced these toxic complications, rendering myelography a relatively benign procedure. However, the risks inherent in myelography should not be overlooked.

INDICATIONS FOR MYELOGRAPHY

Myelography should only be undertaken if the findings will alter the treatment offered for the patient. If a course of action has been or can be decided without the information available from myelography it should not be performed. Often, however, the presence or absence of myelographic lesions will determine the future treatment offered for patients which have spinal disease.

The presence of positive contrast in the subarachnoid space causes the neural tissue to be outlined in negative, the spinal cord cannot be seen on routine plain radiographs. When so outlined, it is possible to ascertain on myelography whether there is compression and, frequently, it is possible to determine the anatomical relationship of the compressive lesion to the neural tissue.

Several broad indications for myelography can be given, prior to intended surgical treatment:

- if no lesion is visible on plain radiographs;
- if more than one lesion is visible on plain radiographs;
- to assess the significance of questionable changes observed on plain radiographs;
- if dynamic studies of certain conditions are required.

It is common to detect a variety of abnormalities on plain radiographs of the spine, such as congenital lesions, spondylosis and narrowed disc spaces. The significance of these lesions often needs to be assessed by myelography. The most frequent indication for spinal radiography is in the diagnosis of TL disc disease in dogs. On plain radiographs there are frequently many abnormalities in the area under assessment, e.g. narrowed disc spaces, spondylosis, calcification of the nucleus pulposus of several discs (Figure 4.4). It is often not possible to determine with absolute accuracy which disc is the cause of current problems by neurological examination or plain radiography. In this instance, myelography will help to provide the answer.

A special application of myelography is in the diagnosis of 'wobbler' dogs, or dogs which have lumbosacral disease. For these patients, flexed, extended and traction views during myelography can provide more detailed information about the exact type of compression present.

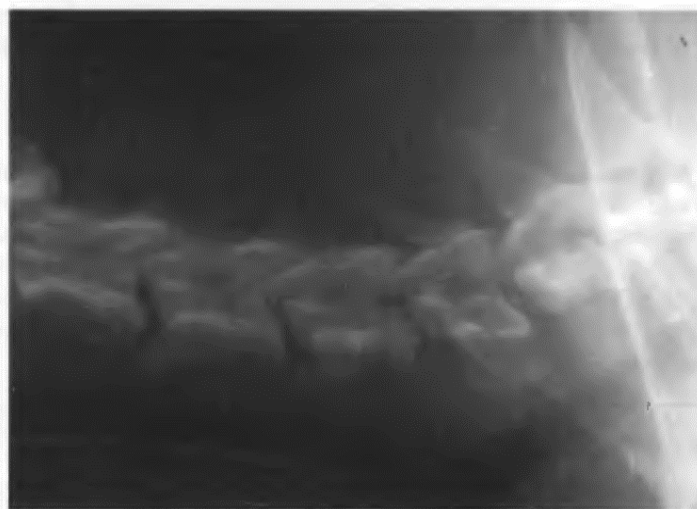

Figure 4.4 Multiple intervertebral disc lesions. The disc responsible for symptoms cannot be deduced from plain radiographs alone.

Familiarity with the normal myelogram is essential. The subarachnoid space varies a little in dimensions in various parts of the spinal cord. The spinal cord widens at the cervical and lumbar intumescences and is thinner in the caudal thoracic/cranial lumbar region. The appearance of the discs also varies; the widest are in the caudal cervical and the caudal lumbar regions. The ventral subarachnoid space is narrowed as it crosses many of the disc spaces, especially that between C2 and C3 (Figure 4.5). Normal myelograms are shown in standard anatomy texts.

Following myelography, the aim should be to diagnose the presence or absence of a compressive lesion and also to classify the lesion by its anatomical relationship to the neural tissue. It is of course essential that both lateral and ventrodorsal views of the area are obtained.

Three categories of lesion are recognized (Figure 4.6): extradural, intradural/extramedullary, and intramedullary. Classification into one of these anatomical groups is important because it is frequently suggestive of the cause of cord compression. This information needs to be evaluated in combination with the history of the clinical signs.

Extradural lesions include extruded disc material, haemorrhage/blood clots and lesions of the vertebrae themselves. With knowledge of the speed of onset of the disease a reasonable attempt at diagnosis can be made. However, this information must be very carefully evaluated as it is possible for extruded disc material to find its way into unusual positions relative to the cord – for instance dorsal to the dural tube. Extradural tumours are frequently malignant and are discussed in Chapter 8.

Intradural/extramedullary lesions are almost exclusively tumours, such as meningiomas or nerve sheath tumours.

Intramedullary lesions are of two types, either medullary swelling because of acute cord trauma or vascular injury with subsequent oedema, or enlargement due to an intramedullary tumour. Care must be taken to obtain a clear history in such

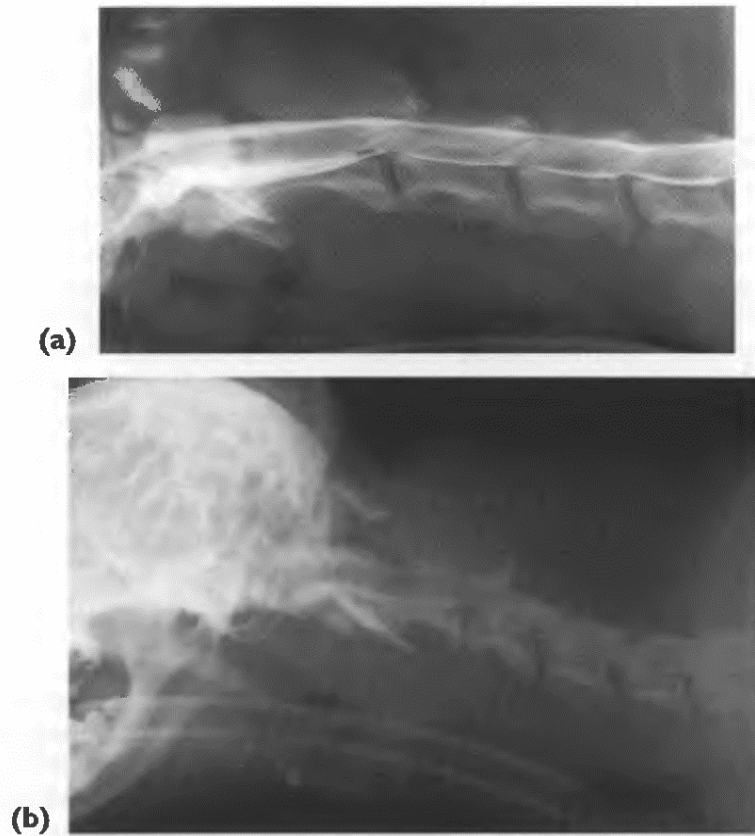


Figure 4.5 The intervertebral space at C2/C3 can be difficult to evaluate: (a) thinning of ventral contrast column is normal; (b) elevation of ventral contrast column is abnormal (caused by disc extrusion).

cases, as this is often the only way to distinguish the likely aetiology (without surgery or post mortem examination).

Although these categories of myelographic lesions are well recognized and described, there are many instances in which clear differentiation of a lesion into one of these categories is not possible. This is particularly a problem when dealing with intradural lesions, where it is often not possible definitely to describe a lesion as intra- or extra-medullary. Exploratory surgery is required in such cases. A further common finding is of extradural compression associated with (usually consequential) intramedullary swelling.

In addition to the information obtained on the relationship of a compressive lesion to the various meninges, it is usually possible to determine the size, shape and degree of lateralization. This information is invaluable when planning surgical intervention, especially if a lateral approach is to be considered.

The contrast agent for myelography can be introduced at one of two sites, either

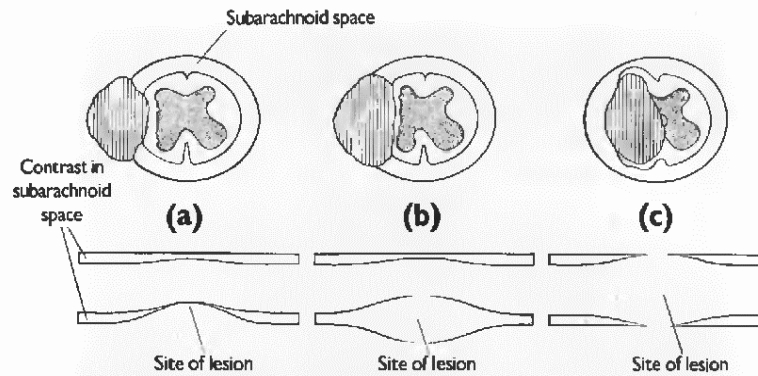


Figure 4.6 Appearance of spinal lesions on myelography depends on their relationship to the subarachnoid space. (a) Extradural lesion causes compression of the subarachnoid space from without. (b) Intradural/extramedullary lesions causes 'island' effect. (c) Intramedullary lesion causes contrast columns to 'flare' apart.

at the cerebellomedullary cistern, or via lumbar puncture (L4/5 or L5/6). On occasion it is necessary to use both routes in one animal.

CISTERNAL PUNCTURE

Cisternal puncture has the following advantages: introduction of needle is easier, and it is a more reliable route to obtain a CSF sample of diagnostic quality (i.e. not contaminated with blood). Its disadvantages are: potential damage to the medulla oblongata; it is potentially dangerous if intracranial pressure is elevated (may cause

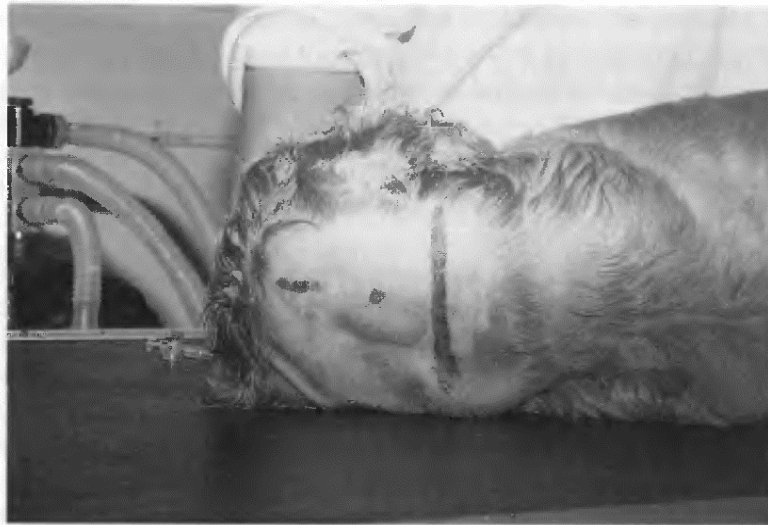


Figure 4.7 Site for cisternal puncture is found on the midline at a point midway between the external occipital protuberance and a line between the wings of the atlas. A dot marks the site of needle entry; horizontal line marks the external occipital crest and the perpendicular line joins the wings of the atlas.

brain herniation under the tentorium or through the foramen magnum); a sloping table is required for adequate contrast flow; and it may not be diagnostic in some cases owing to poor contrast flow.

The site of introduction of the needle is found by palpation of the wings of the atlas, and the external occipital protuberance of the skull. The site for introduction of the needle lies at the middle of the triangle formed by these reference points (Figure 4.7). Routine aseptic precautions should be taken, which conveniently includes wearing sterile surgical gloves. However, if the tip of the needle and the site of introduction are not touched, then an ungloved hand is satisfactory.

Volume of contrast agent to inject is about 0.4 ml/kg, up to a maximum of 10 ml, for the cisternal route. Contrast agent may be introduced with the animal in either lateral or sternal recumbency and should be injected slowly (over about 1 to 2 min) to minimize rostrally directed flow and to facilitate mixing with the cerebrospinal fluid. If the contrast is introduced too rapidly, the contrast column will become 'streaky' and therefore be poorly diagnostic. Head elevation is required after the contrast has been introduced in order to encourage caudally directed flow in the subarachnoid space and discourage flow into the cranium. This is usually achieved by sloping the radiographic table at approximately 15° to the horizontal.

The site of introduction of the needle is very close to the medulla oblongata and there is a potential for neural tissue to be damaged during this procedure, which can be catastrophic, causing vestibular syndromes, paresis or even death. This risk can be minimized by careful, slow introduction of the needle and by use of a spinal needle which contains a stylet. Although regular hypodermic needles can be used for myelography, they are liable to become blocked with tissue during introduction, making it difficult to realize when the subarachnoid space has been entered. Generally, entry into the subarachnoid space can be recognized when the needle 'pops' through and CSF will be readily obtained at the hub. Sometimes some blood will be found in the CSF. This can be disregarded if the CSF becomes clear with continued flow (although it may render the fluid unreliable for analysis – see below), and the contrast agent can be safely introduced. If blood contamination is severe and continues it is usually possible to withdraw the needle and replace it properly. The damaged vessels (branches of the internal venous plexus) lie outside the subarachnoid space and slightly lateral to the midline and laceration of these vessels is not dangerous in itself.

If the intracranial pressure is elevated, such as in multifocal disease involving intracranial structures, introduction of a needle at the cerebellomedullary cistern can allow rapid exit of CSF. This will cause a rapid pressure drop in the caudal part of the cranium and therefore possible herniation of the brain either under the tentorium cerebelli or through the foramen magnum with potentially fatal consequences. The potential for this complication must be carefully evaluated before cervical myelography, especially if the lesion is suspected to be in the cranial cervical segment (confusion with an intracranial lesion is particularly likely). Clinical signs suggestive of elevated intracranial pressure include dilation of the pupils, poor gag reflex and depression. Vestibular signs are also common in this group of patients. If there appears to be a substantial possibility of elevated intracranial pressure, the lumbar route of introduction should be selected in preference.

Introduction of contrast material into the skull is to be avoided as it is associated

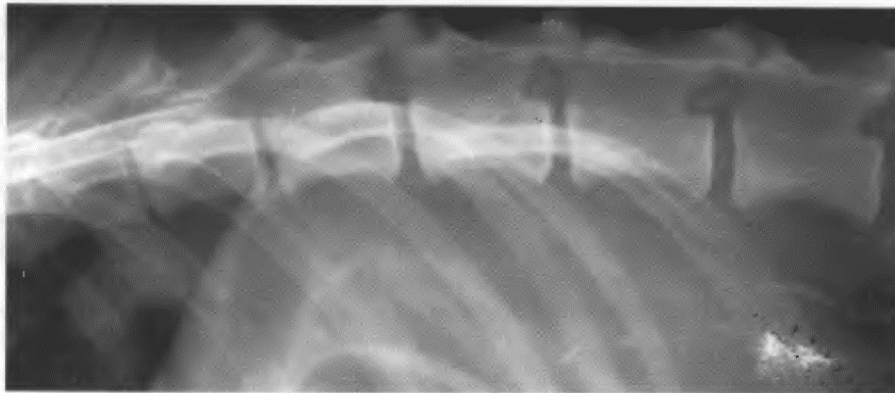


Figure 4.8 Failure of cisternally introduced contrast to completely fill subarachnoid space around thoracolumbar junction renders this myelogram non diagnostic of site or type of lesion.

with the development of post-myelographic seizures. The incidence of post-myelographic seizures has been greatly reduced following the widespread use of the nonionic contrast media but has still been reported to occur in approximately 10% of cases. Slow injection of contrast agent, with the needle bevel directed caudally and with the animal on a well-tilted table is the best way of avoiding this complication, followed by recovering the animal in sternal recumbency, with the head elevated (seizures are more likely when the contrast medium flows over the dorsal and lateral surface of the cerebral hemisphere). If seizures do occur, they can usually be controlled with a single intravenous bolus of diazepam (0.2 mg/kg) and there are usually no further seizures. Close observation of the patient following myelography is required for early detection of this complication.

The most common problem encountered with cisternal myelography is that the study can be non-diagnostic in certain cases. This is particularly common if there is a severe compressive lesion (either intra- or extra-durally) which can block the flow of contrast. The flow of contrast is dependent on gravity alone and so severe lesions may block the flow sufficiently to prevent proper diagnosis of the nature and location of the lesion (Figure 4.8).

Severe acute compressive thoracolumbar disease (commonly acute disc extrusions) may cause severe intramedullary swelling with consequent obliteration of the subarachnoid space over several spinal cord segments. In this instance the contrast column is frequently interrupted up to two or three vertebrae cranial to the site of the lesion. The cervical myelogram in such cases may be of some value to rule out a lesion at some of the disc spaces cranial to the obstruction but often a definite diagnosis is not possible. In some cases of neoplasia affecting the spine, contrast flow is poor because of severe extradural compression affecting a large segment and demarcation of the margins of the lesion may be impossible when relying on cervical myelography alone.

In some cases of cervical cord disease, a partial myelographic block is sufficient to cause poor contrast accumulation at the site of the lesion but will allow the bulk of the material to continue to flow caudally. Such studies are non-diagnostic. A solution to this problem is to elevate both ends of the animal with the site of interest at the lowest point and to allow the contrast to accumulate at this area

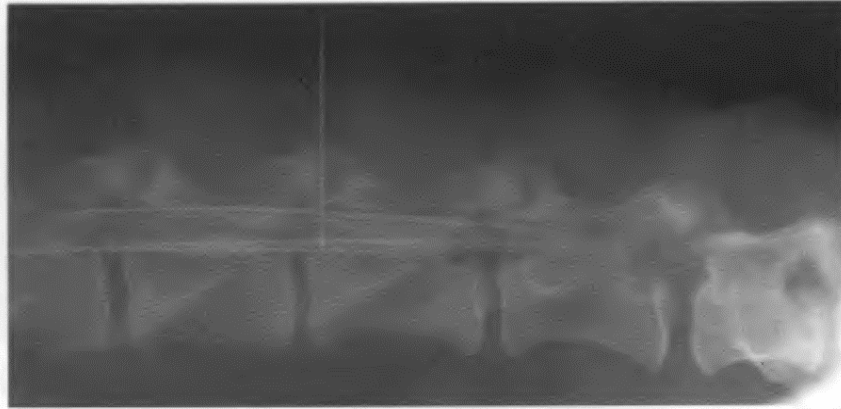


Figure 4.9 Spinal needle correctly placed for lumbar myelography. The L4/5 interspace is used because this dog is large. Note slight flexion of vertebral column.

for a few minutes before repeating the exposures. Care must be taken at this stage to avoid introducing contrast agent into the cranium.

LUMBAR PUNCTURE

Introduction of contrast agent at the lumbar site has the advantage that a good contrast flow can be achieved despite attenuation of the subarachnoid space. Its disadvantages are: introduction of the needle may be difficult, especially in large dogs; artefacts are more common; there is potential for injury of neural tissue.

The site for introduction of the contrast agent is usually at the L4/5 or L5/6 interspace. A fine needle is used (23–20 gauge), which must have a stylet. The needle is introduced parallel to the spinal processes and perpendicular to the long axis of the vertebral column, with the bevel directed cranially (Figure 4.9). The needle penetrates the neural tissue (during which a twitch of the anus and tail is frequently observed), and comes to rest on the floor of the vertebral canal. On removal of the stylet, flow of CSF, often with some blood contamination, is usually observed, although this may take some time (about 30 s) to appear, occasionally it is necessary to withdraw the needle about 1–2 mm in order to obtain CSF flow. The introduction of the needle can be carried out with the animal in either sternal or lateral recumbency and is facilitated by maximal flexion of the lumbar spine, which enlarges the interarcuate space. Contrast agent (up to 0.5 ml/kg, with a maximum of 10 ml) is introduced when CSF flow is observed and can be injected under moderate pressure. On occasions when CSF flow is not observed, it can be useful to give a test injection of about 0.5 ml to determine whether the needle is correctly situated – this is safe provided the needle tip is either resting on or very close to bone (to ensure that the needle bevel cannot be embedded within neural tissue). Injection of the contrast into the spinal cord is possible and can be catastrophic.

Major problems associated with this technique include difficulties in placing the needle correctly, oddly enough placement is usually easier in smaller animals

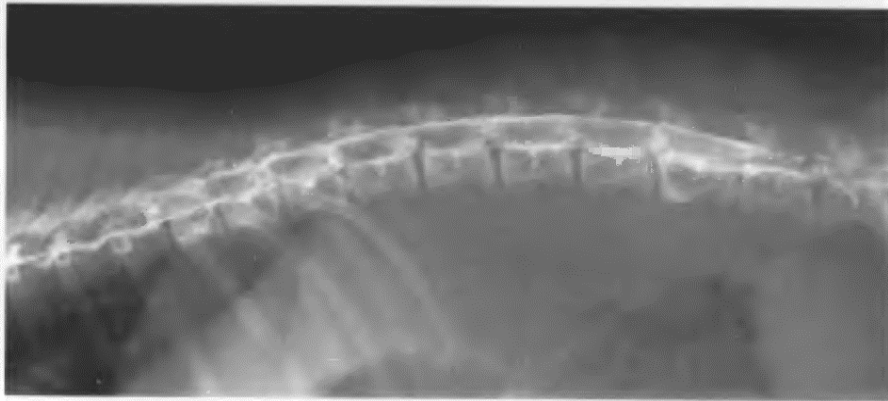

Figure 4.10 *Non-diagnostic lumbar myelogram resulting from inadvertant injection of contrast into the epidural space.*

(presumably any error in location of needle introduction at the skin surface is magnified in larger animals). Assessment of the precise anatomy of the region on lateral radiographs may be useful because of the degree of overhang of the spinous process over the relevant interspace is variable. Comparison with radiographs may help to orientate correct realignment of the needle during subsequent attempts.

The second main problem associated with this technique is the introduction of material into the epidural space rather than into the subarachnoid space. Many lumbar myelograms suffer from this artefact to some extent, which can sometimes render the image difficult to interpret (Figure 4.10). Usually, with time, the epidural component will disperse more rapidly than that in the subarachnoid space (owing to venous drainage) allowing proper interpretation later. The epidural component can be confusing when assessing the lumbosacral region in particular.

Lumbar myelography is superior in the demonstration of severe compressive lesions, especially in the thoracolumbar region, as the contrast medium may be injected under pressure, thereby ensuring adequate fill of the subarachnoid space. Even so, it is frequently necessary to make the first exposure quickly after the contrast has been introduced as rapid dispersal away from these areas will occur. Acute thoracolumbar cord injury is the most frequent indication for lumbar myelography and, in such cases, it is useful to be able to determine to which side the bulk of the disc material has extruded. Therefore it is prudent that the first view obtained following introduction of the contrast agent should be ventrodorsal.

SUMMARY

In conclusion, cervical myelography is preferred for cervical and lumbosacral imaging (as there is less problem with artefact) or if only mild compressive lesion is suspected. Lumbar myelography is preferred if:

- a severe thoracolumbar lesion is suspected,
- a cranial cervical lesion is suspected (because of danger in correct needle positioning or contrast introduction in such cases), or if there is a strong

suspicion of elevation of intracranial pressure. On occasion it may be necessary to introduce the contrast agent at both sites, e.g. when the full extent of a large lesion (often tumour) needs to be determined.

Other imaging techniques

Various other imaging techniques are available which may provide information not available from plain and myelographic studies. Only specialist units have the capabilities to carry out some of these techniques.

Epidurography

The main indication for this study is in the assessment of the lumbosacral region of the vertebral column. Myelography has been claimed by some authors to provide adequate imaging of the lumbosacral joint but in some animals, particularly those of the larger breeds, the dural tube is elevated from the floor of the vertebral canal cranial to the lumbosacral joint thereby rendering the myelogram non-diagnostic for lesions at that location. In a study comparing the diagnostic capabilities of various radiographic methods, epidurography was rated the best technique for evaluation of the low lumbar and sacral regions.

The technique is straightforward to perform; a needle is introduced through the interarcuate space at S3/Co1 or Co1/2 until it contacts the floor of the vertebral canal (Figure 4.11). Contrast medium (not necessarily nonionic) is injected at 0.15 ml/kg and radiographs obtained immediately. Both lateral and ventrodorsal views are useful, and it is often necessary to obtain both flexed and extended views to demonstrate dynamic compression of the dural tube. No complications have been reported following epidurography in the dog.

Lesions demonstrated by this technique include protrusion of the L7/S1 disc, tumours. Care must be taken to study the film for artefacts related to contrast introduction. False positive and false negative results are reported in both experimental and clinical studies of this technique.




Figure 4.11 Spinal needle correctly placed for epidurography.

Intraosseous vertebral venography

This technique can be used for evaluation of the lumbosacral region. It is more difficult to perform satisfactorily than epidurography and usually provides less reliable information. A bone marrow needle is introduced into the body of one of the most cranial of the caudal vertebrae; correct positioning is ascertained by obtaining marrow on aspiration. Contrast medium is introduced and radiographs obtained immediately. It is useful to apply compression to the abdomen during contrast injection as this will encourage the agent to remain in the venous sinuses rather than return to the caudal vena cava via the abdominal vessels.

This technique is rarely used nowadays as epidurography is more often diagnostic and simpler to perform.

Discography

This technique is usually reserved for diagnosis of protrusion of the L7 intervertebral disc. A spinal needle is introduced through the flaval ligament at the lumbosacral junction and advanced into the L7 disc. Radiographs are obtained to ensure correct positioning. Contrast agent is injected under pressure into the nucleus of the disc. Normal disc will not allow the introduction of much fluid, whereas an abnormal disc (i.e. with a protrusion) will accommodate up to 2–3 ml. Lateral and ventrodorsal views are obtained following contrast injection, and can clearly demonstrate the presence of a dorsally or dorsolaterally directed disc protrusion. This technique can be very useful, although a 13% false positive rate was found in a recent series of clinical cases. Furthermore, it is only effective in demonstrating a disc lesion. Should there be cauda equina compression due to neoplasia or other cause then that lesion will not be detected. For this reason, the technique should perhaps be considered as an adjunct to other diagnostic techniques at this level, unless there is clear evidence that a disc lesion is very likely to be the only cause of the animal's symptoms.

Ultrasonography

A recent article has described the use of intraoperative ultrasonography in both normal and cord-injured dogs. The technique enabled detection of fragments of extruded disc material in the vertebral canal, spinal cord compression and the presence or absence of normal cord pulsation. Follow-up ultrasound examination was possible after decompressive surgery. There is little experience with this technique at present, but there may be other applications, such as the intraoperative determination of the location and extent of intramedullary tumours.

Advanced imaging techniques

Access to computed tomography (CT) and magnetic resonance (MR) scanning facilities has become more widely available to veterinarians during the last few years and can provide useful information not available by other means.

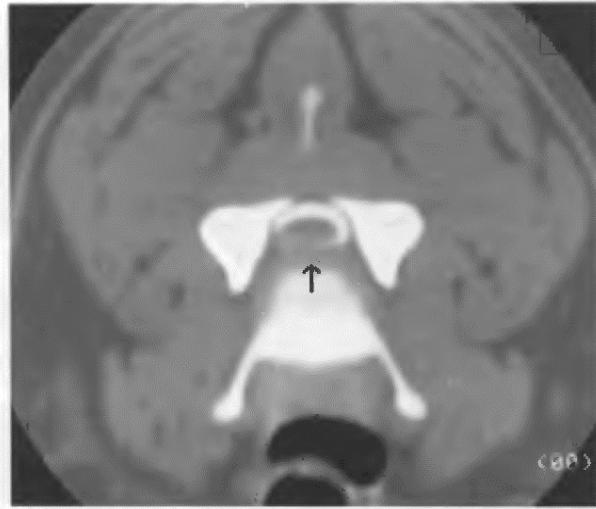


Figure 4.12 CT myelogram of wobbler dog. This cross-sectional view reveals severe spinal cord compression by ventral soft tissue mass – a type II disc protrusion (arrow). Courtesy of Dr J.V. Davies.

CT

CT is able to provide information on cross-sections of the spinal cord and vertebral column, which is not available from conventional radiographic techniques. CT is frequently used in the assessment of spinal disease in people but its use in animals is limited by poor definition of the spinal cord and nerve roots unless a contrast agent is used concurrently. However, plain CT examinations may be useful in the diagnosis of causes of stenosis of the vertebral canal or to obtain additional information on vertebral fractures. CT combined with myelography can provide useful information in dogs affected by the 'wobbler' syndrome (Figure 4.12).

After routine cervical myelography, the animal is scanned at the levels of interest. Lateral and dorsal compression of the cord is visible following this procedure, which may not be apparent on routine myelographic films, and can be used to suggest the approach to the spinal cord in order to alleviate the compression.

Lumbosacral CT scanning is carried out in a similar way. Its main use is in the diagnosis of nerve root compression within the intervertebral foramen.

MR IMAGING

MRI enables images of the spinal cord and vertebral column to be obtained in transverse, sagittal and dorsal planes. The advantages of this technique include the ability to produce excellent quality images without the need for introduction of potentially dangerous contrast agents. In humans, the technique is capable of diagnosing intramedullary lesions such as syringomyelia, which currently are not easily diagnosed in animals antemortem. In addition, it is possible to prognosticate based on the appearance of the spinal cord on MR images. The technique has not yet been widely used in animals owing to the relative lack of access to these

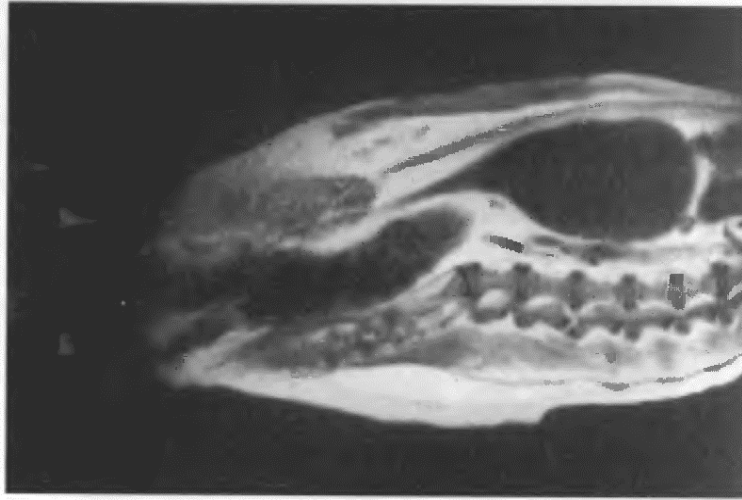


Figure 4.13 *Sagittal T1 weighted MR scan at the lumbosacral region in a German Shepherd dog. Note the detail visible in the discs and vertebral canal. Courtesy Mrs R. Dennis, Animal Health Trust.*

facilities, although its advantages in the diagnosis of lumbosacral disease in dogs have already been established. It is clearly a technique with a great deal of potential in diagnosis of spinal cord and vertebral lesions in small animal patients (Figure 4.13).

Cerebrospinal fluid (CSF) analysis

CSF analysis is useful in the diagnosis of inflammatory or infectious diseases of the spinal cord, meninges or brain. Suspicion of an inflammatory lesion is the most common indication for obtaining a CSF sample. However, a sample of CSF is obtained incidentally from any animal in which (cisternal) myelography is carried out and it is prudent to analyse this fluid. CSF obtained subsequent to myelography can also be used. The changes in CSF characteristics which are induced by myelography have been quantified but an uncontaminated sample is preferable.

CSF analysis can include protein concentration and red and white blood cell counts; normal values for each have been published elsewhere. In addition, it has been suggested that measurement of creatine phosphokinase (CPK) activity and glucose concentration may be of diagnostic value. In animals in which infectious disease is suspected, antibody titres in CSF can also be used to help in diagnosis, for instance canine distemper virus (CDV) titre. Culture of CSF samples can be used to identify bacterial or fungal causes of spinal disease, although these are rare. CSF culture is best carried out by obtaining a large volume sample (2–3 ml or more) and injecting it into a blood culture tube. It is prudent to discuss these tests with a microbiologist beforehand. On rare occasions, neoplastic conditions may be identified during examination of CSF, if there is exfoliation of neoplastic cells.

CSF obtained from either the cisternal and lumbar sites can be analysed; the

protein and cell content are slightly different at the two sites in normal dogs. It has been suggested that obtaining samples from both sites will increase the diagnostic yield of the technique.

The finding of increased white cell count suggests involvement of the meninges and greatly increased cell counts are found in animals that have meningitis. Care should be taken in the interpretation of mildly elevated cell counts or protein content in the CSF; these findings have been identified in animals afflicted with intervertebral disc disease and therefore should not be used as conclusive evidence of the presence of inflammatory or infectious disease of the neuraxis.

Electrodiagnostics

Several electrodiagnostic techniques may be useful in diagnosis of the site and severity of spinal disease. Simple needle electromyographic (EMG) examination can be of value in the identification of nerve root compression as a result of disc protrusion or tumours. This is most useful in cases of lumbosacral disease, in which there is often possible confusion with hip disease, and also in certain cases of the 'wobbler' syndrome, in which nerve root involvement may be apparent. In both instances, an abnormal EMG will define a lesion as involving a certain lower motor neurone (in the absence of other concurrent disease). In cases of lumbosacral disease, finding an abnormal EMG will strongly suggest significant nerve root compression. Abnormal EMG findings in the epaxial muscles can aid in the localization of transverse myelopathies but must be interpreted in the light of results of imaging studies.

Spinally evoked potentials have been used in attempts to evaluate more objectively the severity of compressive lesions. Both ascending (sensory) and descending (motor) pathways have been tested. To date these techniques have not been generally applied and have not been found to be of more value in the diagnosis of irreversible spinal cord injury than simple assessment of the pain responses.

Associated reading

Haemostatic testing

Jergens A.E., Turrentine M.A., Kraus K.H., Johnson G.S. (1987) Buccal mucosa bleeding times of healthy dogs and of dogs in various pathologic states, including thrombocytopenia, uremia, and von Willebrand's disease. *Am. J. Vet. Res.* **48**, 1337.

Radiography and myelography

Brawner W.R., Braund K.G., Shores A. (1990) Radiographic evaluation of dogs and cats with acute spinal cord trauma. *Vet. Med.* **85**, 703.

Fletcher TF. (1979) Spinal cord and meninges. In: Evans H.E., Christensen G.C. (eds), *Miller's Anatomy of the Dog*, 2nd edn. Philadelphia, W.B. Saunders, p. 935.

- Kirberger R.M., Roos C.J., Lubbe A.M. (1992) The radiological diagnosis of thoracolumbar disc disease in the dachshund. *Vet. Radiol. Ultras.* **33**, 255.
- Kirberger R.M., Wrigley R.H. (1993) Myelography in the dog: review of patients with contrast medium in the central canal. *Vet. Radiol. Ultras.* **34**, 253.
- Lewis D.D., Hosgood G. (1992) Complications associated with the use of iohexol for myelography of the cervical vertebral column in dogs: 66 cases (1988–1990). *J. Am. Vet. Med. Assoc.* **200**, 1381.
- Luttgen P.J., Pechman R.D., Hartsfield S.M. (1988). Neuroradiology. *Vet. Clin. N. Am.* **18**, 501.
- Middleton D.L. (1993) Radiographic positioning for the spine and skull. *Vet. Clin. N. Am.* **23**, 253.
- Owens J.M. (1982) The spine. In: Biery D.N. (ed.), *Radiographic Interpretation for the Small Animal Clinician*. St Louis, Ralston Purina, p. 69.
- Park, R.D. (1990) Diagnostic imaging of the spine. *Prog. Vet. Neurol.* **1**, 371.
- Prata R.G. (1977) Diagnosis of spinal cord tumours in the dog. *Vet. Clin. N. Am.* **7**, 165.
- Roberts R.E., Selcer B.A. (1993) Myelography and epidurography. *Vet. Clin. N. Am.* **23**, 307.
- Sande R.D. (1992) Radiography, myelography, computed tomography, and magnetic resonance imaging of the spine. *Vet. Clin. N. Am.* **22**, 811.
- Wheeler S.J., Clayton-Jones D.G., Wright J.A. (1985) Myelography in the cat. *J. Small Anim. Pract.* **26**, 143.
- Wheeler S.J., Davies J.V. (1985) Iohexol myelography in the dog and cat: a series of one hundred cases, and a comparison with metrizamide and iopomidol. *J. Small Anim. Pract.* **26**, 247.

Imaging the cauda equina

- Feeney D.A., Wise M. (1981) Epidurography in the normal dog: technic and radiographic findings. *Vet. Radiol.* **22**, 35.
- Hathcock J.T., Pechman R.D., Dillon A.R., Knecht C.D., Braund K.G. (1988) Comparison of three radiographic procedures in evaluation of the canine lumbosacral spinal canal. *Vet. Radiol.* **29**, 4.
- Lang J. (1988) Flexion–extension myelography of the canine cauda equina. *Vet. Radiol.* **29**, 242.
- Morgan J.P., Bailey C.S. (1990) Cauda equina syndrome in the dog: radiographic evaluation. *J. Small Anim. Pract.* **31**, 69.

Advanced imaging

- de Haan J.J., Shelton S.B., Ackerman N. (1993) Magnetic resonance imaging in the diagnosis of degenerative lumbosacral stenosis in four dogs. *Vet. Surg.* **22**, 1.
- Nakayama M. (1993) Intraoperative spinal ultrasonography in dogs: normal findings and case history reports. *Vet. Radiol. Ultras.* **34**, 262.
- Karkkainen M., Mero M., Nummi P., Punto L. (1991) Low field magnetic resonance imaging of the canine central nervous system. *Vet. Radiol.* **32**, 71.
- Schaeffer D.M., Flanders A.E., Osterholm J.L., Northrup B.E. (1992) Prognostic

significance of magnetic resonance imaging in the acute phase of cervical spine injury. *J. Neurosurg.* **76**, 218.

- Sether L.A., Nguyen C., Yu S., Haughton V.M., Ho K-C., Biller D.S., Strandt J.A., Eurell J.C. (1990) Canine intervertebral disks: correlation of anatomy and MR imaging. *Radiol.* **175**, 207.
- Sharp N.J.H., Wheeler S.J., Cofone M. (1992) Radiological evaluation of "wobbler" syndrome - caudal cervical spondylomyelopathy. *J. Small Anim. Pract.* **33**, 491.

Cerebrospinal fluid examination

- Chrisman C.L. (1991) Special ancillary investigations. In: Chrisman C.L. *Problems in Small Animal Neurology*, 2nd edn. Philadelphia, Lea and Febiger, p. 81.
- Cook JR., DeNicola D.B. (1988) Cerebrospinal fluid. *Vet. Clin. N. Am.* **18**, 475.
- Indrieri R.J., Holliday T.A., Keen C.L. (1980) Critical evaluation of creatine phosphokinase in cerebrospinal fluid of dogs with neurologic disease. *Am. J. Vet. Res.* **41**, 1299.
- Thomson C.E., Kornegay J.N., Stevens J.B. (1989) Canine intervertebral disc disease: change in the cerebrospinal fluid. *J. Small Anim. Pract.* **30**, 685.
- Vandavelde M., Spano J.S. (1977) Cerebrospinal fluid in canine neurologic disease. *Am. J. Vet. Res.* **38**, 1827.
- Widmer W.R., DeNicola D.B., Blevins W.E., Cook J.R., Cantwell H.D., Teclaw R.T. (1992) Cerebrospinal fluid changes after iopamidol and metrizamide myelography in clinically normal dogs. *Am. J. Vet. Res.* **53**, 396.

Electrophysiology

- Shores A., Redding R.W., Knecht C.D. (1987) Spinal-evoked potentials in dogs with acute compressive thoracolumbar spinal cord disease. *Am. J. Vet. Res.* **48**, 1525.
- Sylvestre A.M., Cockshutt J.R., Parent J.M., Brooke J.D., Holmberg D.L., Partlow G.D. (1993) Magnetic motor evoked potentials for assessing spinal cord integrity in dogs with intervertebral disc disease. *Vet. Surg.* **22**, 5.

CHAPTER 5

Pathophysiology of Spinal Cord Injury

Contents

<i>Introduction</i>	64
<i>Pathophysiology of acute spinal cord injury</i>	64
<i>Secondary injury mechanisms</i>	65
<i>Pathophysiology of chronic (compressive) cord injury</i>	69
<i>Associated reading</i>	70

Introduction

Lesions of the vertebral column, spinal cord and nerve roots which may require surgical therapy are those in which compression of nerve tissue occurs. The compression is frequently extramedullary, i.e. outside the spinal cord or nerve roots, with consequent deformation of the pia mater on its outer surface. However, in certain circumstances, for example following an acute concussive injury, pressure elevation occurs within the parenchyma enclosed by the pia.

Both categories of lesion can be subject to surgical decompression but, in order to determine the type of surgery appropriate for each, it is important to understand the pathophysiology of both concussive and compressive spinal cord injuries. Although concussion and compression can be considered as separate means of inducing spinal cord injury, and in experimental work they are often deliberately distinguished, in clinical situations there is usually a mixture of both mechanisms. In many acute injuries (such as acute disc extrusion) the concussive event predominates. However, lesions within the vertebral canal such as bone fragments or extruded disc material will continue to compress the cord after the initial concussion has resolved and may result in persistence of some neurological deficits if left untreated.

Pathophysiology of acute spinal cord injury

Acute injury to the spinal cord occurs commonly in both animals and humans, and may be due to external causes, such as falls or road traffic accidents, or internal causes, such as acute disc extrusions. Because of the great social and economic importance of spinal cord injury in humans, a large number of experimental studies have been carried out on the mechanisms of spinal cord injury and possible therapeutic modulations of such mechanisms. Many of the studies rely on the production of lesions by modifications of the 'weight drop' model of Allen

(1911), in which a known weight is dropped a certain distance onto the exposed spinal cord. The severity of cord injury varies depending on the magnitude of the injury, i.e. the product of weight and distance dropped.

The changes observed in the spinal cord following acute experimental injury have been followed both histologically and biochemically. After acute injury the spinal cord undergoes sequential pathological changes including infarction, haemorrhage, oedema, axonal and neuronal necrosis and demyelination, followed by cyst formation.

Immediate effects

Immediately following impact there is a total conduction block, the cause of which is likely to be efflux of potassium from the mechanically deformed cells. (Vascular changes are thought not to be the cause of the immediate conduction block, owing to the time relationship of these events.) The change in the ratio of extracellular to intracellular potassium will cause depolarization and therefore a conduction block. At this stage there will also be some mechanical damage to blood vessels, with resultant haemorrhage into the neuropil. The magnitude of the initial injury is small and involves only a limited segment of cord tissue.

Vascular observations

Within 5 min of a severe concussive injury, sub-pial and grey matter haemorrhage appears and there is a generalized decrease in blood flow through the cord. Centrifugal spread of ischaemia occurs during the next 24 h; the extent depends on the severity of the initial insult. Grey matter blood flow is dramatically reduced during the first 2 h and remains at low levels for at least the first 24 h. White matter blood flow is also reduced initially, for between 1 h and 6 h, but returns to normal, or even is increased according to some investigators, by 24 h. The effect of decreased blood flow is more marked in the grey matter owing to two main features: its higher metabolic rate and less closely packed constituents, which allows oedema fluid to accumulate and to perpetuate the effects of low blood flow. The persistence of abnormalities in blood flow is a result of biochemical changes within the cord, oedema and loss of autoregulation.

Secondary injury mechanisms

Direct mechanical damage to the cord is insignificant compared with the secondary events that take place as a consequence. Mechanical injury to blood vessels causes ischaemia, initially by direct mechanical means causing vasospasm and, subsequently, by damage to the endothelial cells with activation of secondary injury mechanisms. By means of secondary injury phenomena the continued autodestructive events in the spinal cord may progress in the absence of continued spinal cord pressure. Release of various vasoactive substances and generation of free radicals occurs which prolongs the period of ischaemia and leads to secondary injury. Many mediators of the secondary injury have been proposed, including excitotoxic amino acids, ionic calcium, opioids and oxygen free radicals. Treatment aimed at

reduction of these post-traumatic changes has been evaluated. Many of the treatment options appear to be ineffective but methylprednisolone and some more recently developed compounds have been found to be effective in reduction of the severity of cord injury. The mode of action of methylprednisolone in treatment of acute cord injury has been demonstrated to be separate from its corticosteroid activity and correlates with reduction in oxygen free radical activity.

Calcium

Concomitant with early potassium efflux from the cells, there is calcium influx, which has several consequences, and has been described as the final common pathway of toxic cell death in the nervous system. Increase in intracellular calcium arises as a result of a mechanically induced increase in membrane permeability, the opening of voltage dependent channels and also as a result of glutamate interaction with the NMDA (*N*-methyl *D*-aspartate) receptor. There is vasospasm, impairment of mitochondrial function, and depletion of high-energy phosphate-containing compounds. Elevation in intracellular calcium concentration is also responsible for activation of a large range of enzymes. Some of these enzymes are capable of converting xanthine dehydrogenase to xanthine oxidase, which is a potent producer of oxygen free radicals in the injured cord. Other activated enzymes include those involved in the arachidonic acid cascade resulting in the production of eicosanoids.

Free radicals

Many of the current investigations into spinal cord injury centre on the role of free radicals. Free radicals have an unpaired electron in the outermost orbit. They are therefore extremely reactive and, following reaction with normal molecules, will lead to formation of other radical species, thereby creating a chain reaction. A small number of free radicals are generated during normal cell metabolism, but these are scavenged by various agents, including ascorbate, α -tocopherol (vitamin E) and enzymes such as superoxide dismutase, thereby protecting the cell from their deleterious effects.

Ischaemia results in changed metabolism within the cell, with an accumulation of lactate, and, in combination with high intracellular calcium levels, the activation of biochemical pathways promoting free radical production. Haemorrhage into the neuropil forms a ready source of iron which is required to catalyse the formation of free radicals. During ischaemic cell damage the formation of free radicals overwhelms the normal defence mechanisms, allowing damage to occur. Free radicals will react with the lipid component of the cell membranes, a process known as lipid peroxidation, which leads to cell membrane dysfunction and ultimately can lead to cell death. Neural tissue is particularly sensitive to free radical mediated injury owing to its high lipid content. Free radicals also have other effects such as promoting inflammation by enhancing capillary permeability and acting as chemotactic agents for phagocytic cells.

The significance of free radicals as mediators of spinal cord injury can also be evaluated by the effects of drugs which have anti-oxidant properties. It has been demonstrated that anti-oxidant drugs such as α -tocopherol, methyl prednisolone

and the recently developed aminosteroids (also known as lazaroids) can alleviate the effects of spinal cord concussion.

Eicosanoids

Activation of phospholipase A, as a result of calcium influx, triggers the production of leukotrienes, thromboxanes and prostaglandins from arachidonic acid. Increases in prostaglandin levels will cause increased vascular permeability and vasoconstriction or vasodilatation. In addition, there are also effects on platelet function which can cause thrombosis and release of 5HT (5-hydroxytryptamine) which will also alter vascular permeability. Therefore, the consequences of eicosanoid release include local infarction (due to thrombosis) and accumulation of extra-cellular fluid. Oedema will exacerbate ischaemia owing to pressure increases within the parenchyma bounded by the pia mater.

Neurotransmitters

GLUTAMATE

Some amino acids, in particular glutamate, are active in the CNS as excitatory neurotransmitters. They have been postulated to be involved in the secondary injury mechanism. Mechanically induced depolarization of neurones causes release of neurotransmitters, including glutamate. Extracellular glutamate concentration in the injured spinal cord is massively elevated. This neurotransmitter acts at the NMDA receptor to open channels allowing increase in intracellular sodium, chloride and calcium. Experimental studies have shown reduction of the severity of spinal cord and cerebral ischaemic injury can be achieved by blocking this channel. Calcium influx is thought to be the mechanism of NMDA receptor mediated spinal cord injury.

MONOAMINES

Effects due to the neurotransmitter noradrenaline have been suggested in the past but have since been refuted experimentally.

The neurotransmitter 5HT is thought to play a role in spinal cord injury; elevated concentrations of 5HT arise following obstruction of blood vessels by platelet aggregation. 5HT induces constriction of arteries, arterioles and venules and also initiates platelet aggregation, thereby inducing a vicious circle of thrombosis of spinal cord vasculature.

OPIOIDS

Some attention has been given to the increase in endogenous opioid concentrations observed in the acutely injured spinal cord. These opioids have been demonstrated to cause neural injury when injected intrathecally. It has also been demonstrated that reduction in severity of injury following acute cord trauma can be achieved by use of opioid receptor blocking agents, such as naloxone. The mechanism of action

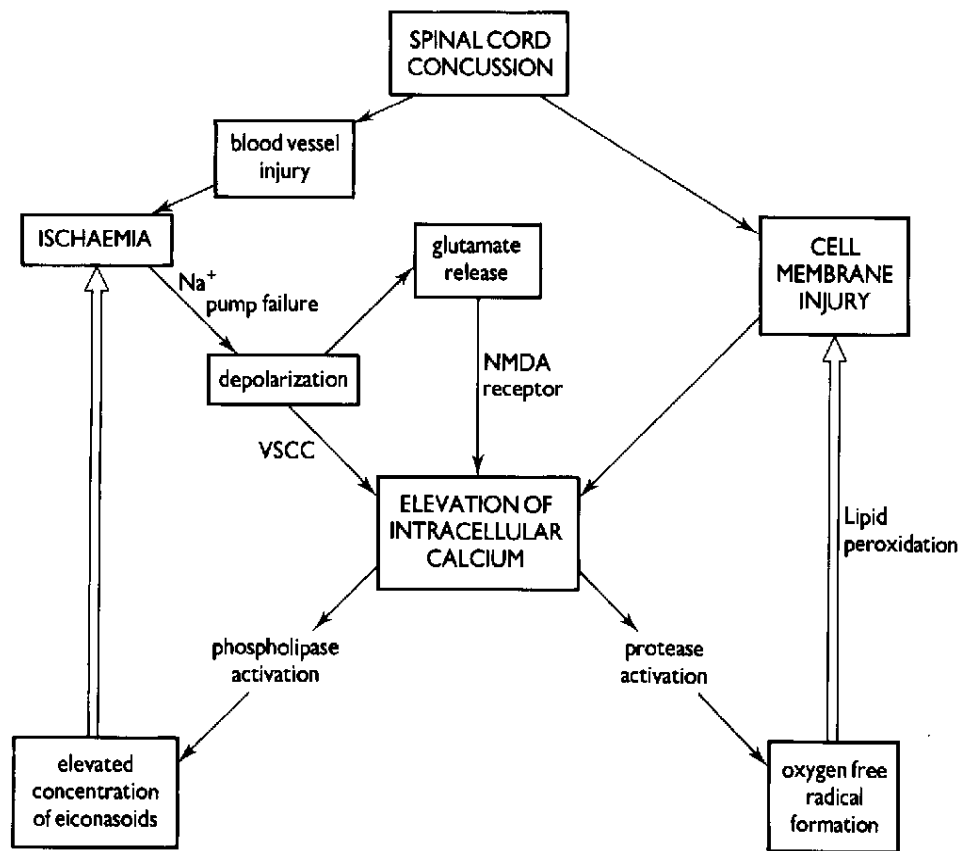


Figure 5.1 Diagram showing pathophysiology of acute spinal cord injury (in simplified form). VSCC, voltage sensitive calcium channel; NMDA, N-methyl D-aspartate. Positive feedback pathways are indicated by double lines.

of the protective effects of naloxone is uncertain but probably is via effects on blood pressure.

Twenty four hours following acute spinal cord injury, the cord shows chronic hyperaemia and loss of autoregulation. Oedema persists until 2 weeks after the incident. Remyelination of demyelinated uninjured axons starts after 1 week and can be complete by 4 weeks; some axons may remain demyelinated.

Little further tissue damage occurs after 24 h following injury. After that time, therapy can only hope to enhance repair processes. For this reason, surgery has only a limited role in the treatment of acute spinal cord concussive injury. In the main, medical therapy is indicated to ameliorate the abnormalities in intracellular metabolism and blood flow and their resultant injurious effects on the cord; these treatments are discussed in Chapter 15. Surgical therapy for concussive injuries is limited to: (i) decompression of the theca, i.e. piodomy, or myelotomy for cases in which there is no likelihood of recurrent concussion, for instance in acute explosive disc extrusion; (ii) stabilization of damaged areas of the vertebral column if recurrent concussive injuries are probable, for example in spinal fractures or luxations.

Conclusion

In general, treatment of acute spinal cord injury is medical rather than surgical. Methylprednisolone is currently the only available veterinary drug which has been demonstrated to ameliorate the consequences of clinical spinal cord injury but many other preparations are likely to be available in the near future.

Occasionally, however, surgery may have a role to play. Before contemplating surgical intervention in an animal with an acute spinal cord injury, the clinician should ascertain what the aim of the surgery is to be. Is the surgery aimed at decompressing the cord by removal of an extradural mass (disc material, bone fragments or haematoma)? Or is it aimed at reducing the effects of the concussive injury by means of piotomy or myelotomy? To be sure of carrying out appropriate surgery it is essential to understand the history and duration of the injury and to have radiographic evidence of the presence or absence of a removable extradural mass. These considerations are of special importance when dealing with an acute cord injury in which a significant mass lesion cannot be observed radiographically. In such cases, gaining surgical access to the cord without also carrying out piotomy may be of no benefit to the patient and medical therapy alone would be more appropriate.

Pathophysiology of chronic (compressive) cord injury

Although acute and chronic cord injuries are described separately, there is of course some overlap between acute concussion and compressive disease in most spinal cord injuries. In chronic compressive type of lesions, concussive events may be superimposed, or form an important part of the progression of the disease itself, e.g. spinal cord of many wobbler dogs suffers chronic compression owing to type II disc protrusion, but concussive injuries will take place on a semicontinuous basis owing to the superimposed dynamic components of the disorder. Spinal tumours usually cause chronic compression with little or no concussive injury to the cord.

Slowly developing or persistent compression will lead to spinal cord injury by a means similar to acute cord concussion. However, during compression which develops slowly, the spinal cord has a remarkable ability to compensate for the induced change in shape. Frequently the symptoms associated with a slowly developing lesion will develop rapidly at a certain stage, when the cord's compensatory ability has been exhausted.

Two major factors are responsible for the clinical signs observed in chronic cord compression: direct mechanical forces and compromise of the vascular supply. Mechanical deformation is easily induced in the spinal cord as it is soft and delicate. Purely mechanical forces are thought by some workers to be responsible for the observed conduction anomalies. Vascular changes are most likely to occur at the level of the microcirculation (it has been shown experimentally that occlusion of major arterial supply to the cord in dogs can be associated with minimal and transient neurological deficits). Oedema is a common sequela to spinal cord compression, probably, in part at least, because of occlusion of the (low pressure) draining vessels.

In contrast to injury resulting from acute cord concussion, in chronic spinal cord

compression the predominant lesions are demyelination and Wallerian degeneration in the spinal tracts within the white matter. However, there can also (rarely) be severe grey matter damage in chronic compression, probably as a result of progressive ischaemia. The relative importance of the grey and white matter damage is dependent on the location of the compression within the spinal cord, i.e. damage to grey matter in the cervical or lumbar intumescences is far more serious than damage to grey matter in the T3–L3 segment.

The differences between the mechanisms of injury in acute and chronic injuries can also be related to the vessels affected by the lesion. During chronic compressive disease, the thinnest-walled vessels (the veins) are preferentially affected leading to cord congestion, oedema and hyalinization of the affected vasculature. The mechanism of ischaemic injury to the cord in compressive disease is similar to that occurring in acute concussive injuries; however, it proceeds at a much slower rate, and so is more amenable to medical and surgical intervention. Surgical removal of lesions responsible for chronic cord compression usually produces very gratifying and rapid results. Following relief of compression in experimental animals the phenomenon of reactive hyperaemia has been observed with resultant vascular leakage of protein. Reperfusion can also result in formation of free radicals. These two events could account for the transient worsening of neurological deficits which is occasionally observed in clinical cases following decompression.

Associated reading

- Allen A.R. (1911) Surgery of experimental lesion of spinal cord equivalent to crush injury of fracture dislocation of spinal column. *J. Am. Med. Assoc.* **57**, 878.
- Balentine J.D. (1978) Pathology of experimental spinal cord trauma. I. The necrotic lesion as a function of vascular injury. *Lab. Invest.* **39**, 236.
- Berg R.J., Rucker N.C. (1985) Pathophysiology and medical management of acute spinal cord injury. *Comp. Cont. Ed. Pract. Vet.* **7**, 646.
- Braund K.G. (1993) Acute spinal cord trauma. In: Bojrab M.J. (ed.) *Disease Mechanisms in Small Animal Surgery*, 2nd edn. Philadelphia, Lea and Febiger, p. 1140.
- Braund K.G., Shores A., Brawner W.R. (1990) The etiology, pathology and pathophysiology of acute spinal cord trauma. *Vet. Med.* **85**, 684.
- Brown S.A., Hall E.D. (1992) Role of oxygen derived free radicals in the pathogenesis of shock and trauma, with focus on central nervous system injuries. *J. Am. Vet. Med. Assoc.* **200**, 1849.
- Choi D.W. (1988) Glutamate neurotoxicity and diseases of the nervous system. *Neurol.* **1**, 623.
- Coughlan A.R. (1993) Secondary injury mechanisms in acute spinal cord trauma. *J. Small Anim. Pract.* **34**, 117.
- Faden A.I., Simon R.P. (1988) A potential role for excitotoxins in the pathophysiology of spinal cord injury. *Ann. Neurol.* **23**, 623.
- Griffiths I.R. (1972) The extensive myelopathy of intervertebral disc protrusions in dogs ("the ascending syndrome"). *J. Small Anim. Pract.* **13**, 425.
- Griffiths I.R. (1975) Vasogenic oedema following acute and chronic spinal cord compression in the dog. *J. Neurosurg.* **42**, 155.

- Griffiths I.R. (1976) Spinal cord blood flow after acute experimental cord injury in dogs. *J. Neurol. Sci.* 27, 247.
- Hall E.D., Wolf D.L. (1986) A pharmacological analysis of the pathophysiological mechanisms of post traumatic spinal cord ischaemia. *J. Neurosurg.* 64, 951.
- Janssens L.A.A. (1991) Mechanical and pathophysiological aspects of acute spinal cord trauma. *J. Small Anim. Pract.* 32, 572.
- Sorjonen D.C., Vaughn D.M. (1989) Membrane interactions in central nervous system injury. *Comp. Cont. Ed. Pract. Vet.* 11, 248.
- Tarlov I.M. (1957) Mechanism of acute spinal compression paralysis. In: Tarlov I.M. *Spinal Cord Compression: Mechanism of Paralysis and Treatment.* Springfield Illinois, Charles Thomas, p. 63.
- Tator C.H., Fehlings M.G. (1991) Review of the secondary injury theory of acute spinal cord trauma with emphasis on vascular mechanisms. *J. Neurosurg.* 75, 15.
- Vandeveldel M., Wolf M. (1993) Spinal cord compression. In: Bojrab M.J. (ed.) *Disease Mechanisms in Small Animal Surgery*, 2nd edn. Philadelphia, Lea and Febiger, p. 1152.
- Wright F., Palmer A.C. (1969) Morphological changes caused by pressure on the spinal cord. *Path. Vet.* 6, 355.

CHAPTER 6

Anatomical Anomalies and Congenital Lesions

Contents

<i>Introduction</i>	72
<i>Disorders of the vertebral column</i>	72
<i>Anomalies of the spinal cord</i>	80
<i>Associated reading</i>	83

Introduction

There are many anatomical anomalies of the spinal cord and vertebral column which may be responsible for abnormalities of neurological function. Most of these are found in young animals and are assumed to be congenital and, in some cases, are inherited. A large number of congenital lesions of the vertebral column are easily diagnosed on plain radiographs, although their significance may not be so clearly defined. Some abnormalities of the spinal cord can be diagnosed with the aid of contrast radiography but many require more advanced imaging techniques for accurate diagnosis. Many, but not all, congenital disorders of the spinal cord cannot be treated surgically. Vertebral anomalies may sometimes be treated effectively by surgery but consistent results may be difficult to achieve.

Disorders of the vertebral column

There are several congenital abnormalities of the vertebral column, some of which can be associated with concomitant disorders of the spinal cord. The congenital abnormalities of the vertebral column are caused by abnormalities in embryonic development and differentiation.

The spinal cord is formed from the ectoderm, the dorsal part of which invaginates to form the neural tube at about 15 days of gestation. The vertebral column is formed from the surrounding mesoderm, which initially is arranged segmentally in somites. The notocord lies ventral to the neural tube (Figure 6.1).

During embryogenesis, part of the cranial somite migrates cranially and part of the caudal somite migrates caudally. These two constituent parts come together to form the vertebrae; thus, the vertebrae are intersegmental. The notocord cells are displaced and some parts develop into the nucleus pulposus of the intervertebral disc of the adult; there are no remnants elsewhere.

At birth there are three ossification centres in each vertebra; one for the centrum

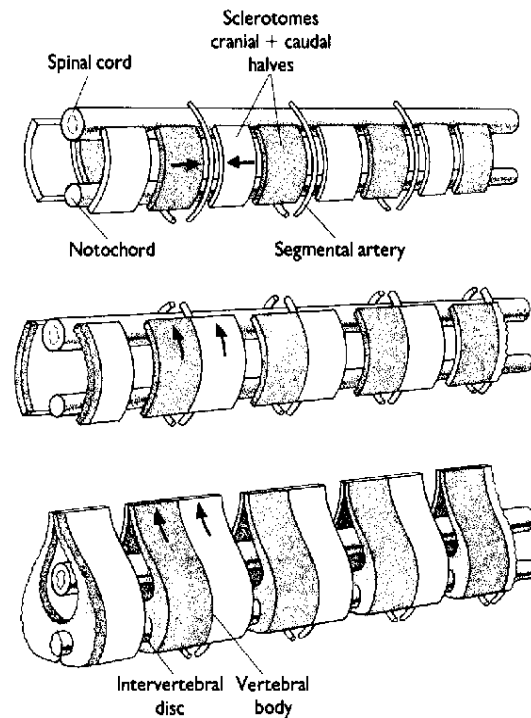


Figure 6.1 Diagram of embryonic development of the vertebral column. Note that the vertebrae form from parts of adjacent embryological segments. In the adult the notochord only persists as the nucleus pulposus, elsewhere it is obliterated (After Colter 1993, with permission).

and one for each half of the developing vertebral arch. Secondary ossification centres develop later and give rise to the various processes of the vertebrae.

Block vertebrae

Block vertebrae arise because of imperfect migration of the mesoderm of the somites, resulting in incomplete separation of adjacent vertebrae (Figure 6.2). This incomplete separation can be of varying degrees, resulting in fusion of adjacent vertebral bodies, arches or simply incomplete development of the intervertebral disc. This type of abnormality is stable and does not cause clinical signs at the primary site. Problems can occasionally arise owing to increase in stress on neighbouring intervertebral spaces, with consequent degenerative changes and possible disc protrusion in later life.

Hemivertebrae

This abnormality affects the vertebral bodies, which may be wedge shaped or butterfly shaped depending on the portion of the vertebral body which fails to develop properly. Both ventrodorsal and lateral radiographic views are required to assess adequately the shape of such malformed vertebrae. They are found

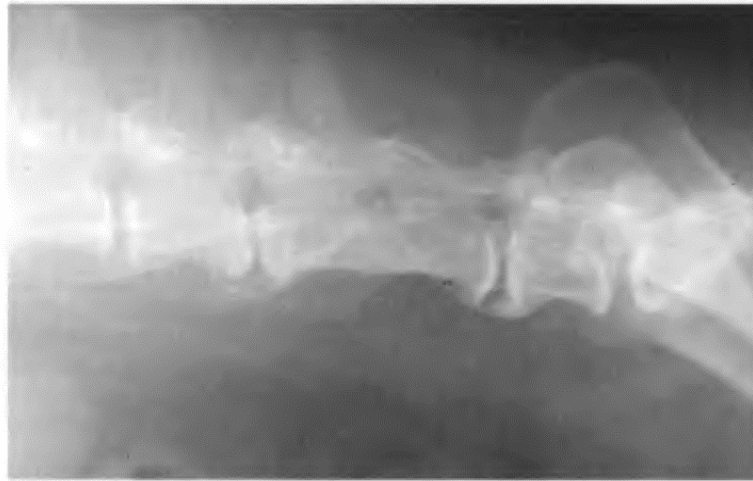


Figure 6.2 Block vertebra, caused by imperfect separation of L5 and L6. The lesion was symptomless but note adjacent spondylosis.

commonly in screw-tailed breeds of dog and occasionally in other breeds, usually in the thoracic, or less commonly, in the lumbar segment of the vertebral column. The anomaly responsible for development of hemivertebrae is not well defined but is likely to be due to displacement of somite segments by half a segment during embryogenesis or failure of development of one side of the ossification centre of the centrum of the vertebral body. Butterfly vertebrae have a central membrane which represents persistence of a portion of the notocord (Figure 6.4).

Although hemivertebrae are inherently unstable and may cause twisting or abnormal flexion (kyphosis) of the vertebral column, they are not always associated with neurological deficits. Sometimes the hemivertebra is pushed dorsally as growth occurs in the young animal, causing development of progressive spinal cord compression and clinical signs of a transverse myelopathy (Figure 6.3). Secondary changes of the abnormal and adjacent vertebrae can occur, such as remodelling of the spinous processes and spondylosis. These secondary abnormalities can also be responsible for clinical signs.

Hemivertebrae found in a dog exhibiting suitable clinical signs should not be assumed to be the cause of the neurological deficits. Myelography is essential to confirm that there is associated spinal cord compression. Clinical signs arising from the same site may also result from myelodysplasia, tethering of the cord, or arachnoid cysts, some of which can also be diagnosed with myelography. Surgical correction of compression caused by hemivertebrae can be carried out by judicious removal of offending bone, plus stabilization where appropriate. Opinions on prognosis given to the owners of surgically treated dogs should be tempered by awareness of the possibility of concurrent myelodysplasia.

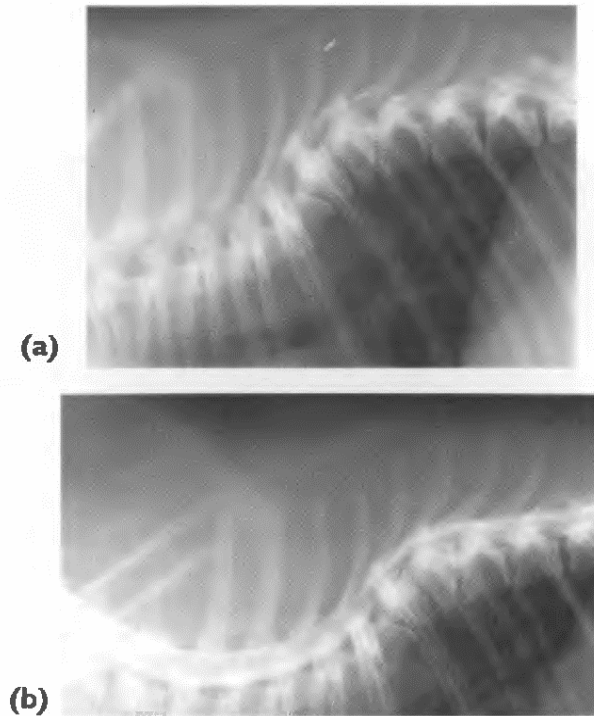


Figure 6.3 (a) Hemivertebrae at T6 and T7 associated with severe kyphosis (flexion) of the vertebral column. (b) Myelography demonstrates that this lesion is causing spinal cord compression.

Transitional vertebrae

These vertebrae exhibit characteristics of two adjacent divisions of the vertebral column, and occur at the junctions of these divisions, e.g. at thoracolumbar junction. These are frequently clinically insignificant, although common. Thoracolumbar transitional vertebrae are not functionally significant but are important to identify prior to surgery in this area as they can cause the surgeon to misidentify the level at which surgery is to be carried out (the last rib is often used as a landmark).

Transitional vertebrae at the lumbosacral junction (most usually unilateral sacralization, i.e. fusion of one-half of the seventh lumbar vertebra to the ilium and/or sacrum) can be associated with clinical signs (Figure 6.5). German Shepherd dogs exhibiting symptoms of cauda equina compression have been found to have a higher incidence of transitional vertebrae at the lumbosacral junction compared with unaffected dogs of the same breed.

Spina bifida

This abnormality is seen most commonly in screw-tailed breeds of dog and in Manx cats. Several types are recognized; spina bifida occulta is used to describe imperfect fusion of the spinous process, and spina bifida manifesta is the term for incomplete fusion of the vertebral arch with concurrent involvement of the spinal cord and/or

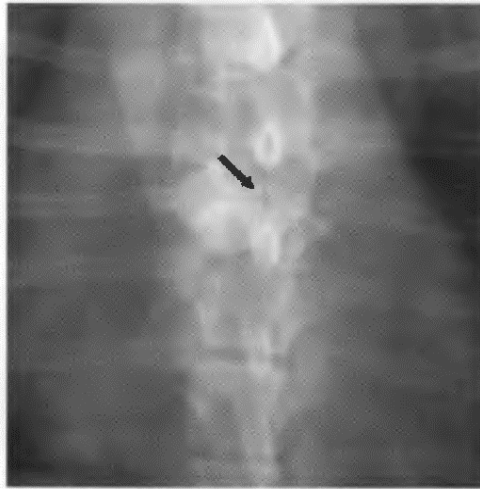


Figure 6.4 Butterfly vertebra and imperfect midline fusion at T5/6 (arrowed).

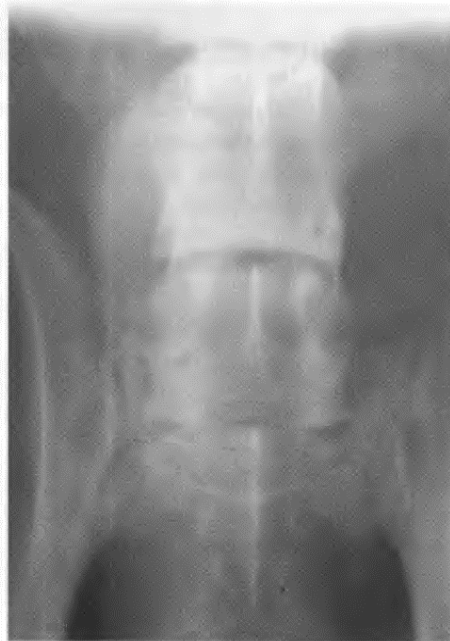

Figure 6.5 Transitional vertebra at lumbosacral junction. One side of the (apparent) L7 vertebra is forming a joint with the wing of the ilium.

meninges. The meninges may protrude through the defect to reach the skin (meningocoele) or the central canal may expand and protrude through the opening to reach the skin; this is termed meningocele (Figure 6.6). Neurological deficits are associated with the abnormal neural tissue development and cannot

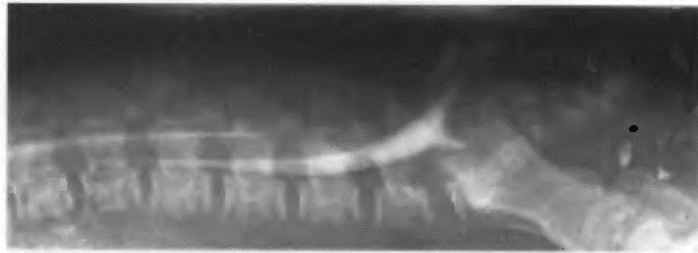


Figure 6.6 Myelogram of meningomyelocele at the lumbosacral junction in an English bulldog.

be treated surgically. The communication of the subarachnoid space or central canal with the exterior can lead to meningitis; this communication can be closed surgically. The dural tube is exposed and, if necessary (i.e. if there is tethering of the cord), dissected free of the surrounding soft tissue and the opening through the dura sutured to achieve closure (Figure 6.6).

Aplasia/hypoplasia/dysplasia of the dens

This condition, in which there is failure of proper formation of the dens of the atlas, is most often encountered in small breeds of dog, in particular toy poodles and Yorkshire terriers. It is rarely observed in other breeds of dog or in cats. Symptoms are not always exhibited unless there has been trauma to the cranial cervical region, such trauma is often apparently very minor. Clinical signs are often exhibited before the animal is 18 months old. The lack of stability caused by this defect allows atlanto-axial subluxation causing ventroflexion of the cranial cervical spine and consequent spinal cord compression. Symptoms usually consist of pain with or without neurological deficits affecting all four limbs; occasional animals exhibit periodic collapsing episodes which may resemble seizures. Treatment is usually surgical and is discussed in Chapter 11.

Vertebral canal stenosis

Stenosis (narrowing) of the vertebral canal occurs at various levels of the vertebral canal with variable frequency.

CERVICAL REGION

In certain breeds of dog stenosis of the cervical vertebral canal is very common. In Dobermann pinschers the caudal cervical vertebral canal is almost always stenotic when compared with dogs of the same size and different breed. Stenosis of the cervical vertebral canal is also encountered in Basset hounds, great Danes, Irish wolfhounds and sporadically in other breeds. In the Dobermann, stenosis is most obvious at the most cranial aspect of the caudal cervical vertebrae, especially C7 –

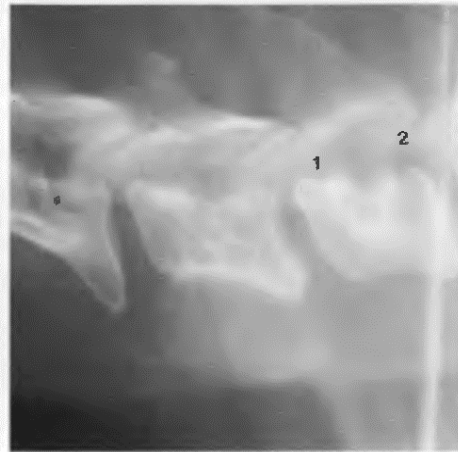


Figure 6.7 Stenosis of the cranial aspect of C7 vertebral canal in a middle aged Dobermann pinscher. Compare ventrodorsal depth at 1 and 2.

the vertebral canal is funnel shaped at such affected vertebrae (Figure 6.7). Symptoms associated with stenosis are not always present in the young dog but the bony stenosis will often exacerbate the effects of degenerative diseases (e.g. type II disc) of the region in later life. Clinical signs relating to stenosis in young dogs can include progressive ataxia and tetraparesis and can be alleviated by surgery. The problems of cervical vertebral canal stenosis and degenerative disease of the caudal cervical region (wobbler syndrome) is considered in more detail in Chapter 12.

THORACIC REGION

Stenosis of the thoracic vertebral canal has been reported in the Dobermann, in which clinical signs are not usually thought to occur, and in the English bulldog.

LUMBOSACRAL JUNCTION

Idiopathic stenosis of the lumbosacral region has been recognized in small and medium breed dogs (often toy poodles), associated with the failure to form an adequately sized vertebral canal. The stenosis can be caused by malformation and thickening of the pedicles and can affect both the vertebral canal at the lumbosacral junction and the intervertebral foramina at L6/7 and L7/S1. Symptoms are thought to arise due to both mechanical compression of the cauda equina and compression of the vascular structures of the area, and can include a variety of clinical signs such as paresis, pain, paraesthesia and sphincter disturbances. Dogs of between 3 and 8 years old have been reported to be affected by this syndrome.

Radiographs of the affected region reveal no evidence of degenerative disc disease, spondylosis, instability, tumour or infection. Stenosis of the vertebral canal can be observed. Contrast studies have not been reported frequently, but epidurography, myelography or MRI would be expected to define more clearly the nature and site of the attenuated area of neural tissue.

Treatment of idiopathic lumbosacral stenosis has been by dorsal laminectomy,

with additional decompression of the nerve roots by foraminotomy or facetectomy as required. Results in all cases were good.

Sacrocaudal hypoplasia

Hypoplasia of elements of the tail is 'normal' in the Manx cat. However, other abnormalities of the caudal part of the vertebral column can occur concurrently. These include agenesis of part of the sacrum, spina bifida and its associated abnormalities, and spinal cord abnormalities such as dysraphism and syringomyelia. Similar abnormalities also occasionally develop in breeds of dog with short or screw tails. Symptoms typically include bladder atony and pelvic limb weakness. Diagnosis of sacrocaudal hypoplasia can be made by radiography and contrast radiography; lower motor neurone (LMN) deficits can be documented with electromyography (EMG). Surgical treatment of this condition is not possible.

Solitary and multiple cartilaginous exostosis

These terms are used to describe the development of proliferating cartilaginous masses in various parts of the body around the growth plates; the terms osteochondroma or osteochondromatosis are also used to describe the same conditions. In the dog, the abnormal growths occur in either the axial or appendicular skeleton, or both, and develop only during the growth phase of the individual. If the proliferating mass develops on a vertebra it may lead to spinal cord compression. Surgical excision of the mass may be associated with a good prognosis but prognosis is dependent on the area affected and the ability of the surgeon totally to excise the lesion. Solitary lesions are reported to be of little clinical importance in the dog but severe clinical signs have been reported in one series. Malignant transformation of multiple cartilaginous exostosis has been reported.

In cats, a condition usually termed osteochondromatosis, has a very different course and likely aetiology. The condition in cats has features of a true neoplasm in that enlargement of the masses is independent of the normal growth of the animal. Most affected cats are young adults and a viral aetiology is suspected. Solitary cartilaginous exostosis has also been reported in the cat and has a good prognosis following excision.

Calcinosis circumscripta

There have been reports of calcinosis circumscripta lesions as the cause of both cervical and thoracolumbar spinal cord compression. The lesions appeared in immature dogs and surgical excision resulted in remission of symptoms. It is possible that some reports of cartilaginous exostosis could be descriptions of variations of this condition.

Mucopolysaccharidosis IV

This storage disease has been identified in the Siamese cat (and occasionally in other breeds), one of the symptoms being progressive paraparesis caused by proliferation of bone of the vertebral arch. Affected cats have abnormally shaped

heads and corneal opacities. Neurological symptoms are first apparent at 4-7 months old and progress rapidly. Surgical treatment of this condition has been reported, through removal of the offending bone. Although the results were poor, it must be considered a logical approach to the problem of progressive compression of the cord.

Anomalies of the spinal cord

Anomalies of the spinal cord are often not amenable to surgical therapy but may be suspected during diagnostic procedures and are often found in association with anomalies of the vertebral column. It is important that the surgeon should be aware of their possible existence, so that the prognosis given for surgical treatment of congenital skeletal abnormalities can be tempered by an awareness of the possibility of there being concurrent untreatable disease of the spinal cord. Increasing use of advanced imaging techniques, especially MRI, is likely to increase the frequency of antemortem diagnosis of such anomalies.

Spinal dysraphism

In this condition the neural tube fails to close. Many other abnormalities may coexist, such as syringomyelia (abnormal CSF-filled space in the spinal cord) (Figure 6.8), and hydromyelia (dilatation of the central canal). The condition has been described most fully in the Weimaraner and sporadically in other breeds of dog. Clinical signs include a characteristic (bunny) hopping gait, with crouching posture and proprioceptive deficits in the hindlimbs. Dogs are usually presented for examination at a few months of age.

Usual diagnostic methods, such as contrast radiography and CSF examination fail to diagnose the abnormality but should be carried out to eliminate the possibility of a correctable cause for such symptoms.

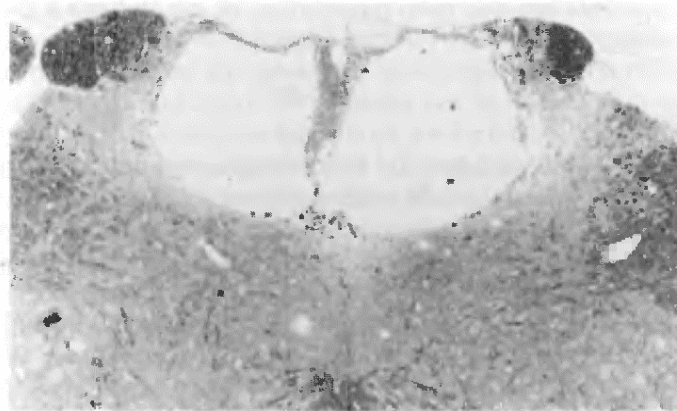


Figure 6.8 *Syringomyelia.* In this case the syrinx resulted from an ischaemic lesion. (Photomicrograph kindly supplied by N.J. Olby, Cambridge University Veterinary School, UK).

Dermoid cysts and pilonodial ducts

In both these conditions there is a failure during embryological development of the ectodermally derived neural tissue to detach itself completely from the ectoderm which forms the integument. Dermoid cysts consist of aggregations of integumental tissue which remain embedded in the spinal cord. These may grow and cause typical signs of transverse myelopathy and they can be identified as intramedullary masses on myelography. There are no reports of successful removal of intraspinal cysts to date; the diagnosis was finally made at post mortem.

Pilonodial ducts are ducts which communicate from the integumental surface to the meninges. The condition has been observed most frequently in the Rhodesian ridgeback, but also sporadically in other breeds of dog. Frequently, a small tuft of hair is identified at the skin surface, and the area is surrounded by abnormal whorling of the hair coat. Secondary infection is the common reason for development of clinical signs, with affected dogs showing typical symptoms of meningitis. The communication to the meninges can be demonstrated by introduction of nonionic radiographic contrast medium into the sinus. Excision of the duct and control of infection have resulted in cures.

Arachnoid cysts

There is some doubt in the reported cases of this condition in dogs as to whether these cysts are a result of repeated trauma to the cord or whether they are congenital lesions. However, they are diagnosed frequently enough in young (under 1 year) dogs which have no history of trauma for a congenital cause to be considered likely in many cases. Affected dogs show evidence of a progressive transverse myelopathy. A blind-ended sac of the pia/arachnoid can be identified on myelographic studies and is thought to be formed as a result of poor separation of the two layers during development (Figure 6.9). Alternative explanations include development of such cysts as a result of adhesions formed between the meningeal layers following trauma to the cord.

Treatment of arachnoid cysts is by means of surgical excision, or marsupialization of the lining membrane. A dorsal laminectomy approach (Chapter 13) is required, followed by durotomy. The cut edges of the dura are retracted by means of stay sutures. The cyst is usually distinct and associated with a depression of the surface of the cord itself. Magnification of the surgical site, for instance using loupes, is helpful. Surgical treatment of these lesions is usually very rewarding, although occasional cases will exhibit recurrence of symptoms, presumably owing to cyst recurrence.

Globoid cell leukodystrophy (Krabbe's disease)

This rare disease has been reported most commonly in West Highland white terriers, Cairn terriers and occasionally in other breeds of dog and cats. Although the entire nervous system is involved, this condition often manifests initially as a spinal cord disease. Symptoms are often first apparent at about 4 months of age (although one report describes a case in a dog of 4 years). Affected dogs are stiff initially then develop ataxia. Later symptoms include generalized tremors and

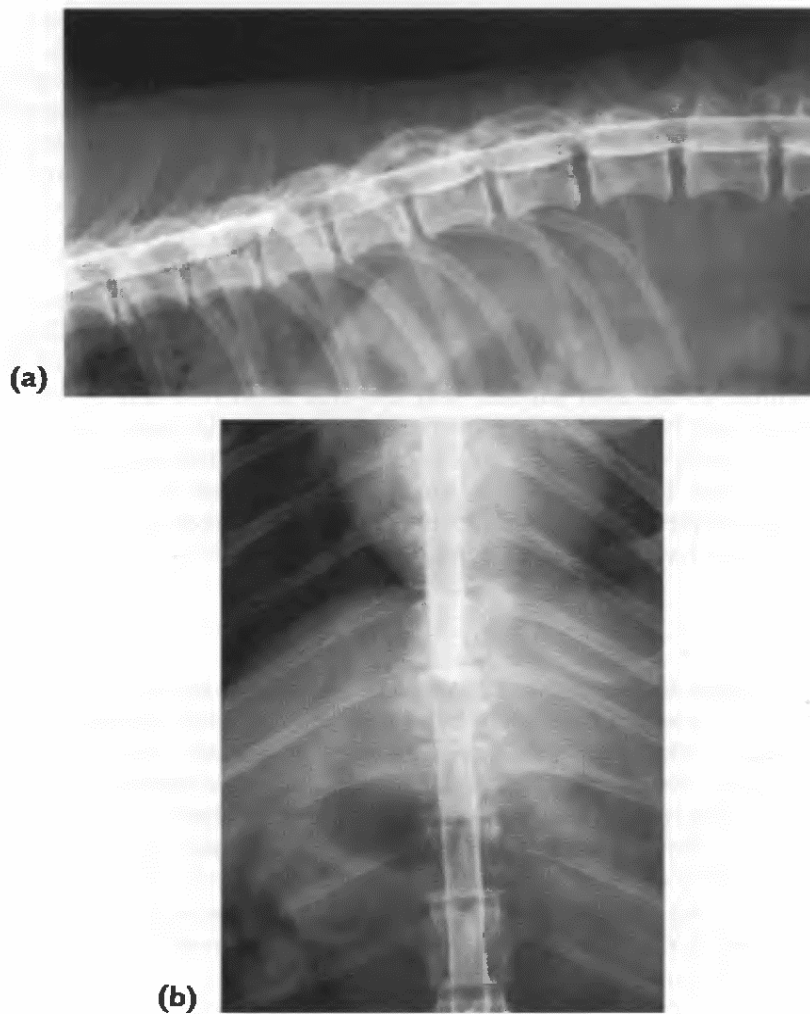


Figure 6.9 Arachnoid cyst at T9/T10.

more overt involvement of parts of the brain. Diagnosis is confirmed by post mortem examination. Spinal cord lesions include demyelination. There is no treatment.

Vascular malformation

Rare cases of congenital malformation of blood vessels within the cord have been recorded. Signs were consistent with a transverse myelopathy and the condition was diagnosed post mortem.

Miscellaneous

Various abnormalities such as duplication of the central canal, syringomyelia, hydromyelia are occasionally encountered. In these cases it is important that routine diagnostic work is carried out to try to identify a correctable lesion. With

increased use of advanced imaging, especially MRI, antemortem identification of these conditions should become more common. These conditions can sometimes be the result of trauma (syringomyelia) or other conditions (hydromyelia can be associated with hydrocephalus); it may become important, therefore, to identify the primary cause and surgical therapy may have a part to play. For example, shunting of hydrocephalus is a recognized treatment for syringomyelia in humans, and a recent report has described drainage of a syrinx in a dog.

Associated reading

- Bailey C.S. (1975) An embryological approach to the clinical significance of congenital vertebral and spinal cord abnormalities. *J. Am. Anim. Hosp. Assoc.* **11**, 426.
- Bailey C.S., Morgan, J.P. (1992) Congenital spinal malformations. *Vet. Clin. N. Am.* **22**, 985.
- Bichsel P., Lang J., Vandeveld M., Haeni H.J., Oettli P. (1985) Solitary cartilaginous exostoses associated with spinal cord compression in three large breed dogs. *J. Am. Anim. Hosp. Assoc.* **21**, 619.
- Canzinille, L., Kornegay, J.N. (1992) Acquired syringomyelia in a dog. *J. Am. Vet. Med. Assoc.* **201**, 1225.
- Colter S.B. (1993) Congenital anomalies of the spine. In: Bojrab M.J. (ed.) *Disease Mechanisms in Small Animal Surgery*, 2nd edn. Philadelphia, Lea and Febiger, 950.
- Done S.H., Drew R.A., Robins G.M., Lane J.G. (1975) Hemivertebra in the dog: clinical and pathological observations. *Vet. Rec.* **96**, 313.
- Dyce J., Herrtage M.E., Houlton J.E.F., Palmer A.C. (1991) Canine spinal 'arachnoid cysts'. *J. Small Anim. Pract.* **32**, 433.
- Finnie J.W., Sinclair I.R. (1981) Multiple cartilaginous exostoses in a dog. *J. Small Anim. Pract.* **22**, 597.
- Gambardella P.C., Osborne C.A., Stevens J.B. (1975) Multiple cartilaginous exostoses in the dog. *J. Am. Vet. Med. Assoc.* **166**, 761.
- Haskins M.E., Bingel S.A., Northington J.W., Newton C.D., Sunde R.D., Jezyk P.F., Patterson D.F. (1988) Spinal cord compression and hindlimb paresis in cats with mucopolysaccharidosis VI. *J. Am. Vet. Med. Assoc.* **182**, 983.
- Hirth R.S., Nielsen S.W. (1967) A familial canine globoid cell leukodystrophy ('Krabbe type'). *J. Small Anim. Pract.* **8**, 569.
- Johnson S.G., Hulse D.A. (1989) Odontoid dysplasia with atlantoaxial instability in a dog. *J. Am. Anim. Hosp. Assoc.* **25**, 400.
- Johnson L., Rolsma M., Parker A.J. (1992) Syringomyelia, hydromyelia and hydrocephalus in two dogs. *Prog. Vet. Neurol.* **3**, 82.
- Knecht C.D., Blevins W.E., Raffe M.R. (1979) Stenosis of the thoracic spinal canal in English bulldogs. *J. Am. Anim. Hosp. Assoc.* **15**, 181.
- Konde L.J., Thrall M.A., Gasper P., Dial S.M., McBiles K., Colgan S., Haskins M. (1987) Radiographically visualised skeletal changes associated with mucopolysaccharidosis VI in cats. *Vet. Rad.* **28**, 223.
- Kornegay J.N., Caizinille L., McVey A.S., Thomas W.B., Hopkins A.C., Plummer S.B., Guenego L., Gainsburg L.A. (1992) Syringomyelia: pathogenesis and

- diagnosis. In: *7th Annual Symposium of the European Society of Veterinary Neurology*, p. 14.
- Lewis D.G., Kelly D.F. (1990) Calcinosis circumscripta in dogs as a cause of spinal ataxia. *J. Small Anim. Pract.* **31**, 36.
- Luttgen P.J., Braund K.G., Storts R.W. (1983) Globoid cell leukodystrophy in a Basset hound. *J. Small Anim. Pract.* **24**: 153.
- McEwan J.D., Thomson C., Sullivan, S., Callanan S., Park M. (1992) Thoracic spinal calcinosis circumscripta causing cord compression in two German shepherd dog littermates. *Vet. Rec.* **130**, 575.
- McGrath J.T. (1965) Spinal dysraphism in the dog. *Pathol. Vet.* (suppl) **2**: 1.
- Morgan J.P. (1968) Congenital anomalies of the vertebral column of the dog: a study of the incidence and significance based on a radiographic and morphologic study. *J. Am. Vet. Rad.* **9**, 21.
- Morgan J.P., Bahr A., Franti C.E., Bailey C.S. (1993) Lumbosacral transitional vertebrae as a predisposing cause of cauda equina syndrome in German shepherd dogs: 161 cases (1987–1990). *J. Am. Vet. Med. Assoc.* **202**, 1877.
- Parker A.J., Adams W.M., Zachary J.F. (1983) Spinal arachnoid cysts in the dog. *J. Am. Anim. Hosp. Assoc.* **19**, 1001.
- Pool R.R. (1990) Tumors of bone and cartilage. In: Moulton J.E. (ed.) *Tumors in Domestic Animals*. 3rd edn. Berkeley, University of California Press, p. 157.
- Selcer E.A., Helman R.G., Selcer R.R. (1984) Dermoid sinus in a shih tzu and a boxer. *J. Am. Anim. Hosp. Assoc.* **20**, 634.
- Selcer E.S., Selcer R.R. (1984) Globoid cell leukodystrophy in two west highland white terriers and one pomeranian. *Comp. Cont. Ed. Pract. Vet.* **6**, 621.
- Tarvin G., Prata R.G. (1980) Lumbosacral stenosis in dogs. *J. Am. Vet. Med. Assoc.* **177**, 154.
- Tomlinson J., Higgins R.J., LeCouteur R.A., Knapp D. (1988) Intraspinal epidermoid cyst in a dog. *J. Am. Vet. Med. Assoc.* **193**, 1435.
- Wilson J.W. (1982) Spina bifida in the dog and cat. *Comp. Cont. Ed. Pract. Vet.* **4**, 626.
- Wilson J.W., Leopold H.W., Lees G.E. (1979) Spina bifida in the dog. *Vet. Path.* **16**, 165.

CHAPTER 7

Degenerative Conditions

Contents

<i>Degenerative disorders of the vertebral column</i>	85
<i>Degenerative conditions of the spinal cord</i>	105
<i>Associated reading</i>	108

Degenerative conditions which can lead to dysfunction of the spinal cord may initially affect either the vertebral column or the spinal cord itself.

Degenerative disorders of the vertebral column

Disc disease

The term 'disc disease' is used here to encompass the spectrum of degenerative changes that occur in the intervertebral discs in small animals. This discussion will consider the dog in particular because clinical signs as a result of disc disease are rare in the cat, although degenerate and protruded discs are frequently found in cats at post mortem examination.

Although not every dog which has degenerative changes in the intervertebral discs will exhibit symptoms and not every disc involved will cause symptoms, clinical signs are frequently observed in affected individuals. Two types of disc degeneration have been described in the dog and have different pathophysiology and consequences for the patient. The difference between the two types (Hansen types I and II) is primarily a matter of whether material escapes from the nuclear region and is related to the anatomical site of degeneration.

TYPE I DISC DISEASE

This type of disc degeneration predominantly affects 'chondrodystrophic' breeds. These breeds are those in which an abnormal cartilage maturation takes place and can be simply described as those with short twisted legs. Thus, dachshunds, Pekingese and Jack Russell terriers are included. However, there are some breeds with a notably high incidence of disc disease, such as the beagle, which do not at first appear to fit into this category. Subsequent studies have led to the reclassification of the beagle as a chondrodystrophic breed. Other breeds that not infrequently exhibit type I disc disease include Springer spaniels, Dobermann pinschers and, occasionally, German shepherd dogs. Mixed breed dogs are also often affected by this type of disc degeneration. There is a tendency for dogs of certain family lines to

be affected with greater than average frequency for the breed. Dachshunds are by far the most frequently affected breed in most studies.

Clinical signs of type I disc degeneration are most common in dogs of middle age, i.e. 5 to 8 years old. However, it is not uncommon to observe radiographic evidence of disc degeneration in animals under 2 years old, and some dogs under 1 year old will need decompressive surgery to alleviate the effects of disc extrusion. Obese individuals are more at risk of developing symptomatic disc degeneration.

The initial changes in type I disc degeneration take place in the nucleus pulposus (NP), particularly in its periphery. There is a decrease in the proteoglycan content, with resultant inability to retain the normal degree of hydration, resulting in a loss of the disc's important hydro-elastic and incompressible properties. There are changes in the ground substance from a mucoid to a chondroid nature and division of the NP into lobules, separated by sheaves of collagen. Necrosis of cells in divided lobules occurs followed by deposition of calcium salts beginning in the periphery of the NP. With time, the abnormal forces that are generated lead to weakening of the annulus fibrosus, the changes in which are consequent on the altered mechanical properties of the NP. Fissures develop between layers of the annulus allowing the nucleus to penetrate and eventually to escape into the surrounding tissues. Similar degenerative changes to those occurring in the annulus also occur in the dorsal longitudinal ligament. Owing to the eccentric placement of the nucleus relative to the annulus, escape of the nucleus is most likely to occur in a dorsal direction with accumulation of extruded material in the epidural space of the vertebral canal (Figure 7.1). The bulk of the extruded material is acellular necrotic material and is commonly calcified. Although the underlying degenerative changes are slow to progress, the ultimate escape of nuclear material (termed extrusion) can be rapid or extremely rapid, thereby causing concussive injury to the spinal cord. The results of concussive injury have been considered in Chapter 5.

TYPE II DISC DEGENERATION

Type II disc degeneration is considered to be an ageing change and usually occurs in dogs which would not be included in the chondrodystrophic group. The underlying pathological lesion is termed fibrinoid metaplasia; the nucleus undergoes replacement by fibrinoid tissue, resulting in loss of its normal mechanical abilities

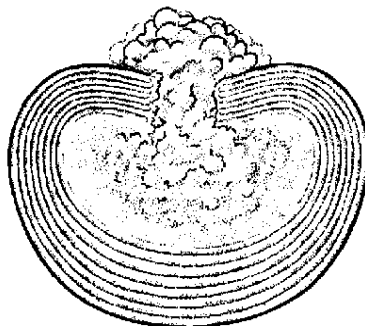


Figure 7.1 Transverse section through type I disc extrusion. Note that dorsal annulus is incomplete.

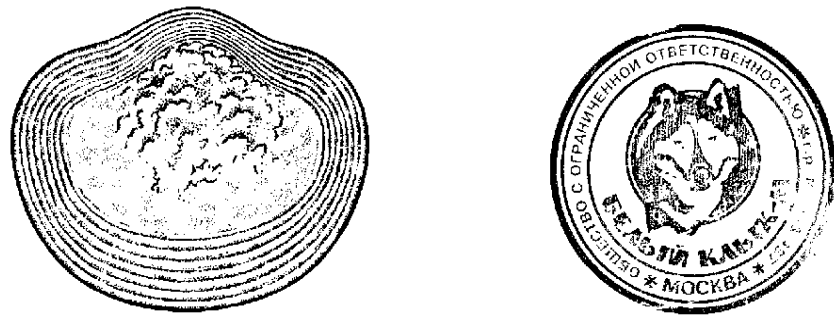


Figure 7.2 Transverse section through type II disc protrusion. Dorsal anulus is intact.

and increased stress transfer to the anulus. Dehydration of the NP is an early change, followed by an increase in collagen content of its ground substance. Increase in collagen may occur diffusely, or result in the division of the nucleus into lobules. Degeneration of the anulus occurs concurrently with degeneration of the nucleus, in contrast to the changes which occur in type I disc degeneration. There is a change in the substance between the fibres of the anulus fibrosus allowing disintegration of the lamellae and consequent intradiscal protrusions. This allows a protrusion of the nucleus to occur, with consequent bulging of the anulus dorsally into vertebral canal (termed disc protrusion) (Figure 7.2). These changes occur over a long period and this type of degenerative change is frequently diagnosed in old dogs which do not exhibit symptoms of a spinal cord disorder. Pain can frequently be elicited on palpation and manipulation of the affected area. Compression of the spinal cord takes place over a long period of time; neurological deficits (if present) result from physical deformation of the cord and effects on the blood supply. The effects of chronic compression on the spinal cord have been considered in Chapter 5.

The reason why discs degenerate is not fully understood but mechanical forces are incriminated owing to consideration of the distribution of lesions within the vertebral column. Clinical signs of disc disease are observed in association with disc lesions in the thoracolumbar and cervical segments of the vertebral column. The most commonly affected area is the junction between the thoracic and the lumbar regions. This area is under greater stress because of the relatively fixed nature of the neighbouring segments of the vertebral column. The thoracic region is relatively fixed owing to the mass of muscle and additional skeletal elements (ribs and sternum) of the thorax; the lumbar area has stiffness owing to the strong and bulky muscles which attach there. Furthermore, at the thoracolumbar junction, there is a change in the anatomical structure of the vertebrae, with a different angulation of the spinous processes and articular facets. In the thoracolumbar region about 70% of clinical disc problems occur at T11–L2. The most commonly affected disc is between T12 and T13 vertebrae. In the cervical region the highest proportion of symptomatic lesions occur in the most cranial discs, which are the intervertebral spaces at which most movement is permitted.

CLINICAL SIGNS

Clinical signs relating to disc disease can be variable. Neurological dysfunction is not always detectable; many dogs exhibit pain only. When present, neurological deficits will relate to the specific segment of the spinal cord affected. Lateralization of disc extrusion or protrusion usually occurs, due to the presence of the midline dorsal longitudinal ligament.

Lateralization of symptoms is often noted by the owner of affected animals, or lateralization of the extradural lesion may be apparent on myelographic studies.

Signs of pain caused by disc extrusion or protrusion may be the result of several mechanisms:

- (1) Discogenic pain – is due to change in pressure distribution within the affected disc. Free nerve endings are found in small numbers in the dorsal annulus fibrosus of the disc and also in larger numbers in the dorsal longitudinal ligament. Stretching of these nerve endings is assumed to be the stimulus responsible for sensation of pain
- (2) Irritation of the meninges – the extradural mass will cause inflammation in the meninges surrounding the spinal cord, and therefore cause pain mediated by prostaglandin release
- (3) Disturbance of the nerve roots – extruded or protruded discs may compress the nerve root as it lies in the intervertebral foramen and both types of disc lesion can elevate the cord from the floor of the vertebra which may stretch the nerve roots. In clinical cases, nerve root compression is frequently found in animals which exhibit severe spinal pain.

Cervical disc lesions

Symptomatic cervical disc disease is most commonly diagnosed in chondrodystrophic breeds of dog such as the dachshund; however, a number of larger breed dogs such as cocker (and other) spaniels and beagles are also commonly presented with symptoms of cervical disc lesions (Figure 7.3). In a series of 1086 clinical cases, symptomatic cervical disc disease accounted for about 12% of all disc lesions and the most commonly affected of the cervical discs is between C2 and C3 vertebrae; the incidence at other cervical sites decreases progressively proceeding caudally.

Commonly, dogs which have cervical disc lesions will present with pain as the only symptom. This pain is variable in severity. Some dogs merely exhibit reluctance to exercise, or to lower the head to drink or eat; others exhibit such severe signs of pain that physical examination cannot be carried out without general anaesthesia. Other individuals are more stoic and exhibit only mild pain responses such as tension or spasm in the cervical musculature during vigorous manipulation and palpation. Symptoms may appear acutely, but the severity typically increases over a period of days to weeks, despite analgesic therapy.

Some dogs which have cervical disc lesions exhibit signs of spinal cord dysfunction, varying from mild ataxia to non-ambulatory tetraparesis. The neurological deficits, if present, exhibited by dogs suffering cervical disc disease will reflect the region of the spinal cord that is affected, i.e. the C1–C4 segment or the C5–T3 segment. However, it is often not possible to state categorically which of the two areas is affected in each case. The severity of neurological deficits varies but it is

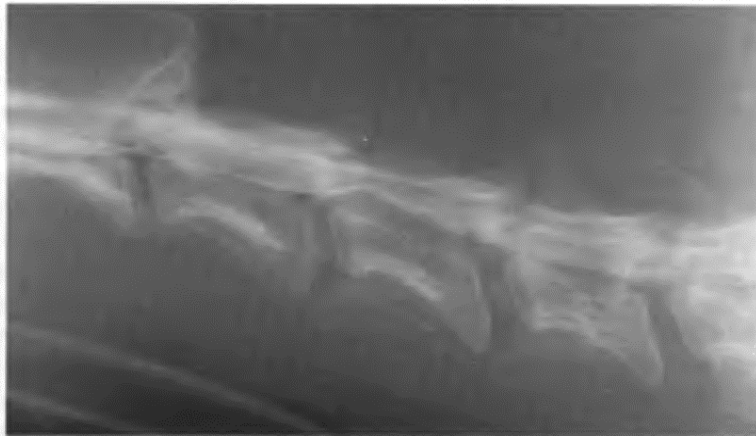


Figure 7.3 Typical myelographic appearance of type I disc extrusion. Extruded disc material commonly is found caudal to the intervertebral space.

extremely rare for there to be total loss of pain sensation, such as can occur following acute thoracolumbar disc extrusions. This is thought to be because the neural canal in the cervical region is relatively large compared with the cord, thereby rendering compressive lesions relatively less severe. Peracute ruptures of the cervical discs are also uncommon compared with the occurrence rate in the thoracolumbar region. Severe cord injury in the C5–C7 region can result in respiratory distress or even death due to paralysis of the diaphragm owing to interference in the phrenic nerve outflow, so clinical cases which have severe lesions at this level are rarely presented. Paralysis of the bladder causing incontinence rarely occurs following cervical disc disease, although it may be difficult to assess continence in a dog which is unable to stand or move.

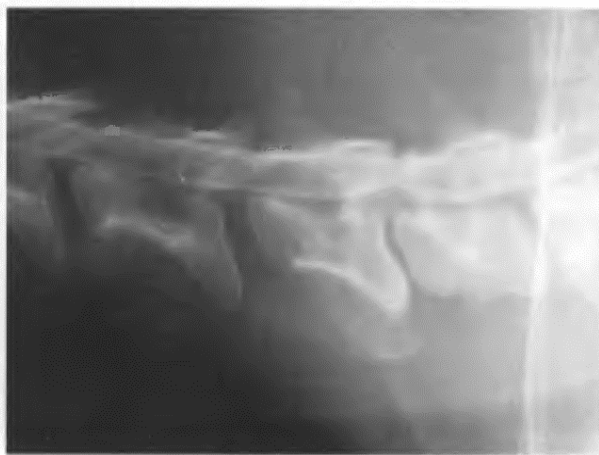


Figure 7.4 Type II disc protrusion at C6/7. This type of lesion is a common cause of the 'wobbler' syndrome – see Chapter 12.

Type II disc protrusion occurs in the cervical region of many breeds, most notably the Dobermann (Figure 7.4). In this breed the disc lesion is responsible for symptoms in the majority of mature animals presented with the 'wobbler' syndrome, which is considered in Chapter 12.

Cervical disc extrusions (type I) can occur in several directions and those which occur laterally can cause compression of the nerve root as it is transmitted through the intervertebral foramen. Nerve root entrapment can cause very severe pain and also can lead to a 'root signature'. Root signature refers to the finding of lameness in a limb in the absence of musculoskeletal abnormalities, except those causing nerve root compression. Dogs exhibiting root signature will often hold the leg up spontaneously, or when crying during physical examination, and this symptom implies that there is compression of the nerve roots of the cervical intumescence in the caudal cervical region. Intermittent signs of this nature are referred to as intermittent claudication and are thought to result from the increased compression of the nerve root which occurs during dilatation of the blood vessels which run alongside the nerve in the intervertebral foramen. Such symptoms are therefore often exhibited following or during bouts of exercise. The nerve root most commonly compressed in the cervical region is C7 as it exits the foramen between C6 and C7 vertebrae (Figure 7.5).

Thoracolumbar disc lesions

The presentation of dogs with evidence of thoracolumbar spinal pain or dysfunction is common in small animal practice. Most frequently this will be because of extrusion of type I discs in chondrodystrophic breeds. The presenting signs in these dogs can be highly variable. Clinical signs can include anything from pain only to paraplegia with loss of deep pain sensation. Typical early symptoms include arching (kyphosis) of the thoracolumbar region with pain evinced on palpation; mild proprioceptive deficits may or may not be present. Some dogs will exhibit progression of the symptoms over a period of several days, or even longer. Those presenting with vague signs of pain can be easily misdiagnosed as suffering from

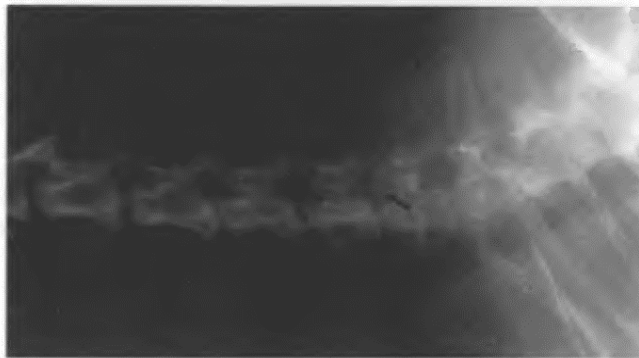


Figure 7.5 Lateralized disc extrusion at C6/7. Note cloud of calcified material in foramen (arrow) in this 45° oblique radiographic projection. This lesion was not visible on routine plain or myelographic views.

various painful conditions of the abdomen such as prostatitis, gastro-intestinal obstruction or pancreatitis. The likelihood of confusion may be increased by the tendency for dogs with severe thoracolumbar spinal pain to 'splint' the abdomen by increasing the tone of the abdominal muscles, which helps the dog to maintain the vertebral column as rigidly as possible. Because of the risk of misdiagnosis it is helpful for the clinician to have a high 'index of suspicion' for disc disease in breeds likely to present with this condition. For instance, a middle aged dachshund presented with an arched back and no other symptoms should be closely examined for evidence of back disease before an abdominal condition is suspected.

Although pain is a very common symptom of disc disease in the thoracolumbar segment, the incidence of associated neurological signs is much higher at this site than in the cervical region. Neurological signs usually reflect a transverse myelopathy affecting a portion of the T3-L3 segment. Some type I disc extrusions will result in a peracute onset of paraplegia. Disc lesions caudal to L4 do occur but are infrequent, with the exception of type II disc protrusions at the lumbosacral junction.

Type I and type II disc lesions are usually expressed in different breeds, but the clinical signs typically associated with each differ considerably. There is usually a slow onset of vertebral column pain with or without symptoms of a transverse myelopathy associated with type II disc protrusion, whereas the onset of symptoms is much more rapid and often more severe in association with type I disc extrusions.

The owners of affected dogs will often be able to state which hindlimb was initially affected in a dog which has shown progressive paraparesis, a feature which can be very helpful in determining the surgical therapy best suited to the patient. Extreme lateralization of disc extrusions in the thoracolumbar spine is relatively uncommon but will occasionally occur; affected animals will exhibit typical associated signs of severe nerve root compression. In unusual cases, signs of nerve root compression will occur without evidence of concurrent spinal cord compression. Symptoms of root signature can be observed in the caudal lumbar region (L4-L7) producing pelvic limb lameness; abnormalities in myotatic reflexes are also common in this group of cases.

Diagnosis of disc disease

A strong suspicion of symptomatic disc disease can be made on the basis of history; signalment and neurological findings. However, there are a large number of differential diagnoses that must be ruled out. Radiography is the most useful and commonly used modality in dogs. Plain radiographs can be used to rule out various differential diagnoses when surgical treatment is not contemplated and can be very suggestive of the site of a significant disc lesion.

Differential diagnosis of disc disease:

- Other compressive lesions
 - epidural
 - tumour
 - fracture/dislocation

- abcess
- haematoma
- vertebral anomalies
- intradural tumour
- Concussive injury
 - 'whiplash' injury (i.e. hyperextension)
 - traumatic disc extrusion (normal disc, extreme mechanical insult)
- Inflammatory conditions
 - meningitis/myelitis
 - corticosteroid responsive meningitis
 - GME/reticulosis
 - viral
 - bacterial
 - fungal
 - protozoal
 - vasculitis
- Vascular conditions
 - fibrocartilagenous embolization

For any case in which a disc lesion is suspected the diagnostic procedure is likely to include a myelogram. It is very important that a CSF sample should be collected during this procedure as many of the differential diagnoses are associated with abnormal CSF.

Calcification of the nucleus occurs as a consequence of type I disc degeneration and can be readily detected on plain radiographs. However, the finding of a mineralized disc does not indicate that the disc is responsible for the symptoms, merely that there is disc degeneration in that individual. In the cervical spine a radiographically calcified disc is frequently the site of an extrusion, whereas in the thoracolumbar region such discs are uncommonly the site of an 'active' lesion.

Active type I disc lesions will commonly exhibit one or many of the following features: narrowing or wedging of the intervertebral space; narrowing of the intervertebral foramen; collapse of the synovial joints; a cloud of calcified material seen apparently lying within the vertebral canal (in the cervical region a 'tail' of calcified material can be seen leaving the disc space in many cases) (Figure 7.6).

Although a tentative diagnosis can often be made from a plain radiograph, it is usually prudent to carry out myelography for two reasons: (i) there may be concurrent disease affecting that individual, i.e. calcified discs are common in middle aged and older chondrodystrophic dogs but are not always the cause of the animal's symptoms; (ii) the type of surgery (or other therapy) will depend on whether a compressive lesion can be diagnosed on myelography and its site relative to the spinal cord (Figure 7.7).

Type II disc protrusions will usually not be evident on plain radiographs although there is frequently spondylosis of the adjacent vertebral bodies, which could be interpreted as evidence of instability. Myelography is essential for diagnosis of type II disc protrusions (Figure 7.8).

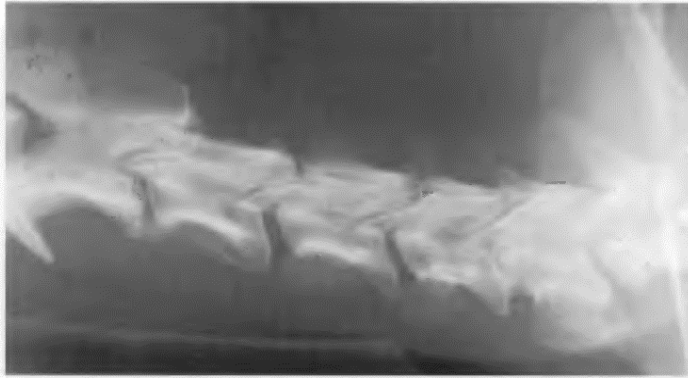


Figure 7.6 Typical lateral radiographic appearance of a type I cervical disc extrusion (C5/6).

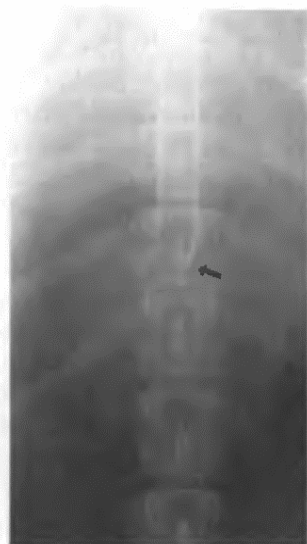
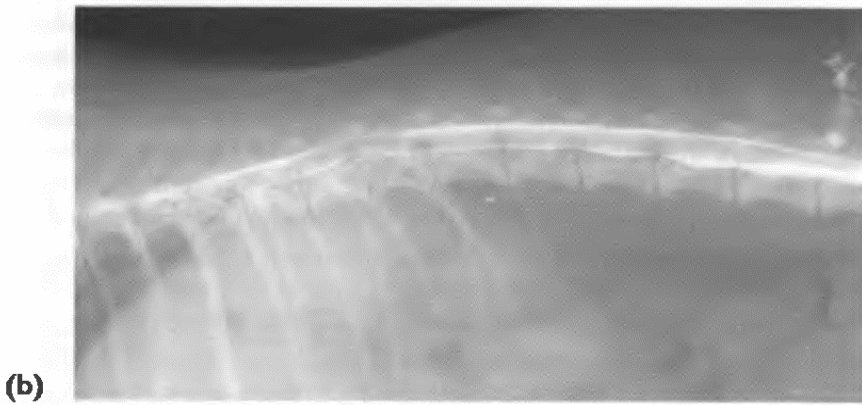
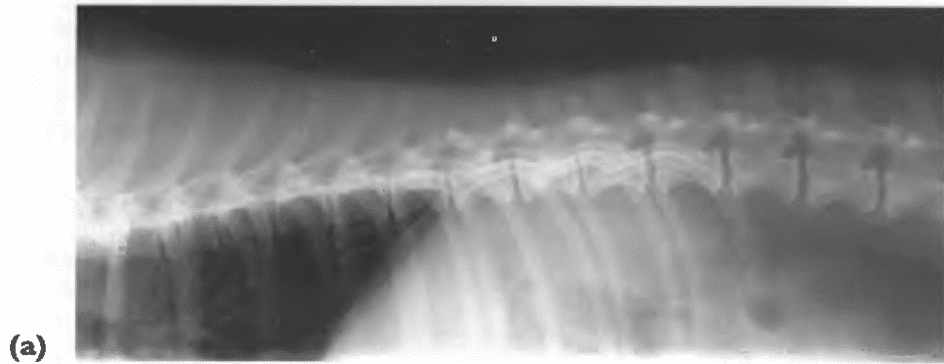
Myelography will usually confirm the site of a disc extrusion. However, extremely lateralized extrusions may not be detected definitively by either routine plain radiographs or by myelography. In these cases the use of an oblique view (at 45° to ventrodorsal view) to highlight the intervertebral foramen is essential to demonstrate the site of the extruded material. This view is best carried out before myelography and is essential in those cases exhibiting a root signalment. A classification of the various directions of cervical disc extrusion has been described by Felts and Prata (1983).

Management

A large number of dogs which have symptomatic disc disease can be adequately managed by conservative treatment. Such treatment usually consists of cage rest for a variable period, plus use of corticosteroids or nonsteroidal anti-inflammatory drugs to reduce pain. In the case of cervical disc extrusions, many conservatively treated animals will ultimately relapse and require surgery. For dogs which have mild symptoms caused by thoracolumbar disc extrusions, conservative therapy is the treatment of choice (especially if it is the first episode in that individual). However, there is a high risk of progression of the condition if conservative therapy is applied inappropriately or casually. Furthermore, thoracolumbar disc fenestration is an appropriate choice of treatment in an animal which has suffered multiple episodes of disc extrusion. Conservative therapy is discussed in more detail in Chapter 15.

Indications for surgery

Two main types of surgical treatment for disc disease are currently available in the dog: (i) fenestration and (ii) decompressive techniques. Fenestration is a procedure aimed at reducing the frequency of recurrent bouts of disc extrusion and is therefore used for prophylaxis. The efficacy of fenestration in reducing the rate of recurrence of symptomatic disc disease has been well demonstrated in several studies. Decompressive (mass removal) techniques are used in order to alleviate



(c)

(d)

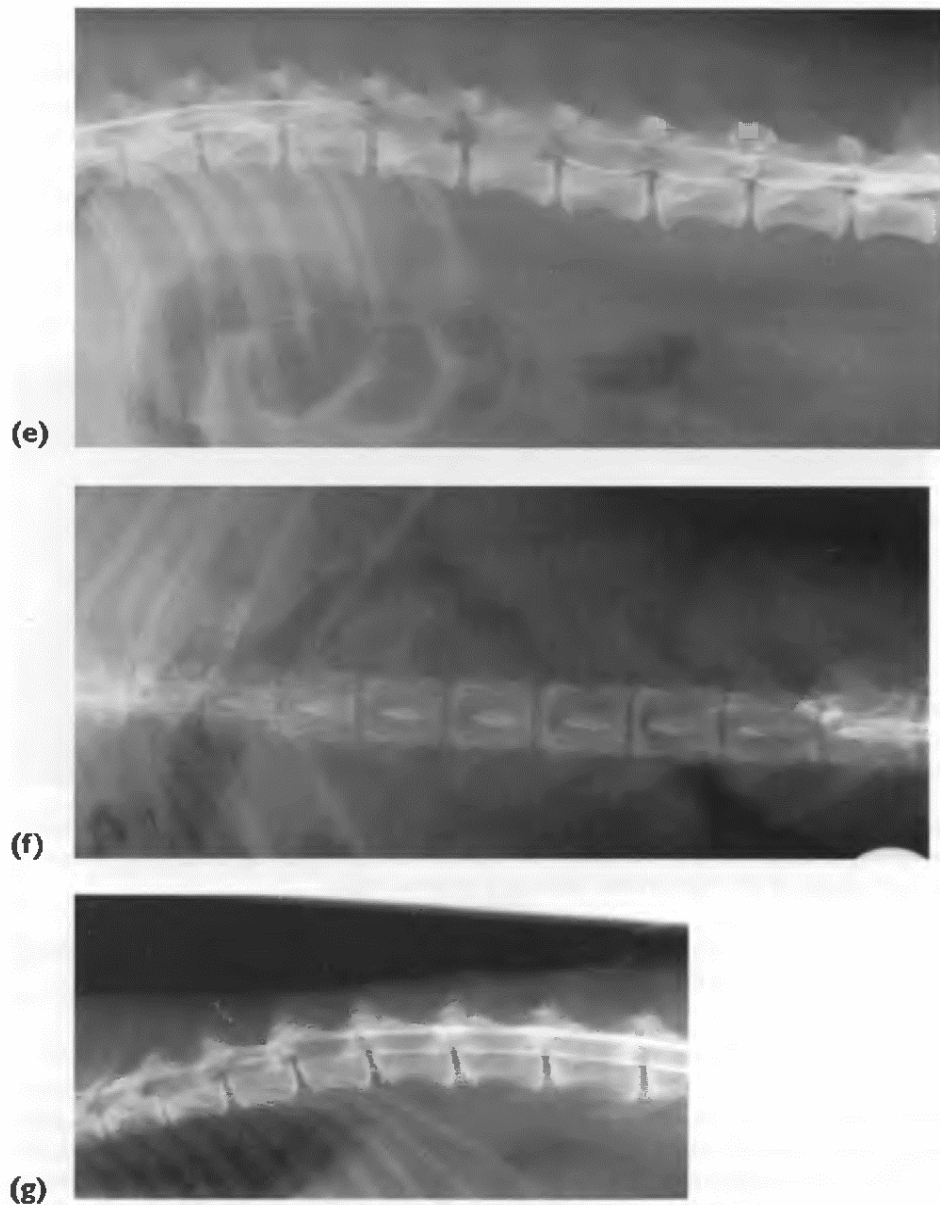


Figure 7.7 Selection of type I lumbar disc extrusions. (a) Characteristic plain radiographic findings associated with lesion at T12/13; note wedging of disc space, narrowing of intervertebral foramen and increased overlap of the articular facets. (b) Typical lateral myelographic appearance associated with lesion at T12/13. (c) Typical ventrodorsal view of disc extrusion at T12/13; note the clear indication that disc has extruded to the right-hand side. (d) Typical appearance of type I disc extrusion in a large-breed dog (Doberman); note the poor definition of contrast columns, although ventral column appears uninterrupted. (e, f) Typical lateral and ventrodorsal myelographic views following peracute disc extrusion; note the severe attenuation of the contrast columns despite injection at the lumbar site. (g) Type I disc extrusion at T12/13 in a cat; note the opacification by contrast material within T12 vertebral canal owing to local myelomalacia.

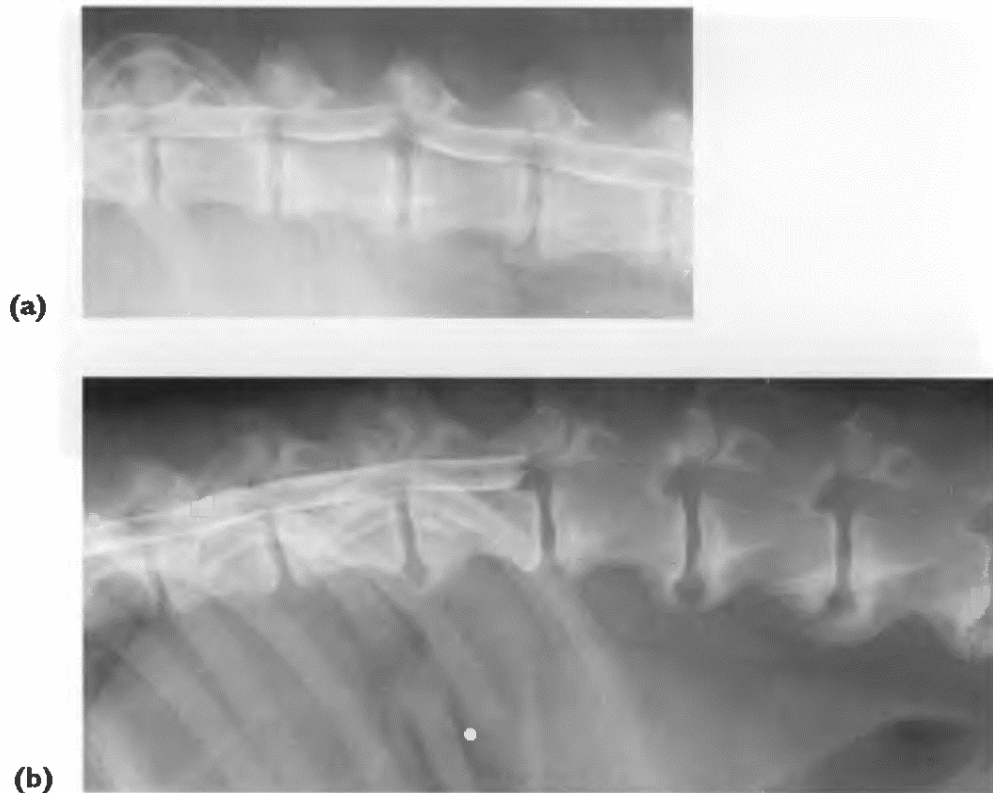


Figure 7.8 (a) Type II protrusion at L2/3; note the splitting of the ventral contrast column, indicating slight asymmetry of the lesion. (b) Type II disc protrusion at L1/2. Note associated degenerative disease of the intervertebral joints and vertebral bodies.

pain and neurological dysfunction, as an alternative to conservative management in animals suffering severe extradural compression.

CERVICAL DISC LESIONS

Surgical management is reserved for those ambulatory animals, in which conservative and medical therapy for up to 6 weeks has been ineffective, and for those exhibiting moderate or severe neurological deficits. Animals exhibiting very severe pain should be treated surgically as soon as possible on humane grounds. Decompressive approaches can be either dorsal, lateral or ventral.

Fenestration is commonly used as the surgical treatment for dogs which have cervical pain that is resistant to medical therapy. If an extrusion is present, it is difficult to understand the rationale for fenestration, as the only pain which would respond to this treatment is discogenic. It therefore seems logical to carry out myelography on every potential surgical case and to reserve fenestration for those cases in which an epidural mass cannot be identified and in which there is no evidence for other spinal disease, such as meningitis. Experience using this method has shown that very few such cases are suitable candidates for fenestration.

Decompressive surgery is required for those animals exhibiting severe neurological deficits and/or pain and with a demonstrable mass lesion on myelographic examination. The approach is determined by the site of the extruded material but is usually ventral (i.e. slot technique). Frequently a myelogram will identify an epidural mass overlying the relevant disc space and, commonly, extending a few millimetres caudally. Concurrent fenestration of all remaining cervical discs is recommended by many authors in order to reduce the risk of further extrusions at other spaces. The ventral slot operation is prophylactic at the operated space and usually there will ultimately be fusion of the drilled vertebral bodies.

In some instances, extradural material can be either tentatively or definitely observed during myelography to lie either lateral, dorsal, or dorsolateral to the spinal cord. Surgery to remove material from these sites must be considered exploratory as the diagnosis must always be in doubt until the area is thoroughly investigated. However, historical and other details of the individual case can provide a strong suspicion that a disc lesion is likely to be the cause of the dog's symptoms. Dorsolateral extruded material is the most difficult to identify accurately. Decompression of entrapped nerve roots must be carried out via a lateral or dorsal approach. Details of these procedures are discussed in Chapter 11.

Management of cervical type II disc protrusions is included in Chapter 12.

THORACOLUMBAR DISCS

Controversy centres around the question as to which patients should be treated surgically and which should be treated medically. To decide which type of therapy is appropriate, the animals can be categorized according to the severity of the symptoms which they are exhibiting. These categories are:

- I, pain only, first episode;
- II, pain only, second or more episodes;
- III, ambulatory paraparesis with or without pain on palpation;
- IV, non-ambulatory paraparesis or paraplegia; deep pain sensation intact;
- V, paraplegia, deep pain negative.

Some surgeons will also assess severity according to whether bladder function is intact or not; however, this is sometimes difficult to determine, for instance in peracute cases, or if the animal is confined in a cage. The presence or absence of intact bladder function does not alter the type of treatment recommended. A further factor is any change in the severity of the clinical signs; animals in which there is progression of symptoms should be considered more urgent candidates for surgical therapy; conversely, even badly affected animals in which the symptoms are regressing should be considered candidates for continued conservative therapy.

- Category I: normally treated conservatively, i.e. by cage confinement followed by physiotherapy and limited exercise. However, certain individuals, such as young chondrodystrophic dogs may be appropriate candidates for fenestration in order to reduce risks of future, perhaps more serious, episodes of dissociated disease.
- Category II: good candidates for fenestration.

- Category III: could be managed conservatively, but are at risk of deteriorating or suffering recurrence at a later date. Therefore many of these dogs are likely to require at least prophylactic treatment at some stage. A decision as to which treatment to carry out for these cases will be determined by the age of the dog, the number of previous episodes, duration of the current episode and degree of pain that the animal is in. A suitable course of action for many dogs in this category is to apply conservative therapy initially (unless the dog is in great pain). If the neurological deficits progress or fail to resolve then decompressive surgery can be carried out. If the neurological deficits resolve, but the dog is perceived to be at high risk of recurrence (i.e. is from a family line which has a high incidence of disc extrusions or has already suffered multiple episodes of disc-related problems), then fenestration is appropriate. Owners of dogs which fall into neither of these categories must still be advised of the risk of recurrence, but surgery would not be recommended.

Many animals in this group which are treated conservatively will have a prolonged period of recovery, and many will not have complete resolution of their neurological deficits. A great proportion of such cases have significant (and often very severe) spinal cord compression which can be clearly observed on myelograms.

- Category IV: recommend immediate decompressive surgery.

Dogs treated according to the above recommendations should all be expected to make a good recovery, i.e. recovery to normal or near normal function (i.e. neurological examination required to detect proprioceptive or other mild deficits). It would be expected that many cases in categories III and IV would also recover if treated conservatively, although the recovery period may be prolonged and neurological recovery is likely to be less satisfactory.

- Category V: this group is controversial. The time lapse between development of deep pain negative status and presentation to a veterinarian may be important. Most of these patients have a peracute onset of paralysis, having suffered acute concussive injury to the spinal cord. Many authors report that these dogs will not recover to walk, while others will give a variable prognosis dependent on the time elapsed since paraplegia occurred. Commonly cited recovery rates include 50% if operated within 12 h, 25% in first 24 h and 5% if longer than 48 h.

Successful results in group V dogs are reported to follow conventional decompressive surgery (i.e. extradural mass removal). However, this procedure would seem unlikely to affect the prognosis of a severely concussed cord. Severe concussive injury to the spinal cord sets into motion a cascade of events leading to necrosis of much spinal cord tissue (see Chapter 5). It seems improbable that mere removal of the extradural compressive mass will have any effect on these events taking place within the substance of the cord.

In the author's experience, those animals assessed to be 'deep pain negative' will not recover, whereas those with any deep pain response (however poor) will

recover ability to walk. The assessment of deep pain response varies from clinician to clinician, which could account for the differences in results obtained. Use of extremely severe stimuli (which involves crushing the terminal phalanges of each digit, the tail, the calcaneus and distal tibia with pliers or similar instruments) for assessment of deep pain response in dogs not responsive to lesser stimuli, may be required in order to demonstrate intact pain sensation in some severely affected cases. Care is required not to fracture the bones involved and to avoid damage to the skin on these areas. Animals with any degree of pain response, for example vague turning to the site of compression, are considered deep pain positive and will recover with conventional surgery, no matter how long they have been in that state. Some of these animals will not make a full recovery, i.e. will remain moderately ataxic, but will recover to walk unassisted. This technique for deep pain assessment can therefore be thought of as identifying a subset of animals which are deep pain negative to conventional testing but clearly have the potential to recover. Furthermore, the technique is a useful means of identifying clinically those animals with spinal cords which are damaged to the limit of that which has the potential to recover regardless of treatment. In experimental animals as few as 10% intact axons in the thoracolumbar cord are compatible with the ability to walk unassisted.

There have been some suggestions that dorsal laminectomy followed by piodomy or myelotomy may be beneficial to dogs with very severe cord lesions. This treatment can be offered to owners of such dogs up to 48 h after spinal cord injury but it is still prudent to offer a poor prognosis for recovery.

Conventional decompressive surgery involves making a bone incision overlying the offending disc material and removing it. The decompression of the spinal cord is effected by removal of extruded disc material; the removal of bone has no decompressive effect. Several approaches have been described, the advantages and disadvantages of each will be discussed in Chapter 13.

Most type I thoracolumbar disc extrusions will be seen on myelograms as an epidural mass associated with the dorsal annulus of the relevant disc. Occasionally, the extruded material will find its way to an unusual place, such as dorsal to the cord. This appears to be particularly common in the larger breeds of dog, such as the German shepherd and the Dobermann pinscher, which occasionally suffer type I extrusions. The problem in these cases is possible confusion with a tumour. A dorsal approach is mandatory for this type of mass but surgery must be considered exploratory. For other decompression a lateral or dorsal approach can be utilized.

ACQUIRED LUMBOSACRAL STENOSIS (DEGENERATIVE LUMBOSACRAL STENOSIS)

Acquired lumbosacral stenosis in the dog is usually the result of protrusion of type II degenerated discs, with or without concurrent abnormalities of the ligamentum flavum. Type II disc protrusion has been recognized as a frequent cause of hind-quarter pain and pelvic limb weakness in many large-breed dogs, especially German shepherd dogs. The onset of the condition is usually insidious but on occasion there may be sudden onset of pain and neurological deficits. The condition has probably been underdiagnosed in the past because of the easy confusion

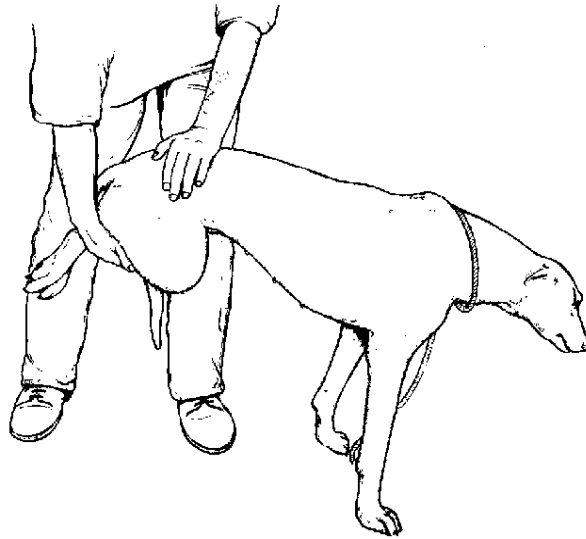


Figure 7.9 Examination of dog with suspected lumbosacral pain. The hips are kept flexed while the lumbosacral region is extended (dorsiflexed).

with hip joint disorders. On examination, affected dogs may exhibit a crouching gait, often with the pelvic limbs placed much more cranially under the body at rest than would be expected. Some dogs will exhibit lameness which may be exacerbated by exercise. This has been attributed to effects on the local vasculature and is referred to as intermittent neurogenic claudication. Affected dogs will often be presented because of a perceived difficulty in climbing stairs, or jumping.

Clinical examination of affected dogs may reveal abnormalities of proprioception but the most consistent finding is pain on palpation of the lumbosacral region. This pain may be evinced by extension of the lumbosacral joint, or by downward pressure on the spinous process of L7 vertebra. Care must be taken in examination of these dogs in that confusion with hip problems is possible and the two conditions may of course co-exist. It is useful to try to allow the hips to assume a flexed position when extending the lumbosacral spine (hip joint pain is usually less in this position) and to assess hip joint pain by abducting the joint (when pain is unlikely to be evinced from the lumbosacral region (Figure 7.9).

Neurological examination may reveal no abnormalities or there may be evidence of lower motor neurone disease of the L7-S3 segment, often including reduced hock strength. This is best observed by assessing the force of hock flexion during pedal reflex testing. Sometimes evidence of sensory deficits on the lateral surface of the lateral digit may be found. EMG evidence of denervation of the distal limb musculature, anal sphincter and tail may be found and confirms that there is neurological involvement.

Diagnosis is usually confirmed by imaging the affected region. There has been some controversy about the best first test to use. Some authors recommend myelography as the first test. Myelography is undoubtedly useful in some animals, particularly when used in combination with flexion and extension studies (Figure 7.10). However, in some animals, particularly those of the larger breeds, the

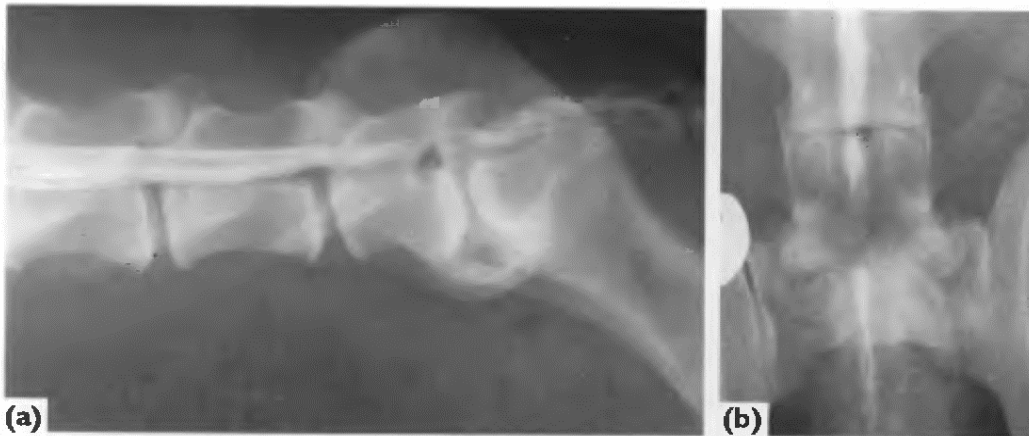


Figure 7.10 (a, b) Lateral and ventrodorsal myelograms of the lumbosacral region. Note elevation of the ventral contrast column on the lateral projection and severe attenuation of the contrast columns on the ventrodorsal view.

subarachnoid space either terminates or is elevated from the floor of the vertebral canal some way cranial to the lumbosacral disc, rendering the images non-diagnostic. Other techniques include discography, which is best performed with image intensification, and epidurography. The various techniques have been compared in several studies. False positive and false negative results have been obtained with most techniques. On the whole, the recommendation would be to use myelography first, partly in order properly to assess more cranial disc spaces such as L5 and L6. Discography and epidurography could then be performed if required (Figure 7.11). The most useful and non-invasive technique, if available, is MRI. This technique can demonstrate abnormalities of the L7 disc and the compression of the nerve roots very well.

Other degenerative conditions of the vertebral column

DEGENERATIVE JOINT DISEASE (DJD) OF THE SYNOVIAL JOINTS

This condition is very frequently observed in all types of older dog but is especially common in the larger breeds. In some animals previous occurrence of osteochondrosis dissecans may be associated with development of DJD in later life. DJD of the synovial joints of the vertebral column is certainly very common in the great Dane. DJD in the vertebral column may be observed in all regions but is most common in the cervical and lumbar areas.

The diagnosis of DJD in the synovial joints can be made on plain radiographs. New bone formation is observed around the articular processes, often forming sharp projections (Figure 7.12). Effusion within these joints is difficult to recognize radiographically.

DJD is rarely a cause of neurological symptoms but may be a cause of spinal pain in some dogs, or symptoms of nonspecific stiffness associated with rising from recumbency in older dogs. In rare cases, there can be neurological signs associated with DJD, especially in the cervical region if the distended joint capsule extends

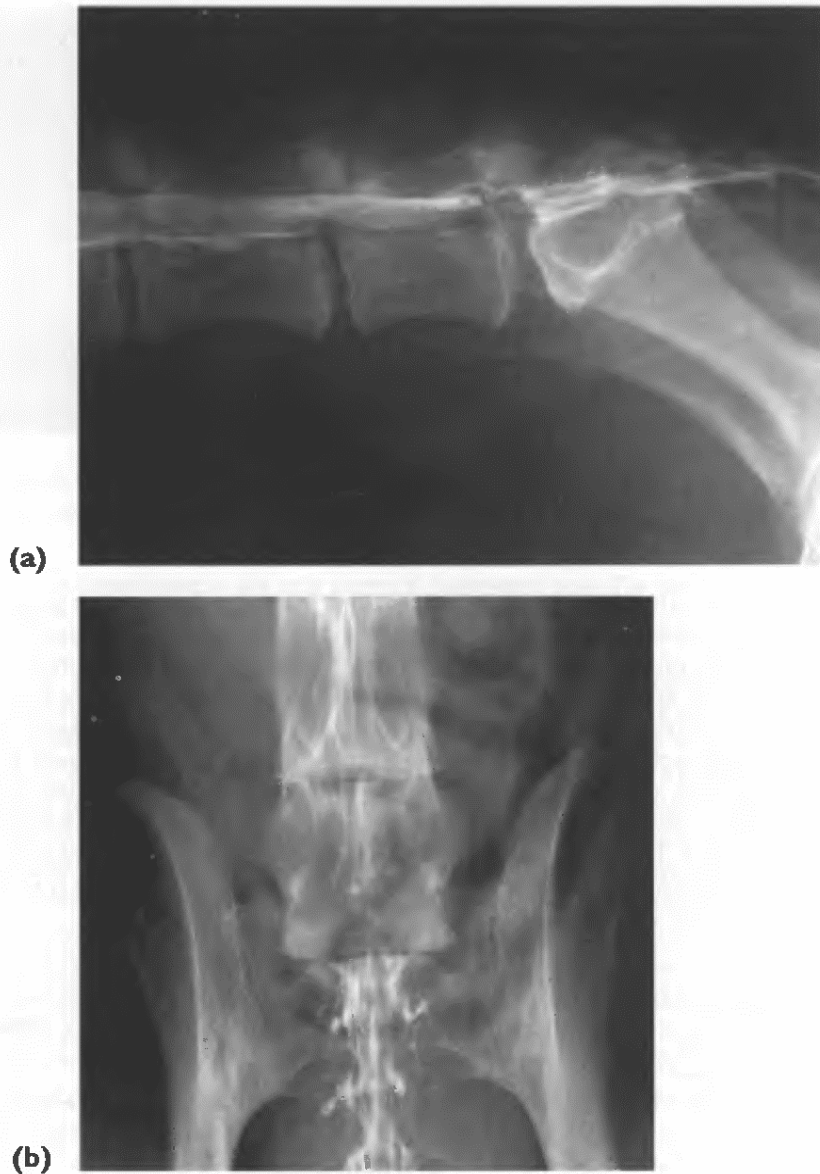

Figure 7.11 (a, b) Lateral and ventrodorsal epidurograms of the lumbosacral region. Note elevation and attenuation of the contrast columns similar to that in Figure 7.10.

sufficiently to impinge on the nerve roots or spinal cord. This means of nerve root compression has also been observed in some cases of lumbosacral disease.

Treatment for the condition is almost exclusively medical (i.e. nonsteroidal analgesics/anti-inflammatory drugs), although surgical therapy could have a role in selected cases in order to alleviate compression of nerve roots, i.e. removal of soft tissue and bone of the joint.




Figure 7.12 Severe degenerative joint disease affecting the synovial joints between articular facets.

SPONDYLOSIS DEFORMANS

Spondylosis is the term used to describe the proliferative bony changes which occur on the ventral and lateral aspects of the vertebral bodies. Hansen (1952) proposed that spondylosis was caused by stretching of the ventral longitudinal ligament as the result of ventral disc protrusions; in humans a similar mechanism has been suggested. Radiographic signs consist of osteophytes, which are most easily visible on the ventral margins of the vertebral endplates. These may grow to large size and span the gap between neighbouring vertebrae – termed ‘bridging spondylosis’. There will be an associated loss of normal range of movement. Care must be taken to distinguish between spondylosis, which is a degenerative condition associated with bony proliferation and spondylitis which is an inflammatory condition in which bony destruction as well as proliferation occurs. On lateral radiographs it is possible for early osteophytes to be confused with degenerated disc material within the vertebral canal; use of ventrodorsal radiographic views will help to ascertain clearly the position of such osteophytes.

It has been suggested that spondylosis may occur at the site of instability and there certainly appears to be a high incidence of spondylosis at sites of type II disc lesions in the cervical and lumbar regions of the vertebral column. However, care should be exercised in interpretation of the significance of spondylosis; myelography is required in order to diagnose definitively the presence of significant disc lesions or instability at an affected site. Spondylosis occurs with considerable frequency at the lumbosacral junction but is not always associated with type II disc protrusions at that site (Figure 7.13).

Spondylosis is usually regarded as an incidental finding and rarely is a cause of neurological symptoms in itself, although it may give rise to pain or stiffness. Occasionally, spondylosis is thought to result in nerve root compression because of impingement of the proliferated bone as they exit from the intervertebral foramina. This cause of nerve root signs is probably underdiagnosed in dogs as the condition is quite common in people and can give rise to very significant symptoms (for instance cervical spondylotic radiculopathy). In dogs the most likely sites to cause detectable nerve root pain would be at the lumbosacral junction and as part of the ‘wobbler’ syndrome, in combination with stenosis of the intervertebral foramina. It can usually be demonstrated by myelography that

spondylosis cannot be the cause of spinal cord compression but the diagnosis of nerve root compression is very much more difficult. The condition in people is more easily recognized owing to the frequent use of CT scanning for investigation of spinal/nerve root pain.

Although symptoms of pain caused by spondylosis in dogs are generally mild, or even asymptomatic, certain individuals may be very severely incapacitated. In cats, severe spondylosis can be found as a result of vitamin A intoxication, which frequently affects the cervical region of the vertebral column in this species and can cause a dramatic reduction in its mobility.

Spondylosis rarely requires treatment as such, as it is usually asymptomatic. Nonsteroidal anti-inflammatory drugs can be used as symptomatic treatment for the stiffness exhibited by some individuals which cannot be explained by other lesions. Medical treatment will merely suppress the symptoms but will not cause regression of the lesion itself.

DURAL OSSIFICATION

In this condition there is development of bony plaques within the dura mater. Often this may be recognized on radiographs as a thin radiodense line or lines running within the vertebral canal, looking similar to myelographic contrast columns (Figure 7.14). The condition is thought not to be a cause for clinical signs, although previous confusion of this condition and the clinical signs of degenerative myelopathy has occurred in the German shepherd dog because of the frequency of both conditions in middle-aged and older dogs of this breed. Fractures of the ossified dura with consequent haemorrhage have been reported as a rare cause of paraparesis.

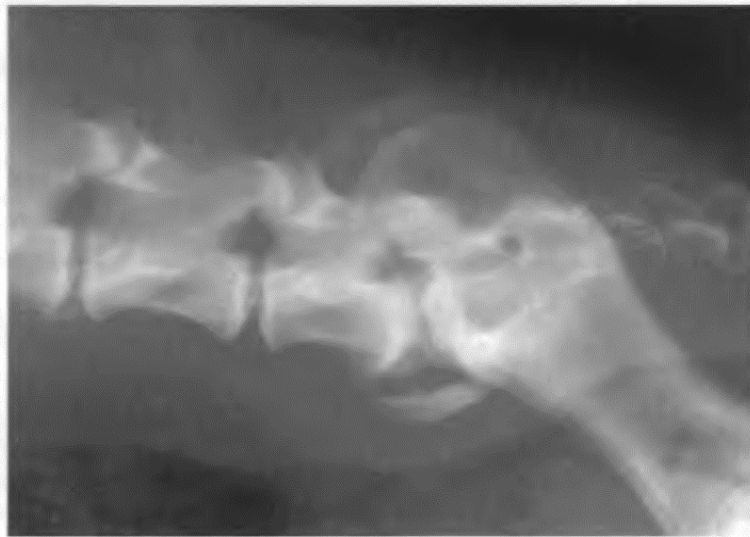

Figure 7.13 Lumbosacral spondylosis. There may or may not be disc degeneration at the same site – contrast radiographs and electrophysiological tests would be required for diagnosis.



Figure 7.14 Dural ossification. Courtesy of Mr M. Herrtage, Cambridge University Veterinary School, UK.

SPONDYLOLISTHESIS

Spondylolisthesis is the term used to describe 'slippage' between one vertebra and its neighbour. The condition is often seen in the cervical spine as one part of the 'wobbler' syndrome, or at the lumbosacral junction. Stressed radiographs may be required to demonstrate the malalignment, i.e. extended and flexed lateral views. The term spondylolisthesis is rejected by some authors on the grounds that the condition is secondary to other lesions (notably type II disc protrusions and vertebral body malformation). Listhesis of adjacent vertebrae may or may not be a cause of compression of the spinal cord as it traverses the intervertebral space. Treatment of the condition may be required if there is demonstrable spinal cord compression, which would normally consist of attempts to stabilize the vertebrae and/or remove associated soft tissue compressions (discs and ligamentum flavum).

Degenerative conditions of the spinal cord

Degenerative myelopathy

This condition is most commonly encountered in the German shepherd dog but can also occur in German shepherd cross-breed dogs and some other large-breed dogs. The symptoms usually appear when the dog is middle aged or older, i.e. about 7 years or older. The owners typically report that the animal is becoming more clumsy in the hindquarters, drags the toenails of the pelvic limbs and tends to sway or even fall as it turns corners. Both sexes appear to be equally affected. The symptoms usually are equally prominent in both pelvic limbs, but there will occasionally be slight asymmetry. Continence and nociception remain intact.

Affected dogs walk with an ataxic pelvic limb gait, sometimes with a tendency to mild hypermetria; swaying is often observed, particularly if the dog is made to turn in a tight circle. Physical examination usually reveals that there is abnormal wear of the toenails on the pelvic limbs. Although many affected dogs will have concurrent hip dysplasia, the gait abnormality can usually clearly be attributed to a neurological condition in view of the depressed proprioceptive responses. Transient improvement in the dog's walking ability in response to anti-inflammatory

medications can often be attributed to the effects of these drugs on concurrent orthopaedic disorders.

Neurological examination usually reveals severe depression of the postural responses in the pelvic limbs, with severe deficits in proprioceptive paw positioning. Thoracic limb responses and reflexes are intact in the early stages but very advanced cases (usually such animals are unable to support weight on the pelvic limbs) will exhibit depression of responses in these limbs also. 'Segmental' spinal reflexes are intact in the vast majority of cases. Occasional animals will exhibit depression of the patellar reflexes, thereby prompting a more likely diagnosis of degenerative radiculomyelopathy (i.e. involvement of nerve roots as well as spinal cord). The condition does not appear to be painful, a feature which can be important in differentiation from other spinal conditions which may cause similar symptomatology.

Definitive diagnosis is based on post mortem examination in most cases, although MRI and blood tests to demonstrate depressed cell-mediated immune responses have also been used in order to make the diagnosis in the live animal. In many cases, the use of myelography is important in order to rule out the possibility of compressive disease as a cause of a dog's symptoms. It should be noted that temporary deterioration in neurological status following myelography appears to be more common in dogs suffering degenerative myelopathy than in dogs with other causes of spinal dysfunction. This temporary deterioration can be expected to last up to 2 or 3 days and the dog will then return to premyelographic status. Important differential diagnosis to be considered consist of type II disc disease and intraspinal neoplasia (especially intradural tumours which generally do not result in pain). These differential diagnoses can be eliminated by negative findings on myelography and a likely presumptive diagnosis of degenerative myelopathy can be established. A more common finding which can lead to some difficulty is the discovery of a compressive lesion (especially a type II disc lesion) in a German shepherd dog of middle age. The question arises as to the significance of such a lesion compared with the possibility that the dog is also suffering degenerative myelopathy. It is necessary that the importance of the compressive lesion should be established before surgical removal is undertaken. The simplest way around the problem is to use corticosteroid therapy as a trial.

Corticosteroids will usually rapidly (within 2 to 3 days) improve the neurological status of a dog affected by chronic spinal cord compression. There will be no appreciable effect on the neurological deficits of a dog affected by degenerative myelopathy alone. Following this response the issue of surgery can be discussed with the client regarding the likely positive results which would accrue from surgery. If corticosteroids are able substantially to improve the dog's neurological function it is likely that surgery will have a similar effect.

Degenerative myelopathy lesions consist of loss of myelin sheaths and axons in the white matter of the spinal cord. The most affected area is the cranial thoracic spinal cord and demyelination is the predominant feature. There is an increase in cellular and vascular components seen at light microscopic level and the pathogenesis is assumed to be immune mediated.

Treatment for degenerative myelopathy is limited. The condition is progressive and most affected dogs will progress to non-ambulatory paraparesis within about 9 to 12 months of onset of symptoms. Treatment with corticosteroids, which has been

advocated in the past, should be avoided as there is a tendency for it to cause increased muscle wasting and weakness. More recently, use of amino caproic acid and vitamin E has been recommended and has been suggested to cause a reduction in rate of disease progression. Experience in a number of clinics has demonstrated poor results from this type of therapy. In general, the prognosis appears to be hopeless.

In addition to the most common degenerative myelopathy described above, there have been a number of reports of similar conditions occurring in two young German shepherd dogs, an aged miniature poodle and a family of Siberian husky dogs.

Hound ataxia

A slowly progressive ataxia has been described in several different breeds of hounds kept in kennels and used for hunting. A swaying gait with a 'kicking' pelvic limb action was noted; segmental spinal reflexes were intact. Proprioceptive responses were intact in most affected dogs. Post mortem examination revealed Wallerian degeneration in most of the spinal cord white matter, with relative sparing of the dorsal columns. The aetiology is unknown, but a nutritional deficiency remains the most likely possibility.

Neuraxonal dystrophy

This condition has been reported in the USA in the Rottweiler. Dogs of this breed and with consistent symptoms have been clinically examined in this country but there are no definitive reports (i.e. histological confirmation) of the condition in the UK.

This condition affects young Rottweilers (i.e. around 1 year old). Initial symptoms may be observed during puppyhood when the dog is noticed to be clumsy. Ataxia of the pelvic limbs and a hypermetric thoracic limb gait are the usual presenting symptoms. Dogs affected with neuraxonal dystrophy do not exhibit deficits in proprioceptive paw positioning and segmental spinal reflexes remain intact or hyperreflexive. Progression of the disease is very slow, such that affected dogs of 5 or 6 years old will still be able to walk, although they are grossly ataxic. Late in the course of the disease, affected individuals will exhibit deficits of head and eye coordination, tremor and loss of menace reflexes. These features can be important in differentiation of the condition from leukoencephalomalacia, which also occurs in the Rottweiler and causes many of the same initial neurological deficits (see below). Both conditions are nonpainful – a feature that can help in differentiating these diseases from others such as meningitis and the 'wobbler' syndrome.

Histological examination of dogs affected by neuraxonal dystrophy reveals little abnormality; however, dystrophic neurones, with spheroidal appearance, will be observed in certain medullary nuclei.

There is no treatment but affected dogs may live a satisfactory pain-free life for many years.

Leukoencephalomyelopathy (LEM) of Rottweilers

This condition initially appears clinically very similar to the neuraxonal dystrophy which affects the same breed and is described above. LEM has been reported in the USA, Holland and Australia but there are no reports of this condition in the UK. Dogs affected with LEM appear normal until the disease onset at between ½ and 4 years old. In the early stages there is ataxia of the pelvic limbs and hypermetria of the thoracic limbs as in neuraxonal dystrophy. Local spinal reflexes remain intact, although there is commonly hyperreflexia or even clonus. Paraparesis, tetraparesis and loss of proprioceptive responses develop during the following few weeks to months. Severe tetraparesis develops within 6 to 12 months of onset of symptoms, resulting in the need for euthanasia.

At post mortem examination all white matter tracts of the spinal cord are affected by malacia, especially in the cervical region. Demyelination predominates, together with mild axonal changes.

The differential diagnosis for animals affected by both the above conditions includes compressive disease of the spinal cord such as 'wobbler' syndrome, and various inflammatory or infectious conditions. Myelography is required to eliminate compressive lesions from consideration and examination of CSF can help in ruling out the presence of significant inflammatory disease. If the results of all diagnostic tests are negative and the dog exhibits suitable clinical signs, one of the above degenerative conditions can be assumed. The differentiation of the two conditions can be made on clinical examination over a period of months, during which the typical features of the two diseases become more apparent. Confirmation of either diagnosis requires post mortem and histological examination.

Miscellaneous

There are many reports of degenerative disease affecting the spinal cord of specific breeds or litters. Some of these conditions have also been shown to be inherited. The frequency of these disorders is low and many have only been reported once in the veterinary literature. The characteristic features of many of these diseases is that they are progressive, nonpainful and may affect young, often pedigree, animals. No abnormalities are detected on myelographic studies and CSF examination is usually unhelpful. Diagnosis is usually made at post mortem examination.

Should one of these disorders be suspected it is helpful to refer to a list of breed-associated spinal cord diseases (e.g. Oliver *et al.*, 1987).

Associated reading*Degeneration of the vertebral column*

- Ball M.U., McGuire J.A., Swaim S.F., Hoerlein B.F. (1982) Patterns of occurrence of disk disease among registered dachshunds. *J. Am. Vet. Med. Assoc.* **180**, 519.
 Braund K.G. (1993) Intervertebral disk disease. In: Bojrab M.J. (ed.) *Disease Mechanisms in Small Animal Surgery*, 2nd edn. Philadelphia, Lea and Febiger, p. 960.
 Braund K.G., Ghosh T.F., Larsen L.H. (1975) Morphological studies on the canine

- intervertebral disc. The assignment of the beagle to the achondroplastic classification. *Res. Vet. Sci.* **19**, 167.
- Brown N.O., Helphrey M.L., Prata R.G. (1977) Thoracolumbar disk disease in the dog: a retrospective analysis of 187 cases. *J. Am. Anim. Hosp. Assoc.* **13**, 665.
- Felts J.F., Prata R.G. (1983) Cervical disk disease in the dog: intraforaminal and lateral extrusions. *J. Anim. Hosp. Assoc.* **19**, 755.
- Gage E.D. (1975) Incidence of clinical disc disease in the dog. *J. Am. Anim. Hosp. Assoc.* **11**, 135.
- Goggin J.E., Li A., Franti C.E. (1970) Canine intervertebral disc disease: characterisation by age, sex, breed and anatomic site of involvement. *Am. J. Vet. Res.* **31**, 1687.
- Griffiths I.R. (1985) Progressive axonopathy: an inherited neuropathy of boxer dogs 1. further studies of the clinical and electrophysiological features. *J. Small Anim. Pract.* **26**, 381.
- Hansen H.J. (1952) A pathologic-anatomical study on disc degeneration in dog. *Acta. Ortho. Scand. Suppl. XI*.
- King A.S., Smith R.N. (1960) Protrusion of the intervertebral disc in the cat. *Vet. Rec.* **70**, 504.
- Larsen J.S., Selby L.A. (1981) Spondylosis deformans in large dogs – relative risk by breed, age and sex. *J. Am. Anim. Hosp. Assoc.* **17**, 623.
- Morgan J.P., Stavenborn M. (1991) Disseminated idiopathic skeletal hyperostosis (DISH) in a dog. *Vet. Rad.* **32**, 65.
- Prata R.G. (1983) Cervical and thoracolumbar disc disease in the dog. In: Kirk R.W. (ed.) *Current Veterinary Therapy VIII*. Philadelphia, W.B. Saunders, p. 708.
- Priester W.A. (1976) Canine intervertebral disc disease – occurrence by age, breed and sex among 8117 cases. *Theriogenol.* **6**, 293.
- Romatowski J. (1986) Spondylosis deformans in the dog. *Comp. Cont. Ed. Pract. Vet.* **8**, 531.
- Verheijen J., Bouw J. (1982) Canine intervertebral disc disease: a review of etiological and predisposing factors. *Vet. Quart.* **4**, 125.
- Wright J.A. (1977) A study of the radiographic anatomy of the cervical spine in the dog. *J. Small Anim. Pract.* **18**, 341.
- Wright J.A. (1982) A study of vertebral osteophyte formation in the canine spine. I. Spinal survey. *J. Small Anim. Pract.* **23**, 697.

Degeneration of the spinal cord and meninges

- Chrisman C.L. (1992) Neurological diseases of rottweilers: neuraxonal dystrophy and leukoencephalomalacia. *J. Small Anim. Pract.* **33**, 500.
- Clemmons R.M. (1989) Degenerative myelopathy. In: Kirk R.W. (ed.) *Current Veterinary Therapy X*. Philadelphia, W.B. Saunders, p. 830.
- Clemmons R.M. (1992) Degenerative myelopathy. *Vet. Clin. N. Am.* **22**, 965.
- Cork L.C., Troncoso J.C., Price D.L. (1983) Canine neuraxonal dystrophy. *J. Neuropathol. Exp. Neurol.* **42**, 286.
- Duncan I.D., Griffiths I.R. (1981) Canine giant axonal neuropathy; some aspects of its clinical, pathological and comparative features. *J. Small Anim. Pract.* **22**, 491.
- Gamble D.A., Chrisman C.L. (1984) A leukoencephalomyelopathy of rottweiler dogs. *Vet. Pathol.* **21**, 274.

- Matthews N.S., deLahunta A. (1985) Degenerative myelopathy in an adult miniature poodle. *J. Am. Vet. Med. Assoc.* **186**, 1213.
- Morgan J.P. (1969) Spinal dural ossification in the dog. *J. Am. Vet. Radiol. Soc.* **10**, 43.
- Oliver J.E., Hoerlein B.F., Mayhew I.G. (1987) Appendix II Species and breed predisposition for noninfectious diseases. In: Oliver J.E., Hoerlein B.F., Mayhew I.G. (eds) *Veterinary Neurology*, 1st edn. Philadelphia, W.B. Saunders, p. 525.
- Palmer A.C., Medd R.K., Wilkinson G.T. (1984) Spinal cord degeneration in hound ataxia. *J. Small Anim. Pract.* **25**, 139.

CHAPTER 8

Fractures, Luxations and External Trauma to the Vertebral Column

Contents

<i>Introduction</i>	111
<i>Reduction methods</i>	114
<i>Methods of surgical fixation of spinal fracture/dislocations</i>	115
<i>Bullets/pellets</i>	123
<i>Hyperextension, 'traumatic discs' and cord concussion</i>	124
<i>Conservative management of spinal fracture/luxations</i>	126
<i>Associated reading</i>	127

Introduction

Trauma to the spinal cord can arise as the result of external agents such as road traffic accidents or falls, which cause damage to the skeletal elements of the vertebral column or as a result of internal injury such as that caused by disc extrusions. In this chapter the results of external trauma will be considered.

Spinal trauma from external agents is common and usually the result of road traffic accidents. Severe trauma is required in order to produce vertebral column injury; consequently, many of the animals presented after such trauma are in shock and have other injuries, some of which may be considered more important than the spinal injury, or be life threatening in themselves. Therefore, it is essential that such cases should be examined and treated following a logical plan; the 'ABC' method is frequently used. This approach has been described in detail by Brasmer (1984); A is for airway, B is for bleeding and C is for central nervous system, etc. This method ensures that injuries are dealt with in their correct order of priority. It is important to assess neurological injuries at an early stage because they may require urgent treatment and also because they may be of sufficient severity that the client may not wish for further treatment to be continued. This is especially the case for animals which are liable to become permanently incontinent.

Having dealt with the immediately life-threatening injuries, a complete neurological examination should be carried out. Neurological examination of such cases requires great care, as inappropriate handling of the vertebral column may cause further damage to neural tissue. When possible, the person attending the scene of the accident should make efforts to secure the patient to a rigid object such as a plank of wood or other rigid support, thereby limiting the movement at the site of injury. Smaller animals may sometimes be safely and conveniently manipulated by the scruff of the neck. Problems can be encountered in the neurological examination of severely traumatized animals, in particular those that are unconscious at

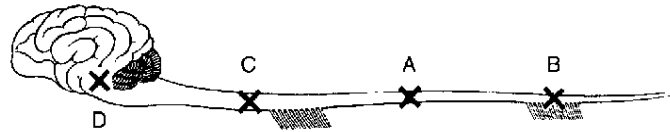


Figure 8.1 Symptoms of a lesion at A can be masked by a lesion at B (which affects the lower motor neurone). Furthermore, a lesion at C can be difficult to detect if there is a lesion at D (which will produce similar signs plus those relating to the brain).

presentation. For these cases, radiographs of the entire vertebral column should be obtained. Other problems relate to the frequency of multiple vertebral injuries (about 20% of animals with vertebral column injuries have lesions at more than one segment of the vertebral column). For this reason, extreme care must be taken when evaluating animals with external trauma, particularly as lesions of the lower motor neurone loop can mask lesions of the upper motor neurone pathways (Figure 8.1).

Force applied to the vertebral column may be in several different planes. Traction, compression, extension, flexion and torsion may all occur as the result of external trauma. Commonly, a combination of the various types of force will occur simultaneously and will also be affected by the tone of the axial musculature during the traumatic event. The various types of force acting on the vertebral column will lead to different combinations or types of fracture and luxation. This has been summarized by Thacher (1993).

It is important for the surgeon to understand how a particular fracture or luxation has occurred in order to identify the optimal means of reduction and fixation of the injury. In the case of a compression fracture of the ventral aspect of a vertebral body, the likely cause would be axially applied compression. The best means of stabilizing such a fracture would be to resist compression, for example by rigid fixation of the ventral aspect of the vertebral body. An animal exhibiting a fracture/luxation would be presumed to have suffered both axial compression or extension (depending on the site of the fracture) with concurrent torsion. The treatment of such an injury must address the consequent rotational instability and aim to promote stability in torsion.

It is important during assessment of vertebral fractures and luxations to remember that the radiographs represent the positions of the spinal cord and vertebral column at that instant and that, at the time of injury, the fragments may have been considerably more displaced. The neurological examination must be used to determine the severity of the injury, not the positions of the bones on radiographs. The radiographs may reveal little displacement in cases in which complete functional transection of the cord has occurred. The neurological examination must be used as a basis to decide whether surgical intervention or any treatment at all is warranted – in cases which have loss of deep pain sensation, euthanasia may be the best course of action.

Diagnosis

A strong presumption of spinal cord trauma is usually based on the history and neurological examination. Diagnosis is usually confirmed with plain radiographs. It is important that the entire vertebral column be radiographed as there are

frequently multiple spinal injuries. Sometimes myelography can be helpful in identifying the extent of spinal cord injury, or its exact site in cases which have multiple vertebral injuries. It may also help to identify the presence of fragments of bone or haematoma in the spinal canal. However, the presence of contrast agent in the spinal canal can also obscure bone fragments. Owing to the severe cord injury and consequent oedema following vertebral fracture or luxation, lumbar myelography is preferable to the cervical route, unless suitable positioning of the patient may incur risk of injury to the spinal cord.

Treatment

Making the decision as to whether an animal should be treated conservatively or surgically can be difficult. One indication for surgery is 'instability', which may not be easy to determine objectively; a second indication is if there is severe disruption of the shape of the vertebral canal. The most helpful means of categorizing the various vertebral column injuries is to use a modification of the three-column system devised for classifying similar injuries in people. The use of this system can help to define more objectively the significance of the observed abnormalities.

The three columns are: (i) ventral aspect of vertebral body, ventral longitudinal ligament, ventral part of the anulus fibrosus; (ii) dorsal part of vertebral body, dorsal longitudinal ligament, dorsal anulus; and (iii) lamina of vertebrae, synovial joint and associated capsule, and ligamentous structures dorsal to the spinal cord, such as ligamentum flavum, interspinous ligaments (Figure 8.2). Disruption of two or more of these columns has been associated with instability sufficient to require surgical intervention.

Non-operative therapy can be highly appropriate for a large number of spinal fractures and luxations and some authors have questioned the ability of internal fixation adequately to stabilize the injured vertebral column. Treatment by means of external splinting or casts is best applied to those cases which do not have injuries


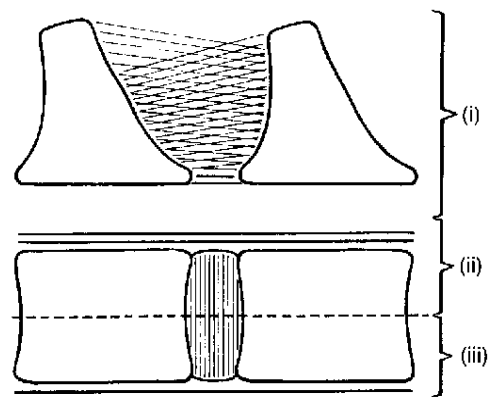


Figure 8.2 The three columns of the vertebral column are:
 (i) dorsal – arch of the vertebral canal and dorsal ligaments (flaval, interspinous and supraspinous plus joint capsule)
 (ii) middle – dorsal longitudinal ligament, dorsal anulus and dorsal portion of the vertebral body
 (iii) ventral – ventral longitudinal ligament, ventral anulus and ventral portion of the vertebral body.

sufficient to cause instability (as defined by the three-column system) or severe disruption of the vertebral canal. Advantages of surgical treatment include the possibility of introducing aggressive rehabilitation methods for animals with stable injuries. Early and aggressive attempts at rehabilitation are likely to be associated with a quicker return to ambulation with fewer of the problems consequent on recumbency, such as bedsores, urine scalding and pneumonia.

There is controversy regarding the value of laminectomy or hemilaminectomy in treatment of animals with vertebral fractures or luxations. The benefit of laminectomy is that it allows direct inspection of the dura, more complete estimation of the degree of compression and removal of loose chips of bone from within the vertebral canal. Durotomy can also be carried out for prognostic purposes in selected cases. The problem associated with laminectomy is that it will decrease stability, which then has to be dealt with before closure. In some cases, such as those with disruption of the ventral components of the three-column system, removal of the laminae will render the spine dangerously unstable with a risk of intra-operative collapse. Hemilaminectomy must be preferred if feasible as it is less likely to destabilize the spine. Some doubt has been cast on the benefits of laminectomy because in some series of cases the results with and without laminectomy are no different, although recent work in humans has suggested that removal of bone fragments in lumbar fractures is associated with significantly improved results. However, the benefits of removal of small bone chips from the vertebral canal have also been doubted in human surgery as studies have suggested that these chips can be moved away from the cord by its innate pulsations and then reabsorbed. When dealing with humans, the problems can be circumvented by the use of CT or MRI imaging which clearly define the need for laminectomy for removal of blood clots or bone fragments. With increasing access to these facilities it should be possible for veterinary surgeons to limit the use of laminectomy to those cases exhibiting clearly defined indications.

Reduction methods

Usually the easiest way to reduce a spinal fracture is to manipulate the bones by means of grasping the spinous processes with towel forceps or small fragment bone forceps. Sometimes grasping the vertebral bodies is possible. Following long-term disruption of the vertebral column it can be helpful to use a distractor which allows the bones to be manipulated into place more easily. The distractor pins are placed through vertebrae at a convenient distance away from the injury site; they can be placed through the vertebral bodies or the spinous processes (Figure 8.3). An assistant is often essential in order to help reduce many of these fractures and luxations and to hold the bones in the correct alignment while fixation is applied, alternatively, the distractor can be used for the same purpose. Some fractures seem to have inherent stability when they are reduced but care must be taken not to allow gross uncontrolled displacement of fragments during reduction and fixation (Figure 8.3).

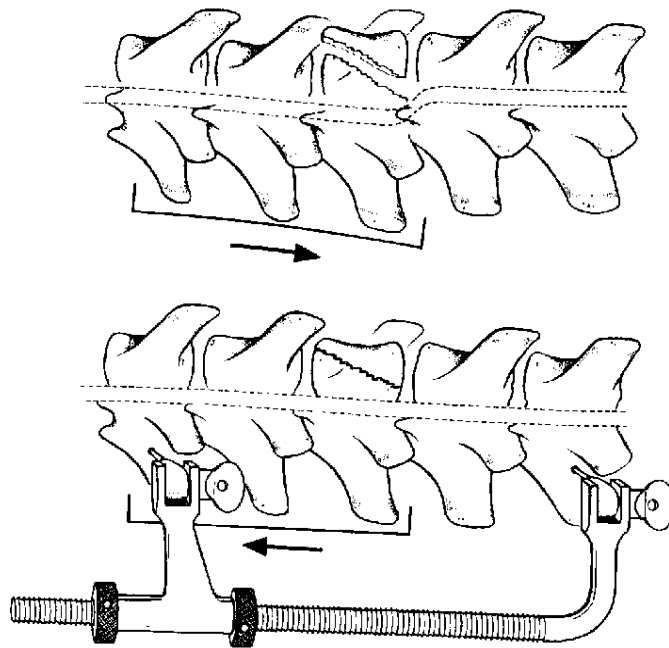


Figure 8.3 Distractor pins placed in spinous processes maintain bone positions facilitating application of fixation technique.

Methods of surgical fixation of spinal fracture/dislocations

Many of the surgical techniques demand detailed knowledge of the anatomy of the vertebral column to ensure proper positioning of the implants. This is usually best provided by having access to anatomical specimens, before and during the procedure, as well as sight of the radiographs during the operation. An important point to remember in the treatment of spinal luxations and fractures is that accurate anatomical alignment is not a vital prerequisite to return of full function. The neural tissue is the important structure to be treated in the vertebral column and although accurate reduction is likely to provide the optimum environment for recovery of the spinal cord it is not usually absolutely essential. This is particularly the case in the cervical and caudal lumbar regions as there is relatively more room for the spinal cord and associated nerve roots.

However, although rigidity is not absolutely necessary, formation of a pseudoarthrosis following failed vertebral fusion is associated with pain in human patients and therefore should be avoided. Rigid stabilization is usually necessary to prevent repeated trauma to the neural tissue but often a limited amount of movement will not hinder neurological recovery.

A large number of different surgical techniques have been used in the treatment of the traumatized spine, many of which can be successful in many cases. There can be difficulties in deciding which technique to use for each individual patient.

Selection of a technique should be based on its effectiveness in overcoming the forces that created the fracture/luxation, thereby ensuring support during repair. Personal preference or past experience can also guide the choice of fixation; many of the available techniques can adequately neutralize all the forces acting on a fracture/luxation.

Vertebral body plating

This technique entails attaching a bone plate to the lateral aspect of the relevant vertebral bodies; it produces a very rigid fixation, if it can be applied properly (Figure 8.4). Problems arise because of the extensive dissection required to expose the lateral aspect of the vertebral body and the difficulties in applying the plate to the bone. Problems may also be encountered in trying to fix bone screws into the bone of the vertebral body, which is frequently rather weak, with thin cortices and large amounts of cancellous bone. Although it is preferable to be able to apply three screws on each side of the fracture, in many cases there is insufficient length of bone in one vertebral body. Poor screw purchase and insufficient number of screws can cause premature loosening of screws, with consequent loss of stability.

Extensive instrumentation, which may not be available to all veterinarians, is useful for applying bone plates. There is a need for detailed knowledge of the anatomy of the area to allow drilling of the holes in the most advantageous position with the least risk of iatrogenic cord injury.

A further drawback to the use of bone plates for vertebral body fixation is the limitation in the areas to which it can be applied. In general, it is only recommended for use between T3 and L3 as during application to the lateral aspect of the vertebral bodies it is necessary to cut the nerve root exiting at the relevant foramen. The nerve roots between T3 and L3 can be severed with little apparent morbidity. Bone plates can occasionally be applied elsewhere in the vertebral column, such as to the arch of the axis; in human surgery plates are commonly applied to the ventral aspect of the vertebral bodies. In small animal species, the application of plates to the ventral aspect of the vertebrae is complicated by the fact that each screw can only be allowed to penetrate one cortex, whereas in humans both cortices can be

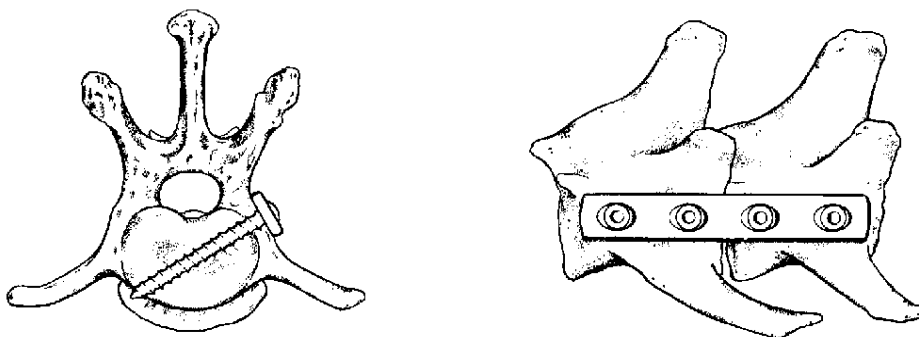


Figure 8.4 Vertebral body plates are applied to the lateral aspect of the vertebral body. Note the direction of screws, which avoids the vertebral canal and nearby blood vessels and optimizes bone purchase.

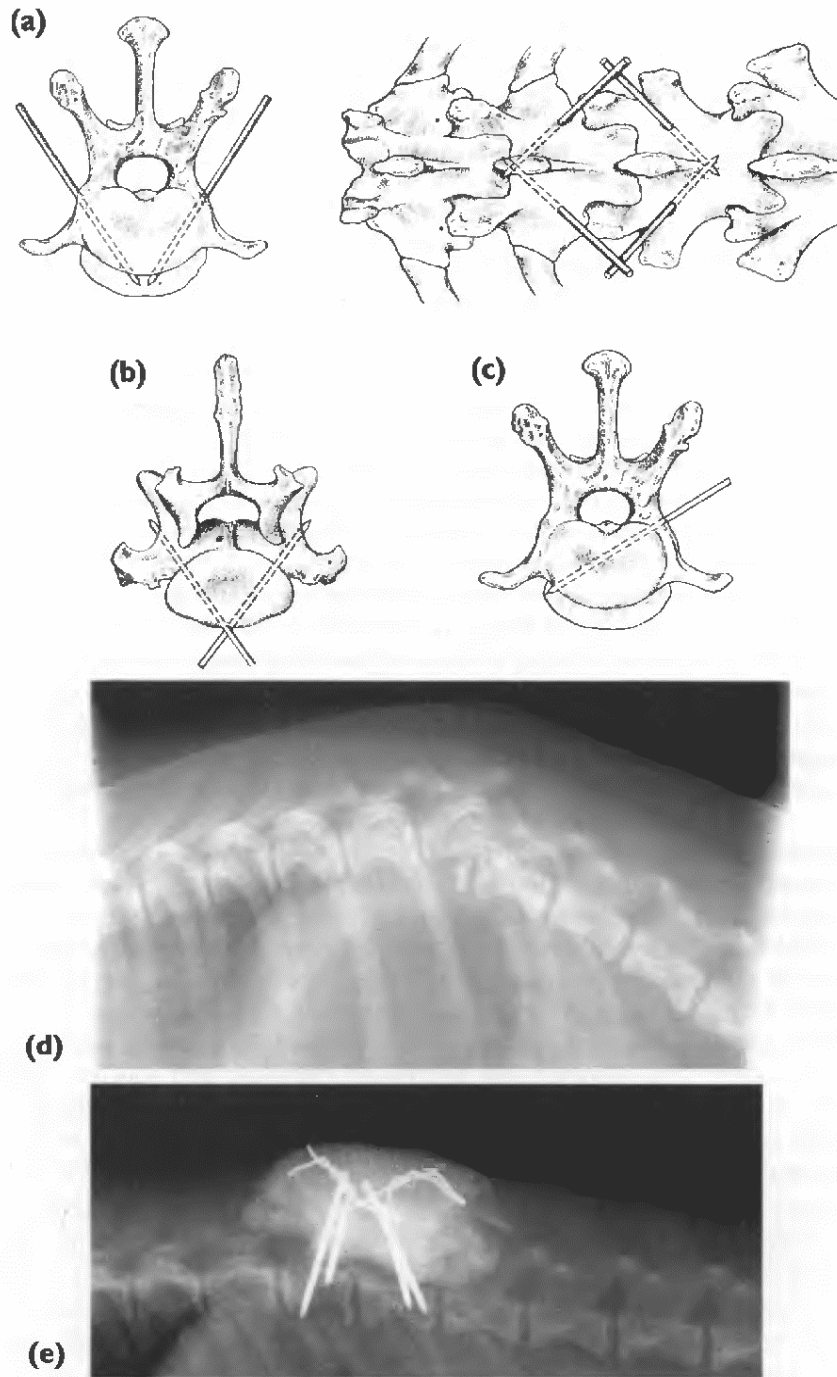


Figure 8.5 (a) Optimal pin placement for pin/PMMA technique in the thoracolumbar region. (b) Optimal pin placement for pin/PMMA technique in the cervical region. (c) Optimal pin placement for unilateral application of pin/PMMA technique in the thoracolumbar region. (d, e) Pre and post operative lateral radiographs of fracture/luxation at T12/13. The wire aids in attachment of PMMA to the pins.

penetrated without inevitably causing neurological injury. With purchase on only one cortex bone screws will usually loosen and the necessity of obtaining purchase on four cortices each side of a fracture becomes difficult without the use of multiple plates. However, some veterinarians have reported the use of ventral plates for treatment of injuries in the cervical and caudal lumbar regions.

Pins and polymethylmethacrylate (PMMA)

This technique is probably now the most widely used in the treatment of small animal spinal fractures. Its popularity stems from the relative ease of application to any area of the vertebral column, minimal dissection required for application and provision of rigid stability. Steinman pins, or Kirschner wires of appropriate diameter are driven through the pedicle of the vertebra and the vertebral body. Pins may be introduced via either ventral (in the cervical region) or dorsal (thoracic, lumbar, sacral regions) approaches. Following reduction of the fracture, the ends of the pins are partially cut, bent and encased in PMMA, which is moulded in a ring shape or applied as a solid mass (see Figure 8.5).

The technique has also been modified by the use of screws instead of pins, which should grip the bone better and the head of the screw will give additional purchase for the PMMA. However, the type of metal used for manufacture of screws has poorer flexibility characteristics, which may encourage premature loosening. The ideal solution is the use of positive-threaded pins (Imex) which combine the advantages of both screws and pins. Partially threaded pins without the positive thread are best avoided as they tend to break at the thread-pin interface (Figure 8.6).

Difficulties encountered in the use of this technique stem from the ability of PMMA to potentiate infection and a large mass of PMMA may necessitate excision of part of the fascia to allow closure. Because of the potential for septic complications PMMA is best avoided in treatment of open fractures and strict aseptic technique is mandatory during its use in other fractures. The use of antibiotic-impregnated PMMA helps to reduce the risk of infection.

Recently, good results have been reported with the use of PMMA and pins when used unilaterally. This allows a less aggressive exposure and shortens operating time. The clinician must decide whether this fixation is sufficiently strong in each individual case on the basis of the size of the animal and the type of fracture/luxation under treatment.

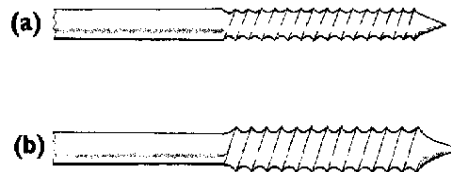


Figure 8.6 (a) Conventional (negative) threaded pin. (b) Positive threaded pin. Note reduction of shaft diameter at the thread-pin interface in the conventional pin.

Spinal stapling

This technique refers to the application of pins and wires to the dorsal components of the vertebrae. Originally, the technique consisted of application of Steinman pins driven through the spinous processes, then bent back on themselves and secured to the neighbouring spinous processes by wires. This technique has subsequently been modified by applying the pins to the region of the facets, with segmental wiring to both rostral and caudal joint facets at each space as well as using spinous process pins (Figure 8.7). The original technique was reported to be of use only in small dogs or cats, but reports on recent modifications would support its use in larger dogs.

The main problem with this technique stems from the time-consuming dissection which is required. In large breeds especially it is necessary to apply the pins to several (4-5) consecutive vertebrae, in order adequately to stabilize one vertebra or intervertebral space. Contouring of the implants can also be problematic, especially in the lumbosacral region. A further drawback is the requirement for many consecutive facets and spinous processes to be intact. Failure due to the wire pulling through the weak bone of the spinous processes is a potential problem but less likely to occur if a sufficient number of vertebrae are incorporated in the fixation.

In theory, the construct is insufficiently stable in torsion. Resistance to torsion by this means of fixation is dependent on adequate width of attachment and security of attachment of the pins and wires to the bone. If the more lateral elements are allowed to ride medially, the consequent reduction in width of the construct will cause instability as torsion is applied.

Cross pins

This technique has been described in many previous texts, however, it can be unstable in torsion, especially if there is damage to the diarthrodial intervertebral joints. It can be deceptively difficult to apply and requires extensive lateral dissection for proper and accurate application. In essence the disrupted area is cross-pinned. Despite its drawbacks it can be useful, particularly in small dogs and cats in which it can be more easily applied (Figure 8.8). Another useful function of this technique can be as a temporary means of reduction before the definitive fixation is applied.

Spinous process fixation

Two techniques have been described using plates and the spinous processes for fixation. In one method, the plate is attached to several consecutive spinous processes by screws driven through the bone itself; in the other method, plastic plates (Lubra plates) are attached by compression applied by screws placed through the plates between the spinous processes. Although these techniques have been reported commonly from the USA, they have been infrequently used in the UK. Both plating techniques suffer from the drawback of requiring a long sequence of unaffected spinous processes in the region of the injury, and the fact that the spinous processes offer rather poor purchase for attachment of fixation devices. Spinous processes may fracture or demineralize under the influence of the forces applied by these techniques.


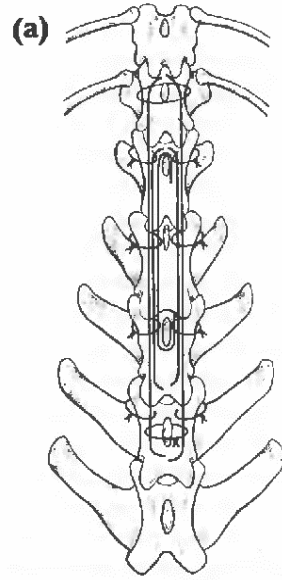
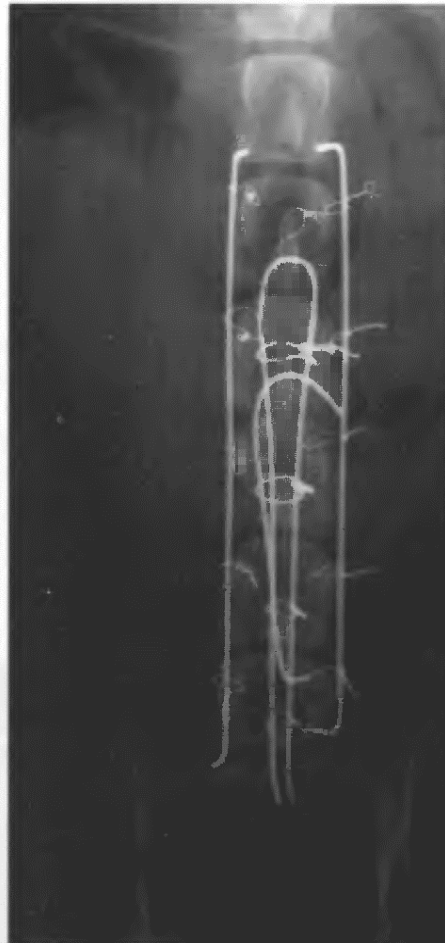



Figure 8.7 (a) Diagram of modified spinal stapling technique. Note the width of the construct which includes attachment of wires to the articular facets. (b-d) Pre- and post-operative radiographs of fracture at L5 treated by spinal stapling technique.

Plastic plates have been used in combination with intramedullary pins for treatment of caudal lumbar fractures.

External fixation

Early experiences with external fixation of spinal fractures in small animals were not very successful but recent work has demonstrated its benefits. An advantage is the possibility of treating open fractures from a distance with minimal interference with the blood supply. Pins for external fixation can be placed through the vertebral bodies, through the spinous processes or through both in order to obtain the necessary purchase. External fixation has also been combined with internal dorsal (spinous process) fixation for treatment of caudal lumbar fracture/luxations.

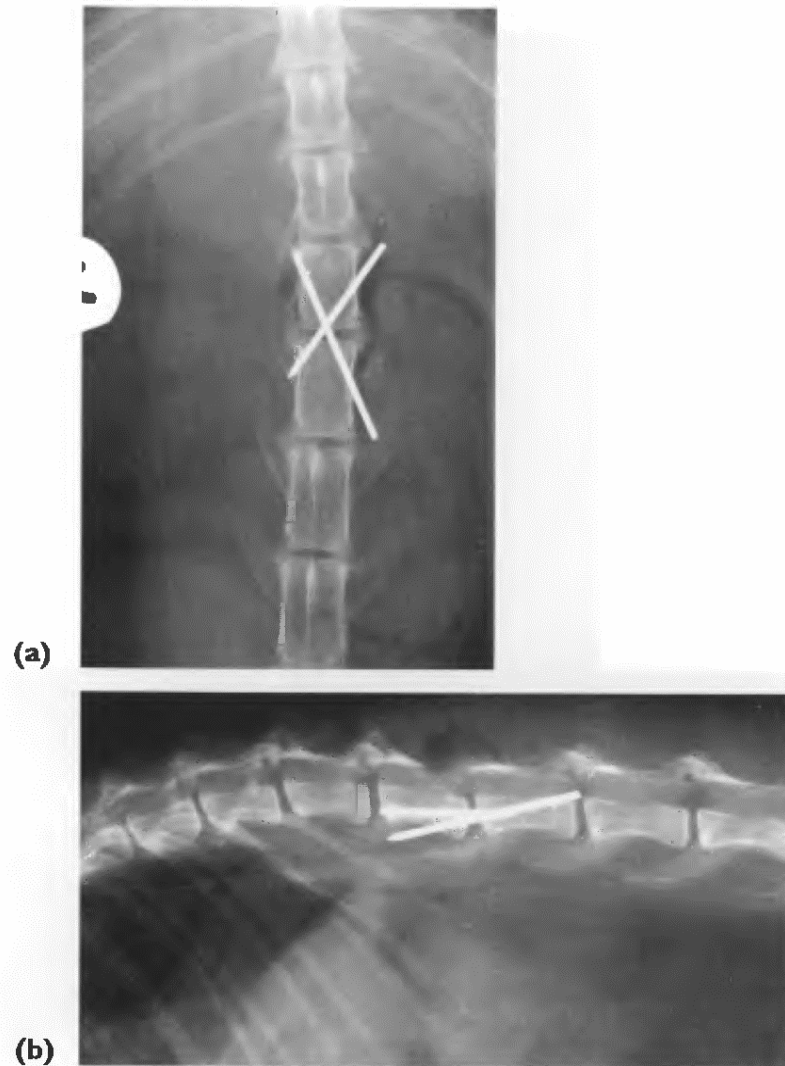


Figure 8.8 (a, b) Lateral and ventrodorsal postoperative radiographs of cat with fracture/luxation at L2/3 treated by cross-pinning (Courtesy of T.G. Yarrow, Citivet, London E1). A dorsal laminectomy has also been carried out.

Potential problems can be related to improper pin placement or to excessive local injury caused by movement between pins and surrounding soft tissues.

Other techniques

Several other methods may be used to stabilize injured areas of the spine with good results. Some of these are applied at very specific areas of the spine and will be covered in more detail in the sections dealing with surgery by site at each location in the spinal cord. Examples are: single pin for L7/sacral fracture, cross-pinning or screws for atlanto-axial subluxation, transarticular screws for cervical luxations.

In some instances the use of more than one technique may be warranted, such as in large dogs or in areas which are inherently difficult to stabilize, for example in the lumbosacral junction.

Complications of surgical treatment

Several possible complications of varying severity are possible following spinal fixation.

RECURRENT INSTABILITY

Instability may recur owing to application of a technique which is insufficiently robust to cope with the normal movements of the patient, resulting in failure of the implant or implant-bone interface. This may be the result of poor choice of fixation technique, insufficient postoperative restraint or poor bone stock. Implant loosening can cause pain due to compression of neural tissue by implant or bone. Distant migration of pins may also occur and cause significant morbidity.

MALUNION/NON-UNION

These complications may or may not be a problem. As mentioned previously, the ability of the spinal cord to function properly is not necessarily dependent on rigid and anatomical bone union. However, excessive callus formation can cause persistent cord or nerve root compression and dysfunction.

IATROGENIC INJURY

This can be the result of induction of instability by the surgical approach itself, the removal of supporting bony elements, or direct damage to neural or vascular structures. The vertebral body techniques are more likely to lead to iatrogenic damage, either because of impingement on the cord or due to penetration of the aorta, which lies adjacent to the ventral aspect of the vertebral bodies in the thoracolumbar region.

Bullets/pellets

It is not uncommon to encounter animals, especially cats, which have sustained spinal injury from a bullet or air-gun pellet. Often the injury is associated with a pellet lodged in a vertebra, usually the pedicle. The neurological status of these animals is variable, ranging from deep pain negative paraplegia to mild paresis and pain. The prognosis is variable, depending on the severity of the original injury. Removal of the pellet, which allows decompression and inspection of the damage, is usually indicated. Although the injury may appear serious at the time of surgery, including disruption of the dura and exposure of the spinal cord parenchyma itself, the prognosis is often surprisingly good. Although infection would be expected to be a potential complication of such injuries, thorough wound hygiene and appropriate use of antibiotics usually prevents its occurrence.

Hyperextension, 'traumatic discs' and cord concussion

Hyperextension injuries

Animals sustaining hyperextension injuries have commonly been involved in falls from a great height or road traffic accidents. Some affected animals will exhibit very severe neurological deficits, but this can be very variable. Pain is not necessarily a feature and would be more likely due to injury to non-neural structures. Hyperextension lesions appear to be most common in the cervical region and bull terrier type dogs may be more commonly affected than others. It seems likely that the large cervical muscle mass protects such breeds from outright fracture/luxation which may be expected in other dogs subjected to trauma of similar magnitude.

Hyperextension injury resulting in cord concussion is assumed to have taken place in animals that have signs of spinal cord injury without radiographic evidence of fracture, luxation or traumatic disc extrusion. Hyperextension injuries are most common in the cervical region, where there is a greater range of normal movement between vertebrae. Cord concussion is caused by hyperextension during which the ligamentum flavum and the dorsal longitudinal ligament will bulge into and occupy a greater proportion of the vertebral canal. This will cause a short period of severe cord compression.

On occasion it may be possible to demonstrate a lesion in one or other of the ligament systems on myelography and sometimes there will be slight subluxation visible at the site as a result of the ligamentous injury. Diagnosis of subluxation may warrant surgical intervention in order to prevent further trauma to the cord. Although myelography can demonstrate the location of the affected area, the extreme swelling of the cord which occurs may render it difficult to obtain diagnostic radiographs, even using the lumbar site of contrast introduction. Intramedullary swelling can be visible on myelography for some days or even weeks following the initial incident (Figure 8.9).

Imaging of similar lesions in the human spinal cord has been achieved by use of MR and often reveals lesions of the dorsal ligaments in the injured area. Correlation of the MR appearance with the ultimate neurological outcome can be made in




Figure 8.9 Myelogram of dog which sustained cord concussion due to RTA. Note poor contrast filling of subarachnoid space at C4/5.




Figure 8.10 Myelogram in dog following traumatic disc extrusion. Note markedly narrowed intervertebral disc space at C4/5 and poor contrast filling of the subarachnoid space, suggesting cord swelling.

human patients; it is to be hoped that with increased access of veterinarians to such facilities that similar correlations can be made in animals.

Traumatic discs

In certain situations animals will be presented with spinal cord injury which has resulted from well-defined external trauma (such as a road traffic accident) but radiographs fail to reveal vertebral fracture or luxation. In some cases there will be narrowing of one of the intervertebral disc spaces in the relevant area of the vertebral column and these cases are assumed to be affected by a 'traumatic disc extrusion'. In these cases, the disc which extrudes is histologically normal but extrudes because of the extreme forces to which it has been subjected. The resulting cord injury is similar to that caused by an acute type I disc extrusion, i.e. concussive.

Cord concussion

For animals in which there has been severe spinal cord injury caused by concussion alone, the only logical surgical treatment would be laminectomy plus pialotomy/myelotomy if deemed appropriate. However, it is difficult to justify invasive surgery of this type in animals with less than complete sensory losses. The treatment of these cases will thus frequently consist of nursing care. Although corticosteroids have long been employed for therapy of spinal cord injury, recent experimental and clinical studies clearly demonstrate that only administration of methylprednisolone within 8 hours of injury is of benefit. Beneficial effects following even this protocol are not great and in many cases the potential deleterious effects of corticosteroid therapy will outweigh the benefits. Many animals that have sustained cord concussion injuries have a good prognosis but frequently require considerable time to make a full recovery, i.e. weeks to months. Animals that have lesions affecting the grey matter of the cervical or lumbar intumescences may be left with profound and permanent lower motor neurone deficits.




Figure 8.11 (a) Immediate and (b) 5 week follow-up radiographs of L5 fracture in a puppy. Despite damage to at least two of the three columns of the spine this case was successfully managed by cage rest (Courtesy of Mrs L. Johnson, Bury St Edmunds, UK).

Conservative management of spinal fracture/luxations

Conservative management of animals with spinal fractures or luxation can be very effective in selected cases. As mentioned previously, the choice between surgery and conservative therapy can be difficult to make. In general, ambulatory animals with injuries which should be stable (i.e. only one column disrupted), can be managed conservatively. Conservative management can take several forms – in some cases simple cage rest is sufficient, alternatively the application of a body cast or other splinting method can be used. Animals which have been treated by external splints or casts may be difficult to handle and urinary incontinence may cause problems with softening of plaster of Paris casts or urine scalding.

A recent paper has described the use of backsplinting in the treatment of a series of dogs suffering from thoracolumbar fracture/luxations (Patterson and Smith 1992). Many of these cases were non-ambulatory at the time of presentation, but recovered to very satisfactory and often normal status within a short period of time. Some biomechanical studies on the splint technique demonstrated that it was able to withstand the bending forces expected in a large-breed dog. Difficulties can arise in applying and attaching the splint to the patient. It is helpful to suspend the patient between two supports; one under the shoulders and one under the pelvis to enable accurate application of splints or casts. Loosening can be avoided by employing a cruciate pattern of application of attaching tapes but complications such as scrotal oedema and urine scalding may still occur. Attentive treatment of such wounds will minimize their importance. The authors of the report suggest that candidates for splinting should have at least one column (of the three spinal columns) intact (so as to prevent further shortening of the spine).

A recent survey of a large number of surgically and conservatively treated animals showed little difference in ability to recover, although the conservatively treated patients were initially less severely injured. Surgically treated animals recovered more quickly and by more neurological grades than did those treated conservatively.

All spinally injured cases benefit from physical therapy to hasten their recovery. Suitable physical therapy varies depending on the nature of the injury, whether surgery was carried out, and the abilities of the animal. Swimming is the most useful activity as the animal's buoyancy allows free movement of the limbs without weightbearing. The effects of flowing water around the patient are also useful to massage the muscles and cleanse the skin. Care must be taken with patients with severe neurological impairment in order to prevent drowning!

Associated reading

- Blass C.E., Seim H.B. (1984) Spinal fixation in dogs using Steinman pins and methylmethacrylate. *Vet. Surg.* **13**, 203.
- Brasmer T.H. (1984) Examination of the trauma patient. In: *The Acutely Traumatized Small Animal Patient*. 1st edn. Philadelphia, W.B. Saunders, p. 45.
- Bruecker K.A., Seim H.B. (1993) Spinal fractures and luxations. In: Slatter D. (ed.) *Textbook of Small Animal Surgery*. 2nd edn. Philadelphia, W.B. Saunders, p. 1110.
- Carberry C.A., Flanders J.A., Dietze A.E., Gilmore D.G., Trotter E.J. (1989) Nonsurgical management of thoracic and lumbar spinal fractures and fracture/luxations in the dog and cat: a review of 17 cases. *J. Am. Anim. Hosp. Assoc.* **25**, 43.
- Denis F. (1983) The three column spine and its significance in the classification of acute thoracolumbar spinal injuries. *Spine* **8**, 817.
- Feeney D.A., Oliver J.E. (1980) Blunt spinal trauma in the dog and cat: insight into radiographic lesions. *J. Am. Anim. Hosp. Assoc.* **16**, 885.
- Gage E.D. (1969) A new method of spinal fixation in the dog. *Vet. Med. SAC.* **64**, 295.
- McAnulty J.F., Lenehan T.M., Maletz L.M. (1986) Modified segmental spinal stabilisation in repair of spinal fractures and luxations in dogs. *Vet. Surg.* **15**, 143.
- McKee W.M. (1990) Spinal trauma in dogs and cats: a review of 51 cases. *Vet Rec.* **126**, 285.
- Matthiesen D.T. (1983) Thoracolumbar spinal fractures/luxations: surgical management. *Comp. Cont. Ed. Pract. Vet.* **5**, 867.
- Patterson R.H., Smith G.K. (1992) Backsplinting for treatment of thoracic and lumbar fracture/luxation in the dog: principles of application and cases series. *VCOT* **5**, 179.
- Selcer R.R., Bubb W.J., Walker T.L. (1991) Management of vertebral column fractures in dogs and cats: 211 cases (1977-1985). *J. Am. Vet. Med. Assoc.* **198**, 1965.
- Shores A. (1992) Fractures and luxations of the vertebral column. *Vet. Clin. N. Am.* **22**, 171.
- Swaim S.F. (1971) Vertebral body plating for spinal immobilisation. *J. Am. Vet. Med. Assoc.* **158**, 1683.
- Thacher C. (1993) Biomechanics of cranial fractures, spinal fractures, and luxations. In: Bojrab M.J. (ed.) *Disease Mechanisms in Small Animal Surgery*, 2nd edn. Philadelphia, Lea and Febiger, p. 999.
- Turner W.D. (1987) Fractures and fracture-luxations of the lumbar spine: a retrospective study in the dog. *J. Am. Anim. Hosp. Assoc.* **23**, 459.
- Wong W.T., Emms S.G. (1992) Use of pins and methylmethacrylate in stabilisation of fractures and luxations. *J. Small Anim. Pract.* **33**, 415.
- Yturrapse D.J., Lumb W.V. (1972) The use of plastic spinal plates for internal fixation of the canine spine. *J. Am. Vet. Med. Assoc.* **161**, 1651.

CHAPTER 9

Tumours

Contents

<i>Introduction</i>	128
<i>Classification by location</i>	129
<i>Modes of therapy</i>	136
<i>Associated reading</i>	136

Introduction

Tumours of the spinal cord and vertebral column may be classified in many ways, including cell of origin and biological behaviour. However, from a clinical viewpoint, the most useful initial classification is the precise anatomical relationship of the tumour to the spinal cord parenchyma. This relationship is apparent on myelographic, CT or MR studies of the spine. The histological classification of a tumour is important but usually cannot be ascertained before surgical exploration and biopsy and so will not usually determine the initial steps in therapy. Amenable of spinal tumours to surgical therapy is variable and depends on the histological type and stage of the disease. In many cases, surgery is primarily exploratory, to determine whether effective treatment is humanely possible, or as a means of obtaining biopsy material. In other cases, surgery may be curative.

CSF analysis in animals which have spinal tumours is usually unrewarding. Only very rarely will cell counts be elevated and help to make a specific diagnosis; it is unusual to find neoplastic cells in the CSF. In dogs, CSF analysis will not usually suggest tumour type, although nonspecific abnormalities such as increased protein content may be detected – a finding which is common in any case of spinal cord compression. The condition of reticulosis, which can be classified as a neoplasm, can be associated with increases in cell counts. In cats, lymphosarcoma (LSA) is a frequent cause of spinal cord dysfunction and, if there is invasion of the meninges, examination of a CSF sample may be expected to yield diagnostic information. However, even in cats affected by lymphosarcoma, CSF samples often are negative. Blood samples for feline leukaemia virus (FeLV) testing taken from cats in which LSA is suspected may be of value. In one study about 85% of affected cats were positive for FeLV. Bone marrow samples may also be indicated for cats in which generalized LSA is suspected.

Classification by location

Extradural (epidural)

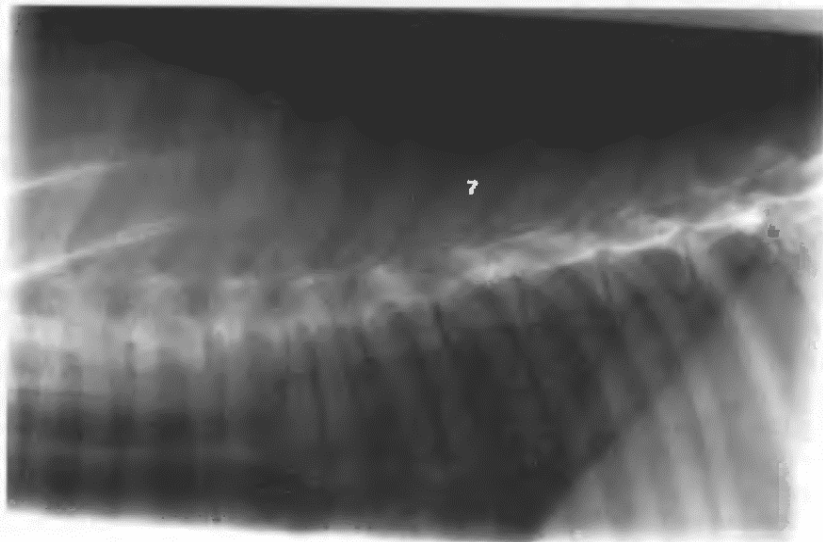
Extradural tumours arise from the various connective tissue elements, which are located in the extradural space, or from vertebral bone. Some tumours which may arise as multifocal lesions, such as lymphosarcoma or metastatic deposits, can also appear at this site. In most series of cases extradural tumours are the most commonly encountered in small animals. The exact proportion of tumours at different locations is probably difficult to ascertain with any degree of accuracy. The nature of the reporting institution will influence the type of cases which are presented most frequently; those institutions dealing predominantly with surgical spinal disease will probably diagnose a greater proportion of extradural tumours owing to their frequent similar presentation to extruded discs.

Symptoms result from compression of the spinal cord as the tumour increases in size, and are often chronic. However, some extradural tumours will lead to pathological fracture of a vertebra, or acute interruption of blood supply to the spinal cord, and therefore can cause acute onset of clinical signs. Extradural tumours will appear on myelography as areas of external compression on the contrast columns (Figure 9.1).

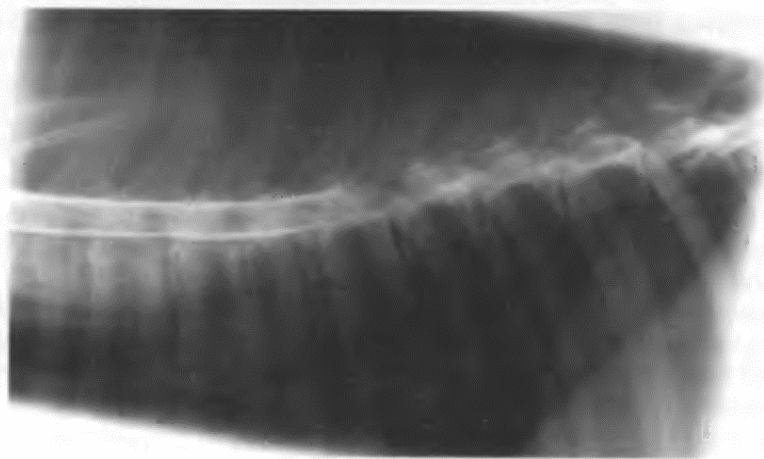
Patients which have extradural tumours may be presented with a variety of symptoms, ranging from peracute total loss of motor and sensory function, to an insidious, progressive loss of function with or without apparent pain. In general, extradural tumours are accompanied by pain as the meninges are distorted and the nerve roots are stretched; however, it may be difficult to demonstrate pain unequivocally in every patient. Signs are usually insidious and progressive.

Tumours of the vertebrae usually cause signs of pain initially but most progress and cause neurological deficits within about 6 weeks of onset of symptoms. Both primary and secondary tumour types have been recognized. In one study 13 of 35 were secondary to intrapelvic tumours; however, osteosarcoma is generally recognized to be the most frequently occurring vertebral tumour type in dogs. Any breed of dog can be affected by vertebral neoplasia, although there is some evidence that German shepherd dogs and retrievers may be over-represented.


The presence of an extradural spinal tumour may sometimes be suspected from a plain radiograph because destruction, or proliferation, of the vertebral bone is a common finding in many of these cases. However, some cases present with equivocal or no evidence of bone changes rendering myelography essential to locate the lesion. With hindsight, following myelography, abnormalities on plain radiographs may be observed. Myelography is able to locate the lesion and can often strongly suggest the presence of a spinal tumour. The main differential diagnosis for an extradural compressive lesion on a myelogram is extruded disc material. The precise location of the lesion in relation to neighbouring structures can be helpful in differentiating the two possibilities. In general, extruded discs will overlie a disc space, appearing just dorsal to the anulus fibrosus, while a tumour may appear at any location and is frequently more lateralized than a disc extrusion. Tumours of the intervertebral disc itself have not been recorded in the dog or cat. However, some care must be taken in interpreting myelographic information, as extruded disc material may find its way to surprising locations, including appearing dorsal



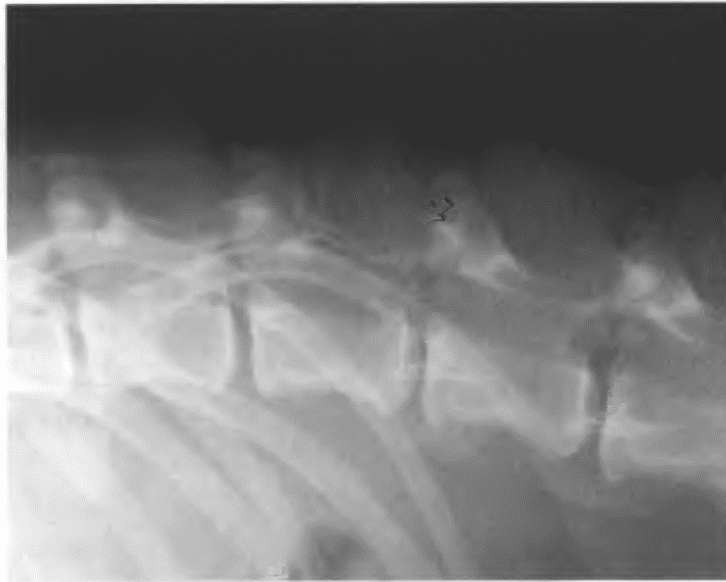(a)



(b)



(c)



(d)

Figure 9.1 (a) Extradural tumour (osteosarcoma) affecting spinous process of T7 vertebra; note 'moth-eaten' appearance typical of malignant extradural tumours. (b) Myelogram of same lesion; note typical deviation of dorsal contrast column. (c) Myelogram of cat with extradural meningioma at T4. (d) Lytic lesions (arrowed) within spinous process and articular facet of L1 in dog affected with multiple myeloma.

to the dural tube in some cases. This finding appears to be more frequent in larger breed dogs, perhaps owing to the relatively larger epidural space in these breeds (Figure 9.2). The location of the extradural mass within the vertebral column may also give some clues as to its nature. Extruded discs are most frequently found in certain regions of the vertebral column and the finding of an extradural mass in the mid-thoracic region should prompt the suspicion that the lesion is likely to be a tumour.

The definitive diagnosis of the nature of an epidural lesion relies on examination of biopsy material and retrieval of appropriate specimens must be obtained before definitive pronouncements are made on prognosis. Biopsy material is usually obtained via laminectomy but two recent reports have described the use of fluoroscopically guided percutaneous fine needle aspirates for the same purpose.

It is frequently apparent during exploratory surgery that total removal of an extradural tumour is impossible without serious compromise of the integrity of the vertebral column. Several possibilities exist at this point: immediate euthanasia, debulking surgery to decompress the cord followed by the use of other anticancer modalities such as radiotherapy and chemotherapy, or aggressive total resection followed by reconstructive surgery. In veterinary patients, either euthanasia or debulking procedures are currently most frequently carried out.

Extradural tumours in small animals are commonly malignant types which often have a high propensity to metastasize. Following the tentative diagnosis of an extradural tumour it is essential to obtain thoracic radiographs and perhaps other

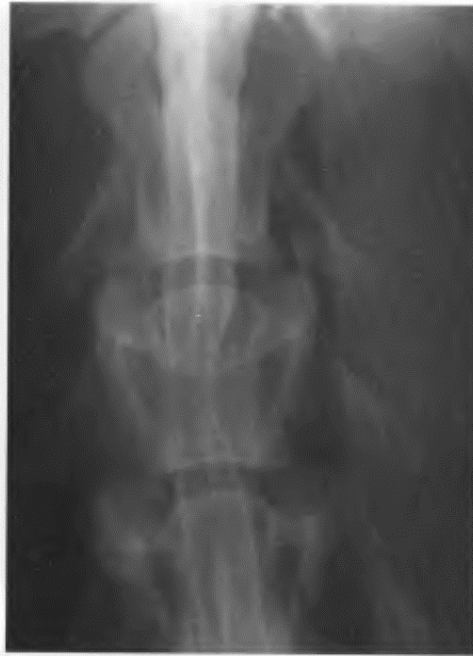

Figure 9.2 Benign extradural lesion (haematoma) within vertebral canal of C3. Exploratory surgery is required to determine nature of such a myelographically defined lesion.

studies to search for metastatic deposits. The finding of typical metastatic lesions in the lungs helps to make the diagnosis and can guide the clinician when considering the possibilities for further treatment of such individuals. Frequently diagnosed extradural tumour types include osteosarcoma, fibrosarcoma, lymphosarcoma. Osteosarcoma is associated with a poor prognosis in any case, although reasonable survival times can be achieved in selected cases by use of postoperative chemotherapy (cisplatin). Treatment of lymphosarcoma with routine triple chemotherapy (vincristine, cyclophosphamide and prednisolone) can be successful in maintaining a satisfactory remission time for some patients. However, LSA in some animals can cause a sudden loss of blood supply to the spinal cord which causes extensive necrosis, thus preventing recovery despite adequate anticancer treatment. Occasionally, extradural masses can be benign, such as some meningiomas in cats (although these are traditionally thought of as intradural/extramedullary tumours), implying that surgical extirpation can be curative.

In cats, LSA is the most common cause of nontraumatic myelopathy. LSA appears to be predominantly a disease of young cats, and even cats as young as 7 months have sometimes been found to be affected. FeLV infection is common in affected animals: tests in 16/19 cats of one series were positive. Treatment by chemotherapy is most effective and can produce very worthwhile remission times. The diagnosis, which is best accomplished by means of fine needle aspirate, must first be established. The surgical debulking of such lesions is probably of little benefit, because the tumour will shrink dramatically in size with drug therapy alone; however, in one study the one cat treated by both surgery and chemotherapy had the longest survival time.

Multiple myeloma can involve any organ or tissue but the vertebral column is often involved because of the tumour's origin in bone marrow. One-third of dogs which have multiple myeloma have spinal involvement. Small areas of punctate lysis of the vertebral bone are observed on radiographs. Bone pain may be demonstrable and compression of the spinal cord because of pathological fractures or soft tissue masses can also occur. Examination of urine and serum for abnormal proteins is the diagnostic test of choice. Treatment of multiple myeloma is by means of alkylating drugs such as melphelan or cyclophosphamide plus corticosteroids and can achieve long survival times.

Multiple cartilaginous exostosis (also known as osteochondromatosis) can also cause extradural spinal cord compression and is discussed in Chapter 6. Surgical resection is the treatment of choice. In cats the multifocal form of the disease is truly neoplastic; the efficacy of surgical treatment is limited by the tendency of the lesion to recur and its association with viral infection.

Intradural/extramedullary tumours

This group of tumours is found within the subarachnoid space and so they appear as 'islands' within the contrast columns (Figure 9.3). The appearance of the contrast columns is often likened to a golf tee because of their typical pattern of attenuation of the contrast columns in their vicinity. Lesions other than tumours are unlikely to

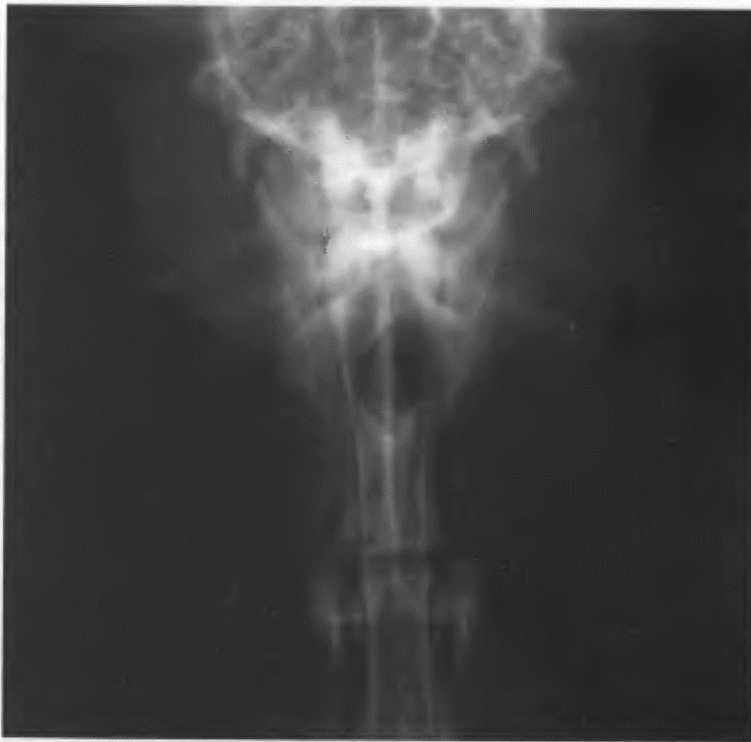

Figure 9.3 Typical myelographic appearance of intradural/extramedullary lesion (this lesion was a meningioma). Note 'island' effect.

appear in this relationship with the spinal cord, although haemorrhage or clotted blood could conceivably look similar. Confusion can arise when intramedullary tumour types cannot clearly be defined to be intramedullary as opposed to intradural/extramedullary. The intradural/extramedullary group of tumours is the most uncommon, representing about 15% in most series. There are only a limited number of tumour types represented in this group, and these are almost exclusively meningiomas and nerve sheath tumours. They are generally slow growing and so animals with these tumours will usually exhibit an insidious onset of neurological signs, frequently over a period of several months. Overt pain is an infrequent finding, especially in the early stages of tumour growth. Occasionally, the presence of these tumours may be inferred from plain radiographs of the affected area; for example enlargement of the intervertebral foramen can be associated with a nerve root tumour. Myelography is required in almost every case to define the site of intradural/extramedullary tumours.

Extramedullary/intradural tumours are often benign or not aggressively malignant, rendering surgical intervention an attractive option in their treatment. Meningiomas, especially in cats, can often be lifted away from the surrounding tissues and very long remission times can be expected in a large proportion of surgically treated cases. Some meningiomas may be rather inaccessible for complete removal, especially when they are located ventral to the spinal cord, debulking surgery followed by radiation is an alternative option in these cases.

Meningiomas in dogs were found more frequently in the cervical region in a series of 13 cases reported by Fingerioth *et al.* (1987), a finding which has also been reported by others. Surgical treatment resulted in improvement of 6 out of 9 cases. Poor results were associated with location of the lesion at an intumescence, ventral position in the cord, invasion of neural tissue and iatrogenic trauma. CSF analysis (elevated protein) was abnormal in only one case.

An unusual intradural/extramedullary tumour has been reported in young large-breed dogs. Features include the predilection for the area T10 to L2; 11 out of 12 dogs in one report were from 6 to 38 months old at presentation. Early surgical removal of these tumours may be beneficial and no metastasis has been observed to occur in any case. Many different names have been applied to these tumours, including medulloepitheliomas, neuroepitheliomas – the cell of origin is unknown and may be non-neural. It has been suggested that the tumour may be a nephroblastoma and result from the incorporation of primordial kidney elements into the intradural space.

Intramedullary tumours

This group of tumours is thought to occur with about the same or slightly greater frequency as the intradural/extramedullary types. Animals bearing these tumours typically present with a fairly rapidly progressive loss of sensory and motor function, often over a period of 1 to 2 months. They do not usually exhibit pain. The appearance of these tumours on myelography is attenuation of the contrast columns in both lateral and ventrodorsal views, i.e. the cord looks swollen. The most important differential diagnosis for this appearance is that of cord oedema or haemorrhage (often secondary to acute cord trauma) (Figure 9.4). The history of the individual case should help to determine which is the more likely cause. The types

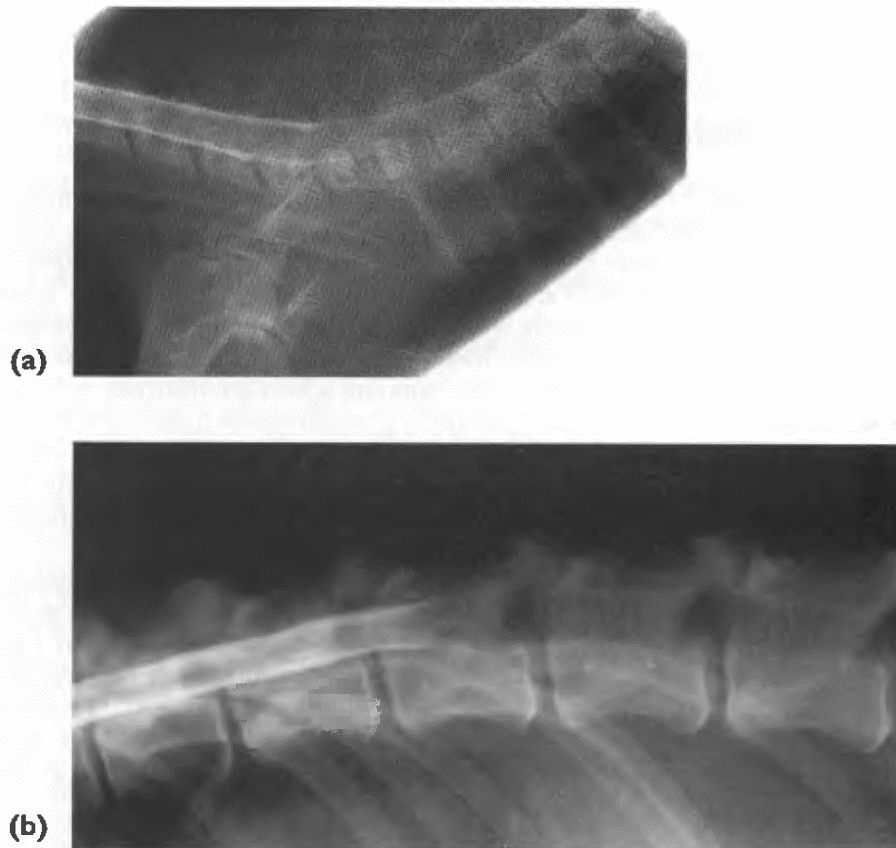


Figure 9.4 (a) Myelographic appearance of intramedullary tumour (astrocytoma) at cervicothoracic junction in a cat; apparent cord swelling at this site is difficult to differentiate from the normal swelling at the cervical intumescence. (b) Myelographic appearance of intramedullary tumour (astrocytoma) at T13 in a dog; note 'flaring' of contrast columns.

of tumour found within the spinal cord are quite limited, being most commonly astrocytomas or ependymomas, but metastatic lesions (including lymphosarcoma) may also occur.

Definitive diagnosis requires examination of histological specimens but the suspicion of a tumour is often very strong beforehand. Fluoroscopically guided biopsy is a desirable method of diagnosis as the prognosis for these tumours may be determined mainly by their histological type. In human patients intramedullary tumours are often removed surgically with subsequent radiotherapy or chemotherapy given for cases in which removal is incomplete. Intramedullary tumours are usually benign types which means that adequate (i.e. total) surgical excision should be curative. The difficulty is to ensure that there is an adequate margin of excision, without undue iatrogenic damage to the surrounding normal cord. Specialized microsurgical instruments are desirable for such surgery, although these tumours can be removed using standard ophthalmological instrumentation. Radiotherapy of ependymomas can be associated with a good prognosis in human

patients; however, this type of therapy is rarely employed for these types of tumour in veterinary cases.

Modes of therapy

As is the case with other tumours, there are three main modes of treatment for spinal tumours: radiotherapy, chemotherapy and surgery. In general, surgical treatment is the most likely to result in cure of a solitary tumour with low metastatic potential. Radiotherapy is another means of controlling local disease, whereas chemotherapy is the only modality with effect against distant spread of malignant tumours. All of these modalities have their place in the actual or potential treatment of spinal tumours in animal species. For tumours which are relatively nonaggressive, surgery is the prime means of therapy, e.g. meningioma in cats. Often surgery is essential only to provide diagnostic material, e.g. ependymoma, which in humans may be treated as effectively by radiation alone as by surgery plus radiotherapy. Unfortunately, a large proportion of spinal tumours are malignant and require systemic treatment with chemotherapeutic agents.

There appears to be much room for improvement in the veterinary treatment of spinal tumours, following the example of surgeons operating on human patients. For instance, much more radical surgical resection and reconstruction can be carried out, using bone cement and bone grafts to stabilize the resultant defects with relative ease. The cervical region of the spine seems to lend itself most easily to this type of aggressive surgical management. At present the prognosis for animals with extradural or intramedullary tumours is at best guarded and at worst hopeless.

Associated reading

- Bell F.W., Feeney D.A., O'Brien T.J., Caywood D.D., Hultgren B.D. (1992) External beam radiation therapy for recurrent intraspinal meningioma in a dog. *J. Am. Anim. Hosp. Assoc.* **28**, 318.
- Fingerroth J.M., Prata R.G., Patnaik A.K. (1987) Spinal meningiomas in dogs: 13 cases (1972–1987). *J. Am. Vet. Med. Assoc.* **191**, 720.
- Gilmore D.R. (1983) Neoplasia of the cervical spinal cord and vertebrae in the dog. *J. Am. Anim. Hosp. Assoc.* **19**, 1009.
- Hammer A.S., Couto C.G. (1994) Complications of multiple myeloma. *J. Am. Anim. Hosp. Assoc.* **30**, 9.
- Harris C.W., Didier P.J., Parker A.J. (1988) Simultaneous central nervous system reticulosis in two related Afghan hounds. *Comp. Cont. Ed. Pract. Vet.* **10**, 304.
- Heyman S.J., Diefenderfer D.L., Goldschmidt M.H., Newton C.D. (1992) Canine axial osteosarcoma. A retrospective study of 116 cases (1986–1989). *Vet. Surg.* **21**, 304.
- Irving G., McMillan M.C. (1990) Fluoroscopically guided percutaneous fine needle aspiration biopsy of thoracolumbar spinal lesions in cats. *Prog. Vet. Neurol.* **1**, 473.

- Jeffery N.D. (1991) Treatment of epidural haemangiosarcoma in a dog. *J. Small Anim. Pract.* **32**, 359.
- Luttgen P.J. (1992) Neoplasms of the spine. *Vet. Clin. N. Am.* **22**, 973.
- Luttgen P.J., Braund K.G., Brawner W.R., Vandeveld M. (1980) A retrospective study of twenty-nine spinal tumours in the dog and cat. *J. Small Anim. Pract.* **21**, 213.
- Morgan J.P., Ackerman N., Bailey C.S., Pool R.R. (1980) Vertebral tumours in the dog: a clinical, radiologic and pathologic study of 61 primary and secondary lesions. *Vet. Rad.* **21**, 197.
- Neer T.M., Kreeger J.M. (1987) Cervical spinal cord astrocytoma in a dog. *J. Am. Vet. Med. Assoc.* **191**, 84.
- Prata R.G. (1977) Diagnosis of spinal cord tumours in the dog. *Vet. Clin. N. Am.* **7**, 165.
- Spodnick G.J., Berg J., Moore F.M., Cotter S.M. (1992) Spinal lymphoma in cats: 21 cases (1976-1989). *J. Am. Vet. Med. Assoc.* **200**, 373.
- Summers B.A., deLahunta A., McEntee M., Kuhajda F.P. (1988) A novel intradural extramedullary spinal cord tumour in young dogs. *Acta Neuropath. (Berl.)* **75**, 402.
- Turrel J.M., Pool R.R. (1982) Primary bone tumours in the cat: a retrospective study of 15 cats and a literature review. *Vet. Rad.* **23**, 152.
- Walker T.L. (1993) Spinal neoplasia. In: *Disease Mechanisms in Small Animal Surgery*, Bojrab M.J. (ed.), 2nd edn. Philadelphia, Lea and Febiger, p. 975.
- Waters D.J., Hayden D.W. (1990) Intramedullary spinal cord metastasis in the dog. *J. Vet. Int. Med.* **4**, 207.
- Wen B-C., Hussey D.H., Hitchon P.W. et al. (1991) The role of radiation therapy in the management of ependymomas of the spinal cord. *Int. J. Rad. Onc. Biol. Phys.* **20**, 781.
- Wheeler S.J. (1989) Spinal tumours in cats. *Vet Ann.* **29**, 270.
- Wright J.A. (1985) The pathological features associated with spinal tumours in 29 dogs. *J. Comp. Path.* **95**, 549.
- Wright J.A., Bell D.A., Clayton-Jones D.G. (1979) The clinical and radiological features associated with spinal tumours in thirty dogs. *J. Small Anim. Pract.* **20**, 461.
- Yoshioka M.M. (1987) Meningioma of the spinal cord in a cat. *Comp. Cont. Ed. Pract. Vet.* **9**, 34.

CHAPTER 10

Inflammatory, Infectious and Vascular Diseases

Contents

<i>Introduction</i>	138
<i>Vascular disease</i>	138
<i>Inflammatory and infectious disease</i>	140
<i>Associated reading</i>	145

Introduction

There are a number of diseases of the vertebral column and spinal cord caused by inflammatory, infectious or vascular aetiologies; they are not amenable to surgical therapy but form important differential diagnoses for the various surgical conditions.

Vascular disease

Fibrocartilagenous embolization (FCE)

Spinal cord infarction secondary to fibrocartilagenous embolization has been reported more frequently in dogs than in any other domestic animal. The typical clinical sign exhibited by affected dogs is peracute onset of nonprogressive neurological dysfunction usually with distinct lateralization. Occasional cases have been reported in which the clinical signs progressed over 48–72 h. Cervical embolization will often cause hemiparesis; thoracolumbar involvement will often cause monoparesis. Initially, many dogs appear to suffer some pain but this is usually short lived (i.e. less than 1 h) and is rarely appreciated by the attending veterinarian. The owners of affected dogs will commonly state that the dog cried at the time of onset of the paralysis. After the first 24 h or so, there is frequently minimal involvement of the contralateral limb or limbs. There is a tendency for the condition to affect the cervical and lumbar intumescences, with selective and severe involvement of the grey matter. Large or giant breeds of dog are apparently predisposed to develop FCE. However, the exact incidence of the condition is difficult to establish because definitive diagnosis is dependent on histological examination of the spinal cord.

Plain radiography reveals no abnormality and myelography will also be unrewarding in most cases. Some authors report a slight swelling of the spinal cord at the site of the lesion within the first 24 h or so following onset of clinical signs.

The usual conditions from which differential diagnosis must be made are acute

disc extrusion or neoplasia. Two features in the history which may assist in differentiation are the clear lateralization of clinical signs in FCE and the selective involvement of certain areas of the spinal cord in disc extrusions. Neoplasia can be provisionally ruled out if there is spontaneous and sustained improvement.

Recovery of much of the lost function does occur in many dogs given sufficient time, i.e. several weeks to months. However, the ischaemic nature of the lesion implies loss of some neurones, which is irreversible, therefore, embolization of grey matter which supplies a limb will cause more permanent neurological deficits. Neurological improvement is therefore dependent on resolution of secondary effects such as haemorrhage and oedema and functional compensation. At post mortem examination of affected dogs there is an area of necrosis, the region depending on which vessel becomes occluded. In well-defined cases small fragments of cartilaginous material have been found in the occluded vessels (Figure 10.1). Both arteries and veins have been found to be affected.

It is interesting to speculate how the material manages to gain access to the vasculature of the cord. The most generally accepted view is that, following degeneration of the nucleus of the disc, a rise in intradiscal pressure associated with vigorous activity can allow material to gain access to the venous sinuses and from there to the leptomeningeal vessels. Embolization of the arterial supply or venous drainage has also been suggested to be the result of disc extrusion into the vertebral body (this is termed Schmorl's node in humans), which is able to penetrate into the arteries in the cancellous bone. Further consideration of mechanics of FCE has been described by Penwick (1989). Unfortunately, many of the explanations of the mechanism remain somewhat unconvincing and unproven. For instance, most dogs affected by FCE are of those breeds in which acute disc extrusions are rarely observed and most affected animals do not show demonstrable signs of disc degeneration when examined post mortem.

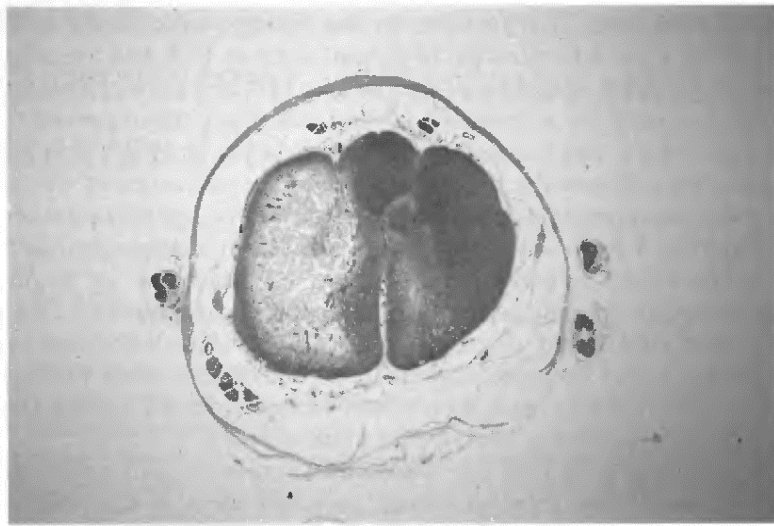Attempted treatment of FCE is medical only. Usually corticosteroids are given in order to minimize the effects of oedema and vascular disruption. The mechanism of ischaemic injury to the spinal cord is similar to that occurring in acute concussive injury; therefore, the same rules governing corticosteroid therapy elsewhere in the spine apply to this condition, i.e. methylprednisolone should be administered within 8 h of occurrence of injury.

Idiopathic spinal cord haemorrhage

This condition is reported rarely. It can be associated with disorders of haemostasis or can occur as a spontaneous disease. Definitive diagnosis cannot be made without histological examination of biopsy or necropsy material. Suspicion of this condition in the live animal may occur in cases in which there is an acute onset of severe neurological impairment which then improves spontaneously. Support for the diagnosis can be obtained by determination of blood coagulation parameters. Should these be abnormal, a search for a likely cause should be instituted.

Occasional cases may be seen in which there is apparent spontaneous haemorrhage into the extradural space. Surgical exploration is required in such cases in order to eliminate the possibility of such lesions being tumours.

(a)



(b)

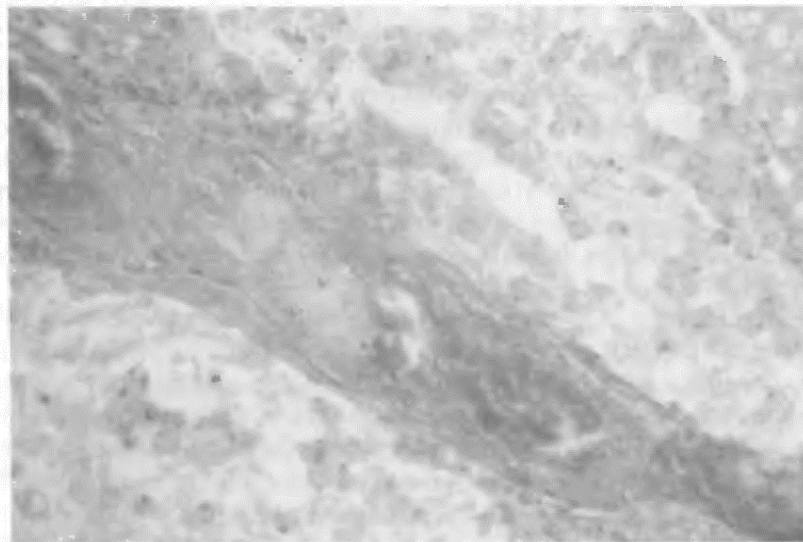


Figure 10.1 (a) Pathological specimen of dog which sustained fibrocartilaginous embolization; note discoloured infarcted area. (b) High-power view showing cartilaginous material in blood vessel. (Courtesy of Dr A.C. Palmer, Cambridge University Veterinary School, UK).

Inflammatory and infectious disease

Discospondylitis/spondylitis

Discospondylitis refers to infection (usually bacterial) of the intervertebral disc and the neighbouring vertebral endplates; spondylitis refers to osteomyelitis of the vertebrae alone. The typical clinical sign is pain (which may be very severe), and in some cases neurological dysfunction will also develop. Neurological signs are usually the result of instability or subluxation of the affected region.

The cause of the condition is usually systemic infection, with haematogenous spread (i.e. bacteraemia) and in many cases is thought to originate from the urinary system. In some cases foreign body migration from the digestive or respiratory tracts allows grass seed awns to find their way to the ventral aspect of L1/L2 region and lodge in the intervertebral discs and cause discospondylitis. In the USA, brucella infection is frequently incriminated in the development of discospondylitis in dogs but this infection has not been diagnosed in the UK.

Discospondylitis most commonly affects young, large-breed dogs and certain areas of the spine are more commonly affected. The most common space affected is the T5/6 disc, followed by L7 and the caudal cervical region. The most common bacterial isolates are staphylococci, most of which are resistant to penicillin.

Diagnosis of discospondylitis can usually be made from plain radiography. There is destruction of the dense bone of the vertebral endplates, with some bone proliferation at the margins of the lesion (Figures 10.2 and 10.3). Radiographically it is possible to confuse spondylosis with discospondylitis; however, in spondylosis there is only bone proliferation, whereas in discospondylitis there is concurrent bone destruction. Diagnosis of the type of bacteria involved is usually not required for initial treatment. Therapy is based on the assumption that there will be a

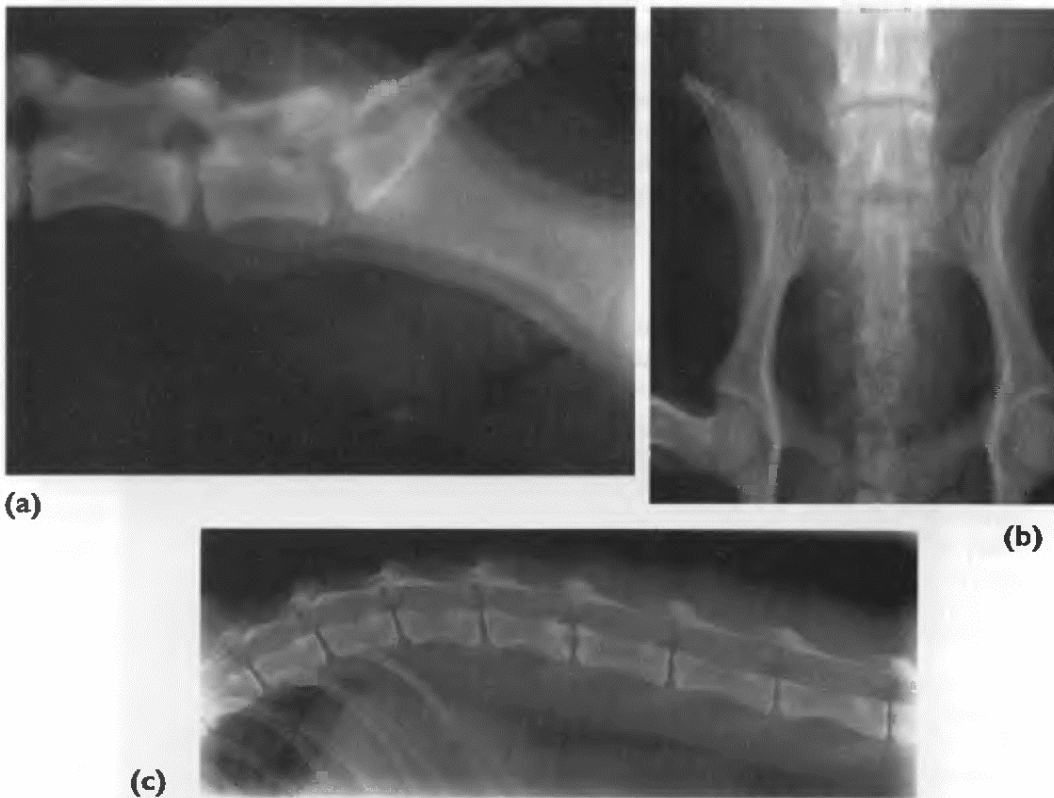

Figure 10.2 (a, b) Radiographs of discospondylitis at lumbosacral junction. Note erosion of cranial endplate of sacrum, apparent widening of disc space and poor definition of caudal endplate of L7 vertebra. (c) Discospondylitis at L2/3 in a cat.

penicillin-resistant staphylococcal infection. Appropriate antibiotic treatment should be given for about 3 months or more in order to eradicate infection. If signs persist or progress, or if there is obvious instability at the affected site, then surgical exploration for the purposes of obtaining a bacteriological diagnosis and stabilization is required.

In rare cases an abscess may form in the epidural space. Associated symptoms are those of pain and transverse myelopathy and may mimic those of a tumour from which they must be differentiated. Exploratory surgery is likely to be required in such cases allowing cord decompression and retrieval of material for microbial culture.

Not all discospondylitis/spondylitis lesions will be caused by bacteria, some are the result of fungal or other (e.g. cryptococcal) infections, but these are uncommon, especially in the UK. Treatment of these infections can be very difficult; very prolonged antibiotic therapy may be required.

Meningitis/myelitis

Meningitis refers to inflammation of the meninges and, although responsible for symptoms of spinal pain, neurological signs are not usually found in the absence of concurrent cord inflammation. Myelitis refers to inflammation of the cord itself and is not usually painful but will cause neurological signs. Both meningitis and myelitis frequently coexist and may be associated with disease elsewhere in the body, especially elsewhere in the nervous system (e.g. encephalitis). A very large number of causal agents for meningitis and myelitis have been identified. Unfortunately, it can sometimes be difficult to reach a definitive diagnosis in every case without examination of necropsy material.

BACTERIAL

Bacterial meningitis is rare in dogs. This sometimes comes as a surprise to owners of dogs, who are often very alarmed if a veterinarian suggests that their dog has

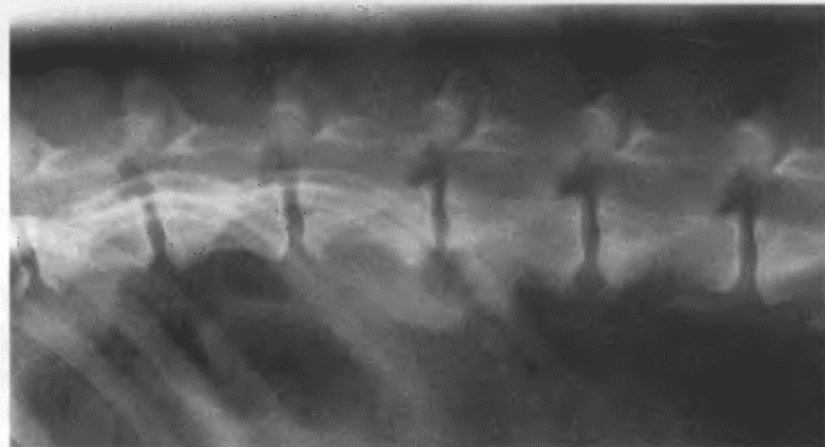


Figure 10.3 Spondylitis at L1/2.

meningitis and they are also frequently worried regarding zoonotic potential. There are no documented cases of transmission of meningitis from dog or cat to humans. In dogs most cases of bacterial meningitis are the result of penetrating injury, or local extension of infection, although some cases may result from haematogenous spread. This can come about as the result of stick injuries to the pharynx, or local extension of infection from middle ear infection (in association with intracranial involvement).

Affected animals frequently show generalized ill health, i.e. anorexia, pyrexia, weight loss and often severe spinal pain. The course of the illness is usually acute (days). Diagnosis is made by examination of CSF, which will often contain very large numbers of neutrophils, plus elevation in total protein content. Xanthochromia is frequent owing to previous haemorrhage. Microbial culture of CSF will provide confirmation of infection (both aerobic and anaerobic culture should be performed). The diagnosis is easier to make if there is a high index of suspicion, such as history of recent stick injury or other relevant information. A history of recent or concurrent systemic illness may also be relevant.

The most important condition from which differential diagnosis must be made is acute cervical disc extrusion. The two conditions can be differentiated by myelography, in which no abnormalities are found for cases of meningitis. However, it is important to obtain a sample of CSF prior to introduction of the contrast agent into the subarachnoid space. Following contrast administration there may be alteration in the cell counts and protein content sufficient to make diagnosis difficult.

Treatment of bacterial meningitis is purely medical; selection of appropriate treatment is made following microbial culture and sensitivity testing of specimens of CSF, or from blood culture in some systemically affected individuals. The role of corticosteroids in treatment of bacterial meningitis has been a source of controversy. In human patients it has been found that use of corticosteroids is associated with greater morbidity and mortality.

VIRAL MENINGITIS

Viruses are the most common infectious cause of meningitis, owing to the ubiquity of the canine distemper virus (CDV). Disease caused by CDV is of varying prevalence in different areas of this and other countries. Although many dogs are vaccinated against CDV, some individuals are still liable to succumb to the neurological form of the disease without exhibiting the classical systemic signs beforehand. CDV can be responsible for any neurological syndrome and should form part of the differential diagnosis for practically any neurological symptom, i.e. 'it can do anything it wants to'. Typical signs associated with CDV encephalomyelitis/meningitis include pain and brainstem signs initially – commonly cerebellar or vestibular signs are seen early in the course of the disease. There is often a rapid progression of signs over several days and other areas of the CNS will be affected. It is not unusual to re-examine an animal 24 h following an initial consultation and find that the neurological signs are very different from those originally observed. Commonly, the neurological signs imply multifocal or diffuse disease but signs consistent with a solitary lesion can also occur.

Diagnostic tests for CDV include serum antibody titres, examination of conjunctival scrapes for evidence of inclusion bodies in the mucosal cells, and examination

of CSF for evidence of intrathecal antibody production. Unfortunately, many of the tests often yield false negative results. False positive results do not occur if tests are properly assessed, for instance demonstration of rising antibody level to the virus. The alterations in CSF associated with CDV infection have been described. There is usually a mild mononuclear pleocytosis, with a moderate increase in the level of protein. These changes are nonspecific and therefore are not of assistance in making a conclusive diagnosis.

Other viruses have been implicated as causes of meningitis and/or myelitis in the dog, among them canine parvovirus, herpes virus and Aujeszky's disease. Feline infectious peritonitis virus (FIP) can cause CNS disease in the cat. This 'dry' form of the disease usually occurs in cats which do not exhibit the typical symptoms associated with the effusive form of the disease. Cats affected by the dry form typically exhibit rapidly progressive symptoms of intracranial disease such as head tilt, seizures, etc. It is unusual for cats affected with FIP to develop signs of spinal disease alone but such cases do occasionally occur.

Useful diagnostic tests for FIP include finding elevation of total blood protein due to hypergammaglobulinaemia and increase in FIP antibodies in the blood (when found in conjunction with other typical signs of the disease). It is common to detect disease elsewhere in the CNS or in the eye (chorioretinitis).

Treatment of viral meningitis/myelitis in cats and dogs is limited to supportive care of the animal. Such care may involve administration of intravenous fluids, or even parenteral nutrition, plus antibiotics if appropriate. The use of corticosteroids for treatment of active CDV infection is controversial – proponents of their use claim that they help to reduce the demyelinating effects of the viral infection which is in part dependent on the host responses. However, the reduction of potency of the immune system of the host must be weighed against this possible benefit. It appears to be safe to use low doses (e.g. 0.1 mg/kg.day prednisolone) of corticosteroids in affected dogs. Use of both corticosteroids and tylosine for treatment of cats suffering with FIP has been recommended but neither appears to be of any benefit.

There are no specific antiviral preparations that can ameliorate the results of active infection. Vaccination of exposed animals against CDV will be protective to some extent although, as already stated, some individuals may develop active CDV infection in the CNS despite what would appear to be adequate vaccination. There is at present no licenced vaccine for FIP in cats.

NON-INFECTIOUS CAUSES

The most common meningitis in the USA is thought to be corticosteroid responsive meningitis. An early description of the condition is by Meric *et al.* (1985). This syndrome is most often seen in larger breed dogs and usually affects young animals – most affected dogs are under 2 years old. The syndrome is rather poorly defined in terms of the pathological lesions as few dogs have been examined histologically. There is usually a fairly rapid onset of signs of spinal pain, which usually is most obviously manifest in the cervical region (i.e. pain on bending down to eat or drink) but affected dogs will also often exhibit kyphosis of the thoracolumbar spine and occasionally a 'walking on eggshells' gait. Neurological signs are infrequent,

although some dogs will exhibit mild proprioceptive deficits. Pain can easily be elicited on palpation or manipulation of the vertebral column.

Examination of blood samples will often reveal a mild to moderate neutrophilia. CSF examination reveals moderate to marked neutrophilic pleocytosis and elevation of protein content. Microbial culture is negative and no significant antibody titres to the various infectious causes of meningitis can be demonstrated. Following negative results of all routine diagnostic tests, dogs may be treated with corticosteroids. This is commenced at a high dose (approximately 2–4 mg/kg.day) and then tailed off over about 6 weeks. Some dogs have recurrent bouts of disease – following tests to re-establish the cause of the symptoms repeated treatment with corticosteroids and tapering of the dose over a longer period of time is indicated. The disease will not usually reappear after the dog is 2 to 3 years old. Thus the prognosis for recovery is excellent, which accounts for the scarcity of affected animals having undergone post mortem examination.

No aetiological agent has been found to account for this syndrome and it has been assumed that there is an immune-mediated component to the disease. In one report, 3/10 dogs had positive LE clot tests, supporting this contention. There is some similarity of this syndrome with the vasculitis diseases seen in specific breeds such as the Bernese mountain dog and beagle. Both these breed-specific conditions have been reported to resolve following suitable corticosteroid therapy, although the recovery rate in the Bernese mountain dogs was not 100% of affected animals. A genetic component is assumed to be involved in the development of these breed-specific syndromes.

Another (uncommon) cause of meningitis and myelitis has been diagnosed in older dogs. This is the condition variously known as reticulosis or granulomatous meningoencephalitis. Symptoms of brainstem or cerebral dysfunction are much more commonly observed as a result of this disease, but occasional dogs have been reported in which the signs appear to exclusively affect the spinal cord. The reported signs were those of slow progressive myelopathy. Myelography was able to delineate lesions occupying the subarachnoid space. Treatment with corticosteroids had a limited beneficial effect and the diagnosis was ultimately confirmed at post mortem examination.

The aetiology of reticulosis is unclear, although both immune mediated and viral causes have been suggested.

Associated reading

Vascular disease

Cordy D.R. (1979) Vascular malformations and haemangiomas of the canine spinal cord. *Vet. Pathol.* **16**, 275.

deLahunta A. (1977) Fibrocartilaginous embolic ischemic myelopathy. In: Kirk R.W. (ed.) *Current Veterinary Therapy VI*. Philadelphia, W.B. Saunders, p. 908.

Dyce J., Houlton J.E.F. (1993) Fibrocartilaginous embolism in the dog. *J. Small Anim. Pract.* **34**, 332.

Gilmore D.G., deLahunta A. (1987) Necrotizing myelopathy secondary to

- presumed or confirmed fibrocartilaginous embolism in 24 dogs. *J. Am. Anim. Hosp. Assoc.* **23**, 373.
- Joshua J.O., Ishmael J. (1968) Pain syndrome associated with spinal haemorrhage in the dog. *Vet. Rec.* **83**, 165.
- Luttgen P.J. (1990) Common degenerative and vascular neurologic disorders in cats and dogs. *Prog. Vet. Neurol.* **1**, 387.
- Martin R.A., Shell L., Dodds W.J. (1986) Focal intramedullary spinal cord haematoma in a dog. *J. Am. Anim. Hosp. Assoc.* **22**, 545.
- Penwick R.C. (1989) Fibrocartilaginous embolism and ischaemic myelopathy. *Comp. Cont. Ed. Pract. Vet.* **11**, 287.
- Zaki F.A. (1981) Chapter 90 Necrotizing myelopathy in the dog in: Pathophysiology In: Bojrab M.J. (ed.), *Small Animal Surgery* 1st edn. Philadelphia, Lea and Febiger, p. 764.

CNS and meningeal infection

- Cook J.R., Evinger J.V., Wagner L.A. (1991) Successful combination chemotherapy for canine cryptococcal meningoencephalitis. *J. Am. Anim. Hosp. Assoc.* **27**, 61.
- Fenner W.R. (1984) Treatment of central nervous system infections in small animals. *J. Am. Vet. Med. Assoc.* **185**, 1176.
- Hass J.A., Shell L., Saunders G. (1989) Neurological manifestations of Toxoplasmosis: a literature review and case summary. *J. Am. Anim. Hosp. Assoc.* **25**, 253.
- Kornegay F.N. (1978) Feline infectious peritonitis: the central nervous system form. *J. Am. Anim. Hosp. Assoc.* **14**, 580.
- Meric S.M. (1988) Canine meningitis. *J. Vet. Int. Med.* **2**, 26.
- Shell L.G. (1990) Canine distemper. *Comp. Cont. Ed. Pract. Vet.* **12**, 173.
- Thomas W.B., Sorjonen D.C., Steiss J.E. (1993) A retrospective evaluation of 38 cases of canine distemper encephalomyelitis. *J. Am. Anim. Hosp. Assoc.* **29**, 129-133.
- Tipold A., Vandeveld M., Jaggy A. (1992) Neurological manifestations of canine distemper virus infection. *J. Small Anim. Pract.* **33**, 466.
- Vandeveld M., Cachin M. (1992) The neurologic form of canine distemper. In: Kirk R.W. (ed.) *Current Veterinary Therapy XI*. Philadelphia, W.B. Saunders, p. 1003.

Extradural infection

- Brennan K.E., Ihrke P.J. (1983) Grass awn migration of dogs and cats: A retrospective study of 182 cases. *J. Am. Vet. Med. Assoc.* **182**, 1201.
- Edwards D.F., Nyland T.G., Weigel J.P. (1988) Thoracic, abdominal and vertebral actinomycosis. *J. Vet. Int. Med.* **2**, 184.
- Johnston D.E., Summers, B.A. (1971) Osteomyelitis of the lumbar vertebrae in dogs caused by grass seed foreign bodies. *Aust. Vet. J.* **47**, 289.
- Johnson R.G., Prata R.G. (1983) Intradiskal osteomyelitis: a conservative approach. *J. Am. Anim. Hosp. Assoc.* **19**, 743.
- Kornegay J.N. (1986) Diskospondylitis. In: Kirk R.W. (ed.) *Current Veterinary Therapy IX*. Philadelphia, W.B. Saunders, p. 810.
- Kornegay J.N., Barber D.L. (1980) Diskospondylitis in dogs. *J. Am. Vet. Med. Assoc.* **177**, 337.

Ndikuwera J., Knottenbelt D.C., Lawrence J., Hill F.W.G. (1987) Spinal abscess in a dog. *Vet. Rec.* **120**, 554.

Non-infectious inflammatory disease of the CNS and meninges

- Bailey C.S., Higgins R.J. (1986) Characteristics of cerebrospinal fluid associated with canine granulomatous meningoencephalomyelitis: a retrospective study. *J. Am. Vet. Med. Assoc.* **188**, 418.
- Harris C.W., Didier P.J., Parker A.J. (1988) Simultaneous central nervous system reticulosis in two related Afghan hounds. *Comp. Cont. Ed. Pract. Vet.* **10**, 304.
- Meric S.M., Child G., Higgins R.J. (1986) Necrotizing vasculitis of the spinal pachyleptomeningeal arteries in three Bernese mountain dog littermates. *J. Am. Anim. Hosp. Assoc.* **22**, 459.
- Meric S.M., Perman V., Hardy R.M. (1985) Corticosteroid-responsive meningitis in ten dogs. *J. Am. Anim. Hosp. Assoc.* **21**, 677.
- Presthus J. (1991) Aseptic suppurative meningitis in Bernese mountain dogs. *Eur. Vet. J.* **1**, 24.
- Russo M.E. (1983) Primary reticulosis of the central nervous system in dogs. In: Kirk R.W. (ed.), *Current Veterinary Therapy VIII*. Philadelphia, W.B. Saunders, p. 732.
- Sarfaty D., Carrillo J.M., Greenlee P.G. (1986) Differential diagnosis of granulomatous meningoencephalomyelitis, distemper and suppurative meningoencephalitis in the dog. *J. Am. Vet. Med. Assoc.* **188**, 387.
- Scott-Moncrieff J.C.R., Snyder P.W., Glickman L.T. *et al.* (1992) Systemic necrotising vasculitis in nine young beagles. *J. Am. Vet. Med. Assoc.* **201**, 1553.
- Sorjonen D.C. (1990) Clinical and histopathological features of granulomatous meningoencephalomyelitis in dogs. *J. Am. Anim. Hosp. Assoc.* **26**, 141.
- Thomas J.B., Eger C. (1989) Granulomatous meningoencephalomyelitis in 21 dogs. *J. Small Anim. Pract.* **30**, 287.

CHAPTER 11

Cervical Spinal Surgery

Contents

<i>Introduction</i>	148
<i>Cervical disc surgery</i>	148
<i>Fractures/subluxations</i>	155
<i>Neoplasia</i>	163
<i>Associated reading</i>	166

Introduction

Common indications for operating on the cervical region of the vertebral column include atlantoaxial subluxation and surgery of the intervertebral discs. The 'wobbler' syndrome is somewhat distinct from other conditions affecting the cervical spine and will be discussed in Chapter 12.

Cervical disc surgery

Discussion of the incidence, signalment and diagnosis of cervical disc disease is included in Chapter 7.

Some animals presented for treatment of cervical disc disease can be adequately managed conservatively. This usually consists of cage rest for a variable period, plus use of corticosteroids or nonsteroidal drugs to reduce pain. Many conservatively treated animals will ultimately relapse and require surgery. Conservative therapy is discussed in more detail in Chapter 15.

There are several options for the surgical treatment of cervical disc disease: fenestration, ventral slot, hemilaminectomy and lateral decompression.

Fenestration

Fenestration of the cervical discs has been recommended as a treatment for dogs exhibiting typical signs of disc disease, often without prior myelography. The reported results are encouraging for those suffering pain only, but many animals have prolonged recovery periods, which can be attributed to failure of the technique to address the problem of extruded disc material in the vertebral canal. Fenestration must now be considered primarily a prophylactic treatment, or as a treatment for animals suspected of having 'discogenic' pain, i.e. those with typical symptoms of cervical disc herniation but with no mass lesion detected by myelography or oblique plain radiographs. Discogenic pain may arise from the stretching

of the annulus fibrosus due to degeneration of the nucleus and consequent generation of abnormal stresses. The diagnosis of discogenic pain must be made with caution, taking care to rule out other potential causes of cervical pain, such as various inflammatory diseases, in those cases with negative findings on plain radiography and myelography. It is rare to encounter dogs in which cervical pain cannot be attributed to a cause other than discogenic pain. The only exception may be some cavalier King Charles spaniels. In this breed it is not unusual to fail to demonstrate a cause in animals which apparently are suffering considerable cervical pain. These individuals may recover with conservative therapy alone or sometimes appear to benefit from fenestration.

Despite these reservations, fenestration can be of value following definitive surgery of other discs in the region, as prophylaxis against further episodes of disc-related cervical pain. However, recurrent disc-related problems in other spaces following ventral slotting of one space are uncommon.

Fenestration of the cervical discs is carried out via a ventral approach, following division of the midline sternohyoid and sternomastoid muscles (Figure 11.1). The trachea, oesophagus and the large blood vessels of the region are retracted to the left, exposing the longus colli muscle on the ventral aspect of the cervical vertebrae. Care must be taken to avoid damage to the recurrent laryngeal nerve which runs on the lateral aspect of the trachea. The intervertebral discs are located just caudally to the V shape made by each pair of insertions of the longus colli tendons on the caudal ventral prominence of each vertebra. Correct identification of each disc space is aided by use of a hypodermic needle to penetrate the annulus and palpate the soft interior of the disc. Fenestration is carried out by removal of an arc of the ventral annulus, followed by removal of the nuclear material using rongeurs, dental tartar scrapers or similar implements. A recent article has described the use of an air drill to aid complete evacuation of the nucleus in thoracolumbar disc fenestration, the same technique could also be applied to cervical discs. Closure includes suturing of the longus colli muscles.

Dogs that exhibited discogenic cervical pain prior to fenestration will be expected to have immediate pain relief. If this does not occur the course of the postoperative pain may be prolonged. Alternatively, another source of pain may be suspected, such as a lateralized disc extrusion, tumour or meningitis/myelitis.

On the whole, fenestration is a safe operation, with few complications. However, two adverse sequelae to fenestration have been described: (i) inadvertant transfer of more disc material into the vertebral canal during the procedure, which can cause worsening of the clinical signs; and (ii) the possibility of causing future problems owing to collapse of the interspace and therefore causing 'redundancy' of the dorsal annulus. This second complication is more of a consideration in the treatment of 'wobbler' dogs but may need to be considered before fenestration is carried out in any dog.

Ventral slot

Ventral slotting is the procedure of choice for removal of extruded cervical disc material if, on myelography, the mass can be demonstrated to lie on the floor of the vertebral canal. This is the most common location for canine cervical disc extrusions. Following ventral slotting there is usually a very rapid regression of

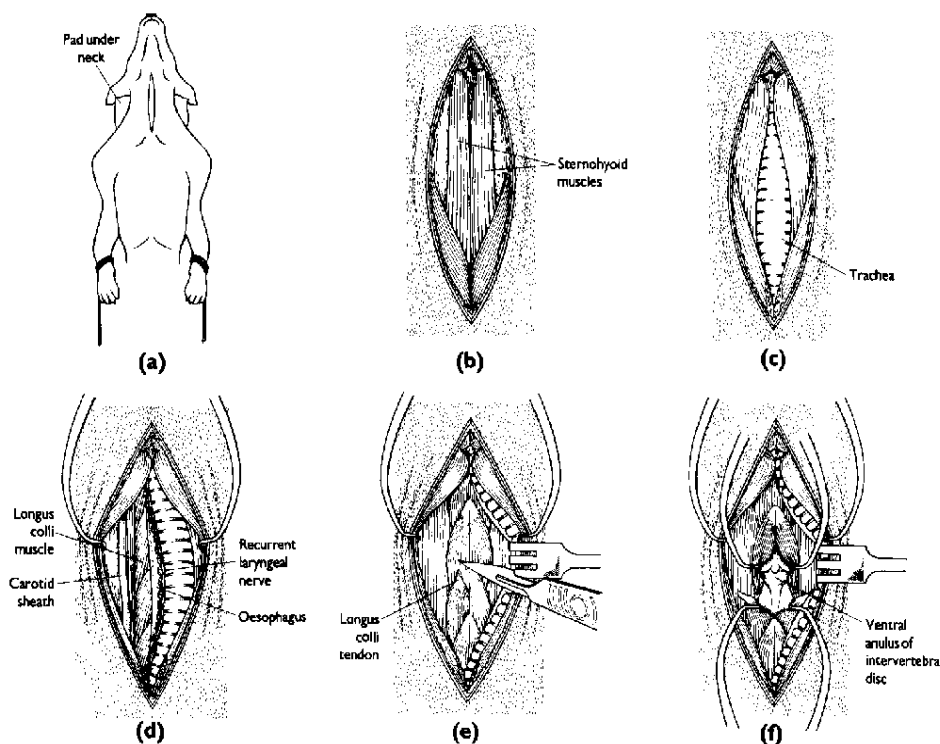


Figure 11.1 Ventral approach to the cervical vertebral column: (a) dog is securely positioned in dorsal recumbency and the neck is in slight extension; (b and c) paired sternohyoid muscles are exposed and divided in the midline to reveal the trachea; (d) retraction of the trachea to the left exposes the longus colli muscle; (e) longus colli tendons are severed at their attachment on the relevant vertebral bodies; (f) retraction of the longus colli muscles exposes the annulus.

symptoms, i.e. relief of pain, within 48 h. Ventral slotting requires more extensive instrumentation than fenestration.

This technique is carried out using the same approach as fenestration. Correct identification of the appropriate space is ensured by counting disc spaces from the C7/T1 disc (or C6/7 in animals in which the transverse processes of C6 are clearly defined). The central one-third of the neighbouring vertebral bodies is drilled out by means of a high-speed air drill until the vertebral canal is reached. The drill hole is up to one third to one half the length of the vertebral bodies when it reaches the vertebral canal; it is usual to start the caudal part of the drill hole very close to the caudal margin of the annulus as the disc lies at an angle to the perpendicular; the dorsal part of the annulus lies considerably further cranially than the ventral part (Figure 11.2).

Following removal of the bone of the floor of the vertebral canal by means of air drill, rongeurs or small picks, the dorsal longitudinal ligament is grasped and excised if it is not already torn. Extruded disc material in the vertebral canal can

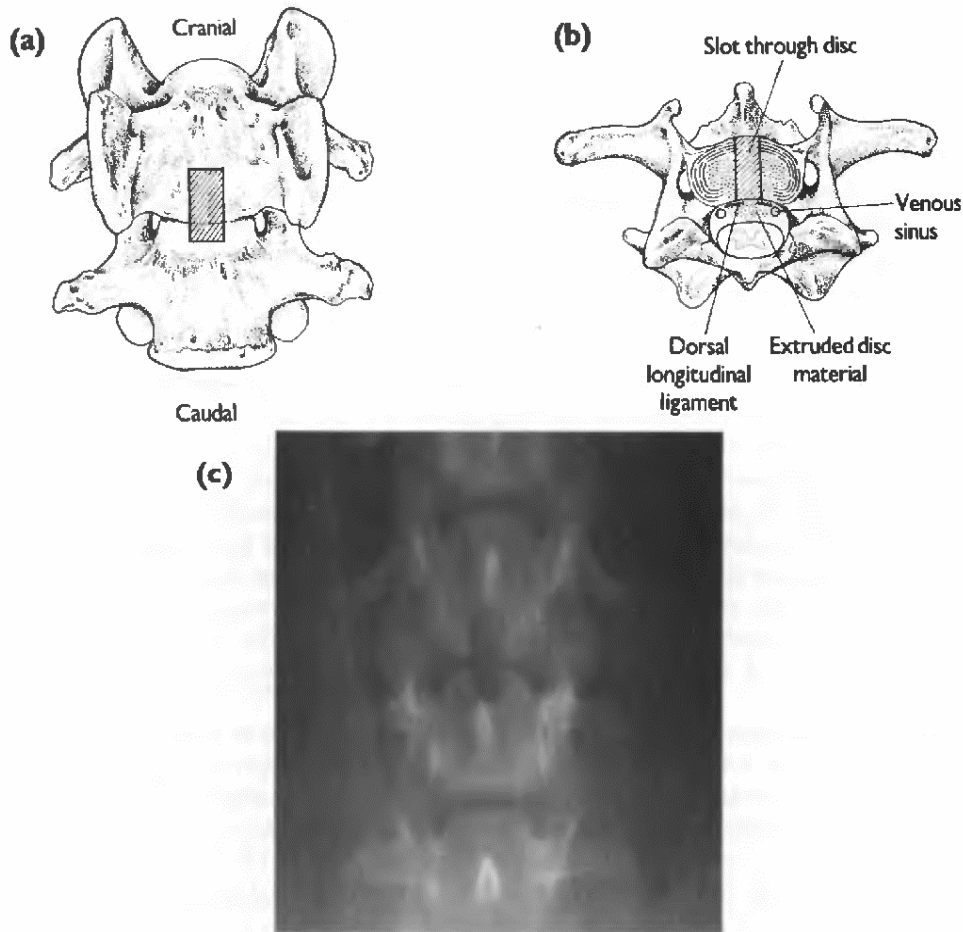


Figure 11.2 (a) Position and size of slot on ventral aspect of vertebrae; note that burring is centred cranial to the intervertebral space. (b) Diagram of slot size and relationships in conventional slot technique. (c) Postoperative ventrodorsal radiograph of ventral slot operation at C5/6.

then be seen and removed. It is retrieved from the vertebral canal by means of suction, fine forceps, rongeurs and dental instruments or microdissectors. It is often possible to remove material from the lateral 'gutters' of the vertebral canal via the ventral slot approach.

A number of complications have been recorded following ventral slotting:

- (1) Laceration of the venous sinuses. This is the most common complication, occurring in 19% of slots in one series. Haemorrhage following damage to the venous sinuses can be very severe and occasionally even fatal. Correct positioning of the animal prior to surgery (i.e. in true dorsal recumbency with no lateral tilting) and limiting the lateral extent of the slot (i.e. no wider than one half of the width of the vertebral body) aids in reduction of the incidence of venous sinus laceration.
- (2) Severe bradycardia. This is an unusual complication, unless there is a great deal

of manipulation of the spinal cord. It is thought to occur because of acute sympathetic blockade

- (3) There have been some reports of collapse of the vertebral body following ventral slotting and therefore care should be exercised to remove no more than the central one-half of the width of the vertebral body. A new version of the ventral slot, the inverted cone decompression technique, has also recently been described. This technique aims to minimize bone removal whilst allowing maximal access to the vertebral canal; it is most useful for treatment of 'wobbler' dogs, and it will be described further in Chapter 12.

PROGNOSIS

The prognosis for dogs with dorsally directed disc extrusions which exhibit pain only and are treated by ventral slotting should be excellent. Most dogs show an immediate improvement in their condition and almost all are improved within 48 h. The prognosis for dogs presenting with non-ambulatory tetraparesis is not as good, although in one study of 12 cases, nine improved sufficiently to walk, of which seven returned to normal. It has also been suggested that dogs with cranial cervical lesions are more likely to make a complete recovery than those with more caudal lesions. The period until recovery is complete in tetraparetic cases is related to the speed of onset of paresis, the more acute the onset, the slower the recovery. The probability of recovery is not related to the duration of non-ambulatory tetraparesis.

A recent retrospective study sought to compare the results of fenestration and ventral slotting in 111 ambulatory dogs with symptomatic cervical disc lesions (Fry *et al.* 1991). The results clearly showed that decompressive surgery (slot) is superior in alleviating symptoms. Only in comparing the rate of intraoperative and immediate postoperative complications was fenestration superior. However, although the major complication of slotting was haemorrhage, only one dog died as a result.

Lateral approach

This technique has recently been described and used in two clinical cases of cervical disc extrusion; it is designed specifically for treatment of very lateralized disc extrusions (Lipsitz and Bailey, 1992). Suitable cases for this operation would be those in which the extruded disc material (or other compressive mass) can be radiographically demonstrated to lie in the foramen. Animals in which a ventral accumulation of extruded material can be seen on myelography are more simply treated by means of the ventral slot technique – access to the ventrolateral aspect of the cord is satisfactory via this route. Lateral approaches to the cervical spine are difficult owing to the large muscle mass and its orientation relative to the spine, therefore easy access following this approach is limited to C3/C4 to C5/C6. This technique could also be useful for exploration of the C5 and C6 nerve roots in cases of tumours of the nerve roots of the brachial plexus.

The animal is placed in lateral recumbency with the uppermost thoracic limb retracted caudally. The skin incision is made parallel to the line of the articular processes. Dissection through the subcutaneous tissues exposes the brachiocephalic muscle, which is incised in a cranial–caudal direction to permit access to the

relevant vertebrae. The exposed dorsal edge of the omotransversarius muscle is dissected free of neighbouring connective tissue and retracted. Retraction of the cut brachiocephalicus exposes the serratus ventralis muscle, which is separated by blunt dissection from the underlying longissimus cervicis muscle; it is then incised dorsocranially to ventrocaudally. The longissimus cervicis and dorsal border of the longissimus capitis muscles are then exposed; they are bluntly dissected and retracted ventrally. At this stage the correct intervertebral space is located by counting transverse or articular processes. The dorsal branch of the spinal nerve exiting at the site of interest must be cut to allow adequate exposure of the foramen. The synovial joint is exposed by elevation of the remaining musculature; the tendinous attachments of the complexus and multifidus muscles to the articular processes require sharp incision. Elevation, using periosteal elevators, and retraction, using Gelpi retractors, of the surrounding muscles is continued to expose the pedicle and lamina of one-half of the vertebra. Suitable exposure of the spinal cord and nerve root is achieved using rongeurs and high-speed drill to remove the overlying bone. Haemorrhage from the venous sinus or its branches can occur and be profuse; diathermy is helpful to attain good haemostasis.

Closure consists of placement of a fat graft into the laminectomy site and reapposition of the incised portions of the serratus ventralis and brachiocephalicus muscles.

Laminectomy/hemilaminectomy

Dorsal laminectomy of the cervical vertebrae is required in animals in which a mass lesion is detected by myelography and lies dorsal or dorsolateral to the dural tube, therefore this approach is primarily used in exploratory surgery. Another use for dorsal laminectomy in this region is in the treatment of certain 'wobbler' dogs (Chapter 12).

Hemilaminectomy can be used to remove lateralized disc material from the lateral and ventral aspect of the cord. Using this approach it is possible to open the intervertebral foramen to free the nerve root from entrapment. The hemilaminectomy is combined with facetectomy to allow exposure of the lateral part of the spinal cord, the nerve roots and the venous sinuses. In most cases only one half of the lamina needs to be excised to allow removal of extruded disc material.

The dorsal approach to the mid and caudal cervical vertebrae is time consuming, especially in large-breed dogs, owing to the large mass of muscle in this location. Incision of the skin reveals subcutaneous muscle which can be divided on the midline to expose the median fibrous raphe, which is thick and well defined. The median raphe is incised in the midline and the incision deepened to expose the nuchal ligament. There are often many arterial bleeders encountered during this procedure, which require ligation or diathermy coagulation. After exposure of the nuchal ligament, it can be detached from its local attachments and retracted laterally. The spinous processes of the vertebrae can be palpated; the site of interest is determined most easily by counting from the spinous process of T1, which is the largest in the area. The muscle attachments on the spinous processes are elevated by incision as close as possible to the bone. They can be retracted laterally using Gelpi retractors. Exposure of the laminae is carried out by continuing the muscle elevation more laterally. Care must be taken when elevating muscle from the region

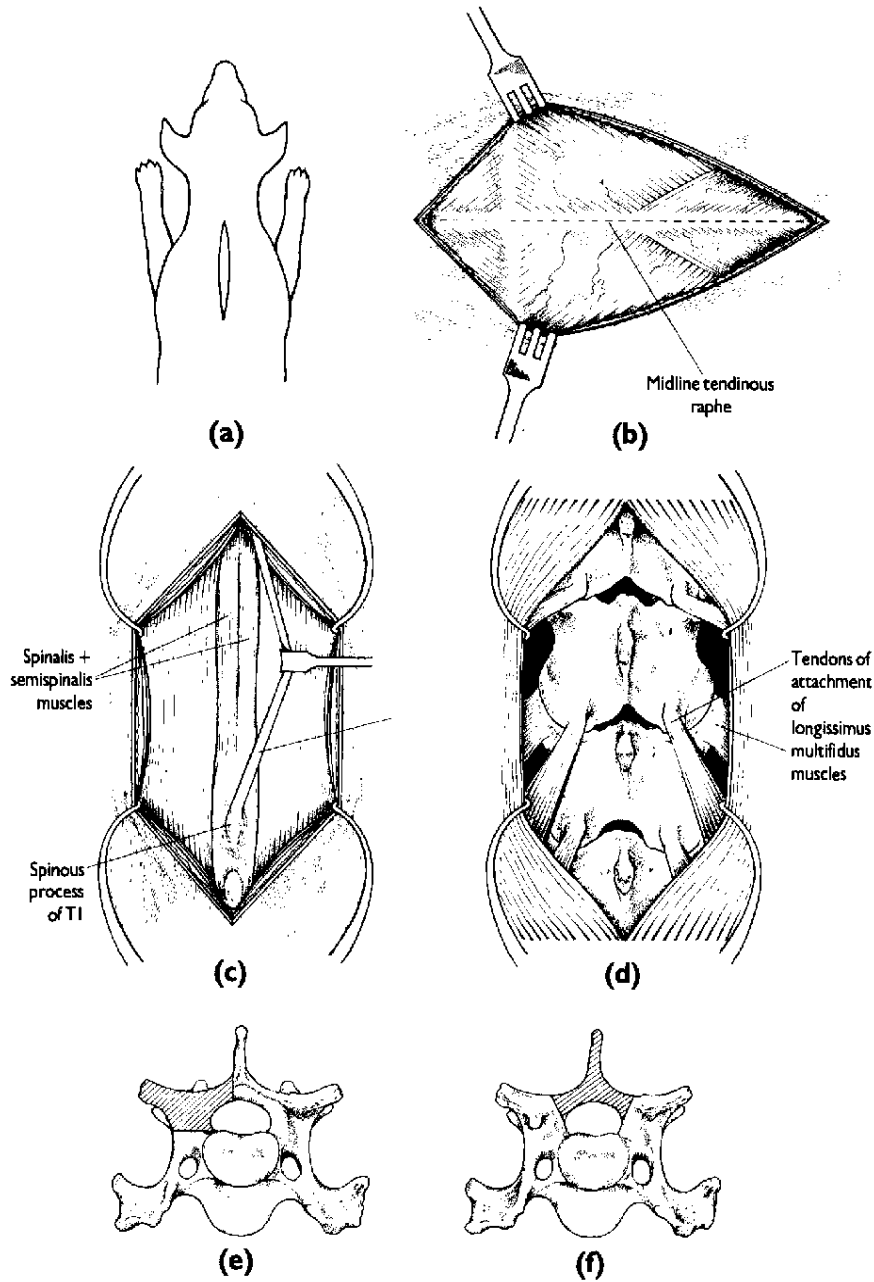


Figure 11.3 Dorsal approach to the mid-caudal cervical vertebral column: (a) secure positioning in ventral recumbency (midline incision); (b) incision continued through midline raphe; (c) exposure of the nuchal ligament is facilitated by continuing midline dissection more deeply – it is retracted laterally exposing the paired midline muscles and a small intermuscular septum; (d) sharp dissection through the midline and blunt elevation of the muscles from bone exposes the dorsal surfaces of the laminae – sharp division of the tendons of the multifidus and longissimus tendons may be required to carry out hemilaminectomy and facetectomy; (e) extent of bone removal for cervical dorsal laminectomy; (f) extent of bone removal for cervical hemilaminectomy and facetectomy

of the synovial joints, as there are large branches of the vertebral artery just ventral to the articular processes. In the more caudal portion of the cervical spine, the approach is slightly complicated by the proximity of the trapezius, rhomboideus and splenius muscles, which add to the bulk of musculature which must be retracted. However, the dissection is still carried out in the same way, by proceeding directly down the midline until encountering the laminae, and then continuing dissection laterally (Figure 11.3).

The dorsal approach entails greater risk of blood loss than the ventral approach, as a great number of large vessels are encountered and the muscle bellies themselves may ooze considerably. There is a risk of incurring serious blood loss in animals in which blood coagulation is impaired. It is therefore prudent to assess blood clotting prior to carrying out this surgical approach – especially in breeds in which there is a high incidence of clotting disorders.

Fractures/subluxations

Atlanto-axial subluxation

Dogs affected by atlanto-axial subluxation usually exhibit severe neck pain, with or without neurological deficits of the upper motor neurone type affecting all four limbs. The motor status can vary from fully ambulatory to tetraplegia. Kyphosis of the thoracolumbar segment is also commonly observed in such cases and may be a source of possible confusion (with disease of the TL segment). Animals which have developmental atlanto-axial subluxation will occasionally exhibit episodic collapse. This can be confused with epilepsy. However, affected dogs usually will merely lie still for several seconds (apparently unconscious) before getting to their feet; no tonic/clonic movements of the legs are observed and there is no aura or postictal disorientation.

Two groups of animals are most commonly affected by atlanto-axial subluxation:

- (1) Young toy breed dogs have a history of mild, or no, trauma to the head and neck. Commonly, owners will report a history of hitting the head on the underside of a table when rising. This group is affected because of abnormal development of the atlanto-axial joint and dens with consequent instability. These dogs are usually presented when under 18 months old and commonly less than 1 year old.
- (2) Any type of dog following trauma. This group is affected due to fracture of the dens. Traumatically affected dogs may be of any type or breed, although bull terrier and greyhound/lurcher type dogs appear to be more commonly affected by this injury. Trauma in these cases is usually severe, either the result of a road traffic accident or because of running at full speed into a fence or other obstacle.

Diagnosis

Plain radiographs are usually sufficient to diagnose subluxation at the atlanto-axial joint (Figure 11.4). In affected toy breed dogs there is frequently an absence, or abnormality, of the shape of the dens of the axis. This is most clearly seen in a ventrodorsal view. Open-mouth views of this region of the vertebral column will

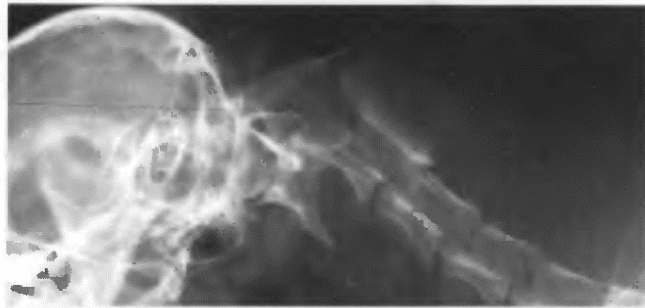


Figure 11.4 Lateral radiograph of severe atlanto-axial subluxation.

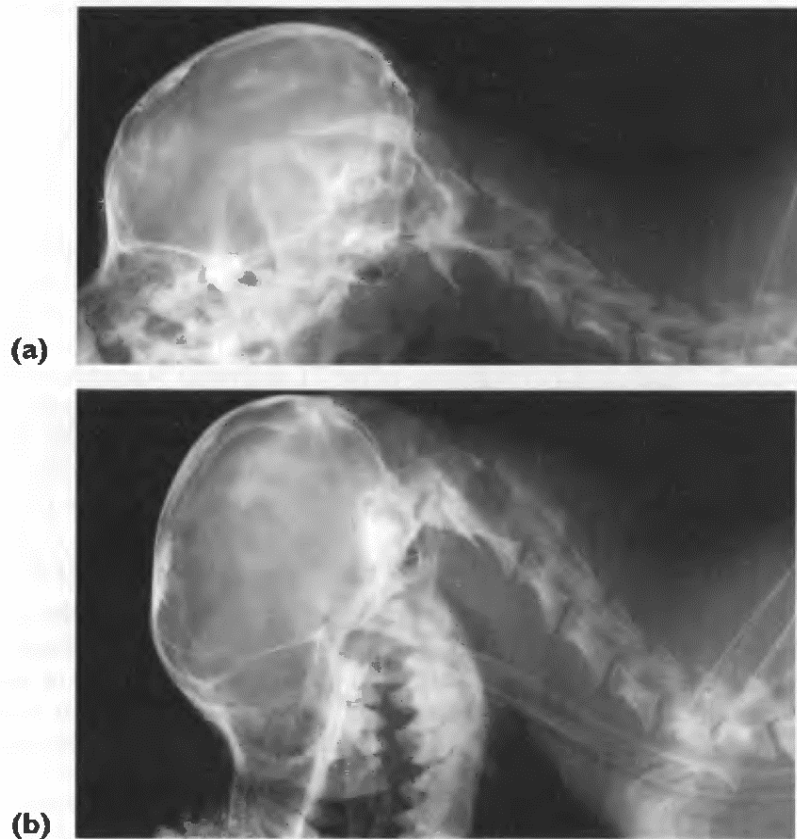


Figure 11.5 (a) Neutral and (b) flexed lateral radiographs of dog affected with atlanto-axial subluxation. This case was mildly affected necessitating a flexed view to substantiate the diagnosis.

clearly demonstrate abnormality of the dens but it can be hazardous to the animal to place it in this position. In some cases in which the subluxation of the C1/C2 interspace is not apparent on nonstressed films, carefully applied flexion of the cervical spine can aid in demonstration of instability (Figure 11.5).

In those animals which sustain atlanto-axial subluxation as the result of trauma, subluxation is usually the result of fracture through the dens and consequent

craniodorsal displacement of the axis. Although subluxation is usually obvious, the fracture line may or may not be easily seen on lateral radiographs.

Positioning of animals for radiography following these injuries must be carried out very carefully. In most cases general anaesthesia is required, as it is otherwise difficult to position the head and neck correctly. There is a tendency for the animal to rotate the head about the axis unless anaesthetized, which can render interpretation of the radiographs difficult. However, the rotated view can also be very helpful in evaluating the integrity of the dens and may be useful in certain individuals. Following induction of anaesthesia, muscle tone (which can be important in stabilisation of this injury) is greatly reduced, thus increasing the possibility for iatrogenic injury to the spinal cord. Care should be taken at all times to limit movement of the upper cervical spine and to allow movement into extension (dorsiflexion) only.

Treatment

Both conservative and surgical treatment of atlanto-axial subluxation have been employed with successful results. Conservative therapy usually consists of application of a padded dressing to the cervical spine, for a period of 4 to 6 weeks. In this time it is hoped that there will be a fibrotic response by the periarticular tissues, or callus formation following fracture, with a resultant increase in rigidity of the joint. Gilmore (1984) reported a series of four cases in which all recovered completely within 12 weeks. Of these cases, three subluxations were the result of road traffic accidents, with resultant fracture of C2 vertebra, and two exhibited severe neurological signs. It would be expected that conservative therapy for fractures would be more reliable than when applied to congenital subluxations, owing to the additional rigidity to be expected during bony callus formation.

There is greater difficulty in appropriately bandaging such animals than may at first be appreciated. In order to immobilize the head, a bandage must be applied as far cranially on the neck as possible, or there will be an increase in the stress applied to the atlanto-axial joint. If the bandage is applied too far caudally, without adequate support of the cranial portion, reduction in movement in the caudal and middle portions of the cervical spine will result in an increase in movement-generated stresses in the cranial segment. There can be complications from bandages applied too tightly to the upper cervical region, mostly owing to potential compression of the airways or venous drainage, and the development of oedema of the head, usually especially apparent in the intermandibular space. Bandages need to be applied so that they form a rigid column extending from just caudal to the mandible to the shoulders.

There are both dorsal and ventral surgical approaches used in the treatment of atlanto-axial subluxation. In most cases a neck collar is also applied following surgery in an attempt to provide extra rigidity during the healing period.

DORSAL APPROACH

Following a midline incision through the skin, the subcutaneous muscle is divided to expose the midline raphe of the epaxial muscles of this region (occipitalis, cervicocutularis, cervicoauricularis superficialis and biventer cervicis). This is

divided on the midline to expose the dorsal process of the axis. The exposure is continued laterally and cranially to expose the arch of the atlas by elevation of the rectus capitis muscle from the spinous process of the axis. Care must be taken not to damage the vertebral artery which lies ventrolateral to the articular processes. Profuse bleeding can occur as a result of damage to this artery and will greatly hamper adequate surgical visibility at the site.

Following incision of the atlanto-occipital membrane, luxation of the atlanto-axial joint can be reduced by means of a right-angled hook placed under the cranial edge of the arch of the atlas.

Stabilization of the luxation can be carried out by a number of means. The most common technique is to pass a loop of wire under the arch of the atlas and secure this to the dorsal process of the axis (Figure 11.6). Problems have been associated with the use of wire, particularly in young, small-breed dogs, in which the bone is especially soft allowing the wire to cut through the bone rather like a cheese wire. In order to overcome these problems, two other techniques have been proposed. One method is to use multifilament nonabsorbable suture material and the other is to use a part of the nuchal ligament in place of wire suture. The problems of 'cheesewiring' through the bone have been reduced, but not abolished, by the use of these materials. Special retractors have been designed for dorsal fixation of this subluxation in humans, and a modification has been used in the dog, failure of this technique has also been reported.

Another drawback to dorsal approaches is the risk of injury to the adjacent neural structures (medulla oblongata). Animals may even die owing to respiratory failure during flexion of the atlanto-axial joint which is required in order to pass suture material under the arch of the atlas.

VENTRAL TECHNIQUES

Owing to occasional failure of dorsally applied fixation to provide lasting stability of atlanto-axial subluxation, ventral techniques have been introduced. These are

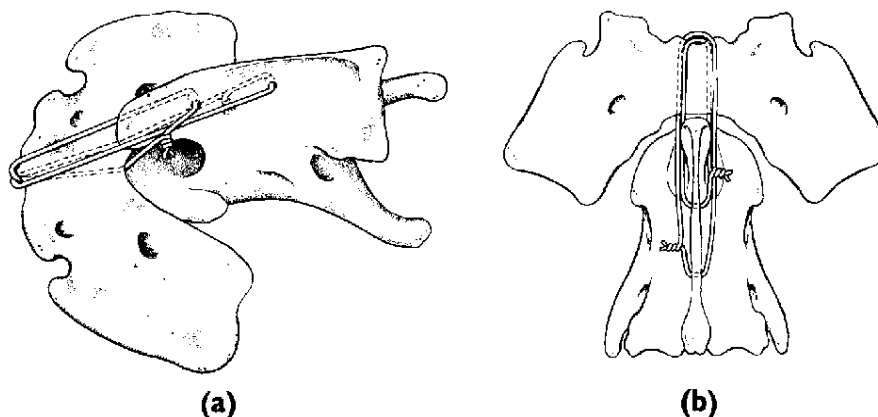


Figure 11.6 (a) Lateral and (b) dorsoventral views of dorsal fixation of atlanto-axial subluxation. One loop of suture material is passed under the arch of the atlas and used to provide two sutures.

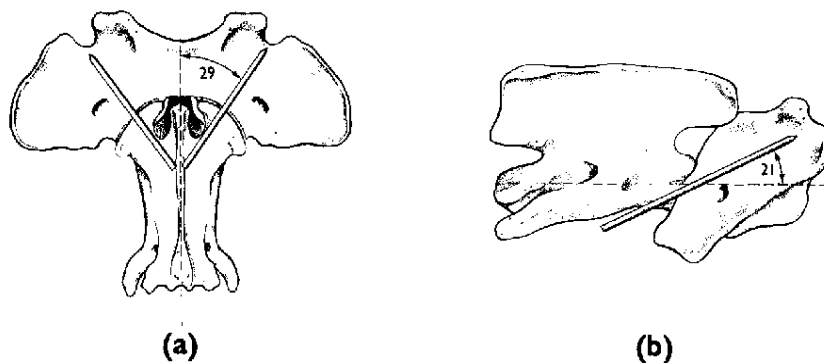


Figure 11.7 (a) Ventrodorsal and (b) lateral views of ventral fixation of atlanto-axial subluxation. Optimum pin placement angles are shown.

variations on the theme of cross-pinning the synovial joints between the axis and atlas. The approach to the joint is made following a ventral midline incision. The sternomastoideus and sternohyoideus muscles are divided along their midline to expose the larynx. The insertion of the sternohyoideus muscle on the right-hand side of the larynx is severed, allowing the larynx, oesophagus, left vagosympathetic trunk and carotid artery to be retracted to the left. Care must be taken to avoid injury to the recurrent laryngeal nerve. The ventral aspect of the atlanto-axial joint is exposed by dividing the insertions of the longus colli muscles on the atlas.

Reduction of the subluxation is often achieved simply by positioning the animal in dorsal recumbency but manipulation through the synovial joints can also be carried out using fine dissectors. On occasion, use of bone forceps to grasp the body of the axis can be helpful. Fixation of the relocated bones is most easily accomplished by cross-pinning. The optimal angle for the pins to be placed in both planes has been described by Sorjonen and Shires (1981). In the ventrodorsal view the pin should be inserted at 29° from the sagittal plane; in the lateral view the pin should be placed at 21.5° from the dorsal plane (Figure 11.7). It is very helpful to have access to sterile goniometers or protractors during operation in order to ensure correct pin placement.

Difficulties associated with poor pin placement can arise (such as damage to the spinal cord or associated blood vessels) but a more common problem is that pin migration can occur as a late complication. To avoid this sequela a recent modification of the technique is to add a small blob of polymethylmethacrylate cement to the pin ends to secure their position. The other option is to use screws instead of pins (Figure 11.8). Screw placement can be hampered by the poor access to drill the pilot holes, and the tendency for the screws to cut through the soft bone to lie close to the margin of the bone of the axis. Another technique is to use a plate (linear or T-shaped) applied to the ventral aspect of the axis and atlas.

The advantage of the ventral techniques is that following debridement of cartilage from the synovial joint and packing with cancellous bone graft, a rigid fixation will result in fusion of the synovial joint, thus reducing the possibility of recurrent luxation.

In some animals the use of one technique will result in failure, requiring a second

attempt at fixation to be made. In some fracture cases, use of both techniques is required to optimize stability. Animals in which preoperative duration of neurological signs was short will rapidly return to full function. The prognosis for those with long-standing neurological deficits is less certain. Although most affected dogs make very satisfactory recoveries, occasional animals which are non-ambulatory before surgery may fail to recover despite long follow-up times.

In general, ventral techniques are preferred in the treatment of toy dogs for which fusion following reduction and fixation is highly desirable. The failure rate of ventral surgery is lower than that for the dorsal techniques in this group of dogs. A further advantage of ventral approaches in such patients is the possibility for removal of the dens should it appear misshapen – a limited ventral slot can be used to approach the dens within the vertebral canal followed by its removal with rongeurs.

For those animals which have sustained fractures, which can be expected to heal rigidly with adequate immobilization, conservative treatment by external support

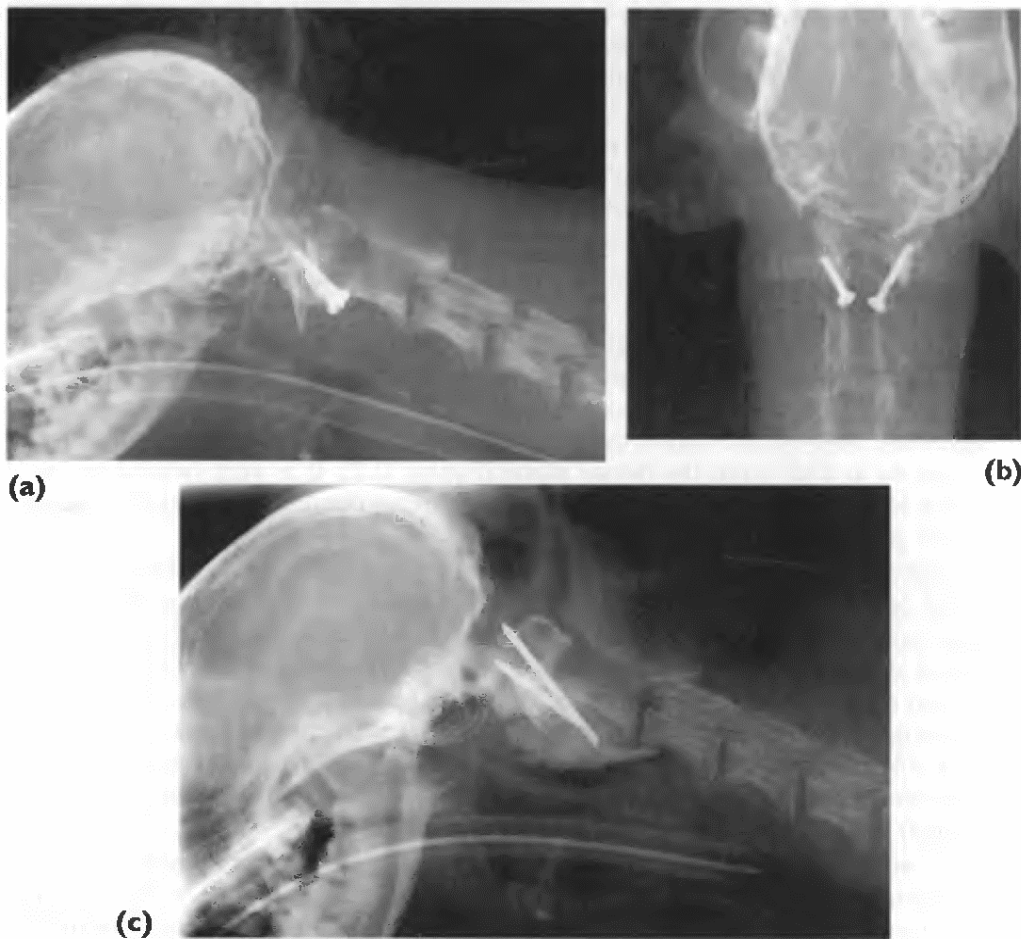


Figure 11.8 Postoperative radiographs of ventral fixation: (a, b) Lateral and ventrodorsal views of screw fixation; (c) lateral view of pin fixation, PMMA has been used to prevent pin migration.

may well be adequate for many cases. If surgery is to be carried out, dorsal techniques may be preferred, as they are more biomechanically sound (i.e. tension device applied to tension side of the fracture/luxation). The ventral techniques suffer from being biomechanically unsound, as the fixation is applied to the compression side of the fracture/subluxation.

Other fracture/luxations of the cervical vertebral column

ATLANTO-AXIAL SUBLUXATION IN THE CAT

Atlanto-axial luxation/subluxation is not as common in the cat as in the dog, but has been reported in association with occipito-atlanto axial malformations. Treatment of these cats was by the same means as in small dogs, by a ventral cross-pinning technique. Cancellous bone grafts in cats are usually best obtained from the ilium, rather than the humerus (often only small quantities are available from the humerus).

ATLANTO-OCCIPITAL SUBLUXATION

Atlanto-occipital subluxation has been reported rarely in either the cat or the dog. Two dogs exhibiting mild cervical pain and neurological deficits were treated by external methods alone, but surgical treatment has also been utilized. Oblique radiographs of the cranial portion of the cervical spine revealed a fracture of the ventral part of the atlas, with dorsal displacement of the atlas relative to the occipital bone. Reduction of the fracture/luxation was secured by means of lag screws and a tension band running from the dorsal spine of the axis to the occipital protuberance. External support was also given. Ability to walk returned within 4 days and a full recovery followed.

FIXATION OF CERVICAL FRACTURES/LUXATIONS

Most of the fractures in the cervical spine occur in the axis and atlas, in a series reported by Stone et al. (1978) 78% had fractures of the axis. Fracture of the axis will cause atlanto-axial subluxation and is discussed above.

Fractures or luxations occurring in the remainder of the cervical spine are less common, perhaps owing to the large muscle mass which surrounds and supports the region. Both conservative and surgical techniques of reduction can be appropriate. Four techniques of cervical spinal stabilization were evaluated by Swaim and Greene (1975). The conclusions were that screw fixation through the facets was the most stable and that ventral plate fixation was difficult and liable to fail owing to problems in penetration of the dorsal cortex of the vertebral body. The combined use of Steinman pins and PMMA is now most commonly used as it is versatile and easy to apply. Fixation techniques using the spinous processes are not reliable in this area of the vertebral column owing to the poor purchase of such fixation on the very short spinous processes of the cervical vertebrae. Reduction of fractures and luxations in this region probably does not need to be so accurate as elsewhere in the vertebral column, owing to the relatively large size of the vertebral canal. The case shown in Figure 11.9 made a complete recovery despite the poor reduction.

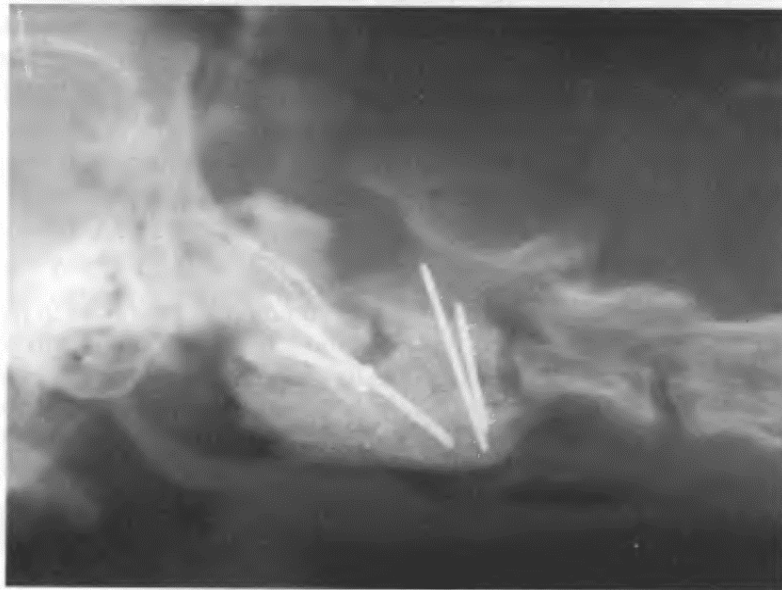

Figure 11.9 Dorsal and ventral fixation of dog with comminuted fracture of C2. Dorsal fixation is by braided nylon suture.

Conservative therapy, including cage rest or plaster of Paris casting can also be successful in many cervical fractures even when there is considerable displacement of fragments.

Ventral fixation using pins and PMMA is carried out following a routine ventral approach to the cervical vertebral bodies. Reduction is accomplished, usually by the use of small reduction forceps to grasp and manipulate the fragments. Steinman pins are driven into the vertebral bodies starting at the midline and diverging so as to avoid the vertebral canal and the vertebral artery. The exact angle for pins to be drilled in each individual dog can be calculated by making drawings from measurements on radiographs; however, it is usually approximately 30–35° from sagittal. Access to a bone specimen and goniometers during operation is also helpful. The size and number of pins applied to each bone fragment can be varied but there should be purchase on at least four cortices each side of the fracture/luxation. In order to try to prevent postoperative pin migration the pins should be notched or bent over near the ends. With the bones correctly aligned and held in position by temporary fixation, such as wire, a ball of PMMA at the doughy stage of curing is applied and wrapped around the pins. The pin ends should be completely encased in bone cement. It is best to include only a short section of the vertebral column in the fixation as this will reduce the stresses that will be applied through the implant during neck movement postoperatively.

MID-CERVICAL SUBLUXATION

An unusual luxation in the cervical spine has been reported by Basinger et al. (1986), which is most often the result of a dog fight. The twisting and linear traction applied to the cervical spine in such cases can result in subluxation of

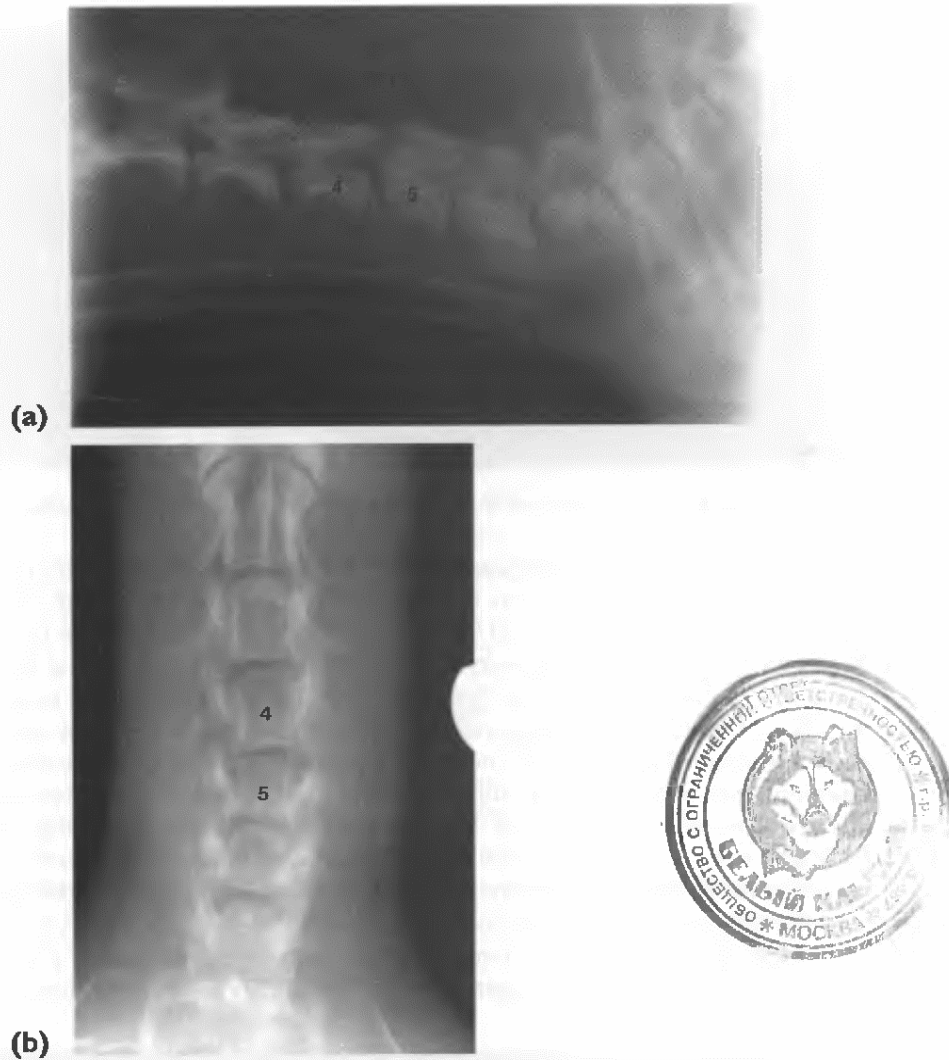

Figure 11.10 (a) Lateral and (b) ventrodorsal views of subluxation of C4/5 in a dog.

both articular facets of one intervertebral joint, usually at C5/C6 or C4/C5 with resultant compression of the spinal cord. Following a dorsal approach to the cervical vertebrae, this lesion is treated by realignment of the articular facets, which can be fixed together by screws to prevent relaxation (Figures 11.10 and 11.11). Wire can be used instead of screws, and may be preferable, in that more intervertebral movement is permitted, thus reducing stress on the implant.

Neoplasia

Although any type of tumour may occur in the cervical region, there appears to be a higher proportion of the intradural types (both intradural/extramedullary and intramedullary) in the cervical region. Meningiomas occurred more commonly in

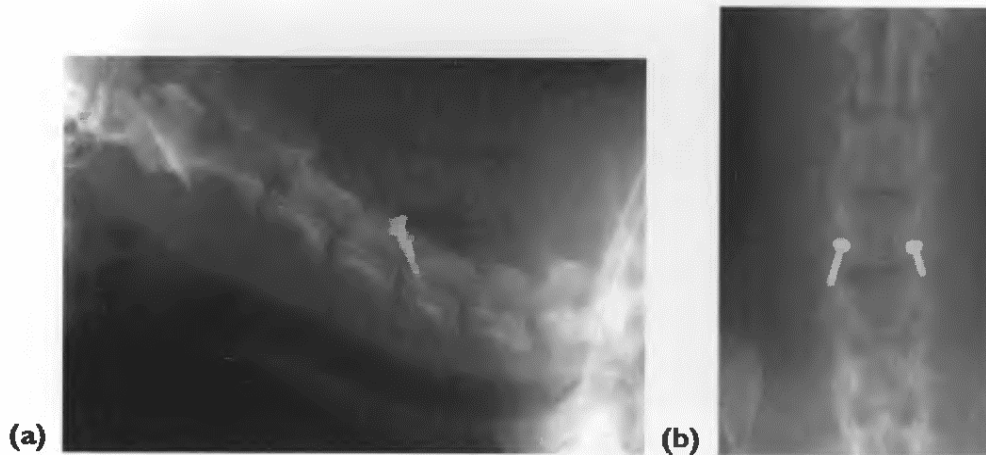


Figure 11.11 (a) Lateral and (b) ventrodorsal views of fixation of C4/5 subluxation.

the cervical cord than elsewhere in one study in dogs and meningioma in the atlanto-axial region appears to be particularly common (Fingerroth et al. 1987). Surgical treatment of intradural/extramedullary types of tumour is more feasible in any case but there also appears to be a greater potential for radical treatment of extradural tumours in the cervical region than elsewhere in the spine, as it is possible to resect an entire vertebral body and stabilize the area with relative ease. The ventral approach to the cervical spine is relatively straightforward and, following the removal of a vertebral body, incorporation of either graft bone (autogenous or autologous) or bone cement can be used to bridge the space. Problems still arise owing to the types of tumour which are commonly involved, i.e. extradural tumours are frequently malignant and so adjunctive treatment would still be required.

A recent report described a laminotomy approach for removal of a meningioma in the atlanto-axial region (Fingerroth and Smeak, 1989). A routine dorsal approach

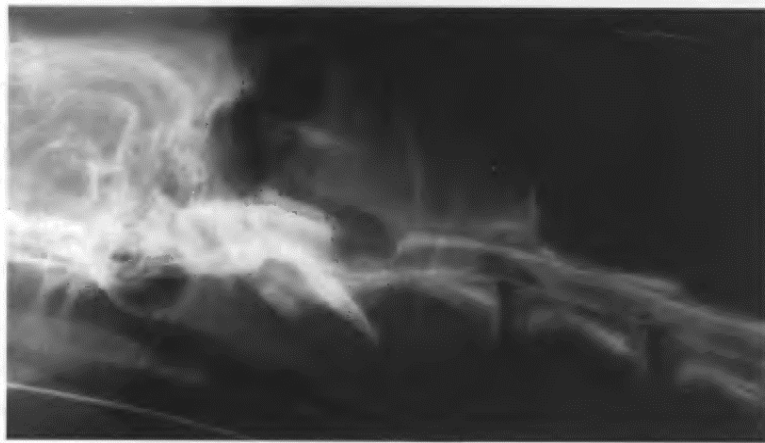

Figure 11.12 Lateral radiograph of meningioma at C1/2.

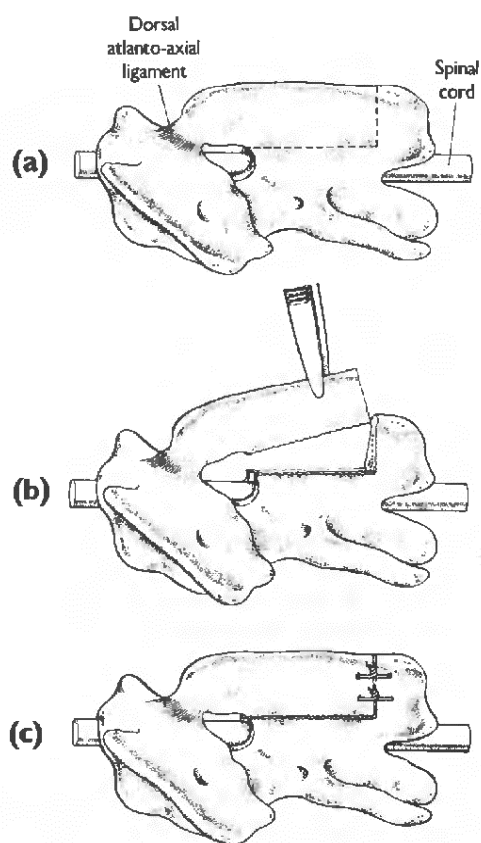


Figure 11.13 Laminotomy approach to removal of lesion within C1/2 region. Bone cuts allow cranially directed hinging of the lamina of the axis and subsequent secure fixation with wire.

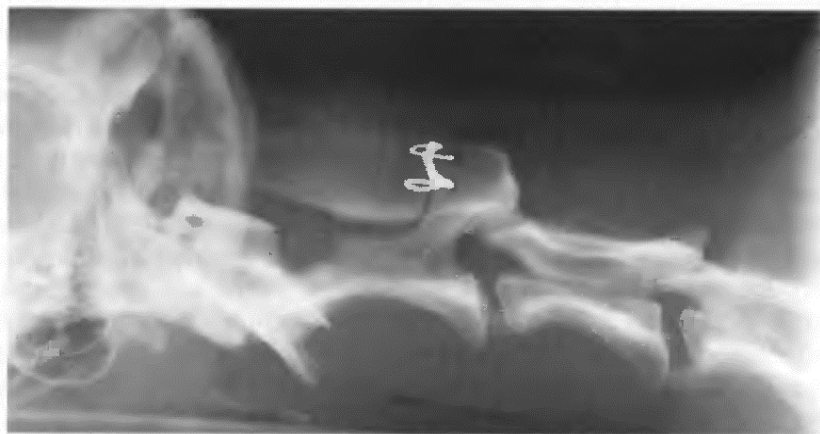

Figure 11.14 Postoperative lateral radiograph of laminotomy.

to the axis and atlas was made. Narrow bone incisions were made in the dorsal pedicles of the axis and joined together dorsally in the caudal part of the lamina of the axis. The loosened portion of the lamina was elevated dorsally and cranially to expose the spinal cord (Figures 11.12–11.14). Fixation of the laminotomy incision was by means of tension band wires in the spinous process of the axis. Thus, removal of the tumour was accomplished without compromising the stability of the vertebral column. This approach is only possible because of the large mass of bone with strong ligamentous attachments in this region.

Associated reading

General

- Gilmore D.R. (1983) Cervical pain in small animals: differential diagnosis. *Comp. Cont. Ed. Pract. Vet.* **5**, 953.
- Raw M-E. (1987) The differential diagnosis of cervical pain in the dog. *Vet. Ann.* **27**, 312.
- Piermattei D.L. (1993) Section III The Vertebral Column In: *An Atlas of Surgical Approaches to Bones and Joints of the dog and cat*, 3rd edn. Philadelphia, W.B. Saunders, p. 45.

Intervertebral disc disease

- Clark D.M. (1986) An analysis of intraoperative and early postoperative mortality associated with cervical spinal decompressive surgery in the dog. *J. Am. Anim. Hosp. Assoc.* **22**, 739.
- Denny H.R. (1978) The surgical treatment of cervical disc protrusion in the dog: a review of 40 cases. *J. Small Anim. Pract.* **19**, 251.
- Felts J.F., Prata R.G. (1983) Cervical disk disease in the dog: intraforaminal and lateral extrusions. *J. Am. Anim. Hosp. Assoc.* **19**, 755.
- Fry T.R., Johnson A.L., Hungerford L., Toombs J. (1991) Surgical treatment of cervical disc herniations in ambulatory dogs. *Prog. Vet. Neurol.* **2**, 165.
- Gilpin G.N. (1976). Evaluation of three techniques of ventral decompression of the cervical spinal cord in the dog. *J. Am. Vet. Med. Assoc.* **168**, 325.
- Goring R.L., Beale B.S., Faulkner R.F. (1991) The inverted cone decompression technique: a surgical treatment for cervical vertebral instability 'wobbler syndrome' in dobermann pinschers. Part 1. *J. Am. Anim. Hosp. Assoc.* 1991; **27**, 403.
- Heavner J.E. (1971) Intervertebral disc syndrome in the cat. *J. Am. Vet. Med. Assoc.* **159**, 425.
- Lipsitz D., Bailey C.S. (1992) Lateral approach for cervical spinal cord decompression. *Prog. Vet. Neurol* **3**: 39.
- Seim H.B., Prata R.G. (1982) Ventral decompression for the treatment of cervical disk disease in the dog: a review of 54 cases. *J. Am. Anim. Hosp. Assoc.* **18**, 233.
- Swaim S.F. (1974) Ventral decompression of the cervical spinal cord in the dog. *J. Am. Vet. Med. Assoc.* 1974; **164**, 491.
- Swaim S.F. (1982) Clinical observations and client evaluation of ventral decompression for cervical intervertebral disk protrusion. *J. Am. Vet. Med. Assoc.* **181**, 259.

- Tomlinson J. (1985) Tetraparesis following cervical disk fenestration in two dogs. *J. Am. Vet. Med. Assoc.* **187**, 76.
- Toombs J.P. (1992) Cervical intervertebral disk disease in dogs. *Comp. Cont. Ed. Pract. Vet.* 1992; **14**, 1477.
- Waters D.J. (1989) Non ambulatory tetraparesis secondary to cervical disk disease in the dog. *J. Am. Anim. Hosp. Assoc.* **25**, 647.

Atlanto-axial subluxation

- Chambers J.N., Betts C.W., Oliver J.E. (1977) The use of non-metallic suture material for stabilisation of atlantoaxial subluxation. *J. Am. Anim. Hosp.* **13**, 602.
- DeCamp C.E., Schirmer R.G., Stickle R.L. (1991) Traumatic atlanto occipital subluxation in a dog. *J. Am. Anim. Hosp. Assoc.* **27**, 415.
- Denny H.R., Gibbs C., Waterman A. (1988) Atlantoaxial subluxation in the dog: a review of 30 cases and an evaluation of treatment by lag screw fixation. *J. Small Anim. Pract.* **29**, 37.
- Gilmore D.R. (1984) Nonsurgical management of four cases of atlantoaxial subluxation in the dog. *J. Am. Anim. Hosp. Assoc.* **20**, 93.
- LeCouteur R.A., McKeown D., Johnson J., Eger C.E. (1980) Stabilization of atlanto-axial subluxation in the dog, using the nuchal ligament. *J. Am. Vet. Med. Assoc.* **177**, 1011.
- Oliver J.E., Lewis R.E. (1973) Lesions of the atlas and axis in dogs. *J. Am. Anim. Hosp. Assoc.* **9**, 304.
- Sorjonen D.C., Shires P.K. (1981) Atlantoaxial instability: a ventral surgical technique for decompression, fixation and fusion. *Vet. Surg.* **1**, 22.
- Stead, A.C., Anderson A.A., Coughlan A. (1993) Bone plating to stabilise atlanto-axial subluxation in four dogs. *J. Small Anim. Pract.* **34**, 462.
- Swaim S.F., Greene C.E. (1975) Odontoidectomy in a dog. *J. Am. Anim. Hosp. Assoc.* **11**, 663.
- Thomas W.B., Sorjonen D.C., Simpson S.T. (1991) Surgical management of atlantoaxial subluxation in 23 dogs. *Vet. Surg.* **20**, 409.

Fractures and luxations

- Basinger R.R., Bjorling D.E., Chambers J.N. (1986) Cervical spinal luxation in two dogs with entrapment of the cranial articular process of C6 over the caudal articular process of C5. *J. Am. Vet. Med. Assoc.* **188**, 865.
- Blass C.E., Waldron D.R., van Ee R.T. (1988) Cervical stabilisation in three dogs using Steinman pins and methylmethacrylate. *J. Am. Anim. Hosp. Assoc.* **24**, 61.
- Denny H.R. (1983) Fractures of the cervical vertebrae in the dog. *Vet. Ann.* **23**, 236.
- Stone E.A., Betts C.W., Chambers J.N. (1979) Cervical fractures in the dog: a literature and case review. *J. Am. Anim. Hosp. Assoc.* **15**, 463.
- Swaim S.F. (1975) Evaluation of four techniques of cervical spinal fixation in dogs. *J. Am. Vet. Med. Assoc.* **166**, 1080.

Neoplasia

- Gilmore D.G. (1983) Neoplasia of the cervical spinal cord and vertebrae in the dog. *J. Am. Anim. Hosp. Assoc.* **19**, 1009.
- Fingeroth J.M., Prata R.G., Patnaik A.K. (1987) Spinal meningiomas in dogs: 13 cases. *J. Am. Vet. Med. Assoc.* **191**, 720.
- Fingeroth J.M., Smeak D.D. (1989) Laminotomy of the axis for surgical access to the cervical spinal cord. *Vet. Surg.* **18**, 123.
- Neer T.M., Kreeger J.M. (1987) Cervical spinal cord astrocytoma in a dog. *J. Am. Vet. Med. Assoc.* **191**, 84.

CHAPTER 12

The 'Wobbler' Syndrome

Contents

<i>Introduction</i>	169
<i>Diagnosis</i>	171
<i>Differential diagnosis</i>	176
<i>Treatment</i>	176
<i>Prognosis</i>	183
<i>Associated reading</i>	184

Introduction

The term 'wobbler' has been applied to the group of dogs which share a set of symptoms consisting of varying degrees of tetraparesis and ataxia associated with anomalous cervical vertebral development and/or degenerative disease of the caudal cervical region of the vertebral column. The name is somewhat controversial and several alternatives have been proposed, among which caudal cervical spondylopathy, cervical spondylomyelopathy and cervical spinal instability are the best known alternatives. The term 'wobbler' is preferred here as a convenient shorthand and because of the tradition of the use of this name in the UK. There is also the advantage that the name is descriptive of the gait of the dog and is not specific regarding the exact aetiology of the lesion in the spine.

The wobbler syndrome is thought to be multifactorial in aetiology, with evidence for genetic (breed susceptibility), conformational and dietary factors. In experiments with overnutrition of great Dane dogs there was development of many of the abnormalities observed in naturally occurring wobblers in this breed.

Two basic categories of affected dogs are recognized:

- (1) Immature dogs which have stenosis of the bony part of the vertebral canal.
- (2) Middle-aged or older dogs which have degenerative disease of the cervical discs (and other ligaments of the vertebral column) with consequent acquired compression of the cervical spinal cord. This compression may be dynamic or static.

Some individual dogs do not easily fit into either category.

Immature wobbler dogs

In the immature dogs group, great Danes and Dobermann pinschers are the most frequently represented breeds; however, many other breeds have been reported to be affected, among them Basset hounds, Irish wolfhounds, Rottweilers and

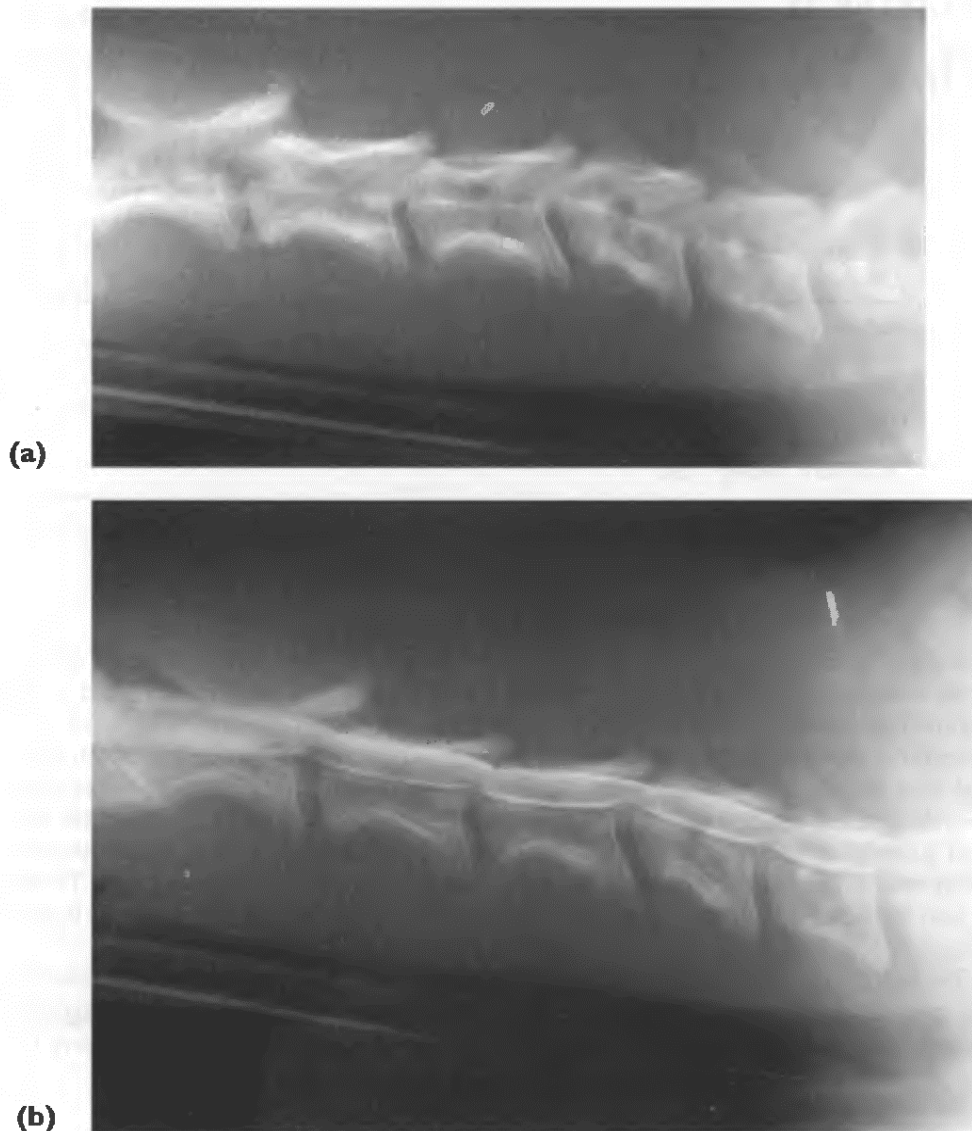


Figure 12.1 (a) Lateral plain and (b) myelographic views of severe cervical vertebral canal stenosis in an immature Doberman pinscher.

Rhodesian ridgebacks. Affected puppies usually first exhibit symptoms at between 5 and 11 months of age. In this group, the lesion is stenosis of the cervical vertebral canal, which may occur at one or many levels; the main site of involvement varies with the breed. It is not uncommon for the entire cervical spine to be affected to a greater or lesser extent (Figure 12.1). The stenosis may be lateral, or ventrodorsal, or occasionally a combination of both, which produces a circumferential compression of the cord. Lateral compression is especially common in the great Dane and can be associated with malformation of the vertebral facet joints.




Figure 12.2 Lateral myelogram of type II disc at C6 from a mature Doberman exhibited typical symptoms of the wobbler syndrome.

Middle-aged wobblers

In the older dogs group, the most common lesion is protrusion of a type II degenerated disc, although affected dogs will also frequently have concurrent stenosis of the bony part of the vertebral canal. This category of wobbler is especially common in middle-aged Dobermanns (Figure 12.2).

Compression of the spinal cord in middle-aged wobbler dogs may be at one or many sites within the cervical spine, most commonly at the C6/C7 disc in the Doberman. On myelographic studies it can often be demonstrated that the ventral compression of the spinal cord caused by the type II disc protrusion can be alleviated by ventroflexion of the neck and exacerbated by dorsiflexion (extension). There is thus a dynamic component to the spinal cord compression. Alleviation of the cord compression can also be obtained by applying linear traction along the cervical spine. This feature has been explained in detail by Seim and Withrow (1982) and has been used as the basis for many of the modes of surgical therapy for the condition (Figure 12.3).

Middle-aged wobbler dogs can also suffer spinal cord compression as a result of hypertrophy of the ligamentum flavum or, rarely, as a result of subluxation of an intervertebral joint.

Diagnosis

Wobbler dogs can present with a wide range of possible symptoms, ranging from cervical pain to tetraplegia. The most common signs include an ataxic pelvic limb gait with long strides, often combined with shortened (choppy) thoracic limb strides. Head carriage is often low. Results of neurological examination are variable but conscious proprioceptive responses are usually depressed in the pelvic limbs; local reflexes in all four legs are intact, with frequent hyperreflexia and crossed extensor responses in the pelvic limbs. The degree of thoracic limb involvement is variable and may sometimes be difficult to detect. Thoracic limb

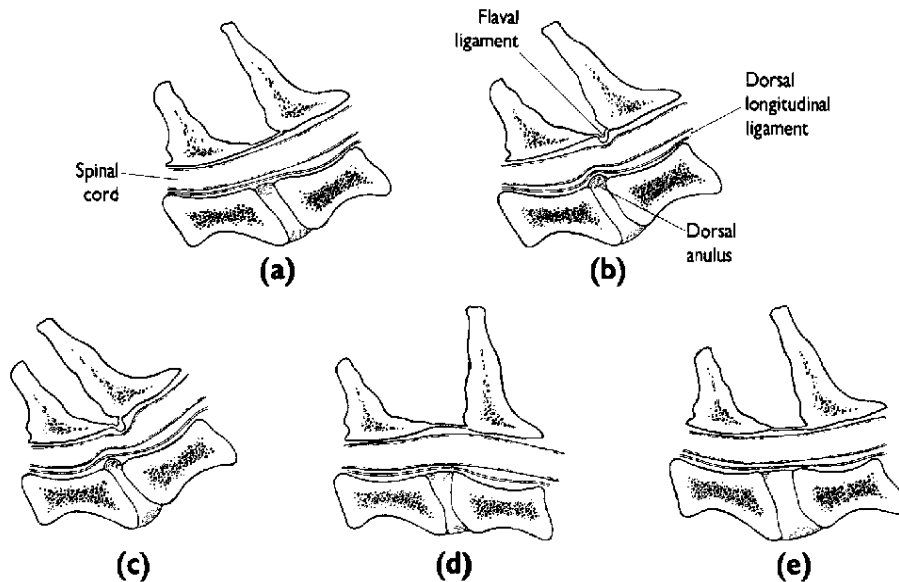


Figure 12.3 Variation in spinal cord compression associated with changes in neck position in disc-associated wobbler syndrome: (a) normal C6/7 region; (b) wobbler in 'neutral' position – compression by flaval ligament and intervertebral disc; (c) wobbler in extended (dorsiflexed) position – exacerbates compression; (d) wobbler in flexed position – alleviates compression; (e) wobbler after application of linear traction to cervical vertebral column – alleviates compression.

involvement is often made more apparent during wheelbarrowing or hopping testing, especially if the animal is blindfolded or if the neck is held in extension. Partial collapse or stumbling frequently occurs, thereby providing evidence of thoracic limb paresis and ataxia.

Examination of the thoracic limbs will often suggest upper motor neurone involvement (i.e. increase in extensor muscle tone and local reflexes are intact), although the lesion is located caudally in the cervical spine. It is thought that loss of flexor muscle tone occurs, owing to interference with the grey matter of the cervical intumescence which supplies these muscles. Frequently there is wasting of the scapular muscles, with prominence of the scapular spine and affected dogs will often stand with the shoulder in partial flexion, suggesting weakness of the shoulder extensors.

Although dogs affected by the wobbler syndrome will usually develop symptoms over a long period, occasional dogs will present with acute tetraparesis. In these cases it is suggested that an episode of hyperextension has occurred which has caused spinal cord concussion. Myelography of these cases will reveal a swollen spinal cord and sometimes only minimal evidence of the typical soft tissue changes associated with the wobbler condition.

Many wobbler dogs show no evidence of spinal pain but occasional cases do so. These dogs are often minimally ataxic or paretic but carry the head very low. Pain is often spasmodic and can be associated with movement of the head in any direction, particularly in extension (dorsiflexion). Painful episodes are often accompanied by

elevation of one of the forepaws from the floor. This root signalment is indicative of compression of one of the spinal nerve roots of the cervical intumescence.

Radiological diagnosis

In susceptible breeds of particular age groups, the diagnosis of wobbler syndrome may be strongly suspected on initial clinical examination. Plain radiographs will often reveal abnormalities that are strongly suggestive of the wobbler syndrome, such as new bone formation, degenerative joint disease affecting the synovial joints, apparent malalignment of adjacent vertebrae, or apparent vertebral canal stenosis. Areas of the cervical vertebral column where there is apparent vertebral malalignment must be interpreted with caution; it is common for such sites not to be the region of significant spinal cord compression on myelographic studies. Lesions visible on plain radiographs include: stenosis, malarticulation, proliferation of bone around synovial joints, spondylosis, narrowed disc space, and malformed vertebrae (Figure 12.4).

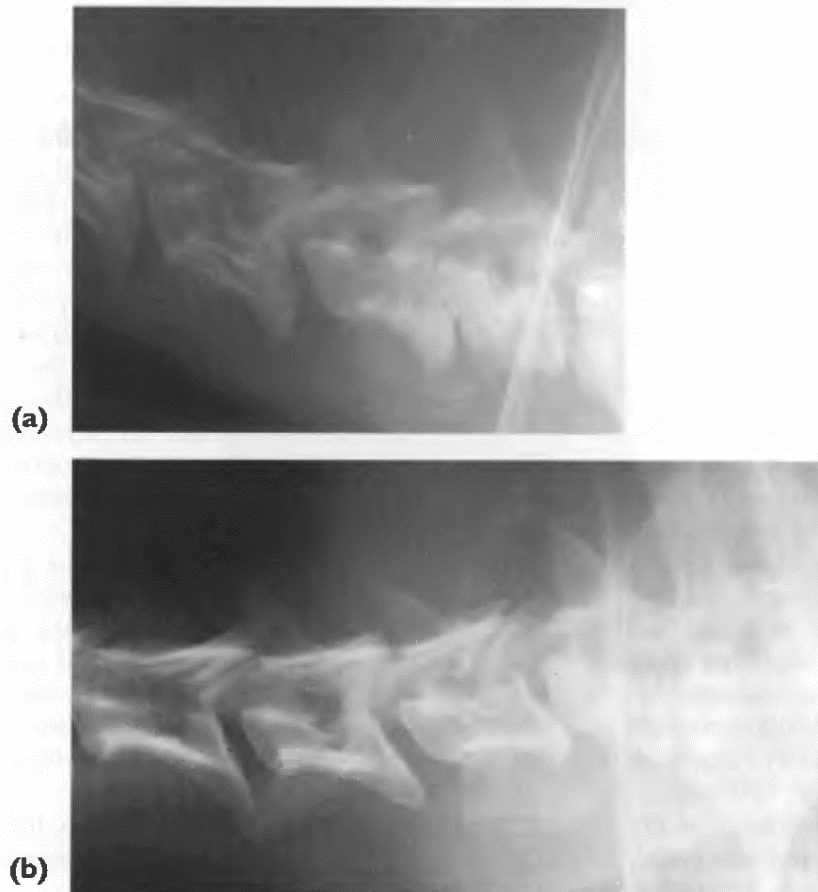


Figure 12.4 (a) Lateral radiograph of wobbler dog; typical findings include narrowed disc space, spondylosis, vertebral canal stenosis. (b) Lateral radiograph of wobbler dog; severe vertebral body tipping and abnormal diarthrodial articulation.

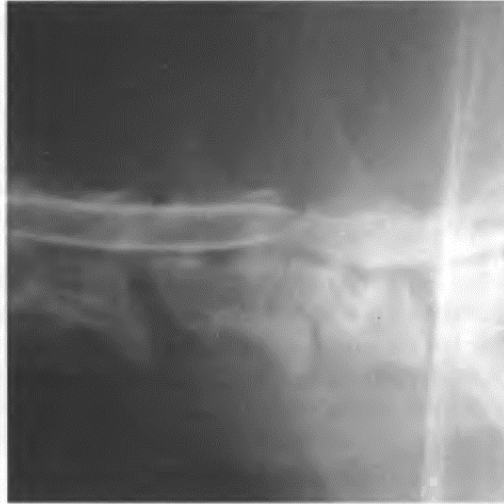


Figure 12.5 Myelogram of wobbler dog demonstrating cord atrophy – contrast has flowed well through area of severe compression.

Myelography is essential in order to make a definite diagnosis. The other reason for carrying out myelography is to locate accurately the site and type of compression (i.e. at what location of the circumference of the cord), to discover whether a dynamic compression exists and whether there are any secondary sites of cord compression. Routinely, cervical myelography is the most appropriate, although problems may be encountered in properly outlining the cervical spinal cord throughout its length in all animals. In some dogs in which the contrast agent flows rapidly towards the tail, it can be helpful to re-position it so that the area of interest is at the lowest point; this is easily achieved by raising the lumbar region while keeping the table positioned with the dog's head high. On myelographic views, it may be possible tentatively to suggest whether there is cord atrophy; i.e. if the contrast easily passes an area of severe compression, and the cord appears thin, this would suggest that there is a loss of cord substance (Figure 12.5).

Several views of the cervical spine should be obtained with the contrast in place; neutral lateral, ventrodorsal, flexed lateral and lateral with the cervical spine subjected to linear traction (Figures 12.6 and 12.7). Some authors have recommended obtaining an extended (dorsiflexed) lateral view. However cord compression is exacerbated in this position, and neurological deterioration has been observed following radiography in this position and so it is best avoided. In the vast majority of cases the detection of a dynamic lesion can be made without this view being obtained.

Lesions visible on myelography include: disc extrusion or protrusion, ligamentum flavum compression of the cord, lateral compression, and alleviation of compression during linear traction or flexion (i.e. dynamic lesion).

Myelographic studies will usually clearly demonstrate lesions typical of the wobbler syndrome. Furthermore, it should be possible to define the exact subtype of the condition in each individual animal. The compression can be categorized as:

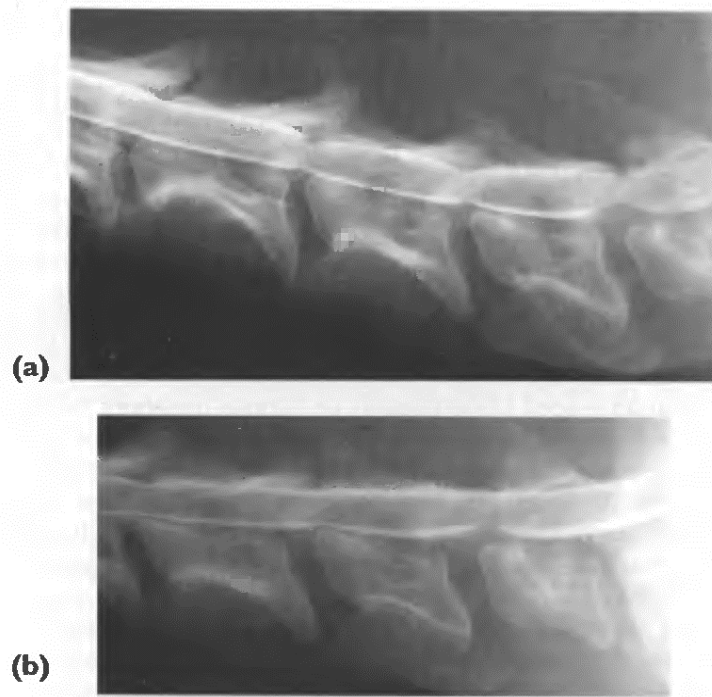


Figure 12.6 (a) Lateral myelogram of wobbler in 'neutral' position. (b) Lateral myelogram of same patient after application of linear traction.



Figure 12.7 Ventrodorsal myelogram of great Dane wobbler dog illustrating lateral compression of the spinal cord at C4/5.

multilevel versus single level, dorsal versus ventral versus circumferential, or static versus dynamic.

It is important that each case be assigned a definite subtype because therapy should be aimed at correcting the abnormality in that individual case, rather than treating every case the same way – the treatment should be tailored to the patient.

Differential diagnosis

Many other conditions can be confused with the wobbler syndrome – the other diseases depend on the type of symptoms exhibited by each dog. For instance, dogs exhibiting generalized weakness may be suffering from cardiomyopathy (which is also common in middle-aged Dobermanns), or various metabolic conditions. Dogs exhibiting cervical pain and tetraparesis or paraparesis could have type I intervertebral disc disease, spinal tumour or various inflammatory conditions. In general, the most important differential diagnosis for the wobbler syndrome in middle-aged dogs is neoplasia. In young dogs the most likely differential diagnoses would include congenital anomalies of the spinal cord and infectious agents.

Treatment

Dogs affected with the wobbler syndrome should be considered potential candidates for surgical treatment. Some animals will respond satisfactorily to medical therapy such as corticosteroids and can be maintained for long periods of time on this type of medication. However, studies have shown that most dogs receiving this type of treatment will slowly deteriorate and, ultimately, most cases will become refractory to medical treatment within 1 year of initiation of such therapy. The prognosis following surgical therapy is worse if the condition has been present for a long period. Some cases when presented very early in the course of the disease may need only a short period of steroid therapy to be restored to a 'normal' state. Some aged animals will also be suitable candidates for medical therapy.

Surgery is therefore the preferred means of therapy of wobbler dogs. The exact type of surgery must be determined by the exact nature of the lesion or lesions in each case. The surgery will be considered by type of lesion.

Single ventral lesion

This is the most common subtype in the middle-aged Dobermann. Cord compression is usually caused by a type II disc protrusion but vertebral canal stenosis is usually found concurrently. In most cases, vertebral canal stenosis is assumed to be unassociated with symptoms prior to the development of the disc lesion (which is 'the straw that breaks the camel's back'). Treatment of the single ventral lesion has been carried out by several methods.

VENTRAL FENESTRATION AND LAG SCREW FIXATION OF ADJACENT VERTEBRAL BODIES

This technique consists of routine fenestration of a series of cervical discs, via a ventral approach, followed by fixation of adjacent vertebral bodies by means of a ventral lag screw directed caudally through the fenestrated space. Cancellous bone graft obtained from the humeral head is applied to the fenestrated space.

This technique was originally devised in the 1970s and although some good results have been reported, it must now be considered to have been superseded by other techniques. From the understanding of the condition as it stands at present, this technique must be considered potentially hazardous; fenestration causes 'redundancy' of the dorsal part of the anulus, allowing it to protrude further into the vertebral canal; lag screw fixation across the space is likely to exacerbate this effect. Fenestration alone has been shown to be an inadequate treatment.

VENTRAL SLOT

This technique has been in use for many years for the treatment of wobblers. The main controversy regarding this technique has revolved around whether there is a need for stabilization of the vertebrae in wobbler dogs. Some authors consider 'instability' to be an important feature of the syndrome; ventral slotting can increase instability in the spine (temporarily at least) and therefore possibly worsen the condition. Others have questioned whether instability actually exists in this condition and certainly it is difficult objectively to demonstrate an instability. Demonstrable instability can also be construed to be a result of type II disc lesions rather than the initiator of such degenerative processes.

A further problem encountered with simply slotting the offending space is the difficulty in removing the protruded type II disc which is stringy and difficult to grasp. This problem has been addressed recently by the introduction of the 'inverted cone decompression technique' which is a modification of the standard slotting technique (Figure 12.8). This technique has greatly enhanced the surgeon's ability to remove the protruded disc material from the vertebral canal. The modification is that the size of the ventral part of the slot is kept to a minimum, while further dorsally the slot is expanded, particularly laterally. The dorsal anulus is left intact while the neighbouring dorsal cortex is burred to a thin shell. The dorsal anulus is then grasped by fine (Lempert) rongeurs and torn out in a ventral direction. Remnants can be retrieved from the vertebral canal by means of fine hooked instruments and then removed by rongeur. The same procedure is used to excise the longitudinal ligament. The dorsal cortex is removed only when no further anulus or longitudinal ligament can be grasped and excised. This approach enables the surgeon more completely to decompress the spinal cord, especially laterally, with a minimum risk of haemorrhage until the final stages.

The last problem which can be associated with simple slotting of the affected space is that collapse of the disc space, which will occur postoperatively, will in some cases cause compression of the nerve root as it exits through the intervertebral foramen. This problem cannot be easily dealt with, although complete lateral excision of protruded disc material, as occurs during the inverted cone technique renders nerve entrapment less likely. If an animal already exhibits narrowing of the

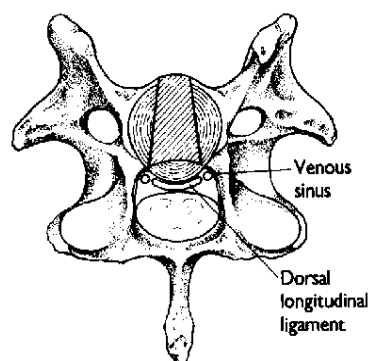


Figure 12.8 Cross-section of inverted cone slot.

intervertebral space, then the complication may be considered less likely to occur. A further precaution is to avoid simple slotting in patients in which nerve root pain appears to be a major part of the presenting symptoms.

LINEAR TRACTION AND STABILIZATION/FUSION

In many wobblers, dynamic myelography will demonstrate that the cord compression can be significantly reduced by application of linear traction. For this category of wobbler, it has therefore been suggested that the affected part of the cervical vertebral column be stabilized in a stretched position; this forms the theoretical basis for many surgical techniques.

A variety of techniques have been recommended to fix the abnormal intervertebral space in the traction position. Fixation has been carried out by means of an interbody screw, pins and bone cement, or screws and bone cement, Lubra plate or Harrington rod instrumentation. Spacing of the relevant vertebral bodies has been carried out by introduction of cortical bone graft, metal spacer, or by relying on the fixation technique alone. Numerous complications have been recorded in relation to use of these fixation techniques, among which failure to maintain traction owing to implant failure, or bone resorption adjacent to the implant are the commonest problems. The potential for direct cord injury exists in any technique in which the implant is directed towards the cord.

Ventral fusion techniques are carried out via a routine ventral approach to the cervical vertebral column. Following a partial ventral slot (when using methylmethacrylate fixation) Steinmann pins of appropriate diameter (usually 2 mm in Dobermanns) are driven into the vertebral bodies at an angle of 35° to the perpendicular (although not essential, it is helpful to have a sterile goniometer to guide the surgeon). This angle is chosen to ensure that the spinal cord, nerve roots and vertebral arteries are not impaled. The pins are driven until a loss of resistance is felt as they penetrate the lamina. The pins are cut off with about 2 cm protruding from the vertebral surface and are coated in a ball of PMMA. If traction is desired it can be applied most conveniently by a non-scrubbed assistant pulling on the dog's head. Traction can also be applied by placing modified Gelpi retractors into neighbouring disc spaces but it has been suggested that this is associated with




Figure 12.9 Postoperative radiograph of wobbler treated by pins and PMMA technique of linear distraction.

increased risk of complications (see later discussion). Usually 3–5 mm of traction is desirable. Traction must be maintained until the PMMA has properly cured (Figure 12.9).

Lubra plates are applied to the ventral surface of the vertebral bodies with the screws diverging away from the spinal cord. The screw length is such that only one cortex is gripped per screw.

Vertebral body screws are applied by drilling a pilot hole across the intervertebral space (cranial to caudal). It is helpful for the cervical spine to be in slight dorsiflexion to enable optimal placement. Care must be taken not to penetrate the thin dorsal cortex of the caudal vertebral body (which lies immediately ventral to the spinal cord). A lag screw, commonly only partially threaded, is used to fix the vertebrae in position. It is important to start the cranial screw hole at the furthest possible point cranially, as fracture of the ventral prominence of the vertebral body is a possible complication of this technique, and will lead to loss of fixation. Prior to introduction of the screw, the ventral anulus and the nucleus pulposus are excised. While traction is applied to the affected interspace and maintained by use of a special instrument, the spacer (usually a metal washer) is placed into the intervertebral space. The interbody screw is then tightened into position through the vertebral bone and the centre of the washer (Figure 12.10).

A question which must arise when traction/fixation techniques are utilized is whether the traction that is placed on the vertebrae can be sustained by the skeletal tissues involved. Substantial linear traction is required to alleviate compression of the cord in most of these lesions. During the radiographic procedure it is frequently necessary to 'hang' the dog on the tilted table, using the dog's own weight to

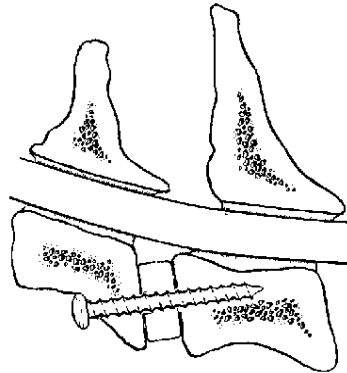


Figure 12.10 Drawing of postoperative appearance of screw and washer distraction technique.

stretch the spine sufficiently. It must be questioned whether the vertebral end plates are capable of sustaining such traction without resorption of bone and consequent loss of traction. Bone resorption is one possible mode of failure of the traction techniques and is most apparent with the intervertebral body techniques using metal discs or cortical bone implants, which can be observed to collapse into the endplates with time. This loss of traction is not necessarily associated with recurrence of clinical signs, provided adequate new bone formation has occurred to stabilize the space. It has been suggested that the intervertebral disc with no forces acting through it will atrophy with time and thereby alleviation of compression will be maintained.

The need to treat a 'dynamic' compression caused by type II disc protrusion by means of traction must be open to question. The structure responsible for spinal cord compression is the protruded disc and if it can be adequately removed (via a ventral slot) then there is no need for fixation or traction to eliminate compression of the cord. It may be possible therefore, for both static and dynamic compression of the cord resulting from type II disc protrusions to be treated by ventral slotting.

Single dorsal lesion

This is most commonly either due to stenosis at a single site because of malformation of the pedicles and lamina, or because of compression by the ligamentum flavum. The latter is often seen as a dynamic compressive lesion on myelography. A dorsal approach and resection of the offending lesion is the most appropriate technique, together with stabilization if this is thought appropriate. The laminae of the affected vertebrae is removed if the bony canal is stenotic, which allows the spinal cord greater space.

Multiple dorsal lesions

This is usually caused by multilevel stenosis of the bony vertebral canal and so can be seen in young animals. Older animals can be affected if there is hypertrophy of

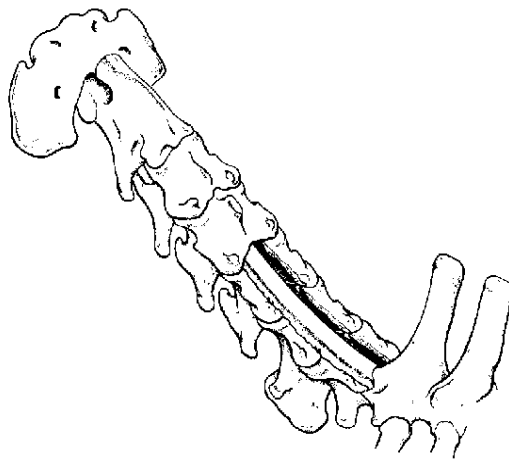


Figure 12.11 Drawing of completed continuous dorsal laminectomy. The bone should be wide enough to be able to see the venous sinuses.

the ligamentum flavum at multiple sites. This condition is best treated by multilevel decompressive dorsal laminectomy (Figure 12.11). Continuous dorsal laminectomy (CDL) has been used to decompress the spinal cord over a long portion of the cervical region, and typically extends from C4 to T1. CDL is carried out via a routine dorsal approach to the caudal cervical spine. Following exposure of the laminae of the relevant vertebrae, the bone is removed. This is most conveniently carried out by use of Kerrison rongeurs, but use of an air drill is also possible.

Concurrent durotomy has been recommended but this has rather uncertain benefits as a method of treatment for most compressive lesions of the spinal cord and is potentially injurious. Stabilization may or may not be recommended, depending on the author.

An alternative approach, laminoplasty, has been proposed for such wobbler

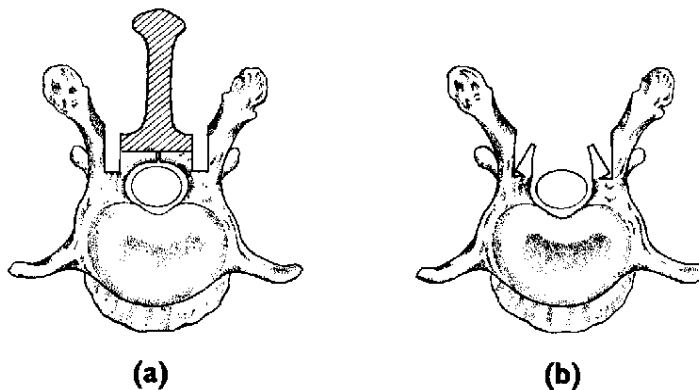


Figure 12.12 Cross-sectional view of 'French window' laminoplasty showing extent of bone cuts and removal. Note enlargement of vertebral canal depth attained by elevation of laminal flaps.

dogs; the results of this treatment in large numbers of affected dogs have not been reported (Figure 12.12).

The dorsal approach to the caudal cervical spine is time consuming, especially in large dogs. There is considerable epaxial musculature which must be divided in the midline and moderate haemorrhage can be expected. Dorsal laminectomy, especially when carried out at multiple sites, is also time consuming and laminoplasty is even more so. All dorsal procedures carry the risk of incurring substantial blood loss. In certain breeds, especially the Dobermann, there is a high incidence of blood clotting disorders. It is prudent to carry out coagulation studies such as buccal mucosa bleeding time, or measurement of von Willebrand factor in Dobermanns which are to undergo dorsal decompressive surgery. Intraoperative haemorrhage in dogs affected by von Willebrand's disease can be reduced by use of synthetic ADH (Desmopressin).

Multiple ventral lesions

When two disc lesions are present, the cutting of two ventral slots is probably the treatment of choice; however, some concern has been expressed that there can be a risk of vertebral collapse following ventral slot of two adjacent spaces. This risk is reduced if the inverted cone technique is utilized. A series of recent reports has recommended continuous dorsal laminectomy for treatment of multilevel ventral compression because good results have been achieved. Surgical stabilization was not carried out on these cases.

Treatment of painful wobblers

Occasional wobbler dogs are presented with symptoms of severe pain which may be intermittent in nature, with unpredictable episodes and may be associated with a root signalment, i.e. the dog will lift one forepaw from the ground while crying in pain. Frequently in these dogs little compression of the spinal cord can be observed on routine myelography, although the typical signs of the wobbler condition are seen radiographically (such as vertebral canal stenosis or spondylosis). Electrodiagnostic studies can be helpful in demonstrating that nerve root abnormalities are present. These dogs are suspected of having nerve root entrapment in the intervertebral foramen. This compression can be exacerbated by type II disc protrusions in a manner similar to nerve root entrapment which occurs in people with cervical spondylotic radiculopathy.

These cases would appear to be best treated by applying linear traction to the cervical spine and fixation of the vertebral bodies. These procedures have the effect of enlarging the intervertebral foramen thereby alleviating any impingement of bone on the nerve root. Ventral slotting may be capable of alleviating disc-associated nerve root compression if adequate excision of the protrusion is attained. The most important site from which disc must be removed is laterally, therefore the inverted cone technique is best suited. If adequate disc removal cannot be achieved, ventral slotting is liable to exacerbate nerve root compression because of collapse of the intervertebral space.



Figure 12.13 Postoperative view of screw fixation of diarthrodial joints at C6/7.

Miscellaneous surgical techniques

Successful treatment of some wobblers which would be difficult to treat by other techniques can be carried out by simply stabilizing the affected spinal segment (Figure 12.13). This can be achieved by screwing together the articular facets of adjacent vertebrae following a dorsal approach, plus bone grafting where appropriate, or the use of other fusion techniques described earlier – such as interbody screws.

Prognosis

The prognosis for wobbler dogs has been linked to severity at the time of presentation, duration of clinical signs and to some extent, the type of therapy offered. Of these factors the most important appears to be the duration of clinical signs, dogs which have long-standing neurological deficits have a far worse prognosis than dogs with similar but acute deficits. The reason for this difference in prognosis is that irreversible damage to the spinal cord may already have occurred in chronic cases, which can sometimes be seen during myelography as an atrophic cord. This appearance is seen to best advantage on CT myelographic studies and this technique may have a role to play in preoperative determination of prognosis. However, although the prognosis may be somewhat worse in these cases this should not be a discouragement to performing surgery but a guide to the owners of such dogs that, although prevention of deterioration and mild improvement may be expected, return to 100% normal function is not a realistic goal.

The neurological status at the time of presentation has some bearing on prognosis, obviously the more severe the deficit the worse the prognosis. However, the neurological status must also be interpreted in light of the duration of the symptoms. Many dogs presented with acute onset of non-ambulatory tetraparesis carry an excellent prognosis, whereas those dogs presented unable to walk following long-term deterioration should be given a poor prognosis.

There is some doubt about how significant the type of surgery carried out is in relation to recovery rate. Many different techniques have been applied and very

similar success rates are claimed for each (about 80–85%). However, there have been many studies in which different lesions have all been treated by the same method, rendering the results rather difficult to compare. It seems prudent that each case should be assessed as an individual and the lesions treated according to their site, size, number and severity, rather than diagnosing a case of wobbler syndrome and treating all cases by the same surgical technique. Using this method it may be possible to increase the success rate to approaching 100%, although a certain proportion of cases which have irreversible spinal cord injury will be unable to recover, regardless of the mode of therapy.

Following any type of surgery in which fusion of adjacent vertebrae occurs (this also includes ventral slotting) there is a potential risk of development of secondary lesions at an adjacent site. This effect has been termed the 'domino' effect and has also been observed in human patients following surgery of similar cervical conditions. The incidence of the domino effect has been reported variably but is up to 20% of cases in some studies. The cause of this effect is thought to be the 'activation' of subclinical sites of compression, or their appearance due to increased stress on neighbouring disc spaces following surgery which renders an intervertebral space rigid. This is a complication of most commonly used surgical techniques for treating wobblers (the exception is continuous dorsal laminectomy), including slotting, in which fusion of the vertebral bodies is expected to occur within about 3 months. The incidence of the domino effect has been highest in those dogs in which the technique of linear traction plus pins/methylmethacrylate fixation has been applied. The reason, according to critics of the technique, is that fenestration of the adjacent disc spaces is carried out to allow traction to be applied by Gelpi retractors during surgery. It certainly seems advisable to avoid this means of applying traction to the affected interspace and alternative methods, such as manual traction on the head of the dog during surgery, are therefore preferable. The domino effect may become apparent at variable times following surgery, i.e. months to years later and, indeed, second sites of compression may become evident in any case without prior surgical intervention.

Associated reading

- Bruecker K.A., Seim H.B., Blass C.E. (1989) Caudal cervical spondylomyelopathy: decompression by linear traction and stabilisation with Steinmann pins and polymethyl methacrylate. *J. Am. Anim. Hosp. Assoc.* **25**, 677.
- Bruecker K.A., Seim H.B., Withrow S.J. (1989). Clinical evaluation of three surgical methods for treatment of caudal cervical spondylomyelopathy of dogs. *Vet. Surg.* **18**, 197.
- Chambers J.N., Oliver J.E., Kornegay J.N., Malnati G.A. (1982) Ventral decompression for caudal cervical disc herniation in large and giant breed dogs. *J. Am. Vet. Med. Assoc.* **180**, 410.
- Chambers J.N., Oliver J.E., Bjorling D.E. (1986). Update on ventral decompression for caudal cervical disc herniation in dobermann pinschers. *J. Am. Anim. Hosp. Assoc.* **22**, 775.
- Denny H.R., Gibbs, C., Gaskell, C.J. (1977) Cervical spondylopathy in the dog. A review of thirty five cases. *J. Small Anim. Pract.* **8**, 117.

- Ellison G.W., Seim H.B., Clemmons R.M. (1988) Distracted cervical spinal fusion for management of caudal cervical spondylomyelopathy in large breed dogs. *J. Am. Vet. Med. Assoc.* **193**, 447.
- Gage E.D., Hoerlein B.F. (1973) Surgical repair of cervical subluxation and spondylolisthesis in the dog. *J. Am. Anim. Hosp. Assoc.* **9**, 385.
- Goring R.L., Beale, B.S., Faulkner R.F. (1991) The inverted cone decompression technique: a surgical treatment for cervical vertebral instability "wobbler syndrome" in doberman pinschers. Part 1. *J. Am. Anim. Hosp. Assoc.* **27**, 403.
- Hedhammer A., Wu F., Krook L., Schryver H.F., de La Hunta A., Whalen J.P., Kallfelz F.A., Nunez E.A., Hunz H.F., Sheffy B.E., Ryan G.D. (1974) Over nutrition and skeletal disease: an experimental study in growing great Dane dogs. *Corn. Vet. Suppl.* **64** (Suppl. 5.), 58.
- Jeffery N.D. (1993) The use of cervical laminoplasty as a treatment for cervical spinal stenosis in the dog. *Proc. Eur. Soc. Vet. Neurol.*, **10**.
- Jergens A.E., Turrentine M.A., Kraus K.H., Johnson G.S. (1987) Buccal mucosa bleeding times of healthy dogs and of dogs in various pathologic states, including thrombocytopenia, uremia and von Willebrand's disease. *Am. J. Vet. Res.* **48**, 1337.
- Kraus K.H., Turrentine M.A., Jergens A.E., Johnson G.S. (1989) Effect of desmopressin acetate on bleeding times and plasma von Willebrand factor in dobermann pinscher dogs with von Willebrand's disease. *Vet. Surg.* **18**, 103.
- Lewis D.G. (1989) Cervical spondylomyelopathy ("wobbler syndrome") in the dog: a study based on 224 cases. *J. Small Anim. Pract.* **30**, 657.
- Lincoln J.D., Pettit G.D. (1985) Evaluation of fenestration for treatment of degenerative disc disease in the caudal cervical region of large dogs. *Vet. Surg.* **14**, 240.
- Lyman R. (1989) Continuous dorsal laminectomy for the treatment of caudal cervical vertebral instability and malformation. *Proc. 13th Ann. Kal. Kan. Symp.* **13**.
- Lyman R. (1991) Continuous dorsal laminectomy is the procedure of choice. *Prog. Vet. Neurol.* **2**, 143.
- McKee W.M., Lavelle R.B., Mason T.A. (1989) Vertebral stabilisation for cervical spondylopathy using a screw and washer technique. *J. Small Anim. Pract.* **30**, 337.
- McKee W.M., Lavelle R.B., Richardson J.L., Mason T.A. (1990) Vertebral distraction-fusion for cervical spondylopathy using a screw and double washer technique. *J. Small Anim. Pract.* **31**, 22.
- Piermattei D.L. (1993) The Vertebral Column In: *An Atlas of Surgical Approaches to Bones and Joints of the Dog and Cat*, 3rd edn. Philadelphia, W.B. Saunders, p. 45.
- Read R.A., Robins G.M., Carlisle C.H. (1983) Caudal cervical spondylomyelopathy (wobbler syndrome) in the dog: a review of thirty cases. *J. Small Anim. Pract.* **24**, 605.
- Rendano V.T., Smith L.T. (1981) Cervical vertebral malformation-malarticulation (wobbler syndrome) - the value of the ventrodorsal view in defining lateral spinal cord compression in the dog. *J. Am. Anim. Hosp. Assoc.* **17**, 627.
- Seim H.B., Withrow S.J. (1982) Pathophysiology and diagnosis of caudal cervical spondylomyelopathy with emphasis on the dobermann pinscher. *J. Am. Anim. Hosp. Assoc.* **18**, 241.

- Sharp N.J.H., Wheeler S.J., Cofone M. (1992) Radiological evaluation of "wobbler" syndrome – caudal cervical spondylomyelopathy. *J. Small Anim. Pract.* **33**, 491.
- VanGundy T. (1989) Canine wobbler syndrome. Part 1. Pathophysiology and diagnosis. *Comp. Cont. Ed. Pract. Vet.* **11**, 144.
- VanGundy T. (1989) Canine wobbler syndrome. Part II. Treatment. *Comp. Cont. Ed. Pract. Vet.* **11**, 269.
- Walker T.L. (1990) Use of Harrington rods in caudal cervical spondylomyelopathy. In: Bojrab M.J. (ed.). *Current Techniques in Small Animal Surgery*, 3rd edn. Philadelphia, W.B. Saunders, p. 584.
- Wright J.A. (1977) A study of the radiographic anatomy of the cervical spine in the dog. *J. Small Animal Pract.* **18**, 341.

CHAPTER 13

Surgery of the Thoracolumbar Spine

Contents

Introduction 187

Decompressive surgery 188

Prophylactic techniques 194

Fractures and subluxations of the thoracolumbar segment 197

Other conditions of the thoracolumbar segment (T3-L3) 197

Neoplasia in the thoracolumbar segment 198

Associated reading 199

Introduction

Of all the abnormalities occurring in the thoracolumbar region of the canine vertebral column which may require surgical treatment, intervertebral disc disease is by far the most common. The incidence of disc disease in dogs is very high and has been reviewed in Chapter 7. The incidence of disc protrusion in cats is quite high in post mortem studies but cats rarely exhibit disc-associated clinical signs. In addition, disc protrusion in cats, as in dogs, can occur secondarily to other abnormalities of the vertebral column (Figure 13.1).

Because of the frequency of canine disc disease, most thoracolumbar surgery is concerned with relief of the effects of disc disease. Two types of surgery are employed in the thoracolumbar region for management of disc disease; either decompressive surgery (entailing removal of the offending material) or prophylactic surgery which aims to reduce the incidence of future disc-related clinical signs.

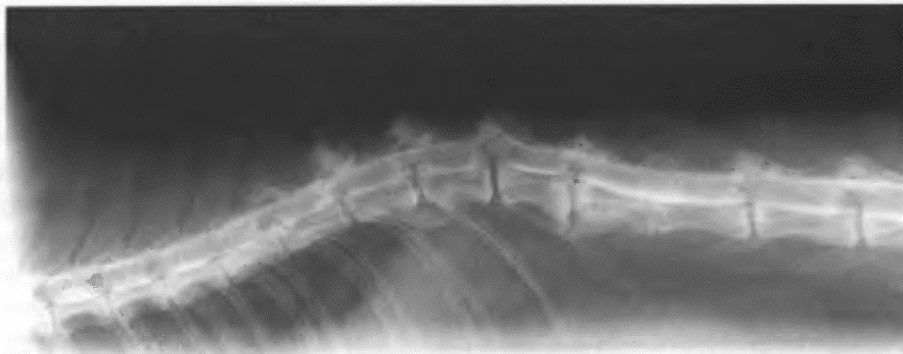


Figure 13.1 Myelogram of disc protrusion at T13/L1 in a cat presumed secondary to block vertebra at L2/3 and spondylosis at L1/2.

Decompressive surgery

There are two basic types of decompressive surgery for disc disease; dorsal laminectomy and hemilaminectomy. There are some modifications of each type that have been made through the years in order to improve the success rate and limit potential complications. The choice of operation in each individual case is determined partly from precise localization of the disc material and partly from personal preference of the surgeon. There is some tendency recently for hemilaminectomy (including the 'mini-hemilaminectomy') to be preferred over dorsal laminectomy.

It is important to stress that decompressive surgery for disc disease is synonymous with removal of the offending disc material. The removal of bone surrounding the spinal cord has no beneficial effect in reduction of cord compression. This has previously been stated more eloquently by Prata (1981), who has compared removal of the bone alone to 'making a hole in the roof of a house to let water out of the basement'. Whatever the means of surgical approach to the spinal cord, the removal of offending disc material is the aim. The results of treatment of large numbers of dogs, which have sustained cord injury as a result of acute disc extrusion, suggest that removal of the disc material is of great benefit in improving rate and extent of recovery and as a means of greatly reducing the pain associated with disc extrusion. Treatment of acute cord oedema may be by both surgical and medical means, as both approaches can have a role to play in promoting recovery.

Acute type I disc extrusion in the dog usually causes severe cord concussion in addition to the mass lesion which causes compression of the cord. The cord concussion and subsequent vascular events cannot be treated by conventional decompressive surgery – the removal of the extruded material will have no effect on this aspect of the cord injury. The purpose of surgery is to remove the disc material which is responsible for continued compression of the cord. In some cases, in which the extruded disc has a very small volume, the value of conventional decompressive surgery is probably negligible. The treatment of severe cord trauma, such as can occur as a result of acute disc extrusions of low volume (i.e. cord concussion), requires a different approach, because the small mass lesion itself is not the major cause of spinal cord dysfunction. In these cases, such surgery can be shown to be of no value if myelography fails to demonstrate a definable mass lesion. In other animals, the effect of the compressive mass will be a very important cause of continued spinal cord dysfunction and decompressive surgery will lead to rapid resolution of clinical signs. There is often a clear cut difference in the rapidity of onset of symptoms in the two groups of dogs; those with negligible mass lesion have usually suffered a peracute onset of paraparesis or paraplegia, whereas those in the other group are usually progressively affected over a period of several hours to several days.

(Dorsal) Laminectomy

This operation is carried out via a dorsal approach to the vertebral column (Figure 13.2). Following a midline skin incision and division of the subcutaneous fat, the dense dorsal lumbar fascia becomes visible. The fascia is incised on the midline and elevated from each side of the spinous processes. The epaxial musculature is

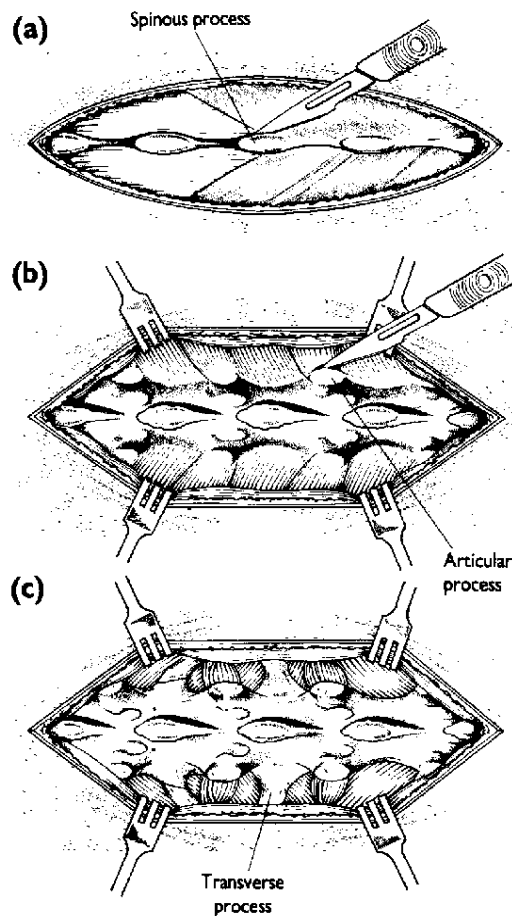


Figure 13.2 Dorsal approach to the thoracolumbar vertebral column. (a) Following incision and retraction of the skin and superficial fascia, the deep fascia is incised around the spinous processes and retracted. (b) The attachments of the multifidus muscle to the articular processes are incised allowing full exposure of the dorsal aspect of the laminae. (c) For hemilaminectomy and modifications, the exposure is continued laterally and the tendons of the longissimus muscle are severed close to their attachment to the accessory processes.

elevated from the spinous processes and laminae of the involved vertebrae. Dissection is carried out as close as possible to the periosteum in order to minimize haemorrhage. Arterial bleeders (branches of the intercostal or lumbar arteries) are often encountered as the tendons of the multifidus muscle are cut at their attachments to the mammillary processes of the articular processes. This haemorrhage is most conveniently arrested by use of diathermy. Muscle is retracted laterally to expose the pedicles just below the level of the synovial joints bilaterally. Removal of the spinous processes is usually best carried out by rongeurs. Removal of the laminae can be carried out by means of rongeurs or by high-speed air drill. Care must be taken when using rongeurs to ensure that the tips do not cause compression of the cord as each bite is taken from the lamina.

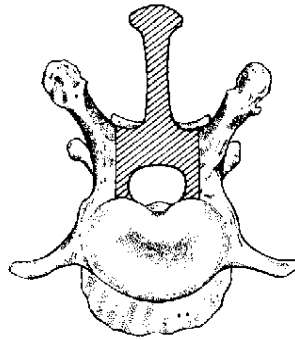


Figure 13.3 Transverse section of dorsal laminectomy; the shaded portion of bone is removed. The inner articular processes (those on the caudal aspect of each vertebra) are usually removed. Cranio-caudal extent depends on extent of lesion.

Several types of dorsal laminectomy have been described. Funkquist (1962) was one of the first veterinarians to describe the techniques for laminectomy in the dog. She investigated the best method of bone removal consistent with the required exposure of the spinal cord without incurring risk of instability or laminectomy membrane formation.

In the Funquist type A operation the pedicles are removed below the level of the dorsal dural surface; in the Funquist type B operation the pedicles are left intact above the spinal cord. It has been found that following type A surgery a 'laminectomy membrane' will form which is able to compress the spinal cord severely enough to cause recurrence of clinical signs; consequently, this form of laminectomy is not now carried out. The type B operation has been modified to include 'undercutting' of the medial aspect of the pedicles, allowing good access to the spinal cord and the lateral channels without removing the pedicles ventral to the dorsal aspect of the cord (Figure 13.3). Access to the lateral channels is important as this is the site of extruded disc material in most affected dogs. It has been suggested that tagging the dura with fine sutures in order to gently roll the spinal cord from side to side may be helpful in order to permit enhanced access to these lateral channels. It is sometimes also helpful to perform rhizotomy (i.e. section of the nerve roots) on one or both sides to allow greater manipulation of the cord. Further modifications of the technique include using saline 'slush' to wash around the cord in an effort to induce hypothermia of the cord and therefore reduce oedema associated with manipulation. In general, it is preferable that manipulations of the spinal cord be minimized or avoided altogether.

During closure following dorsal laminectomy it has been recommended that a fat graft be placed over the cord. The aim of this procedure is to reduce the formation of the laminectomy membrane. Some problems have been encountered with the use of fat grafts, such as swelling of the graft itself *in situ* (causing enhanced compression) and even migration. Not all spinal surgeons are in favour of fat grafts and some prefer the use of material such as Gelfoam. However, this material has been shown to cause increased deposition of fibrous tissue at operation sites. Both free and pedicle (i.e. with blood supply intact) fat grafts have been used for prophylaxis of laminectomy membrane formation but there is no clear advantage to pedicled

grafts experimentally and they are more difficult to collect. Some experimental work has demonstrated quite alarming postoperative cord compression in areas where fat grafts have been applied to laminectomy sites; however, the early swelling and compression of the cord was found to subside quickly. It seems advisable to use only thin portions of fat, bearing in mind the large amount of swelling that can occur with this graft material.

ADVANTAGES AND DISADVANTAGES OF THE DORSAL LAMINECTOMY VERSUS HEMILAMINECTOMY

Advantages:

- (1) Relatively little lateral dissection is required before removal of the lamina can be carried out, so approach is initially quicker, less traumatic and incurs less risk of haemorrhage.
- (2) Exposure of entire width of spinal cord permits true exploratory surgery. This may be an important feature if the diagnosis is uncertain before surgery, if the compressive lesion is thought to be situated primarily dorsal to the dural tube, or if extruded disc material could be situated on either or both sides of the cord.
- (3) Access to the dorsal aspect of the cord permits durotomy (for prognostic purposes) or pletomy or myelotomy (for decompressive purposes). These techniques are part of the surgical treatment options for dogs which have very severe cord swelling secondary to any acute trauma, including certain cases of disc extrusion.

Disadvantages:

- (1) Poor access to the ventral aspect of the cord. This is important, as although disc material may reach the lateral and even dorsal aspects of the cord, the main site of compression is usually ventral, because that is the direction from which the material originates. Extruded disc material is found ventrally most frequently in those dogs with relatively small diameter vertebral canals, such as the dachshund, in which type I disc extrusion is most commonly encountered. Although access to some parts of the vertebral floor is permitted if the cord is moved, this is a traumatic procedure and best avoided.
- (2) Adequate excision of type II disc protrusions is almost impossible via this approach.
- (3) Simultaneous disc fenestration, which is frequently carried out in dogs which have disc extrusions, necessitates further lateral dissection. Furthermore, the combination of dorsal laminectomy with fenestration is potentially a cause of instability in the vertebral column (there being disruption of at least two of the three-column structure of the vertebral column)
- (4) Time consuming – although the access through the soft tissue is quicker the access to spinal cord and nerve roots requires more bone removal, is more time consuming and potentially more traumatic to the cord.

Hemilaminectomy (and modifications)

Conventional hemilaminectomy involves the removal of the articular processes of adjacent vertebrae, together with parts of the pedicle, to expose the dorsolateral

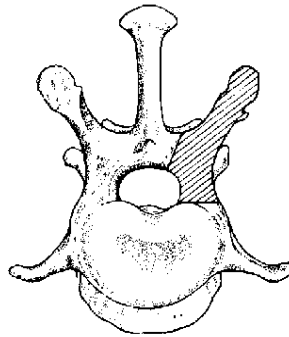


Figure 13.4 Transverse section of standard hemilaminectomy. Both articular processes at each intervertebral space are removed unilaterally.

aspect of the cord. The initial approach is usually dorsal, as for dorsal laminectomy, but dissection of the muscles is carried out unilaterally only. It is beneficial to leave some muscle attached to the spinous processes as this will preserve more of the blood supply to the epaxial muscles. Following dissection to the level of the synovial joint, the incision is continued laterally and ventrally, by elevating the muscle from the pedicle, thereby exposing the accessory process or rib. The tendons of insertion of the longissimus muscle become visible. These are cut a few millimeters from their attachments on the accessory process or rib; the radicular artery runs just ventral to these tendons and should be avoided. Haemorrhage arising from the radicular artery obscures the surgical field but can be arrested conveniently by use of diathermy (unipolar or preferably bipolar). Rongeurs are used to remove the articular processes of the vertebrae and further removal of bone is carried out by rongeur or air drill to expose the cord (Figure 13.4).

The main modification of this technique is the 'mini-hemilaminectomy' technique (also referred to as pediclectomy), in which only a small portion of the pedicle is removed, permitting access to only the ventral part of the vertebral canal (Figure 13.5). The articular processes and diarthrodial joints are left intact in this approach. This technique can be carried out via a dorsal or lateral approach.

Following either of the hemilaminectomy approaches there is no need to apply a

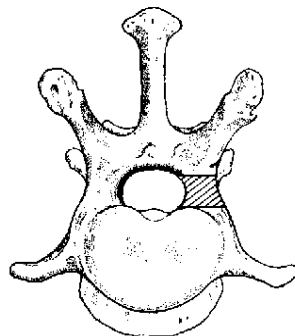


Figure 13.5 Transverse section of 'mini-hemilaminectomy'. The foramen is merely enlarged sufficiently to enable retrieval of disc material in the vertebral canal. The articular processes are left intact.

fat graft as there is little risk of laminectomy membrane formation with its associated problems.

ADVANTAGES AND DISADVANTAGES OF THE HEMI LAMINECTOMY APPROACHES

Advantages:

- (1) Full access to the lateral and ventral aspect of the dural tube, where most extruded disc material will be found. The extruded material can be removed without needing to manipulate the cord in any way – frequently using suction combined with disturbance of the disc material using fine scrapers.
- (2) Easy access to carry out fenestration of the involved disc space and adjacent discs; the cord can be easily observed before, during and after this procedure to detect whether further extrusion has taken place as a result of fenestration.
- (3) Essentially no trauma to the cord need be incurred.

Disadvantages:

- (1) Further lateral dissection is required
- (2) Unilateral approach incurs the risk of operating on the wrong side. This can be overcome by two means, either by selecting a side on clinical grounds and then carrying out a bilateral approach if required, or by obtaining clear evidence of the side of the lesion preoperatively (i.e. having a clear myelographic diagnosis)
- (3) Laceration of the venous sinus which lies on the ventrolateral floor of the vertebral canal is more likely. However, access to the sinus for coagulation is also very good.

Other decompressive procedures

These techniques are durotomy, piodomy and myelotomy. These techniques are usually reserved for animals with severe neurological deficits (usually including loss of deep pain sensation), especially those resulting from acute concussion to the spinal cord. Dorsal laminectomy is required to provide suitable access for these techniques; piodomy and myelotomy must only be carried out on the dorsal midline of the spinal cord.

Durotomy refers to incision of the dural sac surrounding the spinal cord. This is usually best done using a hypodermic needle (20 gauge for most dogs) attached to a syringe and using the bevel to cut the dura carefully, without stabilizing it. As CSF starts to drain out and the opening gapes, the edges can be grasped with fine rat-tooth forceps and the incision lengthened using corneal scissors. It is frequently helpful to form the durotomy incision into an I shape so as to allow the edges to be retracted with fine monofilament stay sutures (Figure 13.6).

The decompressive efficacy of durotomy is controversial but it is often carried out as a prognostic aid in severely affected animals. In cases of myelomalacia, the cord substance will be more or less liquid and will flow from the dural incision. The prognosis for such animals is hopeless and they can be destroyed on the operating table. Durotomy is also required for access to remove intradural tumours; on occasion it may be necessary to remove portions of the dura if they are intimately associated with such lesions. In surgery on humans, great care is taken to ensure a

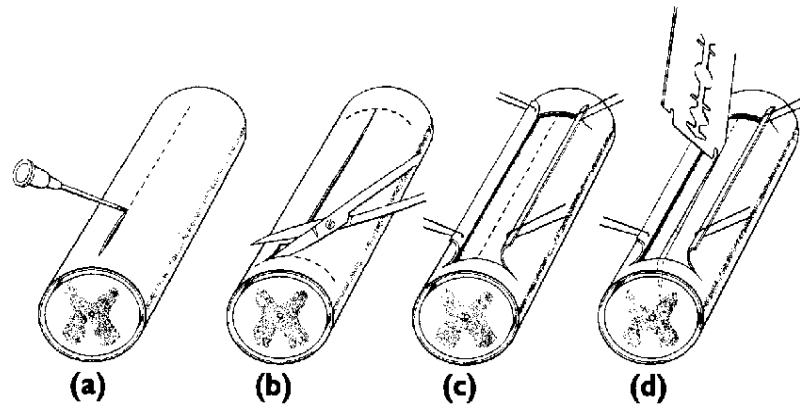


Figure 13.6 (a) Durotomy: the bevel of a hypodermic needle makes a useful cutting edge for initiating this procedure. (b) Conversion of the incision to an I shape using microsurgical scissors. (c) Edges of the incision can be retracted using fine gauge suture material. (d) Myelotomy: a razor blade is the preferred instrument – the incision must be on the midline.

watertight seal following repair of durotomy and failure to achieve this has been associated with post-operative pain and headaches. In cats and dogs symptoms consistent with such complications have not been evident and non-closure of the dura appears to be well tolerated by these species.

Access for decompression and excision of arachnoid cysts also requires durotomy. Following retraction of the margins of the durotomy incision, a 'bleb' of dilated pia/arachnoid can be appreciated. This can be grasped and excised in most cases allowing an unobstructed flow of CSF. Most animals will recover uneventfully following excision of the arachnoid cyst but occasional animals will exhibit recurrence of symptoms; marsupialization of the cyst has been suggested as a means of dealing with this potential problem.

There is evidence that pialotomy (incision of the pia mater) promotes neurological recovery following acute experimental cord injury but its effect has not been fully assessed in clinical cases. Following durotomy, the pia mater is incised on the midline with a scalpel, or preferably with a razor blade. Myelotomy refers to the continuation of this incision down to the central canal. In experimental animals, both these procedures have been shown not to cause severe neurological deficits.

Prophylactic techniques

Fenestration is the main surgical alternative to the decompressive techniques that can be carried out in the TL region of the spine. There is some controversy in the literature regarding the possible benefits of fenestration of TL discs. It has been proposed that fenestration has a beneficial effect in itself and encourages and enhances recovery from the paraparetic state following disc extrusion. It is difficult to understand how fenestration could have this effect because there is no possibility of removing extruded disc material from the vertebral canal where it is causing compression of the spinal cord. It has been suggested that there will be reduction of

the 'dynamic' effect of a disc extrusion and reduction of inflammation in the vertebral canal. However, there is little evidence to substantiate these hypotheses. Fenestration is now regarded as purely prophylactic by most spinal surgeons.

The recurrence rate of disc-associated disease has been shown to be markedly reduced following fenestration, although some authors have questioned the prophylactic benefits of fenestration compared with those achieved by definitive disc surgery alone (i.e. disc removal following laminectomy). Commonly, fenestration of the disc involved and the two adjacent discs has been carried out at the same time as decompressive disc surgery. The recurrence rate is lower following this procedure than if it is not done but now as low as that following multiple disc fenestration. Consequently, recommendations have been made that multiple disc fenestration should be carried out simultaneously with decompressive surgery. In order to avoid unnecessary disruption of the blood supply to the epaxial muscles, if decompressive surgery is to be combined with multiple fenestrations, it is advisable to employ the dorsolateral approach to the thoracolumbar vertebrae, rather than the more usual dorsal approach.

The recurrence rate following fenestration has been reported at different rates according to different authors. Some authors have proposed that recurrence of symptoms may be the result of incomplete removal of the nucleus during such procedures. Recent experimental work has demonstrated that use of a high-speed drill to remove the nucleus results in more complete evacuation of the nucleus and should therefore be recommended.

Three approaches have been described to carry out fenestration of the thoracolumbar discs: (i) dorsal approach, following the same planes as the approach for decompressive surgery; (ii) dorsolateral approach; and (iii) ventral approach.

The dorsolateral approach is useful to gain access to intervertebral discs between T10 and L5 (Figure 13.7). Incision of the lumbodorsal fascia and the aponeurosis of the longissimus thoracis et lumborum muscle is carried out slightly lateral to the midline. The caudal part of the fascial incision is located further laterally (about 2 cm) than the cranial part of the incision (about 0.5 cm); part of the spinalis and semispinalis muscles also must be incised cranially. There is a clear septum between the multifidus and longissimus muscle groups, especially caudally. This division is widened until the tendons of the longissimus muscle are found. These can be used as a guide to the location of the discs because they attach onto the accessory processes of the vertebrae. The disc space can be identified by 'polishing' the lateral anulus with a swab, followed by introduction of a hypodermic needle into the substance of the disc. A window is cut into the lateral aspect of the disc, an arc of anulus excised, and the inner nucleus is removed using tartar scrapers or similar instruments, or a high-speed drill. It can sometimes be helpful to manipulate the spine to encourage expulsion of greater quantities of nuclear material.

The ventral approach allows access to all intervertebral discs from T9 to L5. The dog is positioned in right lateral recumbency. The initial surgical approach consists of a long incision over and parallel to the left thirteenth rib. The skin incision is moved caudally and a paracostal incision into the abdominal cavity is made. Abdominal viscera are retracted and the left kidney is moved ventrally. The iliopsoas muscle is retracted away from the ventral aspect of the vertebrae to allow access to the discs. Discs L1 to L5 are fenestrated via the abdomen. The skin incision is then moved cranially, allowing an intercostal thoracotomy to be

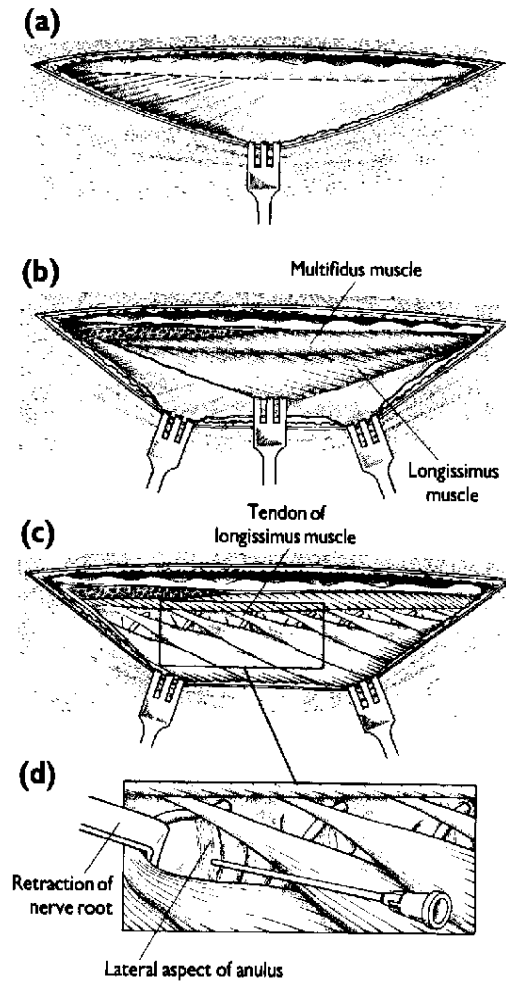


Figure 13.7 Dorsolateral approach to the thoracolumbar vertebral column. (a) Fascial incision is made about 1.5 cm lateral to the midline. (b) The spinalis et semispinalis muscle is incised cranially. (c) Developing the natural division between the multifidus and longissimus muscles allows exposure of the tendons of the longissimus muscles. (d) Tendons of the longissimus are used as a guide to the location of the discs – the nerve root must be retracted to allow clear access, the disc is identified by palpation with a hypodermic needle.

carried out between ribs 10 and 11. Artificial respiration is required during the thoracotomy. Discs T9 to T13 can be located and fenestrated. Care must be taken to avoid damage to the sympathetic trunk and aorta which lie close to the lateral and ventral aspects of these discs.

During fenestration it is routine to treat all the likely susceptible discs, which includes T10–L4. Via a ventral approach, spaces T9/10 and L5/6 are also easily accessible and may be fenestrated. Care must be taken not to create an iatrogenic pneumothorax when attending to the most cranial thoracic discs during the dorsolateral approach and to avoid damage to the exiting nerve roots, especially at the

most caudal locations (L4, L5) as these nerve roots are important in maintenance of normal pelvic limb function.

Recovery from fenestration is usually very rapid. An important potential complication is iatrogenic expulsion of more disc material into the vertebral canal if the dorsal annulus fibrosus has been torn prior to surgery. This would appear to be more likely to occur in recent extrusions and perhaps fenestration should be avoided in such cases for this reason. Some dogs are reported to develop ascending myelomalacia in most series of fenestrations, which is commonly ascribed to the original lesion. However, ascending myelomalacia is not commonly observed following decompressive surgery in similar cases, suggesting that some (at least) of these cases of myelomalacia are the result of iatrogenic disc extrusion during fenestration surgery. Worsening of clinical signs has been observed following fenestration of cervical discs, and has been attributed to iatrogenic disc extrusion.

Fractures and subluxations of the thoracolumbar segment

This part of the vertebral column is more commonly affected by fractures and luxations than other regions, presumably at least partly because of its length compared with other segments. However, there are other features which may make the thoracolumbar junction area more susceptible to injury, such as the relative mobility in the mid-lumbar region compared with that of the rigidly restricted thoracic region and the powerfully muscled caudal lumbar region. This feature could be construed as being likely to allow concentration of forces at the less rigid intervening thoracolumbar junction region. It is usually suggested that fractures and luxations in the vertebral column occur at the interface between fixed and nonfixed areas. However, some studies show that this is not the case, with an equal distribution of lesions along the entire lumbar spine.

Many different techniques are available to treat fractures of this region, although plate fixation should not be carried out caudal to L4 vertebra, because of the requirement for rhizotomy. The technique of fixation utilizing pins and PMMA cement is now the most commonly employed method. Recent studies have suggested that conservative therapy and support with back splints may be sufficient to allow good recovery of function in many affected animals. It must be remembered that the position of the bones relative to each other does not give an indication of stability and should not be used as the sole criterion for decision making when choosing between conservative and surgical treatment.

Other conditions of the thoracolumbar segment (T3–L3)

Type II disc protrusions

Treatment of type II disc protrusions is somewhat different from that applied to type I disc lesions. Type II discs frequently are associated with pain only, or sometimes with mild neurological deficits, in large-breed dogs. They frequently affect the lumbar region of such dogs, but on occasion they can be found in the cranial thoracic region. Excision of type II disc protrusions can be difficult. They are

best approached by a hemilaminectomy (or mini-hemilaminectomy). The preferred side for a surgical approach cannot usually be assessed from myelography but may be determined from the owner's history. The disc is fenestrated laterally, followed by introduction of rongeurs (usually Lempert rongeurs) through the anulus enabling the interior of the disc to be removed. Tartar scrapers or other similar instruments can be used from within the vertebral canal to tear dorsally protruded portions of anulus in a ventral direction into the intervertebral space from where they can be grasped with rongeurs and removed. The dorsal longitudinal ligament should also be excised; a scalpel blade can be used to cut an appropriately sized window in this ligament, allowing it to be grasped and removed using rongeurs. Curettage of the space using curettes or air-powered burr in combination with a bilateral approach (in many cases) will ensure complete removal.

Following surgical excision of type II discs it is quite common for there to be a mild deterioration in the dog's neurological status, which can be attributed to manipulation during surgery, reperfusion injury with formation of free radicals, or instability. Preoperative preparation with methylprednisolone may be of some benefit.

Developmental diseases

Hemivertebrae and other congenital disorders of the vertebral column are frequently found in the thoracic region of the spine. On myelographic studies, compression of the spinal cord which is sometimes caused by this deformity can be appreciated. Sometimes dorsal laminectomy is an appropriate approach to such lesions and can allow the removal of extraneous bone or anomalous fibrous tissue from the affected area. It must be remembered that hemivertebrae are frequently inherently very unstable and that laminectomy can potentially further worsen such a situation. It is imperative that these cases are treated by appropriate stabilization such as methyl methacrylate and pin fixation.

Certain cases of hemivertebra may require more radical therapy, for example if there is substantial compression associated with dorsal displacement of the vertebral body itself. In these cases it may be necessary to attempt removal of the vertebral body (corpectomy). This is best carried out via a ventral approach and requires extensive stabilization. Such surgery carries risk of substantial haemorrhage and these operations require careful planning. Stabilization can be achieved by use of bone cement/plates, or external fixation plus grafts of autogenous or heterogenous bone in certain cases.

Satisfactory results can be achieved in such cases if surgery is properly planned and executed.

Neoplasia in the thoracolumbar segment

Many tumours of the spine are diagnosed in the thoracolumbar segment. They can form an important differential diagnosis for the much more commonly observed disc disease in the same region. The same types of tumour occur in this region as elsewhere and their prognosis is dependent on their histological type. However, there is one unusual tumour which has been diagnosed only in dogs and only in

this region of the spine. There is some doubt regarding the cell type of origin but the consensus of opinion is that it is a nephroblastoma. It is thought that there is a failure of some of the primordial kidney cells to separate from the developing spinal cord. Consequently, an island of potential kidney cells is isolated in the spinal cord parenchyma. Affected animals develop symptoms of a progressive transverse myelopathy – the duration of symptoms prior to therapy or post mortem examination is generally about 1 month. Dogs affected by this tumour are young (i.e. < 18 months old).

The site of the tumour is detected by myelography; a blockage of subarachnoid contrast flow occurs, consistent with an extramedullary/intradural tumour. Most cases which have been reported were histologically diagnosed post mortem but two recent case reports include details of surgical treatment, which resulted in alleviation of symptoms. Ultimately, recurrence occurred in one case resulting in euthanasia.

Attempted surgical treatment, or exploratory surgery to investigate possible tumours in this segment of the spine would normally be undertaken via a dorsal laminectomy.

Associated reading

Decompressive surgery

- Allen A.R. (1911) Surgery of experimental lesion of the spinal cord equivalent to crush injury of fracture dislocation of the spinal column – a preliminary report. *J. Am. Med. Assoc.* **57**, 878.
- Bitetto W.V., Thacher C. (1987) A modified lateral decompressive technique for treatment of canine intervertebral disc disease. *J. Am. Anim. Hosp. Assoc.* **23**, 409.
- Black A.P. (1988) Lateral spinal decompression in the dog: a review of 39 cases. *J. Small Anim. Pract.* **29**, 581.
- Funkquist B. (1962) Thoracolumbar disk protrusion with severe cord compression in the dog. III Treatment by decompressive laminectomy. *Acta Vet. Scand.* **3**, 344.
- Funkquist B. (1970) Decompressive laminectomy in thoracolumbar disc protrusion with paraplegia in the dog. *J. Small Anim. Pract.* **11**, 445.
- Gambardella P.C. (1980) Dorsal decompressive laminectomy for treatment of thoracolumbar disc disease in dogs: a retrospective study of 98 cases. *Vet. Surg.* **9**, 24.
- Jeffery N.D. (1988) Treatment of acute and chronic thoracolumbar disc disease by 'mini hemilaminectomy'. *J. Small Anim. Pract.* **29**, 611.
- McKee W.M. (1992) A comparison of hemilaminectomy (with concomitant disc fenestration) and dorsal laminectomy for the treatment of thoracolumbar disc protrusion in dogs. *Vet. Rec.* **130**, 296.
- Parker A.J., Smith C.W. (1975) Functional recovery from spinal cord trauma following delayed incision of spinal meninges in dogs. *Res. Vet. Sci.* **18**, 110.
- Piermattei D.L. (1993) The Vertebral Column. In: *An Atlas of Surgical Approaches to Bones and Joints of the Dog and Cat*, 3rd edn. Philadelphia, W.B. Saunders, p. 45.

- Prata R.G. (1981) Neurosurgical treatment of thoracolumbar disks: the rationale and value of laminectomy with concomitant disk removal. *J. Am. Anim. Hosp. Assoc.* **17**, 17.
- Rucker N.C., Lumb W.V., Scott R.J. (1981) Combined pharmacologic and surgical treatments for acute spinal cord trauma. *Am. J. Vet. Res.* **42**, 1138.
- Schulman A., Lippincott C.L. (1987) Dorsolateral hemilaminectomy in the treatment of thoracolumbar intervertebral disc disease in dogs. *Comp. Cont. Ed. Pract. Vet.* **9**, 305.
- Seim III H.B., Nafe L.A. (1981) Spontaneous intervertebral disk extrusion with associated myelopathy in a cat. *J. Am. Anim. Hosp. Assoc.* **17**, 201.
- Shores A. (1982) Intervertebral disk syndrome in the dog Part III. Thoracolumbar disk surgery. *Comp. Cont. Ed. Pract. Vet.* **4**, 24.
- Teague H.D., Brasmer T.H. (1978) Midline myelotomy of the clinically normal canine spinal cord. *Am. J. Vet. Res.* **39**, 1584.
- Trevor P.B., Martin R.A., Saunders G.K., Trotter E.J. (1991) Healing characteristics of free and pedicle fat grafts after dorsal laminectomy and durotomy in dogs. *Vet. Surg.* **20**, 282.
- Trotter E.J. (1990) Dorsal laminectomy for treatment of thoracolumbar disc disease. In: Bojrab M.J. (ed.), *Current Techniques in Small Animal Surgery*, 3rd Edn. Philadelphia, Lea & Febiger, p. 608.

Fenestration

- Butterworth S.J., Denny H.R. (1991) Follow up study of 100 cases with thoracolumbar disc protrusions treated by lateral fenestration. *J. Small Anim. Pract.* **32**, 443.
- Davies, J.V., Sharp N.J.H. (1983) A comparison of conservative treatment and fenestration for thoracolumbar intervertebral disc disease in the dog. *J. Small Anim. Pract.* **24**, 259.
- Holmberg D.L., Palmer N.C., Vanpelt D, Willan A.R. (1990) A comparison of manual and power assisted thoracolumbar disc fenestration in dogs. *Vet. Surg.* **19**, 323.
- Knapp D.W., Pope E.R., Hewett J.E., Bojrab M.J. (1990) A retrospective study of thoracolumbar disk fenestration in dogs using a ventral approach: 160 cases (1976–1986). *J. Am. Anim. Hosp. Assoc.* **26**, 543.
- Levine S.H., Caywood D.D. (1984) Recurrence of neurological deficits in dogs treated for thoracolumbar disk disease. *J. Am. Anim. Hosp. Assoc.* **20**, 889.
- Shores A., Cechner P.E., Cantwell H.D. (1985) Structural changes in thoracolumbar disks following lateral fenestration. *Vet. Surg.* **14**, 117.
- Yturrapse D.J., Lumb W.V. (1973) A dorsolateral muscle separating approach for thoracolumbar intervertebral disk fenestration in the dog. *J. Am. Vet. Med. Assoc.* **162**, 1037.

Fractures and luxations

- Carberry C.A., Flanders J.A., Dietze A.E., Gilmore D.G., Trotter E. J. (1989) Non-surgical management of thoracic and lumbar spinal fractures and fracture/

luxations in the dog and cat: a review of 17 cases. *J. Am. Anim. Hosp. Assoc.* **25**, 43.

Mathieson D.T. (1983) Thoracolumbar spinal fractures/luxations: surgical management. *Comp. Cont. Ed. Pract. Vet.* **5**, 867.

Patterson R.H., Smith G.K. (1992) Backsplinting for treatment of thoracic and lumbar fracture/luxation in the dog: principles of application and case series. *V.C.O.T.* **5**, 179.

Turner W.D. (1987) Fractures and fracture-luxations of the lumbar spine: a retrospective study in the dog. *J. Am. Anim. Hosp. Assoc.* **23**, 459.

Neoplasia

Ferretti A., Scanziani E., Colombo S. (1993) Surgical treatment of a spinal cord tumor resembling neuroblastoma in a young dog. *Prog. Vet. Neurol.* **4**, 84.

Moissonnier P., Abbott D.P. (1993) Canine neuroepithelioma: case report and literature review. *J. Am. Anim. Hosp. Assoc.* **29**, 397.

CHAPTER 14

Surgery of the Lumbosacral and Sacrocaudal Regions

Contents

<i>Introduction</i>	202
<i>Type I disc extrusions in the caudal lumbar region</i>	203
<i>Lumbosacral stenosis</i>	204
<i>Fractures and luxations</i>	209
<i>Neoplasia</i>	212
<i>Miscellaneous conditions</i>	212
<i>Associated reading</i>	213

Introduction

Included within this chapter are those conditions which affect the lumbosacral (L4–S3) and more distal spinal cord segments, plus discussion of lesions of the caudal thoracolumbar segment. The spinal cord terminates as the conus medullaris at approximately the caudal end of L6 vertebra in the dog but the dural sac continues slightly further caudally to terminate around the L7/S1 interspace. The relationship varies somewhat between sizes of dog, with the ends of both the spinal cord and the dural sac located further caudally in smaller animals or breeds and also varies between individuals of the same breed. In the cat, the dural sac is a wide structure which continues beyond the lumbosacral junction into the sacrum.

The spinal cord segments L4–S3 are contained within the vertebrae L4–L6 and therefore any lesions affecting this region of the vertebral column can give rise to a common group of symptoms. This is often referred to as the cauda equina syndrome and is usually applied to the group of symptoms derived from dysfunction of the L6–S3 segment of the spinal cord and/or their associated nerve roots. The nerve roots associated with these spinal cord segments course caudally at a quite acute angle to the remainder of the dural sac, resembling a horse's tail, hence the term cauda equina.

Compression of the L7–S3 spinal segments (and related nerves) is most commonly the result of lesions at the lumbosacral junction (L7–S1 vertebral segments). Care must be taken when evaluating animals with neurological signs suggestive of a lesion of L6–S3 spinal cord segments, as there are many sites within the vertebral column at which a lesion will produce identical symptoms. For example, an animal with signs of pelvic limb weakness, poor hock flexion and weak anal tone could have a lesion at L6/7 L7/S1 vertebrae, or possibly within the sacrum. Traction injuries to the tail are common, especially in cats, and can result in damage to the nerve roots or spinal cord contained within the vertebral canal. These injuries will

result in similar neurological impairment to that observed associated with lesions which are situated more cranially.

In addition to lesions within the vertebral column, damage to the lumbosacral plexus external to the vertebral canal can produce signs of pelvic limb dysfunction that can be difficult to distinguish from those caused by lesions within the vertebral canal. Most often, lesions of the lumbosacral plexus will be the result of trauma, in which case the diagnosis may be more easily made. Commonly, sacroiliac fracture/separation and ilial fractures may result in dysfunction of the L7 nerve root or the lumbosacral trunk. These orthopaedic injuries are usually easily recognized on plain radiographs.

Type I disc extrusions in the caudal lumbar region

Although type I disc extrusions occur most frequently in the thoracolumbar region (T3–L3) occasional dogs will be presented with evidence of lower motor neurone

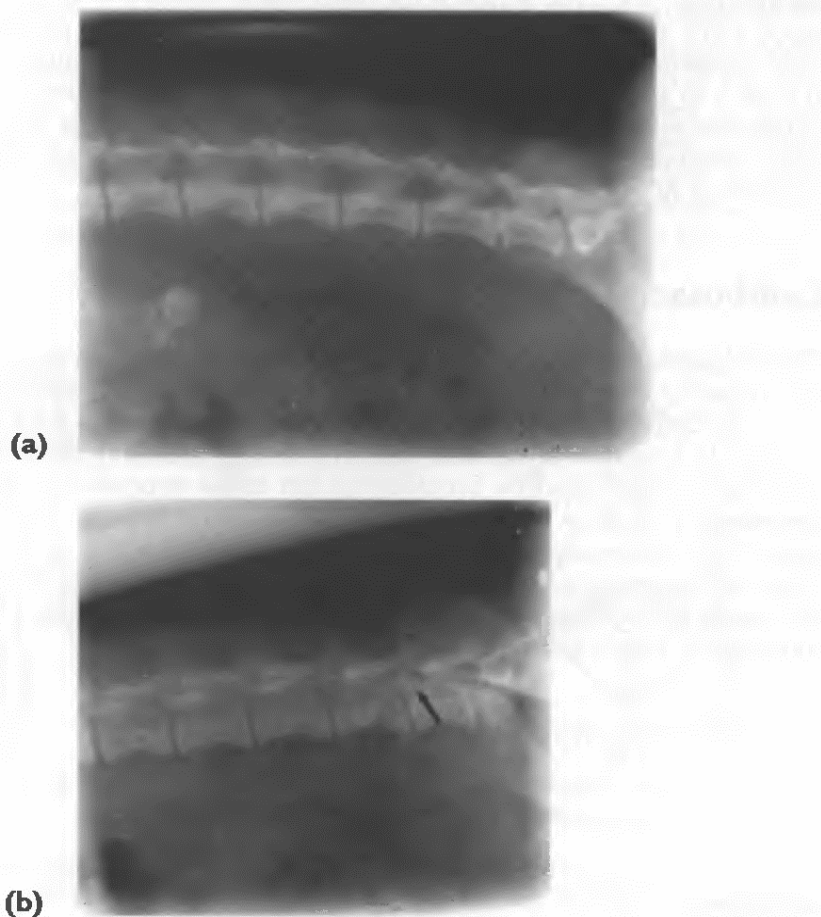


Figure 14.1 (a) Lateral and (b) oblique lateral radiographs of dog with lateralized type I disc extrusion at L6/7 (arrow).

deficits in one or both pelvic limbs in association with disc extrusions. Such affected animals will often be presented for examination because of unilateral pelvic limb paresis, which may be associated with considerable pain. It is unusual for disc extrusions in this region to cause severe paraparesis. Differential diagnosis for affected dogs will include fibrocartilaginous embolism, which has a predilection to occur in the lumbosacral intumescence. A difference in clinical presentation is that dogs suffering disc extrusions will usually exhibit considerable pain and their neurological symptoms are often progressive over a period of days to weeks.

In animals which have very lateralized symptoms, the initial appearance may be suggestive of an orthopaedic condition; however, neurological examination will reveal depression of reflexes in most cases. Diagnosis of extruded discs in this region may be more difficult, as the extreme lateralization may preclude adequate identification during myelography. The use of 45° oblique radiographic views can aid in identification of extruded disc material (Figure 14.1).

Lesions within the L4–L6 vertebral column segments can be approached by the same means as those of the T3–L3 segment, i.e. via hemilaminectomy or dorsal laminectomy. The large wings of the ilia prohibit satisfactory access to the lateral aspect of L7 vertebra, rendering the dorsal approach the only means of attaining wide exposure of the structures in this region. Extreme care must be utilized in approach to the lateral aspect of L4–L6 in that the exiting nerve roots at these interspaces subserve important function in the hindlimbs. These nerve roots effectively preclude the lateral application of plates to support the spine following fractures or luxations in this area.

Lumbosacral stenosis

Non-neoplastic lumbosacral disorders have been recognized in dogs with increasing frequency over the last 10 years, and can be subdivided into idiopathic and acquired stenosis. Idiopathic stenosis is caused by stenosis of the bony vertebral canal at the lumbosacral junction. Acquired stenosis is usually due to impingement into the vertebral canal by proliferating soft tissue structures in the area. Most commonly, protrusion of the L7 disc is the cause but in some dogs there can be nerve root compression owing to distention and thickening of the diarthrodial joints or thickening of the ligamentum flavum. In some cases in which the L7 disc space has collapsed and there may be nerve root compression caused by a combination of soft tissue structures.

Treatment of degenerative lumbosacral stenosis

Several options exist for the treatment of lumbosacral type II disc protrusion: fenestration, disc excision, and fixation/fusion.

FENESTRATION

Fenestration is now rarely considered as an option, although it can be used as a technique to recover material for bacteriological culture in cases of discospondylitis.

Fenestration will not remove protruded material from the vertebral canal. The approach is usually ventral, via a laparotomy.

DISCECTOMY

Disc excision involves creation of a dorsal laminectomy plus excision of the dorsal annulus and removal of the nucleus pulposus using rongeurs or similar instruments. The dorsal approach to the lumbosacral joint is similar to the approach to the thoracolumbar vertebrae. Positioning of the animal for surgery of the lumbosacral region is important; if the joint is slightly flexed, good access to the vertebral canal can be achieved even through small bone incisions. However, the apparent size of a disc protrusion will be reduced with the lumbosacral joint in flexion. Therefore the exact positioning needs to be different for each individual animal, and depends on the certainty of preoperative diagnosis.

A midline skin incision is made, centring on the lumbosacral junction. A layer of thin muscle is encountered and there may be a considerable amount of subcutaneous fat. The thick lumbosacral fascia is situated ventral to the fat layer and is divided on the midline. Epaxial musculature is elevated from the spinous processes and retracted laterally using Gelpi retractors. Subperiosteal elevation of the musculature helps to reduce haemorrhage. Sharp dissection is required to divide attachments of the multifidus muscle tendons to the articular processes. The flaval ligament is grasped using sharp forceps and excised with a scalpel blade to reveal the contents of the vertebral canal. The joint capsule of the diarthrodial joints commonly is confluent with the flaval ligament. On occasion it may be necessary

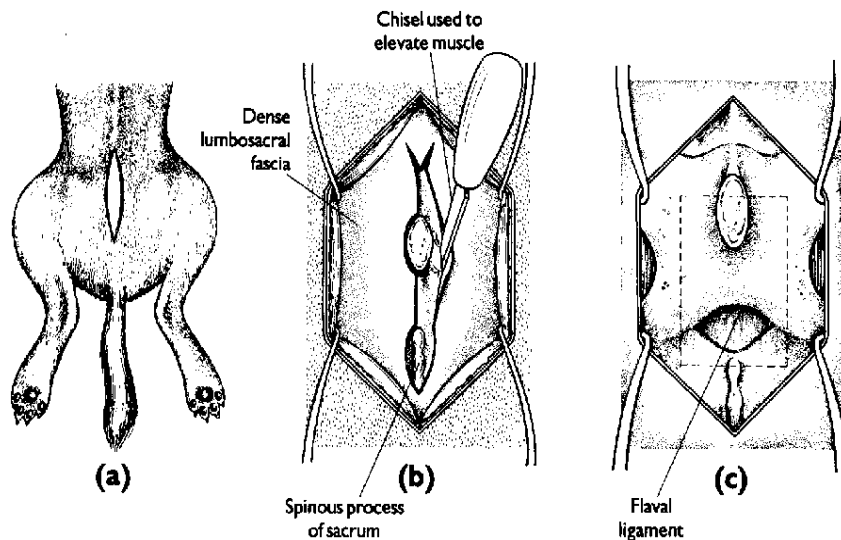


Figure 14.2 Dorsal approach to the lumbosacral joint. (a) A midline skin incision is made centring on the L7/S1 space. (b) Dense fascia is incised in the midline and around the spinous processes. Sharp and blunt dissection is continued by following the contour of the bone. Tendon attachments to the lateral aspect of the articular processes need not be divided. (c) Dotted line indicates area of bone removal.

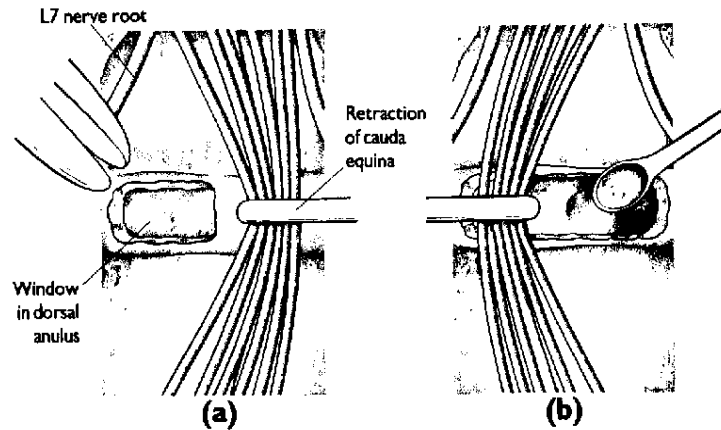


Figure 14.3 Lumbosacral discectomy. (a) Cauda equina is retracted allowing access to one-half of the dorsal anulus; a window is made and the nucleus removed using rongeurs. (b) The cauda equina is retracted to the other side allowing completion of excision of the dorsal anulus – a curette may assist in removal of the nucleus.

to excise parts of this structure in order to achieve adequate exposure of the contents of the vertebral canal.

The cauda equina is relatively robust and can be handled in the same manner as a peripheral nerve trunk (like the sciatic nerve for instance) and can be mobilized laterally to allow sufficient access to permit excision of the anulus (Figure 14.3). Care must be taken to avoid injury to the large venous sinuses during removal of the anulus.

It is often necessary to explore the lateral gutters of the vertebral canal to ensure that the L7 nerve root is not entrapped either in the vertebral canal or in the intervertebral foramen. When this is being carried out it should be noted whether the lumbosacral joint is in extension or flexion, because this will affect the width of the intervertebral foramen and can interfere with proper assessment of the degree of nerve root compression. The intervertebral foramen may be enlarged by use of rongeurs or air drill to allow the nerve root to move freely in the foramen (Figure 14.4). The root can be mobilized with a blunt retractor and should be free to move about 2–3 mm without tension. Sometimes it is necessary to remove the articular process totally in order to accomplish complete decompression of the nerve root – this is termed *facetectomy*.

Drawbacks of the discectomy technique include the theoretical problem of collapse of the disc space with consequent narrowing of the intervertebral foramen. This could possibly exacerbate subclinical compression of the L7 root, which means that accurate assessment of root compression is extremely important during this procedure. A further problem is that removal of the laminae has a potentially destabilizing effect and removal of parts of the pedicle (during *facetectomy*) will exacerbate this effect and consequently may allow subluxation of the L7/S1 articulation. It is recommended that bilateral *facetectomy* should not be done unless secure stabilization of the L7/S1 space is also carried out.

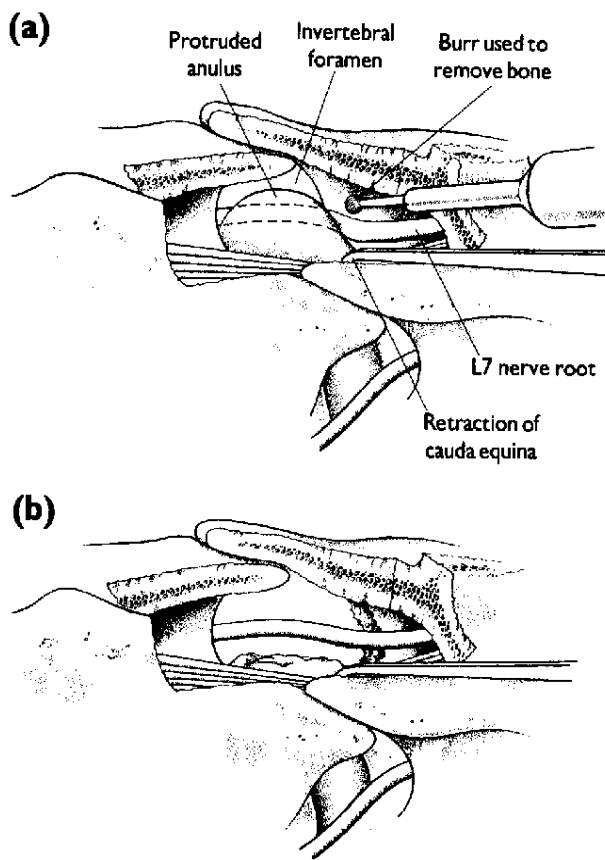


Figure 14.4 Lumbosacral foraminotomy. (a) Prior to foraminotomy the nerve is compressed by protruded anulus in the foramen. (b) Disc has been excised as in Figure 14.3. Foramen has been enlarged by means of air drill/burr. The L7 nerve root is decompressed.

DORSAL FIXATION/FUSION

This technique has been advocated by some authors as an alternative means of decompressing the cauda equina and L7 nerve roots at the L7/S1 interspace (Slocum and Devine 1986). It can be demonstrated that nerve compression is exacerbated during extension of the lumbosacral junction and relieved during flexion or by application of linear traction. The fixation/fusion technique relies on fixation of the lumbosacral joint in a position of flexion or linear traction. With the lumbosacral joint correctly positioned, crossed Steinmann pins are driven across the L7/S1 diarthrodial joints and buried in the wings of the ilia (Figure 14.5). It is usual, but not essential, for the pins to be driven across the base of the L7 spinous process. The flaval ligament but not the dorsal anulus is excised during this procedure. Grafted bone is applied to the laminae of the L7 and sacral segments after the cortical bone has been debrided from their surfaces. The bone graft is conveniently obtained from the wings of the ilia and can be a mixture of cancellous and cortical bone. Fusion of the interspace has been recorded after about 3 months.

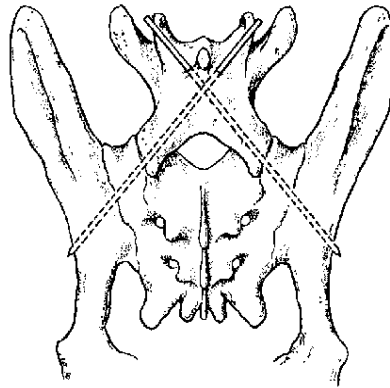


Figure 14.5 Dorsal cross pin fixation of lumbosacral joint. Pins traverse synovial joint between L7 and S1.

Problems associated with this technique are those common to any orthopaedic technique that relies on implants, namely implant failure and migration. Implant migration is particularly common at this site and it has been suggested that bone cement be applied to the ends of the pins as a preventative measure. Use of threaded pins is not recommended as breakage at the thread-pin interface is common. Dorsal fixation/fusion is probably best applied to cases which are liable to require bilateral L7 nerve root decompression, as good decompression can be achieved without compromising the stability of the vertebral column.

CHEMONUCLEOLYSIS

In this technique an enzyme, usually chymopapain, is injected into the nucleus of the L7 disc. Following this treatment there is a gradual reduction in disc width and resolution of the symptoms. Chemonucleolysis has not been reported in a large number of cases yet but the results of this minimally invasive technique certainly appear to be promising. The main drawback is the cost of the enzyme and its short life after being reconstituted. Discography is essential prior to the injection of the enzyme, because it is essential that the dorsal annulus is intact, or enzyme will be permitted to leak into the vertebral canal with potentially catastrophic effects. Although image intensification is helpful for carrying out this technique it is not absolutely essential.

Because this technique causes reduction in disc width, there is still the potential problem of consequent intraforaminal entrapment of the L7 nerve roots.

VENTRAL FIXATION/FUSION

This technique has only rarely been reported in the literature. Following a ventral approach to the lumbosacral junction, a single interbody screw is placed across the L7 disc space and tightened with a lag effect. The ventral approach necessitates a laparotomy, extending caudally to reach the brim of the pubis. The abdominal contents are retracted cranially and laterally. The lumbosacral junction can be

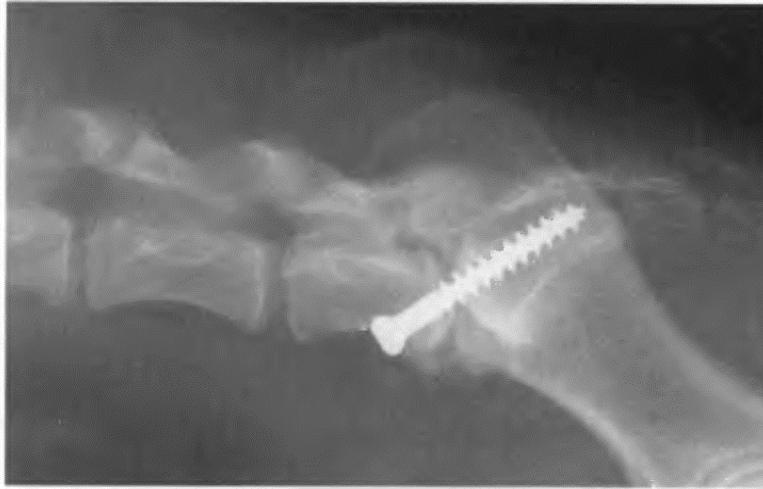


Figure 14.6 Lateral postoperative radiograph of dog following ventral screw fixation of lumbar joint. Impingement of screw into sacral canal was not associated with clinical symptoms.

easily palpated, as there is an obvious change in the angle between the vertebral bodies at that site. With care taken to protect the trifurcation of the aorta which lies close by, the periosteum can be elevated laterally. The disc can be fenestrated using this approach and the vertebral end plates curetted to encourage postoperative bone bridging. The angle to place the interbody screw can be determined by reference to preoperative radiographs. Impingement of the screw into the sacral vertebral canal seems not to be important (Figure 14.6). Radiographic fusion can be expected to occur within about three months.

Treatment of idiopathic lumbosacral stenosis


Reports on cases of idiopathic lumbosacral stenosis which were treated surgically indicate that good results can be achieved by laminectomy, including facetectomy or foraminotomy if required.

Fractures and luxations

Fracture of the L7 vertebral body

Fractures of the L7 vertebral body are relatively common, usually as the result of a road traffic accident. In one series 10/58 lumbar fractures occurred at L7 vertebra. The caudal part of the vertebra typically is displaced cranially and ventrally. Although considerable displacement often occurs, the results of treatment are usually very good. This may still be the case even when considerable function, even including loss of deep pain sensation of the hindlimbs, has been lost.

Reduction of the fracture is usually straightforward; the caudal fragment is grasped in bone-holding forceps, elevated and drawn caudally. Stability can be



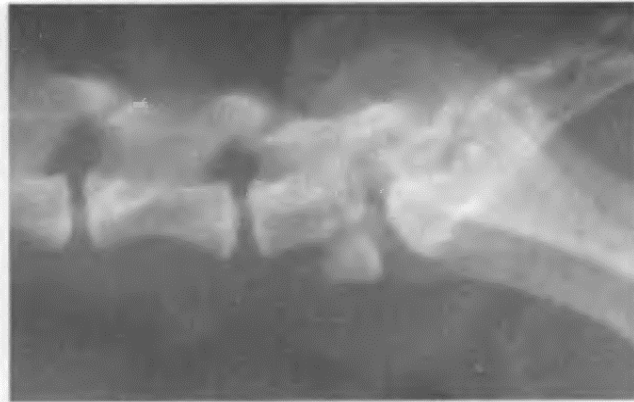


Figure 14.7 Fracture of L7 vertebra. This fracture is not typical of fractures of this vertebra.

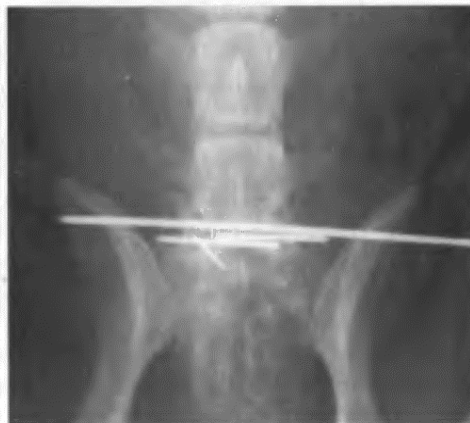


Figure 14.8 Postoperative ventrodorsal view of same dog illustrating transilial bar fixation. The smaller pins have been used to help reduce the synovial joints between the articular facets.

assured simply by placing a transilial pin across the caudal articular processes of L7. The pin should preferably penetrate the base of the spinous process for additional stability (Figures 14.7 and 14.8).

Similar fractures and luxations also occur in other vertebrae of the caudal lumbar region, which can be difficult to treat. Lateral plate application cannot be done at this site because of the need for rhizotomy and difficulties in access. Dorsal fixation by means of pins and PMMA cement can also sometimes be difficult to apply properly. Three techniques have been described to be of use in this region: spinal stapling, which requires there to be many consecutive spinous processes intact and also much lateral dissection; the technique of combined use of Lubra plates with the simple transilial bar; and external fixation. Experience with external fixation is still at an early stage.

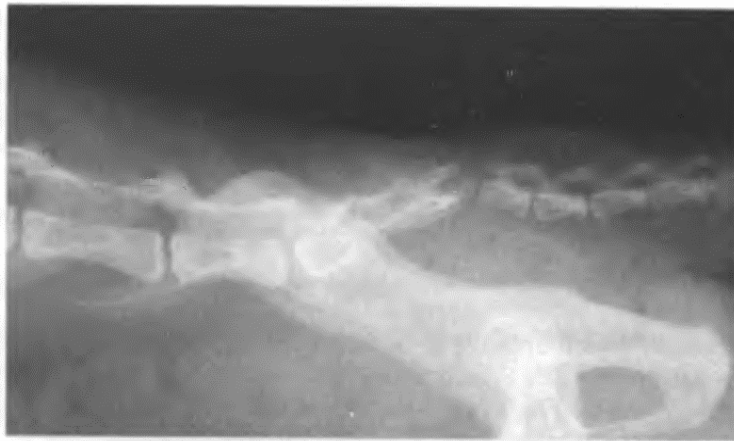

Figure 14.9 Sacrocaudal fracture/luxation in a cat. Courtesy of Mr M. Herrtage, Cambridge University Veterinary School, UK.

Sacrocaudal fracture/luxation

This condition is especially common in cats, usually following RTA. Typically the lesion is a luxation with or without fracture in one or both diarthrodial joints (Figure 14.9). The degree of displacement of the affected vertebrae may vary considerably between cases. Damage to the nerve roots usually is the result of traction, with the result that several of the more cranially located nerve roots of the lumbosacral plexus may also be involved and dysfunctional. Affected cats typically have limp tails, incontinence (usually with little resistance to emptying) and may show signs of partial sciatic palsy (e.g. weak hock flexion). Pelvic limb symptoms may be of short duration only. The prognosis for return of function is variable, reflecting the range of severity of the neural injury, from neurapraxia to complete severance of the nerves. A good prognosis is expected for the majority of affected cats, those that have absent anal tone will be less likely to recover full function. In one study, cats that were not able to urinate normally at 1 month post-injury never recovered.

Treatment can consist of several options: (i) conservative, with care of the bladder by manual expression or indwelling catheter; (ii) reduction and fixation of the fracture/luxation; or (iii) tail amputation. Those animals exhibiting relatively mild signs are usually treated conservatively; i.e. those with weak tail, intact continence and intact pain sensation, or with little displacement of the fragments. Full recovery within 3 weeks is common in this group. Those with severe injury, i.e. loss of pain sensation in the tail, loss of bladder control and severe fracture fragment displacement may benefit from surgical exploration and decompression of the nerve roots. Removal of haematoma and realignment of the spinal canal may allow healing of the nerves to occur more easily and stabilization will prevent further trauma to the nerves. Whether there is a greater rate of recovery in surgically treated cases is not known. Amputation of the tail may be beneficial on two counts: one is that there is frequently considerable trauma and soiling of the tail, which can be difficult to manage; also, the weight of the tail may be responsible for persistent traction on the nerve roots and thereby hinder recovery.

In all these cases it is worth allowing prolonged periods of time to elapse before considering that recovery will not occur, up to 3 months or more may be required before recovery becomes obvious. However, the dedication of the owner and the veterinarian may also be a factor to be considered before embarking on such prolonged treatment of an incontinent animal. (The complications of incontinence are discussed in Chapter 16).

Neoplasia

The lumbosacral region appears to be affected reasonably frequently by tumours. These are commonly extradural types and malignant, a common histological diagnosis is sarcoma. The symptoms associated with neoplasia at this location are often indistinguishable from lumbosacral disc disease; care is required to ensure correct diagnosis. Myelography is frequently a useful diagnostic test, especially as it allows the full extent of the lesion to be clearly seen. In many cases it is possible to excise tumours at this site but unfortunately their malignant nature often precludes long remission times.

Metastatic tumours can also be found at this location, as at other sites within the vertebral column. Metastasis of prostatic tumours is particularly common. Typically there is marked proliferation of the bone of the ventral aspect of the vertebral bodies at the site of prostatic metastasis.

Miscellaneous conditions

Discospondylitis

The L7 disc space is the second most commonly affected with discospondylitis. Discospondylitis in dogs is usually treated by antibiotics alone, at least initially. However, surgical treatment can be useful either for obtaining a specimen for culture or to stabilize affected vertebral segments.

A ventral approach to the L7 disc can be carried out in order to obtain material for culture and also for fixation of this intervertebral space. Alternatively, the dorsal approach followed by discectomy can be employed. Dorsal fixation/fusion following a wide laminectomy at the lumbosacral joint is likely to result in fracture of the articular processes.

Osteochondrosis

Two recent reports have described the radiological appearance and incidence of osteochondrosis. To date, the condition has been described only in German shepherd dogs. The symptoms are similar to those of other conditions of the lumbosacral region, including pain and poor tail carriage. On plain lateral radiographs, a mass of bone density can be seen lying close to the cranial end plate of the sacral body. This is commonly associated with a defect in the shape of the sacrum. Epidurography can clearly demonstrate the compressive effect of the lesion on the cauda equina. Surgical treatment by means of dorsal laminectomy and excision of

the offending loose body results in resolution of symptoms. The loose portion of the bone may adhere closely to the vertebral bone, necessitating use of hammer and chisels or rongeurs to remove it. Care must be taken to protect the nerve roots during such procedures.

Associated reading

Lumbosacral stenosis/cauda equina syndrome

- Betts C.W., Kneller S.K., Skelton J.A. (1976) An unusual case of traumatic spondylolisthesis in a red bone hound. *J. Am. Anim. Hosp. Assoc.* **12**, 470.
- Chambers J.N. (1989) Degenerative lumbosacral stenosis in dogs. *Vet. Med. Rep.* **1**, 166.
- Denny H.R., Gibbs C., Holt P.E. (1982) The diagnosis and treatment of cauda equina lesions in the dog. *J. Small Anim. Pract.* **23**, 425.
- Lenahan T.M. (1983) Canine cauda equina syndrome. *Comp. Cont. Ed. Pract. Vet.* **5**, 941.
- Morgan J.P., Bailey C.S. (1990) Cauda equina syndrome in the dog: radiographic evaluation. *J. Small Anim. Pract.* **31**, 69.
- Morgan J.P., Bahr A., Franti C.E., Bailey C.S. (1993) Lumbosacral transitional vertebrae as a predisposing cause of cauda equina syndrome in German shepherd dogs: 161 cases (1987–1990). *J. Am. Vet. Med. Assoc.* **202**, 1877.
- Oliver J.E., Selcer R.R., Simpson S. (1978) Cauda equina compression from lumbosacral malarticulation and malformation in the dog. *J. Am. Vet. Med. Assoc.* **173**, 207.
- Palmer R.H., Chambers J.N. (1991) Canine lumbosacral diseases. Part I. Anatomy, pathophysiology and clinical presentation. *Comp. Cont. Ed. Pract. Vet. (Europ.)* **1**, 12.
- Palmer R.H., Chambers J.N. (1991) Canine lumbosacral diseases. Part II. Definitive diagnosis, treatment and prognosis. *Comp. Cont. Ed. Pract. Vet. Europ.* **1**, 95.
- Piermattei D.L. (1993) Section III The Vertebral Column In: *An Atlas of Surgical Approaches to Bones and Joints of the Dog and Cat*, 3rd edn. Philadelphia, W.B. Saunders, p. 45.
- Schulman A.J., Lippincott C.L. (1988) Canine cauda equina syndrome. *Comp. Cont. Ed. Pract. Vet.* **10**, 835.
- Sisson A.F., LeCouteur R.A., Ingram J.T., Park R.D., Child G. (1992) Diagnosis of cauda equina abnormalities by using electromyography, discography, and epidurography in dogs. *J. Vet. Int. Med.* **6**, 253.
- Slocum B., Devine T. (1986) L7–S1 fixation–fusion for treatment of cauda equina compression in the dog. *J. Am. Vet. Med. Assoc.* **188**, 31.
- Tarvin G, Prata R.G. (1980) Lumbosacral stenosis in dogs. *J. Am. Vet. Med. Assoc.* **177**, 154.

Fractures and luxations

- Dulish M.L., Nichols J.B. (1981) A surgical technique for management of lower lumbar fractures: case report. *Vet. Surg.* **10**, 90.

- Helphrey M. (1983) Spinal trauma. In: Bojrab M.J. (ed.) *Current Techniques in Small Animal Surgery*, 2nd edn. Philadelphia, Lea & Febiger 577.
- Lewis D.D., Stampley A., Bellah J.R., Donner G.S., Ellison G.W. (1989) Repair of sixth lumbar fracture-luxations, using transilial pins and plastic spinous process plates in six dogs. *J. Am. Vet. Med. Assoc.* **194**, 538.
- Shores A. (1992) Fractures and luxations of the vertebral column. *Vet. Clin. N. Am.* **22**, 171.
- Shores A., Nichols C., Koelling H.A., Fox W.R. (1988) Combined Kirschner-Ehmer apparatus and dorsal spinal plate fixation of caudal lumbar fractures in dogs: biomechanical properties. *Am. J. Vet. Res.* **49**, 1979.
- Slocum B., Rudy R.L. (1975) Fractures of the seventh lumbar vertebra in the dog. *J. Am. Anim. Hosp. Assoc.* **11**, 167.
- Smeak D.D., Olmstead M.L. (1985) Fracture/luxation of the sacrococcygeal area in the cat. A retrospective study of 51 cases. *Vet. Surg.* **14**, 319.
- Ullman S.L., Boudrieau R.J. (1993) Internal skeletal fixation using a Kirschner apparatus for stabilisation of fracture/luxations of the lumbosacral joint in six dogs. *Vet. Surg.* **22**, 11.

Neoplasia

- Nafe L.A., King G.K., Hulse D.A., Taylor H.W. (1983) An enlarged intervertebral foramen associated with an anaplastic sarcoma in a dog. *J. Am. Anim. Hosp. Assoc.* **19**, 299.
- Schueler R.O., Roush J.K., Oyster R.A. (1993) Spinal ganglioneuroma in a dog. *J. Am. Vet. Med. Assoc.* **203**, 539.
- Shores A., Kazacos E., Parker A.J., Cantwell H.D. (1984) Meningeal sarcoma mimicking a sciatic neuropathy in a dog. *J. Small Anim. Pract.* **25**, 719.

Miscellaneous

- Gilmore D.R. (1986) Lumbosacral pain in the dog. *Canine Pract.* **13**, 6.
- Gilmore D.R. (1987) Lumbosacral disk spondylitis in 21 dogs. *J. Am. Anim. Hosp. Assoc.* **23**, 57.
- Lang J., Hani H., Schawalder P. (1992) A sacral lesion resembling osteochondrosis in the German shepherd dog. *Vet. Rad. Ultras.* **33**, 69.
- Moise N.S., Flanders J.A. (1983) Micturition disorders in cats with sacrocaudal vertebral lesions. In: Kirk R.W. (ed.), *Current Veterinary Therapy VIII* Philadelphia, W.B. Saunders, p. 722.

CHAPTER 15

Medical and Conservative Therapy

Contents

<i>Introduction</i>	215
<i>Antibiotic treatment of spinal disease</i>	215
<i>Corticosteroid therapy of spinal disease</i>	217
<i>Other treatments</i>	219
<i>Conservative therapy of mild disc-associated symptoms</i>	220
<i>Associated reading</i>	221

Introduction

There are many lesions of the spinal cord or vertebral column for which surgical treatment has no effect on the outcome and is therefore inappropriate. For these types of lesion, medical treatment sometimes has a part to play. There is only a limited number of drugs which are useful in medical treatment of spinal conditions.

Conditions for which surgery has no role include vascular lesions (e.g. fibrocartilaginous embolization) and inflammatory or infectious conditions of the spinal cord. Conditions for which surgery may also be inappropriate include those traumatic lesions in which the clinical signs are mild and self limiting. Deciding whether medical or surgical therapy is most appropriate can, in some cases, be difficult and may vary with the experience and temperament of the surgeon. For some patients, although initial medical treatment may be advisable, if clinical signs progress or fail to resolve then surgery can become a second line of treatment, for instance in the management of discospondylitis or type II disc protrusion. Physical therapy is an important part of the management of animals with dysfunction of the spinal cord, although the means are relatively crude compared with those available for treatment of human patients. Physical therapy is considered in more detail in the section dealing with postoperative care.

Antibiotic treatment of spinal disease

The use of antibiotics in spinal disorders is limited almost exclusively to treatment of lesions of the extradural tissues, most commonly the vertebrae and the disc space. Bacterial infection is rarely encountered within the dural sac, and even more rarely does it involve the neural tissue itself. Theoretical considerations regarding the penetration of antibiotics into the neural tissue are therefore not often clinically relevant. There is a blood–spinal cord barrier, similar to that separating the brain and blood, which impedes the passage of certain drugs into

CSF and neural parenchyma. On the rare occasions in which infection is present in the subarachnoid space these considerations may arise, although selection of antibiotic in most cases will be determined by culture and sensitivity testing of appropriate samples. Bacterial infections in the subarachnoid space are usually the result of a penetrating injury and the correct antibiotic can be determined from culture of material obtained either from the CSF or from sites outside the vertebral column. Before sensitivity results are available, it is prudent to treat intradural infections with a bacteriocidal antibiotic which achieves good penetration into the CSF. In general, the more lipid-soluble antibiotics with lower polarity are better distributed in the CSF and spinal cord. These antibiotics include chloramphenicol and trimethoprim. However, the blood-spinal cord barrier will often be impaired as a result of inflammation enabling other less lipid-soluble antibiotics to cross more readily into the CSF and spinal cord parenchyma.

Several types of infection may warrant treatment with antimicrobial drugs: (i) bacteria, including spirochaetes such as *Borrelia*; (ii) fungal agents such as *Cryptococcus* among others (in the USA); (iii) protozoal agents such as *Toxoplasma* and *Neospora*; and (iv) rickettsial infections (USA).

The most common use of antibiotics in spinal disease is in the treatment of discospondylitis. In discospondylitis, it is usual to assume that the infection is a penicillin-resistant staphylococcus, unless culture has shown otherwise. Culture material in cases of discospondylitis can be obtained from the lesion itself or in many cases from a blood or urine culture. The most common bacterial pathogen in most series is *Staphylococcus intermedius* or *S. aureus*, although *Brucella canis* has also been isolated in cases in the USA. Although some reports have suggested that discospondylitis be treated with surgery and then antibiotics, other authors suggest that response to antibiotics and analgesics alone is usually as good. These authors suggest that surgery should be reserved for the unusual cases in which medical therapy has been unsuccessful.

Treatment, as for any bone infection, must be prolonged, often for as long as 3 months. Failure to respond adequately to antibiotics within a suitable period is indication for surgical exploration of the lesion and collection of a specimen for culture. Because of the pain associated with discospondylitis, the concurrent use of non-steroidal anti-inflammatory drugs is often warranted. Suitable antibiotics for treatment of discospondylitis are based on the premise that the infecting bacterium is resistant to normal penicillin, therefore agents such as cephalosporins or potentiated amoxycillin are most suitable.

Surgical treatment should be carried out cautiously if indicated for investigation and treatment of discospondylitis, because there may be instability of the vertebral column resulting from bone destruction. Myelography is advised prior to surgical intervention in order to identify space-occupying lesions which may require removal. Care should be taken prior to surgery to identify suitable means of postoperative stabilization of the surgical area. Surgical treatment should be limited where possible to curettage for the purpose of obtaining a specimen for culture. In certain cases it may be possible to obtain enough material from needle aspirates, particularly if fluoroscopy is available.

Foreign bodies have been associated with the development of discospondylitis in certain cases and surgical treatment will ultimately be required in such cases for removal of the inciting agent. Other rare cases requiring surgery and antibiotic

therapy include those in which a discrete abscess has formed. Cases have been recorded in which epidural or subdural abscesses have been the cause of cord dysfunction – myelography can be used to identify such space-occupying lesions.

Borrelia, the causative organism of Lyme disease, can be eliminated by use of a variety of drugs including tetracycline and penicillin. Lyme disease has recently been identified in many parts of the world, including the UK, where its distribution has become increasingly widespread. Borreliosis can give rise to neurological symptoms in some affected dogs; the agent gains entry to the CNS itself (as evidenced by intrathecal antibody production), therefore antibiotics which penetrate the blood–CNS barrier are preferred.

Protozoal infections are sometimes suspected to be the cause of spinal cord dysfunction but are rarely proven as a definite cause. However, it is often useful to give treatment for these conditions where another definite cause cannot be elucidated. The most commonly incriminated organism is *Toxoplasma*. However, some doubt has been cast on the prevalence of this infection, with the recent discovery of the *Neospora* organism; nevertheless, therapy for infection by either of these organisms is the same. The best treatment is a combination of potentiated sulphonamides and the antimalarial drug pyrimethamine. Both of these drugs can penetrate sufficiently well into the CSF to be able to eliminate infection. Clindamycin can also be used, especially in cats.

In the USA there are a large number of rickettsial infections of the nervous system which may require treatment, e.g. Rocky mountain spotted fever, ehrlichiosis. Treatment of these infections is with tetracyclines. Prognosis can be good if infection is detected at an early stage.

Fungal infections are rarely encountered in the UK but are found in some other parts of the world, e.g. southern states of USA. These diseases are frequently rapidly progressive and often fatal. Treatment with antifungal drugs is problematic owing to their poor penetration into the theca, their toxicity and the aggressive nature of the infections. Although prognosis is usually poor, successful treatment of some of these infections has been recorded.

Corticosteroid therapy of spinal disease

Corticosteroids have long been used in the therapy of spinal diseases, both to treat the cord itself and also as a means of relieving symptoms of pain associated with some of these diseases.

Use of steroids in acute spinal cord injury

Corticosteroids have been used in attempts to resolve the oedema and reduce the inflammation and vascular lesions which occur following acute cord injury. Recent work has demonstrated no benefit from the use of corticosteroids in clinical or experimental situations except in very limited circumstances. The exception is the use of methylprednisolone (MP) at a specific dosage (30 mg/kg) within the first 8 h of the trauma occurring followed by 5.4 mg/kg/h for 23 h. Use of dexamethasone at any time, except before the injury occurs, has not been demonstrated to have any beneficial effect on the rate or extent of recovery of the acutely injured spinal cord.

Furthermore, dosages of MP other than that recommended have not been shown to be beneficial and can be associated with a poorer prognosis. Use of MP after the 8-h period can also be associated with a poorer return of function.

Many other drugs have been tried in the therapy of acute cord injury, including naloxone, DMSO, reserpine and thyrotropin; none of these has consistently shown a beneficial response. Calcium channel blockers are currently under test at several institutions. Although they may be efficacious in ameliorating the effects of cord injury, many have undesirable systemic side-effects and therefore are not yet available for clinical use. More encouraging has been the research into the mechanism of action of MP which suggests that it acts by the inhibition of free radical formation. The part of the molecule responsible for protection against free radical injury is independent of its corticosteroid activity and so research is continuing in order to identify molecules which will separate the actions completely. One of the problems associated with use of corticosteroids at high dosages is the development of side-effects such as gastrointestinal tract ulceration, which can result in severe and even life-threatening haemorrhage. These newly developed compounds, which are related to MP, are known as lazaroids or aminosteroids and should be free of these side effects. They are currently undergoing clinical testing in human subjects.

Use of corticosteroids in chronic spinal cord compression

Corticosteroids (CS) can also be used in therapy of more chronic conditions such as long-term cord compression caused by discs or tumours. The effect of steroids in these cases can be quite dramatic, owing to their effects in reducing the zone of oedema surrounding such lesions and thereby decreasing their compressive effect. This anti-oedema effect has been found to be associated with anti-prostaglandin effects and is shared by some nonsteroidal anti-inflammatory drugs. However, use of corticosteroids in chronic cord compression is probably more helpful as a diagnostic tool rather than as a treatment, although some aged dogs affected by the wobbler syndrome, or other type II disc disease may be best treated by these. In some cases in which there is some doubt regarding the significance of a type II disc lesion on the overall neurological status of the animal (e.g. in the German shepherd dog with type II thoracolumbar disc lesion plus suspected concurrent degenerative myelopathy) treatment with CS can help to determine the significance of each. If the dog improves with CS therapy then the disc protrusion is likely to be significant.

Some clinicians feel that the use of CS (again preferably MP) just prior to surgery can help to alleviate the effects of iatrogenic injury to the neural structures resulting from intraoperative manipulations or the formation of free radicals following decompression of previously compromised tissues (i.e. that resulting from reperfusion injury). Experience of operating without perioperative use of any CS drugs suggests that they are not necessary. Animals appear to recover just as quickly without CS as with and, furthermore, there is a definite reduction in the incidence of postoperative melaena. If a surgeon feels that intraoperative manipulation was sufficient to cause problems, then MP can be given following or during surgery as a precaution with the expectation that a good response to the drug can still be obtained.

Deleterious effects of CS given at the time of surgery can include the development

of gastrointestinal ulceration. Although it is possible to protect the gastric mucosa to some extent by use of histamine H₂ antagonists (e.g. cimetidine), ulceration of other areas of the gastrointestinal tract (e.g. colon) can still occur. It has been suggested that the high incidence of ulceration following disc surgery when combined with dexamethasone therapy may be the result of a number of factors, including transient hypotension and the stress associated with surgery, as well as the drug itself.

Other treatments

Nonsteroidal anti-inflammatory drugs (NSAIDs)

These drugs can be used as part of the therapy for dogs exhibiting spinal pain, such as those affected by discospondylitis, disc extrusions or disc protrusions. In general, the pain relief afforded by these drugs in pain of neurological origin, i.e. entrapped nerve roots or meningeal inflammation, is not as good as that obtained from use of CS. However, the side-effects of NSAIDs are less widespread and if a positive response is obtained then they are preferable for long-term treatment. A major problem in their use is that often it can be desirable to use CS drugs if NSAIDs do not work and there have been a number of reports of serious complications from the concurrent use of the two types of drugs. In common with CS, when NSAIDs are used in the treatment of dogs exhibiting pain alone as a result of disc extrusion, care must be taken to ensure that dogs are limited strictly in their activity, i.e. cage rest only. The relief of pain in these cases can lead to excessive activity on the part of the dog resulting in exacerbation of symptoms.

Diazepam

This drug has been recommended as a treatment for an ambulatory dog which has an acute disc extrusion, as a means of reducing painful muscle spasm. A potential problem is that the muscle spasm helps to reduce movement of the affected area of the spine and reduction in this stiffness may tend to exacerbate the underlying condition.

Acupuncture

This means of physical therapy is claimed by some authors to give good response in cases of acute disc injury to the cord. It can also be helpful in relief of pain associated with disc disease. The means of action of acupuncture are still largely undetermined but the postulated changes in blood flow and release of endorphines which are thought to occur may be beneficial at certain stages of the healing process. The great advantages of acupuncture are that it is cheap and relatively free of harmful effects. Reports on accurate trials of acupuncture versus conventional therapy are not available.

Chemonucleolysis

Chemonucleolysis is the chemical dissolution of the intervertebral disc and has been used as an alternative to surgery in selected human patients. Two enzymes have been used – chymopapain and collagenase. Enzyme is introduced into the nucleus of the disc by means of a needle. Either fluoroscopic guidance or a surgical approach can be utilized to ensure correct positioning. Following injection of the enzyme there is a reduction in disc width (height). Beneficial results are thought to be the result of reduction in size of disc protrusions and denervation of the annulus fibrosus. Only certain human patients are potential candidates for this technique and the use of similar guidelines may limit the use of chemonucleolysis in dogs. For instance, enzymes are inappropriate for treatment of patients with 'sequestered' material, i.e. disc material which is free in the vertebral canal, or those suffering severe neurological dysfunction. The main proposed uses in dogs would be as a treatment for dogs which have type II disc protrusions at the lumbosacral junction or perhaps for type II discs elsewhere. Chemonucleolysis may also have an indication in dogs which would otherwise be fenestrated. Following chemonucleolysis there may be a danger that 'redundant' annulus fibrosus could still form a source of continued spinal cord or nerve root compression.

There have been many experimental studies on chemonucleolysis in dogs, which have established the feasibility of the technique. The results in a series of dogs with clinical symptoms associated with type II disc protrusions at the lumbosacral junction have been reported and are quite encouraging. One further remaining problem with the technique is the high cost of the enzyme.

Conservative therapy of mild disc-associated symptoms

Many animals, especially dogs, are presented for treatment of very mild traumatically induced lesions of the spinal cord. Commonly, such lesions will be the result of disc extrusions. For mildly affected patients surgery is not warranted as it will not affect the speed or extent of recovery. These cases will therefore receive conservative therapy. Mildly affected cases are those exhibiting pain only, or pain plus moderate paraparesis, but the animals are still able to walk unassisted.

Conservative therapy in these cases entails strict confinement, i.e. in a cage or similar enclosed space, in order to prevent exercise which may cause further extrusion of nuclear material. The use of children's playpens is not recommended as there is a tendency for dogs to stand on their hindlimbs in order to see out, or even to attempt to climb out. Some animals can be suitably managed at home but the owner must be advised in detail regarding the treatment and of what to do should the condition deteriorate. In general, treatment as an outpatient is more appropriate for dogs that have cervical disc extrusions because there is no great risk of rapid progression of neurological symptoms.

Most thoracolumbar cases are best treated in the hospital, permitting close observation, repeated neurological examination and the administration of analgesics as required. Many such cases are treated with corticosteroids but, as previously mentioned, their use is probably mostly as an analgesic rather than curative. The practice of treating animals which have thoracolumbar disc lesions with CS and

then discharging them to the owners' care is not to be recommended. The main problem is that with analgesic treatment the dogs feel better (without the normal limitation on exercise imposed by spinal pain) and therefore attempt their normal activity. This can lead to exacerbation of the existing condition and frequently is associated with the deterioration of a moderately paretic animal to a state in which it is unable to walk and requires emergency surgery, or worse still, progression to the stage of deep pain negative paraplegia. This progression is frequently observed following such a treatment regime.

The advised treatment would therefore be either to treat the animals at home by enforced rest/confinement without any drug treatment, or to admit the dog to a hospital kennel and allow the administration of analgesics and/or muscle relaxants. The period of rest in the kennels should be determined by the dog's progress but would normally entail a stay of at least 5 days. The owners must be advised of the possibility of recurrence or progression of the condition, i.e. either pain, paresis or both and the possible benefits of prophylactic surgery. The normal recommendation is to allow the dog two episodes of back pain before recommending fenestration but this may be altered in specific circumstances, such as very young chondrodystrophic dogs exhibiting signs of back pain (i.e. those with very high risk of recurrence). Attempts to make a specific diagnosis in these cases need only be fairly limited. The use of plain radiographs alone is suitable because many of the differential diagnoses will be associated with changes seen in plain films. The absence of abnormalities is supportive but not diagnostic of disc disease. The failure of conservative therapy to produce improvement in symptoms over a relative short period of time should lead to more effort in diagnosis. The routine use of myelography for animals exhibiting mild spinal pain of short duration cannot be recommended because the findings would not alter the treatment offered to such animals.

Associated reading

- Bracken M.B., Shepard M.J., Collins W.F., Holford T.R., Baskin D.S., Eisenburg H.M., Flamm E., LeoSummers I., Maroon J.C., Marshall I.F., Pert P.L. Jr., Piepmeyer J., Sonntag U.K.H., Wagner F.C. Jr, Wilberger J.L., Winn H.R., Young W. (1992) Methylprednisolone or naloxone treatment after acute spinal cord injury: 1 year follow-up data. (NASCIS 2) *J. Neurosurg.* **76**, 23.
- Crawford L.M., Wilson R.C. (1982) Melaena associated with dexamethasone therapy in the dog. *J. Small Anim. Pract.* **23**, 91.
- Dow S.W., Rosychuk R.A.W., McChesney A.E., Curtis C.R. (1990) Effects of flunixin and flunixin plus prednisone on the gastrointestinal tract of dogs. *Am. J. Vet. Res.* **51**, 1131.
- Editorial (1990) Steroids after spinal cord injury. *Lancet* **336**, 279.
- Hall E.D. (1992) The neuroprotective pharmacology of methylprednisolone. *J. Neurosurg* **76**, 13.
- Hoerlein B.F., Redding R.W., Hoff E.J., McGuire J.A. (1983) Evaluation of dexamethasone, DMSO, mannitol and solcoseryl in acute spinal cord trauma. *J. Am. Anim. Hosp. Assoc.* **19**, 216.
- Hoerlein B.F., Redding R.W., Hoff E.J., McGuire J.A. (1985) Evaluation of naloxone,

- croctin, thyrotropin releasing hormone, methylprednisolone, partial myelotomy and hemilaminectomy in the treatment of acute spinal cord trauma. *J. Am. Anim. Hosp. Assoc.* **21**, 67.
- Janssens L.A.A. (1991) Therapeutic aspects of acute spinal cord trauma. *J. Small Anim. Pract.* **32**, 620.
- Moore R.W., Withrow S.J. (1982) Gastrointestinal haemorrhage and pancreatitis associated with intervertebral disk disease in the dog. *J. Am. Vet. Med. Assoc.* **180**, 1443.
- Rucker N.C. (1990) Management of spinal cord trauma. *Prog. Vet. Neurol.* **1**, 397.
- Vonderhaar M.A., Salisbury S.K. (1993) Gastroduodenal ulceration associated with flunixin meglumine administration in three dogs. *J. Am. Vet. Med. Assoc.* **203**, 92.
- Young W., DeCrescito V., Flamm E.S., Blight A.R., Gruner J.A. (1988) Pharmacological therapy of acute spinal cord injury: studies of high dose methylprednisolone and naloxone. *Clin. Neurosurg.* **34**, 675.

Acupuncture

- Janssens L.A.A. (1985) The treatment of canine cervical disc disease by acupuncture: a review of thirty-two cases. *J. Small Anim. Pract.* **26**, 203.
- Janssens L.A.A., DePrins E.M. (1989) Treatment of thoracolumbar disk disease in dogs by means of acupuncture: a comparison of two techniques. *J. Am. Anim. Hosp. Assoc.* **25**, 169.
- Still J. (1989) Analgesic effects of acupuncture in thoracolumbar disc disease in dogs. *J. Small Anim. Pract.* **30**, 298.

Chemonucleolysis

- Atiola M.A.O., Cockshutt J.R., McLaughlin R., Cochrane S., Pennock P.W. (1993) Collagenase chemonucleolysis – a long term radiographic study in normal dogs. *Vet. Radiol. Ultras.* **34**, 321.
- Fry T.R., Johnson A.L. (1991) Chemonucleolysis for treatment of intervertebral disk disease. *J. Am. Anim. Hosp. Assoc.* **199**, 622.
- Miyabayashi T., Lord P.F., Dubielzig R.R., Biller D.S., Manley P.A. (1992) Chemonucleolysis with collagenase. *Vet. Surg.* **21**, 189.

CHAPTER 16

Postoperative Care and Physical Therapy

Contents

<i>Introduction</i>	223
<i>Pain</i>	223
<i>Recumbency</i>	224
<i>Management of incontinent animals</i>	227
<i>Physiotherapy</i>	228
<i>Associated reading</i>	230

Introduction

Animals affected by disease of the spine, and those which have undergone surgery of the spine, often require very demanding nursing attention. Many of these patients are not fully mobile and may be unable fully to control urination and defaecation. Pre- or post-operative pain may also complicate nursing care, because it will tend to make the animal more apprehensive and therefore less easy to handle. Those animals which are recumbent for long periods of time will also be at risk of long-term complications such as severe muscle wasting, pneumonia, urinary tract infection and bedsores (decubital ulcers). Attentive nursing care and properly applied physical therapy can aid in reducing the incidence and severity of these problems.

Items of special concern in nursing patients with spinal disease are (i) pain; (ii) recumbency and its attendant problems (pneumonia, faecal/urinary soiling, bedsores, limb oedema, muscle wasting; and (iii) urinary infection.)

Pain

Many spinal disorders can be extremely painful, especially in those cases in which there is compression of the nerve roots. Although surgery can be very effective in reducing pain in the spine there is frequently a short period of postoperative pain suffered by the patient. The use of opiate analgesics is almost mandatory as most other analgesics are not sufficiently potent to alleviate this type of pain. Recently, however, clinical trials with carprofen, a nonsteroidal anti inflammatory drug (NSAID), have shown it to be equally effective as pethidine following surgery. The perioperative use of carprofen and opiate analgesic together is both possible and desirable.

Postoperatively it is sensible to use analgesics that do not cause too much

sedation, for example the use of methadone instead of morphine, so as to allow better assessment of the animal's neurological status and to allow it more ability to exercise for itself. After the immediate period of postoperative pain – about 48 h – nonsteroidal analgesics can be substituted for the opiates. The duration of nonsteroidal drug use can be varied depending on the patient but many animals benefit from use of these drugs over a long period, as they encourage mobility by eliminating some of the associated pain.

Although some pain is to be anticipated following spinal surgery, its severity should quickly subside if the operation has been carried out correctly and there are no complications. The return of pain in an animal which has previously exhibited improvement following surgery should be considered serious and an indication of possible implant failure, subluxation, infection or another postoperative complication, depending on the type of surgery that was carried out.

Recumbency

The complications of recumbency may fall into early and late categories. Early complications include the possibility of pneumonia, and urinary and faecal soiling. Later complications of recumbency include bedsores, limb oedema and muscle wasting.

Pneumonia

Pneumonia is a particular risk for recumbent animals owing to the tendency to develop stasis of blood in dependent areas of lung. This can lead to rupture of delicate capillaries. The exudate and extravasated blood associated with such a process is an excellent culture medium for opportunist bacteria and bacterial pneumonia can easily supervene. However, sterile pneumonia (hypostatic pneumonia) can also occur and can be fatal in itself. Frequent percussion of the thoracic wall, especially using cupped hands, encourages coughing and can aid in mobilizing pooled secretions in the bronchial tree (Figure 16.1). Changing the position of an animal in recumbency will also reduce the likelihood of pneumonia and should be done frequently, i.e. three to four times per 24 h. When dogs bark they will re-expand semi-collapsed areas of lung and clear secretions from the bronchi, thereby reducing the potential risk of development of pneumonia. Dogs may sometimes be encouraged to bark by allowing them to see other animals in the vicinity.

Soiling with urine or faeces

This type of soiling is more likely in patients that have compromised continence and reduced ability to change position. In some cases it can be difficult to ascertain whether an animal is truly incontinent when kept in a cage because of its difficulty in moving from the soiled area. Animals in the immediate postoperative period are more likely to become soiled owing to their reduced state of consciousness. Soiling of the coat causes a greater incidence of skin sores, particularly on the ventral abdominal skin or in the perineal region, associated with urine scalding. The use of fleecy bedding such as Vetbed, which allows only unidirectional liquid flow (away

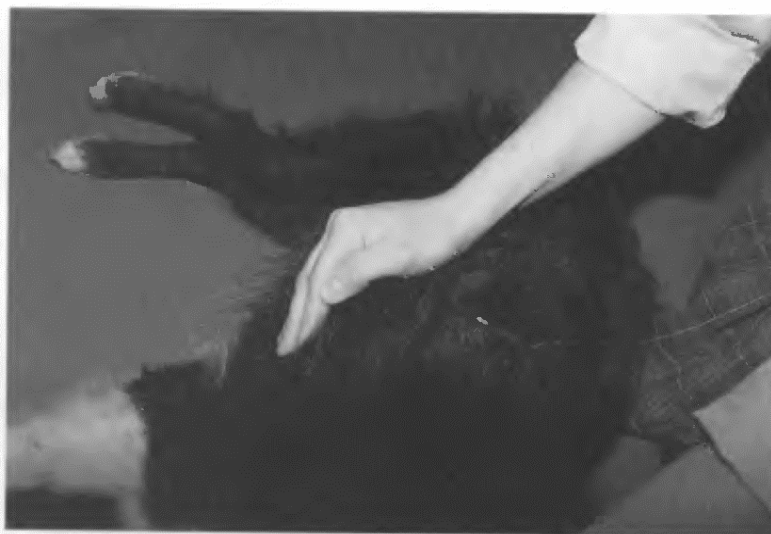

Figure 16.1 *Physiotherapy for the lungs by means of chest wall percussion. Note the cupped shape of the hand.*

from the animal) is very helpful for such patients. Frequent bathing followed by proper and effective drying may be required for some patients.

Bedsores

Bedsore (also known as decubital ulcer) are deep ulcers in the skin and underlying tissues which may develop following long-term recumbency and usually form over prominent areas of bone such as the greater trochanter or lateral aspect of the elbow. In common with most postoperative problems, it is preferable to avoid the complication rather than to treat it following its development. Prevention of bedsore consists of keeping the skin and coat clean and dry, frequent turning of the patient to prevent one area from taking the weight for prolonged periods, together with massage of the prominences to encourage sluggish circulation. Bedsore can be very difficult to treat if they develop and can lead to other complications such as systemic infection. Severe bedsore may require plastic surgery for reconstruction of the skin deficits. The use of padded bedding or waterbeds helps to redistribute the weight of the animal more evenly and can reduce the incidence of bedsore. A cheap, effective bed for such patients can be made by covering foam rubber blocks with plastic-coated sheeting; the plastic coat can be easily cleaned, while the padding will function to distribute the animal's weight more effectively and protect against bedsore (Figure 16.2).

Limb oedema

Limb oedema will develop in the recumbent animal as a result of disuse of the limb and the lack of the normal pumping action of the muscles as they contract and relax. Tissue fluid tends to accumulate in the tissues. This complication is most




Figure 16.2 Soft bed suitable for nursing recumbent patient. In order for attending personnel comfortably to handle large recumbent dogs a large kennel is required.

easily observed in areas where there is little soft tissue coverage, such as around the caudal aspect of the hock surrounding the calcaneal tendon. Oedema will impair circulation, which can lead to vascular stasis and thrombosis and ultimately increased rate of local infection or even gangrenous change in severe cases. This complication is more frequently observed in recumbent human patients than in veterinary cases. Massage and passive exercising of the limb help to disperse extra tissue fluid accumulation and stimulate the normal pumping action of the muscles.

Muscle wasting

Muscle wasting will occur in recumbent animals due simply to disuse but can also occur in certain cases of spinal disease as a result of injury to the lower motor neurone system (for example, 'wobblers' dogs which have lesions affecting the C6 or C7 grey matter or nerve roots). It may be difficult to differentiate between these two causes of muscle loss, especially early in the course of its development. Muscle loss due to lower motor neurone involvement cannot be alleviated by physical means, except for treatment of the underlying cause. Muscle loss due to disuse may be minimized by passive exercise and encouragement of active exercise by the patient. Swimming is the best exercise but unfortunately is rarely possible owing to the lack of suitable facilities. Smaller breed dogs may be allowed to swim in large tanks or baths.

Urinary tract infection

Urinary tract infection is a potential complication in any recumbent animal but those that are incontinent are at particular risk. Urine retention can lead to damage of the bladder wall therefore potentiating infection. If bladder distention is severe or prolonged there can also be damage to the smooth muscle of the bladder wall

and subsequent dysfunction of the detrusor reflex. In the incontinent state bacteria are able to gain access at the distal end of the urethra and ascend to the bladder. In neglected cases of cystitis there is a risk that pyelonephritis will develop.

Management of incontinent animals

The management of incontinent animals is somewhat controversial, revolving around the use of catheters. Animals that have upper motor neurone incontinence tend to have bladders that are difficult to express (at least in the early stages) and incontinence is the overflow type. In certain cases affected by lesions of the sacral part of the spinal cord there will also be urinary retention and overflow. Catheterization allows the bladder to be easily emptied. The drawback to catheterization is that it greatly increases the risk of introducing infection into the bladder. In order to reduce this risk, catheterization should be performed as an aseptic technique and the skin surrounding the distal urethra requires proper preparation. If the catheter is to be left in place, it is prudent to use a closed drainage system. This can easily be made by attaching an intravenous fluid giving set to the catheter, with the other end leading to an empty intravenous fluid bag. The collecting bag must be positioned lower than the patient so that urine will drain away from the bladder. Reflux into the bladder must also be avoided when the bag is removed for emptying. Use of antibiotics for prophylaxis of urinary tract infection is not effective in animals in which aseptic conditions are not maintained. Antibiotics should be reserved for treatment of infection should it develop.

The alternatives to indwelling catheterization are intermittent catheterization or manual expression of the bladder. Intermittent catheterization is probably the least desirable option as there is still a risk of introducing infection and no permanent drainage. Manual expression can be difficult to achieve, especially in large-breed recumbent dogs and may still cause urine soiling during bladder emptying. In small patients, care must be taken during manual bladder expression not to rupture the bladder. The risk of bladder rupture is greatest in those patients which have increased sphincter muscle tone and high resistance to emptying. Use of steady, moderate pressure is less likely to injure the bladder. In some patients which have lower motor neurone incontinence manual expression is easy.

Many animals which have incontinence as a result of a thoracolumbar cord lesion will develop an 'automatic bladder' after a period of a few days to a few weeks. When the bladder becomes full and the pressure is increased (by urine accumulation or by manual pressure) the bladder will empty – but not completely. The small amount of urine retention still increases the risk of development of cystitis but at this stage emptying of the bladder by catheter or manually is usually not required, although observation of the urine quality, particularly for signs of infection, is still necessary.

Various drugs can be helpful in correcting dysfunction in micturition. Some upper motor neurone lesions can cause hypertonicity of the sphincter muscle, preventing proper emptying. The tone in the internal urethral sphincter can be reduced by α adrenergic blocking drugs such as phenoxybenzamine (0.5 mg/kg sid to tid). A few days are required to assess the effects. Low blood pressure and its attendant effects on the animal can be observed in some cases. The external urethral

sphincter tone can be reduced by diazepam (2–10 mg tid to qid). Enhancement of detrusor contractility can be achieved by using bethanechol (2.5–10 mg tid); however, care must be taken to ensure that there is no blockage to outflow before it is used. There is some evidence that bethanechol will also cause increase in sphincter tone. For animals in which there has already been development of bladder atony and distention and consequent damage to the smooth muscle, drug therapy is of little benefit. In such cases, the bladder can be permanently decompressed by means of an indwelling catheter which can allow return of function within a few weeks.

Physiotherapy

In small animal patients, physiotherapy is generally given rather haphazardly, but can play an important part in early rehabilitation of spinally injured patients. Simple range of motion exercises carried out as frequently as possible will reduce the incidence of postoperative joint stiffness, limb oedema and muscle wasting. Animals can be encouraged to exercise as soon as they have recovered from surgery, provided the pain has been adequately controlled and the surgical site is stable enough to allow a reasonable range of activities. Although exercise under control is usually helpful to encourage recovery, walking must only be permitted on surfaces that are unlikely to allow the animal to fall and injure itself. Many patients which have undergone spinal surgery are ataxic and paretic and may easily fall on slippery surfaces. Concrete and grass are usually good surfaces but indoor floor coverings such as linoleum can be very slippery, especially when wet. For large dogs, provision of large rubber floor mats can be extremely useful to avoid the risk of injury. Paraparetic animals which are able to attempt to walk, but cannot bear



Figure 16.3 Support for a paraparetic dog may be given by grasping the base of the tail.



Figure 16.4 Alternatively, support may be given by using a towel (or pair of tights) passed under the abdomen.

weight properly, can be encouraged by supporting the hindquarters. A towel passed under the abdomen can be used for this purpose; alternatively, a small dog may be supported by holding the base of the tail (Figures 16.3 and 16.4). Non ambulatory tetraparetic animals are more difficult to deal with, especially large breed dogs. Two people are usually required in order to support them adequately. Various designed home made slings may help and these can be based on a hammock type of construction.

Care may be needed to prevent dogs (in particular) from attempting to carry out activities which are potentially either painful or hazardous to their recovery, such as climbing stairs, fences or jumping. Motivation to try to walk may be provided by offering food titbits. Many animals will more quickly learn to walk again when allowed to return home to the owner's care. They will be in familiar surroundings and will usually attempt to carry out their routine behaviour and interact with other animals and people in the house. Animals will not be encouraged to learn to walk while confined to a cage at the veterinary clinic. However, before discharging the animal it is essential that owners are aware of the burden of care that they are undertaking. It is also prudent to ensure that the patient is recovering as expected and that further intensive medical attention will not be required.

As a guide, animals can be discharged to the owners within 24–48 h following uncomplicated treatment of disc extrusions in either the cervical or thoracolumbar regions – this applies to both fenestration and decompressive surgery. Dogs which have undergone lumbosacral surgery may require rest in a kennel for several days following surgery in order to ascertain that instability at the surgical site is not a problem. Wobbler dogs may require a very variable period of hospitalization ranging from 48 h to several weeks, depending on pre- and post-operative status. Animals that have suffered spinal fractures or luxations will also have variable needs depending on the pre- and post-operative status and stability of

the injured region. In general, animals which have undergone surgical treatment of fractures or luxations can be handled more vigorously and discharged to the owners earlier, than those treated nonoperatively.

Associated reading

- Haskins S.C. (1987) Use of analgesics post operatively in a small animal intensive care setting. *J. Am. Vet. Med. Assoc.* **191**, 1266.
- Haskins S.C. (1992) Post operative analgesia. *Vet. Clin. N. Am.* **22**, 353.
- Krawiec D.R. (1988) Urinary incontinence in dogs and cats. *Mod. Vet. Pract.* **69**, 17-24.
- Moreau P.M. (1991) How do I treat? Functional urinary obstruction. *Prog. Vet. Neurol.* **2**, 80.
- Nolan A., Reid J. (1993) Comparison of the post operative analgesic and sedative effects of carprofen and papaveretum in the dog. *Vet. Rec.* **133**, 240.
- Tangner C.H. (1984) Physical therapy in small animal practice: basic principles and application. *Comp. Cont. Ed. Pract. Vet.* **6**, 933.

Index

- A/O (ASIF) instruments and implants 7
- acquired lumbosacral stenosis *see* lumbosacral stenosis, degenerative acupuncture 219
- α adrenergic blocking drugs 227
- alpha motoneurone 21
- amino caproic acid 107
- aminosteroids 67, 218
- antibiotic treatment of spinal disease 215–17
- anulus fibrosus 14, 15
- aplasia of the dens 77
- arachnoid cysts 74, 81, 82
- arachnoid mater 18
- astrocytoma 135
- atlanto-axial joint 16
- atlanto-occipital joint 16
- atlas 10, 11
- Aujeszky's disease 144
- automatic bladder 227
- axis 10–11, 12

- back splints 126, 197
- beagle, vasculitis diseases in 145
- Bernese mountain dog, vasculitis diseases in 145
- bethanechol 228
- bladder
 - automatic 227
 - function 35
 - nerve supply 36
- block vertebrae 73, 74
- Borrelia* 216, 217
- bridging spondylosis 103
- Brucella canis* 216
- Bucky grids 2, 46
- burrs 6
- butterfly vertebra 74, 76

- calcinosis circumscripta 79
- calcium channel blockers 218
- canine distemper virus (CDV) 45, 60, 143–4
- canine parvovirus 144
- carcinoma 26
- cardiomyopathy 26
- carprofen 223
- cauda equina 20
 - compression 58, 75
 - syndrome 202

- caudal cervical spondylopathy *see* wobbler syndrome
- caudal lumbar region, type I disc extrusions 203–4
- central canal, duplication of 82
- central nervous system (CNS), diagrammatic representation 28
- cerebrospinal fluid (CSF) analysis 3, 60–1
- cervical disc surgery 148–55
 - fenestration 96–7, 148–9
 - indications 96–7
 - laminectomy/hemilaminectomy 153–5
 - lateral approach 152–3
 - ventral slot 149–52
 - complications 151–2
 - prognosis 152
- cervical intumescence 19
- cervical spinal instability *see* wobbler syndrome
- cervical spinal surgery, fractures/subluxations 155–63
 - atlanto-axial subluxation 155, 156
 - in the cat 161
 - atlanto-occipital subluxation 161
 - cervical fixation 161–2
 - diagnosis 155–7
 - mid-cervical subluxation 162–3
 - PMMA and pins in ventral fixation 160, 161–2
 - treatment 157–61
 - dorsal approach 157–8
 - ventral techniques 158–61
- cervical spondylomyelopathy *see* wobbler syndrome
- cervical spondylotic radiculopathy 104
- chemonucleolysis 220
- chorioretinitis 144
- chymopapain 208, 220
- cimetidine 219
- cisplatin 132
- clindamycin 217
- collagenase 220
- computed tomography (CT) 2, 58–9
- conscious proprioception 20
- continuous dorsal laminectomy (CDL) 181
- conus medullaris 18, 20
- corpectomy 198
- corticospinal tract 21
- corticosteroid therapy 217–19, 220
 - in acute spinal cord injury 217–18

- in chronic spinal cord compression 106, 218–19
- in degenerative myelopathy 107
- coxofemoral degenerative joint disease 26
- creatinine phosphokinase (CPK) 45, 60
- Cryptococcus* 216
- cuneate nucleus 20
- cyclophosphamide 132, 133
- cystitis 227
- cysts
 - arachnoid 74, 81, 82
 - marsupialization of 194
 - dermoid 81
- Dachshund
 - thoracolumbar disc lesion 42, 91
 - type I disc disease 86
- decompressive surgery
 - cervical disc lesions 96–7
 - thoracolumbar 188–94
- decubital ulcers 223, 225
- deep pain response 99
- degenerative joint disease (DJD) of the synovial joints 101–3
- degenerative lumbosacral stenosis *see* lumbosacral stenosis, degenerative
- degenerative myelopathy 105–7
- dens 10, 48
 - aplasia/hypoplasia/dysplasia of 77
- dermoid cysts 81
- descending pathways 20
- dexamethasone 217, 219
- diabetes mellitus 27
- diazepam 54, 219, 228
- disc extrusion
 - acute 64
 - traumatic 125
- disc protrusion 87
 - in cats 187
- discogenic pain 16, 149
- discography 58
 - in acquired lumbosacral stenosis 101
- discospondylitis 4, 26, 140–2, 212, 214, 216
- DMSO 218
- Dobermann pinschers
 - blood clotting disorders 182
 - cervical vertebral canal stenosis 77, 78
 - thoracic vertebral canal stenosis 78
 - type II disc protrusion 90
 - von Willebrand's disease 45, 182
 - wobbler 41, 169, 170, 171
- domino effect 184
- dura mater 18, 19
- dural hooks 5
- dural ossification 104–5
- durotomy 114
- dysplasia of the dens 77
- dysraphism 79
- durotomy of thoracolumbar spinal cord 193–4
- ehrlichiosis 217
- electrodiagnostics 61
- electromyography (EMG) 3, 61
- encephalitis 142
- endocarditis 26
- English bulldog, myelocoele in 77
- ependymomas 135, 136
- epidurography 57
 - in acquired lumbosacral stenosis 101
- epilepsy 155
- extradural lesions 50
- extramedullary lesions 50
- facetectomy 209
- fasciculi, dorsal and lateral 20
- feline infectious peritonitis virus (FIP) 144
- feline leukaemia virus (FeLV) 128, 132
- fenestration 96
 - cervical 148–9
 - in lumbosacral stenosis 204–5
 - thoracolumbar 194–5, 196–7
 - in wobbler syndrome 177
- fibrinoid metaplasia 86
- fibrocartilaginous embolization (FCE) 25, 138–9, 140, 204, 215
- fibrosarcoma 132
- foraminotomy 209
- fungal infections 217
- Funquist dorsal laminectomy 6, 190
- gelatin sponge (Gelfoam) 7
- Gelpi 4
- German shepherd dogs
 - cauda equina compression 75
 - degenerative myelopathy in 105
 - osteochondrosis 212
 - osteosarcoma 129
 - type II disc lesions in 218
- glia 19
- globoid cell leukodystrophy 81–2
- goniometers 7
- gracile nucleus 20
- granulomatous meningoencephalitis 145
- great Danes
 - overnutrition 169
 - wobbler 169
- haematoma 132
- haemorrhage, idiopathic spinal cord 139
- hemilaminectomy 114, 198
 - cervical 153–5
 - thoracolumbar 188, 191–3
- hemivertebrae 73–4, 75, 198
- herpes virus 144
- hip dysplasia 26

- Horner's syndrome 41
 hound ataxia 107
 hydrocephalus 83
 hydromyelia 80, 82, 83
 5-hydroxy tryptamine (5HT) 67
 hyperadrenocorticism 27
 hypoplasia of the dens 77
- incontinent animals, management of 227-8
 index of suspicion 25, 91, 143
 instrumentation 1-8
 - diagnostic equipment 1-3
 - imaging 1-3
 - neurological examination 1
 - haemostatic agents 6-7
 - bone wax 6
 - patties 7
 - surgical cellulose 7
 - operating room 3-6
 - diathermy 5
 - lighting 3
 - magnification 3
 - microsurgery 4-5
 - powered instruments 5-6
 - suction and irrigation 5
 - surgical instruments 4-5
 - table 3
 - orthopaedic 7-8
- intermittent claudication 90, 100
 intervertebral discs (IVD) 14-16
 - nerve supply 15-16
- intervertebral joints, anatomy 14-16
 intervertebral synovial joints 16
 intradural lesions 50
 intraosseus vertebral venography 57-8
 inverted cone decompression (modified slot)
 - technique 4, 177
- investigation of spinal disease 24-43
 - history 24-6
 - intercurrent/recent disease 25-6
 - lateralization 25
 - progression of symptoms 25
 - rapidity of onset of symptoms 25
 - response to previous treatment 25
 - signalment 25
 - localization of lesions 41-3
 - surgical spinal disease 42-3
- neurological examination 27-41
 - bladder function 35
 - gait 28
 - head examination 37-41
 - muscle mass and tone 28
 - palpation of the spine 37
 - postural reactions 31-2
 - sensory tests 32-5
 - spinal reflexes 28-31
 - physical examination 26-7
 - attitude 26
 - cardiovascular disease 26
 - endocrine system 27
 - musculoskeletal system 26-7
 - temperature 26
 - urinary tract 27
- Kerrison rongeurs 4
 Kirscher wires 118
 knuckling of the digits 31
 Krabbe's disease 81-2
- laminoplasty 181-2
 laminectomy 114, 209
 - cervical 153-5
 - continuous dorsal (CDL) 181
 - thoracolumbar 188-91
- laminotomy 164-6 Langenbecks retractor 4
 lazaroids 67, 218 Lempert rongeurs 4
 leukoencephalomalacia 107
 leukoencephalomyelopathy (LEM) of Rottweilers 108
- ligaments of vertebral column 16-19
 - long ligaments 17-18
 - dorsal longitudinal ligament 17
 - nuchal ligament 17
 - supraspinous ligament 17
 - ventral longitudinal ligament 18
 - short ligaments 18
 - flaval ligaments 18
 - intercapital ligaments 18
 - interspinous ligaments 18
- lipid peroxidation 66
 loupes 3
 lower motor neurone (LMN) 20
 - deficits 27, 79, 100 Lubra plates 119, 210
- lumbar intumescence 19
 lumbosacral region
 - disorders 27
 - surgery of 202-13
- lumbosacral spondylosis 104
 lumbosacral stenosis 204-9
 - degenerative (acquired)
 - chemonucleolysis 208
 - diagnosis 101
 - discectomy 205-7
 - dorsal fixation/fusion 207-8
 - facetectomy 206
 - fenestration 204-5
 - indications for surgery 99-101, 102
 - treatment 204-9
 - ventral fixation/fusion 208-9
 - idiopathic 204
 - treatment 209
- limb oedema 225-6
 Lyme disease 217
 lymphosarcoma (LSA) 128, 129, 132, 135

- magnetic resonance imaging (MRI) 2, 59
 - in acquired lumbosacral stenosis 101
- Manx cat
 - sacrocaudal hypoplasia 79
 - spina bifida 75
- medulloepithelioma 134
- melphelan 133
- meninges 18
- meningiomas 50, 134, 136
 - extradural 131
 - laminotomy surgical approach 164
- meningitis 60, 77, 81, 97, 107
 - bacterial 142–3
 - non-infectious causes 144–5
 - viral 143–4
- meningocoele 76, 77
- meningomyelocele 76
- methadone 224
- methylprednisolone 66, 69, 99, 125, 139, 198, 217–18
- microdissectors 4, 5
- microscopes, operating 3
- mild disc-associated symptoms 220–1
- mini-hemilaminectomy 198
- mucopolysaccharidosis IV 79–80
- multiple cartilaginous exostosis 79
- multiple myeloma 131, 133
- muscle wasting 226
- mycoses 45
- myelitis 142–5
- myelocoele 77
- myelodysplasia 74
- myelography 49–56
 - in acquired lumbosacral stenosis 101
 - cisternal puncture 2, 51–4
 - in diagnosis 49
 - disc extrusion 95
 - indications 49–51
 - lumbar puncture 2, 54–6
 - of spinal tumour 129
 - in wobbler syndrome 51, 174–6
- myelomalacia 26, 197

- naloxone 67–8, 218
- Neospora* 45, 216, 217
- nephroblastoma 134, 199
- nerve root entrapment 90
- nerve sheath tumours 50
- neuraxonal dystrophy 107–8
- neuroepithelioma 134
- nonsteroidal anti-inflammatory drugs (NSAIDs) 219
- noradrenaline 67
- nucleus pulposus 14, 15, 86

- osteochondromatosis 79, 133
- osteochondrosis 212–13

- osteosarcoma 129, 130, 132


- pain
 - deep 99
 - discogenic 16, 149
 - postoperative 223–4
 - responses 26
- pediculectomy 192
- penicillin-resistant bacteria 141, 216
- phenoxybenzamine 227
- phospholipase A 67
- physiotherapy 228–30
- pia-arachnoid 18
- pia mater 18
- picks 4, 5
- pilonodial ducts 81
- pins and PMMA *see* PMMA and pins
- piotomy 193, 194
- PMMA and pins technique
 - in thoracolumbar fractures and subluxations 197
 - in ventral fixation 160, 161–2, 178–9
 - in vertebral column trauma 117, 118
- pneumonia 224
- polymethylmethacrylate (PMMA) bone cement 7
 - see also* PMMA and pins technique positioning aids 2, 3
- post-myelographic seizures 53, 54
- postoperative care 223–30
- postoperative scarring 7
- postural reactions 31–2
 - conscious proprioceptive positioning 31–2
 - extensor postural thrust 32, 33
 - hemistanding 32
 - hemiwalking 32
 - hopping 32
- sliding paper test 32
 - wheelbarrowing (thoracic limbs) 32, 33
- prednisolone 132
- pupils, examination 41
- pyelonephritis 227
- pyrimethamine 217

- radiography 46–56
 - machine specifications 1–2
 - plain 46–9
 - see also* myelography
- recumbency, complications 224–7
 - bedsores 223, 225
 - limb oedema 225–6
 - muscle wasting 226
 - pneumonia 224
 - soiling with urine or faeces 224–5
 - urinary tract infection 226–7
- reflexes
 - anal 30–1
 - Babinski (extensor toe) 36
 - cranial nerve 38–40

- crossed extensor 30, 36–7
cutaneous trunci muscle (panniculus) 35–6, 37, 42
flexor 30–1, 34
myotatic 28–30
patellar 29, 30
spinal 28–31
reticulosis 128, 145
reticulospinal tract 21
retractors 4
rickettsia infections 45, 216
rongeurs 4
root signature 90
Rottweilers
 leukoencephalomyelopathy (LEM) of 108
 neuraxonal dystrophy 107
rubrospinal tract 21
- sacrocaudal region
 fracture/luxation 211–12
 hypoplasia 79
 surgery of 202–13
sacroiliac articulation 14
sarcoma 26, 212
Schiff-Sherrington phenomenon 37, 42
Schmorl's node 139
seizures, post myelographic 53, 54
sensory pathways 20
sensory tests 32–5
 deep pain response 34–5
 superficial sensation 34
Siamese cat, mucopolysaccharidosis IV in 79
SOAP format of case recording 24
solitary cartilaginous exostosis 79
spaniels, cavalier King Charles, cervical pain 149
spina bifida 75–7, 79
spinal cord
 anatomy 18–22
 anomalies 80–3
 blood supply 21–2
 cerebrospinal fluid (CSF) 22
 cross-sectional anatomy 20–1
 degenerative conditions 105–8
 haemorrhage, idiopathic 139
 see also spinal cord injury; spinal cord trauma,
 fractures and luxations
spinal cord injury
 acute, pathophysiology 64–5, 68
 immediate effects 65
 measuring severity 64–5
 vascular observations 65
 chronic (compressive), pathophysiology 69–70
 secondary injury mechanisms 65–9
 calcium 66, 67
 eicosanoids 67
 free radicals 66–7
 neurotransmitters 67–8
 glutamate 67
 monoamines 67
 opioids 67–8
spinal dysraphism 80
spinal needles 2
spinocerebrallar pathways 20
spinothalamic tract 20, 34
spondylitis 140–2
spondylolisthesis 105
spondylosis 74, 103, 182
spondylosis deformans 103–4
Staphylococcus aureus 216
Staphylococcus intermedius 216
Steinman pins 118, 119, 161
subarachnoid space 19
subluxations see fractures/subluxations
superoxide dismutase 66
sway response 32
syringomyelia 22, 59, 79, 80, 82, 83
- temperament, changed 26
thoracolumbar spine, surgery 187–99
 decompressive surgery 188–94
 developmental disease 198
 disc lesions 89, 90–1, 92–3
 indications for surgery 97–9
 dorsal laminectomy 188–91
 advantages and disadvantages 191
 durectomy 193–4
 fractures and subluxation of 197
 hemilaminectomy 188, 191–3
 advantages and disadvantages 193
 mini-hemilaminectomy 188, 192
 myelotomy 193, 194
 neoplasia 198–9
 pediclectomy 192
 piotomy 193, 194
 prophylactic techniques 194–7
 type II disc protrusions 197–8
thromboembolism, aortic 26
thyrotropin 218
 α -tocopherol 66
Toxoplasma 45, 216, 217
toy poodles
 cervical vertebral canal stenosis 77
 lumbosacral vertebral canal stenosis 77
transilial bar fixation 210
tumours 26, 128–36
 cervical 163–6
 classification by location 129–36
 extradural (epidural) 129–33
 intradural/extramedullary 133–6
 intramedullary 134–6
 lumbosacral 212
 modes of therapy 136
 nerve sheath 50
 prostatic 212



- thoracolumbar 198–9
- vertebral 129
- see also* meningiomas
- ultrasonography 2, 58
- upper motor neurone (UMN) 20
 - lesions 31
- urinary tract infection 226–7
- vascular malformation 82
- ventral slot 177–8
- vertebrae 10
 - anticlinal 12
 - butterfly 74, 76
 - transitional 75
- vertebral body L7 fracture 209–10
- vertebral body plating 116–18
- vertebral canal stenosis 77–9, 182
 - cervical 77–8
 - lumbosacral 78–9
 - thoracic 78
- vertebral column
 - analogy
 - cervical, with crane 9, 10
 - thoracolumbar, with bow and string 9
 - anatomy 10–14
 - cervical 10–12
 - columns of 113
 - disorders of 72–80
 - embryonic development 72–3
 - forces acting through 9
 - ligaments 16–19
 - location of segments 10, 11
 - lumbar 13–14
 - caudal vertebrae 14
 - sacrum 14
 - thoracic 12–13
 - see also* vertebral column, degenerative
 - disorders; vertebral column, fractures and luxations
- vertebral column, degenerative disorders 85–105
 - cervical disc lesions 88–90
 - disc disease 84–8, 92–3, 95
 - clinical signs 88
 - diagnosis 91–6
 - type I 85–6, 87, 94, 95
 - type II 86–7
 - indications for surgery 96–101
 - cervical disc lesions 96–7
 - degenerative (acquired) lumbosacral stenosis 99–101, 102
 - thoracolumbar discs 97–9
 - management 96
 - thoracolumbar disc lesions 89, 90–1, 92–3
- vertebral column, fractures and luxations 111–27
 - bullets/pellets 123
 - conservative management 126–7
 - cord concussion 125
 - diagnosis 112–13
 - hyperextension injuries 124–5
 - reduction methods 114, 115
 - surgical fixation 115–23
 - complications 123
 - cross pins 119, 122
 - external fixation 121–2
 - iatrogenic injury 123
 - malunion/non-union 123
 - pins and polymethylmethacrylate (PMMA) 117, 118
 - recurrent instability 123
 - spinal stapling 119, 120–1
 - spinous process fixation 119
 - vertebral body plating 116–18
 - traumatic disc extrusion 125
 - treatment 113–14
- vertebral neoplasia 129
- vestibulospinal tract 21
- vincristine 132
- vitamin A intoxication 104
- vitamin E 107
- von Willebrand's disease 45, 182
- weight drop model 64
- wobbler syndrome 78, 90, 107, 108, 169–84
 - breeds affected 169–70
 - compressive cord injury 69
 - cord atrophy 174
 - CT in 59
 - diagnosis 171–6
 - differential 176
 - radiological 173–6
 - immature dogs 169–70
 - middle-aged 171
 - prognosis 183–4
 - spondylosis in 104
 - treatment 176–83
 - linear traction and stabilization/fusion 178–80
 - miscellaneous surgical techniques 183
 - multiple dorsal lesions 180–2
 - multiple ventral lesions 182
 - of painful wobblers 182
 - screw and washer distraction technique 180
 - single dorsal lesion 180
 - single ventral lesion 176–7
 - ventral fenestration and lag screw fixation 177
 - ventral slot 177–8
- xanthine dehydrogenase 66
- xanthine oxidase 66




This book is a guide to decision-making and the evaluation of cases of spinal problems in the dog and cat. It is aimed at the non-specialist practitioner, and covers investigation and management (both surgical and non-surgical) of small animal spinal disease. It is logically organized and comprehensively illustrated with line drawings, providing a concise handbook invaluable to all small animal practitioners.

W.B. Saunders Company Limited
24-28 Oval Road
London NW1 7DX, UK

Printed in Great Britain

ISBN 0-7020-1688-8



9 780702 016882 >